



Original Article

Non-Invasive Assessment of Coronary Artery Stenosis with Estimation of Myocardial Wall Stress

Hassan Moladoust, PhD¹, Manijhe Mokhtari-Dizaji, PhD^{1*}, Zahra Ojaghi-Haghighi, MD², Fereidoon Noohi, MD²

¹Department of Medical Physics, Tarbiat Modares University, Tehran, Iran.

²Shaheed Rajaie Heart Center, Iran Medical Sciences University, Tehran, Iran.

Received 16 August 2009; Accepted 15 November 2009

Abstract

Background: More diagnostic techniques require a better understanding of the forces and stresses developed in the wall of the left ventricle. The aim of this study was to differentiate significant coronary artery disease (CAD) patients using a non-invasive quantification of myocardial wall stress in the diastole phase.

Methods: Sixty male subjects with sinus rhythm (30 patients with significant and 30 with moderate left anterior descending coronary artery stenosis in the proximal portion) as well as 35 healthy subjects as the control group were recruited into the present study. By two-dimensional, pulsed wave, and tissue Doppler echocardiography, the average end-diastolic wall stress was calculated at the left ventricle anterior and interventricular septum wall segments using regional wall thickness, meridional and circumferential radii, and non-invasive left ventricular end-diastolic pressure.

Results: A comparison of the calculated end-diastolic myocardial wall stress between the patients with significant and moderate coronary stenosis on the one hand and the healthy subjects on the other showed statistically significant differences in the anterior and septum wall segments (p value < 0.05). The patients with significant left anterior descending coronary artery stenosis had higher end-diastolic myocardial wall stress than did those with moderate stenosis and the healthy group in all the anterior and septum wall segments.

Conclusion: It is concluded that non-invasive end-diastolic myocardial wall stress in coronary artery disease patients is an important index in evaluating myocardial performance.

J Teh Univ Heart Ctr 1 (2010) 29-35

Keywords: Coronary artery disease • Echocardiography • Diagnosis

Introduction

Coronary artery disease (CAD) is the number one killer in the world. As a case in point, each year 650,000 previously asymptomatic patients present in the United States with an acute coronary event as the initial presentation of CAD.¹ Approximately, one-third of individuals dying annually from sudden cardiac death possess no identifiable Framingham risk indices that would predict a future hard cardiac event.²

Therefore, the detection of coronary heart disease early in its course is of great potential importance.

More advanced diagnostic techniques require that one gain a better understanding of the mechanics and performance of the myocardium, and this in turn calls for an analysis of the forces and stresses developed in the wall of the left ventricle (LV).³ Systolic and diastolic wall stress has been previously determined by combining simultaneous measurements of LV pressures with angiographic and echocardiographic

*Corresponding Author: Manijhe Mokhtari-Dizaji, Professor of Medical Physics, Department of Medical Physics, Tarbiat Modares University, Jalal Ale-Ahmad Ave, Tehran, Iran. 1411713116. Tel: +98 21 82883893. Fax: +98 21 88006544. E-mail: mokhtarm@modares.ac.ir

measurements of the LV radius and wall thickness.⁴⁻⁷ This method, in addition to being cumbersome and time-consuming, requires invasive procedures. The non-invasive assessment of LV end-diastolic pressure provides important information on the hemodynamic status⁸ and may be an important clinical tool in these patients, taking advantage of non-invasive quantification of myocardial wall stress in end-diastole. Recently, we demonstrated⁷ the role of Color-Tissue Doppler imaging (TDI) in the estimation of LV end-diastolic pressure (LVEDP) in patients with CAD. We concluded from our study that the ratio of the early transmitral filling velocity (E) to the early-diastolic mitral annular velocity (Ea) as an interesting application of TDI⁹ provided an index of LVEDP.

The aim of the present study was to estimate and compare the non-invasive regional myocardial wall stress in the diastole phase between patients with significant coronary stenosis, moderate coronary stenosis, and healthy subjects.

Methods

Sixty male CAD patients with sinus rhythm (30 with significant and 30 with moderate left anterior descending coronary artery (LAD) stenosis in the proximal portion, aged 53±5 and 52±5 years old, respectively) as well as 35 healthy volunteers aged 51±8 years old were enrolled in the study. Significant and moderate stenosis was defined as more than 70% and between 50-70% stenosis determined by coronary angiograms, respectively. Exclusion criteria included a history of cardiovascular surgery, LV hypertrophy, pacemaker rhythm, severe valvular disease, and diabetes. All the healthy subjects had a normal physical examination, electrocardiography (ECG), normal echocardiography, and no history of cardiovascular disease, angina, hypertension or diabetes, and medication. Blood pressure was recorded in the left radial artery with the patient in supine position using a semiautomatic device (Riester 0124, Germany) before the measurement of the echocardiographic studies. All the subjects gave their informed consent prior to their participation in the study. This study was performed from June 2007 to January 2009 through random sampling and was approved by the ethics committee of Tarbiat Modares University and Shaheed Rajaie Cardiovascular and Research Center.

Invasive coronary angiography was performed by expert cardiologists through the femoral approach, using standard Judkin's technique with 6F catheters. Selective injection of left and right coronary arteries was performed in multiple orthogonal views. The culprit lesion was identified by angiographic criteria for the severity of stenosis. The percent luminal diameter stenosis was derived using the caliper technique by comparing the diameter of the stenosis with that of the most normal appearing region proximal to the stenosis.

Images were acquired and digitally recorded in at least two orthogonal optimal projection angles at 25 frames per second (Siemens Medical Systems, Germany). Between 1 and 2 days after the angiography, transthoracic conventional and tissue Doppler echocardiography examinations were performed.

All the echocardiography studies were conducted with a Vivid7 digital ultrasound scanner (GE, Milwaukee, WI, USA) equipped with an M3S transthoracic sector transducer with harmonic capability. The images were acquired with the subjects at rest and lying in the lateral decubitus position. Two-dimensional ECG was superimposed on the images and end-diastole was considered at the peak R-wave of the ECG. LV ejection fraction (LVEF) was measured using Simpson's biplane method by measuring end-diastolic and end-systolic volumes in two-dimensional 2(D) images. TDI was performed using standard transthoracic apical two- and four-chamber views according to the guidelines of the American Society of Echocardiography (ASE).¹⁰

The sample volume of the pulsed wave Doppler was placed between the tips of the mitral leaflets with the ultrasonic beam aligned to flow in the apical four-chamber view and early transmitral flow velocity was obtained. Color Doppler myocardial imaging (CDMI) was performed by adjusting the signal filters until they reached a Nyquist limit of 16 cm/s. The CDMI raw data were recorded at a depth of 16 cm, frequency of 2.4 MHz, and frame rates higher than 150 frames per second throughout the three cardiac cycles and stored digitally as cine-loop format on the memory of the scanner. Off-line analysis was carried out by the quantitative analysis software equipped to obtain regional myocardial velocity. Digital 5 mm sample volumes were placed within the lateral mitral annulus^{7, 11, 12} and tissue velocity curves were acquired. The wall filter settings were adjusted to exclude high-frequency signals and the gain was minimized, so the onset of the early-diastolic mitral annular velocity could be reliably identified. Echocardiographic analysis was performed by an experienced observer who was unaware of the patient's angiographic outcomes. All the Doppler data were measured at end-expiration, and the average of three cardiac cycles was taken into account for analysis in this study.

The force per unit area of myocardium, or wall stress, is proportional to the LV intra-cavity pressure and LV cavity dimension and inversely proportional to wall thickness.¹³ In this study, the radii and thickness of the LV segments were measured from the apical four- and two-chamber echocardiograms at end-diastole. In these echocardiograms, the septal and anterior wall radii and thickness quantities were measured at base, mid, and apical segments respectively by averaging three consecutive heartbeats. Endocardial meridional and circumferential radii were determined for each wall segment by considering each region to be locally ellipsoidal as described in detail elsewhere (Figure 1).⁴

The average end-diastolic wall stress (σ) was calculated

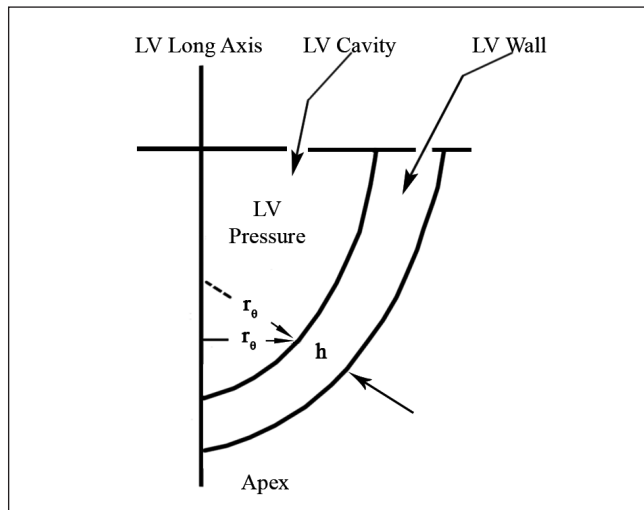


Figure 1. A diagram depicting the variables used to calculate wall stress. An illustration of how local left ventricular (LV) wall geometry can be described by wall thickness (h), endocardial circumferential radius of curvature (r_0) and endocardial meridional radius of curvature (r_θ)

using the formula proposed by Deanda et al.^{14, 15} taking into account regional wall thickness (h), mid-wall meridional (R_θ), and circumferential (R_0) regional radii of the curvature at the equator of each segment and LVEDP:

$$\sigma = 1.332 \times LVEDP \times \frac{R_\theta}{4h} \left(3 - \frac{R_\theta}{R_0} \right)$$

Where R_0 and R_θ are endocardial circumferential radius ($r_0 + \frac{h}{2}$) and endocardial meridional radius ($r_\theta + \frac{h}{2}$), respectively. In this study, non-invasive LVEDP was estimated with lateral early-diastolic color-TDI annular velocity, combined with mitral early velocity by pulsed Doppler echocardiography (lateral E/Ea ratio) as follows by averaging three consecutive heart beats:⁷

$$LVEDP = 1.44 + [1.36 \times (\text{lateral E/Ea})]$$

It has been demonstrated that the correlation coefficient between LVEDP and lateral E/Ea is higher and its limit of agreements (LOA) is lower than those of other mitral segments;^{7, 11, 12} therefore, in this study we applied only lateral E/Ea ratio to the estimation of LVEDP and quantification of myocardial wall stress.

All the data are expressed as mean \pm standard deviation (SD). The data were tested for normal distribution and homogeneity of variance by the Kolmogorov-Smirnov test (K-S) and Levene test respectively. Maximum sample size was estimated on 23 samples with a confidence level of 95% and power of test of 90% in each group. One-way analysis of variance (ANOVA) was used to test the hypothesis that the means of the three study groups were equal and the Post Hoc least significant differences (LSD) test was used for multiple comparisons. The p values were obtained using Student's t -test whenever two groups were compared. P values less than 0.05 were chosen as the levels of statistical significance.

Intraobserver and interobserver variabilities were the

differences between the measurements expressed as a percentage of the error of the means. All the statistical analyses were performed using the SPSS software package (SPSS Inc. Chicago, IL, USA).

Results

The demographic and echocardiographic characteristics of the 95 subjects are presented in Table 1 as Mean \pm SD. The subjects were divided into three groups according to the presence of diameter narrowing as follows: 1) Healthy: no diameter narrowing; 2) Moderate LAD coronary artery stenosis in the proximal portion: diameter narrowing of between 50-70% stenosis ($61 \pm 3\%$ of stenosis); and 3) Significant LAD coronary artery stenosis in the proximal portion: diameter narrowing of more than 70% ($90 \pm 3\%$ of stenosis). The groups were comparable as regards age, heart rate, and body mass index (BMI) ($p =$ non significant).

In Figure 2, radial systolic and diastolic blood pressures are shown for the three groups with significant and moderate LAD stenosis in the proximal portion and healthy subjects. The statistical analysis of the systolic and diastolic blood pressure showed that there were no significant differences between the groups. The reason is that patients with stenosis usually use hypertension drugs (60%) (p value < 0.05).

The results of LVEF% are presented in Figure 3. With the progression of stenosis, the LVEF% was decreased by 11% and 25% compared with that of the healthy group, respectively. There were significant LVEF% differences between the study groups (p value < 0.05).

At the end-diastole phase, the anterior and the septal wall radii (meridional and circumferential radii) and wall thickness quantities measured at base, mid, and apical segments are depicted in Table 2 for the groups with significant and moderate LAD coronary artery stenosis and the healthy subjects.

The statistical analysis of the anterior and the septal wall radii (meridional and circumferential radii) and wall thickness quantities measured at base, mid, and apical segments showed no significant differences between the groups except for the anterior wall thickness in the base, mid, and apex regions, septal wall thickness in the base and mid regions, and the septum meridional radius in the apex region.

Comparisons between the groups (using Student's t -test) demonstrated that the healthy and significant LAD coronary artery stenosis groups were significantly differentiable with the septal wall meridional radius in the mid and apex regions, the septal wall circumferential radius in the base, mid, and apex regions, and hence the anterior wall meridional radius in the base region and the anterior wall circumferential radius in the apex region.

Also, there were significant differences between the healthy and significant LAD coronary artery stenosis groups

Table 1. Characteristics of the subjects*

Variables	Healthy N = 35	Moderate LAD coronary artery stenosis N = 30	Significant LAD coronary artery stenosis N = 30
Age (y)	51±8	52±5	53±5
Stenosis (%)	-	61±3	90±3
Body mass index (kg/m ²)	25±2	25±2	24±2
Heart rate (beats/min)	72±8	74±18	79±14

*Data are presented as mean±SD

LAD, Left anterior descending coronary artery

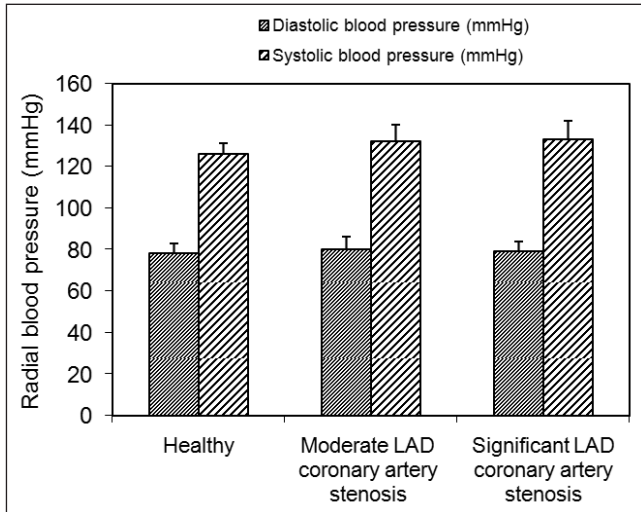


Figure 2. Comparison of radial diastolic and systolic blood pressures in different groups

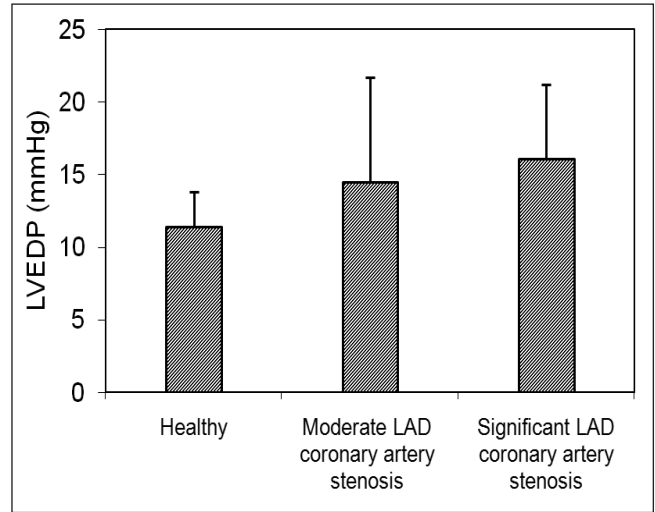


Figure 4. Comparison of non-invasive left ventricular end-diastolic pressures (LVEDP) in different groups

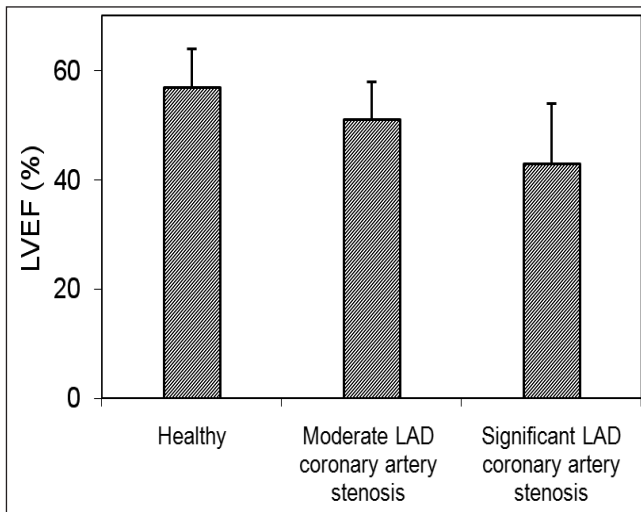


Figure 3. Comparison of left ventricular ejection fractions (LVEF) in different groups

with respect to the septal wall thickness in the base region.

We applied lateral early-diastolic color-TDI annular velocity (E), combined with mitral early velocity by pulsed Doppler echocardiography (Ea), to the estimation of LVEDP and quantification of myocardial wall stress. The results of non-invasive LVEDP estimated for the groups with significant and moderate LAD coronary artery stenosis and healthy subjects are presented in Figure 4.

The statistical analysis of LVEDP demonstrated significant differences between the groups (p value < 0.05). The least significant difference (LSD) analysis of LVEDP parameter to test the significance between the two groups showed that the healthy group was significantly differentiable with significant and moderate LAD coronary artery stenosis, but there was no significant difference between the moderate and significant LAD coronary artery stenosis groups.

The average end-diastolic wall stress (σ) was calculated using regional wall thickness (h), mid-wall meridional (R_m), and circumferential (R_c) regional radii of the curvature at the equator of each segment and LVEDP. The comparisons of the calculated anterior and septum wall stresses between the patients with significant and moderate stenosis and the healthy subjects are shown in Figures 5 (a) and (b), respectively.

The results showed an increase in the end-diastolic myocardial wall stress relating to the progression of LAD coronary artery stenosis. The patients with significant LAD coronary artery stenosis had higher end-diastolic myocardial wall stress than did those with moderate stenosis and the healthy group in all the anterior and septum wall segments (p value < 0.05).

The end-diastolic wall stress averages of the anterior and septum walls in the moderate stenosis and significant stenosis groups were approximately 10% and 40% greater,



Table 2. Comparison of the anterior and the septal wall radii and wall thickness quantities measured at three different segments

Segments		Healthy (N=35)	Moderate LAD coronary artery stenosis (N=30)	Significant LAD coronary artery stenosis (N=30)	p value*	
Anterior wall	Meridional Radius (mm)	Base	29.3±2.0	30.0±3.6	30.8±2.2	0.086
		Mid	29.0±2.8	28.9±3.8	30.5±3.9	0.148
		Apex	21.5±2.6	22.1±3.1	22.7±2.5	0.261
	Circumferential radius (mm)	Base	26.5±2.4	30.1±3.6	30.8±2.2	0.110
		Mid	28.7±2.7	28.9±3.8	28.9±3.8	0.385
		Apex	19.6±2.4	22.1±3.1	22.1±3.1	0.071
	Wall thickness (mm)	Base	10.2±1.3	11.1±1.3	10.9±2.1	0.002
		Mid	10.2±1.8	11.2±1.2	11.2±2.8	0.012
		Apex	10.1±1.5	10.8±1.1	10.2±2.1	0.028
Septal wall	Meridional Radius (mm)	Base	23.1±1.9	23.5±2.7	24.3±2.9	0.206
		Mid	21.0±2.2	21.2±2.4	22.4±3.2	0.087
		Apex	19.3±1.7	19.6±3.6	20.9±2.4	0.045
	Circumferential radius (mm)	Base	22.0±2.0	22.7±2.8	30.5±2.2	0.112
		Mid	20.7±2.3	20.9±2.4	30.5±4.0	0.104
		Apex	18.0±1.5	18.2±3.5	22.7±2.5	0.051
	Wall thickness (mm)	Base	9.2±1.2	10.8±1.4	10.2±1.7	0.000
		Mid	10.3±1.1	11.0±1.0	10.5±1.6	0.006
		Apex	10.0±1.3	10.5±1.3	10.0±1.6	0.180

*ANOVA's p value

LAD, Left anterior descending coronary artery

respectively, compared with the healthy coronary artery group.

The LSD analysis showed no significant differences between the wall stress of the healthy controls and the patients with moderate coronary stenosis; however, due to the high wall stress of the patients with significant coronary stenosis, the overall ANOVA was significantly different. There were significant differences between the healthy controls and the patients with significant coronary stenosis and also between the patients with moderate and significant coronary stenosis (p value < 0.05). Intraobserver and interobserver variability of the wall stress (taking into account regional wall thickness, regional radii of curvature, and LV pressure) was in the range of 4.1-7.6% and 4.8-8.5%, respectively.

Discussion

CAD or atherosclerotic heart disease is the end result of the accumulation of atheromatous plaques within the walls of the coronary arteries that supply the myocardium with oxygen and nutrients.^{16, 17} The importance of the assessment of the properties of LV and ventricular muscle and their

quantification has been evaluated in terms of myocardial wall stress and these calculations have been used in the investigation of various heart diseases.¹⁸⁻²⁰ Wall stress may be calculated at the diastolic phase of the cardiac cycle; however, this calculation requires invasive measurements of LV blood pressure in the cardiac catheterization laboratory during retrograde left heart catheterization.²¹ In our previous study, we concluded from our experience that non-invasively obtained Doppler E/Ea ratio as an interesting application of TDI provided an index of LVEDP, which could be measured using color Doppler myocardial imaging. In that study, based on very encouraging initial results (LVEDP related strongly to lateral E/Ea, $r = 0.85$; p value < 0.001)³, we applied lateral E/Ea for the purpose of non-invasive estimation of LVEDP and therefore non-invasive quantification of myocardial diastolic wall stress.

The average end-diastolic wall stress was calculated at the LV anterior and interventricular septum wall segments using the formula proposed by Deanda et al.¹⁴ and taking into account LV pressure, regional wall thickness, and meridional and circumferential regional radii of the curvature. The stress calculated by this formula represents the mean value of the average stress across the thickness of the LV wall, with

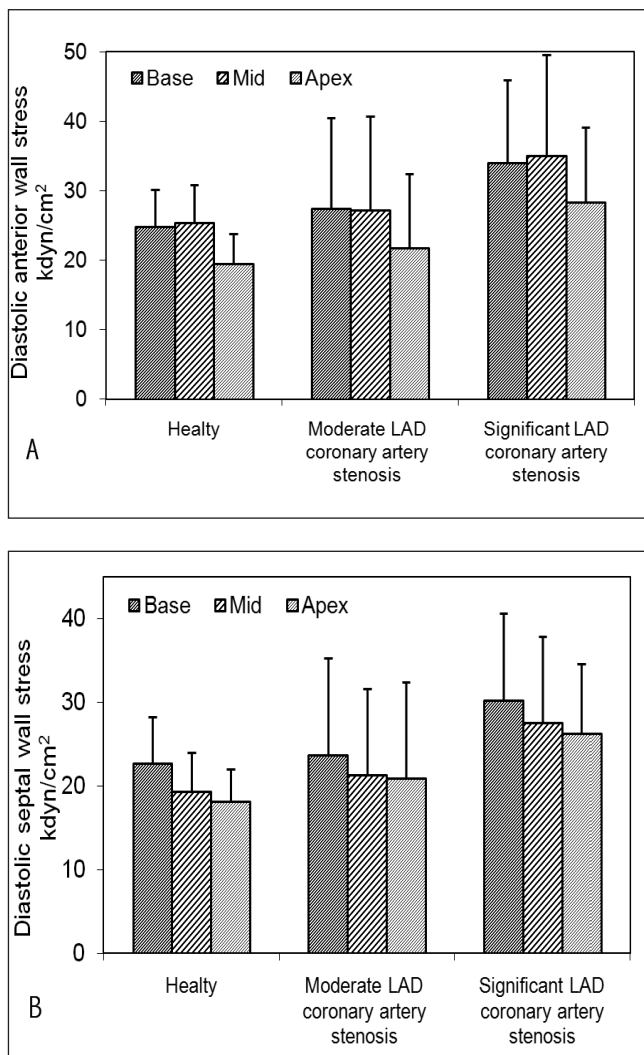


Figure 5. Comparison of end-diastolic myocardial wall stress (kdyn/cm²) in different groups at the three different segments LAD, Left anterior descending coronary artery

local maximal stress occurring on the endocardial and local minimal stress on the epicardial surface. The assumptions used in this analysis were:¹⁴ 1) the myocardium was isotropic, linearly elastic, and homogeneous; 2) ignoring bending moments; 3) the meridional and circumferential midwall radii of curvatures could be derived as the endocardial radius of curvature plus one-half of the wall thickness; 4) the midwall LV wall stress is an average of the epicardial and endocardial stresses; and 5) the only load on the ventricle was an internal pressure.

In this study, we estimated regional end-diastolic myocardial wall stress in the anterior and septum walls for base, mid, and apex segments. The results showed that the variations of end-diastolic myocardial wall stress in atherosclerotic patients were significantly greater than those of the healthy group (p value < 0.05).

We are cognizant of the fact that invasive coronary angiography is the standard clinical means for depicting the

coronary arteries and is the gold standard for diagnosing CAD, but angiographic coronary stenosis does not always reflect the potential alteration in the regional myocardial perfusion. The relationship between stenosis severity and physiological reduction in the coronary flow is quite variable even when there are no imaging limitations, for example eccentric stenosis or obscure areas due to thrombus. Radionuclide methods would be more accurate than coronary angiography in defining ischemic myocardial wall segments, and the accuracy of wall stress may be different when compared with this perfusion technique.

One of the reasons for investigating relationships between the mechanical parameters of the myocardial tissues and coronary stenosis is to find possibilities for remotely characterizing the conditions of normal and diseased tissues. The main focus in most previous studies of tissue characterization has been on elasticity acoustic parameters. More recently, progress has been made in making use of the great sensitivity of strain properties of tissues to their pathological condition: the so-called ultrasonic strain rate imaging. The relation between forces acting upon an object and the resulting deformation is described by Hooke's law, which states that forces and deformation are linked by the elasticity. This relation remains valid when applied to the myocardium; be that as it may, in order to describe the total deformation of the myocardium, all forces acting on it have to be taken into account.²²

The clinical assignment of patients and healthy subjects in the present study may have been biased by their referring physicians. However, we observed no significant differences in age, gender, and body mass index between the groups, indicating an excellent match of the three groups.

Annular velocities may vary with the site of sampling, and thus the utility of this method is dependent on the location of the sample volume. Tissue Doppler recordings were obtained only from the lateral mitral annulus, and the other mitral segments were not evaluated in this study. We chose the lateral aspects of the mitral annulus because this site is easy to obtain from the apical window and, in contrast to the parasternal window, the velocities should not be influenced by anteroposterior translation.²³ The main disadvantage of color-TDI is the requirement for an offline analysis for quantifying myocardial velocities and inability to provide instantaneous display of the Doppler information, which can be time-consuming. In this study, E/Ea was calculated using color-TDI and was used to estimate wall stress non-invasively. Further studies are required to compare E/Ea calculated using pulsed-TDI and E/Ea calculated using color-TDI to non-invasively estimated LVEDP and resulted wall stress. In this study, the non-invasive indices of regional wall stress were calculated from the non-invasive estimation of LVEDP and echocardiographic segmental LV diameter and wall thickness in the LAD at risk regions and further studies are required to calculate wall stress for other coronary



arteries at risk regions.

Conclusion

In conclusion, non-invasive evaluations of diastolic function constitute an important role of clinical echocardiography and research setting. Our results underscore the importance of end-diastolic myocardial wall stress in CAD patients as an index in the non-invasive evaluation of myocardial performance.

Acknowledgment

We wish to thank Dr A. Khaledifar and Dr A. Khajavi for their invaluable technical assistance. This study was approved by the Institutional Review Board and Ethics Committee of Tarbiat Modares University. The first author, Hassan Moladoust, is currently affiliated with the Department of Medical Physics, Guilan Medical Sciences University, Rasht, Iran.

References

- Raggi P. Role of coronary calcium screening in preventive cardiology. *Prev Cardiol* 2000;6:214-216.
- Taylor AJ, Feuerstein I, Wong H, Barko W, Brazaitis M, O'Malley PG. Do conventional risk factors predict subclinical coronary artery disease? Results from the prospective army coronary calcium project. *Am Heart J* 2001;3:463-468.
- Mirsky I. Left ventricular stresses in the intact human heart. *Biophys J* 1969;9:189-208.
- Quinones MA, Mokotoff DM, Nouri S, Winters WL, Miller RR. Noninvasive quantification of left ventricular wall stress: validation of method and application to assessment of chronic pressure overload. *Am J Cardiol* 1980;45:782-790.
- Quinones MA, Gaasch WH, Cole JS, Alexander JK. Echocardiographic determinations of left ventricular stress-velocity relations in man: with reference to the effects of loading and contractility. *Circulation* 1975;51:689-700.
- Grossman W, Jones W, McLaurin LP. Wall stress and patterns of hypertrophy in the human left ventricle. *J Clin Invest* 1975;56:56-64.
- Moladoust H, Mokhtari-Dizaji M, Ojaghi-Haghighi Z, Khaledifar A, Khajavi A. Estimation of LV end diastolic pressure using color-TDI and its application to noninvasive quantification of myocardial wall stress. *Echocardiogr* 2009;26:403-410.
- Mansencal N, Bouvier E, Joseph T, Farcot JC, Pilliere R, Redheuil A, Lacombe P, Jondeau G, Dubourg O. Value of tissue Doppler imaging to predict left ventricular filling pressure in patients with coronary artery disease. *Echocardiogr* 2004;21:133-138.
- Sengupta PP, Mohan JC, Pandian NG. Tissue Doppler echocardiography: principles and applications. *Indian Heart J* 2002;54:368-378.
- Henry WL, DeMaria A, Gramiak R, King DL, Kisslo JA, Popp RL, Sahn DJ, Schiller NB, Tajik A, Teichholz LE, Weyman AE. Report of the American society of echocardiography committee on nomenclature and standards in two-dimensional echocardiography. *Circulation* 1980;62:212-215.
- Mansencal N, Bouvier E, Joseph T, Farcot JC, Pilliere R, Redheuil

- A, Lacombe P, Jondeau G, Dubourg O. Value of tissue Doppler imaging to predict left ventricular filling pressure in patients with coronary artery disease. *Echocardiogr* 2004;21:133-138.
- Ommen SR, Nishimura RA, Appleton CP, Miller FA, Oh JK, Redfield MM, Tajik AJ. Clinical utility of Doppler echocardiography and tissue Doppler imaging in the estimation of left ventricular filling pressures. A comparative simultaneous Doppler-catheterization study. *Circulation* 2000;102:1788-1794.
- Legget ME. Usefulness of parameters of left ventricular wall stress and systolic function in the evaluation of patients with aortic stenosis. *Echocardiogr* 1999;16:701-710.
- Deanda A, Komeda M, Moon MR, Green GR, Bolger AF, Nikolic SD, Daughters GT, Miller DC. Estimation of regional left ventricular wall stresses in intact canine hearts. *Am J Physiol* 1998;275:1879-1885.
- Regen DM, Anversa P, Capasso JM. Segmental calculation of left ventricular wall stresses. *Am J Physiol* 1993;264:1411-1421.
- Ross R. Atherosclerosis: an inflammatory disease. *N Engl J Med* 1999;340:115-126.
- Gebber JO. Atherosclerosis, cholesterol, nutrition, and statins: a critical review. *Ger Med Sci* 2007;5:1-11.
- Ballo P, Mondillo S, Guerrini F, Barbati R, Picchi A, Focardi M. Midwall mechanics in physiologic and hypertensive concentric hypertrophy. *J Am Soc Echocardiogr* 2004;17:418-427.
- Cupps BP, Moustakidis P, Pomerantz BJ, Vedala G, Scheri RP, Kouchoukos NT, Davila-Roman VG, Pasque MK. Severe aortic insufficiency and normal systolic function: determining regional left ventricular wall stress by finite-element analysis. *Ann Thorac Surg* 2003;76:668-675.
- Napoli PD, Taccardi AA, Grilli A, Felaco M, Balbone A, Angelucci D, Gallina S, Calafiore AM, Caterina RD, Barsotti A. Left ventricular wall stress as a direct correlate of cardiomyocyte apoptosis in patients with severe dilated cardiomyopathy. *Am Heart J* 2003;146:1105-1111.
- Davidson CJ, Bonow RO. Cardiac catheterization. In: Zipes DP, Libby P, Bonow RO, Braunwald E, eds. *Braunwald's Heart Disease: A Textbook of Cardiovascular Medicine*. 7th ed. Philadelphia: W. B. Saunders; 2005. p. 395-422.
- Bijnens B, Claus P, Weidemann F, Strotmann J, Sutherland GR. Investigating cardiac function using motion and deformation analysis in the setting of coronary artery disease. *Circulation* 2007;116:2453-2464.
- Nagueh SF, Middleton KJ, Kopelen HA, Zoghbi WA, Quinones MA. Doppler tissue imaging: a noninvasive technique for evaluation of left ventricular relaxation and estimation of filling pressures. *J Am Coll Cardiol* 1997;30:1527-1533.