

Henry Ford Health System

## Henry Ford Health System Scholarly Commons

---

Case Reports

Medical Education Research Forum 2020

---

5-2020

### Broken Heart, Broken Mind

Taha Ashraf

*Henry Ford Health System, TAshraf1@hfhs.org*

Ivan M. Columbus Morales

*Henry Ford Health System, icolumb1@hfhs.org*

Avi Cohen

*Henry Ford Health System, acohen4@hfhs.org*

Follow this and additional works at: <https://scholarlycommons.henryford.com/merf2020caserpt>

---

#### Recommended Citation

Ashraf, Taha; Columbus Morales, Ivan M.; and Cohen, Avi, "Broken Heart, Broken Mind" (2020). *Case Reports*. 114.

<https://scholarlycommons.henryford.com/merf2020caserpt/114>

This Poster is brought to you for free and open access by the Medical Education Research Forum 2020 at Henry Ford Health System Scholarly Commons. It has been accepted for inclusion in Case Reports by an authorized administrator of Henry Ford Health System Scholarly Commons.



## INTRODUCTION

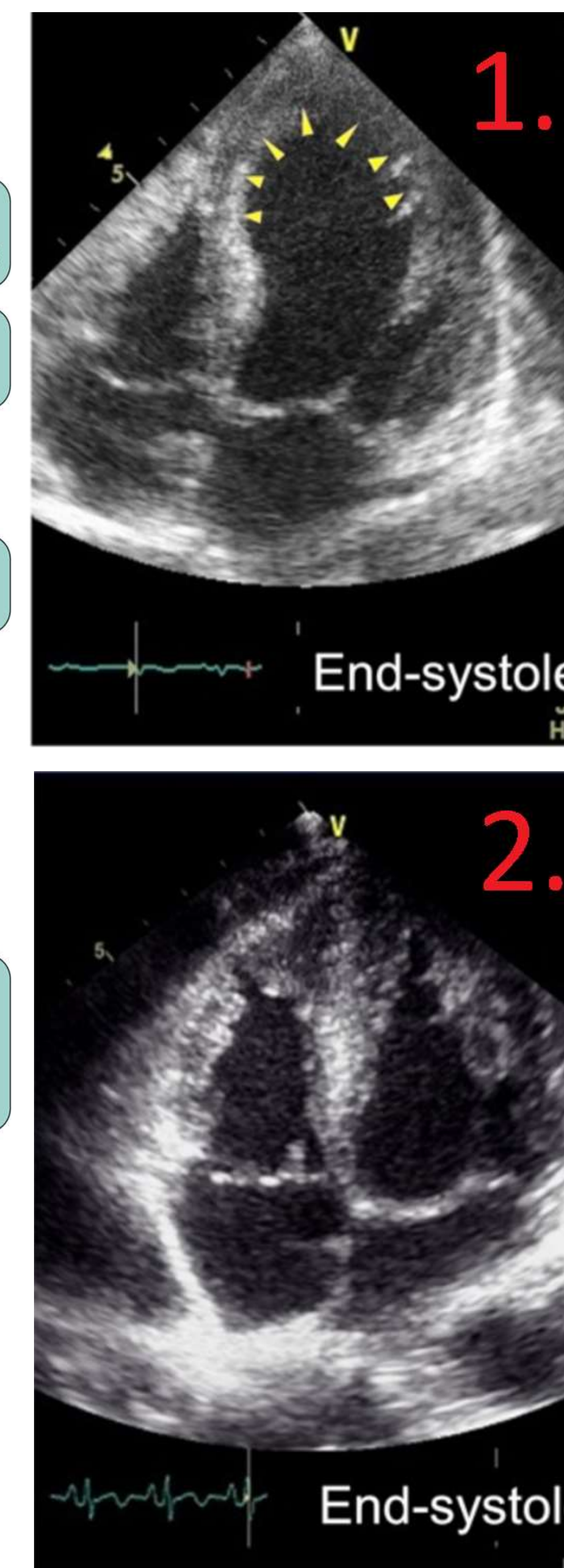
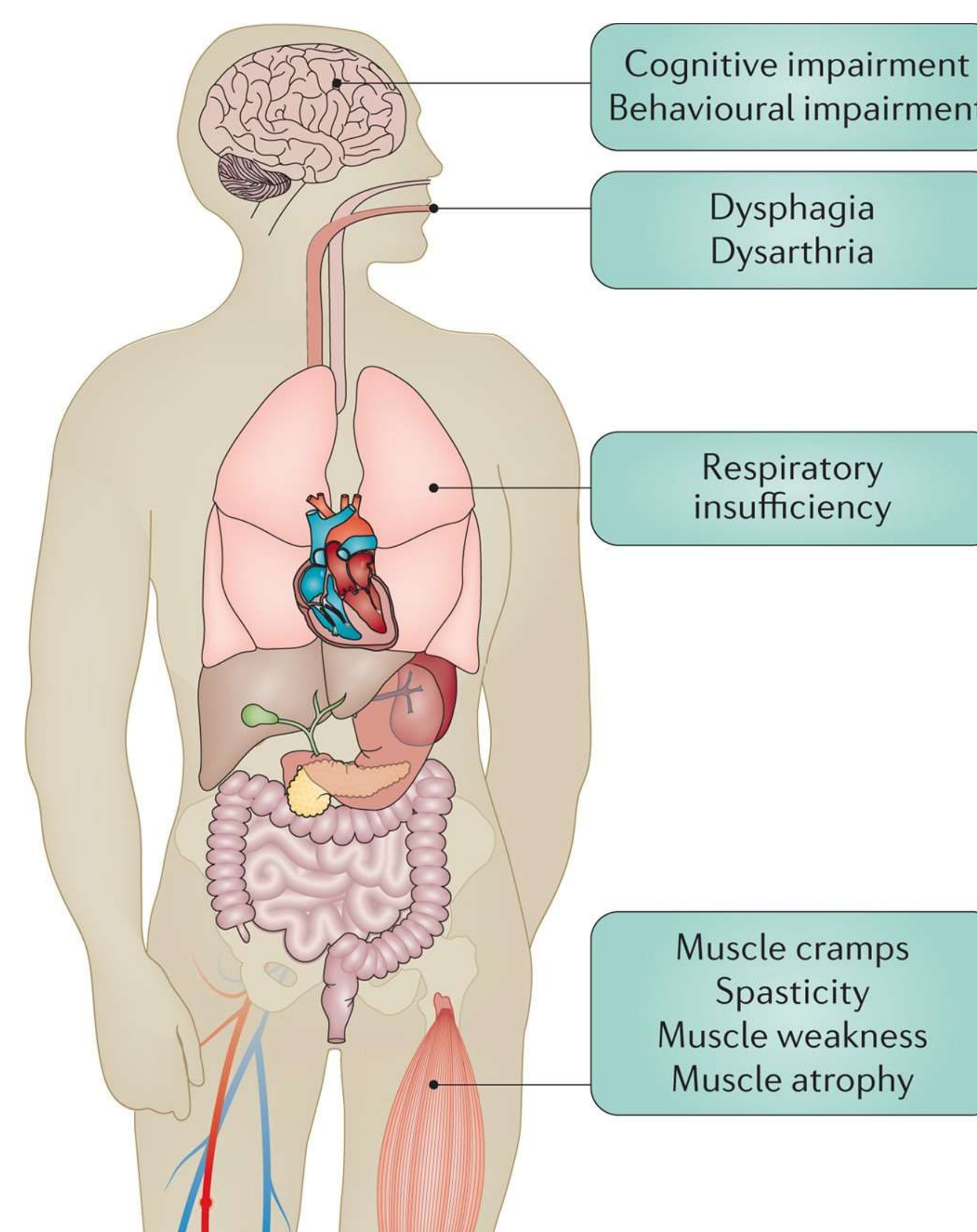
- Takotsubo Cardiomyopathy (TCM) is a unique condition of reversible cardiac dysfunction precipitated by emotional or physical stress.
- Studies are emerging noting an association with advanced Amyotrophic Lateral Sclerosis (ALS).
- This may be secondary to baseline elevation of catecholamines.

## CASE PRESENTATION

- 53-year-old female with background of anxiety presented with acute onset chest pain.
- Initial evaluation revealed elevated troponins without ST changes on EKG.
- Echocardiogram showed EF 28% with apical ballooning and left heart catheterization was unremarkable.
- Echocardiogram normalized 2 weeks later, consistent with TCM.
- During evaluation it was noted she was dysarthric - further history revealed progressive odynophagia for the past year, generalized muscle weakness for months and dysarthria for 4-6 weeks.
- Neurological exam demonstrated both upper and lower motor neuron findings of muscle atrophy, fasciculations as well as brisk peripheral reflexes, jaw jerk and bilateral Hoffmans.
- CPK, anti-MUSK, anti-acetylcholine receptor antibodies were normal and extensive evaluation of paraneoplastic, vitamin and autoimmune disease were negative.
- MRI brain/spine imaging showed no significant abnormalities and EMG indicated lower motor neuron changes.

## CASE PRESENTATION

- Due to worsening respiratory status she required intubation with subsequent tracheostomy placement.
- Our patients ultimately was discharged to a long-term care facility.



**Figure 1 and 2:** Echocardiogram demonstrating apical ballooning (1) that is reversible (2) as seen in Takotsubo Cardiomyopathy. <sup>2</sup>

## DISCUSSION

- ALS is neurodegenerative disease involving both upper and lower motor neurons. In recent years it has come under focus in the public eye however early diagnosis and subsequent management remains challenging for many physicians.
- The diagnosis is suggested by physical examination however it is important to rule out vitamin B12 deficiency, paraneoplastic syndromes and other autoimmune conditions.
- Takotsubo Cardiomyopathy is characterized by reversible apical ballooning of the left ventricular wall resulting in systolic dysfunction. There must be absence of coronary disease as seen in our patient.
- Recent literature has noted an association with Takotsubo Cardiomyopathy in up to 14% of cases in some studies.<sup>1</sup> Patients presenting with both features at once are rare.
- Both TCM and ALS are associated with an increase in adrenergic activity and it is hypothesized that this may be the underlying link.<sup>3</sup>

## REFERENCES

1. J Neurol Sci. 2017 Apr 15;375:289-293. doi: 10.1016/j.jns.2017.02.012. Epub 2017 Feb 8. Takotsubo cardiomyopathy in amyotrophic lateral sclerosis. Choi SJ, Hong YH, Shin JY, Yoon BN, Sohn SY, Park CS, Sung JJ.
2. Izumi, Yuishin et al. "Distinct Incidence of Takotsubo Syndrome Between Amyotrophic Lateral Sclerosis and Synucleinopathies: A Cohort Study." Frontiers in neurology vol. 9 1099. 13 Dec. 2018.
3. Finsterer J, Stöllberger C. Central Nervous System (CNS) Disease Triggering Takotsubo Syndrome. International Cardiovascular Forum Journal 2016;5:36-39

## CONCLUSION

This case highlights the uncommon association of TCM in ALS in a unique scenario where it was the presenting feature of the disease. Physicians should be vigilant for neurological symptoms in patients presenting with chest discomfort or risk missing the diagnosis.