

A Dissertation on

**A STUDY OF ETIOLOGY, MANAGEMENT  
OF PTOSIS IN MIDDLE AGE  
POPULATION AND ITS SURGICAL  
OUTCOME**

*Submitted in partial fulfillment of requirements of*

**M. S. OPHTHALMOLOGY**

**BRANCH – III**

**REGIONAL INSTITUTE OF OPHTHALMOLOGY**

**MADRAS MEDICAL COLLEGE**

**CHENNAI – 600 003**



**Submitted to**

**THE TAMILNADU DR. M.G.R. MEDICAL  
UNIVERSITY CHENNAI**

**MAY - 2020**

## **CERTIFICATE**

This is to certify that **Dr.K.NIKKITHA**, Post Graduate student in M.S Ophthalmology, at Regional Institute of Ophthalmology and Government Ophthalmic hospital attached to Madras Medical College, Chennai, carried out this dissertation on “**A STUDY OF ETIOLOGY, MANAGEMENT OF PTOSIS IN MIDDLE AGE POPULATION AND ITS SURGICAL OUTCOME**” under our direct guidance and supervision during the academic period from May 2017 to May 2020.

This dissertation is submitted to the TamilNadu Dr.MGR Medical University, Chennai for the fulfillment of award of M.S. Degree in Ophthalmology.

**Prof. Dr.M.ANANDA BABU M.S., D.O**  
Director & Superintendent,  
RIO – GOH,  
Chennai – 8.

**Prof. Dr.R.JAYANTHI M.D., FRCP (Glasg)**  
Dean,  
Madras Medical College,  
Chennai – 3.

## **CERTIFICATE BY THE GUIDE**

This is to certify that **Dr. K.NIKKITHA** , Post Graduate student (May 2017 to April 2020) in the Department of Ophthalmology , at Regional Institute of Ophthalmology and Government Ophthalmic hospital attached to Madras Medical College, has done this dissertation work titled **“A STUDY OF ETIOLOGY, MANAGEMENT OF PTOSIS IN MIDDLE AGE POPULATION AND ITS SURGICAL OUTCOME”** under my guidance and supervision in partial fulfillment of the regulations laid down by The Tamil Nadu Dr. M.G.R. Medical University ,Chennai for **M.S., Ophthalmolgy** , Degree examination to be held in May 2020.

**Prof. Dr.R.MALARVIZHI, M.S, D.O.,**  
Guide and Chief,  
Head of Department,  
Squint, Neuro-ophthalmology &  
Paediatric ophthalmology,  
RIO – GOH,  
Chennai – 8.

## **DECLARATION**

I, **Dr.K.NIKKITHA**, solemnly declare that the dissertation titled **“A STUDY OF ETIOLOGY, MANAGEMENT OF PTOSIS IN MIDDLE AGE POPULATION AND ITS SURGICAL OUTCOME”** has been prepared by me. This is submitted to The Tamil Nadu Dr.M.G.R. Medical University, Chennai, in partial fulfillment of the requirement for the award of M.S. Ophthalmology (Branch - III), degree Examination to be held in May 2020.

**Place: Chennai**

**Signature of the candidate**

**Date:**

**DR. K.NIKKITHA**

## **CERTIFICATE – II**

This is to certify that this dissertation work titled “**A STUDY OF ETIOLOGY, MANAGEMENT OF PTOSIS IN MIDDLE AGE POPULATION AND ITS SURGICAL OUTCOME**” of the candidate **Dr. K.NIKKITHA (REGISTRATION NO:221613006)** for the award of **M.S., DEGREE BRANCH-III (OPHTHALMOLOGY)**. I personally verified the urkund.com website for the purpose of plagiarism check. I found that the uploaded thesis file contains from introduction to conclusion pages and result shows **6 (seven)** percentage of plagiarism in the dissertation.

Guide & Supervisor Sign with Seal

## **ACKNOWLEDGEMENT**

I express my sincere thanks to **Prof. Dr. R.JAYANTHI M.D., FRCP (Glasg)**, Dean Madras Medical College for giving me permission to conduct the study in this institution.

I am very grateful to **Prof. Dr. M.ANANDA BABU M.S.,D.O.**, Director and Superintendent, RIO & GOH, Chennai, for helping me conduct the study.

I express my gratitude to **Prof. Dr. R.MALARVIZHI M.S.,D.O.**, Guide and Unit Chief, Dept of Squint, Neuro ophthalmology & Pediatric ophthalmology, for assigning this topic for study and guidance throughout my post graduate course. I wish to express my sincere thanks for the valuable help, encouragement and guidance at various stages of the study.

I am grateful to Assistant Professors **Dr. A.ANURADHA M.S., Dr.K.VASUMATHI, M.S.**, for rendering their valuable advice and guidance for the study.

I wish to express my sincere thanks to all my Patients for their co operation for completion of this study.

# CONTENTS

| <b>S. No.</b> | <b>TITLE</b>                    | <b>Page No</b> |
|---------------|---------------------------------|----------------|
|               | <b>PART – I</b>                 |                |
| 1.            | INTRODUCTION                    | 1              |
| 2.            | REVIEW OF LITERATURE            | 3              |
| 3.            | ANATOMY OF EYELIDS              | 5              |
| 4.            | PHYSIOLOGY OF EYELIDS           | 20             |
| 5.            | CLASSIFICATION OF PTOSIS        | 24             |
| 6.            | TYPES OF PTOSIS                 | 29             |
| 7.            | EVALUATION OF A CASE OF PTOSIS  | 37             |
| 8.            | MANAGEMENT OF PTOSIS            | 45             |
| 9.            | COMPLICATIONS OF PTOSIS SURGERY | 57             |
|               | <b>PART – II</b>                |                |
| 10.           | AIM OF THE STUDY                | 59             |
| 11.           | MATERIALS AND METHODS           | 59             |
| 12.           | RESULTS AND ANALYSIS            | 62             |
| 13.           | DISCUSSION                      | 81             |
| 14.           | SUMMARY                         | 84             |
| 15.           | CONCLUSION                      | 87             |
|               | <b>PART – III</b>               |                |
| 16.           | BIBLIOGRAPHY                    | 89             |
| 17.           | PROFORMA                        | 93             |
| 18.           | KEY TO MASTER CHART             | 98             |
| 19.           | MASTER CHART                    | 100            |

# INTRODUCTION

Blepharoptosis (Ptosis) usually indicates drooping of upper eyelid. Its often unilateral but can be bilateral also. It can be congenital or acquired. In congenital ptosis most common cause is improper development of levator muscle whereas in adults it is due to levator aponeurosis dehiscence, or tendon stretch due to aging. It may also be myogenic, neurogenic or mechanical.

Management of ptosis depends upon the etiology. For better cosmetic outcome detailed history and appropriate clinical examination is essential to arrive at a correct diagnosis and management accordingly. Management of ptosis depends on age, etiology, whether uni or bilateral involvement, severity of ptosis, the levator function, and presence of additional ophthalmologic or neurologic features.

Treatment of ptosis may be medical or surgical. In case of severe ptosis with involvement of visual axis surgery is the treatment of choice which varies with levator function. Ptosis surgery restores normal position and stability of eyelid.



Complications of ptosis surgery includes infection, bleeding, over or under correction. Although improvement in lid height is usually achieved, the eyelids may not be perfectly symmetrical.

In our study we take ptosis with age group (20-50 years) were included to find out the most common etiology and management. If managed surgically the results and complications were also analysed.

## REVIEW OF LITERATURE

- ❖ **Kersten et al**<sup>1</sup> in 1995 did a study on 91 patients of 15-50 years of age regarding causes of acquired ptosis and found that rigid contact lens wear was the most common cause due to levator aponeurosis dehiscence followed by trauma.
- ❖ **Rasiah et al**<sup>2</sup> did a retrospective cohort study on 266 young adults with acquired ptosis and found that the most common cause were trauma related followed by anophthalmic blepharoptosis.
- ❖ **Jeffrey et al**<sup>3</sup> in 2013 conducted a study on congenital ptosis and found its syndromic associations, genetic factors and surgical procedure. The choice of procedure depends on patient specific factors like degree of ptosis, levator function, surgeon preference and resource availability.
- ❖ **Simon et al**<sup>4</sup> did a study on different surgical designs and suture materials used in frontalis sling surgery and found that single loop and double pentagon design had same success. Nylon suture had better cosmetic outcome and poly tetra fluoro ethylene had lowest recurrence rate.
- ❖ **Benia et al**<sup>5</sup> did a retrospective study on 1500 cases of ptosis and found that simple congenital ptosis as the most common cause and the most common surgery was levator resection.
- ❖ **Mc culley et al**<sup>6</sup> in an article did a retrospective case cohort study on results of aponeurotic advancement surgery in aponeurotic ptosis

with transcutaneous approach and found that 77% cases had ideal results and remaining 23% had under correction.

- ❖ **Baroody et al**<sup>7</sup> in 2004 studied advances in evaluation and treatment of ptosis and found that frontalis suspension surgery is the most commonly performed surgery and frontalis advancement flap can also be used in congenital ptosis. Advancement of levator aponeurosis can be performed by minimally invasive small incision approach.
- ❖ **Wong et al**<sup>8</sup> in 2000 did a retrospective non comparative interventional case series in 28 patients with myogenic ptosis and found that the most common cause was chronic progressive external ophthalmoplegia and most common ocular finding other than ptosis was pigmentary retinopathy. The most common systemic finding was dysphagia. About 20% of patient were treated surgically by frontalis suspension only after visual axis got obscured.
- ❖ **Satchi et al**<sup>9</sup> in 2014 did a study on isolated neurogenic ptosis due to neuropraxic injury to nerve supplying levator palpebrae superioris and found that all cases recovered in less than 6 months duration. Hence in case of isolated neurogenic ptosis it was found to observe upto 6 months for spontaneous recovery and if unsuccessful then surgical intervention can be advised.

# **ANATOMY OF EYELIDS**

Eyelids act to protect anterior surface of eye. They act as shutters protecting the globe, distributing tear film over the cornea during blinking, and also aid in tear flow by their pumping action on the conjunctival sac and lacrimal sac.

## **EXTENT:**

The upper eyelid extends upto eyebrow superiorly, which separates eyelid from the forehead. The lower lid extends upto the inferior orbital rim where it joins the cheek, where the eyelids loose connective tissue merges with the denser tissue of the cheek.

## **STRUCTURE:**

Eyelid consists of following layers from anterior to posterior.

At 3 mm from lid margin it constitutes six layers namely,

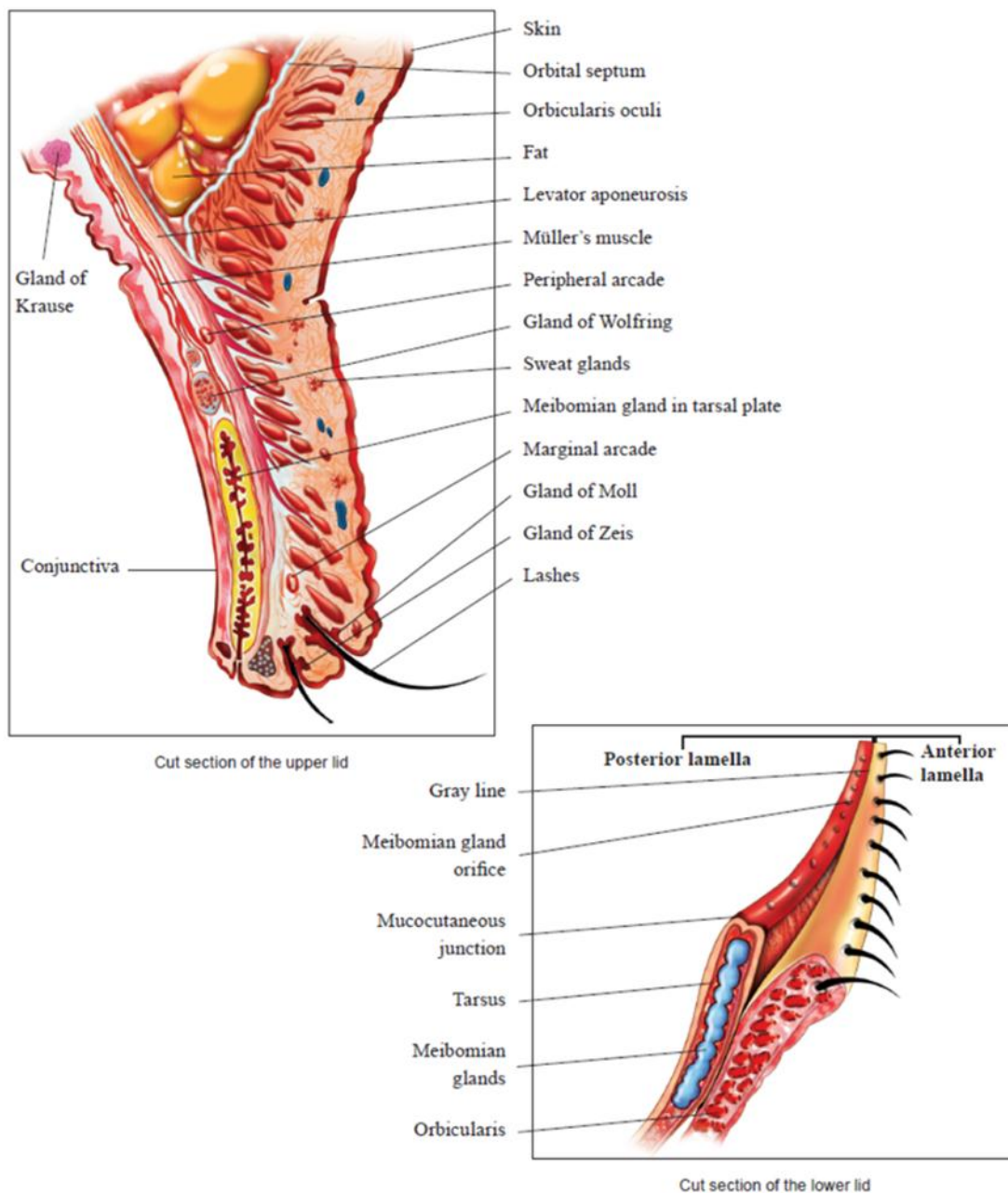
1. Skin
2. Subcutaneous areolar tissue
3. Orbicularis oculi muscle
4. Submuscular areolar tissue
5. Tarsal plate
6. Conjunctiva

At 15 mm above the lid margin, the lamellae constitute 9 layers (fig 1) namely,

1. Skin
2. Subcutaneous areolar tissue
3. Orbicularis oculi muscle
4. Submuscular areolar tissue
5. Orbital septum
6. Pre aponeurotic orbital fatpad
7. Levator aponeurosis
8. Mullers muscle
9. Conjunctiva

### **1.SKIN:**

The skin covering eyelid is thinnest part of the body (<1 mm) which is elastic and mobile. The skin of the nasal part is more smoother, more oily and has finer hairs compared to temporal aspect. The pretarsal skin is demarcated from the preseptal skin at the level of supratarsal lid crease 7-10 mm from lid margin.



**Fig 1: Layers of upper and lower eyelid**

## **2. SUBCUTANEOUS AREOLAR TISSUE:**

Consists of loose areolar tissue. Subcutaneous tissue is absent over the lateral and medial palpebral ligaments, where the skin adheres to the palpebral ligaments. Dermatochalasis, blepharochalasis, and epicanthic

folds are conditions that involve the skin and subcutaneous tissue of the eyelids.

### **3.ORBICULARIS OCCULI MUSCLE:**

It is the most superficial muscle of the eyelid involved in facial expression. It is further divided into

1. Orbital part
2. Palpebral part
3. Pars lacrimalis ( Lacrimal part)
4. Pars ciliaris (The muscle of Riolan)

#### **THE ORBITAL PART:**

It is a circular muscle arising from medial orbital rim fans out around periphery of eyelids to insert near its site of origin. The upper fibres of the orbital part passing to skin of medial eyebrow are called as musculus superciliaris. Inferior fibres that are attached to cheek are called musculus malaris.

#### **THE PALPEBRAL PART:**

Its subdivided into pretarsal and preseptal part. They overlie the tarsus and orbital septum respectively. They arise from medial palpebral ligament arcs and posterior lacrimal crest superiorly and inferiorly and inserts along lateral horizontal raphe and lateral canthal tendon. It is further

divided into pretarsal and preseptal portions based on the structure underneath the muscle.

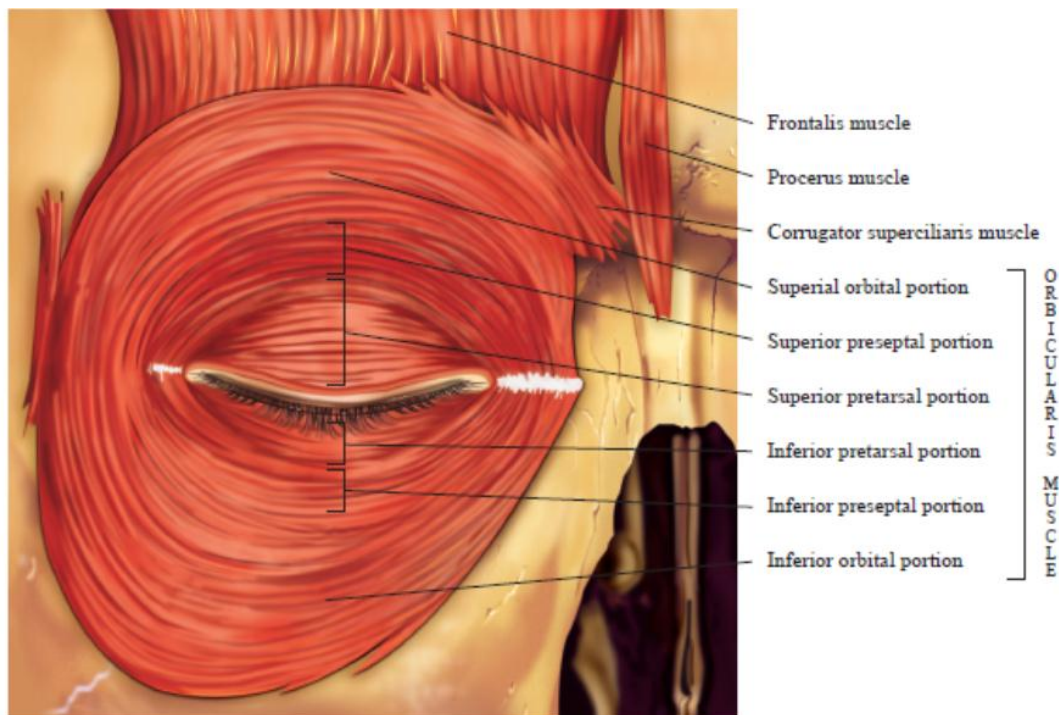
### **THE PARS LACRIMALIS:**

Also called as horners muscle are attached behind lacrimal sac area to lacrimal fascia and upper posterior part of lacrimal crest.

### **THE MUSCLE OF RIOLAN:**

Formed by the pretarsal fibres which run along the lid margin behind the ciliary follicle

**INNERVATION:** Temporal and zygomatic branches of facial nerve.



**Fig 2: Parts of Orbicularis Oculi muscle**

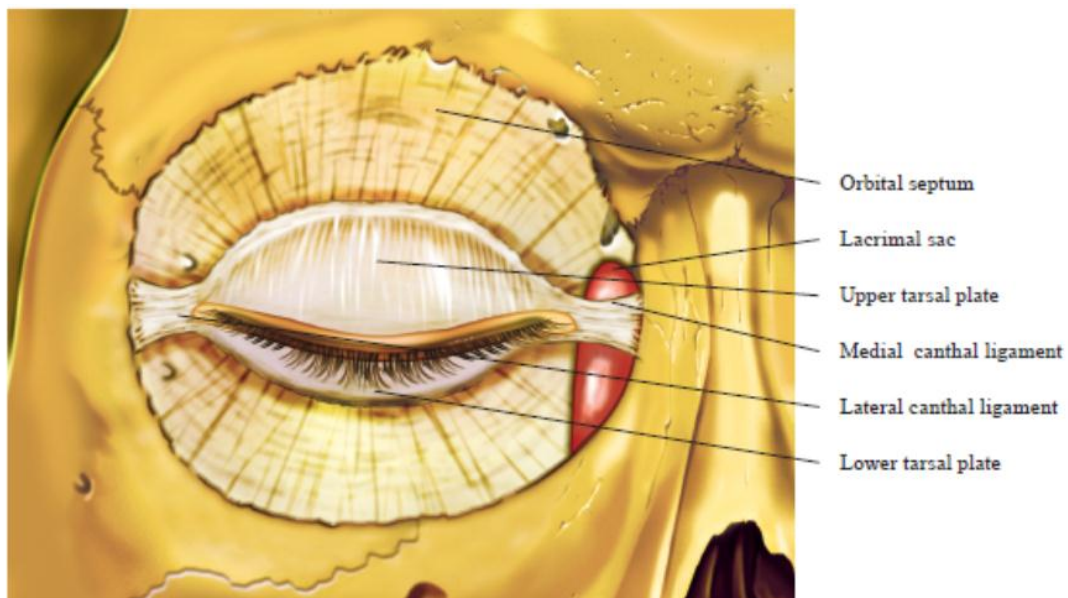


#### **4.SUBMUSCULAR AREOLAR TISSUE:**

It consists of loose connective tissue. It provides an important surgical landmark because the lid may be split into anterior and posterior portions through this potential plane which is reached by division of gray line of lid margin.

#### **5.THE ORBITAL SEPTUM:**

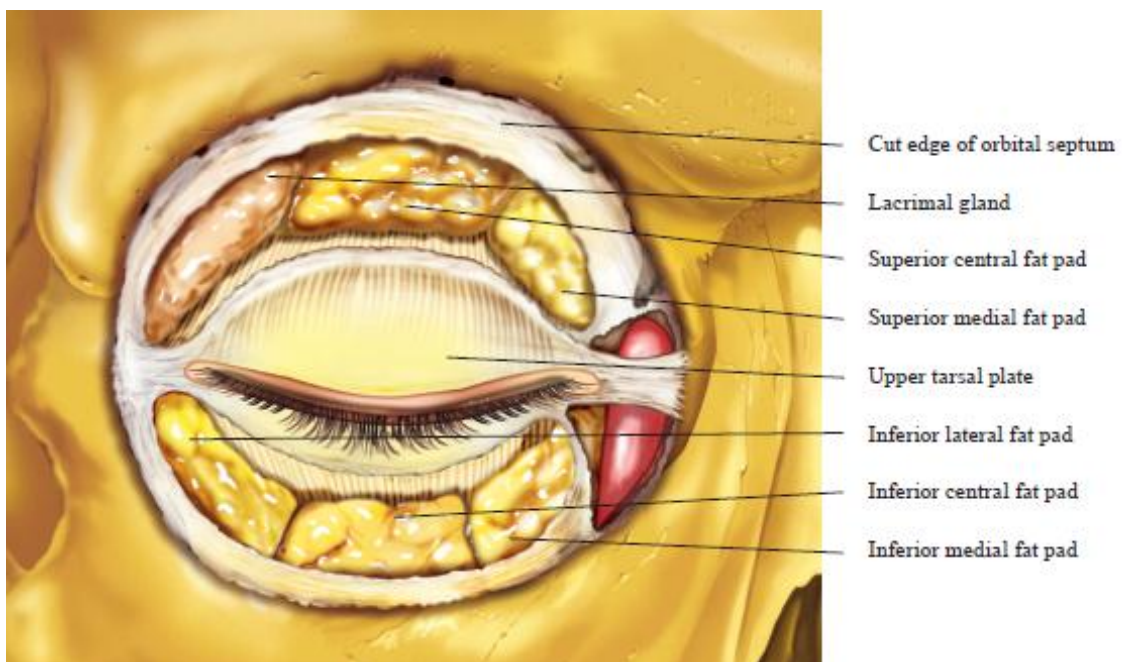
It is a strong thin connective tissue that takes part in movement of eyelids. Centrally it becomes continuous with tarsal plate. Peripherally it originates from arcus marginalis. In the upper lid, the septum blends with the fibres of levator aponeurosis 3 to 4mm just above tarsal plate. It fuses with capsulopalpebral fascia in the lower lid.



**Fig 3: Parts of orbital septum**

## 6.PRE APONEUROTIC ORBITAL PAD OF FAT:

Upper eyelid preaponeurotic fat is found between the orbital septum and the levator aponeurosis. It is seen as 2 compartments a **central fat pad** and a **medial fat pad** in the upper lid. Three retro septal fat pads namely central, medial and lateral are present in the lower eyelid. The medial and central pad of fat are separated by the inferior oblique muscle.



**Fig 4: Orbital septum with orbital fat pads**

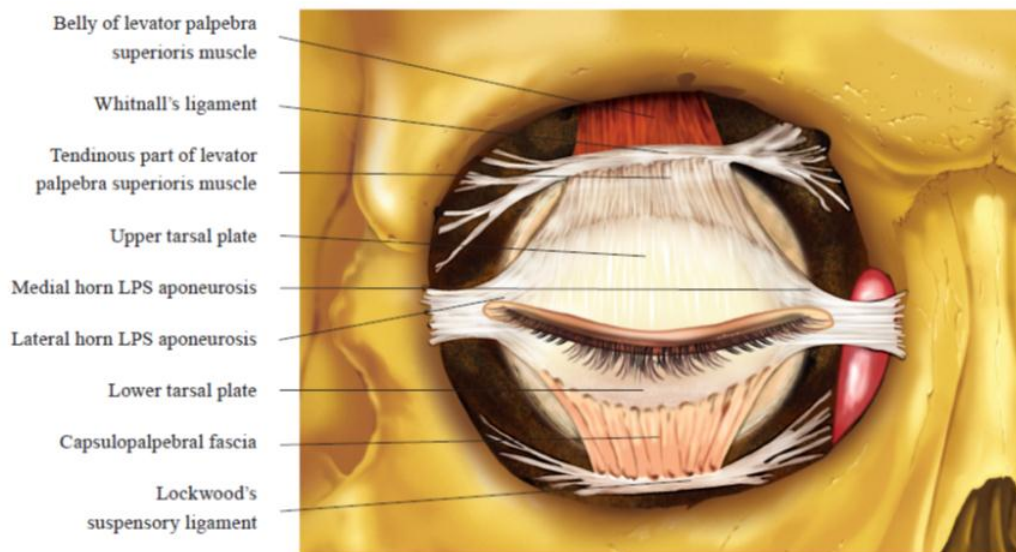
## 7.LEVATOR PALPEBRAE SUPERIORIS:

### ORIGIN:

The levator palpebrae superioris (LPS) arises at the orbital apex from the lesser wing of the sphenoid bone. The levator muscle and superior rectus muscle shares common developmental origin and are connected to each other by fibrous attachments.

## **COURSE:**

The LPS proceeds forwards for 40 mm and ends in an aponeurosis 10 mm behind the orbital septum. The levator complex changes direction from horizontally to vertically at the level of Whitnall's ligament. The superior transverse ligament (Whitnall's ligament) lies at the junction of the muscular and aponeurotic component of levator palpebrae superioris and represents orbital fascial condensation between the trochlea and the lacrimal gland fascia.



**Fig 5: The attachments of levator palpebrae superioris**

## **LEVATOR APONEUROSIS:**

Levator aponeurosis is a unique tendon which is 10 – 50 mm long delivering force to horizontally acting muscle in posterior and vertical

motion of lid elevation. This ligament gets attached to the orbital wall medially at trochlea, lacrimal gland capsule laterally and to the orbital wall periosteum acting as check ligament to levator retractor. The levator aponeurosis fans out and occupies 30 to 35mm width of the entire eyelid

**INSERTION:**

Aponeurosis has 5 insertion sites first by fusing with the distal fibres of the orbital septum about 3 to 4mm above the tarsal plate, second into the intermuscular septum and the overlying skin. It gets attached to anterior surface of tarsus and to the superior fornix of conjunctiva. Third medially it gets inserted into medial canthal tendon and forms the medial horn and fourth laterally forming lateral horn. Finally the aponeurotic fibres form prominent horizontal eyelid crease by inserting into skin with elevation of eyelid.

**INNERVATION:** Superior division of oculomotor (CN III) nerve.

**ACTION:** Elevation of upper lid

**MULLERS MUSCLE:**

Smooth muscle originating from the (posterior fibres) undersurface of levator muscle travelling between LPS and conjunctiva. Gets inserted into superior margin of tarsus. There is peripheral vascular arcade of

upperlid between LPS and mullers muscle which acts as a plane of dissection in blepharoptosis surgery.

**Nerve supply:** The sympathetic nervous system

**Action:**

1. Accessory elevator of upper lid
2. Widening of palpebral fissure on increased sympathetic tone

### **TARSAL PLATES:**

They are responsible for the structural integrity of eyelids comprising dense fibrous connective tissue. Tarsal plates are 29mm long and 1 mm thick with superior tarsus being 9-10mm in vertical height while inferior being 3-5mm at the centre. The inferior border forms lid margin while posteriorly it is adhered to the conjunctiva. Each tarsus encloses about 30-40 sebaceous meibomian gland superiorly and 20-30 inferiorly along the vertical height which opens at the lid margin posterior to the grey line anterior to mucocutaneous junction.

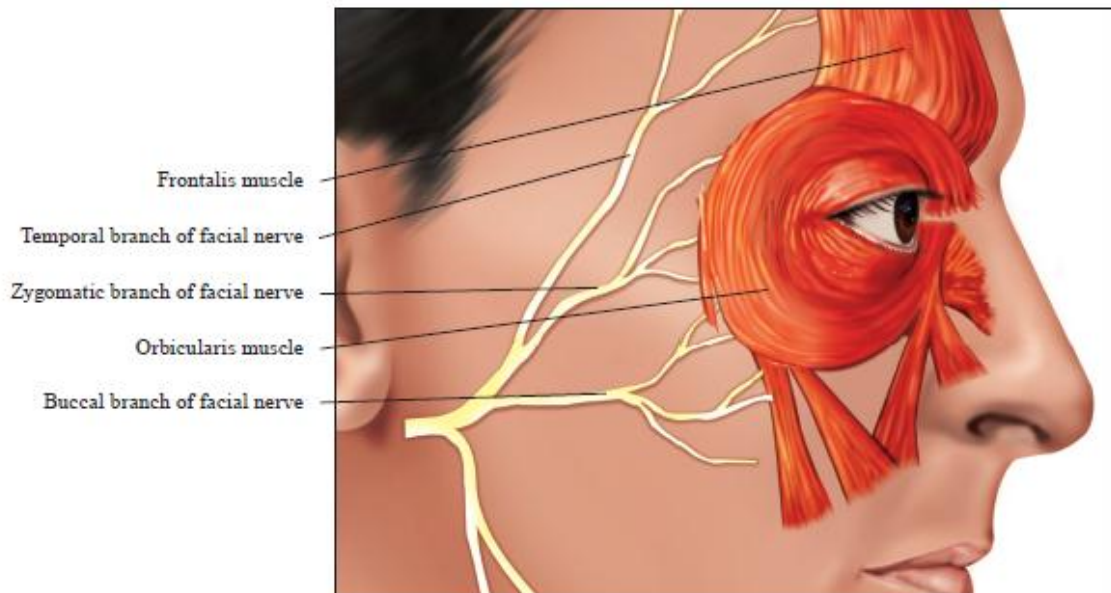
### **PALPEBRAL CONJUNCTIVA:**

It is a smooth translucent mucous membrane, lining the posterior surface of both lids as tarsal conjunctiva and continues as orbital fornicial conjunctiva reflecting further anteriorly and continues as bulbar

conjunctiva. Numerous accessory lacrimal glands like Krause and wolfring and mucous secreting goblet cells are contained within.

### **NERVE SUPPLY:**

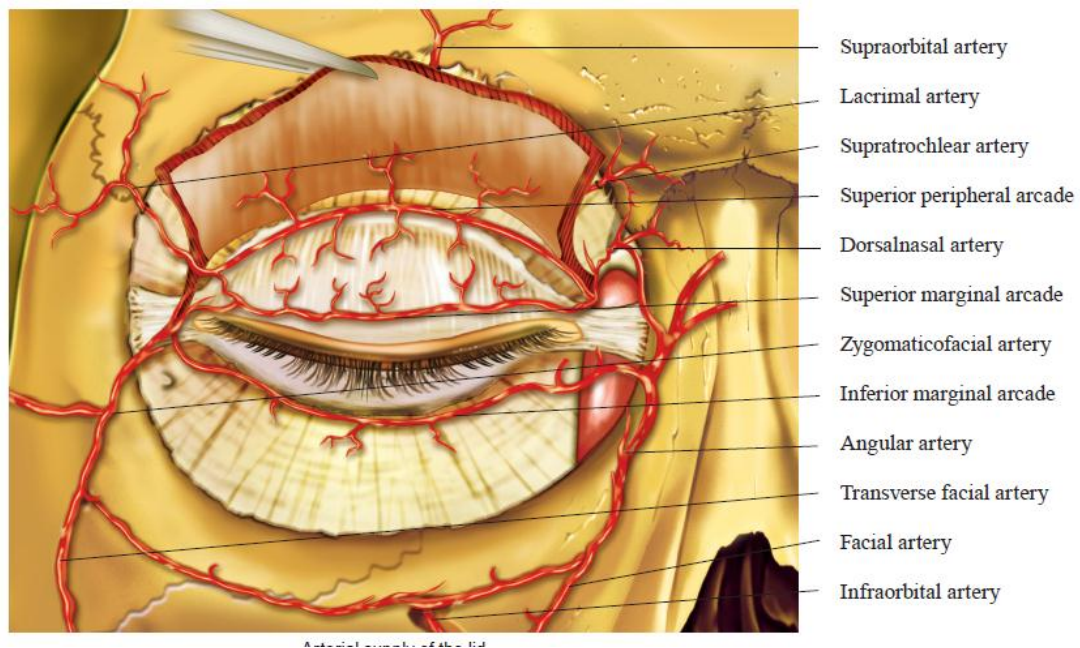
- ❖ **Sensory supply:** Sensory innervation is by ophthalmic (CN V1) and maxillary (CN V2) division of trigeminal nerves.
- ❖ **Motor supply:** Orbicularis oculi by facial nerve (CN VII) and levator palpebrae superioris by oculomotor nerve (CN III).
- ❖ **Sympathetic supply:** Mullers muscle, glands of skin and vessels



**Fig 6: Motor innervation of the eyelid**

## **BLOOD SUPPLY:**

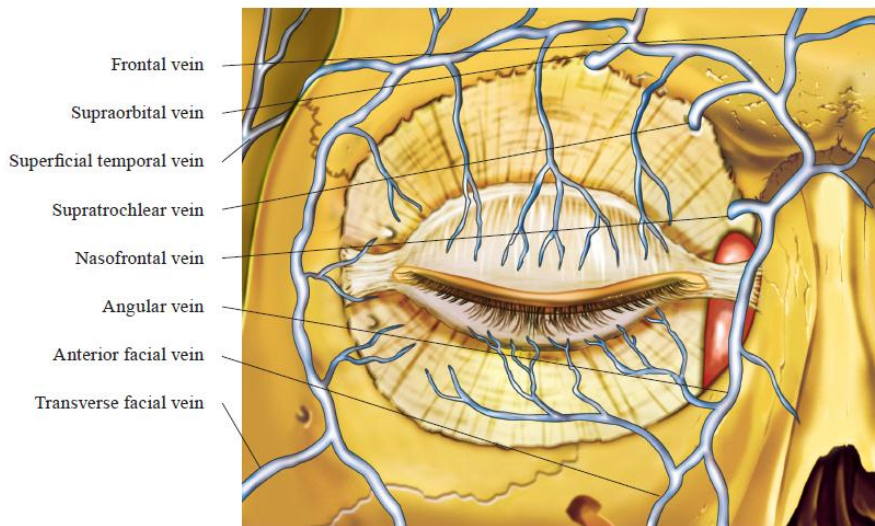
Lid arterial supply is by both internal and external carotid arteries. The superior marginal arterial arcade is formed by ophthalmic artery, lateral palpebral artery and medial palpebral artery which lie in the submuscular plane in front of tarsal plate. Along with this supraorbital and dorsal nasal branches supply levator muscle and eyelids. Branches from arterial arcade supply skin, fornix, orbicularis, tarsal glands and conjunctiva. External carotid artery branches like facial, maxillary(infraorbital) and superficial temporal also supply lower eyelid.



**Fig 7: The arterial supply of upper and lower lid**

## **VENOUS DRAINAGE:**

Veins are more in number and larger than the arteries. Pretarsal venous plexus drains structures that are superior to tarsus. They further drain medially into angular and finally into internal jugular vein. Laterally lacrimal and superficial temporal drain finally into external jugular veins. Post tarsal venous plexus drains structures that are posterior to tarsus into ophthalmic vein.

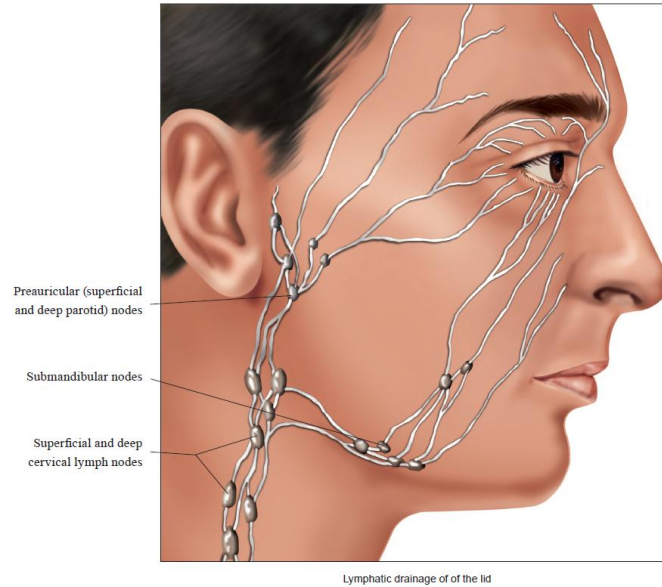


**Fig 8: The venous drainage of upper and lower lid**

## **LYMPHATIC DRAINAGE:**

Eyelids and conjunctiva have rich lymphatic drainage. Lateral  $2/3^{\text{rd}}$  upper lid and lateral  $1/3^{\text{rd}}$  lower lid drains into pre auricular lymph nodes while medial  $1/3^{\text{rd}}$  upper lid and medial  $2/3^{\text{rd}}$  lower lid into submandibular lymph nodes respectfully.





**Fig 9: Lymphatic drainage of eyelids**

### **FRONTALIS MUSCLE:**

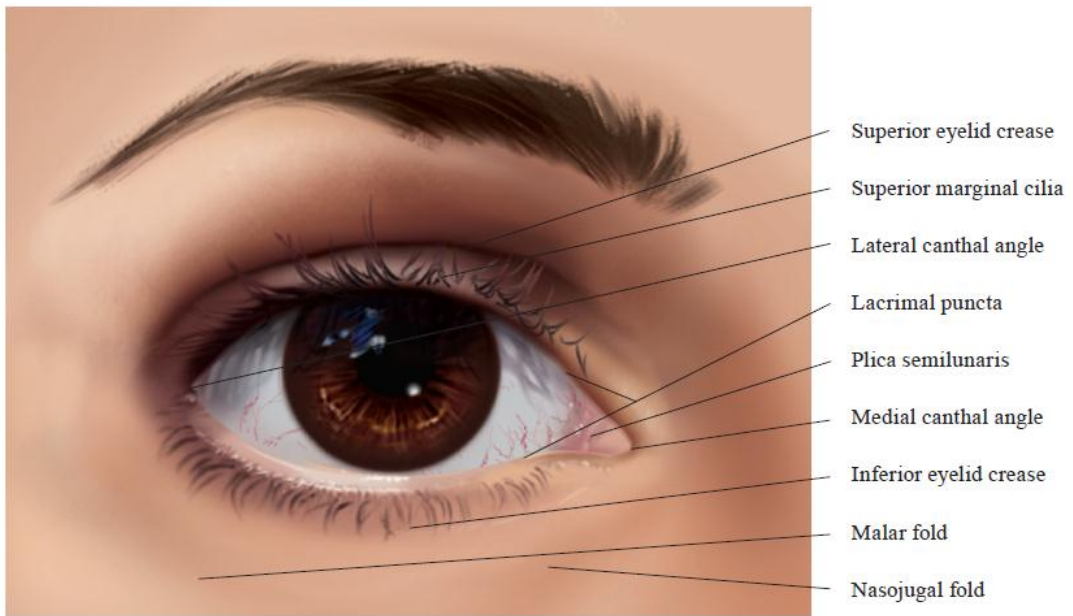
Quadrangular muscle originating from epicranial aponeurosis which gets inserted into eyebrow skin and also sends fibers to orbicularis and corrugators.

**Innervation** : Facial nerve (CN VII)

**Action** : Elevation of eyebrow above line of vision

### **INTERPALPEBRAL FISSURE:**

Measures 25 – 28 mm horizontally and 7 – 11 mm vertically. It comprises exposed globe between the eyelids. Upper eyelid margin lies 1-2mm below superior corneal limbus while lower eyelid just touches inferior corneal limbus.



**Fig 10: The interpalpebral fissure**

# PHYSIOLOGY OF EYELIDS

Eyelids have numerous functions like providing mechanical protection to the globe, even distribution of pre corneal tear film, regulates amount of light entering eye, covers eye during sleep. The mobility of eyelids requires sophisticated interplay of ocular muscles and its suspensory ligaments coordinated by fine motor and sensory mechanisms in relation to ocular movements.

## **EYELID MOVEMENTS:**

1. Lid opening
2. Lid closure
3. Blinking
4. Voluntary blinking and winking
5. Bell's phenomenon

### **1. EYELID OPENING:**

It is done by upper lid elevators and lower lid retractors.

#### **Upper eyelid elevators:**

Levator palpebrae superioris forms primary elevator while mullers muscle and frontalis muscle becomes important in case of defective levator muscle. Opening movements of eyelids are usually bilateral, symmetrical and identical in their amplitude and direction by **HERING'S LAW OF**

**EQUAL INNERVATION** between bilateral levator muscles. Hence ptosis in one eye may cause retraction on the other eyelid. **SHERRINGTON'S LAW OF RECIPROCAL INNERVATION** exists between levator and orbicularis oculi of the same eye. Frontalis contributes to lid elevation in extreme upgaze above the line of vision.

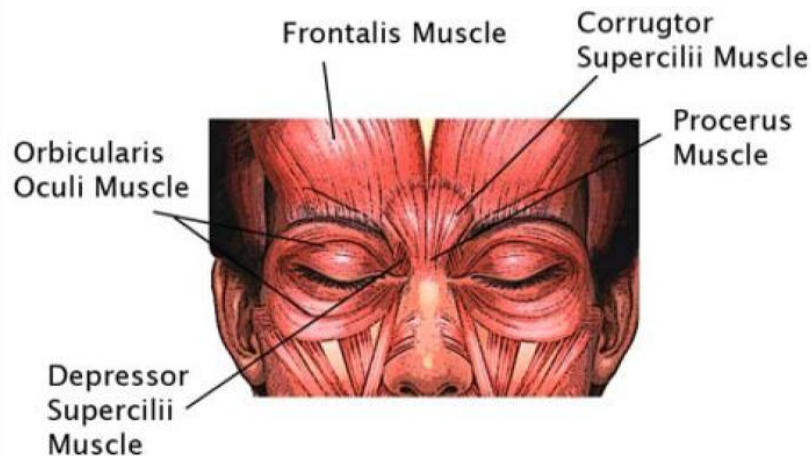
**Lower eyelid retractors:**

There is no true counterpart for levator muscle in lower eyelid. Inferior tarsal muscle and capsulopalebral fascia are lower eyelid retractors. The opening of lower eyelid is aided by traction exerted by attachment of inferior rectus muscle to inferior tarsus and lower lid retractors.

**2.EYELID CLOSURE:**

Eyelid closure is produced by action of orbicularis oculi muscle. It constitutes 3 main parts namely

- ❖ **Pretarsal fibres** – responsible for spontaneous blinking and tactile corneal reflex
- ❖ **Preseptal fibres** – responsible for voluntary blinking and sustained activity and aids in tear drainage
- ❖ **Orbital fibres** – responsible for forceful lid closure.



**Fig 11: The muscles involved in eyelid closure**

### **3.BLINKING:**

It can be divided into voluntary and involuntary. Involuntary blinking is further classified as spontaneous and reflex blinks. Spontaneous blinking is the most common form which occurs without any voluntary efforts or external stimuli. The average rate is 12-20 per minute. It is increased in conditions like dryness, strong air currents, emotional stress whereas decreased in case of visual observation. Reflex blinking occurs in response to a stimulus. Various stimuli include corneal touch(tactile), bright light(dazzle), sudden presence of near object(menace), loud noise(auditory), tap or blow(orbital).

### **4.VOLUNTARY BLINKING AND WINKING:**

It is a coordinated opening and closure of both eyelids. It is produced as protective gesture. Winking is unilateral voluntary lid closure. It's a

learned activity. Both are produced by simultaneous contraction of palpebral and orbital portions of orbicularis oculi.

#### **5.BELL'S PHENOMENON:**

It is a protective mechanism where there is a bilateral highly coordinated reflex between oculomotor (CN III) and facial nuclei (CN VII) where on attempted closure of eyelids the eyeball gets rotated upwards and outwards. Mechanism behind it is that on closure of eyelids, all the electrical activity cease in the levator muscle and simultaneously abruptly rises in the superior rectus and inhibited in inferior rectus muscle.

# CLASSIFICATION OF PTOSIS

## I. ETIOLOGICAL CLASSIFICATION OF PTOSIS –

**SIDNEY FOX<sup>23</sup> (1972):**

### 1. CONGENITAL PTOSIS

- Simple
- Complicated
  - ✚ By ophthalmoplegia
  - ✚ Other lid anomalies
  - ✚ Paradoxical ptosis (neurological)

### 2. ACQUIRED PTOSIS

- Myogenic
- Neurogenic
- Traumatic
- Senile

### 3. HEREDO FAMILIAL

- At birth
  - ✚ Embryonic fixation
- Late appearing
  - ✚ External ophthalmoplegia

## II. MECHANISTIC CLASSIFICATION OF PTOSIS –

**FRUEH B<sup>17</sup> (1980):**

### 1. MYOGENIC PTOSIS

- a. Congenital development dystrophy
- b. Progressive external ophthalmoplegia
- c. Myotonic dystrophy
- d. Traumatic levator muscle injuries
- e. Myasthenia gravis
- f. Oculopharyngeal muscular dystrophy
- g. Toxic myopathy
- h. Late acquired hereditary ptosis
- i. Non acquired acquired myopathy

### 2. NEUROGENIC PTOSIS

- a. 3<sup>rd</sup> nerve palsy
- b. Aberrant regeneration (misdirected 3<sup>rd</sup> nerve fibres)
- c. Horner's syndrome



### 3. APONEUROTIC PTOSIS

- a. Aponeurotic disinsertion or dehiscence
- b. Senile redundancy

### 4. MECHANICAL PTOSIS

- a. Lid or orbital tumours
- b. Dermatochalasis
- c. Lid edema/ hematoma/ infection
- d. Brow ptosis
- e. Upper lid skin disease
- f. Cicatricial conjunctival scarring
- g. Redundant tarsal syndrome

### 5. PSEUDO PTOSIS

- a. Orbital volume loss
- b. Blepharo/hemifacial spasm
- c. Hypotropia
- d. Chronic ocular surface
- e. Irritative disease
- f. Contralateral lid retraction

### **III. BEARD'S CLASSIFICATION<sup>26</sup> (1981):**

#### 1. CONGENITAL PTOSIS – 60%

- i. Superior rectus normal function
- ii. Superior rectus weakness
- iii. Blepharophimosis syndrome
- iv. Marcus gunn jaw winking (synkinetic ptosis)
- v. Misdirected 3<sup>rd</sup> nerve ptosis

#### 2. ACQUIRED PTOSIS – 40%

##### a) Neurogenic ptosis

- a. Traumatic ophthalmoplegia
- b. Oculomotor nerve palsy
- c. Ophthalmoplegic migraine
- d. Horner's syndrome
- e. Multiple sclerosis associated

##### b) Myogenic ptosis

- a. Senile ptosis
- b. Late acquired hereditary ptosis
- c. Hyperthyroidism
- d. Progressive external ophthalmoplegia
- e. Steroid ptosis

c) Traumatic ptosis

d) Mechanical ptosis

- a. Lid tumours
- b. Blepharochalasis
- c. Cicatrical ptosis

e) Pseudo – ptosis

- a. Hypotrophia
- b. Anophthalmia/ microphthalmos/ phthisis bulbi
- c. Dermatochalasis

# **TYPES OF BLEPHAROPTOSIS**

## **CONGENITAL PTOSIS:**

It is present since birth. Most common cause is idiopathic. Histologically levator muscle shows dystrophy whose action is elevation of upper eyelid. Here the levator muscle and aponeurotic tissue is infiltrated or replaced by fat and fibrous tissue. May also occur by autosomal dominant inheritance with strong hereditary tendency. It is of nine variable patterns namely

### **1) SIMPLE PTOSIS**

- i. Simple uncomplicated ptosis
- ii. Double levator palsy

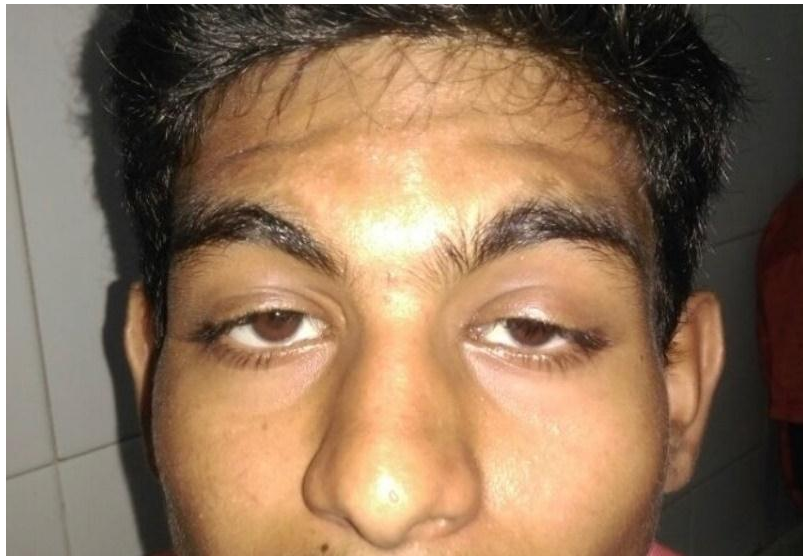
### **2) ASSOCIATED WITH OTHER LID DEFORMITIES**

- i. Blepharophimosis syndrome

### **3) Ptosis complicated by varying degree of ophthalmoplegia**

- i. Chronic progressive external ophthalmoplegia
- ii. Kearne sayre syndrome
- iii. Myotonica dystrophica

- 4) Associated with myasthenia gravis and myotonia
- 5) Sympathetic ptosis
- 6) Synkinetic ptosis
  - i. Marcus gunn jaw winking phenomenon
  - ii. Congenital 3<sup>rd</sup> nerve palsy with synkinesis
  - iii. Duane's syndrome
- 7) Periodic ptosis – cyclic oculomotor spasm
- 8) Intermittent pseudoptosis – retraction syndrome
- 9) Ptosis with systemic anomalies



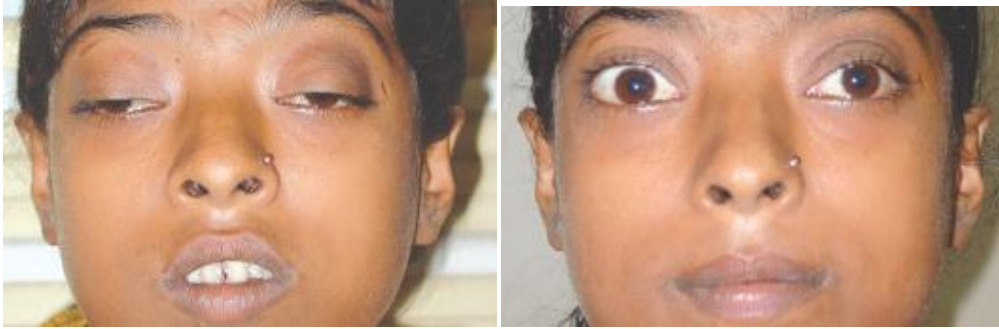**Fig 12: Simple uncomplicated congenital ptosis**

# ACQUIRED PTOSIS

## MYOGENIC PTOSIS:

Acquired myogenic ptosis is uncommon and can result from localized or diffuse muscular diseases like myasthenia gravis, myotonic dystrophy, chronic progressive external ophthalmoplegia.

- ❖ CPEO is characterized by bilateral, symmetrical and progressive ptosis. Ciliary and iris muscles are spared. Often associated with pigmentary retinopathy. Since bell's phenomenon is absent, ptosis surgeries are often contraindicated. Crutch spectacles can be tried.
- ❖ Myasthenia gravis is an autoimmune disease where antibodies are formed against acetylcholine in post synaptic myoneural junction. Ice pack test, fatigability test, tensilon test is useful in diagnosing MG. Standard electromyography, single fiber EMG, assays for Ach receptor antibodies confirm the diagnosis of MG. CT CHEST detects thymoma. Management involves cholinesterase inhibiting medications like **Pyridostigmine**. Immunosuppressants, plasmapheresis and thymectomy are also effective. In refractory cases, ptosis can be under corrected using silicone sling




**Fig 13: Myasthenia gravis (following Tensilon test)**

### **NEUROGENIC PTOSIS:**

Acquired neurogenic ptosis is caused by acquired third nerve palsy and horner's syndrome.

### **THIRD NERVE PALSY:**

Acquired third nerve palsy may present with or without pupillary involvement. Usually present with sudden onset of unilateral ptosis and on opening the upper eyelid patient complains of double vision with affected eye in exotropic and hypotropic position. There will be limitation of all movements except abduction. It may present as isolated or associated with other neurological deficits depending on the level of lesion. Causes include trauma, aneurysms, carcinomatous meningitis, ischemic vasculopathies and management is either medical or surgical depending on the etiology.



**Fig 14: Ptosis due to left 3<sup>rd</sup> nerve palsy**

### **HORNER'S SYNDROME:**

Acquired horner's syndrome is caused by interruption in oculo sympathetic nerve pathway anywhere between its origin in hypothalamus and the eye. Patient presents with mild ptosis, pupillary miosis, anhidrosis and apparent enophthalmos. Other ocular findings include increased amplitude of accommodation, paradoxical contralateral eyelid retraction and changes in tear viscosity.

Common causes of preganglionic involvement include trauma, aortic dissection, carotid dissection, tuberculosis and Pancoast tumour. Common causes of postganglionic involvement include trauma, cluster migraine and neck or thyroid surgery. Various pharmacological tests are used like topical cocaine, apraclonidine and hydroxyamphetamine tests to identify the level of lesion.



## **APONEUROTIC PTOSIS:**

The function of levator aponeurosis is to transmit levator force to the eyelid. Therefore any disruption in its function or anatomy may lead to blepharoptosis. Aponeurotic ptosis is the most commonly occurring acquired ptosis caused by either levator aponeurosis stretching, dehiscence or disinsertion from its normal position. Common causes include senile, involutional, chronic inflammation or intraocular surgery and also long term use of contact lenses.



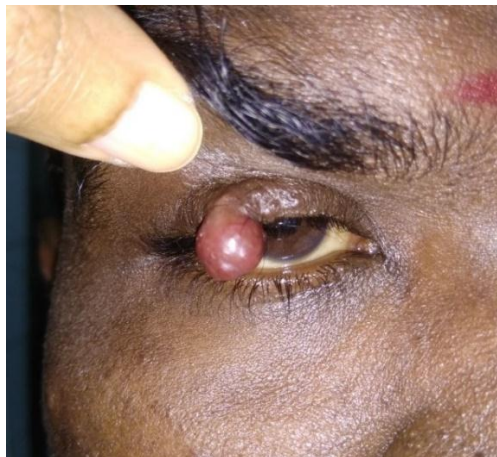**Fig 15: Left aponeurotic ptosis**

## Comparison between congenital and aponeurotic ptosis

| S No | Characteristics          | Congenital ptosis    | Aponeurotic ptosis        |
|------|--------------------------|----------------------|---------------------------|
| 1.   | Palpebral fissure height | Mild – severe ptosis | Mild – severe ptosis      |
| 2.   | Upper lid crease         | Weak / absent crease | Higher than normal crease |
| 3.   | Levator function         | Reduced              | Near normal               |
| 4.   | On down gaze             | Eyelid lag           | Eyelid drop               |

### MECHANICAL PTOSIS:

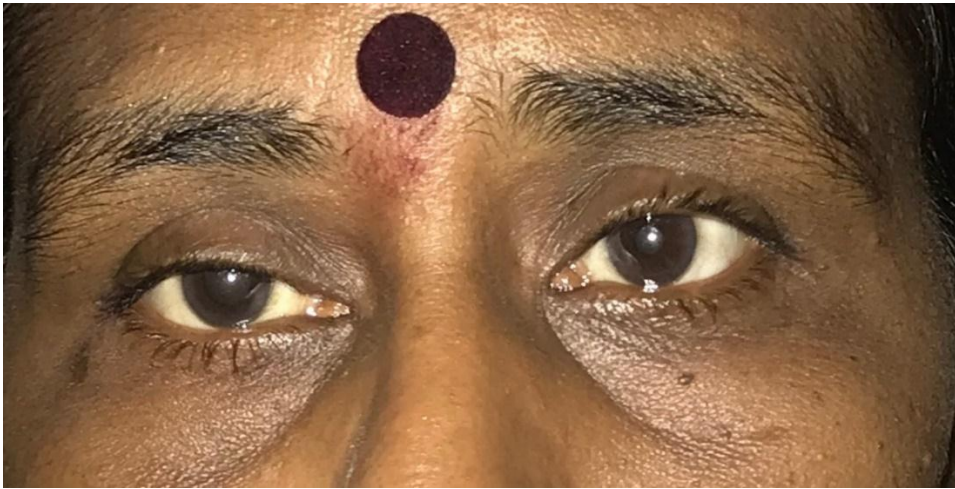It is a condition where there is a swelling in the upper eyelid which inturn pulls the lid down. The most common causes are either due to congenital abnormality such as plexiform neurofibroma or acquired tumours like hemangioma, basal or squamous cell carcinoma or frontal mucocele.



**Fig 16: Mechanical ptosis**

## **TRAUMATIC PTOSIS:**

Can occur after an eyelid laceration where there is a complete transection of the upper eyelid elevators or if there is a discontinuity in neurological input. Any orbital or neurosurgical procedures can also lead to traumatic ptosis.



**Fig 17: Right traumatic ptosis**

# EVALUATION OF A CASE OF PTOSIS

A good history taking and examination are very vital because it helps in correct diagnosis and management whether medical or surgical and if surgical the choice of surgery.

## **HISTORY:**

- First time of onset whether present since birth or acquired.
- Duration
- Whether unilateral or bilateral
- Static/ progressive/ improving
- Variation during day

## **Associated history:**

- Associated jaw wink
- Presence or absence of diplopia
- Muscle weakness/ odynophagia
- H/o contact lens use

## **Past history:**

- H/o of birth (forceps) delivery
- H/o trauma
- H/o of previous surgery

**Family history:**

- Presence of similar complaints in family

**OBSERVATION:**

We should always observe the patient's face and eyes while taking history. The importance of it is that presence of blepharophimosis, dermatochalasis, brow ptosis, blepharospasm, facial muscle weakness etc can be found by keen observation itself.

Chin lift indicates presence of ptosis at or beyond pupillary axis. Head turn or tilt indicates presence of associated strabismus and further indicated the need for evaluation of ocular motility. The presence of any scar or mass lesion is noted. Eyelid retraction of either lowerlid or contralateral lid may raise suspicion of early thyroid orbitopathy.

Lack of eye movements suggests chronic progressive external ophthalmoplegia. Presence of anisocoria may possibly be due to third nerve palsy, horner's syndrome or ocular trauma.

**OCULAR EXAMINATION:****VISUAL ACUITY:**

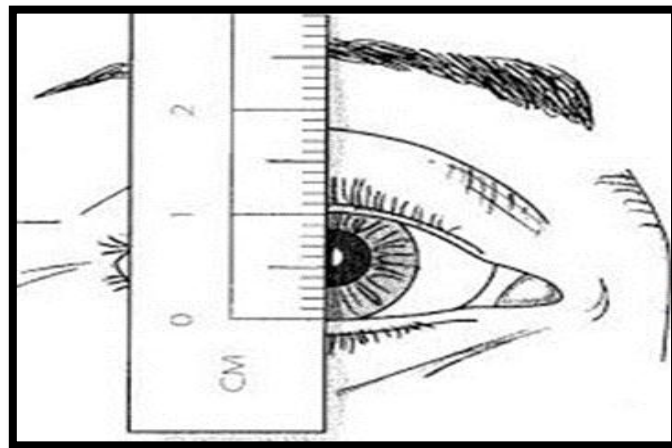
Best corrected visual acuity should be recorded to evaluate the presence or absence of amblyopia on the ptotic eye.

### **PALPEBRAL APERTURE:**

Approximate measurement of ptosis can be found by difference in palpebral aperture of both eyes.

### **VERTICAL PALPEBRAL FISSURE HEIGHT:**

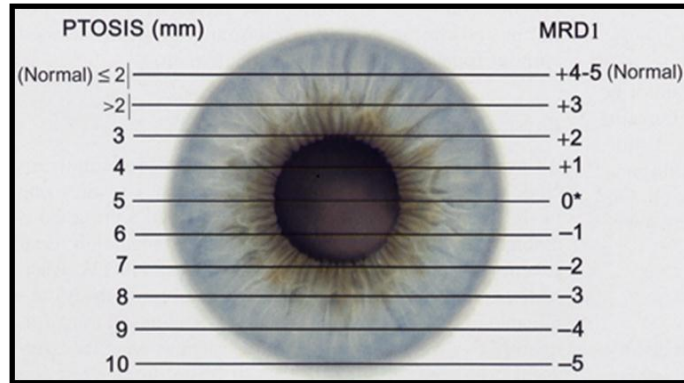
It is measured as the widest point between the upper and lower lid with the patient in primary gaze.



**Fig 18: Measurement of vertical palpebral fissure height**

### **MARGIN REFLEX DISTANCE (MRD) – 1:**

It is the distance from corneal light reflex to the eyelid margin of the upper lid in primary position. The normal value is +4 and negative if below pupillary axis.



**Fig 20: Association of severity of ptosis with margin reflex distance**

**MARGIN REFLEX DISTANCE (MRD) – 2:**

It is measured as the distance between corneal light reflex to the eyelid margin of lower lid in primary position.

The sum of MRD -1 and MRD - 2 equals the vertical palpebral height.

Ptosis can be graded as

| <b>Grading of ptosis</b> | <b>Measurement in mm</b> |
|--------------------------|--------------------------|
| <b>Mild ptosis</b>       | <b>2mm</b>               |
| <b>Moderate ptosis</b>   | <b>3mm</b>               |
| <b>Severe ptosis</b>     | <b>4mm or more</b>       |

## **ACTION OF THE LEVATOR PALPABRAE SUPERIORIS MUSCLE:**

It is the most important value since depending on the levator action only further surgical management can be planned. There are various methods to measure LPS action like

1. Berke's method
2. Putterman's method
3. Illif's test

### **BERKE'S METHOD:**

This method is demonstrated by blocking the action of frontalis muscle and measuring the excursion of upper lid from extreme down gaze. The surgeon's hand presses the forehead of the patient above the eyebrows without any upward or downward push and the patient is asked to look at extreme downgaze and then again in extreme upgaze and the readings are measured in millimeters.

| <b>LEVATOR ACTION</b> | <b>MEASUREMENT IN MM</b> |
|-----------------------|--------------------------|
| <b>Excellent</b>      | <b>14 mm or more</b>     |
| <b>Good</b>           | <b>8 – 13 mm</b>         |
| <b>Fair</b>           | <b>5 – 7 mm</b>          |
| <b>Poor</b>           | <b>4mm or less</b>       |



### **PUTTER MAN'S METHOD:**

It is another method of assessing levator muscle function in extreme up gaze by measuring the marginal limbal distance (MLD).

### **ILLIF'S TEST:**

It is useful in assessing levator function in infants. Here while the child looks down the upper eyelid of child is everted and if action of levator muscle is good then the lid reverts back to its normal position.

### **BELL'S PHENOMENON:**

Presence of an intact bell's phenomenon is confirmed by presence of upward rotation of eyeball on attempted closure of eye. The importance is to assess the risk of exposure keratitis postoperatively.

### **MARGIN CREASE DISTANCE:**

It is measured from the distance between the upper eyelid margin and the prominent eyelid crease. The crease is elevated in case of involutional ptosis whereas mild or absent in congenital ptosis. The importance of this measurement is that it helps in planning the surgical incision.

### **ICE PACK TEST:**

It is useful in the diagnosis of myasthenia gravis. It is a simple procedure where an icepack is applied to patients eyelid for about 2 minutes. If there is an improvement in ptosis more than 2 mm it indicates that myasthenia should be ruled out. The improvement is because of the presence of enhancement of transmission in the neuromuscular junction because of the inhibition of acetyl cholinesterase. Other clinical test used to rule out myasthenia is the FATIGUABILITY TEST.

### **PUPILLARY ASSESSMENT:**

Pupillary abnormalities are present in neurogenic ptosis where miosis is elicited in horner's syndrome while mydriasis is elicited in case of oculomotor nerve palsy. Traumatic mydriasis can also be elicited in case of sphincter tear.

### **PHARMACOLOGICAL TESTS:**

1. TENSILON / EDROPHONIUM TEST: used in diagnosis of myasthenia gravis
2. PHENYL EPHRINE TEST: used in diagnosis of horner's syndrome.

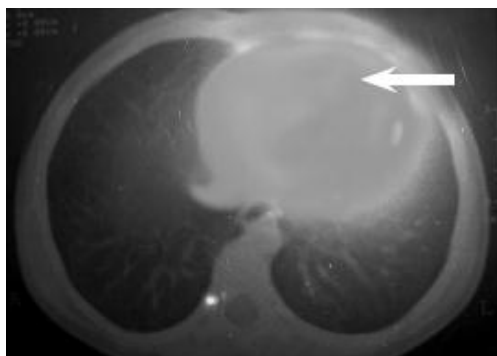
## **LABORATORY TESTS:**

- Myasthenia gravis – assay of acetyl choline receptor antibodies and single fibre electromyography
- Chronic progressive external ophthalmoplegia – electroretinography and visual evoked potential and mitochondrial assay.
- Thyroid eye disease – T3, T4 AND TSH.

## **IMAGING MODALITIES:**

Indicated in conditions like ptosis due to

- Neurological deficits and multiple sclerosis – level of lesion.
- Horner's syndrome – level of lesion
- Myasthenia gravis (CT CHEST) – detects thymoma



**Fig 20: Axial CT chest showing thymoma in Myasthenia**

## **MANAGEMENT OF PTOSIS**

### **MEDICAL MANAGEMENT:**

Observation can be done in cases of mild congenital ptosis if there are no signs of strabismus, amblyopia and abnormal head posture is present. In myasthenia gravis also the first line of management is with cholinesterase inhibiting medications, immunosuppressive agents and steroids and crutch spectacles can be tried. In refractory cases undercorrection of ptosis can be planned using silicone slings.



**Fig 22: Crutch glasses**

## **SURGICAL MANAGEMENT**

### **GOALS OF PTOSIS SURGERY:**

Ptosis surgery is one of the challenging surgeries for oculoplastic surgeons. Its primary goal is to recreate nearly perfect position of eyelids and creating a lid fold if needed. Special attention is also given to the symmetry and contour of eyelids. The consequences of ptosis surgery should be explained in detail to the patients. The lid level can be changed but dynamic limitations of the affected muscle persist post operatively and can result in lid lag or lagophthalmos.

### **TIMING OF SURGERY:**

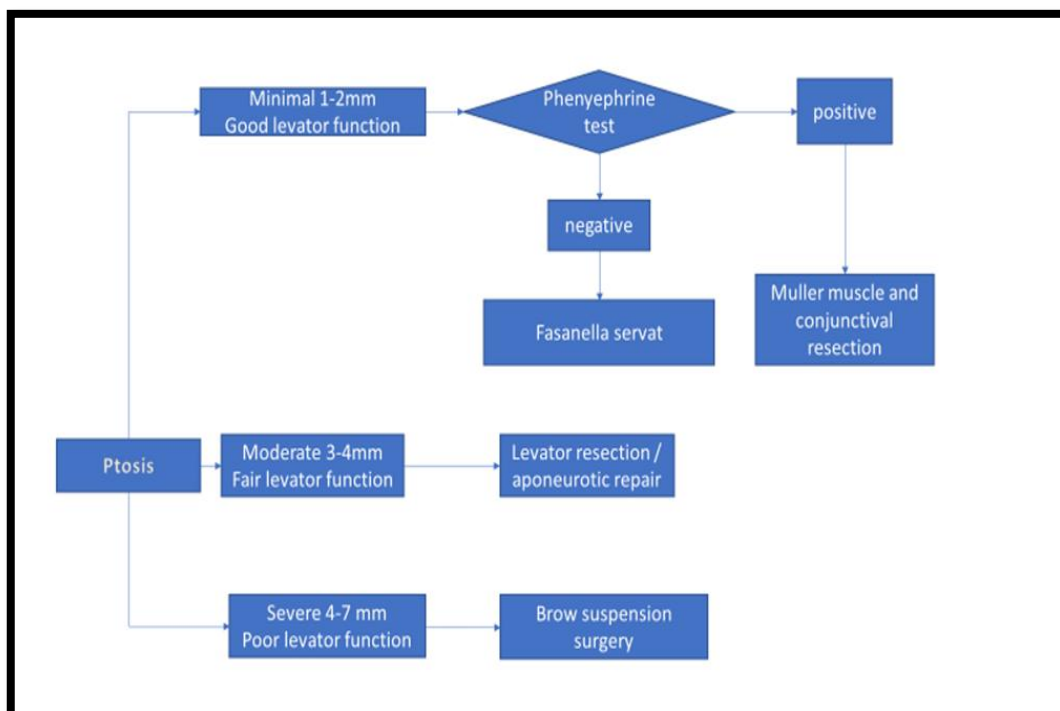
- In case of congenital ptosis, the primary reason is cosmetic. Most surgeons agree that it should be corrected prior to age of 5. If there is risk of amblyopia then it should be treated urgently with surgical correction of ptosis and amblyopia management is essential.
- In case of acquired ptosis, surgery is often recommended when the patients daily activities are compromised due to occlusion of visual axis or superior field is completely lost or there is extreme fatiguability while reading.

## ANESTHESIA:

General anesthesia is preferred in case of children whereas in case of adults local anesthesia is preferred since it avoids levator akinesia and helps to allow levator muscle to function intraoperatively. The maintenance of levator function is essential since it provides valuable guide in judging amount of levator resection.

## SURGICAL PROCEDURES:

The choice of surgery depends on the severity of ptosis and the levator muscle function.



**Fig 22: Table for management of ptosis**

## **SURGERIES FOR SIMPLE CONGENITAL PTOSIS:**

1. Fasanella servat (trans tarso conjunctival mullerectomy)
2. Muller's muscle and conjunctival resection
3. Levator resection
4. Brow suspension or trans – frontalis suspension

## **SURGERIES FOR APONEUROTIC PTOSIS:**

1. Aponeurotic advancement.

## **FASANELLA SERVAT PROCEDURE:**

### **Principle:**

In this procedure upper part of tarsus along with its attached palpebral conjunctiva and muller's muscle is excised and hence shortening of the posterior lamella of upper eyelid is achieved.

### **Indications:**

- ❖ Horner's syndrome
- ❖ Mild congenital ptosis with good levator function.
- ❖ Small degree of involutional ptosis that is not associated with aponeurotic weakness.

**Advantages:** Very useful procedure for mild ptosis with good levator function.

## **MULLER'S MUSCLE AND CONJUNCTIVAL RESECTION:**

### **Principle:**

Here the muller muscle along with underlying conjunctiva is resected.

### **Indications:**

2.5% Phenylephrine test is very useful in assessing the outcome of surgery preoperatively. Any ptosis with positive response (>2mm lid elevation) can be planned for this procedure.

### **Advantages:**

Tarsectomy, meibomian secretion loss in tarsal gland – tarsal procedure can lead to lid instability and can be prevented in this procedure.

## **LEVATOR RESECTION:**

1. Anterior or trans cutaneous approach (EVERBSCH SURGERY)
2. Posterior or trans conjunctival approach (BLASKOVIC'S SURGERY)



## **ANTERIOR APPROACH FOR LEVATOR RESECTION:**

### **Principle:**

The orbital septum is divided and then the pre aponeurotic fat is exposed which is retracted, so that the underlying levator is exposed. The muscle is shortened and is sutured directly to tarsus. The skin crease is reformed. Amount of levator resection based on **BEARD'S** pre-operative evaluation.

| <b>Degree of ptosis</b> | <b>Levator function</b> | <b>Resection</b>                                      |
|-------------------------|-------------------------|---|
| <b>Mild (&lt;2mm)</b>   | <b>&gt;8 mm</b>         | <b>Small (10-13 mm)</b>                               |
| <b>Moderate (3mm)</b>   | <b>5-8 mm</b>           | <b>Moderate (14-17 mm)</b><br><b>Large (18-22 mm)</b> |
| <b>Severe (&gt;4mm)</b> | <b>&lt;5mm</b>          | <b>Maximum (&gt;23 mm)</b>                            |

### **Indications:**

Ptosis with moderate levator function.

### **Advantages:**

Better approach with easier accessibility and identification of lid structures (muscle attachments). Larger levator resection is possible and also formation of lid crease.

## **POSTERIOR APPROACH FOR LEVATOR RESECTION:**

It has principle similar to that of anterior approach but with a trans conjunctival approach.

### **Indications :**

Ptosis with moderate or more levator function.

### **Advantages:**

Isolating the levator muscle from surrounding structures is easier.  
Cosmetically better procedure compared to anterior approach.

### **Disadvantages:**

Since the lid is oriented inside out, orientation of structures become difficult, larger dissection of levator muscle is difficult. There is also a risk of damage to lacrimal gland.

## **BROW SUSPENSION OR TRANS FRONTALIS SUSPENSION:**

### **Principle:**

The frontalis muscle can be made to lift eyebrow and eyelid with placement of a sling which connects upper tarsal plate to the frontalis muscle.

**Indications:**

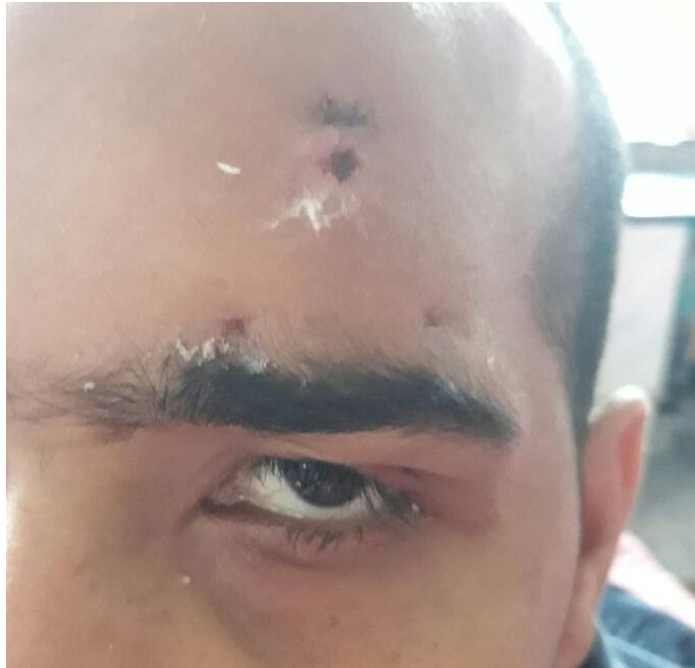1. Ptosis with poor levator function (<4mm)
2. Blepharophimosis syndrome
3. Myogenic and neurogenic ptosis

**Various materials used for frontalis sling surgery:**

- ❖ Fascia lata
- ❖ Frontalis muscle flaps
- ❖ Frozen banked dura mater
- ❖ Palmaris longus tendon
- ❖ Non absorbable suture materials like 4'0 prolene
- ❖ Silicone rods
- ❖ Mersilene mesh
- ❖ Goretex suture

**Different Methods:**

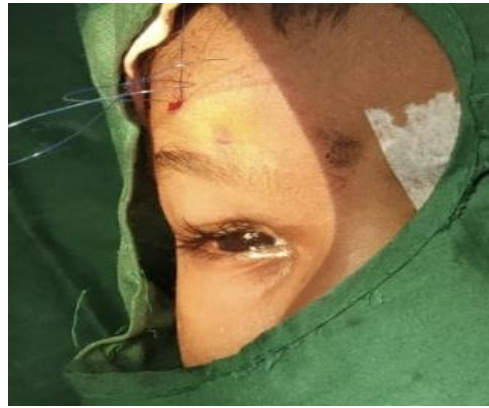
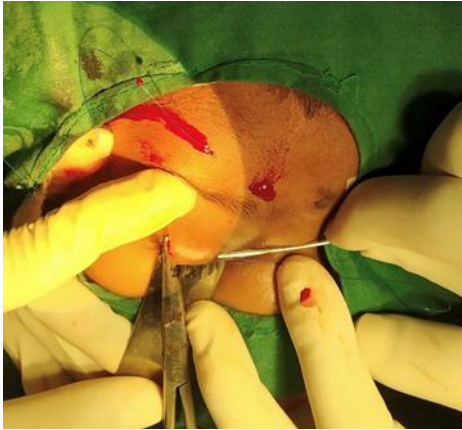
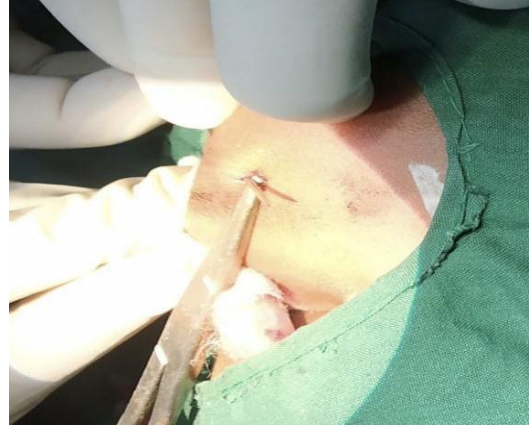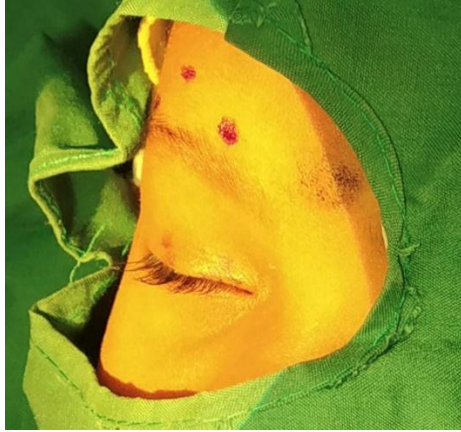- ❖ Double rhomboid sling
- ❖ Crawford's triangular or modified crawford's sling
- ❖ Fox pentagon sling



Of these, fox pentagon sling is the most commonly used procedure.

- ❖ Fox pentagon technique involves total of 5 incisions, two in upperlid and three supra brow incisions. The sling material is then passed under the orbital septum near arcus marginalis and the passes out of brow incision using wright's needle. The sling is externalized in the central brow incision, which is tightened cut and buried. The stab incisions are then closed with 6'0 vicryl suture.

## STEPS OF FRONTALIS SLING SURGERY



## **SURGERY FOR APONEUROTIC PTOSIS:**

### **Aponeurotic advancement surgery:**

#### **Principle:**

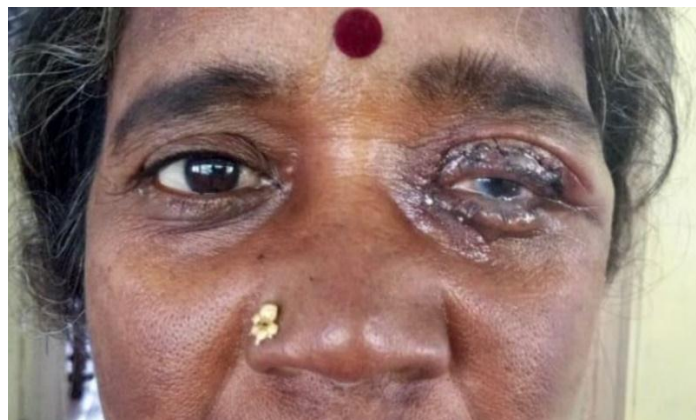The anatomical defect caused due to complete dehiscence of the levator aponeurosis from the tarsal plate is repaired .

#### **Indication:**

In cases of acquired aponeurotic ptosis (senile involucional) or ptosis secondary to trauma or chronic inflammatory changes which results in dehiscence or disinsertion of the levator aponeurosis with near normal levator function.

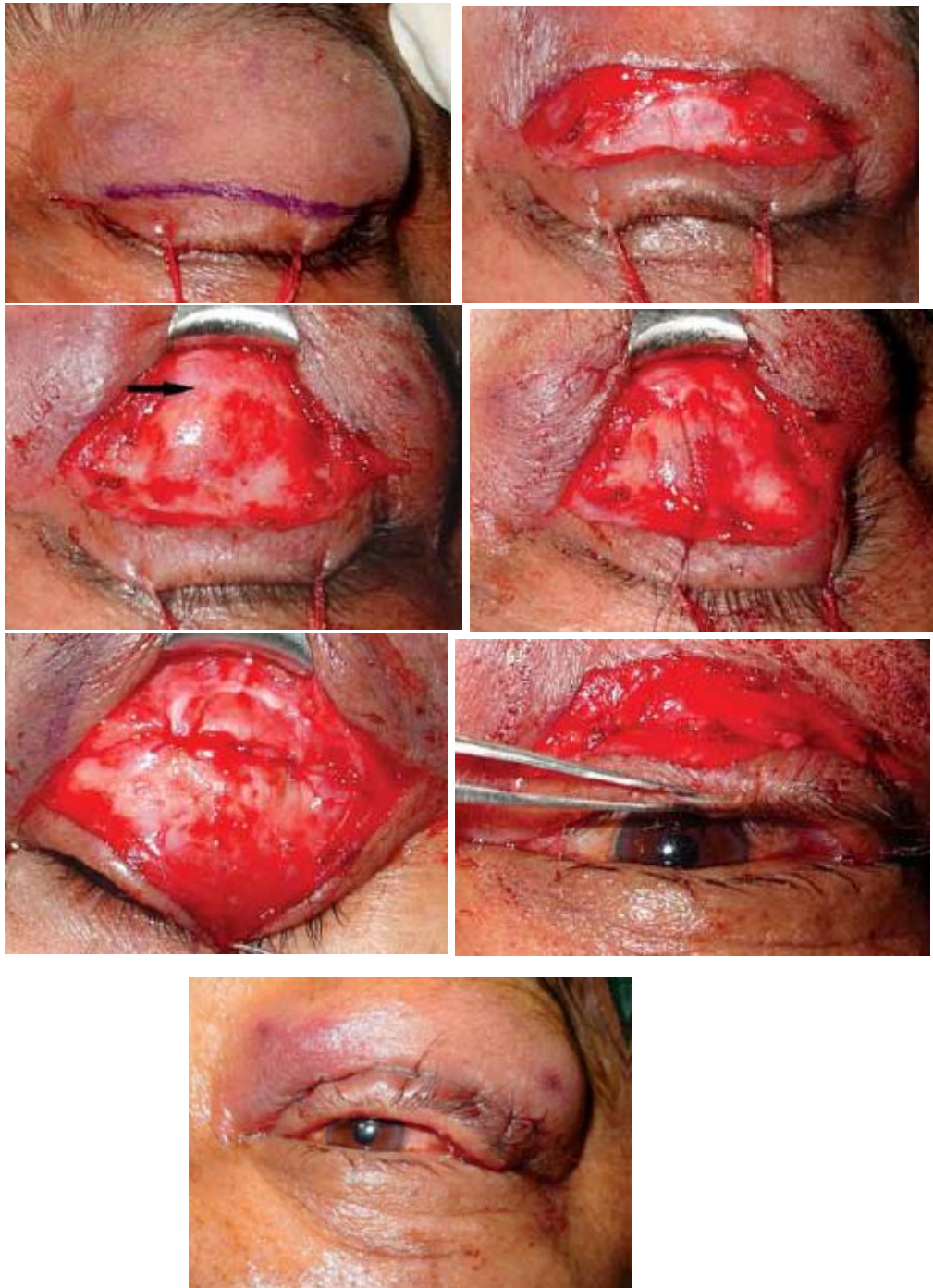#### **Contraindications:**

- All other causes of ptosis
- Ptosis with poor levator function.



**Fig 23: Aponeurotic advancement surgery**

## STEPS OF LEVATOR ADVANCEMENT SURGERY



## **COMPLICATIONS OF PTOSIS SURGERY**

### **a) Under correction:**

It is one of the most common complications due to either less resection of the levator muscle or following frontalis sling. It is either due to faulty judgement or techniques. May require repeat surgeries.

### **b) Overcorrection**

### **c) Lid lag or lagophthalmos**

### **d) Exposure keratitis:**

Due to lid lag or overcorrection of ptosis. Lubricating eye drops can be prescribed. If severe tarsorrhaphy can be planned.

### **e) Ectropion :**

Following posterior approach (trans conjunctival) of levator resection.

### **f) Entropion:**

Following frontalis sling surgeries or following maximal levator resection.



**g) Loss of eyelid lashes**

**h) Lid crease / lid fold abnormalities:**

Lid crease may be too mild or too low. Multiple lid folds can occur if excess skin has not been excised.

**i) Conjunctival prolapse:**

It is one of the rare and reversible complication of ptosis surgery.

**j) Hemorrhage:**

Due to abundant blood supply. Treatment involves pressure bandage over the eyelids for 1 -2 days.

**k) Infection:**

Though rare if occurs should be treated with antibiotics. More common among non absorbable sutures where if it recurs require removal of sutures and resurgery.

## **SECTION II**

### **AIM OF THE STUDY:**

- 1.To study the etiology of ptosis between 20 – 50 years of age.
- 2.Management of various types of ptosis.
- 3.To assess various modalities of surgical management of ptosis and its complications.

### **MATERIALS AND METHODS:**

This prospective study was conducted at Regional Institute Of Ophthalmology, Government Ophthalmic Hospital, Chennai for a period of one year from July 2018 – June 2019. Cases were from Chennai, and were referred from different parts of the state to this tertiary care hospital.

### **INCLUSION CRITERIA:**

- ❖ Includes all patients with ptosis between the age of 20 – 50 years.

## **EXCLUSION CRITERIA:**

- ❖ Patients less than 20 years and more than 50 years of age
- ❖ Vascular malformations and malignant tumours of the lid.

## **STATISTICAL ANALYSIS:**

- ❖ Here all variables were described with frequency distribution and displayed using percentage (statistical package)

## **METHODOLOGY:**

- ❖ 30 patients who presented to orbit and oculoplasty services with ptosis between 20 – 50 years of age were registered, evaluated and followed up during the study period.
- ❖ Patients were evaluated with detailed history, and complete general examination and ocular examination. Ocular examination includes visual acuity, anterior segment evaluation, ptosis evaluation and posterior segment evaluation.
- ❖ Ptosis evaluation included examination of Head Posture, Vertical Palpebral Height, Margin Reflex Distance, Lid Crease Level, Levator Palpebrae Superioris Action, Bell's Phenomenon, Marcus Gunn Jaw Winking Phenomenon, Ice

Pack Test, Fatiguability Test, corneal sensation, Strabismus Evaluation and Extra Ocular Muscles Motility.

- ❖ Based on clinical examination appropriate diagnosis was arrived and further investigations were done to confirm the etiological diagnosis. Patients were referred to other departments whenever indicated.
- ❖ Patients were treated accordingly and if managed surgically then the outcome of the surgery is also assessed. Pre and post operative photographs were taken and documented for comparing the outcome of surgery.
- ❖ Surgery was decided on the type of ptosis, amount of levator function, margin limbal distance and degree of ptosis.
- ❖ Post operative evaluation were done for all operated cases on first and fifth post operative day and monthly follow up for 2<sup>nd</sup> and 6<sup>th</sup> month. The need for follow up was to look for incidence of complications like under or over correction, lid peaking, ectropion and entropion.

## RESULTS AND ANALYSIS

Total number of ptosis cases reported to RIOGO during the study period July 2018 – June 2019 were 90 cases which includes all age group.

### DISTRIBUTION OF PTOSIS IN GENERAL POPULATION:

| AGE            | NO OF CASES | PERCENTAGE |
|----------------|-------------|------------|
| Upto 19 years  | 46          | 51%        |
| 20 – 50 years  | 30          | 33%        |
| Above 50 years | 24          | 26%        |

Table 1: Distribution of ptosis in general population

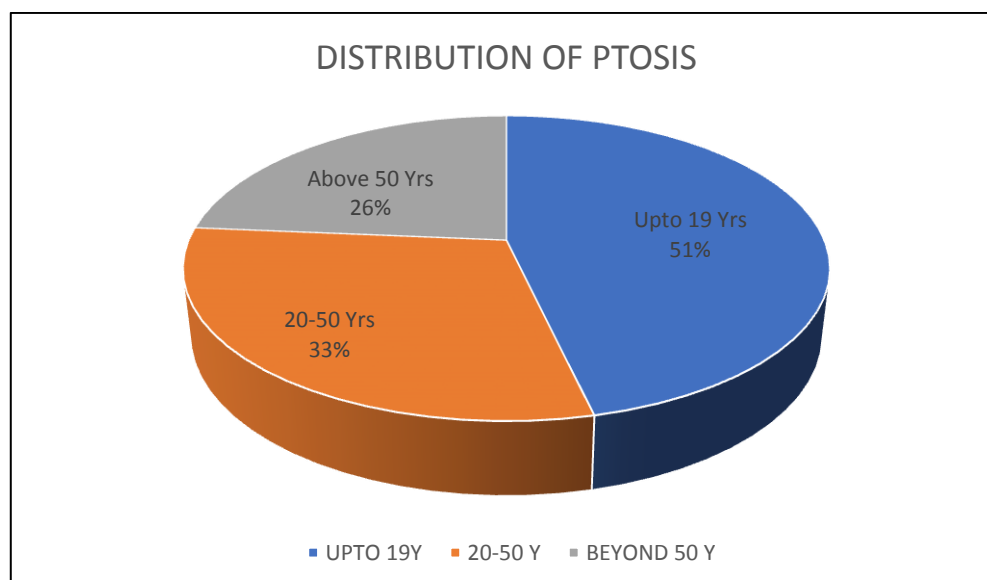


Chart 1: Pie chart showing distribution of ptosis in general population

The incidence of ptosis was high in less than 20 years followed by 20–50 years and then above 50 years. Only 33% of population were between 20 – 50 years which were included in the study.

### **INCIDENCE OF PTOSIS BETWEEN 20-50 YEARS:**

Incidence of ptosis between 20-50 years in Regional Institute Of Ophthalmology during the study period was 30 of which congenital ptosis – 11 cases (37%), aponeurotic ptosis – 8 cases (26%), myogenic ptosis – 4 cases (13%), neurogenic ptosis – 3 cases(10%), mechanical ptosis – 2 cases (7%), post traumatic ptosis -2 cases (7%).

| <b>Type of ptosis</b> | <b>Congenital ptosis</b> | <b>Aponeurotic ptosis</b> | <b>Myogenic ptosis</b> | <b>Neurogenic ptosis</b> | <b>Mechanical ptosis</b> | <b>Post traumatic ptosis</b> | <b>Total</b> |
|-----------------------|--------------------------|---------------------------|------------------------|--------------------------|--------------------------|------------------------------|--------------|
| <b>No of cases</b>    | <b>11</b>                | <b>8</b>                  | <b>4</b>               | <b>3</b>                 | <b>2</b>                 | <b>2</b>                     | <b>30</b>    |
| <b>Percentage</b>     | <b>37%</b>               | <b>26%</b>                | <b>13%</b>             | <b>10%</b>               | <b>7%</b>                | <b>7%</b>                    | <b>100%</b>  |

Table 2: Incidence of ptosis between 20 – 50 years of age

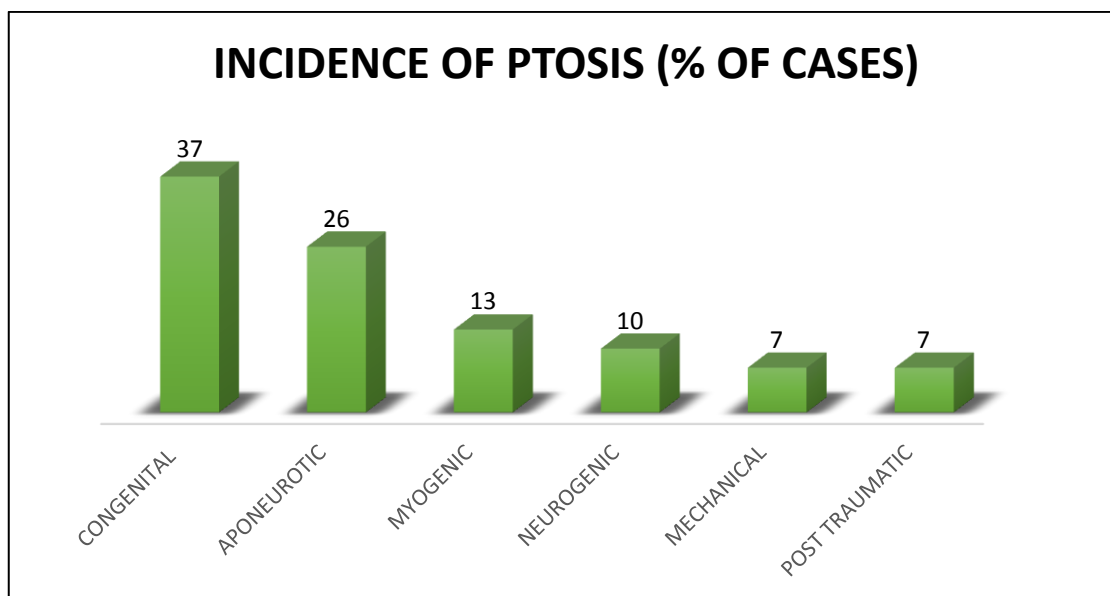


Chart 2: Bar diagram showing incidence of ptosis between 20-50 years

Of the total cases in our study, the highest incidence was by congenital ptosis followed by aponeurotic ptosis.

### **AGE DISTRIBUTION BETWEEN 20 – 50 YEARS OF AGE:**

| <b>AGE IN YEARS</b> | <b>NO OF CASES</b> | <b>PERCENTAGE</b> |
|---------------------|--------------------|-------------------|
| 20 – 29 yrs         | 13                 | 44%               |
| 30 – 39 yrs         | 10                 | 33%               |
| 40 – 49 yrs         | 7                  | 23%               |

Table 3: Age distribution between 20 – 50 years of age with ptosis

Of the ptosis between 20 - 50 age group in our study, the highest incidence was seen between 20 – 29 years of age (44%).

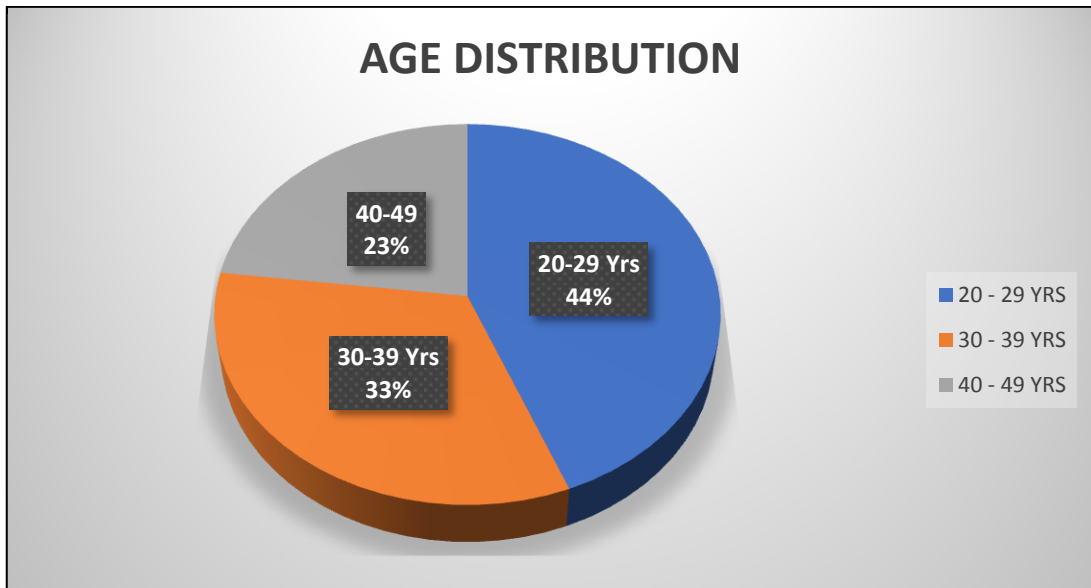


Chart 3: Pie chart showing age distribution between 20 -50 years of age with ptosis.

### AGE WISE INCIDENCE OF PTOSIS :

| AGE IN YRS | CONGENITAL PTOSIS | APONEUROTIC PTOSIS | MYOGENIC PTOSIS | NEUROGENIC PTOSIS | MECHANICAL PTOSIS | POST TRAUMATIC PTOSIS |
|------------|-------------------|--------------------|-----------------|-------------------|-------------------|-----------------------|
| 20-29      | 10                | -                  | 2               | -                 | -                 | 1                     |
| 30-39      | 1                 | 5                  | -               | 1                 | 2                 | 1                     |
| 40-49      | -                 | 3                  | 2               | 2                 | -                 | -                     |

Table 4: Age wise incidence of ptosis among middle age



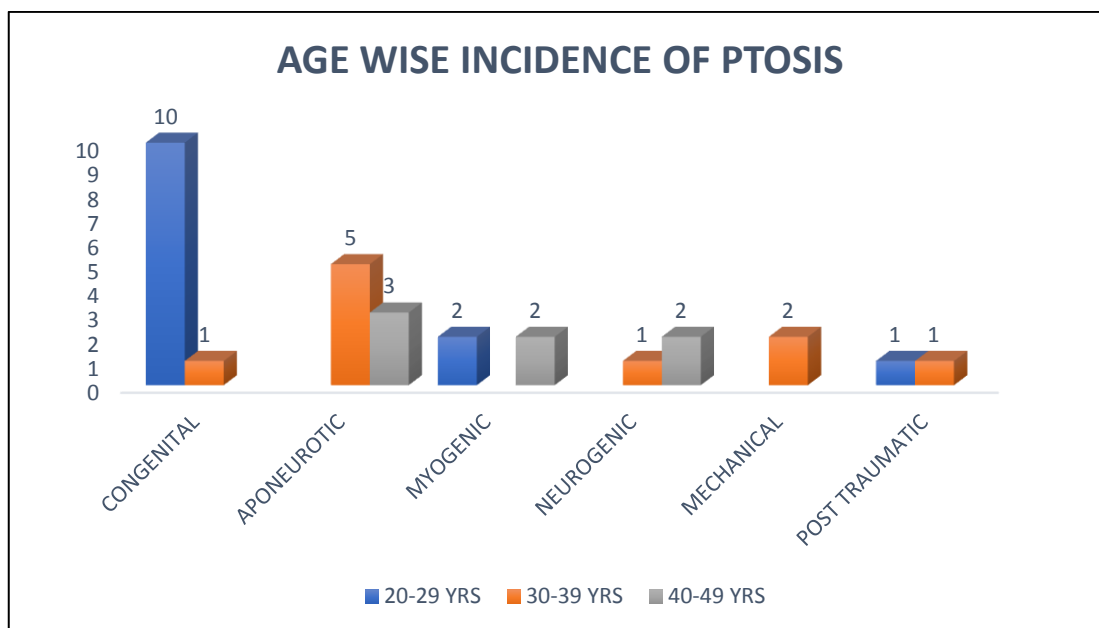


Chart 5: Age wise incidence of ptosis between 20 – 50 years of age.

It shows that incidence of congenital ptosis was more common among 20-29 years indicating the cosmetic consciousness in such age group and incidence of aponeurotic ptosis were more common after 30 years.

## **SEX DISTRIBUTION BETWEEN 20 – 50 YEARS OF AGE WITH PTOSIS:**

| <b>SEX</b> | <b>NO OF CASES</b> | <b>PERCENTAGE</b> |
|------------|--------------------|-------------------|
| Male       | 21                 | 70%               |
| Female     | 9                  | 30%               |

Table 5: Sex distribution between 20 – 50 years of age with ptosis

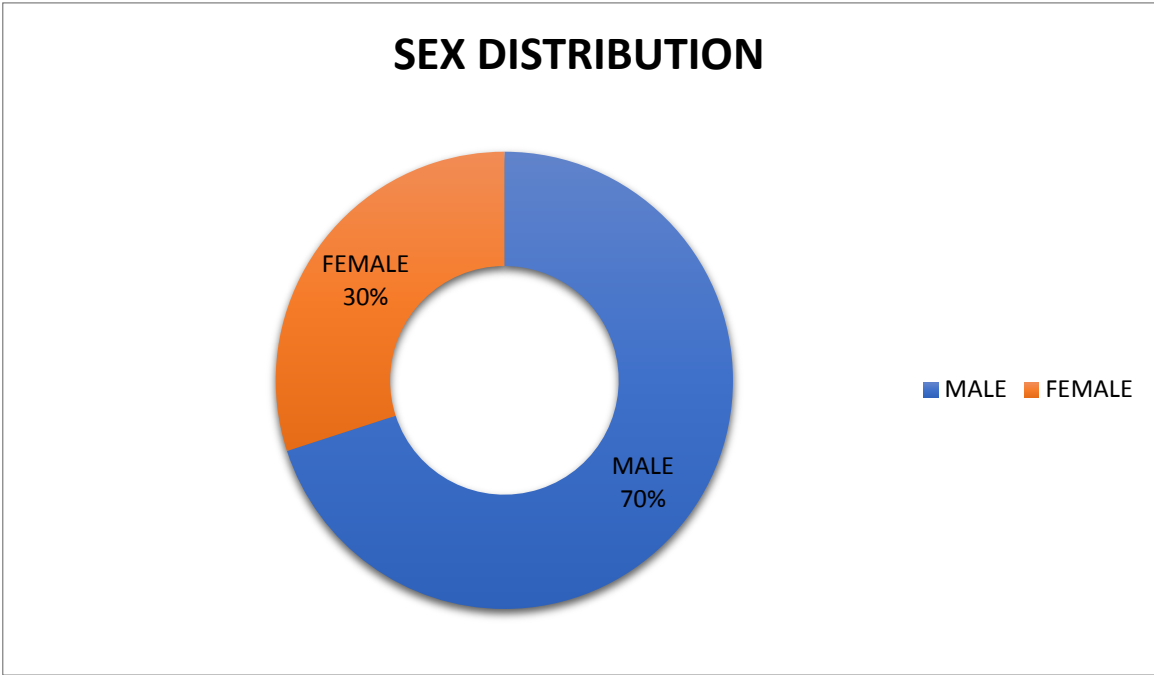
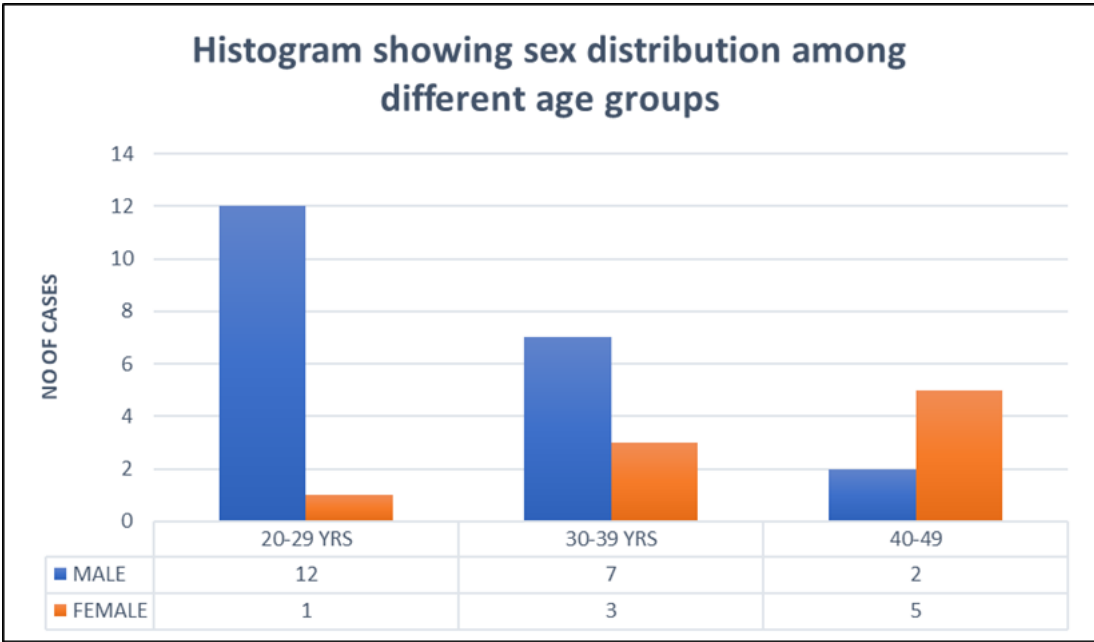


Chart 5: Doughnut chart showing Sex distribution.

Of the reported ptosis cases between 20 – 50 years of age in this study, 70% were males and the remaining 30% were female. This shows that there is a male predominance in our study.



## LATERALITY:

Among 30 cases, 23 patients had unilateral ptosis while 7 patients had bilateral ptosis. Right eye was involved in 13 cases, left eye in 10 cases and both in 7 cases. Hence unilateral ptosis was more common than bilateral ptosis and predominance of right eye was seen in this study.

| LATERALITY | NO OF CASES | PERCENTAGE |
|------------|-------------|------------|
| Unilateral | 23          | 77%        |
| Bilateral  | 7           | 23%        |

Table 6: Laterality of ptosis between 20 – 50 years of age

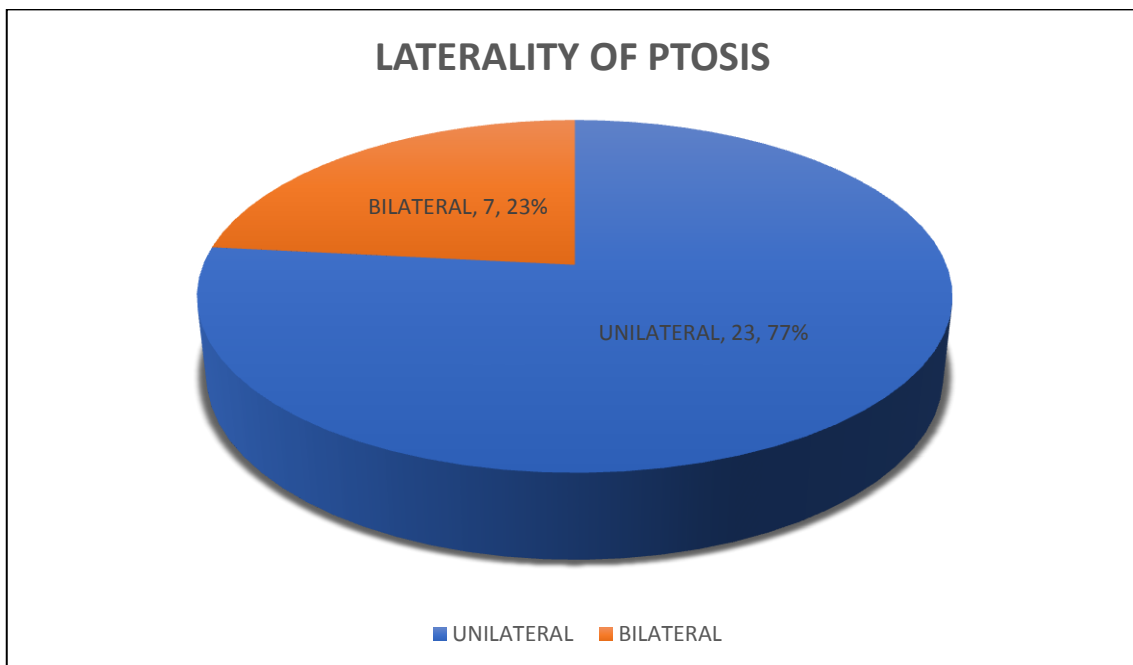


Chart 6: Laterality of ptosis between 20 – 50 years of age

| <b>LATERALITY</b> | <b>NO OF CASES</b> | <b>PERCENTAGE</b> |
|-------------------|--------------------|-------------------|
| Right eye         | 13                 | 43.3%             |
| Left eye          | 10                 | 33.3%             |
| Both eyes         | 7                  | 23.3%             |

Table 7: Laterality of ptosis between 20 – 50 years of age

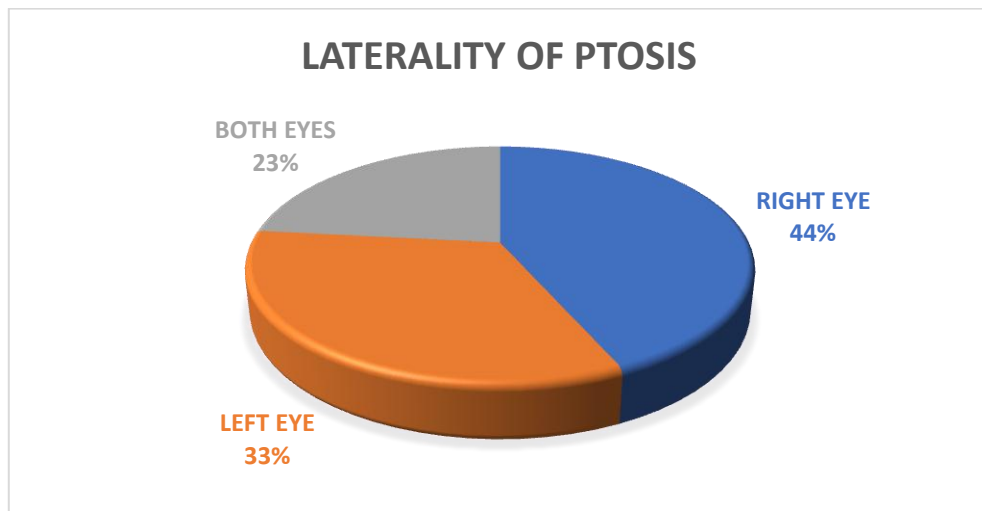


Chart 7: Distribution of Laterality of ptosis

### **DEGREE OF PTOSIS:**

Mild degree of ptosis (1-2mm) was found in 3 cases (10%), whereas moderate degree of ptosis (3mm) in 14 cases (46.7%) and severe ptosis (>4mm) in 13 cases (43.3%).

| Degree of ptosis | Mild (1-2mm) | Moderate(3mm) | Severe (>4mm) |
|------------------|--------------|---------------|---------------|
| No of cases      | 3            | 14            | 13            |
| Percentage%      | 10%          | 46.7%         | 43.3%         |

Table 8: Degree of ptosis between 20 – 50 years of age

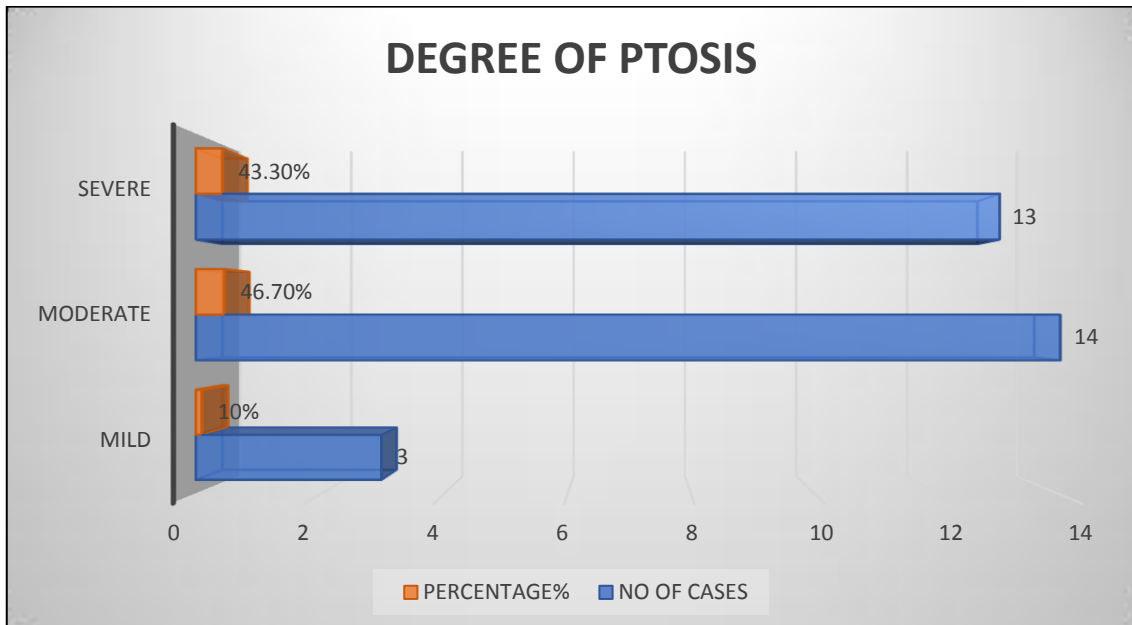


Chart 8: Bar diagram showing severity of ptosis

Hence moderate ptosis (46.7%) formed a major composition of our study shortly followed by severe ptosis (43.3%) followed by mild ptosis (10%).

## **MANAGEMENT OF PTOSIS BETWEEN 20 – 50 YEARS OF AGE:**

Out of 30 cases in our study population, with 37 eyes (7 bilateral ptosis), 9 cases were managed medically (30%) and 21 cases (70%) surgically. In 7 bilateral ptosis, 2 cases were managed medically and 5 cases needed surgical intervention of which 1 case had been operated on both eyes while remaining 4 cases had one eye operated and did not have other eye operated.

| <b>Management</b>     | <b>Medical</b> | <b>Surgical</b> |
|-----------------------|----------------|-----------------|
| <b>No of cases</b>    | 9              | 21              |
| <b>Percentage (%)</b> | 30%            | 70%             |

Table 9: Analysis of treatment modalities among middle age population.

Among 30 patients, 21 patients underwent surgery for ptosis correction. All surgeries were done under local anaesthesia. Congenital, aponeurotic and mechanical ptosis were treated surgically while myogenic, neurogenic and post traumatic ptosis were managed medically in our study.

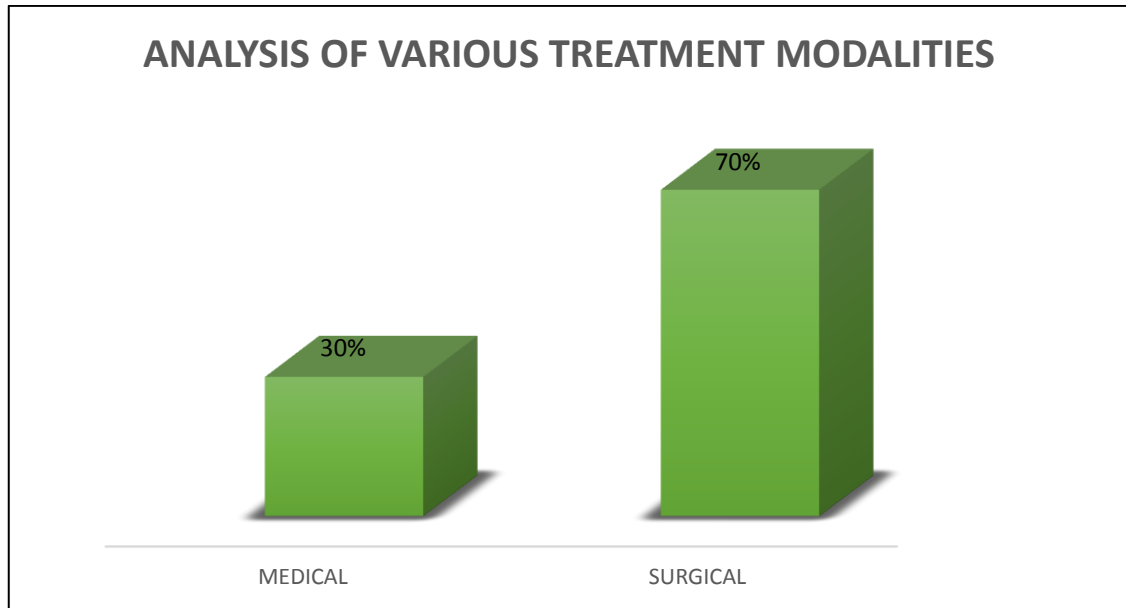


Chart 9: Analysis of various treatment modalities among middle age population

### **MANAGEMENT OF CONGENITAL PTOSIS:**

Frontalis sling was done for 11 patients of congenital ptosis with poor levator function of which 10 cases were males and 1 case was female. Frontalis sling was done with fox pentagon technique and it gave good results. In our study we used 4'0 prolene as suspensory material. In recent advances even mercilene mesh and silicon rods can also be used. Though bilateral frontalis sling is preferred since it produces symmetrical results on down gaze for cosmetic results, only the affected eye was operated in this study.

The reason for selection of 4'0 prolene as suspensory material was

- Less expensive
- Ease of availability
- Though fascia lata is ideal material, many were not willing for harvest.

Disadvantages <sup>31</sup>:

- Risk of suture granuloma
- Extrusion
- Failure

The major complications that were encountered during follow up were under correction (27.3%) in 3 cases followed by mild exposure keratitis (9.1%) in one patient which was managed medically by lubricants.

| <b>COMPLICATIONS</b> | <b>NO OF CASES</b> | <b>PERCENTAGE</b> |
|----------------------|--------------------|-------------------|
| Under correction     | 3                  | 27.3%             |
| Exposure keratitis   | 1                  | 9.1%              |
| Uncomplicated        | 7                  | 63.6%             |

Table 10: Complications following frontalis sling surgery



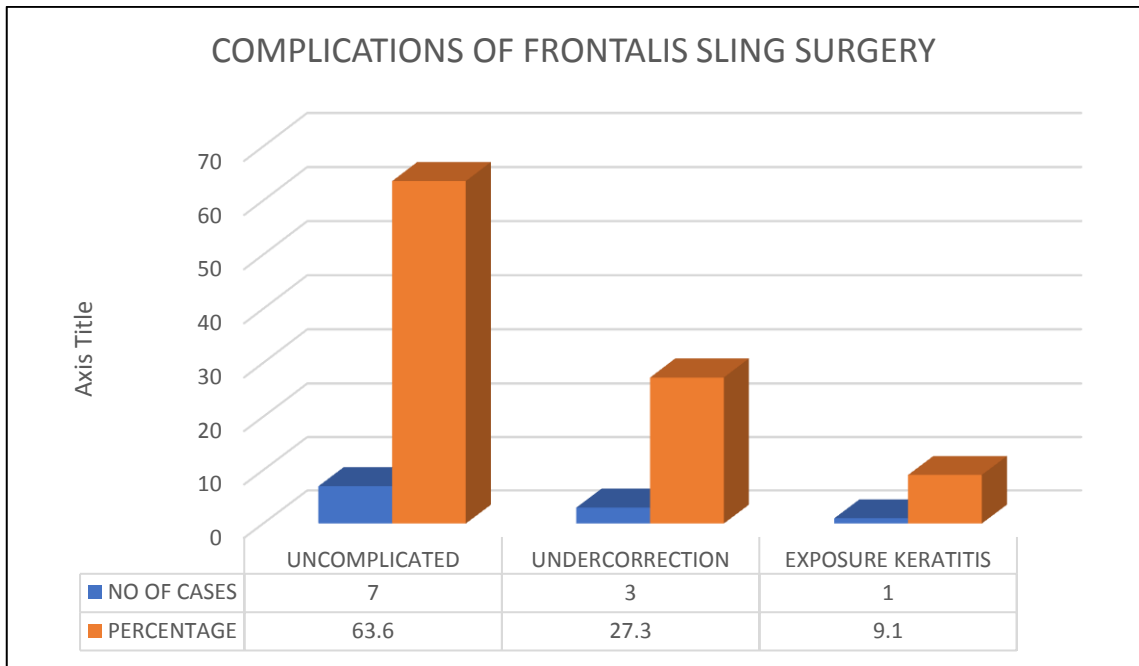
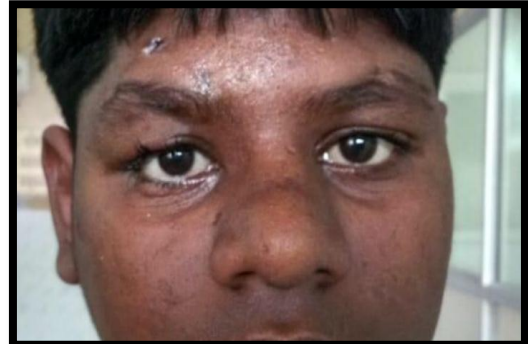
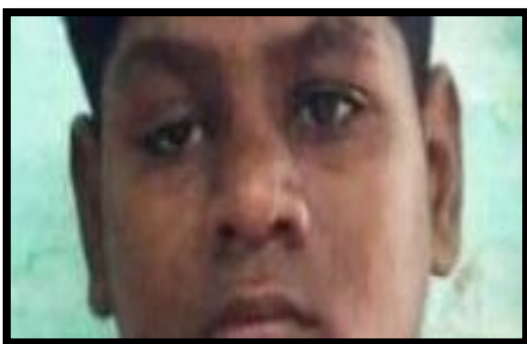
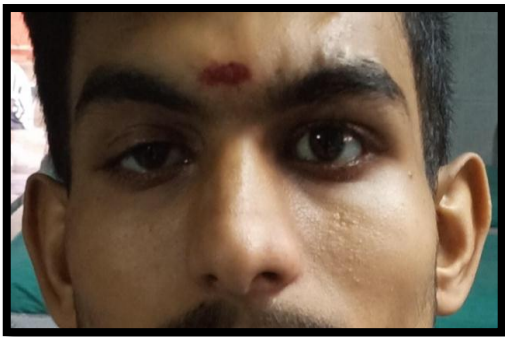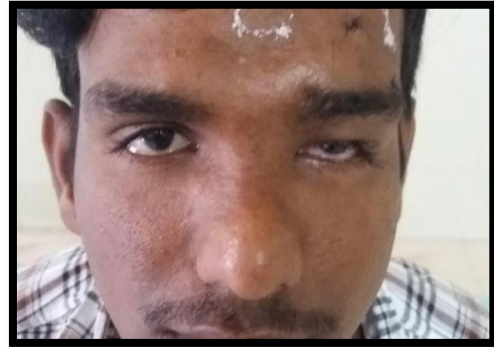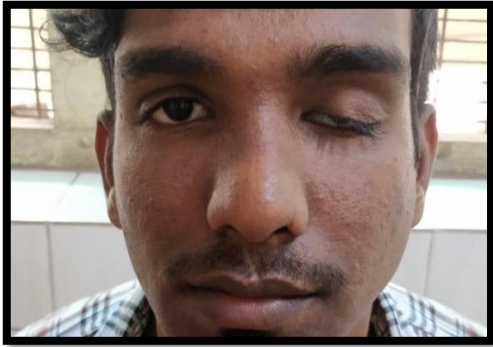Chart 10: Distribution of Complications following frontalis sling surgery

**FRONTALIS SLING SURGERY**

**PRE OP**

**POST OP**



## **MANAGEMENT OF APONEUROTIC PTOSIS:**

Levator Aponeurotic advancement surgery was done for 8 patients with aponeurotic ptosis with good levator function of which 5 were male and 3 were female. The technique that was used was transcutaneous approach. Careful attention was given to eyelid crease and intraoperative adjustment was made by comparing with the other eye lid position. 3 suture technique<sup>24</sup> was used in all cases.

Advantages of this technique:

- Easy and better exposure of tissues
- There is no need for lid eversion
- More access to levator aponeurosis
- There is no conjunctival or corneal injury
- Lid fold and excess skin can be easily excised and formation of new lid crease is easier

Complication encountered during this procedure is undercorrection in one case (12.5%) and mild lid peaking in one case (12.5%).

| <b>Complications</b>    | <b>No of cases</b> | <b>Percentage</b> |
|-------------------------|--------------------|-------------------|
| <b>Uncomplicated</b>    | 6                  | 75%               |
| <b>Under correction</b> | 1                  | 12.5%             |
| <b>Lid peaking</b>      | 1                  | 12.5%             |

Table 11: Distribution of complications of aponeurotic advancement surgery

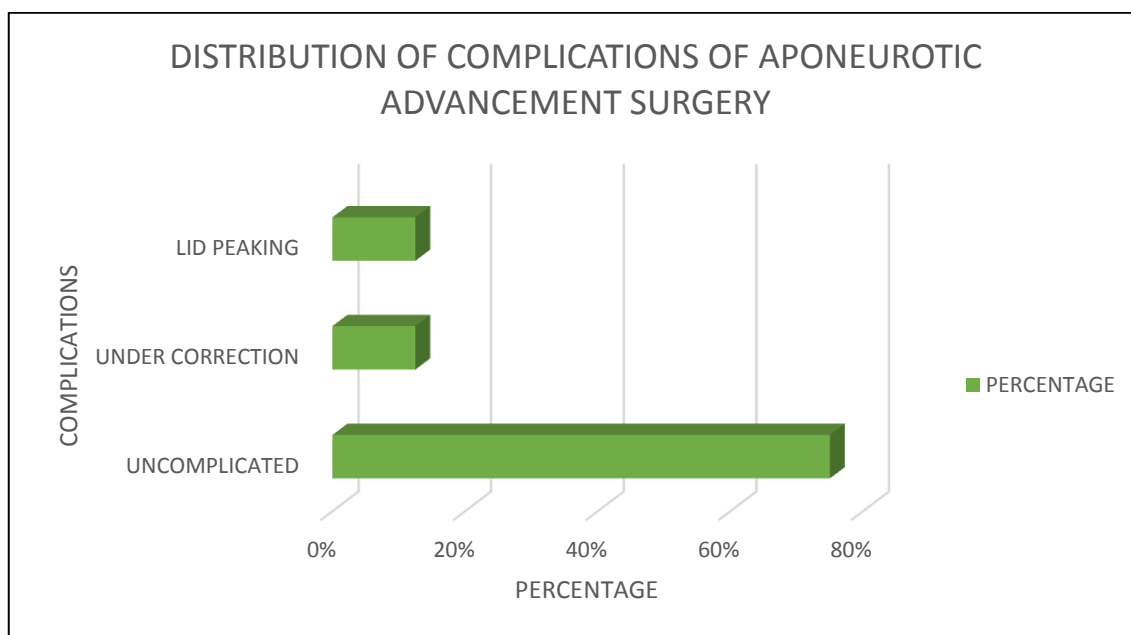
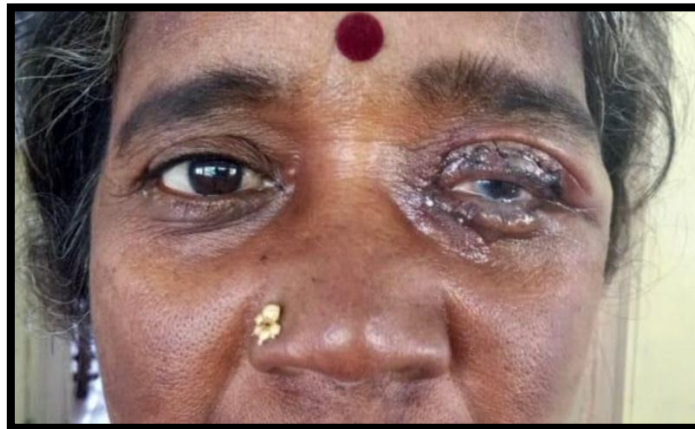

Chart 11: Distribution of complications of aponeurotic advancement surgery

## **APONEUROTIC PTOSIS PRE OP AND POST OP**



### **MANAGEMENT OF MECHANICAL PTOSIS:**

In our study we had 2 cases of which Excision biopsy was done for one patient which on histopathological examination turned out to be squamous papilloma and other was chalazion induced mechanical ptosis for which chalazion incision and curettage was done.

## **MANAGEMENT OF NEUROGENIC PTOSIS:**

In our study we had 3 cases of neurogenic ptosis, first case was due to leptomeningeal carcinomatosis infiltrating the 3<sup>rd</sup> nerve and the patient is on chemotherapy and other case was due to posterior communicating artery aneurysm for which aneurysmal clipping was done in neurosurgical department last case was due to microvascular ischemia of diabetic etiology and MRI BRAIN turned out to be normal hence the patient were managed medically and symptomatically by occlusion of the affected eye.

## **MANAGEMENT OF MYOGENIC PTOSIS:**

Out of 4 myogenic cases 3 cases turned out to be myasthenia with positive ice pack and fatiguability test and anti acetylcholine receptor antibody positivity and was managed medically by acetylcholinesterase inhibitors. Other case was diagnosed to have CPEO and was prescribed crutch glasses.

## **MANAGEMENT OF POST TRAUMATIC PTOSIS:**

There were 2 cases of traumatic ptosis, one was due to traumatic 3<sup>rd</sup> nerve palsy with traumatic optic neuropathy and the patient was started on IV methylprednisolone 500mg bd for 3 days followed by oral prednisolone 1mg/kg body weight. Other patient had mild traumatic ptosis due to levator dehiscence and traumatic iritis which was managed medically by topical cycloplegics and steroids.

## DISCUSSION

- ❖ **Ahn et al**<sup>10</sup> in 1979 did a prospective study on clinical observation and surgical results of 67 cases of blepharoptosis and found that majority of patients (70%) were operated in second and third decade which was in correlation with our study and the most common ptosis was simple congenital ptosis and most common surgery was levator resection through transcutaneous approach.
  
- ❖ **Lee et al**<sup>11</sup> in 2018 studied demographic patterns of blepharoptosis and found that in 2328 patients, 1815 (78%) had simple congenital ptosis and 512 (22%) had acquired ptosis. Of congenital ptosis most had poor levator function (60.1%) Frontalis sling was most common surgery done which has results similar to our study.
  
- ❖ **Lim et al**<sup>12</sup> in 2013 did a retrospective study in 251 patients and found that aponeurotic ptosis (60.2%) is the most common type followed by traumatic ptosis(11.2%). Of neurogenic and myogenic ptosis 3<sup>rd</sup> nerve palsy was most common followed by myasthenia and chronic progressive external ophthalmoplegia whose results are similar to our study.



- ❖ **Thapa et al**<sup>13</sup> in 2006 did a descriptive cross sectional study in 125 patients and found that congenital ptosis were more common than acquired ptosis whose results were similar to our study. But in acquired ptosis trauma (32%) was most common cause followed by neurogenic (25.5%) ptosis but in study aponeurotic was most common cause followed by myogenic ptosis.
  
- ❖ **Gautam et al**<sup>14</sup> in 2016 did a retrospective study in 326 patients and found that congenital ptosis was present with early mean age being 23(SD +/- 9.9) and acquired ptosis with late mean age 35 (SD +/- 14). Unilateral ptosis (87%) was most common which was in correlation with our study. Among acquired myogenic was most common cause.
  
- ❖ **Clauser et al**<sup>15</sup> in 2006 on did a study on 42 patients of which 12 were congenital and 30 were acquired. The most commonly used surgery was levator resection and frontalis suspension surgery. Moderate (49.2%) and severe (43.6%) ptosis were the most common type followed by mild (7%) ptosis whose results were similar to our

study were moderate ptosis was most common type followed by severe and then mild ptosis.

- ❖ **Kim et al**<sup>16</sup> in 1995 did an analysis on 300 patients with ptosis and found that congenital ptosis (86%) was most common followed by acquired ptosis (14%) and the results were similar to our study. Of acquired ptosis mechanical (35.9%) was most common followed by traumatic ptosis (23.1%) in comparison to our study which had aponeurotic ptosis as the most common cause. Severe ptosis (72%) was most common whereas in our study moderate ptosis were most common.

## SUMMARY

30 patients with ptosis between 20 – 50 years of age who attended and was referred to the outpatient department of Orbit and Oculoplasty Services in RIOGOH, Chennai between July 2018 to June 2019 were analysed.

The analysis included incidence and various causes of ptosis, detailed clinical examination and investigations to arrive at the etiology of ptosis and the outcome of various treatment modalities which may be medical or surgical.

The findings of the analysis includes:

- i. Of the total 90 cases of ptosis who attended the hospital during the study period, 30 of them were between 20 – 50 years of age (33.3%).
- ii. The most common etiology between 20 – 50 years of age was congenital ptosis (37%) followed by aponeurotic ptosis (26%).
- iii. The most common age group between 20 – 50 years was between 20 – 29 years.
- iv. Congenital ptosis was more common among early 20s while aponeurotic ptosis presented generally above 35 years of age.

- v. The incidence of ptosis were more common among males (70%) compared to females (30%).
- vi. 23 cases presented with unilateral ptosis (77%) and 7 cases with bilateral ptosis (23%).
- vii. Of the unilateral ptosis, right eye (43.3%) was more predominant when compared to left eye (33.3%).
- viii. Moderate (46.7%) and severe (43.3%) ptosis were more predominant and almost equal on initial presentation when compared to mild ptosis (10%).
- ix. Of the different types of ptosis, congenital ptosis, aponeurotic ptosis and mechanical ptosis were managed surgically while myogenic, neurogenic and traumatic ptosis were managed medically.
- x. Surgical intervention composed 70% of the ptosis management.
- xi. The most common surgical procedure done in congenital ptosis was frontalis sling surgery by fox pentagon technique using 4'0 prolene as suspensory material. The most common complication encountered was under correction.
- xii. The most common surgical procedure done in aponeurotic ptosis was levator aponeurotic advancement by transcutaneous approach. Lid peaking and under correction were the most common complications encountered.

- xiii. Mechanical ptosis were treated by treating according to the primary pathology.
- xiv. Myogenic and neurogenic have very low incidence which were managed either by neurologist or by neurosurgical intervention.

## CONCLUSION

- ❖ Among the middle age population (20 – 50 years), incidence of ptosis was found to be more common in the age group of 20 – 29 years indicating the need for cosmetic correction among this group.
- ❖ Congenital and aponeurotic ptosis was the most common etiology seen in this age group.
- ❖ The incidence of congenital ptosis was more in 20s while aponeurotic was more above age group of 35 years indicating its etiopathological significance.
- ❖ The most common cause for acquired ptosis was aponeurotic followed by myogenic, neurogenic, traumatic and mechanical.
- ❖ Surgical intervention formed the major treatment of choice. Frontalis sling surgery was the most common surgery performed. Use of prolene as suspensory material gives good functional outcome. Other materials like fascia lata and mersilene mesh can also be considered.

- ❖ Aponeurotic advancement was the most common procedure done for acquired ptosis.
  
- ❖ Proper detailed history elicitation and complete clinical examination and ptosis evaluation will aid in arriving at correct etiology of ptosis. This is essential for plan of appropriate management. This results in good cosmetic and functional outcome of ptosis management.

## BIBLIOGRAPHY

1. Kersten RC, de Conciliis C, Kulwin DR. Acquired ptosis in the young and middle-aged adult population. *Ophthalmology*. 1995 Jun 1;102(6):924-8.
2. Rasiah S, Hardy TG, Elder JE, Ng CY, Lenake M, McNab AA. Aetiology of acquired blepharoptosis in young adults. *Orbit*. 2018 Jan 2;37(1):59-64.
3. Soohoo, Jeffrey R, Brett W. Davies, Felicia D. Allard and Vikram D. Durairaj. "Congenital ptosis." *Survey of ophthalmology* 59 5 (2014): 483-92 .
4. Simon GJ, MacEdo AA, Schwarcz RM, Wang DY, McCann JD, Goldberg RA. Frontalis suspension for upper eyelid ptosis: evaluation of different surgical designs and suture material. *American journal of ophthalmology*. 2005 Nov 1;140(5):877-85.
5. Benia L. A retrospective study of 1,500 personal cases of ptosis. *Journal francais d'ophtalmologie*. 1999 May;22(5):541-4.
6. McCulley TJ, Kersten RC, Kulwin DR, Feuer WJ. Outcome and influencing factors of external levator palpebrae superioris aponeurosis advancement for blepharoptosis. *Ophthalmic Plastic & Reconstructive Surgery*. 2003 Sep 1;19(5):388-93.
7. Baroody M, Holds JB, Vick VL. Advances in the diagnosis and treatment of ptosis. *Current opinion in ophthalmology*. 2005 Dec 1;16(6):351-5.
8. Wong VA, Beckingsale PS, Oley CA, Sullivan TJ. Management of myogenic ptosis. *Ophthalmology*. 2002 May 1;109(5):1023-31.
9. Satchi K, Kumar A, McNab AA. Isolated traumatic neurogenic ptosis with delayed recovery. *Ophthalmic Plastic & Reconstructive Surgery*. 2014 Jan 1;30(1):57-9.



10. Ahn YS, Lee TS. Clinical observation and their surgical results of 67 cases of blepharoptosis. *Journal of the Korean Ophthalmological Society*. 1979 Sep 1;20(3):283-90.
11. Lee YG, Son BJ, Lee KH, Lee SY, Kim CY. Clinical and Demographic Characteristics of Blepharoptosis in Korea: A 24-year Experience including 2,328 Patients. *Korean Journal of Ophthalmology*. 2018 Aug 1;32(4):249-56.
12. Lim JM, Hou JH, Singa RM, Aakalu VK, Setabutr P. Relative incidence of blepharoptosis subtypes in an oculoplastics practice at a tertiary care center. *Orbit*. 2013 Aug 1;32(4):231-4.
13. Thapa R, Karmacharya PC, Nepal BP. Etiological pattern of blepharoptosis among patients presenting in teaching hospital. *JNMA; journal of the Nepal Medical Association*. 2006;45(162):218-22.
14. Gautam P, Adhikari R, Sharma BR. Etiopathogenetic patterns of blepharoptosis in Western Nepal: an Overview. *Nepalese Journal of Ophthalmology*. 2016 Dec 12;8(1):36-40.
15. Clauser L, Tieghi R, Galie M. Palpebral ptosis: clinical classification, differential diagnosis, and surgical guidelines: an overview. *Journal of Craniofacial Surgery*. 2006 Mar 1;17(2):246-54.
16. Kim SY, Chung WS. Analysis of the Causes of Ptosis. *Journal of the Korean Ophthalmological Society*. 1995 Oct 1;36(10):1649-54.
17. Frueh BR. The mechanistic classification of ptosis. *Ophthalmology*. 1980 Oct 1;87(10):1019-21.
18. van den Bosch WA, Lemij HG. Blepharoptosis induced by prolonged hard contact lens wear. *Ophthalmology*. 1992 Dec 1;99(12):1759-65.

19. Smith B, McCord CD, Baylis H. Surgical treatment of blepharoptosis. *American journal of ophthalmology*. 1969 Jul 1;68(1):92-9.
20. Anderson RL, Dixon RS. Aponeurotic ptosis surgery. *Archives of Ophthalmology*. 1979 Jun 1;97(6):1123-8.
21. BERKE RN. Congenital ptosis: A classification of two hundred cases. *Archives of ophthalmology*. 1949 Feb 1;41(2):188-97.
22. Berke RN, WADSWORTH JA. Histology of levator muscle in congenital and acquired ptosis. *AMA archives of ophthalmology*. 1955 Mar 1;53(3):413-28.
23. Fox SA. Surgery in ptosis. *Archives of Ophthalmology*. 1980 Jan 1;98(1):186-.
24. Hussain I. Cosmetic outcome of three sutures levator aponeurosis tuck procedure in congenital ptosis. *Journal of the College of Physicians and Surgeons--Pakistan: JCPSP*. 2006 Oct;16(10):652-4.
25. Simon GJ, Lee S, Schwarcz RM, McCann JD, Goldberg RA. External levator advancement vs Müller's muscle-conjunctival resection for correction of upper eyelid involutional ptosis. *American journal of ophthalmology*. 2005 Sep 1;140(3):426-32.
26. Beard C. A new classification of blepharoptosis. *International ophthalmology clinics*. 1989 Dec 1;29(4):214-6.
27. Iliff JW, Pacheco EM. Ptosis surgery. *Duane's Clinical Ophthalmology*. Philadelphia: Lippincott Williams and Wilkins. 2001:1-8.
28. Collin JR. *A manual of systematic eyelid surgery*. Elsevier Health Sciences; 2006 Jan 11.
29. Downes RN, Collin JR. The Mersilene mesh sling--a new concept in ptosis surgery. *British journal of ophthalmology*. 1989 Jul 1;73(7):498-501.

30. Anderson RL, Baumgartner SA. Amblyopia in ptosis. Archives of Ophthalmology. 1980 Jun 1;98(6):1068-9.
31. Hossain MA, Ahmed MS, Uddin MS. Frontalis Sling Procedure Using Prolene Material in Severe Ptosis. Faridpur Medical College Journal. 2017 Aug 10;12(1):31-3.

## PROFORMA

**Name** :

**Age** :

**Sex** :

**OP/IP Number** :

**Complaints** :

**History of present illness** :

Age of onset

Duration

One /both eye

Variability

Alleviating or aggravating factors

Visual acuity

**Associated history** :

H/o diplopia

H/o odynophagia

H/o muscle weakness

Cardiac problems

Night blindness

**Past history** :

H/o trauma or surgery

H/o contact lens use

H/o lid edema

H/o allergy

H/o previous ptosis surgery

**Family history** :

**Treatment history** :

**Previous photographs** :

**General examination** :

Built- Well/Moderate/ill

Nourishment-Well/Moderate/ill

Consciousness/Orientation

Anemia/Jaundice/Cyanosis/Clubbing/Lymphadenopathy

**Vitals** : PR/BP/RR/TEMP

**OCULAR EXAMINATION:**

HEAD POSTURE :

EYEBROW POSITION :

FACIAL ASYMMETRY :

**ANTERIOR SEGMENT EVALUATION:**

| <b>RIGHT EYE</b> | <b>EXAMINATION</b>          | <b>LEFT EYE</b> |
|------------------|-----------------------------|-----------------|
|                  | <b>VISUAL ACUITY</b>        |                 |
|                  | <b>EOM</b>                  |                 |
|                  | <b>EYELIDS</b>              |                 |
|                  | <b>EYELASHES</b>            |                 |
|                  | <b>CONJUNCTIVA</b>          |                 |
|                  | <b>CORNEA</b>               |                 |
|                  | <b>ANTERIOR<br/>CHAMBER</b> |                 |
|                  | <b>IRIS</b>                 |                 |
|                  | <b>PUPIL</b>                |                 |
|                  | <b>LENS</b>                 |                 |

**FUNDUS EXAMINATION:**

**PTOSIS EVALUATION:**

| <b>RIGHT EYE</b> | <b>EXAMINATION</b>                                | <b>LEFT EYE</b> |
|------------------|---|-----------------|
|                  | <b>VERTICAL<br/>PALPEBRAL<br/>HEIGHT</b>          |                 |
|                  | <b>MARGIN REFLEX<br/>DISTANCE</b>                 |                 |
|                  | <b>LPS ACTION</b>                                 |                 |
|                  | <b>LID CREASE<br/>LEVEL</b>                       |                 |
|                  | <b>BELL'S<br/>PHENOMENON</b>                      |                 |
|                  | <b>MARCUS GUNN<br/>JAW WINKING<br/>PHENOMENON</b> |                 |
|                  | <b>ICE PACK TEST</b>                              |                 |
|                  | <b>FATIGUABILITY<br/>TEST</b>                     |                 |
|                  | <b>STRABISMUS<br/>EVALUATION</b>                  |                 |

**OTHER SYSTEM EXAMINATIONS:**

CVS/RS/ABDOMEN/CNS

OTHER CONSULTATIONS:

**PROVISIONAL DIAGNOSIS:**

**INVESTIGATIONS:**

TC/DC/ESR/HB:

URINE ALBUMIN /SUGAR/DEPOSITS:

TENSILON TEST:

EMG:

ECG:

ERG:

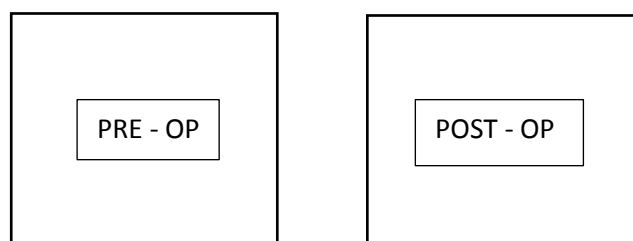
OTHERS:

**FINAL DIAGNOSIS:**

**TREATMENT:**

**PHOTOGRAPHS**

**FOLLOWUP:**





| S NO | NAME          | AGE | SEX | EYE | PTOSIS (MM) | LPS (MM) | EOM          | BP | CS | S T | ICEPACK | PUPIL | CVA (RE) | CVA (LE) | DIAGNOSIS          | SURGERY      | COMPLICATION |
|------|---------------|-----|-----|-----|-------------|----------|--------------|----|----|-----|---------|-------|----------|----------|--------------------|--------------|--------------|
| 1    | Narasimman    | 45  | M   | BE  | SEV         | 11,12    | FULL         | +  | N  | -   | NEG     | RTL   | 6/9      | 6/12     | BE APO             | BE APO AD    |              |
| 2    | Shanmugam     | 40  | M   | RE  | MOD         | 12,14    | FULL         | +  | N  | -   | POS     | RTL   | 6/6      | 6/6      | RE MG              | MED MG       |              |
| 3    | Nithish kumar | 23  | M   | LE  | SEV         | 12,4     | FULL         | +  | N  | -   | NEG     | RTL   | 6/6      | 6/6      | LE CP              | LE FSS       | UC           |
| 4    | Kannan        | 30  | M   | RE  | SEV         | 8,10     | FULL         | +  | N  | -   | NEG     | RTL   | 6/9      | 6/9      | RE APO             | RE APO AD    |              |
| 5    | Velu          | 26  | M   | BE  | MOD         | 5,5      | ALL RES      | -  | N  | -   | NEG     | RTL   | 6/18     | 6/18     | BE CPEO            | CRUTCH GLASS |              |
| 6    | Jaya          | 35  | F   | LE  | SEV         | 12,6     | ABD+ ALL RES | -  | N  | -   | NEG     | RTL   | 6/9      | 6/12     | LE III NP D/T METS | MED MG       |              |
| 7    | Raguram       | 24  | M   | BE  | SEV         | 6,4      | FULL         | +  | N  | -   | NEG     | RTL   | 6/6      | 6/6      | BE CP              | BE FSS       |              |
| 8    | Babu          | 25  | M   | LE  | SEV         | 4,12     | FULL         | +  | N  | -   | NEG     | RTL   | 6/6      | 6/6      | LE CP              | LE FSS       |              |
| 9    | Jayamma       | 48  | F   | LE  | MOD         | 11,9     | FULL         | +  | N  | -   | NEG     | RTL   | 6/9      | 6/12     | LE APO             | LE APO AD    |              |
| 10   | Ansari        | 27  | M   | LE  | SEV         | 11,3     | FULL         | +  | N  | -   | NEG     | RTL   | 6/6      | 6/9      | LE CP              | LE FSS       | UC           |

# MASTER CHART

- 20.MG - MYASTHENIA GRAVIS
- 21.MED MG - MEDICAL MANAGEMENT
- 22.CPEO - CHRONIC PROGRESSIVE EXTERNAL  
OPHTHALMOPLEGIA
- 23.MECH - MECHANICAL PTOSIS
- 24.TP - TRAUMATIC PTOSIS
- 25.TON - TRAUMATIC OPTIC NEUROPATHY
- 26.NP - NERVE PALSY
- 27.I&C - INCISION AND CURETTAGE
- 28.UC - UNDERCORRECTION
- 29.ABD - ABDUCTION

## KEY TO MASTER CHART

1. LPS - LEVATOR PALPEBRAE SUPERIORIS
2. RE - RIGHT EYE
3. LE - LEFT EYE
4. EOM - EXTRAOCULAR MOVEMENTS
5. BP - BELL'S PHENOMENON
6. CS - CORNEAL SENSATION
7. ST - SCHIRMER'S TEST
8. CVA - CORRECTED VISUAL ACUITY
9. MIL - MILD PTOSIS
- 10.MOD - MODERATE PTOSIS
- 11.SEV - SEVERE PTOSIS
- 12.N - NORMAL
- 13.POS - POSITIVE
- 14.NEG - NEGATIVE
- 15.RTL - REACTING TO LIGHT
- 16.APO - APONEUROTIC PTOSIS
- 17.APO AD - APONEUROTIC ADVANCEMENT
- 18.CP - CONGENITAL PTOSIS
- 19.FSS - FRONTALIS SLING SURGERY

| S NO | NAME        | AGE | SEX | EYE | PTOSIS (MM) | LPS (MM) | EOM          | BP | CS | S T | ICEPACK | PUPIL | CVA (RE) | CVA (LE) | DIAGNOSIS                | SURGERY            | COMPLICATION      |
|------|-------------|-----|-----|-----|-------------|----------|--------------|----|----|-----|---------|-------|----------|----------|--------------------------|--------------------|-------------------|
| 11.  | Prabu       | 36  | M   | RE  | MOD         | 13,14    | FULL         | +  | N  | -   | NEG     | RTL   | 6/6      | 6/6      | RE MECH                  | RE EXCISION BIOPSY |                   |
| 12   | Janani      | 24  | F   | RE  | MOD         | 6,12     | FULL         | +  | N  | -   | NEG     | RTL   | 6/6      | 6/6      | RE CP                    | RE FSS             |                   |
| 13   | Sekar       | 35  | M   | BE  | SEV         | 10,10    | FULL         | +  | N  | -   | NEG     | RTL   | 6/9      | 6/6      | BE APO                   | BE APO AD          | LID PEAKING       |
| 14   | Manikandan  | 27  | M   | RE  | MOD         | 4,12     | FULL         | +  | N  | -   | NEG     | RTL   | 6/6      | 6/6      | RE CP                    | RE FSS             | MILD EXP KERTITIS |
| 15   | Janaki      | 42  | F   | BE  | MIL         | 13,13    | FULL         | +  | N  | -   | POS     | RTL   | 6/12     | 6/12     | BE MG                    | MED MG             |                   |
| 16   | Prushotaman | 26  | M   | LE  | MIL         | 12,9     | ABD+ ALL RES | -  | N  | -   | NEG     | RAPD  | 6/6      | 2/60     | LE TP (III NP)<br>LE TON | MED MG             |                   |
| 17   | Mohan       | 32  | M   | BE  | MOD         | 10,11    | FULL         | +  | N  | -   | NEG     | RTL   | 6/6      | 6/9      | BE APO                   | BE APO AD          |                   |
| 18   | Dhinakar    | 30  | M   | RE  | SEV         | 3,13     | FULL         | +  | N  | -   | NEG     | RTL   | 6/6      | 6/6      | RE CP                    | RE FSS             |                   |
| 19   | Saradha     | 40  | F   | RE  | MOD         | 12,12    | FULL         | +  | N  | -   | NEG     | RTL   | 6/9      | 6/9      | RE APO                   | RE APO AD          |                   |
| 20   | Suresh      | 22  | M   | LE  | MOD         | 13,5     | FULL         | +  | N  | -   | NEG     | RTL   | 6/6      | 6/6      | LE CP                    | LE FSS             |                   |

| S NO | NAME      | AGE | SEX | EYE | PTOSIS (MM) | LPS (MM) | EOM          | BP | CS | S T | ICEPACK | PUPIL | CVA (RE) | CVA (LE) | DIAGNOSIS | SURGERY           | COMPLICATION |
|------|-----------|-----|-----|-----|-------------|----------|--------------|----|----|-----|---------|-------|----------|----------|-----------|-------------------|--------------|
| 21   | Senthil   | 32  | M   | RE  | MOD         | 11,12    | FULL         | +  | N  | -   | NEG     | RTL   | 6/9      | 6/6      | RE APO    | RE APO AD         |              |
| 22   | Palani    | 33  | M   | RE  | MOD         | 12,12    | FULL         | +  | N  | -   | NEG     | RTL   | 6/6      | 6/6      | RE MECH   | RE CHALAZI ON I&C |              |
| 23   | Malarkodi | 38  | F   | RE  | MIL         | 8,11     | FULL         | +  | N  | -   | NEG     | SRTL  | 6/18     | 6/6      | RE TP     | MED MG            |              |
| 24   | Rahul     | 21  | M   | RE  | SEV         | 10,12    | FULL         | +  | N  | -   | POS     | RTL   | 6/6      | 6/6      | RE MG     | MED MG            |              |
| 25   | Krishna   | 22  | M   | LE  | MOD         | 12,3     | FULL         | +  | N  | -   | NEG     | RTL   | 6/6      | 6/6      | LE CP     | LE FSS            | UC           |
| 26   | Lakshmi   | 43  | F   | RE  | SEV         | 6,13     | ABD+ ALL RES | -  | N  | -   | NEG     | RTL   | 6/12     | 6/12     | RE III NP | MED MG            |              |
| 27   | Aditya    | 25  | M   | RE  | SEV         | 4,10     | FULL         | +  | N  | -   | NEG     | RTL   | 6/6      | 6/6      | RE CP     | RE FSS            |              |
| 28   | Ruku      | 45  | F   | LE  | SEV         | 11,7     | ABD+ ALL RES | -  | N  | -   | NEG     | NRTL  | 6/12     | 6/36     | LE III NP | NS INT            |              |
| 29   | Kala      | 39  | F   | BE  | MOD         | 11,10    | FULL         | +  | N  | -   | NEG     | RTL   | 6/6      | 6/6      | BE APO    | BE APO AD         |              |
| 30   | Chandru   | 26  | M   | LE  | MOD         | 13,4     | FULL         | +  | N  | -   | NEG     | RTL   | 6/6      | 6/6      | LE CP     | LE FSS            |              |