

A Dissertation On  
**“A STUDY ON ROLE OF FLAP TACKING IN POST-MASTECTOMY  
SEROMA REDUCTION IN CARCINOMA BREAST”**

A DISSERTATION SUBMITTED TO  
**THE TAMILNADU DR.M.G.R MEDICAL UNIVERSITY**

*In partial fulfillment of the regulations for the award of the*

**M.S.DEGREE EXAMINATION**

**BRANCH I**

**GENERAL SURGERY**



**DEPARTMENT OF GENERAL SURGERY  
STANLEY MEDICAL COLLEGE AND HOSPITAL TAMILNADU  
DR.MGR MEDICAL UNIVERSITY, CHENNAI**

**MAY 2020**

## **CERTIFICATE BY THE INSTITUTION**

This is to certify that the dissertation titled “*A STUDY ON ROLE OF FLAP TACKING IN POST-MASTECTOMY SEROMA REDUCTION IN CARCINOMA BREAST*” is the bonafide work done by *Dr. VASANTH KUMAR.K* Post Graduate Student (2017– 2020) in the Department of General Surgery, Government Stanley Medical College and Hospital, Chennai under my direct guidance and supervision, in partial fulfillment of the regulations of The Tamil Nadu Dr. M.G.R Medical University, Chennai for the award of M.S., Degree (General Surgery) Branch - I, Examination to be held in May 2020.

**Prof. Dr. R. Rosy Adhaline Selvi, M.S.,**  
Professor of Surgery,  
Dept. of General Surgery,  
Stanley Medical College,  
Chennai-600001.

**Prof. Dr. T. Sivakumar, M.S., D.ortho**  
Professor and Head of the Department,  
Dept. of General Surgery,  
Stanley Medical College,  
Chennai-600001.

**PROF. Dr.R. SHANTHI MALAR,M .D.,D.A.,,**  
The Dean,  
Stanley Medical College,  
Chennai-600001.

## DECLARATION

I, **Dr.VASANTH KUMAR.K** solemnly declare that this dissertation titled “*A STUDY ON ROLE OF FLAP TACKING IN POST-MASTECTOMY SEROMA REDUCTION IN CARCINOMA BREAST*” is a bonafide work done by me in the Department of General Surgery, Government Stanley Medical College and Hospital, Chennai under the guidance and supervision of my beloved professor and head of the department **prof Dr. SIVAKUMAR M.S Dortho** Who Has Been A Source Of Constant Inspiration And Encouragement To Accomplish this Work.

I am sincerely thankful to my guide and unit chief. **Prof. DR.R.ROSY ADHALINE SELVI, M.S., Professor of Surgery** for her immense support and completing my work

This dissertation is submitted to The Tamilnadu Dr. M.G.R. Medical University, Chennai in partial fulfilment of the university regulations for the award of M.S., Degree (General Surgery) Branch - I, Examination to be held in May 2020.

Place:

Date:

**Dr.VASANTH KUMAR.K**

## **ACKNOWLEDGEMENT**

My sincere thanks to **Prof. Dr. SHANTHI MALAR MD., D.A.**, The Dean, Govt. Stanley Medical College for permitting me to conduct the study and use the resources of the College. I consider it a privilege to have done this study under the supervision of my beloved Professor and Head of the Department **Prof. Dr. T. Sivakumar, M.S, D.ortho** who has been a source of constant inspiration and encouragement to accomplish this work.

I am highly indebted to my guide and Mentor **Prof. Dr. R. ROSY ADHALINE SELVI, M.S.**, Professor of Surgery for her constant help, inspiration and valuable advice in preparing this dissertation. I express my deepest sense of thankfulness to my Assistant Professors **Dr. C. MALARVIZHI, M.S., Dr. PONMUTHU, M.S., Dr. RANI SUGANYA, M.S.**, for their valuable inputs and constant encouragement without which this dissertation could not have been completed. I express my sincere gratitude to my Mentor and former Professor **Prof. Dr. D. NAGARAJAN, M.S.**, former Head of Department of General Surgery. I thank them for the constant support, able guidance, inspiring words and valuable help they rendered to me during my course.

I would like to thank my former Assistant Professors **Dr. A. RAJESWARAN, M.S., and Dr. P. MATHUSOOTHANAN, M.S.,** **Dr. PALANIMAHADDEVAN, M.S.,** for their valuable suggestions and help in completing this dissertation.

I am particularly thankful to my friends Dr.Prasanth, Dr.Ajay Kumar, Dr.Amrish, Dr.Manimegala, Dr surendar without whom accomplishing this task would have been impossible. I thank my Seniors Dr.Mathews, Dr.Sreekanth , Dr.Ben Abraham , Dr.T.Mohanraj, Dr.R.Sukumar, Dr.praveen for their valuable support in this study.I am extremely thankful to my patients who consented and participated to make this study possible.

## **CERTIFICATE BY GUIDE**

This is to certify that this dissertation work titled “**A STUDY ON ROLE OF FLAP TACKING IN POST-MASTECTOMY SEROMA REDUCTION IN CARCINOMA BREAST**” of the candidate **Dr.VASANTH KUMAR.K** with **Registration Number 221711071** for the award of M.S General surgery degree. I personally verified the urkund.com website for the purpose of plagiarism check. I found that the uploaded thesis file contains from introduction to conclusion pages and result shows of plagiarism in the dissertation.

**Prof. Dr .ROSY ADHALINE SELVI M.S.,**  
Guide and Supervisor,  
Professor of Surgery,  
Department of General Surgery,  
Stanley Medical College,  
Chennai 600001.

## **PLAGIARISM CERTIFICATE**

This is to certify that this dissertation work titled “**A STUDY ON ROLE OF FLAP TACKING IN POST-MASTECTOMY SEROMA REDUCTION IN CARCINOMA BREAST**” of the candidate **Dr.VASANTH KUMAR.K** with **Registration Number 221711071** for the award **M.S. Degree in the BRANCH-1 GENERAL SURGERY.I** personally verified the urkund.com website for the purpose of Plagiarism check.

I found that the uploaded thesis file contains from introduction To conclusion pages and results shows **8%** of Plagiarism in the Dissertation.

**GUIDE AND SUPERVISOR**

**SIGN WITH SEAL**

## Urkund Analysis Result

**Analysed Document:** vasanth new NIHA.docx (D57456241)  
**Submitted:** 10/22/2019 2:17:00 PM  
**Submitted By:** vasanth308@gmail.com  
**Significance:** 8 %

### Sources included in the report:

<https://wjso.biomedcentral.com/articles/10.1186/1477-7819-2-44>  
<https://www.ncbi.nlm.nih.gov/pmc/articles/PMC3542843/>  
<https://www.slideshare.net/Lucidante1/the-axilla>  
<https://www.hindawi.com/journals/ijbc/2015/287398/>  
<https://clinicaltrials.gov/ct2/show/NCT03902977>  
<https://breast-cancer.ca/7a-staging/>  
<https://www.sciencedirect.com/topics/medicine-and-dentistry/extended-radical-mastectomy>  
[https://en.wikipedia.org/wiki/Axillary\\_lymph\\_nodes](https://en.wikipedia.org/wiki/Axillary_lymph_nodes)  
<https://www.hindawi.com/journals/ijbc/2012/643132/>  
[https://www.ncbi.nlm.nih.gov/books/NBK65744.5/table/CDR0000062787\\_\\_679/](https://www.ncbi.nlm.nih.gov/books/NBK65744.5/table/CDR0000062787__679/)  
 report=objectonly  
<https://bmccancer.biomedcentral.com/articles/10.1186/s12885-018-4740-8>  
<https://www.ncbi.nlm.nih.gov/pmc/articles/PMC3244263/>  
<https://www.ncbi.nlm.nih.gov/pubmed/16684859>  
<https://www.loffysiotherapie.nl/assets/files/1010-bosman-lymptaping-seroma-jol.pdf>  
[https://www.researchgate.net/publication/258445349\\_Quilting\\_Prevents\\_Seroma\\_Formation\\_Following\\_Breast\\_Cancer\\_Surgery\\_Closing\\_the\\_Dead\\_Space\\_by\\_Quilting\\_Prevents\\_Seroma\\_Following\\_Axillary\\_Lymph\\_Node\\_Diss](https://www.researchgate.net/publication/258445349_Quilting_Prevents_Seroma_Formation_Following_Breast_Cancer_Surgery_Closing_the_Dead_Space_by_Quilting_Prevents_Seroma_Following_Axillary_Lymph_Node_Diss)  
 ection\_and\_Mastectomy  
<https://quizlet.com/ca/390707717/anatomy-y2m3-prep-flash-cards/>  
[https://www.researchgate.net/publication/269463043\\_Factors\\_Predicting\\_Seroma\\_Formation\\_Following\\_Breast\\_Cancer\\_Surgery\\_A\\_Concise\\_Review](https://www.researchgate.net/publication/269463043_Factors_Predicting_Seroma_Formation_Following_Breast_Cancer_Surgery_A_Concise_Review)  
<https://www.ncbi.nlm.nih.gov/pmc/articles/PMC1420833/>  
 e719c5b6-4763-442d-b4e2-8059cc633b58  
<https://oncohemakey.com/anatomy-of-the-breast-axilla-and-chest-wall/>

### Instances where selected sources appear:





**GOVERNMENT STANLEY MEDICAL COLLEGE & HOSPITAL, CHENNAI -01**  
**INSTITUTIONAL ETHICS COMMITTEE**

TITLE OF THE WORK : A STUDY ON ROLE OF FLAP TACKING IN POST MASTECTOMY  
SEROMA REDUCTION IN CARCINOMA BREAST.


PRINCIPAL INVESTIGATOR : DR. VASANTH KUMAR K,  
DESIGNATION : PG IN MS GENERAL SURGERY,  
DEPARTMENT : DEPARTMENT OF GENERAL SURGERY,  
GOVT. STANLEY MEDICAL COLLEGE.

The request for an approval from the Institutional Ethical Committee (IEC) was considered on the IEC meeting held on 03.04.2019 at the Council Hall, Stanley Medical College, Chennai-1 at 10am.

The members of the Committee, the secretary and the Chairman are pleased to approve the proposed work mentioned above, submitted by the principal investigator.

The Principal investigator and their team are directed to adhere to the guidelines given below:

1. You should inform the IEC in case of changes in study procedure, site investigator investigation or guide or any other changes.
2. You should not deviate from the area of the work for which you applied for ethical clearance.
3. You should inform the IEC immediately, in case of any adverse events or serious adverse reaction.
4. You should abide to the rules and regulation of the institution(s).
5. You should complete the work within the specified period and if any extension of time is required, you should apply for permission again and do the work.
6. You should submit the summary of the work to the ethical committee on completion of the work.

  
MEMBER SECRETARY,  
IEC, SMC, CHENNAI

## TABLE OF CONTENTS

| <b>S. No</b> | <b>TOPIC</b>              | <b>Page No</b> |
|--------------|---------------------------|----------------|
| 1            | INTRODUCTION              | 1              |
| 2            | AIMS & OBJECTIVES         | 3              |
| 3            | METHODOLOGY               | 4              |
| 4            | REVIEW OF LITERATURE      | 6              |
| 5            | EPIDEMIOLOGY              | 31             |
| 6            | STAGING                   | 35             |
| 7            | SURGICAL TECHNIQUE OF MRM | 43             |
| 8            | SEROMA                    | 60             |
| 9            | OBSERVATIONS AND RESULTS  | 70             |
| 10           | SUMMARY                   | 77             |
| 11           | CONCLUSION                | 78             |
| 12           | BIBLIOGRAPHY              | 79             |
| 13           | MASTER CHART              |                |

## INTRODUCTION

As far back as the time of Egyptian civilization, female Breast Carcinoma was the first tumour to be reported and is the treatable cancer in this century. Hippocrates, the father of modern medicine, advocated surgery as the only option to treat these patients. A prototype of radical mastectomy was performed during the time of Celsus. LeDran(1685-1790) recognised the metastatic nature of the disease and suggested to remove them lymph nodes of primary and axillary groups in continuity. The main modality of treatment over the past 80 years has been Surgical and almost all patients are subjected to surgery unless fit due to other reasons. Halstead of Baltimore made a detailed description of Radical Mastectomy in 1894. Due to recent advances in the field of medicine, various improvisations and modifications have been made. Breast Conservation Surgery and Auchincloss's Modified Radical Mastectomy have been integral part of the surgical management.

The most common complication after breast surgery is serous fluid collection which is called Seroma,. The aim of this study is to analyse the outcome of reducing dead space mechanically by flap tacking in order to reduce seroma formation . Literature shows that flap tacking reduces seroma formation, simplify postoperative care and dressing,remove drains earlier.

## **AIMS & OBJECTIVES**

**1.** To know and assess the effect of flap tacking

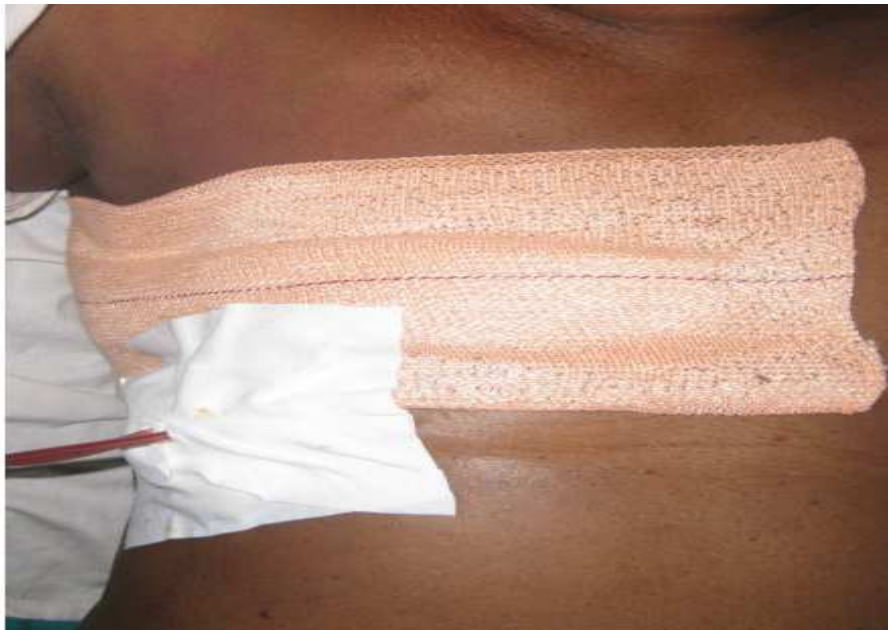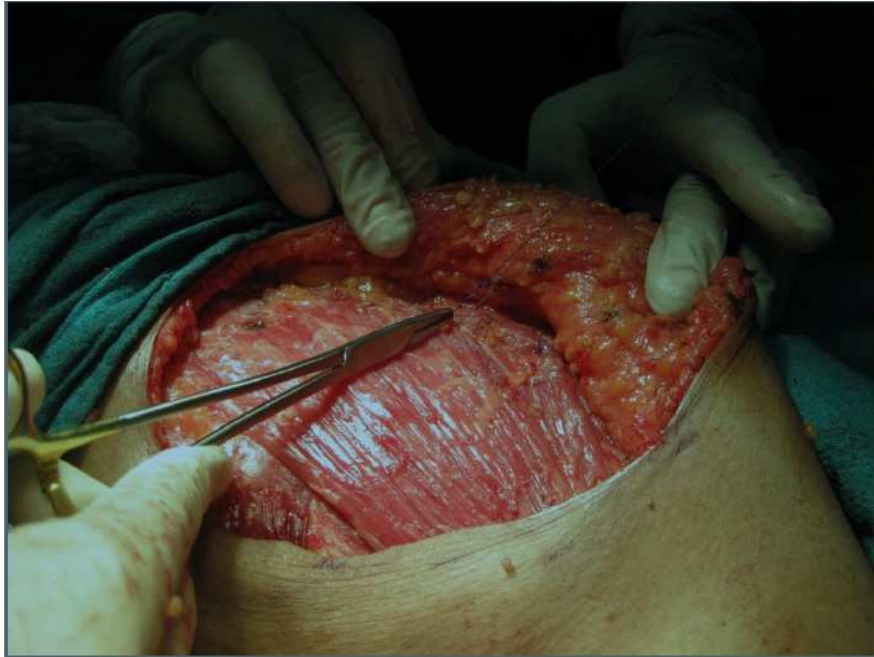in modified radical mastectomy patients of carcinoma breast

**2.** To compare the role of flap tacking and with that of standard wound

closure in reducing postmastectomy seroma

## METHODOLOGY

- Patients undergoing Modified Radical Mastectomy for Carcinoma Breast in our Department from April 2019 to November 2019 are included in this study.
- During closure, the skin flaps are tacked to the underlying pectoralis major with uniformly spaced 2-0 Vicryl sutures and wound is closed with a suction drain.
- The amount of seroma is calculated in a standard measuring jar everyday. The volume of seroma are compared to those patients undergoing conventional closure of wound and conventional wound dressings.
- Drains were removed when the daily total quantity was less than 30 ml.



Postoperative seroma drainage volume, total days with DT , was recorded for each patient.

Observations are tabulated according to the predesigned proforma.

## **REVIEW OF LITERATURE**

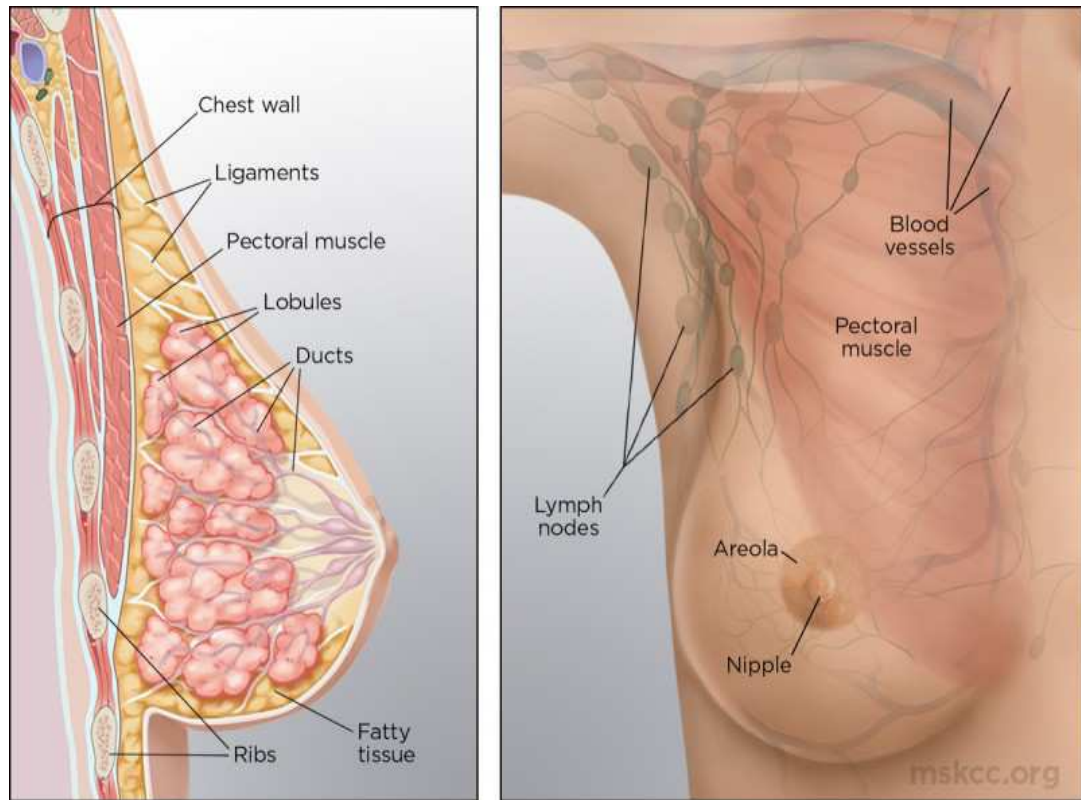
Mammary tissues correspond to anatomically mature modified sweat glands. These tissues contain a distinctive feature of mammals. Embryologically the paired mammary gland develops along the milk line that extend between the limb buds from the primordial axilla distally to the inguinal region. In humans and most primates, only one pair of glands normally develops in the pectoral region, one gland on each side.

This postnatal growth of the female mammary gland is related to age and is primarily regulated by hormones (estrogens) that influence reproductive function. The greatest development of the breast is attained by the age of 20 years, and atrophy begins premenopausally at approximately the age of 40 years. During pregnancy and lactation, striking variants occur in both the amount (volume) of glandular tissue and the functional activity of the breast. Structural changes are also observed during menstrual cycles that result from variations in ovarian hormone levels. During menopause, with the changes occurring in the hormonal secretory activity of ovarian function, the mammary gland undergoes involution and is replaced by fat and connective tissue, and thereafter, diminishes its structural volume, form, and contour.



## **Gross Anatomy of the Breast**

The mammary glands are located within the superficial fascia of the anterior chest wall. It consists of 15 to 20 lobes of tubuloalveolar glandular tissue, fibrous connective tissue that supports its lobes, and the adipose tissue that resides in parenchyma between the lobes. Subcutaneous connective tissue typically does not possess a distinctive capsule around breast components; rather, this tissue surrounds the gland and extends as septa between the lobes and lobules, Providing longitudinal and gravitational support to the glandular elements. The deep layers of superficial fascia that lie upon the posterior surface of the breast fuses with the deep(pectoral) fascia of the chest wall.



A distinct space, the retromammary bursa, can be identified anatomically on the posterior aspect of the breast and resides between the deep layer of the superficial fascia and the deep investing fascia the pectoralis major and the contiguous muscles of the thoracic wall. The retromammary bursa contributes to the mobility of the breast on the chest wall.

Fibrous thickenings of supportive connective tissue interdigitate between the parenchymal tissue of the breast and extend from the deep layer of the superficial fascia to attach to the dermis of the skin. These suspensory structures, known as Cooper ligaments, perpendicular to the delicate

superficial fascial layers of the dermis, permit remarkable mobility of the breast while providing structural support and breast contour. The mature female breast extends from the level of the second or third rib inferiorly to the inframammary fold that is located at the level of the sixth or seventh rib. Laterally, the breast extends from the lateral border of the sternum to the anterior or midaxillary line. Breast tissue extends commonly into the anterior axillary fold as the axillary tail of Spence. The upper half of the breast, particularly the upper outer quadrant, contains the greater volume of glandular tissue than the remainder of the breast. The posterior or deep surfaces of the breast rest upon portions of the fasciae of the pectoralis major, serratus anterior, and external oblique muscles; the gland also resides on upper portions of the anterior rectus sheath.

## **Anatomy of the Axilla**

The axilla is a pyramidal compartment located between the upper extremity and the thoracic wall; this structure has four boundaries inclusive of a base and an apex. The curved base is composed of the axillary fascia. The apex of the axilla represents an aperture that extends into the posterior triangle of the neck via the cervicoaxillary canal.

Most structures that course between the neck and the upper extremity enter this anatomic passage, which is bounded anteriorly by the clavicle, medially by the first rib, and posteriorly by the scapula. The anterior wall of the axilla is composed of the pectoralis major and minor muscles and their associated fasciae. The posterior wall is formed primarily of the subscapularis muscle, located on the anterior surface of the scapula, and to a lesser extent by the teres major and latissimus dorsi muscles. The lateral wall of the axilla is the bicipital groove, a thin strip of condensed muscular tissue between the insertion of the musculature of the anterior and posterior compartments. The medial wall is composed of the serratus anterior muscle.

The fascia of the pectoralis major and minor muscles are evident in two distinct planes: The superficial layer, called the pectoral fascia, invests the pectoralis major muscle, whereas the deep layer, called the clavipectoral or costocoracoid fascia, extends from the clavicle to the axillary fascia in the floor of the axilla and encloses the subclavius and the pectoralis minor muscle. The upper portion of the clavipectoral fascia, the costocoracoid membrane, is pierced by the cephalic vein, the lateral pectoral nerve, and branches of the thoracoacromial trunk. The medial pectoral nerve does not penetrate the costocoracoid membrane, but enters the deep surface of the pectoralis minor and passes through the anterior investing fascia of the pectoralis minor to innervate the pectoralis major muscle.

The lower portion of the clavipectoral fascia, located below the pectoralis minor, is sometimes referred to as the suspensory ligament of the axilla or the coracoaxillary fascia. Commonly referred to as an anatomic landmark, the Halsted ligament represents a dense condensation of the clavipectoral fascia that extends from the medial aspect of the clavicle, attaches to the first rib, and invests the subclavian artery and vein as each traverse the first rib.

The axilla contains the great vessels and nerves of the upper extremity, which, together with the other axillary contents, are encircled by loose connective tissue. These vessels and nerves are anatomically contiguous and are enclosed within an investing layer of fascia referred to as the axillary sheath. The axillary artery can be divided into three parts within the axilla:

- The first portion, located medial to the pectoralis minor muscle, gives rise to one branch, the supreme thoracic, that supplies the upper thoracic wall inclusive of the first and second intercostal spaces.

- The second portion of this artery, located immediately posterior to the pectoralis minor, gives rise to two branches, the thoracoacromial trunk and the lateral thoracic artery. Pectoral branches of the thoracoacromial and lateral thoracic arteries supply the pectoralis major and minor muscles. Identification of these vessels during surgical dissection of the axilla is imperative to provide safe conduct of the procedure. The lateral thoracic artery gives origin to the lateral mammary branches.

- The third portion of this vessel, located lateral to the pectoralis minor muscle, gives rise to three branches. These include the anterior and posterior humeral circumflex arteries that supply the upper arm, and the subscapular artery, which is the largest branch within the axilla. After a

short course, the subscapular artery gives origin to its terminal branches, the subscapular circumflex and the thoracodorsal arteries. The thoracodorsal artery, which courses with its corresponding nerve and vein, crosses the subscapularis muscle, providing its substantial blood supply, as well as that of the serratus anterior and latissimus dorsi muscles. Tributaries of the axillary vein follow the course of the branches of the axillary artery, usually in the form of venae comitantes, paired veins that follow the course of the artery. The cephalic vein passes in the groove between the deltoid and pectoralis major muscles, and thereafter enters the axillary vein after piercing the clavipectoral fascia.

The axillary artery is anatomically contiguous with various portions of the brachial plexus throughout its course in the axilla. The cords of the brachial plexus are named according to their structural and positional relationship with the axillary artery medial, lateral, and posterior rather than their anatomic position in the axilla or on the chest wall. Three nerves of principal interest to surgeons are located in the axilla. The long thoracic nerve, located on the medial wall of the axilla, arises in the neck from the fifth, sixth, and seventh cervical roots (C5, 6, and 7) with entry in the axilla via the cervicoaxillary canal.

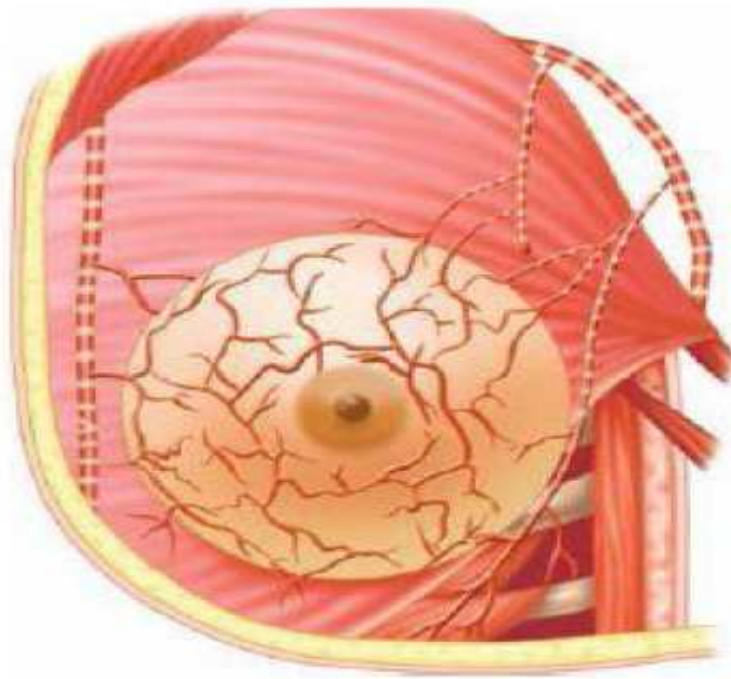
This medially placed nerve lies on the lateralmost surface of the serratus anterior muscle and is invested by the serratus fascia such that it might be accidentally divided together with resection of the fascia during surgical dissection (sampling) of lymphatics of the axilla. The long thoracic nerve, although diminutive in size, courses a considerable anatomic distance to supply the serratus anterior muscle; injury or division of this nerve results in the winged scapula deformity with denervation of the muscle group and the inability to provide shoulder fixation. The thoracodorsal nerve takes origin from the posterior cord of the brachial plexus and innervates the laterally placed latissimus dorsi muscle. Injury or division is inconsequential to primary shoulder function; however, preservation of this nerve is essential to provide transfer survival and motor function preservation for the myocutaneous flap used for the latissimus dorsi musculocutaneous reconstruction. The intercostobrachial nerve is formed by the merging of the lateral cutaneous branch of the second intercostal nerve with the medial cutaneous nerve of the arm; this nerve provides sensory innervation of the skin of the apex and lateral axilla and the upper medial and inner aspect of the arm. A second intercostobrachial nerve may sometimes form an anterior branch of the third lateral cutaneous nerve.



## **Blood Supply of the Breast**

The breast receives its blood supply from perforating branches of the internal mammary artery, lateral branches of the posterior intercostal arteries, and several branches of the axillary artery. The latter vessels include the highest thoracic, lateral thoracic, and pectoral branches of the thoracoacromial artery. Branches from the second, third, and fourth anterior perforating arteries pass to the breast as medial mammary arteries. The lateral thoracic artery gives origin to branches to the serratus anterior muscle, both pectoralis muscles, and the subscapularis muscle, and also supplies the axillary lymphatics and supporting fatty tissues.

## Arterial Supply of Breast



The posterior intercostal arteries give rise to mammary branches in the second, third, and fourth intercostal spaces.

Although the thoracodorsal branch of the subscapular artery does not contribute to the primary blood supply of the breast per se, this vessel is intimately associated with the central and scapular lymph node groups of the axilla.

This fact should be taken into consideration during axillary node dissection, as bleeding that is difficult to control can result when penetrating branches of this vessel are severed. Major venous drainage of the breast has preferential flow toward the axilla, with the veins principally paralleling the path of the arterial distribution. The superficial venous plexus of mammary parenchyma has extensive anastomoses that may be evident through the overlying skin.

Around the nipple, these superficial veins form an anastomotic circle, the *circulus venosus*. Veins from this circle and from deeper aspects of the gland converge to drain blood to the periphery of the breast, and thereafter into vessels that terminate in the internal mammary, axillary, and internal jugular veins.

The three principal groups of veins essential to provide venous drainage of the breast and the thoracic wall include

- (a) perforating branches of the internal mammary vein,
- (b) tributaries of the axillary vein, and
- (c) perforating branches of posterior intercostal veins.

The posterior intercostal veins lie in direct continuity with the vertebral plexus of veins (Batson's plexus) that surround the vertebrae and extend from the base of the skull to the sacrum. Clinically, this plexus may provide an important pathway for hematogenous dissemination of breast cancer, and physiologically accounts for metastases to the skull, vertebrae, pelvic bones, and enteral nervous system in the absence of pulmonary metastases

## **INNERVATION OF THE BREAST**

Sensory innervation of the breast is primarily supplied by the lateral and anterior cutaneous branches of the second through the sixth intercostal nerves. These sensory nerves of the breast originate principally from the fourth, fifth, and sixth intercostal nerves, although the second and third intercostals nerves may provide cutaneous branches to the superior aspect of the breast. Nerves arising from the cervical plexus, specifically the anterior or medial branches of the supraclavicular nerve, supply a limited region of the skin of the upper portion of the breast. Collectively, these nerves convey sympathetic fibers for innervation to the breast and the overlying skin.

The lateral branches of the intercostal nerves exit the intercostal space via the attachment sites of the slips of the serratus anterior muscle. These nerves divide into anterior and posterior branches as they exit the muscle. Anterior branches of the intercostal also supply the anterolateral thoracic wall. The third through the sixth branches, known as the lateral mammary branches, supply the majority of the surface of the breast. As noted above, the intercostal brachial nerve, a large and constant sensory nerve, takes origin from the lateral branch of the second intercostal nerve. The intercostal brachial nerve courses through the fascia of the floor of the axilla to commonly join the medial cutaneous nerve of the arm.

This nerve is of little functional significance; however, with injury to the intercostal brachial nerve during axillary dissection, the principal consequence for the patient is modest loss of cutaneous sensation in the upper medial aspect of the arm and axilla. No motor loss is evident after injury or division of the intercostals brachial nerve but prolonged hypoesthesia and/or paresthesia can be expected

The anterior branches of the intercostal nerves exit the intercostal space near the lateral border of the sternum to allow arborization of branches medially and laterally over the thoracic wall. The branches that course laterally innervate the medial aspect of the breast and are referred to as medial mammary branches.

### **Lymphatic Drainage of the Breast**

The main route of lymphatic drainage of the breast is via the axillary lymph node groups. There have been considerable variations in nomenclature for the lymph node groups of the axilla as the boundaries of these nodal groups are not well demarcated. These variations are particularly evident in level I nodal groups. Anatomists usually describe four groups of axillary lymph nodes, whereas surgeons typically identify six groups at three anatomic levels. The most commonly used terms to describe the axillary nodes are as follows:

□ The axillary vein group, usually identified by anatomists as the lateral group, consists of four to six lymph nodes that lie lateral and posterior to the axillary vein. This group is well identified at the anatomic confluence of the lateral vein with the latissimus dorsi. These nodes receive the majority of lymphatic contents from the upper extremity and ipsilateral back with the exception of lymph that drains into the deltopectoral lymph nodes, a group also referred to as the infraclavicular nodes.

□ The external mammary group, usually identified by anatomists as the anterior or pectoral group, consists of four or five lymph nodes positioned along the lower and lateral border of the pectoralis minor muscle contiguous in association with the lateral thoracic vessels. These nodes receive the principal volume of lymph drainage from the breast parenchyma. From these nodes, lymph drains primarily into the central lymph nodes. However, lymph may pass directly from the external mammary nodes to the subclavicular lymph nodes.

□ The scapular group, usually identified by anatomists as the posterior or subscapular group, consists of six or seven lymph nodes positioned near the posterior wall of the axilla in juxtaposition to the lateral border of the scapula and contiguous with the subscapular vessels near the axillary

floor. These nodes receive lymph primarily from the lower aspects of the neck, the posterior skin and subcutaneous tissues of the trunk (as low as the iliac crest), and posterior portions of the shoulder region. Lymph from the scapular nodes drains into the central and subclavicular nodes.

□ The central group, considered to be centrally positioned by both anatomists and surgeons, consists of three or four large lymph nodes that are embedded in the fat of the axilla, usually behind the pectoralis minor muscle. These nodes receive lymph from the preceding nodal groups (axillary, external mammary, and scapular nodal sites) and may also receive afferent lymphatic vessels directly from the breast.

Lymph from the central group, which may lie directly upon the ventral and anterior aspects of the axillary vein, drains directly to the subclavicular (apical, level III) nodes. This group is often placed superficially beneath the skin and the fascia of the midaxilla, and it is centrally located between the posterior and anterior axillary folds. This nodal group is the most palpable and numerous of axillary lymphatics, and because of its superficial position may provide accurate clinical assessment of metastatic disease.



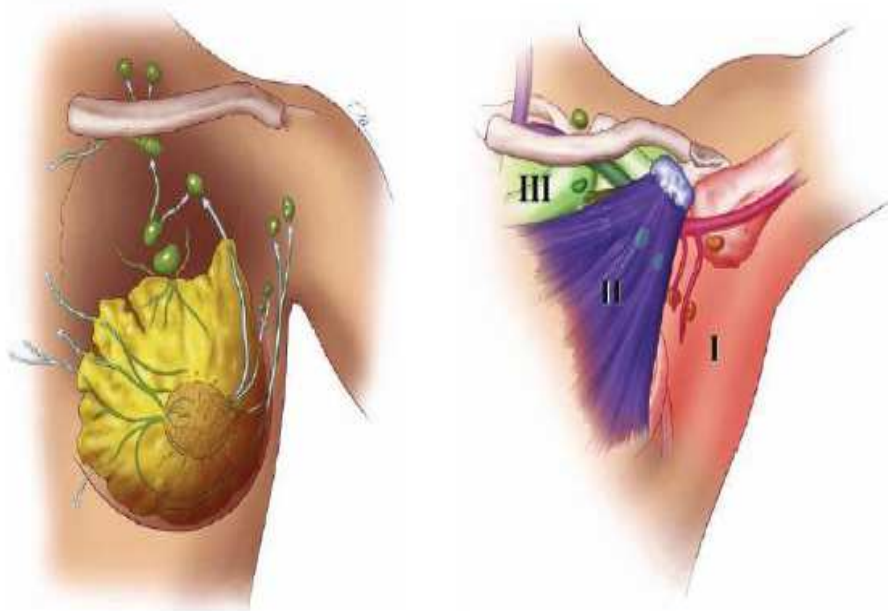
□ The subclavicular group, identified by anatomists as the apical group, consists of six to twelve lymph nodes that are located in part posterior and partially above the upper border of the pectoralis minor muscle. This nodal group extends into the apex of the axilla along the medial aspect of the axillary vein. These nodes receive lymph from all the other axillary lymph node groups.

Thereafter, these efferent lymphatic vessels from the subclavicular lymph nodes unite to form the subclavian trunk. The course of the subclavian trunk is highly variable anatomically. It may join and directly enter the internal jugular vein or the subclavian vein, or their junction. On the right side of the subclavian trunk, the right lymphatic duct may enter this structure, whereas on the left side confluence with the thoracic duct is common. Efferent vessels from the subclavicular lymph nodes may also pass to the deep cervical lymph nodes.

□ The interpectoral or Rotter group, usually identified by surgeons but not by anatomists, consists of one to four small lymph nodes located between the pectoralis major and minor muscles. This group is contiguous with pectoral branches of the thoracoacromial vessels. Lymph from these nodes enters the central and subclavicular nodes. The British surgeon W. Sampson Handley is credited with the recognition of metastatic spread of breast carcinoma to the internal mammary nodes as a

primary route of lymphatic dissemination. Extensive clinical and anatomic research confirmed that central and medial breast lymphatics pass medially, parallel the course of major blood vessels to perforate the pectoralis major muscle, and terminate in the internal mammary nodal chain.

### **Lymphatic Drainage and Lymph Node Groups**



The internal mammary nodal group is located in the retrosternal interspaces between the costal cartilages approximately 2 to 3 cm within the sternal margin . This nodal group traverses and parallels the internal mammary vasculature and is invested by endothoracic fascia. The internal mammary lymphatic trunks terminate in the subclavicular nodal groups .The right internal mammary nodal group enters the right lymphatic duct, whereas the left enters the main thoracic duct.

**Three interconnecting groups of lymphatic vessels drain the breast:**

- A primary set of vessels originate as channels within the gland in the interlobular spaces and parallel the robust accumulation of lactiferous ducts of the breast parenchyma.
  
- The vessels draining the glandular tissue and the overlying skin of the central part of the gland pass directly into the subareolar plexus, an interconnecting network of vessels located beneath the areola.
  
- A rich lymphatic plexus lies upon the deep surface of the breast to communicate with minute vessels that parallel the deep fascia underlying the breast. Along the medial border of the breast, lymphatic vessels within the substance of the gland anastomose with vessels that pass to parasternal nodes. More than 75% of the lymph from the breast flows

directly to the axillary lymph nodes, whereas the majority of residual lymph egresses to parasternal nodes. This anatomic fact provides support for the rationale of the sentinel lymph node biopsy (sampling) of the axilla to determine the (accurate) histologic status of these nodes and, hence, valid pathologic staging.

Although some authorities have suggested that the parasternal nodes receive lymph primarily from the medial part of the breast, others report that both the axillary and the parasternal lymph node groups receive lymph from all quadrants of the breast, with no definitive probability for any quadrant to drain medially or laterally. This observation allows surgeons to use sentinel nodes procured in the axilla to be the principal determinate of pathologic staging, regardless of the quadrant of anatomic presentation of the index tumor. The skin of the breast also drains via the superficial lymphatic vessels to the axillary lymph nodes. The anterolateral chest and the upper abdominal wall cephalad to the umbilicus show a striking unidirectional flow of lymph toward the axilla. Lymphatic vessels near the lateral margin of the sternum pass through intercostal spaces to the parasternal lymph nodes that course with the internal thoracic vessels. In the upper pectoral region, small numbers of lymphatic vessels pass over the clavicle to inferior deep cervical lymph nodes.

Lymphatic vessels of deeper structures of the thoracic wall drain primarily into three groups of lymph nodes:

The parasternal, intercostal, and diaphragmatic lymphatics.

The parasternal (internal thoracic) lymph nodes are a group of smaller lymphatics positioned approximately 1 cm lateral to the sternal border in the intercostal spaces along the internal mammary vessels. These nodes reside in the areolar tissue just beneath the endothoracic fascia bordering the space between the adjacent costal cartilages. The intercostal lymph nodes represent a small group located in the posterior portion of the thoracic cavity within the intercostal spaces near the origin of the ribs. One or more nodes are found in each intercostal space with contiguous relationship to the intercostal vessels. These nodes receive deep lymphatics from the posterolateral thoracic wall, including lymphatic channels from the breast. Upper efferent lymphatics from the intercostal lymph nodes on the right side terminate in the right lymphatic duct, whereas the efferent lymphatics from the corresponding nodes on the left side terminate in the thoracic duct.

The diaphragmatic lymph nodes consist of three groups of small lymph nodes located upon the thoracic surface on the diaphragm. The anterior group includes two or three small lymph nodes, also known as

prepericardial nodes, located behind the sternum at the base of the xiphoid process. The efferent lymphatics from the anterior diaphragmatic nodes pass to the parasternal nodes.

The lateral set of diaphragmatic lymph nodes is composed of two or three small nodes on each side of the diaphragm, adjacent to the pericardial sac, where the phrenic nerve innervates the diaphragm. These nodes lie near the vena cava on the right side and near the esophageal hiatus on the left. The posterior set of diaphragmatic nodes consists of a few lymph nodes located near the crura of the diaphragm. These nodes receive lymph from the posterior aspect of the diaphragm and convey the same to posterior mediastinal and lateral aortic nodes.

### **Microscopic Anatomy of the Breast**

Parenchymal structure of the adult mammary gland is composed of 15 to 20 irregular lobes of branched tubuloalveolar glands. These lobes, separated by fibrous bands of connective tissue, radiate from the mammary papilla (or nipple) and are further subdivided into multiple lobules. The fibrous bands that support the parenchyma and attach to the cutis reticularis of the dermis are termed the suspensory ligaments of Cooper. These tubuloalveolar glands lie within the subcutaneous tissues. Each lobe of the primary gland terminates in the lactiferous duct, 2 to 4

mm in diameter, and empties into the subareolar ampulla via a constricted orifice at the terminus of the nipple.

Beneath the areola at the termination of each duct is a dilated portion that is termed the lactiferous sinus. These lactiferous ducts are populated near their openings with stratified squamous epithelium. The epithelial lining of the duct has evidence of gradual transition to two layers of cuboidal cells in the lactiferous sinus, thereafter becoming a single layer of columnar or cuboidal cells distributed throughout the remainder of the ductal system. The morphology of the secretory portion of the mammary gland varies significantly with patient age and has physiologic and anatomic variance with pregnancy and lactation. The glandular component of the breast is sparse in the inactive (nonpregnant) premenopausal gland and consists predominantly of duct elements. The inactive organ undergoes slight cyclical changes throughout the menstrual cycle. During pregnancy, the mammary glands undergo dramatic proliferation via cellular hypertrophy, lactation, and development. These events are accompanied by relative diminution in the volume of connective and adipose tissue. With pregnancy, the epidermis of the nipple and areola becomes deeply pigmented and somewhat corrugated.

It is covered thereafter with keratinized, stratified squamous epithelium. The areola contains sebaceous glands, sweat glands, and accessory areolar glands of Montgomery, which are intermediate between true mammary glands and sweat glands in their structure. These accessory areolar glands present as small elevations on the surface of the areola. Sebaceous and sweat glands are distributed along the margin of the areola. The tip of the nipple contains numerous free sensory nerve endings and Meissner (tactile) corpuscles in the dermal papillae, whereas the areola contains few of these terminal sensory structures. Neuronal plexuses are also present around hair follicles in the skin peripheral to the areola; Pacinian (pressure) corpuscles are present in the dermis and in the glandular tissue. The rich sensory innervation of the breast is of great functional significance in lactation.



## EPIDEMIOLOGY

Presently, India already has one of the worst survivals from breast cancer, in the world. India has the highest number of women dying from breast cancer in the world; and India ranks number one in the numbers of healthy life years lost (DALY - Disability Adjusted Life Years) due to breast cancer. Since more patients (in India) turn up in later stages, they do not survive long irrespective of the best treatment they may get, and hence the mortality is fairly high.

There are lots of reasons for late presentations including lack of awareness, shyness on part of patients, social stigma, ignorance of doctors (patients present on time, but doctors are not aware and they delay treatment), and many other causes.

### **Breast Cancer Risk Factors(Non-Modifiable)**

- Increasing age*
- Female gender*
- Early age at menarche, late menopause*
- Nulliparity*

- Family history*
- Genetic predisposition*
- History of radiation exposure*

## **Incidence of Sporadic, Familial, and Hereditary Breast**

### **Cancer**

- Sporadic breast cancer 65–75%
- Familial breast cancer 20–30%
- Hereditary breast cancer 5–10%
- BRCA1* 45%
- BRCA2* 35%
- p53a* (*Li-Fraumeni syndrome*) 1%
- STK11/LKB1a* (*Peutz-Jeghers syndrome*) <1%

## **Histological Classification of Breast Cancer**

### **Non Invasive Epithelial Cancers**

- LCIS
- DCIS
- Mixed connective and epithelial tumors
- phyllodes tumor
- carcinosarcoma
- angiosarcoma
- adenocarcinoma

### **Invasive Epithelial Cancers**

Invasive lobular carcinoma 10%

invasive ductal carcinoma

- Not Otherwise Specified(NOS) 50-70%
- tubular ca 2- 3 %

mucinous or colloid ca 2-3 %

medullary ca 5%

cribriform ca 1-3 %

papillary 1-2%

adenoid cystic ca 1%

metaplastic ca 1%

## BREAST CANCER STAGING

The American Joint Committee on Cancer (AJCC)

staging system groups patients into 4 stages according

to the TNM system, which is based on tumor size (T),

lymph node status (N), and distant metastasis (M).

Primary Tumour(T)

Tumor size definitions are as follows:

- o Tx – cannot be assessed
- o T0 – No tumor
- o Tis – DCIS
- o Tis – LCIS
- o Tis – Paget disease , no tumor
- o T1 – Tumor  $\leq 2$  cm
- o T2 – 2-5cm

- o T3 – >5 cm
- o T4 – Tumor any size + extention
- o T4a- Chest wall (not pectoralis)
- o T4b- Skin
- o T4c – Both T4a and T4b
- o T4d – Inflammatory disease

Clinical regional lymph node definitions are as

follows:

- o Nx –cannot be assessed
- o N0 – No node
- o N1 – **Mobile** ipsilateral **axillary** lymph node(s)
- o N2 –
  - N2a – Ipsilateral **fixed** or matted **axillary**

node(s)

□ N2b – Ipsilateral **internal mammary** nodes

ONLY

o N3 –

□ N3a – Ipsilateral **infraclavicular** lymph

node(s)

□ N3b – Ipsilateral **internal mammary** lymph

node(s) AND **axillary** lymph node(s)

□ N3c – Ipsilateral **supraclavicular** lymph

node(s)

Metastases are defined as follows:

- Mx – cannot be assessed
- M0 – None
- M1 – Distant metastases

## STAGING

- Stage I – T1N0M0

- Stage IIa- T0N1M0

- T1N1M0

- T2N0M0

- IIb- T2N1M0

- T3N0M0

- Stage IIIa-T3N1M0

- T0N2M0

- T1N2M0

- T2N2M0

- T3N2M0

- IIIb-**T4**N0M0

- T4**N1M0



-**T4N2M0**

IIIc-anyT, **N3M0**

- Stage IV -anyT, anyN, **MI**

### **GRADING**

| <b>DESCRIPTION</b>                             | <b>STAGE</b>                  |
|--|-------------------------------|
| <b>In Situ Breast Cancer</b>                   | <b>Stage 0</b>                |
| <b>Early Invasive Breast Cancer</b>            | <b>Stage I,IIA,IIB</b>        |
| <b>Advanced LocoRegional Breast<br/>Cancer</b> | <b>Stage IIIA<br/>or IIIB</b> |
| <b>Metastatic Breast Cancer</b>                | <b>Stage IV</b>               |

The 5-year survival rates are highly correlated with tumor

stage, as follows:

- Stage 0, 99-100%
- Stage I, 95-100%

Stage II, 86%

Stage III, 57%

Stage IV, 20%

**STAGE 0-**

**BCS WITHOUT RT**

**• STAGE IT1N0-**

**BCS WITH SLNB WITH RT**

**• STAGE IIT2NO-**

**BCS WITH SLNB WITH RT/**

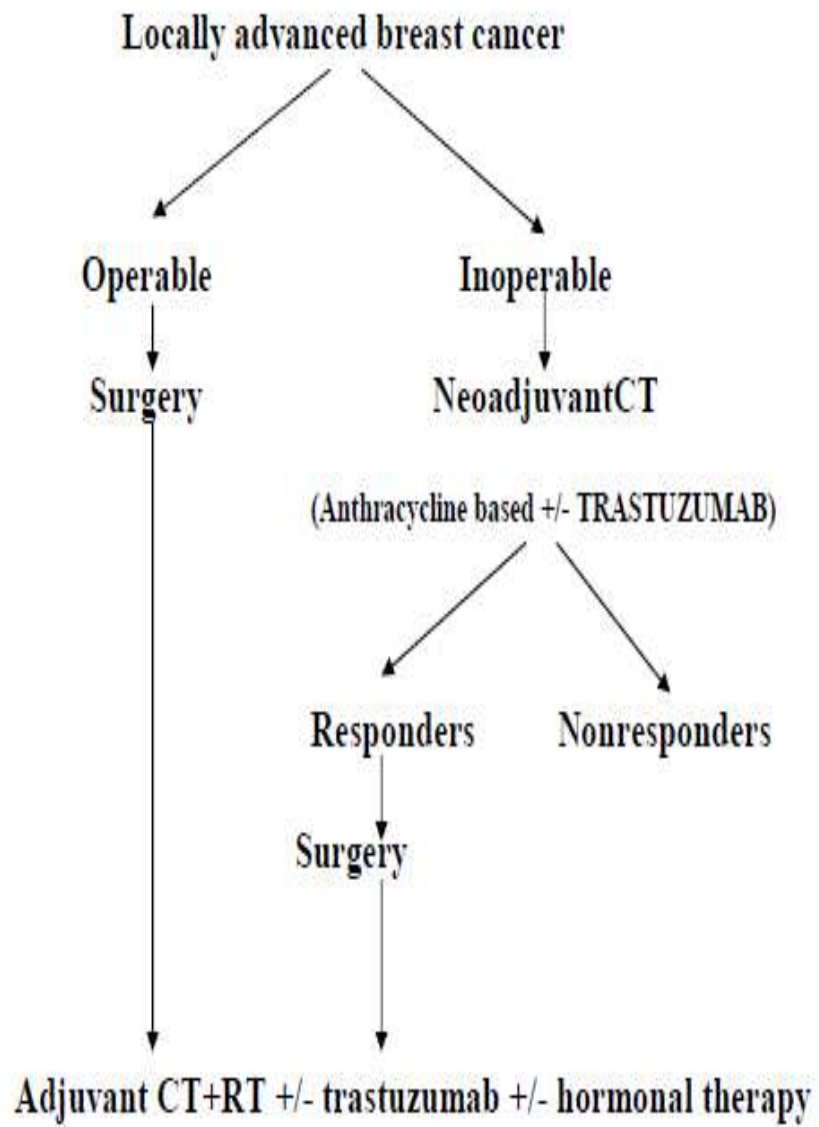
**MASTECTOMY WITH SLNB.**

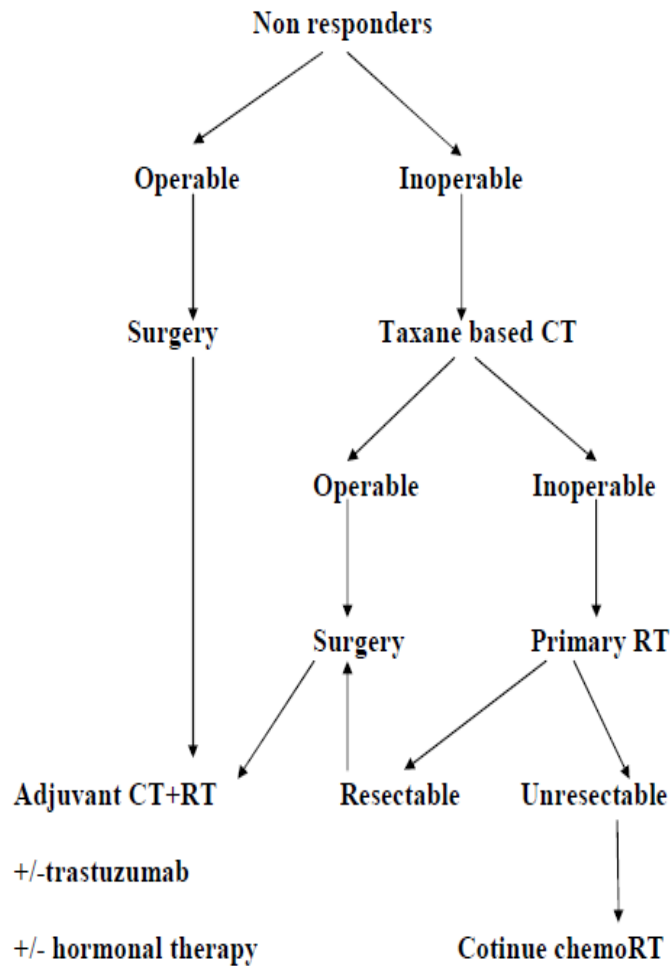
**T1N1,T2N1- BCS WITH ALND WITH RT/**

**MRM.**

**T3N0- MASTECTOMY WITH SLNB/**

**MRM.**





Mostly for inoperable tumours aggressive multimodality treatment is required. Chemoradiation is the initial treatment of choice. Anthracycline- and taxane-based chemotherapy regimens are appropriate as induction chemotherapy. If tumor reduces in size total mastectomy and axillary clearance can be done. Tamoxifen and Trastuzumab are added according to receptor status. In spite of modern multimodality therapy, 5 yr survival rate is only 25-30%

## **SURGICAL TECHNIQUE OF MODIFIED RADICAL MASTECTOMY**

A skin-sparing mastectomy removes all breast tissue, the nipple-areola complex, and only 1 cm of skin around excised scars. There is a recurrence rate of less than 2% when skin-sparing mastectomy is used for T1 to T3 cancers. A total (simple) mastectomy removes all breast tissue, the nipple-areola complex, and necessary skin. An extended simple mastectomy removes all breast tissue, the nipple-areola complex, necessary skin, and the level I axillary lymph nodes. A modified radical mastectomy removes all breast tissue, the nipple-areola complex, necessary skin, and the level I and II axillary lymph nodes. The Patey modification of the modified radical mastectomy also removes the pectoralis minor muscle, which permits complete dissection of the apical (level III) axillary lymph nodes.

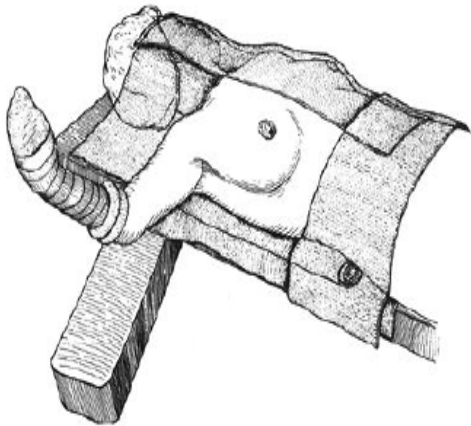
The Halstead radical mastectomy removes all breast tissue, the nipple areola complex, necessary skin, the pectoralis major and pectoralis minor muscles, and the level I, II, and III axillary lymph nodes. Currently, chemotherapy, hormone therapy, and radiation therapy for breast cancer have nearly eliminated the need for a Halstead radical mastectomy.

The patient is positioned on the operating table in the supine position for induction of general endotracheal anesthesia. A rolled sheet provides modest elevation of the ipsilateral, hemithorax and shoulder so that shoulder movement is not limited. Positioning the patient at the edge of the operating table affords the surgeon and the surgical assistant ample access to the breast and axilla and avoids undue retraction on the pectoralis muscle groups or the brachial plexus.

The ipsilateral breast, neck, shoulder, and hemithorax are prepped down to the operating table and across the midline of the chest. Folded towels are used to expose the prepped operative field, which includes the shoulder, lower neck, sternum, and upper abdominal musculature. The towels are secured in place with towel clips or surgical staples. In addition, the ipsilateral axilla, arm, and hand are fully prepared within the operative field and the arm is positioned on an arm board that is placed perpendicular to the operating field.

While alternative methods exist for including the arm and hand in the operative field, isolation of the hand and forearm with an occlusive cotton dressing (stockinette) is preferred. The stockinette is secured in place by applying an elastic or cotton bandage distal to the ipsilateral elbow, thereby ensuring free mobility of the ipsilateral elbow, arm, and shoulder.

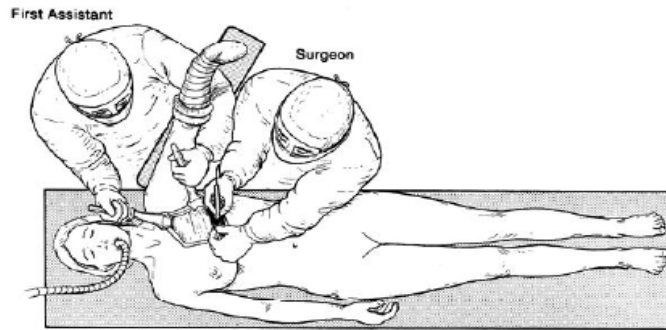
### **Preparation the patient for MRM**



At the commencement of a modified radical mastectomy, the first surgical assistant is positioned over the shoulder of the ipsilateral breast, cephalad to the arm board. This position permits the assistant to position the arm and shoulder and retract the pectoral muscles appropriately at the time of the axillary dissection.

In an obese patient with large breasts, a second surgical assistant can be positioned on the contralateral side of the operating table to assist with exposure of the axilla during axillary dissection.

### **Positioning of the surgical team**

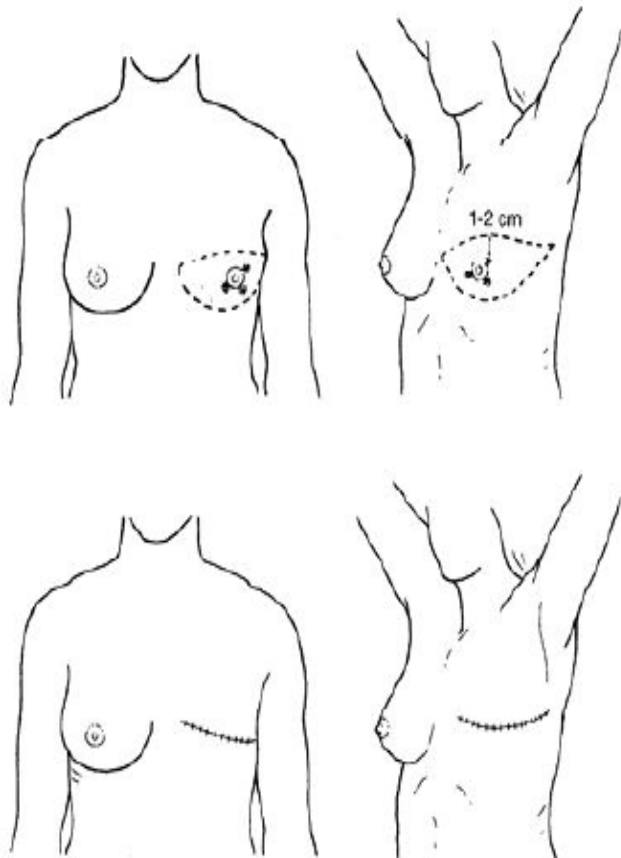


The elliptical incision of the breast skin incorporates the nipple-areola complex and skin overlying the breast cancer en bloc with skin margins that lie 1 to 2 cm from the cephalad and caudad extents of the cancer. Skin flaps are developed using cautery or scalpel and extend to the boundaries of dissection for the modified radical mastectomy, which are (a) the anterior margin of the latissimus dorsi muscle laterally, (b) the midline of the sternum medially, (c) the subclavius muscle superiorly, and (d) the caudal extension of the breast, which is 3 to 4 cm inferior to the inframammary fold, inferiorly.



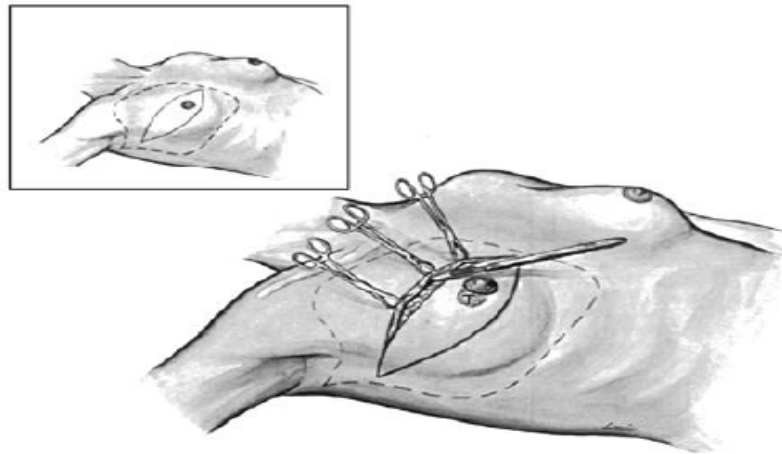
The skin edges are elevated at a right angle to the chest wall to adequately expose the superficial fascia. Skin flaps include the skin and tela subcutanea and vary in thickness depending on body habitus. The appropriate dissection plane for skin flap elevation is deep to the subcutaneous vasculature and superficial to the vessels of the breast parenchyma

### **The classic Stewart Elliptical Incision**



The surgeon elevates the skin flap with consistent thickness to avoid creation of devascularized subcutaneous tissues, which can contribute to wound seroma, skin necrosis, and flap retraction. Once the skin flaps are developed, the breast parenchyma and pectoralis major fascia are elevated from the underlying pectoralis major muscle in a plane parallel with the muscle bundles as they course from their medial origin (ribs 2 to 6) to their lateral insertion on the humerus .

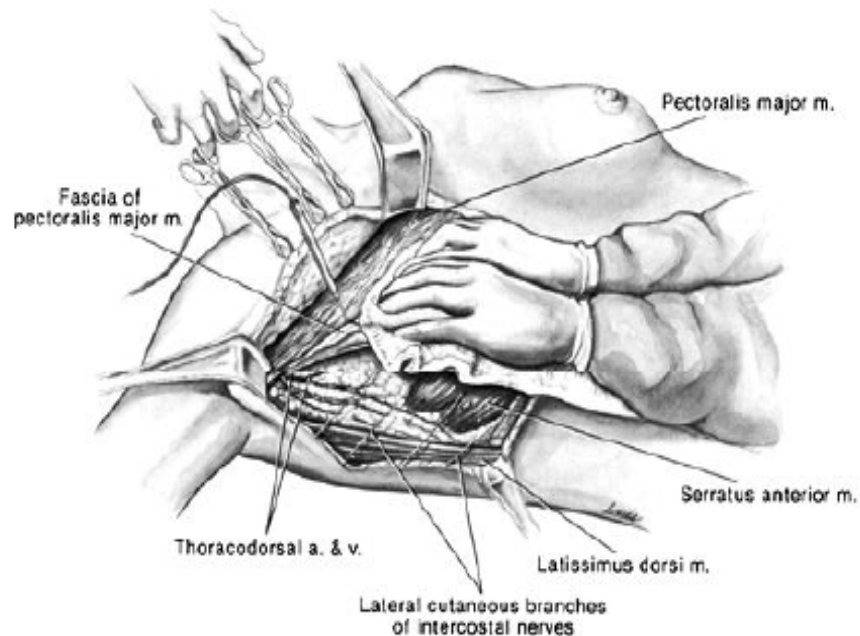
### **Initiation of the Modified Radical Mastectomy**



Perforating vessels from the lateral thoracic or anterior intercostal arteries, which are end arteries that supply the pectoralis major and minor muscles and breast parenchyma, are regularly encountered during elevation of the breast parenchyma and pectoralis major fascia. These vessels are individually identified and secured with 2-0 or 3-0 nonabsorbable sutures.

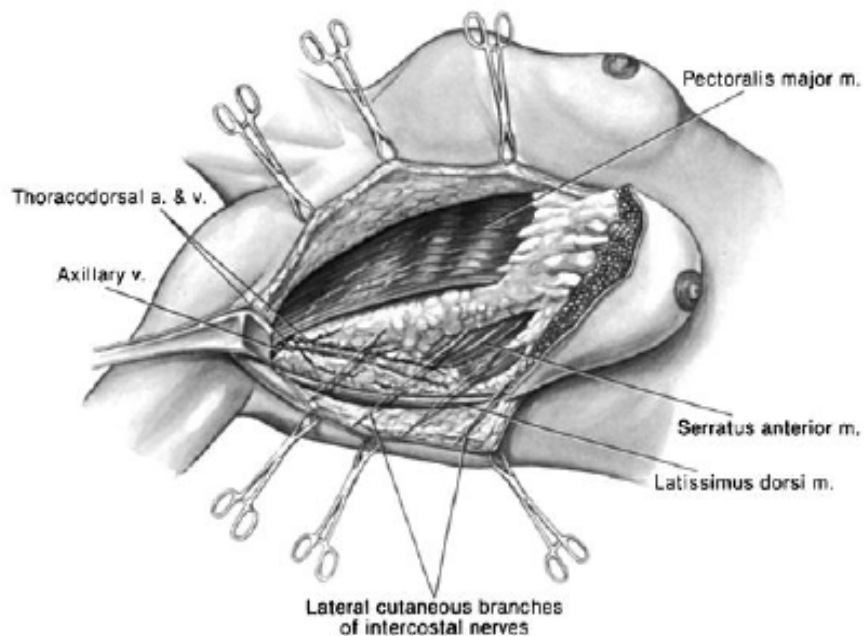
Elevation of the breast parenchyma and pectoralis major fascia is continued laterally until the lateral edge of the pectoralis major muscle and the underlying pectoralis minor muscle are exposed. The surgeon is aware of the anatomic location of the lateral neurovascular bundle in which the medial pectoral nerve (laterally placed with origin from the medial cord) courses to innervate the pectoralis major and minor muscles. If possible, this nerve is preserved to prevent atrophy of the lateral head of the pectoralis major, a significant cosmetic and functional defect.

### **Development of skin flaps**



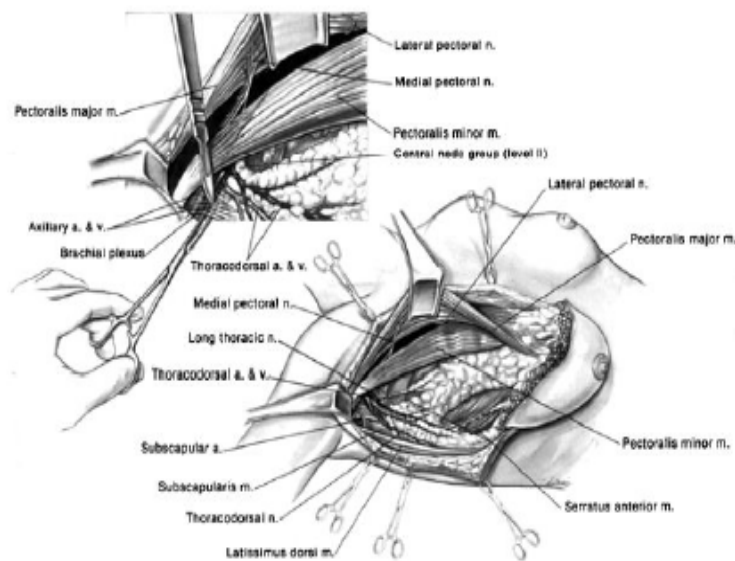
Once elevation of the breast parenchyma and pectoralis major muscle fascia from the underlying pectoralis major muscle is completed, an incision in the axillary lymph node dissection is performed. The investing fascia of the axillary space is sharply divided, the pectoralis minor muscle is defined, and lymph nodes, which may lie between the pectoralis muscles (Rotter nodes), are cleared.

### **Elevation of the breast parenchyma and pectoralis major muscle fascia**



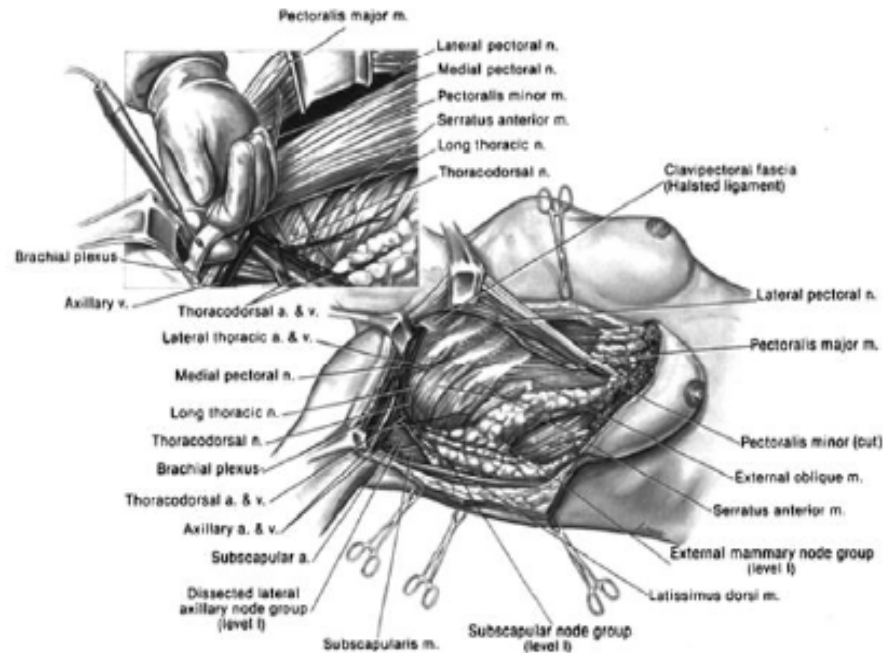
As the axillary lymph node dissection proceeds, the loose areolar tissue of the lateral axillary space is elevated with identification of the lateral extent of the axillary vein in its course anterior and caudad to the brachial plexus and axillary artery. (The axillary contents can also be removed in a medial to lateral direction.)

### **Exposure of the pectoralis minor muscle and incision of the investing fascia of the axilla**



The investing layer of the axillary vein is dissected sharply, with dissection allowing complete visualization of the anterior and ventral surfaces of the vein. Ligation and division of intervening venous tributaries is performed.

## Axillary lymph node dissection



Retraction of the superomedial aspect of the pectoralis major muscle exposes the lateral pectoral nerve, which originates from the lateral cord, and is protected to preserve innervations to the medial heads of the pectoralis major muscle. Dissection continues medially on the anteroventral surface of the axillary vein, and the loose areolar tissue at the juncture of the axillary vein with the anterior margin of the latissimus dorsi muscle is swept inferomedially to include the lateral group of axillary lymph nodes (level I).

The intercostobrachial nerves are infrequently visualized, except for the superior trunk that commonly divides close to the chest wall and courses through the level II axillary lymph nodes that lie below the axillary vein. Generally, no attempt is made to salvage the superior trunk and branches of the intercostobrachial nerve.

The surgeon preserves the thoracodorsal artery and vein, which are located deep in the axillary space and are invested with loose areolar tissue and the axillary lymph nodes of the lateral and subscapular groups. The thoracodorsal nerve originates from the posterior cord medial to the thoracodorsal artery and vein and is visualized and protected along its variable inferolateral course en route to its innervation of the latissimus dorsi muscle.

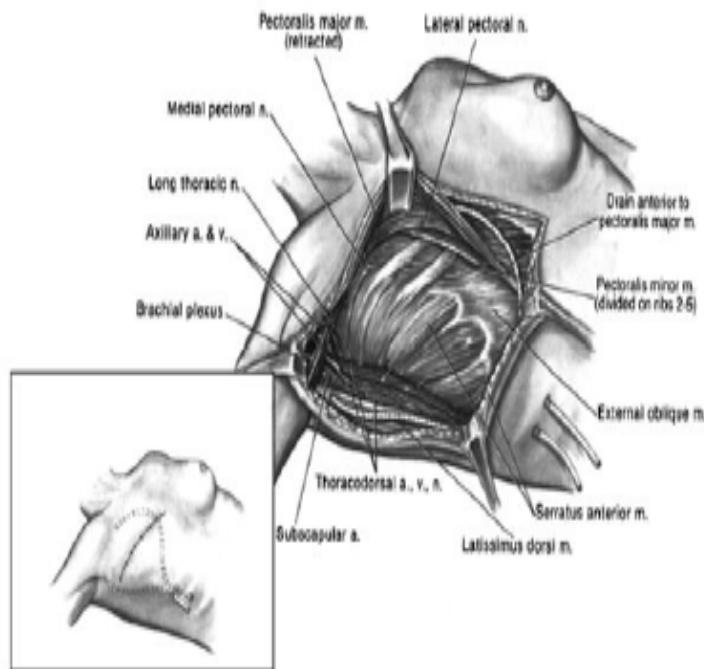
The lateral axillary lymph node group is retracted inferomedially and anterior to the thoracodorsal neurovascular bundle and dissected en bloc with the subscapular group of axillary lymph nodes (level I), which are medially located between the thoracodorsal nerve and the lateral chest wall. Dissection of the posterior contents of the axillary space exposes the posterior boundary of the axilla, allowing visualization of the heads of the teres major muscle laterally and the subscapularis muscle medially.

Dissection then proceeds medially with extirpation of the central axillary lymph node groups (level II). The superomedial aspect of the dissection specimen can be identified with a metallic marker or suture to provide anatomic orientation for the pathologist. The surgeon continues the dissection en bloc to avoid separation of nodal groups and disruption of lymphatic vessels in the axilla. With medial dissection, the surgeon encounters the chest wall deep in the medial axillary space and is able to identify and preserve the long thoracic nerve (Bell respiratory nerve), which is constant in its location, anterior to the subscapularis muscle, and is closely applied to the investing fascial compartment of the chest wall. The long thoracic nerve is dissected along its course to where it innervates the serratus anterior muscle.

Damage to the nerve causes permanent disability with a winged scapula deformity secondary to denervation of the serratus anterior muscle. The axillary contents anterior and medial to the long thoracic nerve are then swept inferomedially with the dissection specimen. The surgeon ensures that the long thoracic and thoracodorsal nerves are completely visualized before dividing the inferior extent of the axillary dissection.



## The completed axillary lymph node dissection



When level III lymphadenopathy is present, a Patey modification of the modified radical mastectomy is employed. As the surgeon proceeds medially to complete dissection along the lateral margin of the pectoralis major muscle, abduction of the shoulder and extension of the arm along with finger dissection at the lateral margin of the pectoralis major muscle allows visualization of the insertion of the pectoralis minor muscle on the coracoid process of the scapula.

The Patey modification involves division of the tendinous portion of the pectoralis minor muscle near its insertion on the coracoid process with or without removal of the muscle, which permits access to the apical axillary lymph nodes (level III) and visualization of the full extent of the axillary vein as it courses beneath the pectoralis minor muscle to its confluence with the subclavian vein beneath the costoclavicular ligament (Halsted ligament). Once the axillary lymph node dissection is complete, the resection specimen is sent for histologic examination and for immunohistochemistry (ER, PR, Ki67, Her2 neu).

The surgical bed is irrigated with sterile water or saline to evacuate residual tissue, blood clots, and serum. Bleeding points are identified and clipped, cauterized, or ligated. After this, the surgeon, surgical assistant, and scrub nurse don fresh surgical gloves and utilize clean surgical instruments to avoid implantation of exfoliated cancer cells in the surgical bed. Just prior to closure, closed suction silastic catheters are placed in the surgical bed and are brought out through separate stab wounds inferiorly. The laterally placed silastic catheter is positioned in the axillary space approximately 2cm inferior to the axillary vein on the ventral surface of the latissimus dorsi muscle to provide drainage of the axilla. The medially placed silastic catheter is positioned under the skin flaps.

Both catheters are secured to the skin with a 3-0 nylon suture and are maintained on low-pressure suction. The wound is closed in two layers with 3-0 absorbable sutures placed in the subcutaneous tissues, while the skin edges are approximated with staples or with 4-0 absorbable subcuticular sutures, in which case, short Steri-Strips are applied perpendicular to the skin to closely approximate the skin edges. Noncompressive dressings can be applied

## **Anatomic Complications of the Modified Radical Mastectomy**

### **Vascular Injury**

- The first and second perforating vessels are too large for cautery. They are ligated.
  
- The axillary vein, if torn, is repaired. Ligation may cause chronic edema.

## **Nerve Injury**

Intercostobrachial nerve  When cut, circumscribed numbness of the medial aspect of the ipsilateral upper arm results.

Long thoracic nerve  If cut, a winged scapula deformity results.

Medial and lateral  If cut, the pectoralis muscles atrophy.

thoracic nerves

Thoracodorsal nerve  If cut, internal rotation and abduction of the shoulder are weakened.

Wound dressings are removed after 24 to 48 hours.

The silastic catheters remain in place until drainage becomes serous or serosanguineous in character and decreases to less than 30 mL per 24 hours for a 48-hour period. Generally, the catheters are removed between postoperative days 5 and 7, but, when necessary for continued high-volume drainage, can remain until postoperative day 10. Range-of-motion shoulder exercises begin 24 hours after surgery but are suspended for the 24-hour period following drain removal.

Development of a seroma beneath the skin flaps or in the axilla represents the most frequent complication of mastectomy and axillary lymph node dissection, reportedly occurring in as many as 30% of cases. Wound infections occur infrequently after a mastectomy and the majority occur secondary to skin flap necrosis. Culture of the infected wound for aerobic and anaerobic organisms, debridement, and antibiotics are effective management. Moderate or severe hemorrhage in the postoperative period is rare and is best managed by return to the operating room with early wound exploration for control of hemorrhage and re-establishment of closed system suction drainage.

The incidence of functionally significant lymphedema after a modified radical mastectomy is less than or equal to 10%. Extended axillary lymph node dissection, adjuvant radiation therapy, the presence of pathologic lymph nodes, and obesity contribute to an increased incidence. When necessary, individually fitted compressive sleeves and intermittent compression devices can reduce the extent of lymphedema and palliate symptoms.

## SEROMA

With surgical ablation of the breast, the intervening lymphatics and fatty tissues are resected en bloc, thus the vasculature and lymphatics of the gland are transected. Thereafter, transudation of lymph and the accumulation of blood in the operative field are expected. The pathophysiology and mechanism of seroma formation in breast cancer surgery remains controversial and not fully understood, as little attention has been paid in the literature to etiologic factors. However, excessive accumulation will stretch the skin and cause it to sag, resulting in, significant morbidity, and delay in the initiation of adjuvant therapy, patient discomfort and prolongation of hospital stay. To prevent seroma formation, it is important to estimate individual risk of seroma formation i.e., the identification of predictive variables will be helpful in designing future trials aimed at reducing the incidence of this common complication of mastectomy.

Seroma occurs in most patients after mastectomy/MRM and is now increasingly being considered side effect of surgery rather than a complication however, all patients are not clinically symptomatic. Incidence of seroma formation after breast surgery varies between 2.5% - 51%<sup>8</sup>. Although it is not life threatening, it can lead to significant

morbidity (e.g. flap necrosis, wound dehiscence, predisposes to sepsis, prolonged recovery period, multiple physician visits) and may delay adjuvant therapy.

A retrospective cross sectional study conducted by E. Hashemi et al, on 158 patients which included patients undergoing Breast Preservation surgery and Modified Radical Mastectomy showed that, it was, only the type of surgery which was significantly associated with seroma formation and no other factor studied ( e.g. age, tumour size, nodal involvement, pre-operative chemotherapy, surgical instrument - electrocautery / scalpel, use of pressure garment, post-operative arm activity, duration of drainage ) was found to significantly effect seroma formation.

A prospectively randomized study on 92 women conducted by Lumachi F. et al, showed that size of the tumour, and total amount of drainage represent the principal factors. The study also concluded that use of ultrasound scissors for axillary dissection resulted in lower incidence of seroma formation.

According to Douay N. et al, frequency of seroma formation is independent of the axillary technique of surgery. The risk factors isolated were, high body mass index, high volume of the first 3 days drainage and arterial hypertension. Techniques like sentinel node biopsy, padding of

the axilla and the axillary drainage showed a benefit in the reduction of the seroma.

Agrawal A. et al, suggests an increase in the incidence of seroma following thermal trauma from electrocautery dissection.

Menton M. et al showed that seroma formation was associated with drainage of significantly higher amounts of fluid. It generally began on the 7th day after operation, reached a peak rate of growth on the 8th day, and subsequently slowed continuously up to the 16th day after operation. The study revealed age to be a very important etiologic factor: the frequency of formation increasing with age.

One meta-analysis, 51 randomized controlled trials, 7 prospective studies and 7 retrospective studies by Katsumasa Kuroi et al., concluded that, a number of factors though being correlated with seroma formation, lack strong evidence and sentinel lymph node biopsy was shown to reduce seroma formation.



## **PATHOPHYSIOLOGY OF SEROMA**

Seroma is defined as a serous fluid collection that develops after mastectomy and/or axillary dissection under the skin flaps or in the axillary dead space. Risk factors are age, breast size, comorbid conditions, number of malignant nodes in the axilla, previous surgical biopsy, and use of drugs. Following surgery seromas form as an exudate due to increased fibrinolytic activity in response to inflammatory reaction to increase serous fluid collection. Seroma formation can be due to surgical factors or patient factors.

## **FACTORS RELATED TO SURGERY**

### **Techniques**

Surgical treatment for breast cancer has reached its advance as to breast conservation from Halstead's radical mastectomy. Studies reveal that radical mastectomy increases seroma formation compared to simple mastectomy.

Following MRM when compared to breast conservation there is an increase in seroma formation. There is no direct evidence to show that seroma formation increases with respect to removal of increased number of lymph nodes.

Conventional axillary dissection demonstrated significantly higher seroma formation than that of sentinel lymph node biopsy.

### **Surgical devices**

To reduce blood loss and time during surgery various devices are used which include

-Electrocautery,

-Argon diathermy

-Laser scalpel

-Ultrasonic scissors

-Ultrasonic scalpel

-Vessel sealer.

Seroma formation is increased in association with use of electro-cautery for tissue dissection whereas it is inversely proportional to use of ultrasound scissors or surgical scissors with ligation.

## **PATIENT FACTORS**

Patient factors related to postoperative seroma formation are

- Body Mass Index
- Status of Hormone receptor
- Axillary nodal status and positivity
- Stage and grade of disease

Factors having influence on seroma formation but lack statistical evidence are

- Breast size
- Anemia
- Diabetes mellitus
- Smoking
- Size and location of tumour
- Type of Histology
- Disease site
- Weight of the Specimen

## **Techniques for Mechanical Closure of Dead Space**

Following Modified Radical Mastectomy ,techniques for dead space closure beneath skin flaps include

-Fixation of Flap with sutures

-External pressure Compression

Adhesion of flap to the underlying Pectoralis Major is enhanced by these techniques by obliterating the dead space between the chest wall and flaps by suturing and external compression. Plastic Surgeons emphasize the former techniques which are gaining popularity. As suggested by Halsted, in breast surgery, obliteration of dead space under the clavicle can be done by fixing the skin flaps to the underlying structures at the edge and to cover the axillary contents. The remaining defect in the wound was covered using a graft without inserting a drain. Later, studies have shown that to accelerate the flaps in position, suturing the deep structures to the skin helped. The complications associated with these methods are pain and focal pressure necrosis. Larsen et al recommended fixation of subcutaneous tissue to the underlying muscles and fascia with cotton sutures following radical mastectomy and drains were not inserted unless persistence of dead space or an unusually wet chest wall. Studies

were also conducted by Atkin and members to analyse the usefulness of absorbable material in tacking subcutaneous tissues to secure the flaps. Since then, similar techniques were investigated by number of studies. This technique includes tacking different parts of flap with multiple sutures to muscle underlying or tacking the subcutaneous tissues to the muscle underlying at the wound edge.

But axillary dead space is the potentially larger one which needs to be obliterated. Studies performing limited ALND, Functional ALND were conducted to observe the effect on axillary space reduction and its effect on seroma

formation. Use of Drains favours closure of dead space and thus decreasing seroma. In earlier years, static drains were used which are now superseded by suction drainage(closed). The advantages of closed drainages are, easy ambulation, reduced use of dressings, reduced incidence of tissue breakdown and infection and patient comfortness is improved postoperatively.

## **Mechanical**

Various methods have been adopted in obliterating the space under the axilla and flaps to reduce formation of seroma. Initially Halsted suggested to create a superior flap which is shorter and to suture it to underlying fascia using silk sutures

intermittently and to cover the remaining defect using skin graft. Use of tension sutures in flap tacking with chest wall was advocated in 1951 by Orr.

Use of continuous sutures in attaching the chest wall and skin flaps was suggested by Keyes in 1953. Apart from these, other methods which have been tried to reduce seroma include- suturing subcutaneous tissue and the flaps, non usage of drains in axilla after breast conservation surgery and approximating the muscles to obliterate the dead space in axilla. Coveney and his members studied the effects of skin flap tacking to muscle underneath against routine closure of skin which showed incidence of formation of seroma to be lower in former group, however the procedure of flap tacking added to total duration of surgery. A recent RCT analysed a combination of techniques which included lymphatics ligation, flap tacking, and dead space obliteration in axilla to routine closure of skin post mastectomy. The results showed to decrease the incidence of seroma

formation to as low as 2% with combination of methods. However it is difficult to interpret which of the components in the combination produced the effect observed. Application of mechanical pressure to obliterate dead space after surgery has also been tried but using a pressure garment has not reduced drainage postoperatively .

### **Effect of Mechanical Closure of Dead Space on Seroma Formation**

Different studies conducted globally comparing the effects of mechanical closure of dead space in reducing seroma formation have produced differing results. Certain studies showing no added benefit and certain studies showing statistically beneficial effects. However, these methods provide early smoother recovery, lower incidence of flap necrosis, preserved range of shoulder movements, reduction in prolonged serous drainage and earlier removal of drain, reduction in costs and better cosmetically. And similarly on analysis of studies showing negative findings, it was found that technical aspects have to do with the results and improved techniques have resulted in better outcome. Padding of axillary space after functional axillary dissection have led to Day Care surgery of Breast Conserving Surgery without drainage of axilla.

## **OBSERVATIONS AND RESULTS**

This study was conducted in the Department of General Surgery, Govt. Stanley Medical College & Hospital, Chennai. Patients, who fulfilled the inclusion criteria, were enrolled in this study, after obtaining an informed consent.

Total Number patients enrolled in the study – 52

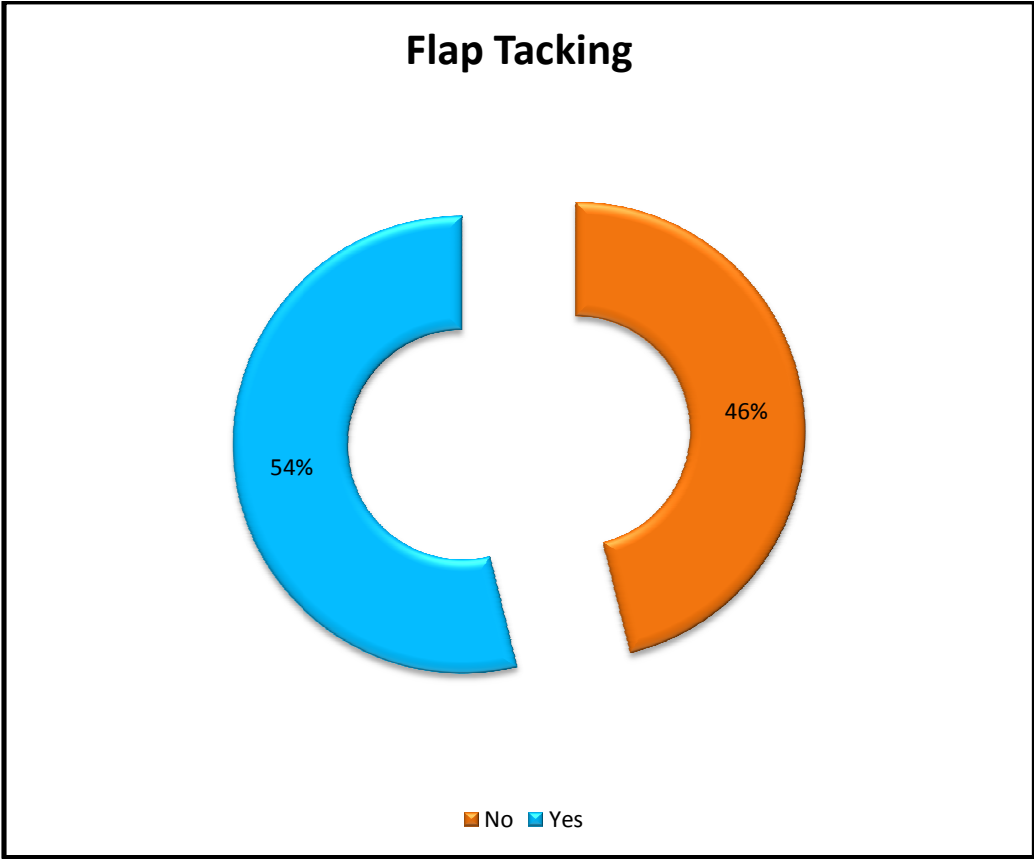
Total Number patients underwent flaptacking – 28

The quantity of seroma in the post operative period was measured on 3rd, 7th, 10th, 15th & 20th day and compared between both groups and tabulated.

Axillary vein Doppler and Culture Sensitivity of the seroma were done and vein patency confirmed and infective cause ruled out post operatively

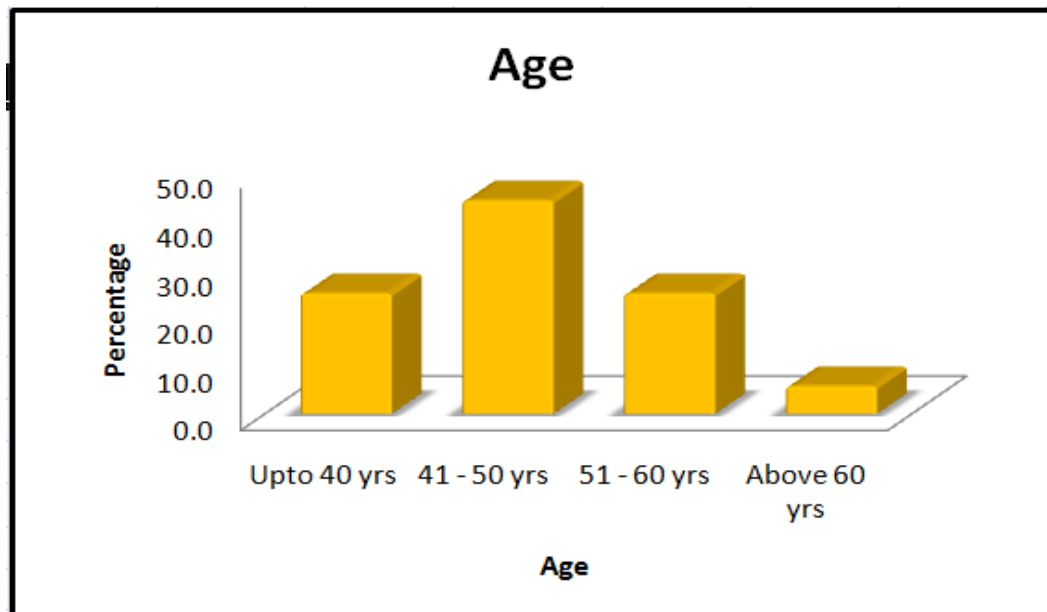


**TOTAL NUMBER OF PATIENTS INVOLVED IN THE STUDY**



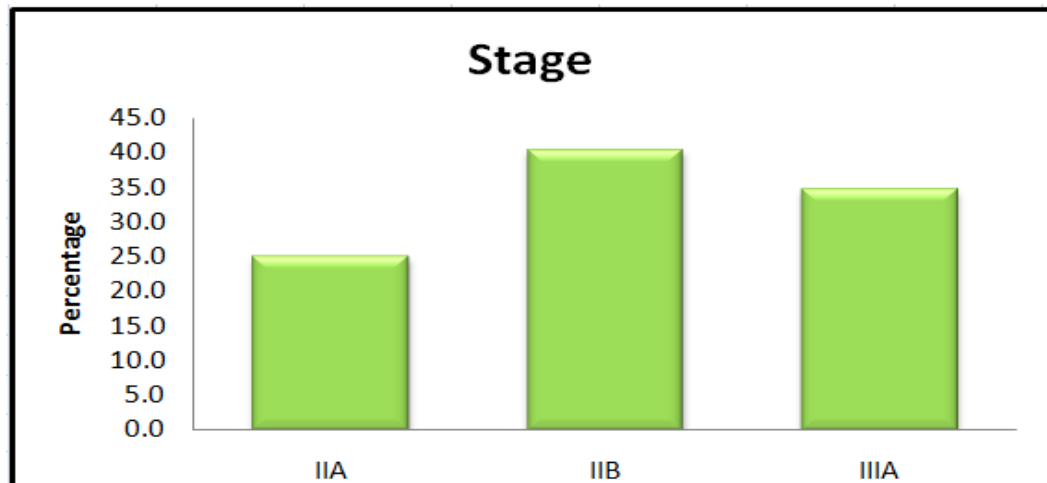
### Age wise distribution of carcinoma breast

|              | Frequency | Percent |
|--------------|-----------|---------|
| Upto 40 yrs  | 13        | 25.0    |
| 41 - 50 yrs  | 23        | 44.2    |
| 51 - 60 yrs  | 13        | 25.0    |
| Above 60 yrs | 3         | 5.8     |
| Total        | 52        | 100.0   |



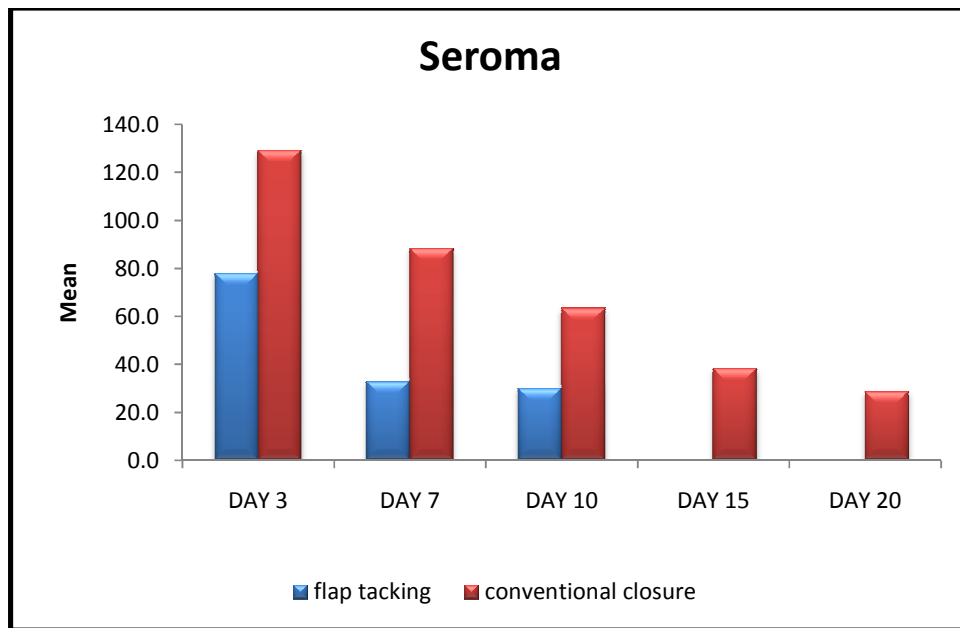
### Stage wise distribution in percentage

| <b>STAGE</b> |  | Frequency | Percent |
|--------------|--|-----------|---------|
| IIA          |  | 13        | 25.0    |
| IIB          |  | 21        | 40.4    |
| IIIA         |  | 18        | 34.6    |
| Total        |  | 52        | 100.0   |

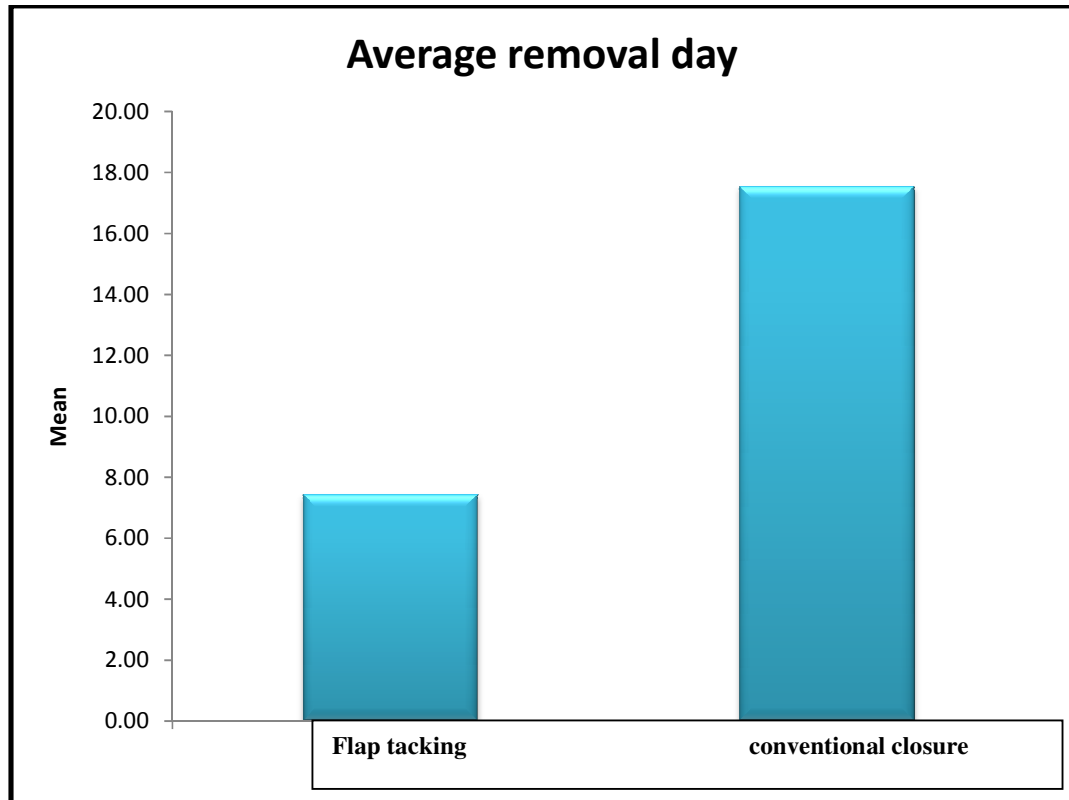


**Average quantity of seroma in ml postoperatively**

|                      | DAY 3 | DAY 7 | DAY 10 | DAY 15 | DAY 20 |
|----------------------|-------|-------|--------|--------|--------|
| flap tacking         | 77.9  | 32.9  | 30.0   |        |        |
| conventional closure | 129.2 | 88.3  | 63.3   | 38.3   | 28.8   |



## Average day of removal of drain



## Test of Stastical significance

| Comparison of day of removal by Unpaired t-test |     |    |       |       |         |           |
|---|-----|----|-------|-------|---------|-----------|
| FLAP TACKING                                    |     | N  | Mean  | S.D   | t-value | P-value   |
| Removal day                                     | Yes | 28 | 7.43  | 1.260 | 19.715  | 0.0005 ** |
|   | No  | 24 | 17.54 | 2.226 |         |           |

\*\* Highly Significant with  $P < 0.01$  level

Analyzing the above results using t-test, null hypothesis is rejected and the test is statistically significant.

## SUMMARY

- Total number of patients enrolled in the study period – **52**
- Total number of patients underwent Flap Tacking – **28**
- Total number of patients underwent conventional closure–**24**
- The quantity of seroma is less in patients of flap tacking and show DT remove early
- The average day of Drain removal was around **8** days in the patients of flap tackin whereas **17** days in patients who underwent conventional closure.
- Analyzing the above results using t-test,null hypothesis is rejected and the test is statistically significant.

## CONCLUSION

The role of flap tacking in Modified Radical Mastectomy has reduced the seroma formation significantly and has led to reduced early removal of drains, institution of 1st cycle of chemotherapy before discharge and thus reducing the stay in hospital. It has also led to reduced incidence of flap necrosis post operatively.

However, further studies are needed to stratify whether flap tacking is solely responsible for the reduction in seroma. Similarly, whether co-morbid illness like Diabetes, Hypertension and institution of Neo-Adjuvant Chemotherapy has any confounding effect on the formation of seroma needs to be studied. Several preliminary and prospective studies have shown that suturing the flaps to the chest wall thus obliterating the dead space has proved to be useful allowing smoother recovery



## BIBLIOGRAPHY

1. Romrell LJ, Bland KI. Anatomy of the breast, axilla, chest wall and related metastatic sites. In: Bland KI, Copeland EM III, eds. The breast: comprehensive management of benign and malignant diseases, 3rd ed. Philadelphia: WB Saunders, 2004.
2. Bland KI, Copeland EM III, eds. The breast: comprehensive management of benign and malignant disorders. Philadelphia: WB Saunders, 2004:759.
3. Kuroi K, Shimozuma K, Taguchi T, Imai H, Yamashiro H, Ohsumi S, Saito S: Pathophysiology of seroma in breast cancer. *Breast Cancer* 12:288-293, 2005.
- 4) Pogson CJ, Adwani A, Ebbs SR: Seroma following breast cancer surgery. *Eur J Surg Oncol* 29:711-717, 2003.
5. Katsumasa Kuroi, Kojiro Shimozuma, Tetsuya Taguchi, Hirohisa Imai, Hiroyasu Yamashiro, Shozo Ohsumi, Shinya Saito. Evidence-based risk factors for seroma formation in breast surgery. *Japanese Journal of Clinical Oncology* 2006 36(4): 197-206
6. Ferlay J, Parkin D, Stelioarova-Foucher EG. Estimated cancer Incidence, mortality and prevalence worldwide in 2012. IARC Cancer Base 2012.

7. Pogson CJ, Adwani A, Ebbs SR. Seroma following breast cancer surgery. *Eur J Surg Oncol* 2003; 29: 711-717.
8. Gong Y, Xu J, Shao J. Prevention of seroma formation after mastectomy and axillary dissection by lymph vessel ligation and dead space closure: a randomized trial. *Am J Surg* 2010; 200: 352-356.
9. Ten BW, FJH van den W. Quilting prevents seroma formation following breast cancer surgery: closing the dead space by quilting prevents seroma following axillary lymph node dissection and mastectomy. *Ann Surg Oncol* 2014; 21: 802-807.
10. Khater A, Elnahas W, Roshdy S. Evaluation of the quilting technique for reduction of postmastectomy seroma: A randomized controlled study. *Int J Breast Cancer* 2015.
11. Aitken DR, Minton JP: Complications associated with mastectomy. *Surg Clin North Am* 63:1331-1352, 1983.
12. Tadych K, Donegan WL: Postmastectomy seromas and wound drainage. *Surg Gynecol Obstet* 165:483-487, 1987.
13. Pogson CJ, Adwani A, Ebbs SR: Seroma following breast cancer surgery. *Eur J Surg Oncol* 29:711-717, 2003.
14. Larsen BB: Fixation of skin flaps by subcutaneous sutures in radical mastectomy. *J Am Med Assoc* 159:24,1955.

15. Urban JA, Baker HW: Radical mastectomy in continuity with en bloc resection of the internal mammary lymph-node chain; a new procedure for primary operable cancer of the breast. *Cancer* 5:992-1008, 1952.
16. Keyes EL, Hawk BO, Sherwin CS: Basting the axillary flap for wounds of radical mastectomy. *AMA Arch Surg* 66:446-451, 1953.
17. Larsen BB, Hagan C, Jr.: Fixation of skin flaps in radical mastectomy by subcutaneous sutures; observations *AMA Arch Surg* 71:419-423, 1955.
18. Menton M., Roemer V. M. Seroma formation and drainage technique following mastectomy. *Fortschr Med* 1990 Jun 20;108(18):350-2
19. Jain P. K., Sowdi R., Anderson A. D., MacFie J. Randomized clinical trial investigating the use of drains and fibrin sealant following surgery for breast cancer. *Br J Surg* 2004 Jan; 91(1):54-60
20. Gonzalez E. A. , Saltzstein E. C., Riedner C. S., Nelson B. K. Seroma formation following breast cancer surgery *Breast J* 2003 Sept-Oct; 9(5): 385-8



H/o major illness/ hospital admissions, if any:

H/o drug intake/contraceptive usage,if any:

**PERSONAL HISTORY:**

Age of menarche      Marital status                      Consanguinity

No.of. Children

Breast fed: Yes/No    If Yes,Duration of feed:              Age of menopause:

**FAMILY HISTORY:**

H/o similar complaints in mother,grandmother,female siblings,if any

H/o Prostatic illness in father,if any

**CLINICAL EXAMINATION:**

General examination:

Local Examination: Breast and Axilla

Arm,Chest wall,Supraclavicular fossa

Systemic examination:

CVS

RS

CNS

Abdomen

Spine and Cranium

Clinical diagnosis:

**INVESTIGATIONS:**

CBC:

RFT:

HIV:

HBsAg:

Anti-HCV:

Blood Grouping & Typing:

BT/CT:

Chest X-Ray:

ECG:

USG Breast/Mammogram:

FNAC/Trucut Biopsy:

USG ABDOMEN:

CT Thorax/Bone scan:

**FINAL DIAGNOSIS:**

**GOVT.STANLEY MEDICAL COLLEGE, CHENNAI- 600 001**

**INFORMED CONSENT**

**DISSERTATION TOPIC: ““A STUDY ON ROLE OF FLAP  
TACKING IN POST-MASTECTOMY  
SEROMA REDUCTION IN CARCINOMA BREAST”**

PLACE OF STUDY: GOVT. STANLEY MEDICAL COLLEGE, CHENNAI

**NAME AND ADDRESS OF PATIENT:**

I, \_\_\_\_\_ have been informed about the details of the study in

my own language.

I have completely understood the details of the study.

I am aware of the possible risks and benefits, while taking part in the study.

I understand that I can withdraw from the study at any point of time and even

then, I will continue to receive the medical treatment as usual.

I understand that I will not get any payment for taking part in this study.

I will not object if the results of this study are getting published in any medical

journal, provided my personal identity is not revealed.

I know what I am supposed to do by taking part in this study and I assure that I

would extend my full co-operation for this study.

Name and Address of the Volunteer:

Signature/Thumb impression of the Volunteer

Date:

Witnesses:

(Signature, Name & Address)

Name and signature of investigator

| S.NO | PATIENT NAME  | AGE | I.P.NO     | DIAGNOSIS   | STAGE | PROCEDURE | SEROMA | DAY3 | DAY7  | DAY10 | DAY15 | DAY | DT REMOVAL   | FLAP TACKING |
|------|---------------|-----|------------|-------------|-------|-----------|--------|------|-------|-------|-------|-----|--------------|--------------|
| 1    | BHUVANESHWAI  |     | 48 1933661 | CA RT BREAS | IIIA  | RT MRM    | 80 ml  |      | 30ml  |       |       |     | 7th POD      | Y            |
| 2    | JAYALAKSHMI   |     | 45 1934285 | CA LT BREAS | IIB   | LT MRM    | 120ml  |      | 60ml  | 30ml  |       |     | 11th POD     | Y            |
| 3    | BOMMI         |     | 58 1928803 | CA RT BREAS | IIIA  | RT MRM    | 130ml  |      | 100ml | 70ml  | 30ml  |     | 16th POD     | N            |
| 4    | KANAMA        |     | 50 1936299 | CA RT BREAS | IIA   | RT MRM    | 90ml   |      | 30ml  |       |       |     | 8th POD      | Y            |
| 5    | KALYANI       |     | 56 1937495 | CA LT BREAS | IIB   | LT MRM    | 60ml   |      |       |       |       |     | 6th POD      | Y            |
| 6    | MUTHUMANI     |     | 49 1944677 | CA RT BREAS | IIA   | RT MRM    | 70ml   |      | 30ml  |       |       |     | 9th POD      | Y            |
| 7    | LAKSHMI       |     | 65 1949131 | CA LT BREAS | IIB   | LT MRM    | 150ml  |      | 100ml | 70ml  | 50ml  |     | 17th POD     | N            |
| 8    | MARIAMMAL     |     | 47 1951036 | CA RT BREAS | IIIA  | RT MRM    | 70ml   |      | 30ml  |       |       |     | 8th POD      | Y            |
| 9    | AMUDHA        |     | 50 1932495 | CA LT BREAS | IIA   | LT MRM    | 130ml  |      | 100ml | 70ml  | 30ml  |     | 16th POD     | N            |
| 10   | VASANTHY      |     | 59 1963735 | CA RT BREAS | IIB   | RT MRM    | 80ml   |      | 30ml  |       |       |     | 8th POD      | Y            |
| 11   | SUMATHY       |     | 36 1919660 | CA RT BREAS | IIA   | RT MRM    | 150ml  |      | 100ml | 60ml  | 50ml  |     | 30r 22nd POD | N            |
| 12   | VASANTHA      |     | 45 1929902 | CA RT BREAS | IIIA  | RT MRM    | 150ml  |      | 90ml  | 70ml  | 50ml  |     | 30 20th POD  | N            |
| 13   | SUN DARI      |     | 41 1930145 | CA LT BREAS | IIB   | LT MRM    | 60ml   |      | 30ml  |       |       |     | 6th POD      | Y            |
| 14   | LALITHA       |     | 42 1934853 | CA RT BREAS | IIA   | RT MRM    | 150ml  |      | 100ml | 70ml  | 50ml  |     | 3( 18th POD  | N            |
| 15   | JAYANTHI      |     | 35 1936210 | CA LT BREAS | IIIA  | LT MRM    | 90ml   |      | 40ml  |       |       |     | 9th POD      | Y            |
| 16   | CHELLAMA      |     | 60 1936357 | CA RT BREAS | IIB   | RT MRM    | 80ml   |      | 30ml  |       |       |     | 7th POD      | Y            |
| 17   | RANJITHA DEVI |     | 45 1940815 | CA LT BREAS | IIIA  | LT MRM    | 90ml   |      | 30ml  |       |       |     | 8th POD      | Y            |
| 18   | GIRIJA        |     | 59 1941473 | CA RT BREAS | IIA   | RT MRM    | 100ml  |      | 60ml  | 60ml  | 30ml  |     | 18th POD     | N            |
| 19   | RENUKA        |     | 45 1938804 | CA LT BREAS | IIB   | LT MRM    | 130ml  |      | 90ml  | 50ml  | 30ml  |     | 16th POD     | N            |
| 20   | SUMATHI       |     | 55 1949732 | CA RT BREAS | IIIA  | RT MRM    | 60ml   |      |       |       |       |     | 6th POD      | Y            |
| 21   | NESAMANI      |     | 53 1948130 | CA RT BREAS | IIB   | RT MRM    | 120ml  |      | 90ml  | 70ml  | 30ml  |     | 17th POD     | N            |
| 22   | ALIMELU       |     | 57 1958376 | CA RT BREAS | IIIA  | RT MRM    | 90ml   |      | 30ml  |       |       |     | 7th POD      | Y            |
| 23   | KANIYAMAL     |     | 50 1947099 | CA LT BREAS | IIB   | LT MRM    | 80ml   |      | 30ml  |       |       |     | 8th POD      | Y            |
| 24   | MOHANA        |     | 60 1953067 | CA RT BREAS | IIIA  | RT MRM    | 110ml  |      | 60ml  | 60ml  | 30ml  |     | 16th POD     | N            |
| 25   | KANIYAMAL     |     | 62 1952877 | CA LT BREAS | IIB   | LT MRM    | 150ml  |      | 120ml | 90ml  | 60ml  |     | 30 20th POD  | N            |
| 26   | MALA          |     | 35 1949876 | CA RT BREAS | IIA   | RT MRM    | 80ml   |      | 30ml  |       |       |     | 7th POD      | Y            |
| 27   | VALLI         |     | 40 1957681 | CA LT BREAS | IIIA  | LT MRM    | 130ml  |      | 80ml  | 60ml  | 30ml  |     | 19th POD     | N            |
| 28   | GOWRI         |     | 43 1961604 | CA LT BREAS | IIB   | LT MRM    | 60ml   |      |       |       |       |     | 6th POD      | Y            |
| 29   | SUSILA        |     | 50 1962901 | CA RT BREAS | IIA   | RT MRM    | 130ml  |      | 90ml  | 60ml  | 30ml  |     | 17th POD     | N            |
| 30   | SATHYA        |     | 43 1962868 | CA LT BREAS | IIB   | LT MRM    | 120ml  |      | 100ml | 60ml  | 40ml  |     | 20n 20th POD | N            |
| 31   | HEMALATHA     |     | 35 1922429 | CA RT BREAS | IIIA  | RT MRM    | 90ml   |      | 60ml  | 30ml  |       |     | 9th POD      | Y            |
| 32   | MALLIGA       |     | 55 1925422 | CA LT BREAS | IIA   | LT MRM    | 100ml  |      | 60ml  | 40ml  | 30ml  |     | 18th POD     | N            |
| 33   | SURYA         |     | 35 1925591 | CA RT BREAS | IIB   | RT MRM    | 120ml  |      | 60ml  | 30ml  |       |     | 14th POD     | N            |
| 34   | MANJULA       |     | 50 1926239 | CA LT BREAS | IIIA  | LT MRM    | 80ml   |      | 30ml  |       |       |     | 8th POD      | Y            |
| 35   | MALATHY       |     | 55 1928488 | CA RT BREAS | IIIA  | RT MRM    | 70ml   |      |       |       |       |     | 6th POD      | Y            |
| 36   | VARALAKSHMI   |     | 43 1930298 | CA LT BREAS | IIB   | LT MRM    | 150ml  |      | 120ml | 70ml  | 50ml  |     | 3( 20th POD  | N            |



|    |              |    |         |                  |        |       |       |      |      |          |   |
|----|--------------|----|---------|------------------|--------|-------|-------|------|------|----------|---|
| 37 | PUSPHA       | 36 | 1935282 | CA RT BREAS IIA  | RT MRM | 80ml  | 20ml  |      |      | 7th POD  | Y |
| 38 | RAJESHWARI   | 39 | 1935378 | CA LT BREAS IIB  | LT MRM | 120ml | 90ml  | 60ml | 30ml | 16th POD | N |
| 39 | ANJALI       | 61 | 1949511 | CA RT BREAS IIIA | RT MRM | 100ml | 90ml  | 60ml | 30ml | 18th POD | N |
| 40 | PARVATHY     | 35 | 1964095 | CA RT BREAS IIB  | RT MRM | 90ml  | 30ml  |      |      | 9th POD  | Y |
| 41 | PARVALAKSHMI | 39 | 1935737 | CA LT BREAS IIB  | LT MRM | 60ml  |       |      |      | 6th POD  | Y |
| 42 | RANI         | 30 | 1915150 | CA RT BREAS IIIA | RT MRM | 110ml | 60ml  | 60ml | 30ml | 14th POD | N |
| 43 | RAMANI       | 50 | 1917293 | CA LT BREAS IIB  | LT MRM | 130ml | 60ml  | 60ml | 30ml | 17th POD | N |
| 44 | MUNIAMMA     | 47 | 1924043 | CA RT BREAS IIA  | RT MRM | 70ml  | 30ml  |      |      | 8th POD  | Y |
| 45 | THILAGAM     | 60 | 1929958 | CA LT BREAS IIB  | LT MRM | 150ml | 120ml | 90ml | 60ml | 19th POD | N |
| 46 | KALA         | 40 | 1937507 | CA RT BREAS IIIA | RT MRM | 60ml  |       |      |      | 6th POD  | Y |
| 47 | PARIMALA     | 45 | 1931780 | CA LT BREAS IIA  | LT MRM | 90ml  | 30ml  |      |      | 7th POD  | Y |
| 48 | DEVIKA       | 54 | 1940978 | CA RT BREAS IIB  | RT MRM | 120ml | 90ml  | 60ml | 30ml | 13th POD | N |
| 49 | NILLA        | 37 | 1943195 | CA RT BREAS IIIA | RT MRM | 70ml  |       |      |      | 6th POD  | Y |
| 50 | LATHA        | 48 | 1943123 | CA RT BREAS IIA  | RT MRM | 150ml | 90ml  | 70ml | 50ml | 20th POD | N |
| 51 | TAMIL SELVI  | 50 | 1943145 | CA LT BREAS IIB  | LT MRM | 70ml  | 30ml  |      |      | 7th POD  | Y |
| 52 | KAMALA       | 49 | 1943295 | CA LT BREAS IIIA | LT MRM | 90ml  | 30ml  |      |      | 8th POD  | Y |