

Duloxetine Poisoning: A Unique Case of Cardiotoxicity

Derek J. Fikse DO

Lehigh Valley Health Network, Derek.Fikse@lvhn.org

Alexandra Amaducci DO

Lehigh Valley Health Network, Alexandra.Amaducci@lvhn.org

Margaret A. Vido DO

Lehigh Valley Health Network, margaret.vido@lvhn.org

Robert D. Cannon DO

Lehigh Valley Health Network, Robert_D.Cannon@lvhn.org

Kenneth D. Katz MD

Lehigh Valley Health Network, Kenneth_D.Katz@lvhn.org

Follow this and additional works at: <https://scholarlyworks.lvhn.org/emergency-medicine>



Part of the [Medical Toxicology Commons](#)

Published In/Presented At

Fikse, D., Amaducci, A., Vido, M., Cannon, R., & Katz, K. (2021, April). *Duloxetine Poisoning: A Unique Case of Cardiotoxicity*. [Poster presentation]. Pennsylvania College of Emergency Physicians, PACEP SA21 Spivey and CPC Competitions, Virtual.

This Poster is brought to you for free and open access by LVHN Scholarly Works. It has been accepted for inclusion in LVHN Scholarly Works by an authorized administrator. For more information, please contact LibraryServices@lvhn.org.

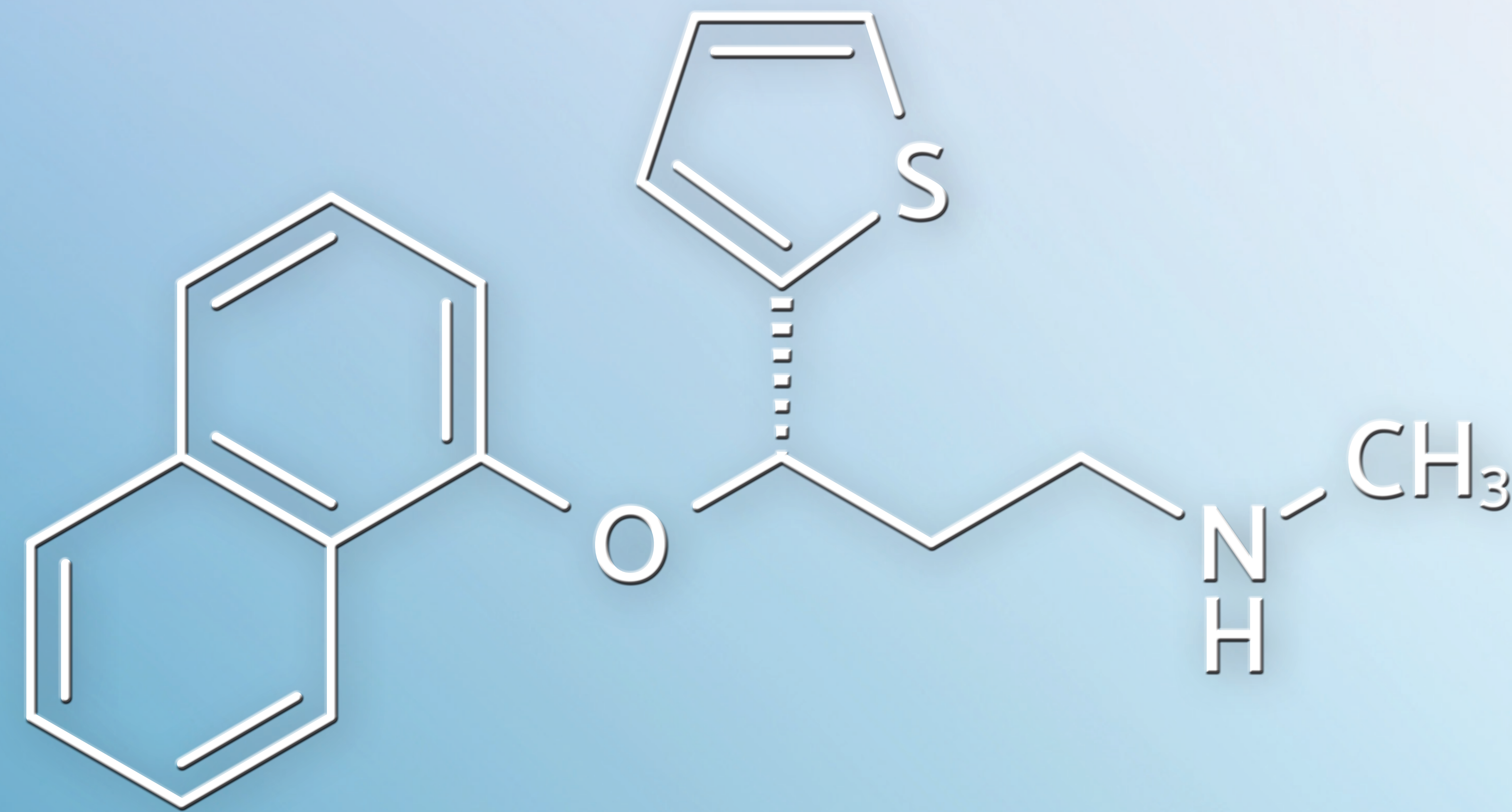
Duloxetine Poisoning: A Unique Case of Cardiotoxicity

Derek J. Fikse, DO; Alexandra M. Amaducci, DO; Margaret A. Vido, DO; Robert D. Cannon, DO; Kenneth D. Katz, MD

Lehigh Valley Health Network, Department of Emergency and Hospital Medicine/USF Morsani College of Medicine, Allentown, Pa.

Background

Duloxetine is a SNRI similar to venlafaxine. While cardiotoxicity from venlafaxine poisoning has been described, it has not previously been reported with duloxetine.



Case

A 15-year-old boy with PMH of depression and anxiety prescribed fluoxetine 20 mg and hydroxyzine 10 mg intentionally ingested 3,060 mg of his mother's duloxetine pills. Notable VS were BP 145/88 and HR 127. On exam, his mental status was normal. He was noted to have six beat ankle clonus and hyperreflexia. CBC, CMP, VBG, salicylate, acetaminophen, and ethanol were unremarkable. Initial EKG demonstrated sinus tachycardia 109 bpm, QRS 103 ms, and QTc 462 ms. One hundred ml of 8.4% sodium bicarbonate was administered intravenously without any change in the QRS duration. Serial EKGs demonstrated gradual prolongation of QRS and QTc reaching a maximum of 134 ms and 543 ms, respectively. Sodium bicarbonate IV was re-administered, again without improvement in the QRS duration. Although his tachycardia and serotonergic signs resolved within 12 hours post ingestion, the QRS widening persisted with gradual resolution over 84 hours to 100 ms. He developed neither hemodynamic instability nor dysrhythmias. Serum LC/MS detected duloxetine, fluoxetine, hydroxyzine, cannabinoids, and caffeine. The patient was admitted to inpatient psychiatry on hospital day five.

Discussion

The patient was prescribed fluoxetine, a potent CYP450 2D6 inhibitor, which may have inhibited the metabolism of duloxetine, also metabolized by CYP450 2D6. Although in vitro evidence exists demonstrating duloxetine's ability to block cardiac sodium channels, QRS widening or other clinically significant cardiotoxicity has not been described. It is also noteworthy that this patient's QRS interval did not improve after sodium bicarbonate administration. Neither fluoxetine nor hydroxyzine is expected to cause QRS widening.

Conclusion

Physicians should be aware of the potential for duloxetine-induced cardiotoxicity.