

Utility of the FloTrac(TM) Sensor for Anesthetic Management of Laparoscopic Surgery in a Patient After Pneumonectomy: A Case Report and Literature Review.

著者	AKAZAWA Mai, NAKANISHI Miho, MIYAZAKI Narumi, TAKAHASHI Kan, KITAGAWA Hirotochi
journal or publication title	The American journal of case reports
volume	21
page range	e925979
year	2020-12-04
URL	http://hdl.handle.net/10422/00012871

doi: 10.12659/AJCR.925979(<https://doi.org/10.12659/ajcr.925979>)

Received: 2020.05.14

Accepted: 2020.10.07

Available online: 2020.10.23

Published: 2020.12.04

Utility of the FloTrac™ Sensor for Anesthetic Management of Laparoscopic Surgery in a Patient After Pneumonectomy: A Case Report and Literature Review

Authors' Contribution:

Study Design A
Data Collection B
Statistical Analysis C
Data Interpretation D
Manuscript Preparation E
Literature Search F
Funds Collection G

BEF 1 **Mai Akazawa**
ADEF 1 **Miho Nakanishi**
B 1 **Narumi Miyazaki**
AB 2 **Kan Takahashi**
DF 1 **Hirotohi Kitagawa**

1 Department of Anesthesiology, Shiga University of Medical Science, Otsu, Shiga, Japan

2 Department of Anesthesiology, Kanazawa Medical University, Uchinada, Ishikawa, Japan

Corresponding Author: Miho Nakanishi, e-mail: mnakani@belle.shiga-med.ac.jp

Conflict of interest: None declared

Patient:	Female, 35-year-old
Final Diagnosis:	Left adrenal gland metastases • post right pneumonectomy for lung metastases • retroperitoneal angiosarcoma
Symptoms:	Dyspnea
Medication:	—
Clinical Procedure:	FloTrac™ sensor
Specialty:	Anesthesiology
Objective:	Unusual setting of medical care
Background:	Pneumonectomy is associated with various anatomical changes and potential complications involving the respiratory and cardiovascular systems. How laparoscopic surgery affects cardiorespiratory status in postpneumonectomy patients is yet to be ascertained. Here, we describe the use of the FloTrac™ sensor for the anesthetic management of laparoscopic adrenalectomy in a postpneumonectomy patient.
Case Report:	A 35-year-old woman underwent an extended hysterectomy and right pneumonectomy for retroperitoneal angiosarcoma and lung metastases, respectively. The metastasis was found in her left adrenal gland; therefore, laparoscopic adrenalectomy was scheduled. Spirometry demonstrated the following: forced vital capacity (FVC), 1.90 L (55.6% of predicted value); vital capacity, 53.6%; forced expiratory volume (FEV ₁), 1.38 L (47.3% of predicted value); and FEV ₁ /FVC, 72.4%. The heart and mediastinal structures had shifted into the right hemithorax. Hugh-Jones classification was grade 2. The induction of general anesthesia was planned. The patient was orotracheally intubated and managed with the pressure control ventilation-volume guaranteed mode of ventilation, targeting an expired tidal volume of 6–7 ml/kg, without using PEEP. We evaluated cardiac output (CO), cardiac index (CI), stroke volume (SV), and stroke volume variation (SVV) using a FloTrac™ sensor. After the establishment of pneumoperitoneum, SVV increased. CO and SV decreased slightly; however, the patient's hemodynamic status was stable. After surgery, we extubated the patient in the operating room; she demonstrated good progress and was discharged home on postoperative day 5.
Conclusions:	We found changes in the values of SVV after pneumoperitoneum in a postpneumonectomy patient. The FloTrac™ sensor may be a minimally invasive and promising monitor for detecting hemodynamic changes associated with laparoscopic surgery in postpneumonectomy patients.
MeSH Keywords:	Anesthetics, General • Cardiac Output • Laparoscopy • Pneumonectomy • Pneumoperitoneum • Ventilators, Mechanical
Abbreviations:	CI – cardiac index; CO – cardiac output; CT – computed tomography; FVC – forced vital capacity; HR – heart rate; PIP – peak inspiratory pressure; SV – stroke volume; SVV – stroke volume variation; TV – tidal volume

Full-text PDF: <https://www.amjcaserep.com/abstract/index/idArt/925979>



1838



2



2



33



Background

Pneumonectomy leads to a variety of anatomical changes and significant decreases in pulmonary function, which give rise to complications involving the respiratory system, cardiovascular system, and pleural space [1]. After pneumonectomy, the lung volume, forced expiratory volume in one second (FEV_1), forced vital capacity (FVC), and the diffusing capacity for carbon dioxide (DLCO) decrease [1,2]. After lung resection, the right ventricular ejection fraction decreases, whereas the right ventricular end-diastolic volume increases [3].

Reports describing the anesthetic management of postpneumonectomy patients are few; therefore, no official anesthetic guidelines have been set to establish the choice of appropriate anesthetic management, such as the method of anesthesia and its monitoring [4]. Although the use of laparoscopic surgery has increased, the effect of general anesthesia during the establishment of pneumoperitoneum and that of surgical position on the cardiorespiratory status in postpneumonectomy patients remains unclear [5].

The FloTrac™ sensor (arterial pressure-based cardiac output sensor) has been utilized as an easy and effective means of hemodynamic monitoring [6,7]. At present, no clinical report exists on the use of the FloTrac™ sensor for laparoscopic surgery in postpneumonectomy patients.

The objective of this case report is to present the results on the use of the FloTrac™ sensor for the anesthetic management of laparoscopic adrenalectomy in a patient after pneumonectomy.

Case Report

A 35-year-old woman (weight 69 kg, height 167 cm, ASAII) was diagnosed with retroperitoneal angiosarcoma. She previously underwent an extended hysterectomy at 32 years of age and a right pneumonectomy at 34 years of age to manage the lung metastases.

However, left adrenal metastasis was found on follow-up computed tomography (CT), and she was therefore scheduled for laparoscopic adrenalectomy. Her baseline SpO_2 was 98% (in room air) and home oxygen therapy was not needed. She presented no tachypnea or dyspnea at rest, had no heart failure, and was assigned grade 2 on the Hugh-Jones (HJ) classification scale. Her pulmonary function test demonstrated an FVC of 1.90 L (55.6% of predicted); vital capacity, 53.6%; FEV_1 , 1.38 L (47.3% of predicted); and FEV_1/FVC , 72.4%. The DLCO test was normal. Chest X-ray image and CT revealed a shift of the heart and mediastinal structures into the right hemithorax, elevation of the right hemidiaphragm, and hyperinflation of the remaining lung (Figure 1). Anesthetic management with general anesthesia was planned and the anesthetic record is shown in Figure 2. After oxygenation, general anesthesia was induced via target-controlled infusion of propofol ($3.0 \mu\text{g}\cdot\text{ml}^{-1}$) and remifentanyl ($0.25 \mu\text{g}\cdot\text{kg}^{-1}\cdot\text{min}^{-1}$), and subsequently, the trachea was intubated following the administration of rocuronium (60 mg). She was orotracheally intubated with a 7.0-mm spiral tube, and the position of the endobronchial tube was verified by bronchoscopy. After induction of general anesthesia, a radial artery catheter was inserted and the FloTrac™ sensor (ver.4.00, Edwards Lifesciences, LLC) was attached. The cardiac output (CO), cardiac index (CI), stroke volume (SV), and stroke volume variation (SVV) were evaluated using the EV 1000 monitor. Thereafter,

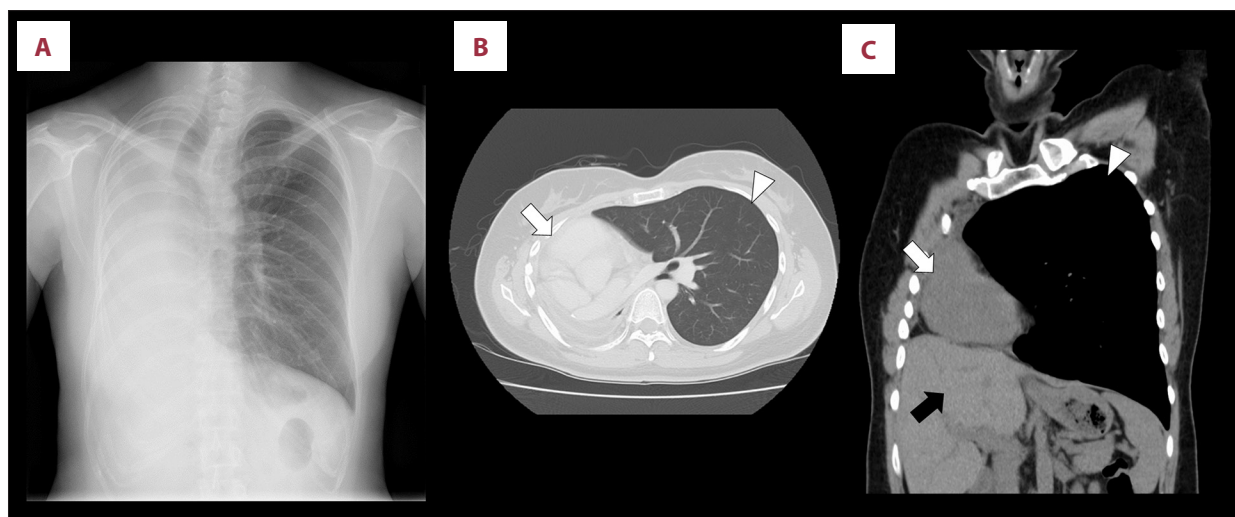


Figure 1. Chest images after pneumonectomy. Chest radiographs show the mediastinum shifting into the right pleural space (A). Chest computed tomography images on axial views (B) and coronal views (C). The left lung is overinflated (arrow) and the heart is shifted into the right space (white arrow). The hemidiaphragm and the liver are elevated (black arrow).

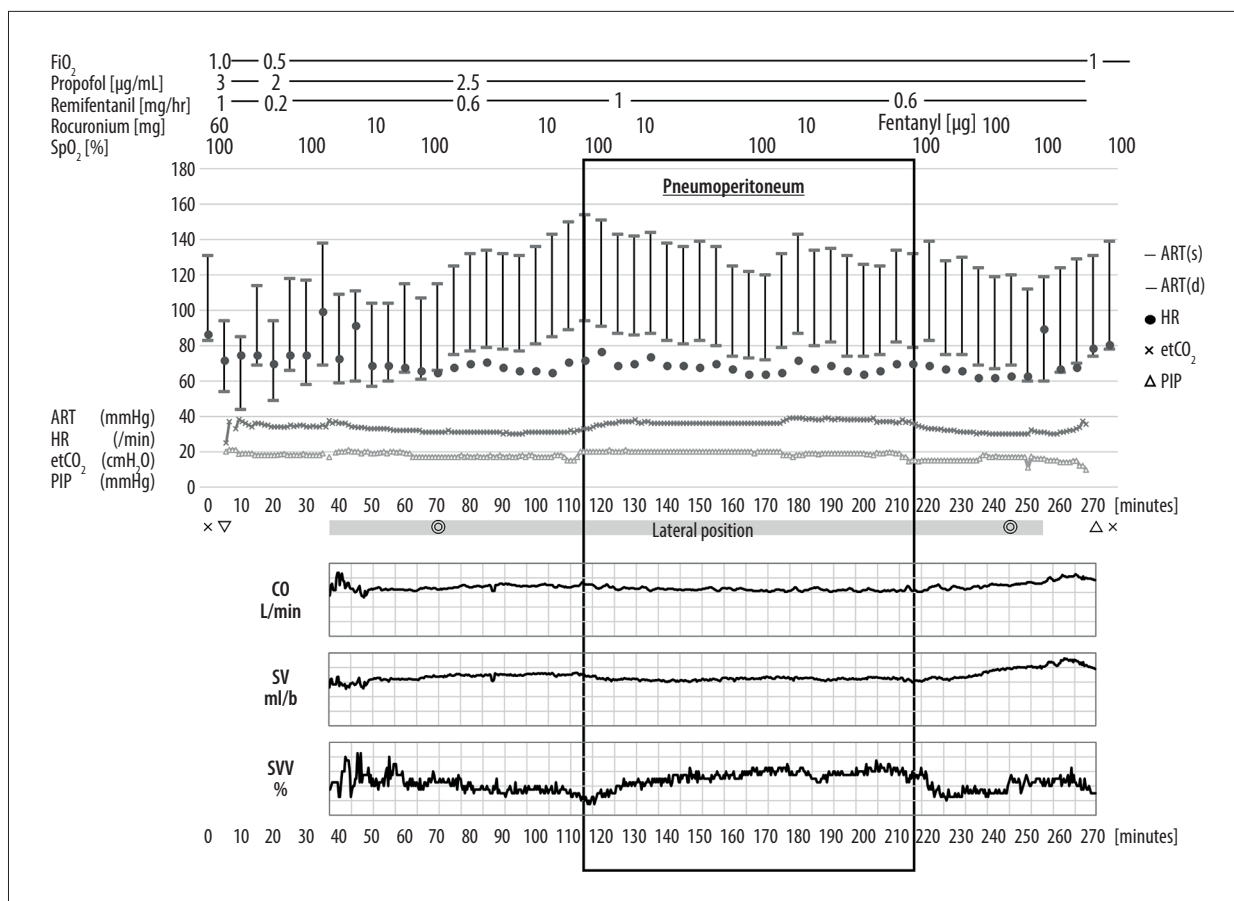


Figure 2. Anesthetic record. Double circle marks represent start/end of surgery; cross marks represent start/end of anesthesia; a triangle mark represents endotracheal intubation/extubation. Heart rate (HR [1/min]: ●), cardiac output (CO [L/min]: ◆), stroke volume variation (SVV [%]: ■), end-tidal CO₂ (etCO₂ [mmHg]: ×), and peak inspiratory pressure (PIP [cmH₂O]: Δ).

she was placed in the right lateral position. From the beginning to the end of the position conversion, the hemodynamic and respiratory status was stable. Anesthesia was maintained with continuous infusion of propofol and remifentanyl, with a bolus of rocuronium. She received pressure control ventilation-volume guaranteed (PCV-VG) mode of ventilation, targeting an expired tidal volume (TV) of 6–7 ml/kg, 0.5 fraction of inspired oxygen, and peak inspiratory pressure (PIP) ≤20 cmH₂O, without using PEEP. Mechanical ventilation was adjusted to maintain the end-tidal pressure of P_{ET}-CO₂ between 30 and 35 mmHg. The lung recruitment test and suction were done as appropriate. Hypoxemia was not observed, and arterial blood gas findings were normal. During the establishment of pneumoperitoneum, SVV increased from 6.7±0.6 to 10.9±1.3%, CO and SV decreased slightly within the normal range (CO: from 6.9±0.2 to 6.4±0.2 L/min, SV; from 103.1±3.2 to 96.4±3.2 L/s); however, no change in blood pressure (BP) or heart rate (HR) was noted. The SVV recovered after the end of pneumoperitoneum. Hemodynamic monitoring, including SVV, CO, and SV, was not changed after changing the patient's position from lateral to supine. After confirming the lack of complications with chest X-ray imaging and blood gas

test, the patient was extubated in the operating room. The duration of the surgery and anesthesia were 177 min and 280 min, respectively. Blood loss was minimal, and the urine volume was 530 ml. She showed good progress and was subsequently discharged home on the 5th postoperative day.

Discussion

This case describes 2 clinical issues. The first is the anesthetic management of laparoscopic adrenalectomy after pneumonectomy using PCV-VG respirator mode. The second is the case of use and effectiveness of the FloTrac™ sensor for detecting hemodynamic change.

The FloTrac™ sensor is minimally invasive and is useful for detecting hemodynamic changes [6,7]. After lung resection, the right ventricular ejection fraction decreases, whereas the right ventricular end-diastolic volume increases [3]. Therefore, early detection of signs of heart failure is important in the anesthetic management of postpneumonectomy patients.

Okada et al. reported a significant decrease in the right ventricular SV after the operation, with a significant increase in HR being considered necessary to maintain CO after major pulmonary resection [8]. Smulders et al. reported that an elevated resting HR and reduced SV in 15 patients, 5 years after pneumonectomy [9]. Liu et al. attempted to reduce the anesthetic and surgical risk associated with severe pulmonary hypertension by following the anesthetic management based on serial SV values using the FloTrac™ sensor [10].

Pneumoperitoneum with laparoscopic surgery affects the hemodynamic status of postpneumonectomy patients. Previous reports on the hemodynamic status of non-pneumonectomy patients during laparoscopic surgery demonstrated the poor reliability of FloTrac™ parameters, especially CO, during the establishment of pneumoperitoneum [11]. Recently, SVV has proven useful in anesthesia management for laparoscopic surgery. Wajima et al. reported that SVV increased during pneumoperitoneum and decreased significantly afterwards [12]. Liu et al. reported that both SVV and plethysmographic variability index increased progressively as the level of intra-abdominal pressure also increased in patients undergoing laparoscopic cholecystectomy [13]. Erik et al. reported that SVV can be safely used as an alternative to CVP monitoring during both open and laparoscopic hepatectomy [14]. It has also been shown to be useful as a dynamic variable of fluid responsiveness during laparoscopic surgery [15,16]. On the other hand, whether SVV with the FloTrac™ sensor can be used as a preload variable for patients undergoing one-lung ventilation (OLV) remains controversial [17–19].

In this case, as evaluated by the FloTrac™ sensor, the SVV increased during the establishment of pneumoperitoneum. The changes in the value of SVV were nearly equal to the change induced by pneumoperitoneum, as previously reported [13]. CO and SV only decreased slightly within the normal range during the establishment of pneumoperitoneum. In addition, the increase of SVV values and the small decrease of CO and SV values recovered after pneumoperitoneum. Therefore, we could determine that the patient's SVV change due to the pneumoperitoneum was within the allowance. The FloTrac™ sensor detected small changes associated with pneumoperitoneum, even in the present postpneumonectomy patient, and may be able to detect signs of heart failure.

Laparoscopic surgery in a postpneumonectomy patient requires careful respiratory management, and respiratory status is closely related to hemodynamic status. Pulmonary function after pneumonectomy depends largely on the preoperative function of the remaining lung [20], age of the patient at the time of surgery [21], the extent of compensatory hyperinflation developed postoperatively, duration of the period following pneumonectomy [22,23], and area of resection (right or left lung) [24].

Here, the patient underwent a right pneumonectomy; however, 1.5 years had elapsed since her pneumonectomy at the time of performing the adrenalectomy. Moreover, her subjective symptoms were mild, that is, grade 2 on HJ classification. Therefore, her remaining lung was considered relatively good.

During the establishment of pneumoperitoneum, the lung was compressed by the raised intra-abdominal pressure, thereby reducing the diaphragmatic excursion, compliance, and functional residual capacity. The recommended necessary tidal volume requires higher plateau and peak airway pressures [25]. Only 2 reports exist on the use of anesthesia for managing laparoscopic surgery in patients after pneumonectomy. Newington et al. and Nair et al. managed laparoscopic surgery after pneumonectomy using endotracheal general anesthesia with mechanical ventilation (pressure-controlled ventilation; the TV of 5–6 ml/kg producing a PIP of 25 cmH₂O) [26,27].

Our lung-protective ventilation strategy was a combination of low TV, low PIP, and minimal PEEP. In this case, we used PCV-VG (producing a PIP of 18–20 cmH₂O and targeting an expired TV of 6–7 ml/kg, without using PEEP). The PIP during anesthesia was similar to that reported in previous studies, and there was less hypercarbia during laparoscopic surgery, as sufficient TV could be achieved using the PCV-VG, in contrast to the previous reports. The primary components of protective ventilation include the low tidal volume (LTV, tidal volume 6–8 mL/kg) and limited peak airway pressure, with or without PEEP [28]. In a comparative study of the 3 respiratory modes during laparoscopic surgery or OLV, PCV-VG and PCV mode leads to a lower PIP and better preservation of compliance than the VCV mode [29, 30]. A recent study showed that PCV-VG has a more consistent tidal volume, fewer excessively deep breaths, lower peak pressure, less hypo- and hypercarbia, and lower levels of inflammatory cytokines [31]. Thus, PCV-VG is a respiratory mode that can provide ideal respiratory management for laparoscopic surgery in postpneumonectomy patients.

This is the first report describing the anesthetic management of laparoscopic surgery in a postpneumonectomy patient using the FloTrac™ sensor to detect hemodynamic changes. Whether the FloTrac™ sensor can help manage laparoscopic anesthesia in patients after lung resection needs to be thoroughly considered in the future. During the establishment of pneumoperitoneum in laparoscopic surgery, not all FloTrac™ parameters are reliable [11]. Regarding SVV, there are problems, such as what should be done with the management target value. Because it is debatable whether SVV can be used as a preload variable during OLV, further research on SVV in postpneumonectomy patients is needed [17,18,32]. Since SVV is measured continuously, SVV indicates, at least, the relative changes if not the absolute values, in postpneumonectomy patients [33]. In postpneumonectomy patients, minimally invasive monitoring is preferred. Although

the FloTrac™ sensor has the practical advantage of being minimally invasive, patients with significantly decreased preoperative cardiopulmonary function may require additional monitoring using more accurate means. In this case, we were able to observe the change in SVV values due to pneumoperitoneum using the FloTrac™ sensor, even in a pneumonectomy patient.

Conclusions

We reported a case of laparoscopic adrenalectomy after pneumonectomy using the FloTrac™ sensor. In cases of laparoscopic surgery after pneumonectomy, special attention must be given

to the respiratory function, hemodynamic status, and the effects of pneumoperitoneum. SVV assessed using the FloTrac™ sensor was able to capture the changes resulting from pneumoperitoneum in this postpneumonectomy patient, which could not be detected by ordinary parameters such as the BP or HR. Thus, SVV measurement using the FloTrac™ sensor appears to be an easy-to-use and promising monitor for detecting the hemodynamic changes associated with laparoscopic surgery in postpneumonectomy patients.

Conflict of interests

None.

References:

1. Kopec SE, Irwin RS, Umali-Torres CB, Balikian JP, Conlan AA: The postpneumonectomy state. *Chest*, 1998; 114(4): 1158–84
2. Deslauriers J, Ugalde P, Miro S et al: Adjustments in cardiorespiratory function after pneumonectomy: Results of the pneumonectomy project. *J Thorac Cardiovasc Surg*, 2011; 141(1): 7–15
3. Kowalewski J, Brocki M, Dryjanski T et al: Right ventricular morphology and function after pulmonary resection. *Eur J Cardiothorac Surg*, 1999; 15(4): 444–48
4. Fragkidis A, Dimitriou A, Dougenis D: Coronary artery bypass grafting and/or valvular surgery in patients with previous pneumonectomy. *J Cardiothorac Surg*, 2012; 7: 110
5. Tanaka M, Ono Y, Matsuda T et al: Guidelines for urological laparoscopic surgery. *Int J Urol*, 2009; 16(2): 115–25
6. Reuter DA, Felbinger TW, Schmidt C et al: Stroke volume variations for assessment of cardiac responsiveness to volume loading in mechanically ventilated patients after cardiac surgery. *Intensive Care Med*, 2002; 28(4): 392–98
7. Cannesson M, Musard H, Desebbe O et al: The ability of stroke volume variations obtained with Vigileo/FloTrac system to monitor fluid responsiveness in mechanically ventilated patients. *Anesth Analg*, 2009; 108(2): 513–17
8. Okada M, Ota T, Okada M et al: Right ventricular dysfunction after major pulmonary resection. *J Thorac Cardiovasc Surg*, 1994; 108(3): 503–11
9. Smulders SA, Holverda S, Vonk-Noordegraaf A et al: Cardiac function and position more than 5 years after pneumonectomy. *Ann Thorac Surg*, 2007; 83(6): 1986–92
10. Liu J, Nahrwold DA, Serdiuk AA et al: Intraoperative goal-directed anesthetic management of the patient with severe pulmonary hypertension. *Am J Case Rep*, 2019; 20: 998–1001
11. Concha MR, Mertz VF, Cortinez LI et al: Pulse contour analysis and transesophageal echocardiography: A comparison of measurements of cardiac output during laparoscopic colon surgery. *Anesth Analg*, 2009; 109(1): 114–18
12. Wajima Z, Shiga T, Imanaga K: Pneumoperitoneum affects stroke volume variation in humans. *J Anesth*, 2015; 29(4): 508–14
13. Liu F, Zhu S, Ji Q et al: The impact of intra-abdominal pressure on the stroke volume variation and plethysmographic variability index in patients undergoing laparoscopic cholecystectomy. *Biosci Trends*, 2015; 9(2): 129–33
14. Dunki-Jacobs EM, Philips P, Scoggins CR et al: Stroke volume variation in hepatic resection: A replacement for standard central venous pressure monitoring. *Ann Surg Oncol*, 2014; 21(2): 473–78
15. Hoiseith LO, Hoff IE, Myre K et al: Dynamic variables of fluid responsiveness during pneumoperitoneum and laparoscopic surgery. *Acta Anaesthesiol Scand*, 2012; 56(6): 777–86
16. Isosu T, Obara S, Ohashi S et al: Examination of the usefulness of non-invasive stroke volume variation monitoring for adjusting fluid supplementation during laparoscopic adrenalectomy in patients with pheochromocytoma. *Fukushima J Med Sci*, 2012; 58(1): 78–81
17. Jeong DM, Ahn HJ, Park HW et al: Stroke volume variation and pulse pressure variation are not useful for predicting fluid responsiveness in thoracic surgery. *Anesth Analg*, 2017; 125(4): 1158–65
18. Fu Q, Zhao F, Mi W, Zhang H: Stroke volume variation fail to predict fluid responsiveness in patients undergoing pulmonary lobectomy with one-lung ventilation using thoracotomy. *Biosci Trends*, 2014; 8(1): 59–63
19. Sahutoglu C, Turksal E, Kocabas S, Askar FZ: Influence of stroke volume variation on fluid treatment and postoperative complications in thoracic surgery. *Ther Clin Risk Manag*, 2018; 14: 575–81
20. Pianetto MB, Harris HA, Sweet HC: Changes in pulmonary function before and after pneumonectomy for pulmonary tuberculosis. *Am Rev Respir Dis*, 1967; 95(2): 189–99
21. Laros CD, Westermann CJ: Dilatation, compensatory growth, or both after pneumonectomy during childhood and adolescence. A thirty-year follow-up study. *J Thorac Cardiovasc Surg*, 1987; 93(4): 570–76
22. Bolliger CT, Jordan P, Soler M et al: Pulmonary function and exercise capacity after lung resection. *Eur Respir J*, 1996; 9(3): 415–21
23. Brunelli A, Xiume F, Refai M et al: Evaluation of expiratory volume, diffusion capacity, and exercise tolerance following major lung resection: A prospective follow-up analysis. *Chest*, 2007; 131(1): 141–47
24. Jacobsen H, Frenokner P, Björkman S: Some attempts at determining the volume and function of each lung separately. *Acta Med Scand*, 1932; 79: 174–88
25. Neudecker J, Sauerland S, Neugebauer E et al: The European Association for Endoscopic Surgery clinical practice guideline on the pneumoperitoneum for laparoscopic surgery. *Surg Endosc*, 2002; 16(7): 1121–43
26. Newington DF, Ismail S: Laparoscopic cholecystectomy in a patient with previous pneumonectomy: A case report and discussion of anaesthetic considerations. *Case Rep Anesthesiol*, 2014; 2014: 582078
27. Nair A, Kulkarni V, Macherla G, Verma S: Laparoscopic adrenalectomy in a post-pneumonectomy state. *Indian J Anaesth*, 2015; 59(6): 386–87
28. Gao S, Zhang Z, Brunelli A et al: The Society for Translational Medicine: Clinical practice guidelines for mechanical ventilation management for patients undergoing lobectomy. *J Thorac Dis*, 2017; 9(9): 3246–54
29. Kothari A, Baskaran D: Pressure-controlled volume guaranteed mode improves respiratory dynamics during laparoscopic cholecystectomy: A comparison with conventional modes. *Anesth Essays Res*, 2018; 12(1): 206–12
30. Lin F, Pan L, Qian W et al: Comparison of three ventilatory modes during one-lung ventilation in elderly patients. *Int J Clin Exp Med*, 2015; 8(6): 9955–60
31. Keszler M: Volume-targeted ventilation. *J Perinatol*, 2005; 25(Suppl. 2): S19–22
32. Zhang J, Chen CQ, Lei XZ et al: Goal-directed fluid optimization based on stroke volume variation and cardiac index during one-lung ventilation in patients undergoing thoracoscopy lobectomy operations: A pilot study. *Clinics (Sao Paulo)*, 2013; 68(7): 1065–70
33. Mayer J, Boldt J, Schollhorn T et al: Semi-invasive monitoring of cardiac output by a new device using arterial pressure waveform analysis: A comparison with intermittent pulmonary artery thermodilution in patients undergoing cardiac surgery. *Br J Anaesth*, 2007; 98(2): 176–82