



## BRIEF COMMUNICATION

**Missense *PDSS1* mutations in CoenzymeQ10 synthesis cause optic atrophy and sensorineural deafness**Francesca Nardecchia<sup>1</sup>, Agnese De Giorgi<sup>1</sup>, Flavia Palombo<sup>2</sup>, Claudio Fiorini<sup>2</sup>, Anna M. De Negri<sup>3</sup>, Valerio Carelli<sup>2,4</sup>, Leonardo Caporali<sup>2,a</sup>  & Vincenzo Leuzzi<sup>5,a</sup> <sup>1</sup>Division of Child Neurology and Infantile Psychiatry, Department of Human Neurosciences, Sapienza University of Rome, Rome, Italy<sup>2</sup>IRCCS Istituto delle Scienze Neurologiche di Bologna, Bellaria Hospital, Bologna, Italy<sup>3</sup>Azienda Ospedaliera San Camillo-Forlanini, Roma, Italy<sup>4</sup>Unit of Neurology, Department of Biomedical and NeuroMotor Sciences (DIBINEM), University of Bologna, Bologna, Italy<sup>5</sup>Department of Human Neurosciences, Università di Roma La Sapienza, Rome, Italy**Correspondence**

Vincenzo Leuzzi, Division of Child Neurology and Infantile Psychiatry, Department of Human Neurosciences, Sapienza, University of Rome, Via dei Sabelli 108, 00141 Roma, Italy, Tel: +39649972930; Fax: +3964440232; E-mail: vincenzo.leuzzi@uniroma1.it

**Funding Information**

This work was supported by Italian Ministry of Health (grants GR-2016-02361449 to L.C.).

Received: 7 August 2020; Revised: 7 October 2020; Accepted: 7 October 2020

*Annals of Clinical and Translational Neurology* 2021; 8(1): 247–251

doi: 10.1002/acn3.51232

<sup>a</sup>These authors share senior authorship.

**Introduction**

Coenzyme Q10 (CoQ10) is involved in several essential reactions, such as the production of ATP in the mitochondrial respiratory chain,<sup>1</sup> the pyrimidine biosynthesis<sup>2</sup> and it is also an important antioxidant,<sup>3</sup> and apoptosis modulator.<sup>4</sup> CoQ is composed of a quinone ring, whose precursor is 4-hydroxybenzoate (4HB), and a polyisoprenoid side chain that has a variable length in different species (10 isoprenic units in humans-CoQ10). *PDSS1* and *PDSS2* genes encode two proteins (DPS1 and DLP1) implied in the first step of CoQ10 synthesis and consist of a heterotetramer, called *decaprenyl diphosphate synthase*, involved in the synthesis of the appropriate length chain. Subsequently, inside mitochondria, *Coq2* connects a polyisoprenoid side chain to

**Abstract**

CoenzymeQ10 is one of the main cellular antioxidants and an essential lipid involved in numerous cell reactions, such as energy production and apoptosis modulation. A large number of enzymes are involved in CoQ10 biosynthesis. Mutations in the genes encoding for these enzymes cause a CoQ10 deficiency, characterized by neurological and systemic symptoms. Here we describe two young sisters with sensorineural deafness followed by optic atrophy, due to a novel homozygous pathogenic variant in *PDSS1*. The visual system seems to be mainly involved when the first steps of CoQ10 synthesis are impaired (*PDSS1*, *PDSS2*, and *COQ2* deficiency).

a benzoquinone ring that is then modified by a complex of enzymes.<sup>5</sup>

CoQ<sub>10</sub> deficiency causes a syndromic combination of neurological symptoms, including visual and auditory impairments, variably associated with cardiological and nephrological involvement.<sup>1</sup> The visual system seems to be especially involved in *PDSS1*, *PDSS2*, or *CoQ2* deficiency.<sup>6–11</sup>

We here report on two sisters with prominent visual and auditive involvement due to a novel homozygous pathogenic variant in *PDSS1*. Pathogenic variants in this gene were previously described in only two families.<sup>6,7</sup>

**Case Description and Results**

This 16-year-old girl was born to consanguineous Egyptian parents following an uneventful pregnancy. She is the

firstborn of four siblings; her 6-year-old sister suffered bilateral sensorineural hearing loss. Her motor development was described as normal, with independent walking acquired at 15 months, but a severe language delay was noticed. At the age of 4 years, a profound bilateral sensorineural hearing loss was found and treated with an externally powered prosthesis. After the prosthesis application, the girl was able to speak simple sentences, whereas verbal comprehension difficulty persisted. Later on, a mild intellectual disability was diagnosed.

When 14-year-old she was referred to our department for evaluation of a progressive visual loss. Family history revealed a paternal recurrence of glaucoma. At 11 years of age her visual acuity was reported as normal, while on ophthalmologic examination at 14 years, her visual acuity was 1/10 bilaterally. At the Ishihara tables, dyschromatopsia on a red-green axis was also reported. A normal direct and consensual pupillary light reflex was noticed without a relative afferent pupillary defect.

Fundus examination showed optic atrophy prevalent in the inferior temporal sector, visual-evoked potentials (VEP) documented an increase in latency and a reduction in amplitude of the P100 waveform in both eyes. Optical coherence tomography (OCT) revealed a bilateral reduction of the retinal nerve fiber layer (RNFL) thickness, more evident in the temporal-inferior sector.

Neurological examination showed diffuse mild muscle weakness with normal deep tendon reflexes and upper limbs mild postural tremor. Brain MRI was normal. An echocardiographic study showed a moderately dysplastic mitral valve with moderate insufficiency, medium-grade tricuspid insufficiency with indirect estimation of systolic pressure in the pulmonary artery of 40 mmHg and moderately dilated left atrium. Biotinidase, Alpha-Fucosidase, and Alpha-Mannosidase activities were normal. Sanger sequencing of *OPA1*, *OPA3*, and *WFS1* did not show pathogenic variants. A whole-exome sequencing analysis revealed a homozygous likely pathogenic missense variant c.735G > T in the *PDSS1* gene, never reported in the public database GnomAD. This variant causes the amino acid change p.Gln245His, in a highly conserved position (98.5%, Fig. 1A). The variant lies in a long region of homozygosity (12 Mb) and its segregation was confirmed in her parents (I:1 and I:2). The analysis has been extended to the patient's siblings and confirmed the presence of the variant in homozygosity in the younger affected sister (II:4); the unaffected sister (II:2) and brother (II:3) was, respectively, homozygous wild-type and heterozygous for the variant (Fig. 1). The affected sister, at the age of 6 years, developed a decrease in visual acuity and a following ophthalmological examination revealed an optic atrophy, with bilaterally pallor of the

optic nerve head on the temporal sector at fundus examination, and divergent strabismus.

## Discussion

*PDSS1* defect has been described in three patients from two families<sup>6,7</sup> carrying three pathogenic variants in the *PDSS1* gene, homozygous in one family and compound heterozygote in the other (Table 1). The clinical picture of the first two siblings described by Mollet and colleagues,<sup>6</sup> carrying a homozygous missense pathogenic variant, was characterized by neurosensorial deafness, optic atrophy, mild intellectual disability, muscular weakness, and cardiac involvement consisting in mild to moderate valvulopathy. Notably, in these cases, neurosensorial loss preceded optic atrophy, like in our cases. In contrast, Vasta and colleagues<sup>7</sup> described a patient, carrying a missense and a truncating pathogenic variant in compound heterozygosity, with a much severe phenotype characterized by leukoencephalopathy with a lactic acid peak on spectroscopy, associated with a severe nephrotic syndrome that caused kidney failure and death at the age of 16 months. Brain MRI was not performed in the first two affected siblings, whereas it was normal in the older sister of the present report.

While unusual in mitochondrial disorders, steroid-resistant nephrotic syndrome (SRNS) is a hallmark of primary CoQ10 deficiency. However, SRNS has been reported not only in infancy with a rapid progression but also with onset in the first or second decade of life and slow progression.<sup>8</sup>

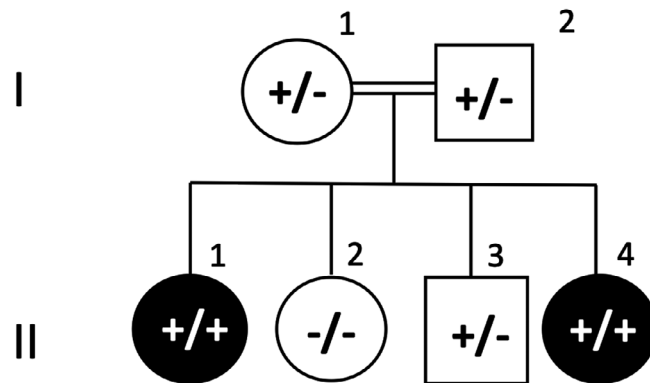
Visual system involvement in CoQ10 deficiencies has been reported only in the defect of the very first steps of CoQ10 synthesis and it consists of optic atrophy, a combination of optic atrophy and retinitis pigmentosa or retinitis pigmentosa only in *PDSS1*, *PDSS2*, and *COQ2* defect, respectively.<sup>6–12</sup>

Most inherited optic neuropathies are recognized as a result of alterations in mitochondrial metabolism, especially when associated with sensorineural deafness. Cellular energetic impairment related to CoQ10 deficiency and other mitochondrial dysfunctions, may affect the visual pathway from the retina to retrochiasm structures.<sup>13</sup> *PDSS1* deficiency is a clinically heterogenous rare disorder that deserves to be added to the differential diagnosis of optic atrophy associated with sensorineural deafness. In contrast to *OPA1* and *OPA3* defects, the onset of sensorineural deafness seems to precede the optic atrophy in *PDSS1*, hallmarking this particular form. CoQ10 synthesis defects should be deemed as treatable conditions and as such should enter in the differential diagnosis of optic atrophy and sensorineural deafness, although ultrarare so far.

# A

p.Gln245His	235-	IEDLVRGEFL	<b>H</b>	LGSKENENER	-255
Homo sapiens	235-	IEDLVRGEFL	Q	LGSKENENER	-255
Pan paniscus	235-	IEDLVRGEFL	Q	LGSKENENER	-255
Macaca mulatta	235-	IEDLVRGEFL	Q	LGSKENENER	-255
Felis catus	218-	IEDLVRGEFL	Q	LGSKENENER	-238
Canis lupus familiaris	193-	IEDLVRGEFL	Q	LGSKENENER	-213
Bos taurus	232-	IEDLVRGEFL	Q	LGSKENENER	-252
Equus caballus	224-	IEDLVRGEFL	Q	LGSKENENER	-244
Loxodonta africana	180-	IEDLVRGEFL	Q	LGSKENENER	-200
Oryctolagus cuniculus	243-	IEDLVRGEFL	Q	LGSKENENER	-263
Mus musculus	217-	IEDLVRGEFL	Q	LGSKENENER	-237
Vombatus ursinus	112-	IEDLVRGEFL	Q	LGSKENENER	-132
Ornithorhynchus anatinus	197-	LEDLVRGEFL	Q	LGSKENENER	-217
Alligator mississippiensis	182-	IEDLVRGEFL	Q	LGSKENENER	-202
Ophiophagus Hannah	144-	IEDLVRGEFL	Q	LGSKENENER	-164
Xenopus laevis	232-	MEDLVRGEFL	Q	LGSKENENER	-252
Nothobranchius kuhntae	252-	IEDLVRGEFM	Q	LGSKENQNER	-272
Danio rerio	221-	IEDLVRGEFM	Q	LGSKENENER	-241
Lygus hesperus	208-	LSDLVQGEFM	Q	LGAKETENER	-228
Bactrocera latifrons	280-	LTDLVQGEFM	Q	LGSKETENER	-300
Hydra vulgaris	192-	IHDLVKGE	L	LVSKDDIDQR	-212

# B



**Figure 1.** Global alignment of PDSS1 protein sequences from a wide range of eukaryotes (A). Amino acid residues with a percentage of conservation ranging between 70.0% and 79.9% are highlighted in light gray, those between 80.0% and 94.9% are highlighted in dark gray and those between 95.0% and 100% are highlighted in black. The percentage of conservation was calculated on 184 protein sequences. Pedigree of the affected family (B). \*flags the residue mutated in the present case.

**Table 1.** Clinical features of the previously published patients with *PDS1* pathogenetic variants.

	Mollet et al 2007 <sup>6</sup>	Mollet et al 2007 <sup>6</sup>	Vasta et al 2012 <sup>7</sup>	Present case (1)	Present case (2)
PDSS1 variants Ref Seq NM_014317.5	c.924T> G (p.Asp308Glu) homozygous	c.924T> G	p.Asp308Glu) homozygous	c.661C> T (p.Arg221Ter) c.1108A> C (p.Ser370Arg) compound heterozygous	c.735G> T p.Gln245His homozygous
Sex/age at examination	M 22y	F 14y	Death at 16 months	F 14y	F 6y
Developmental impairment	Mild intellectual disability	Mild intellectual disability	Developmental delay	Mild intellectual disability	Mild intellectual disability
Brain MRI	ND	ND	Leukoencephalopathy/lactic acid peak on spectroscopy	Normal	ND
Lactic acidosis	+	+	ND	–	–
Macrocephaly	+	+	ND	–	–
Failure to thrive	–	–	+	–	–
Peripheral neuropathy	+	+	ND	–	–
Muscular involvement (weakness/exercise intolerance)	+	+	ND	+	+
Sensorineural deafness	+	+	ND	+	+
Optic atrophy	+	+	ND	+	+
Cardiac valvulopathy	+	+	ND	+	–
Obesity/livedo reticularis	+	+	ND	–	–
Nephrotic syndrome	–	–	+	–	–

## Acknowledgment

A warm thank goes to the patients (and their families) for sharing their history and data.

## Conflict of Interest

The authors declare that they have no conflict of interest.

## Authors' Contributions

All authors have read and approved the manuscript. De Giorgi Agnese and Nardecchia Francesca were involved in the patient's care; acquisition, analysis, and interpretation of data, and drafting/revising the manuscript for content. Anna Maria De Negri was involved in the patient's care; acquisition, analysis, and interpretation of data and revising the manuscript. Palombo Flavia and Fiorini Claudio were involved in the genetic analysis, the interpretation of data and revising the manuscript. Caporali Leonardo and Carelli Valerio were involved in the genetic analysis, the interpretation of data, revising the manuscript, and study

supervision. Leuzzi Vincenzo was involved in the patient care; acquisition, analysis, and interpretation of data; drafting/revising the manuscript for content and study supervision.

## References

1. Quinzii CM, López LC, Naini A, et al. Human CoQ10 deficiencies. *BioFactors* 2008;32:113–118.
2. López-Martín JM, Salviati L, Trevisson E, et al. Missense mutation of the COQ2 gene causes defects of bioenergetics and de novo pyrimidine synthesis. *Hum Mol Genet* 2007;16:1091–1097.
3. Ernster L, Dallner G. Biochemical, physiological and medical aspects of ubiquinone function. *Biochim Biophys Acta* 1995;1271:195–204.
4. Fontaine E, Ichas F, Bernardi P. A ubiquinone-binding site regulates the mitochondrial permeability transition pore. *J Biol Chem* 1998;273:25734–25740.
5. Marbois B, Gin P, Faull KF, et al. Coq3 and Coq4 define a polypeptide complex in yeast mitochondria for the biosynthesis of coenzyme Q. *J Biol Chem* 2005;280:20231–20238.

6. Mollet J, Giurgea I, Schlemmer D, et al. Prenyldiphosphate synthase, subunit 1 (PDSS1) and OH-benzoate polyprenyltransferase (COQ2) mutations in ubiquinone deficiency and oxidative phosphorylation disorders. *J Clin Invest* 2007;117:765–772.
7. Vasta V, Merritt JL 2nd, Saneto RP, et al. Next-generation sequencing for mitochondrial diseases: a wide diagnostic spectrum. *Pediatr Int* 2012;54:585–601.
8. Salviati L, Trevisson E, Doimo M, et al. Primary coenzyme Q10 deficiency. 2017 Jan 26. In: M. P. Adam, H. H. Ardinger, R. A. Pagon, et al., eds. *GeneReviews*® [Internet]. Seattle, WA: University of Washington, 1993–2020.
9. Rötig A, Appelkvist EL, Geromel V, et al. Quinone-responsive multiple respiratory-chain dysfunction due to widespread coenzyme Q10 deficiency. *Lancet* 2000;356:391–395.
10. Rahman S, Clarke CF, Hirano M. 176th ENMC International Workshop: diagnosis and treatment of coenzyme Q10 deficiency. *Neuromuscul Disord* 2011;22:76–86.
11. Mitsui J, Matsukawa T, Ishiura H, et al. Mutations in COQ2 in familial and sporadic multiple-system atrophy. *N Engl J Med* 2013;369:233–244.
12. Desbats MA, Morbidoni V, Silic-Benussi M, et al. The COQ2 genotype predicts the severity of coenzyme Q10 deficiency. *Hum Mol Genet* 2016;25:4256–4265.
13. Leruez S, Amati-Bonneau P, Verny C, et al. Mitochondrial dysfunction affecting visual pathways. *Revue Neurol* 2014;170:344–354.