

Research Article

Clinicopathologic Aspects of Endometrial Proliferous Processes in Women of Reproductive Age

Iryna Vovk, Nataliya Gorban^{*}, Valentyna Kondratiuk

Abstract

The peculiarities of benign proliferative pathology of endometrium including their combination in women of reproductive age are reviewed in the article.

Materials and methods. The results of pathohistological research of benign proliferative pathology of endometrium (without atypia) were analyzed. Statistical data processing was performed by means of MedStat software package.

Results. The obtained results revealed that benign proliferative pathology of endometrium is one of the most frequent gynaecological malignancies among female patients of reproductive age accounting for 52.2 % cases. Endometrial polyps were found to be accompanied by morphological peculiarities indicating chronic inflammatory process in endometrium in 56.5% cases ($p < 0.05$) in comparison with endometrial hyperplasia in 38.2% cases, proving the presence of long-term inflammation in endometrial tissue and its trigger role in the development of the proliferative processes. Among patients with chronic salpingo-oophoritis, infertility was revealed in almost half of cases (44.5% of patients with endometrial polyps, 40.5% of patients with endometrial hyperplasia and 48.3% of women with combined proliferative pathology of endometrium) clinically confirming the data of morphological research. Peculiar signs of proliferative processes in genitals were determined, namely coexistence of uterine and endometrial pathology: endometrial hyperplasia was found in 40.4% of patients with uterine leiomyoma and 30.3% of patients with adenomyosis. The same combinations were peculiar for patients with endometrial polyps: endometrial hyperplasia was found in 30.1% of patients with uterine leiomyoma and 36.3% of patients with adenomyosis. Menstrual disorders were revealed in every third woman with endometrial hyperplasia (30.3%) and co-existent polyposis (30.2%).

Keywords

endometrial hyperplasia; endometrial polyps; infertility; proliferative processes

Institute of Pediatrics, Obstetrics and Gynecology of the National Academy of Medical Sciences of Ukraine, Kyiv, Ukraine

***Corresponding author:** ngorban@i.ua

Problem statement and analysis of the recent research

Over the past decades there has been a significant increase in the incidence of endometrial hyperplasia, cancer, and malignant endometrial hyperplastic processes (EHP) [9].

The EHP group is represented by an aggregate of morphological and biological heterogenic changes in endometrium varying from excessive proliferation to endometrial cancer [11]. This group of diseases includes different variants of hyperplasia and endometrial polyps.

Endometrial hyperplasia is a benign pathology of uterine lining characterized by advanced clinicopathologic manifestations from simple to complex hyperplasia to atypical precursor of endometrial cancer, which develops on the background of absolute or relative hyperestrogenia [7]. Although estrogenic stimulation of endometrium is considered the main etiological risk factor for the development of endometrial hyperplasia, some researchers indicated other factors, such as immunosuppression and infection [13].

Endometrial polyps are local benign proliferation of uterine lining along with subjacent stroma [8].

A number of pathologists demonstrated that endometrial polyps develop initially in focal basal hyperplasia of endometrium, when nodes appear due to glandular and stromal hyperplasia [12]; this explains a similarity of these different proliferative nosologies.

Taking into consideration the diversity of histological construction of different types of EHP, an issue of the unified clinical interpretation of terminological definitions of the process has long been the subject of constant discussions.

Thus, in 1943, the researchers Papanicolaou and Fraut revealed that cytological investigation could diagnose endometrial cancer (they received a high percentage of coincidence of vaginal smears and histological findings of endometrium in patients with endometrial cancer); however, over the next 40 years the scientists had proven that the effectiveness of such therapy was not more than 50%.

In 1994, the World Health Organization (WHO) adopted

the classification of endometrial hyperplasia based on the recommendations of leading gynaecologists, oncologists and pathomorphologists, according to which the diagnostic criterion for endometrial cancer precursors was the presence of cytological atypia (endometrial hyperplasia without atypia – simple or complex and atypical hyperplasia of endometrium – simple or complex). The classification given above was of great importance for the tactical selection of treatment, whereas an important difference between these two kinds of hyperplasia was the damage to tissue differentiation (complex atypical hyperplasia, as compared to high-grade differentiated adenocarcinoma, which has no signs of stromal invasion) [1].

However, the classification given above had some disadvantages – there were no established patterns of transformation of one kind of endometrial hyperplasia into another one or endometrial cancer; concomitant sites of endometrial cancer could remain unnoticed. This classification did not include a separate classification of “endometrial polyp” considering the recommendations how to interpret it in chronic endometritis requiring the additional examination and adequate etiopathogenetic anti-inflammatory therapy, and hormonal therapy in such cases was determined by the peculiarities of morpho-functional structure of background endometrium [4, 10].

At the beginning of the 21st century (1999 and 2000), two groups of morphologists: European Group of Experts and G. Mutter with Endometrial Collaborative Group proposed to reduce variants of endometrial hyperplasia from 4 to 2. Thus, the European approach proposed endometrial hyperplasia and endometrial neoplasia (EN), G. Mutter and co-authors proposed endometrial hyperplasia and endometrial intraepithelial neoplasia (EIN) [6].

Morphological differentiation of two categories consisted in the visual analysis of architectonics of the parenchyma (glands) and cytological changes and was confirmed by morphometrically semi-quantitative determination of the ratio between stroma and endometrial volume, considering the measurements of stroma, epithelium and glandular lumen area [17]. According to the calculations – EN/EIN is the pre-malignant process with approximately 30% risk of malignant changes requiring more thorough treatment and observation. Some researches consider that such scheme predicts the rate of disease progression more accurately than the classification of 1994 [2, 18, 21].

The recent international guideline for the treatment of endometrial hyperplasia adopted in 2016 by the Royal College of Obstetricians and Gynaecologists (RCOG) and the British Society of Gynaecological Endoscopy (BSGE), recommends in practical activity to follow the 2014 WHO classification, which divides endometrial hyperplasia into two groups based on the presence of cytological atypia: hyperplasia without atypia and atypical hyperplasia or hyperplasia with atypia Class D [16].

Summarizing the above-mentioned information, it is necessary to understand that despite the EHP classification chosen by a doctor the important factor for differential diagnostics

between benign and malignant process is receiving a sufficient quantity of the material which is possible only in diagnostic curettage or endometrial aspiration [10].

According to normative and regulatory acts in the field of medicine in Ukraine, namely – nomenclature coding, application of international classification of diseases in the 10th revision, we used the following classification during clinicopathologic research:

- N 84 Polyp of female genital tract.
- N 84.0 Polyp of corpus uteri.
- N 85 Other non-inflammatory uterus damages, except cervix.
- N 85.0 Glandular hyperplasia of endometrium: polycystic, glandular-polycystic polyp.

The objective of the research was to analyze morphological data on abnormal endometrium in women of reproductive age with gynaecological pathology to specify peculiarities of pathogenetic mechanisms of reproductive health disorders among a given population.

1. Materials and methods

There were analyzed 910 case reports of patients with benign endometrial proliferative processes undergoing medical treatment in the department of family planning and operative rehabilitation of reproductive function in women of the Institute of Pediatrics, Obstetrics and Gynaecology of the National Academy of Medical Sciences (NAMS) of Ukraine during 2010-2014.

Case reports were analyzed to determine the structure of concomitant gynaecological pathology among a given population.

Inclusion criteria were: the patient's reproductive age (18-49 years), the results of pathohistological research of benign proliferative pathology of endometrium (without atypia): endometrial polyp, endometrial hyperplasia, combined proliferative endometrial pathology.

EHP was verified in all the patients at the preoperative stage by ultrasound examination of the pelvic organs. Patients were examined bacteriologically (the absence of sexually-transmitted infections, as well as diagnostically significant levels of bacterial load of non-specific opportunistic flora of the reproductive tract was confirmed). In the preoperative period, all patients received antibiotics, namely pluripotent systemic preparations and local sanitation.

To determine the state of the uterine cavity, to estimate the localization of pathological changes in endometrium visually, to control the quality of diagnostic curettage, hysteroscopy was carried out in combination with further obligatory pathohistologic investigation of the material received.

In concomitant gynaecological pathology requiring surgical treatment (tubo-peritoneal or combined forms of infertility), laparoscopy or laparotomy was performed.

Laparoscopy and hysteroscopy with biopsy of endometrium were performed by means of equipment manufactured by Aesculap and KarlStorz (Germany) according to standard procedure.

Tissues received during surgery (uterine cavity curettage) were used for histological analysis. The investigations were carried out in pathomorphological laboratory of the Institute of Pediatrics, Obstetrics and Gynaecology of NAMS of Ukraine.

Statistic data processing was carried out by means of MedStat software package (Lyakh YuE, Guryanov VG, 2004-2011). To represent quantitative signs - the median value (Me) and the value of the first and third quartiles (QI – QIII) [22] were calculated; to represent qualitative signs – the frequency of manifestations (%) and the standard error (m%) were calculated. To compare the indices in three groups, the Kruskal-Wallis test was used, and as a post-hoc test the Dunn's multiple comparison test was used [22]. To compare sign manifestation frequency, a chi-squared test was used [22]; the Marascuilo procedure was performed in post-hoc comparisons. In all cases, the results were statistically significant at 0.05.

2. Results and discussion

During 2010-2014, 1, 743 patients treated in the department of family planning and operative rehabilitation of reproductive function in women of the Institute of Pediatrics, Obstetrics and Gynaecology of NAMS of Ukraine underwent surgery (hysteroscopy, diagnostic curettage of the uterine cavity) due to gynaecological diseases.

Among them, there were 910 (52.2%) patients of reproductive age with benign proliferative pathology.

The distribution of cases (Fig. 1) is clearly indicative of the absence of the decrease in the incidence of pathology and rather stable indices within 5 years among the examined women.

During the analysis of age structure of the examined female population, their age was found to vary from 18 to 49 years; the average age was 35 years.

According to Table 1, EHP was most frequently diagnosed in women of reproductive age (71.0 %) - from 26 to 40 years (in 26.2 %, they were at the age of 31-35 years).

According to the type of benign proliferative endometrial pathology, all the patients were distributed into 3 groups: Group I included patients with endometrial polyps (n=705); Group II comprised patients with verified endometrial hyperplasia (n=89); Group III included women with combined endometrial pathology – hyperplasia and polyps (n=116).

Thus, the average age of women of Group I was 34 years (from 24 to 48 years), the average age of women of Group II was 35 years (from 25 to 46 years), the average age of women of Group III was 36 years (from 25.3 years to 47 years), without statistically significant difference between the research groups ($p=0.81$ in the Kruskal-Wallis test), allowing us comparing data and analyze them.

The main pathohistological characteristics reflecting the morphological state of the study material were the following: signs of chronic endometritis, sites of fibromuscular tissue, non-synchronous transformation of endometrium, stromal fibrosis, hypoplasia of the mucous membrane (Fig. 2, Table 2).

Thus, according to Fig. 2, in all groups of patients, the most frequent morphological sign was CIP in endometrium (chronic endometritis and/or focal stromal fibrosis, developing on the background of long-lasting chronic inflammation, sometimes involving rather large sites [5]), which was detected in 56.5% of women with endometrial polyps, 38.2% of patients with endometrial hyperplasia and 38.8% of patients with combined proliferative pathology of endometrium ($p<0.001$). CIP was found more frequently in patients with endometrial polyps than in those with endometrial hyperplasia ($p<0.05$). There was no statistically significant difference ($p>0.05$) when comparing groups with endometrial hyperplasia and combined proliferative pathology of endometrium.

The data mentioned above demonstrated the state of the uterine cavity in patients with proliferative pathology of endometrium without clinical signs of pelvic inflammatory disease since surgery and the presence of sexually transmitted infections. Chronic endometritis was verified in more than a half of patients with endometrial polyps and every third woman with hyperplasia or combined proliferative pathology of endometrium indicating the leading etiological role in the pathology development - chronic subclinical inflammatory process without an objective sign.

The data received coincided with modern microbiological researches [14, 19], where a correlation between endometrial polyps and chronic endometritis developing on the background of high levels of bacterial contamination of reproductive tract (including *Ureaplasma urealyticum* or different associations of non-specific opportunistic flora) was determined [20]. There is an idea that this may be one of the reasons of excessive growth of endometrial tissue due to long-term stimulation by biological inflammatory factors [14, 19].

It is necessary to note that in literature [15], there are only few works describing the attempts to study endometrial polyps of bacterial origin, necessitating more in-depth research of bacterial and viral characteristics of biological environment in patients with proliferative endometrial pathology.

The next morphological characteristics of the examined material obtained from patients with proliferative endometrial pathology was the presence of fibromuscular tissue sites (Table 2) which were found in 23.3% of patients with endometrial polyps, 18.0% of patients with endometrial hyperplasia and 17.2% of females with combined endometrial proliferative pathology. The indices were rather uniform between the groups without statistically significant difference ($p=0.220$).

The data described above indicated that approximately every fifth woman of reproductive age suffering from endometrial proliferative pathology (polyps or signs of endometrial

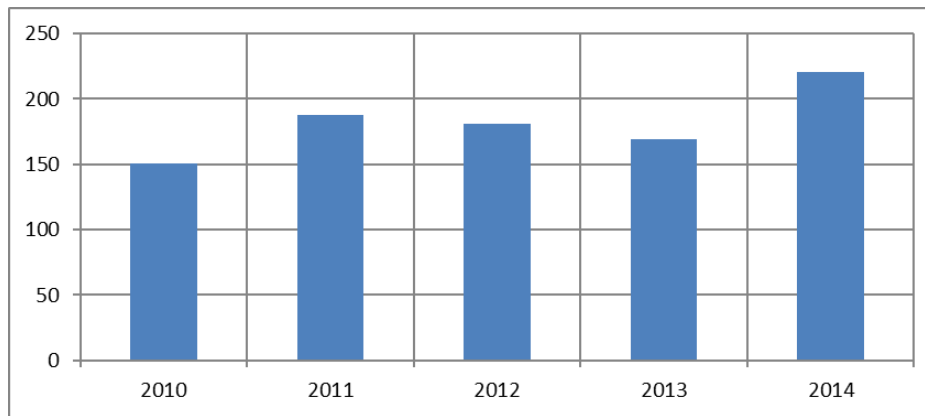


Figure 1. Frequency of EHP determination in patients who underwent surgery (hysteroscopy, diagnostic curettage of the uterine cavity) during 2010-2014

Table 1. Distribution of the examined women per year, abs (%)

Index (years)	18-25	26-30	31-35	36-40	41-45	46-49
Abs.	56	201	238	207	140	68
(%)	(6.1)	(22.1)	(26.2)	(22.7)	(15.4)	(7.5)

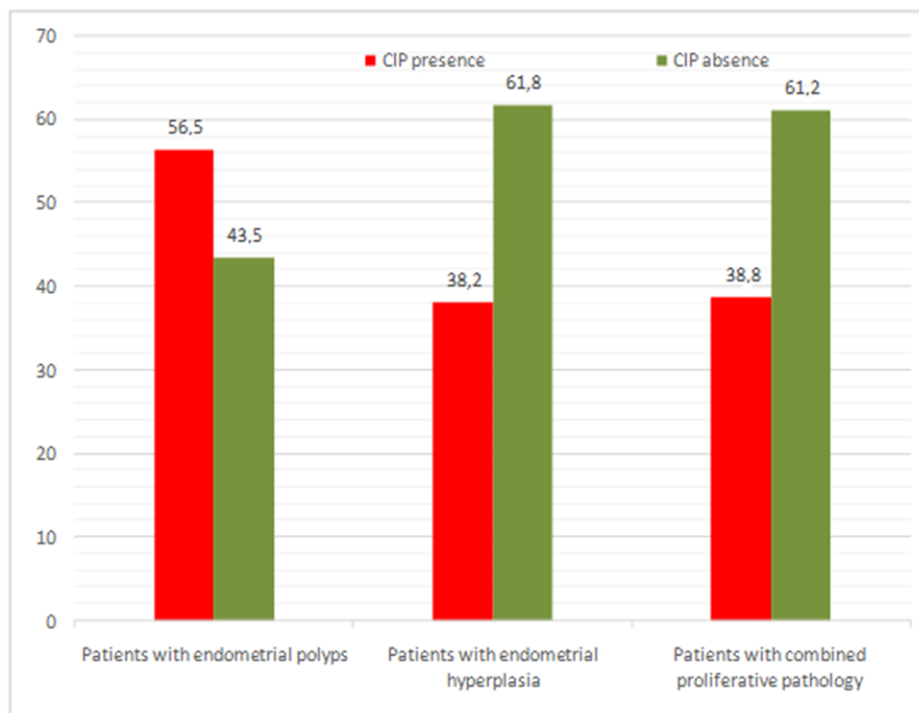


Figure 2. Frequency of determination of chronic inflammatory process (CIP) of endometrium in patients with endometrial proliferative pathology

hyperplasia according to ultrasound investigation) can have uterine submucous myoma, which is rather difficult to visually differentiate from other EHP. Such a situation may be a cause of unsuccessful results of conservative treatment of

such patients and the presence of more pronounced clinical signs of the disease.

Endometrial tissue is known to be hormone-dependent organ, functional activity of which depends completely on

Table 2. Morphological characteristics of uterine cavity material in patients with proliferative pathology of endometrium, abs. (%±m%)

Index		Manifestation frequency, abs. (%±m%)			p
		Group I (n=705)	Group II (n=89)	Group III (n=116)	
Fibromuscular tissue sites	Yes	164 (23.3±1.6)	16 (18.0±4.1)	20 (17.2±3.5)	0.22
	No	541 (76.7±1.6)	73 (82.0±4.1)	96 (82.8±3.5)	
Non-synchronous transformation of endometrium	Yes	93 (13.2±1.3)#	2 (2.2±1.6)*	9 (7.8±2.5)	0.004
	No	612 (86.8±1.3)	87 (97.8±1.6)	107 (92.2±2.5)	
Hyperplasia of mucous membrane	Yes	23 (3.3±0.7)	3 (3.4±1.9)	–	0.14
	No	682 (96.7±0.7)	86 (96.6±1.9)	116 (100)	

Notes. Chi-square analyses were used for comparison, post-hoc comparison was carried out with the application of the Marascuilo procedure.

* - the difference from Group I is statistically significant ($p < 0.05$);

- the difference from Group II is statistically significant ($p < 0.05$).

steroid hormone homeostasis. Absolute or relative hyperestrogenia causing disorders of cyclic function of endometrium towards the proliferation and complications of tissue disorders is proven to be the main pathogenetic component in the formation of endometrial hyperplasia.

Non-synchronous endometrium transformation may occur secondary to it being histologically verified in patients with proliferative pathology of endometrium in 13.2% to 2.2% cases (13.2% - Group I, 2.2% - Group II, 7.8% - Group III). There was a statistically significant difference ($p = 0.004$) between patients with endometrial polyps and those with endometrial hyperplasia expressing non-adequacy of homogeneous cyclic change in endometrial tissue in patients with endometrial polyps.

The next stage of our research was the study of the structure of the reproductive system disease in patients with proliferative endometrial pathology. It is reflected in Table 3.

We selected the most common nosological forms being the main genital disorders in women of reproductive age (infertility, chronic salpingitis, spike process of the pelvic organs, uterine leiomyoma, adenomyosis), which were diagnosed at patient's discharge from the hospital.

Thus, in almost half of patients, infertility was detected (44.5% of patients with endometrial polyps, 40.5% of patients with endometrial hyperplasia and 48.3% of women with combined proliferative pathology of endometrium); there were no statistically significant differences between the groups ($p = 0.626$). In Group I, 27.1% of patients had primary infertility and 17.4% of patients had secondary infertility; in Group II, primary infertility was found in 27.0% of cases and secondary one was detected in 13.5% of women; in Group III, primary infertility was diagnosed in 32.8% of patients,

secondary infertility was detected in 15.5% of patients.

The next nosological form of reproductive disorders was CIP diagnosed in 50% of patients with endometrial polyps and those with combined proliferative endometrial pathology (50.1% and 50.0%, respectively). Lower index was observed in women with endometrial hyperplasia – 44.9%, however, it was too high ($p = 0.657$).

Considering a high incidence of infertility and chronic inflammatory process, the next stage was the analysis of the tube-peritoneal factor indices – the presence of spike process of the pelvic organs which was revealed in about every fourth woman with the following distribution: Group I – in 28.7% of patients, Group II – in 22.5% of patients, Group III – in 24.1% of patients; there were no differences between the groups, $p = 0.324$.

Taking into account the priority direction of our work, namely proliferative processes of endometrium, it was important to estimate myometrial proliferative changes considering the modern views on the unity and unidirectionality of these pathological changes (“hyperplastic syndrome” [3]).

Thus, uterine leiomyoma was diagnosed in 30-40% of women of reproductive age with endometrial proliferative pathology: among women with endometrial polyps, leiomyoma was revealed in 30.1% of cases; among patients with hyperplasia of endometrium, it was found in 40.4% of cases; patients with combined proliferative pathology of endometrium were diagnosed with leiomyoma in 29.3% of cases; there were no differences between the groups, $p = 0.125$.

Adenomyosis was diagnosed in 30-38% of patients with proliferative endometrial pathology: among patients of Group I, adenomyosis was diagnosed in 36.3% of cases; among patients of Group II, it was observed in 30.3% of cases; 37.9%

Table 3. Structure of reproductive system diseases in patients with endometrial proliferative pathology abs. (%±m%)

Index		Manifestation frequency, abs. (%±m%)			p
		Group I (n=705)	Group II (n=89)	Group III (n=116)	
Infertility	I1	191 (27.1±1.7)	24 (27.0±4.7)	38 (32.8±4.4)	0.63
	I2	123 (17.4±1.4)	12 (13.5±3.6)	18 (15.5±3.4)	
	No	391 (55.5±1.9)	53 (59.5±5.2)	60 (51.7±4.6)	
Chronic salpingitis	Yes	353 (50.1±1.9)	40 (44.9±5.3)	58 (50.0±4.6)	0.66
	No	352 (48.9±1.9)	49 (55.1±5.3)	58 (50.0±4.6)	
Spike process of the pelvic organs	Yes	202 (28.7±1.7)	20 (22.5±4.4)	28 (24.1±4.0)	0.32
	No	503 (71.3±1.7)	69 (77.5±4.4)	88 (75.9±4.0)	
Uterine leiomyoma	Yes	212 (30.1±1.7)	36 (40.4±5.2)	34 (29.3±4.2)	0.13
	No	493 (69.9±1.7)	53 (59.6±5.2)	82 (70.0±4.2)	
Adenomyosis	Yes	256 (36.3±1.8)	27 (30.3±4.9)	44 (37.9±4.5)	0.48
	No	449 (63.7±1.8)	62 (69.7±4.9)	72 (62.1±4.5)	

Note. Chi-square analyses were used for comparison.

patients of Group III group were diagnosed with adenomyosis; there were no differences between the groups, $p=0.483$, i.e., in every third woman, proliferative endometrial processes co-existed with adenomyosis.

Considering the unity of proliferate cascade of reactions in those patients, the state of ovarian tissue was examined, allowing us to determine the presence of functional ovarian cysts (OC) (endometrioid cyst (EC), corpus luteum cyst (CLC), follicular cyst (FC)) and parovarian ganglions (PG) (Morgagni's cysts, parovarian cysts) in insignificant number of women (Table 4).

Thus, in patients with endometrial polyps, this index was as follows: EC was seen in 5.4% of cases, CLC was revealed in 0.6% of women, FC was found in 0.4% of patients, PG were revealed in 2.7% of females. In women with endometrial hyperplasia, there was the following distribution: EC was seen in 2.2% of cases, CLC was revealed in 1.1% of women, FC was found in 5.6% of patients, PG were diagnosed in 4.5% of females. In combined proliferative endometrial pathology, EC was seen in 7.0% of patients, CLC was revealed in 0.9% of women, FC was found in 1.7% of patients, PG was diagnosed in 2.6% of women. The only difference between the groups concerned ovarian follicular cyst being statistically significant at a level <0.001 with index increase from 0.4% in patients with local endometrial pathology up to 5.6% in women with

endometrial hyperplasia.

Polycystic ovarian syndrome was determined with equal frequency in patients of Group II and Group III (12.4% and 12.9%, respectively), with a tendency to decrease in women with endometrial polyps – up to 6.7% of cases.

The patient's complaint of menstrual disorders is known to be the most frequent clinical manifestation of endometrial hyperplasia. It developed in 30.3% to 18.4% of patients (30.3% of patients with endometrial hyperplasia, 30.2% of patients with combined proliferative endometrium pathology, 18.4% of women with endometrial polyps), with a difference ($p=0.001$) between patients with endometrial polyps and patients of two other groups - it may be used as a convenient diagnostic marker.

3. Conclusions

1. Benign proliferative pathology of endometrium is one of the most frequent gynaecological malignancies among female patients of reproductive age who underwent hospital treatment accounting for 52.2 % cases.
2. Endometrial polyps were found to be accompanied by morphological peculiarities indicating CIP in endometrium in 56.5% cases ($p<0.05$) in comparison with endometrial hyperplasia in 38.2% cases, proving

Table 4. State of the ovaries in patients with endometrial proliferative pathology, abs. (%±m%)

Index		Manifestation frequency, abs. (%±m%)			p
		Group I (n=705)	Group II (n=89)	Group III (n=116)	
OC	Yes	19 (2.7±0.6)	4 (4.5±2.2)	3 (2.6±1.5)	0.62
	No	686 (97.3±0.6)	85 (95.5±2.2)	113 (97.4±1.5)	
EC	Yes	38 (5.4±0.9)	2 (2.2±1.6)	8 (7.0±2.4)	0.32
	No	667 (94.6±0.9)	87 (97.8±1.6)	108 (93.0±2.4)	
CLC	Yes	4 (0.6±0.3)	1 (1.1±1.1)	1 (0.9±0.9)	0.80
	No	701 (99.4±0.3)	88 (98.9±1.1)	115 (99.1±0.9)	
FC	Yes	3 (0.4±0.2)#	5 (5.6±2.4)*	2 (1.7±1.2)	<0.001
	No	702 (99.6±0.2)	84 (94.4±2.4)	113 (98.3±1.2)	
Polycystic ovarian syndrome	Yes	47 (6.7±0.9)	11 (12.4±3.5)	15 (12.9±3.1)	0.02
	No	658 (93.3±0.9)	78 (87.6±3.5)	101 (87.1±3.1)	
Menstrual disorders	Yes	130 (18.4±1.5)\$	27 (30.3±4.9)	35 (30.2±4.3)*	0.001
	No	575 (81.6±1.5)	62 (69.7±4.9)	81 (69.8±4.3)	

Notes. Chi-square analyses were used for comparison, post-hoc comparison was carried out with the application of the Marascuilo procedure

* – the difference from Group I is statistically significant ($p < 0.05$);

– the difference from Group II is statistically significant ($p < 0.05$);

\$ – the difference from Group III is statistically significant ($p < 0.05$).

the presence of long-term inflammation in endometrial tissue and its trigger role in the development of the proliferative processes.

3. Among patients with chronic salpingo-oophoritis, infertility was revealed in almost half of cases (44.5% of patients with endometrial polyps, 40.5% of patients with endometrial hyperplasia and 48.3% of women with combined proliferative pathology of endometrium) clinically confirming the data of morphological research.
4. Characteristic features of genital proliferative processes were determined, namely coexistence of uterine and endometrial pathology: endometrial hyperplasia was found in 40.4% of patients with uterine leiomyoma and 30.3% of patients with adenomyosis. The same combinations were peculiar for patients with endometrial polyps: endometrial hyperplasia was found in 30.1% of patients with uterine leiomyoma and 36.3% of patients with adenomyosis
5. The state of menstrual function in patients with proliferative

erative pathology of endometrium was characterized by cycle disorders in every third woman with endometrial hyperplasia (30.3%) and co-existent polyposis (30.2%), which proves the advisability of mandatory ultrasound investigation which allows diagnosing endometrial proliferative process in a patient at the outpatient stage.

6. The given above data indicate that the issue considered is one of the main problems in modern gynaecology as well as reproductive medicine and should be pathogenetically substantiated and solved in an integrated manner.

References

- [1] Zaporozhan VM. Obstetrics and gynecology. Zaporozhan VM, editor. Neoperatyvna hinekolojiya. 2014; 502-503.
- [2] Bishtavi AH, Manuhin IB, Tabakman YY. Modern concepts of endometrial hyperplasia and endometrial intraep-

- ithelial neoplasia (literature review). *Problemy reproduktsii*. 2010; 6: 52-8.
- [3] Vishnevskiy AS. Hyperplastic syndrome in gynaecology. *InformMed*. c2013; 188p.
- [4] Kovalenko EP, Tatarchuk TF, Kubyshkin AV, Filonenko TG. Endometrial hyperplasia and inflammation: evaluation of leukocyte infiltration and level of proinflammatory cytokines. *Zdorovye zhenshchiny*. 2011; 7 (63): 142-145.
- [5] Kuznetsova AV. Chronic endometritis. *Arh. patol*. 2000; 3 (62): 48-52.
- [6] Metelskaya MA, Rogov YI. The possibilities of using a computer image analyzer for differential diagnosis of endometrial hyperplastic processes. *Onkologicheskii zhurnal*. 2012; 3 (23): 15-22.
- [7] On approval of clinical protocols for obstetric and gynecological care. The Order of Ministry of Health of Ukraine of 03.11.2008 No 624.
- [8] Vihlyayeva EM, Zheleznov BI. Polyps of the endometrium. *Guide to Endocrine Gynecology*. 3rd ed. 2006; 447-462.
- [9] Zaporozhan VN, Tatarchuk TF. Modern diagnostics and treatment of endometrial hyperplastic processes. *Reproduktivnaya endokrinologiya*. 2012; 1 (3): 5-12.
- [10] Tatarchuk TF, Zadorozhna TD, Vorobyova LI. Modern principles of diagnosis and treatment of hyperplastic processes of endometrium. *Metodychni rekomendatsiyi*. Kyiv; 2005.
- [11] Chernuha GE. Hyperplasia of the endometrium: the prospects for the development of the problem. *Akusherstvo i ginekologiya*. 2009; 4: 11-14.
- [12] Yakovleva IY, Kukuteh VG. Morphological diagnosis of precancerous processes and uterine tumors by biopsy and scrapings. 1979; 145.
- [13] Bobrowska K, Kamiński P, Cyganek A, Pietrzak B, Jabiry-Zieniewicz Z, Durlik M. High rate of endometrial hyperplasia in renal transplanted women. *Transplantation Proceedings*. 2006; 178-197.
- [14] El-Hamarnah T, Hey-Cunningham AJ, Berbic M, Al-Jefout M, Fraser IS, Black K. Cellular immune environment in endometrial polyps. *Fertil Steril*. 2013; 100 (5): 1364-1372. DOI: <https://doi.org/10.1016/j.fertnstert.2013.06.050> [PMid:23931965]
- [15] Kitaya K, Yasuo T. Aberrant expression of selectin E, CXCL1, and CXCL13 in chronic endometritis. *Modern Pathology*. 2010; 23 (8): 1136-1146. DOI: <https://doi.org/10.1038/modpathol.2010.98>
- [16] Green-top Guideline 67 RCOG/BSGE Joint Guideline of February 2016. Management of Endometrial Hyperplasia.
- [17] Mutter GL. Endometrial intraepithelial neoplasia (EIN): will it bring order to chaos? The Endometrial Collaborative Group. *Gynecol Oncol*. 2000; 76 (3): 287-290. DOI: <https://doi.org/10.1006/gyno.1999.5580>
- [18] Mutter GL, Baak JPA, Crum CP, Richart RM, Ferenczy A, Faquin WC. Endometrial precancer diagnosis by histopathology, clonal analysis, and computerized morphometry. *J Pathol*. 2000; 190 (4): 462-469. DOI: [https://doi.org/10.1002/\(SICI\)1096-9896\(200003\)190:4<462::AID-PATH590>3.0.CO;2-D](https://doi.org/10.1002/(SICI)1096-9896(200003)190:4<462::AID-PATH590>3.0.CO;2-D)
- [19] Al-Jefout M, Black K, Schulke L, Berbic M, Luscombe G, Tokushige N et al. Novel finding of high density of activated mast cells in endometrial polyps. *Fertil Steril*. 2009; 92 (3): 1104-1106. DOI: <https://doi.org/10.1016/j.fertnstert.2009.02.016>
- [20] Cicinelli E, De Ziegler D, Nicoletti R, Tinelli R, Saliani N, Resta L, et al. Poor reliability of vaginal and endocervical cultures for evaluating microbiology of endometrial cavity in women with chronic endometritis. *Gynecol Obstet Invest*. 2009; 68 (2): 108-115. DOI: <https://doi.org/10.1159/000223819>
- [21] Skov BG, Broholm H, Engel U, Franzmann MB, Nielsen AL, Lauritzen AF, et al. Comparison of the reproducibility of the WHO classifications of 1975 and 1994 of endometrial hyperplasia. *Int J Gynecol Pathol*. 1997; 16 (1): 33-37. DOI: <https://doi.org/10.1097/00004347-199701000-00006> [PMid:8986530]
- [22] Petrie A, Sabin C. *Medical Statistics at a Glance*. 2nd ed. c2005. 157p.

Received: 14 Nov 2017

Revised: 26 Dec 2017

Accepted: 26 Dec 2017