



THE AGA KHAN UNIVERSITY

eCommons@AKU

Internal Medicine, East Africa

Medical College, East Africa

3-2021

Cases of neuromyelitis optica spectrum disorder from the East Africa region, highlighting challenges in diagnostics and healthcare access

Dilraj Sokhi

Adil Suleiman

Soraiya Manji


Juzar Hooker

Peter Mativo

Follow this and additional works at: https://ecommons.aku.edu/eastafrica_fhs_mc_intern_med



Part of the [Neurology Commons](#)



Cases of neuromyelitis optica spectrum disorder from the East Africa region, highlighting challenges in diagnostics and healthcare access

Dilraj Sokhi^{a,b,*}, Adil Suleiman^{a,b}, Soraiya Manji^{a,b}, Juzar Hooker^b, Peter Mativo^{a,b}

^a Department of Medicine, Faculty of Health Sciences, Aga Khan University Medical College of East Africa, Nairobi, Kenya

^b The Aga Khan University Hospital, Nairobi, Kenya

ARTICLE INFO

Keywords:

Neuromyelitis optica spectrum disorder
Neuro-immunology
Neuro-inflammation
Sub-Saharan Africa

ABSTRACT

Background: Neuromyelitis optica spectrum disorder (NMOSD) is an auto-immune disease of the central nervous system (CNS) associated with the IgG-antibody against aquaporin-4 (AQP4-IgG). There is little published epidemiology of NMOSD from sub-Saharan Africa (SSA).

Methods: We retrospectively collated NMOSD cases admitted to our tertiary regional neurology centre.

Results: We identified 11 cases (10 female, average age 30 years). 64% (7/11) were seropositive for AQP4-IgG, measured using indirect immunofluorescence. The remaining cases could either not afford tests, or had pathognomonic radiological features. 57% (4/7) of seropositive cases had concurrent/recent CNS infection. All patients were treated with high-dose intravenous methylprednisolone (IVMP), and 36% (4/11) also had plasma exchange. Only 55% (6/11) of the patients were seen by a neurologist at presentation: they had less relapses (1.3 vs 2.4), less diagnostic delay (2.3 vs 7.4 months), and were less disabled at the end of our review period. 10 cases were immunosuppressed long-term: 60% on mycophenolate, 30% azathioprine, and one on rituximab.

Conclusion: Our study is the largest case series of NMOSD from the East Africa region. Patients faced challenges of access to appropriate and affordable testing, and timely availability of a neurologist at onset, which had impacts on their functional outcomes. The majority of the seropositive cases had recent/concurrent CNS infections, suggesting triggered auto-immunity.

1. Introduction

Neuromyelitis optica spectrum disorder (NMOSD) is an auto-immune relapsing central nervous system disorder (CNS), diagnosed based on the presence of core clinical characteristic presentations, the presence of aquaporin-4 immunoglobulin G antibodies (AQP4-IgG), and/or pathognomonic findings on CNS magnetic resonance imaging (MRI) as per the International Panel for NMOSD Diagnosis (IPND) criteria [1]. It is strongly recommended that AQP4-IgG is tested using a cell-based assay, but if negative or not available then the clinical characteristics and MRI findings can fulfil the NMOSD diagnostic criteria. About one-third of AQP4-IgG seronegative NMOSD patients have been found to be positive for antibodies against myelin oligodendrocyte

glycoprotein (MOG-Ab) [2]. Anti-MOG disease is another CNS auto-immune demyelinating syndrome which mimics the clinical presentation of NMOSD but has been recently identified as a separate entity [3]. It has therefore been proposed that it is reasonable to test for both AQP4-IgG and MOG-Abs in patients with an NMOSD presentation [4].

Patients presenting acutely with NMOSD should be promptly recognised, investigated and then commenced on relapse treatment followed by long-term maintenance immunosuppression to prevent devastating relapses [5]. However, there is variable availability of testing for AQP4-IgG and MOG-Ab globally with the least accessibility noted in low/lower-middle income countries in Africa [6], and coupled with the lack of MRI scanners in Africa [7] this makes the diagnosis of NMOSD and anti-MOG disease particularly more challenging in these

Abbreviations: CNS, Central nervous system; CSF, Cerebrospinal fluid; EDSS, Extended Disability Status Scale; HIV, Human immunodeficiency virus; HSV-2, Herpes simplex virus type 2; ICD-10, International Classification of Diseases version 10; IPND, International Panel for NMOSD Diagnosis; IVMP, Intravenous methylprednisolone; LETM, Longitudinally extensive transverse myelitis; MMF, Mycophenolate mofetil; MOG, Myelin oligodendrocyte glycoprotein; MRI, Magnetic resonance imaging; nd, not done; NMOSD, Neuromyelitis optica spectrum disorder; OCBs, Oligoclonal bands; ON, Bilateral simultaneous or sequential optic neuritis; PLEX, Plasma exchange; RRMS, Relapsing-remitting multiple sclerosis; RTX, Rituximab; TPHA, Treponema pallidum haemagglutination assay.

* Corresponding author at: Room 405 4th Floor East Tower Block, Third Avenue Parklands, P.O.Box 30270, Nairobi 00100 GPO, Kenya.

E-mail address: Dilraj.Sokhi@aku.edu (D. Sokhi).

<https://doi.org/10.1016/j.ensci.2021.100320>

Received 13 October 2020; Received in revised form 22 December 2020; Accepted 17 January 2021

Available online 23 January 2021

2405-6502/© 2021 The Author(s).

Published by Elsevier B.V. This is an open access article under the CC BY-NC-ND license

(<http://creativecommons.org/licenses/by-nc-nd/4.0/>).

settings.

The epidemiology of NMOSD in developing countries is being increasingly understood e.g. in Latin America, NMOSD prevalence varies from 0.37–4.2/100,000 inhabitants, with AQP4-IgG seropositivity being 33–73.5% [8]. However, there remains a significant gap of data from Africa e.g. in a 2013 systematic review of 216 population-based studies, five reported the incidence and prevalence of NMOSD but none were from Africa [9], and a 2018 review also revealed no prevalence studies from Africa [10]. Latitude does not seem to be related to NMOSD prevalence [11], yet to date there are less than 500 cases of NMOSD published from Africa [12], of which the majority are from North [13–15] and West [16–19] Africa, with a smaller cohort from South Africa [20] and only one case report from East Africa [21].

Based on studies published from large multi-ethnic cohorts mostly in developed countries, it has been consistently shown that NMOSD, particularly atypical optic neuritis, is much more common [22], more severe, and more likely to be associated with AQP4-IgG seropositivity in patients of African and Afro-Caribbean background [8,23,24]. In a retrospective analysis from eleven Brazilian hospitals, 81/153 cases of NMOSD had at least one black grandparent, and they were more likely to have worse disability at diagnosis when compared to Caucasian patients [25]. We have previously reported the largest cohort of multiple sclerosis (MS) from East Africa [26] from our ongoing registry project. Given all the literature reviewed above, we report here NMOSD cases from our hospital cohort as the local population seem to be more at risk of developing severe disease.

2. Materials and methods

2.1. Ethical considerations

Our protocol of our continuing MS cohort study at our regional tertiary referral hospital has been approved by our Institutional Ethics Review Committee (approval number REC-99/2018). The protocol includes looking for MS mimics and chameleons [27] particularly NMOSD.

2.2. Informed consent and patient details

We have obtained written informed consent from all the patients for whom we have supplied MRI images as well as the supplementary video, and these consent forms have been filed in their medical records at our hospital. The patient identifiers from the images and video have been removed or obscured to maintain patient confidentiality.

2.3. Identification of NMOSD cases

We performed case-finding for NMOSD cases from our MS registry through a combination of:

1. International Classification of Diseases version 10 (ICD-10) coding for patients discharged from our hospital (our institution does not code for outpatient visits) with the following codes: NMOSD, acute transverse myelitis in demyelinating disease of CNS, optic neuritis, acute brainstem syndrome, area postrema syndrome, diencephalic syndrome and narcolepsy;
2. Positive AQP4-IgG antibodies in serum and/or cerebrospinal fluid (CSF) obtained from our laboratory database as per the 'Investigations' section of our MS registry data collection protocol;
3. Recollection from memory by the neurologists at our institution (authors DSS, JH and PM).

We reviewed all cases and collected information on the clinical presentation(s), including timelines, and investigation results, particularly MRI findings and AQP4-IgG results in order to match the IPND criteria as well as to ensure there were no 'red flags' to suggest a

diagnosis other than NMOSD. In addition, as per the MS research protocol, we gathered information according to the 'Treatment/Management' and 'Outcome' sections of the MS registry protocol, which included management of acute relapses and choice of immunosuppression, and outcome measured using the Extended Disability Status Scale (EDSS).

2.4. Data analysis and management

Case summaries were collected in a Microsoft Word document. We tabulated the findings in a Microsoft Excel sheet. Neither of these documents contained any patient identifiers, and both were password-protected and were stored in a shared drive within our institution's intranet, which is only accessible by the authors via passwords. The information in these sheets could only be linked to the patient via a handwritten sheet of random numbers that were locked in the office of the leading author (DSS).

3. Results

We collected 11 cases, all of whom were of black African background and indigenous to East Africa. The findings above are summarised in Table 1. 91% (10/11) were female, with an average age of 30 years at presentation (range 15–51 years). Longitudinally extensive transverse myelitis (LETM) and Optic neuritis (ON) – all bilateral simultaneous or sequential – were the commonest first presentations in 45% (5/11) and 36% (4/11) of cases, and similarly for second presentations [27% (3/11) and 18% (2/11) respectively]. One patient (case 1) had with both LETM and ON at the first presentation i.e. classic Devic syndrome. 27% (3/11) presented with acute brainstem syndrome (ABS), all as a first symptom (including case 5; see Fig. 1 for respective MRI brain scan correlates), and only one patient (case 6) had area postrema syndrome (APS) as a second symptom after LETM (see Fig. 2 for MRI correlates). Two patients (cases 5 and 7) had pathognomonic dystonic spasms (see Supplementary Video 1 of case 5, Fig. 3).

In terms of AQP4-IgG testing, 64% (7/11) had a positive result from serum, of which three cases also had a positive test in CSF (CSF AQP4-IgG was not done in the remaining 4 patients who were seropositive). Case 11 could not afford testing for AQP4-IgG, and the remaining patients (cases 8 through 10) were seronegative, but we included these cases in our series for the following reasons:

- Our institution does not offer cell-based assay testing for AQP4-IgG;
- Case 9 and 11 both presented with bilateral sequential ON then LETM;
- Case 8 presented with LETM and case 10 with bilateral simultaneous ON extending over half the optic nerve length on MRI (see Fig. 4 for MRI of optic nerves in case 10) with an altitudinal visual field defect, and both required PLEX.

There were other positive results from investigations that we noted, most notably that the majority (4/7) of AQP4-IgG positive cases had laboratory, including CSF, evidence of concurrent or recent CNS infection: tuberculosis (TB, case 2), herpes simplex virus type 2 (HSV-2, case 6), syphilis (case 7: see Fig. 5 for MRI of LETM), and sterile meningitis with pleocytotic CSF [case 1, who also had oligoclonal bands (OCBs) in CSF]. Case 8 had lymphocytic CSF but no positive microbiology or PCR/serology.

10 of the 11 patients were treated with high-dose intravenous methylprednisolone (IVMP), administered as 1 gram per day for three to five days, for each acute relapse, and some were given a tapering dose of oral prednisolone of variable doses and duration after IVMP. All the cases with concurrent/recent infections were treated with the appropriate anti-microbials before embarking on IVMP treatment, as directed by our infectious disease specialists: case 6 was given fourteen days of intravenous acyclovir together with PLEX; case 2 was treated with anti-

Table 1
Summary of results of NMOSD cases.

Case no.:	AQP4-IgG antibody positive							AQP4-IgG antibody -ve/unavailable				
	1	2	3	4	5	6	7	8 ^g	9	10	11	
Age at onset (in years)	15	17	22	36	36	45	51	18	26	30	34	
Core clinical characteristic presentation ^a	ON	1	1	2	2	1	1	1	1	1	2	
	LETM	1	2	2	1	1	1	1	2			
	APS											
	ABS			1		1					1	
AQP4-IgG antibody:	Serum	+ve	+ve	+ve	+ve	+ve	+ve	-ve	-ve	-ve	nd	
	CSF	nd	nd ^d	nd	+ve	na ^f	+ve	nd	-ve	-ve	nd	
CSF (NR): white cell count (<5/mm ³) ^b		32 (76%)	nd	<5	<5	na	145 (90%)	61 (85%)	<5	<5	nd	
glucose (2.22–3.89 mmol/L)		3.32	nd	3.39	3.11	na	3.42	5.36	3.6	2.31	3.55	
protein (0.15–0.45 g/L)		1.59	nd	0.23	0.37	na	0.48	0.36	0.57	0.44	0.17	
positive microbiology		n	nd	n	n	na	HSV2	TPHA	n	n	n	
OCBs		-ve	nd	-ve	-ve	nd	-ve	-ve	-ve	-ve	-ve	
PLEX after IVMP		n	n	n	n	y	y	n	y	n	y	
Neurologist involved at onset		y	y	y	y	y	n	n	n	n	y	
Delay to diagnosis (in months)		0	14	7	1	1	1	5	3	7	0	
Relapses before diagnosis		1	4	2	1	1	1	2	2	3	1	
Maintenance immunosuppression		None	MMF	MMF	MMF	AZP	MMF	MMF	RTX	MMF	AZP	
Relapses after immunosuppression		None	na ^e	None	None	None	None	1	None	None	None	
EDSS at last review		na ^e	2	7	1	1	8	7	2	8	2	
Diagnosis to last review (months)		46	11	26	18	39	13	9	32	18	21	
Additional notes		OCBs +ve after 4 years	First treated as CNS TB	first treated as RRMS	Post-partum & lactating	Tonic spasms		Relapse as non-compliant		Anti-MOG negative	Could not afford tests	

Abbreviations: +ve = positive; -ve = negative; ABS = acute brainstem syndrome; APS = area postrema syndrome; AZP = azathioprine; CNS = central nervous system; CSF = cerebrospinal fluid; EDSS = extended disability status scale; HSV-2 = Herpes simplex virus type 2; IVMP = intravenous methylprednisolone; LETM = longitudinally extensive transverse myelitis; MMF = mycophenolate mofetil; MOG = myelin oligodendrocyte protein; na = not available; nd = not done; NR = normal range; OCBs = oligoclonal bands; ON = bilateral simultaneous or sequential optic neuritis; PLEX = plasma exchange; PCR = polymerase chain reaction; RRMS = relapsing-remitting multiple sclerosis; RTX = rituximab; TB = tuberculosis; TPHA = treponema pallidum haemagglutination assay

^a Number denotes presentation: “1” = first presentation, “2” = second presentation.

^b Red cell counts all <5mm³.

^c Percentage lymphocytes.

^d Not done as evidence of pulmonary tuberculosis so treated empirically for CNS disease.

^e Lost to follow-up as emigrated.

^f Not available as done in another country and records unavailable.

^g Male patient (remainder of cases all female).

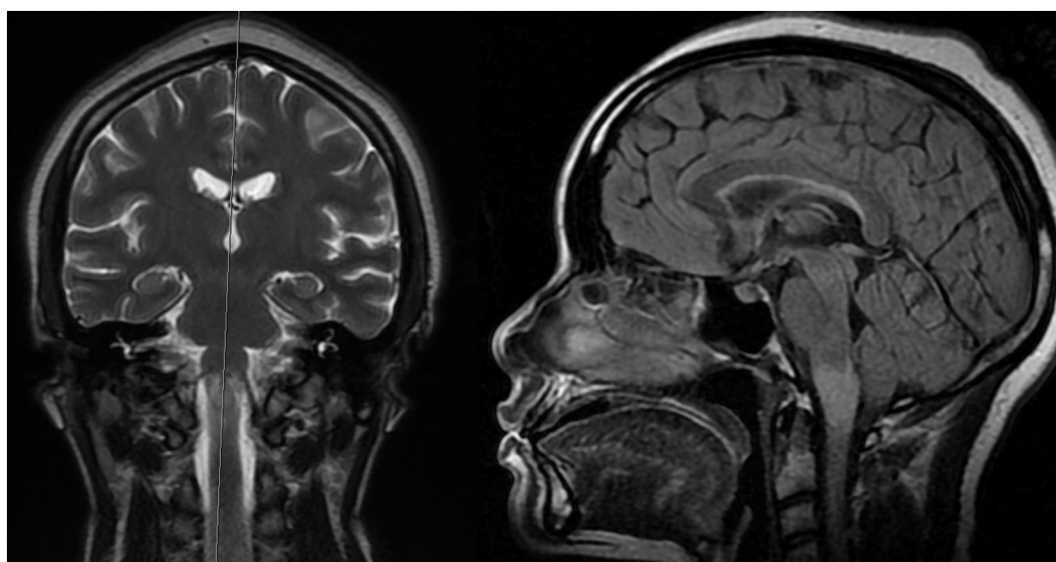


Fig. 1. Coronal T2 (left image) and sagittal (right image) fluid-attenuated inversion recovery (FLAIR) magnetic resonance imaging (MRI) sequences of case 5 showing a hyper-intense expansile lesion of the medulla and cervical-medullary junction, who presented with acute brainstem syndrome and quadriplegia.

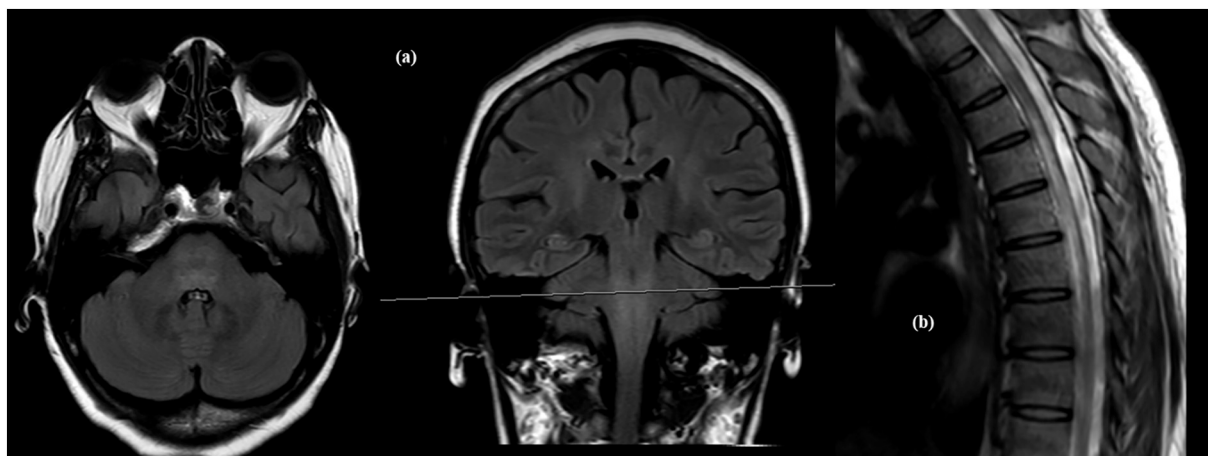


Fig. 2. (a) Axial and coronal MRI FLAIR sequences showing pontomedullary non-enhancing T2/FLAIR hyper-intense signals in case 6 which manifested as persistent vomiting and vertigo in keeping with an area postrema syndrome. (b) The patient first presented with LETM (b) at another hospital (source images unavailable). This MRI sagittal T2 slice of thoracic spine shows hyperintense spinal cord signals from C7-T9 (non-enhancing as post-PLEX).

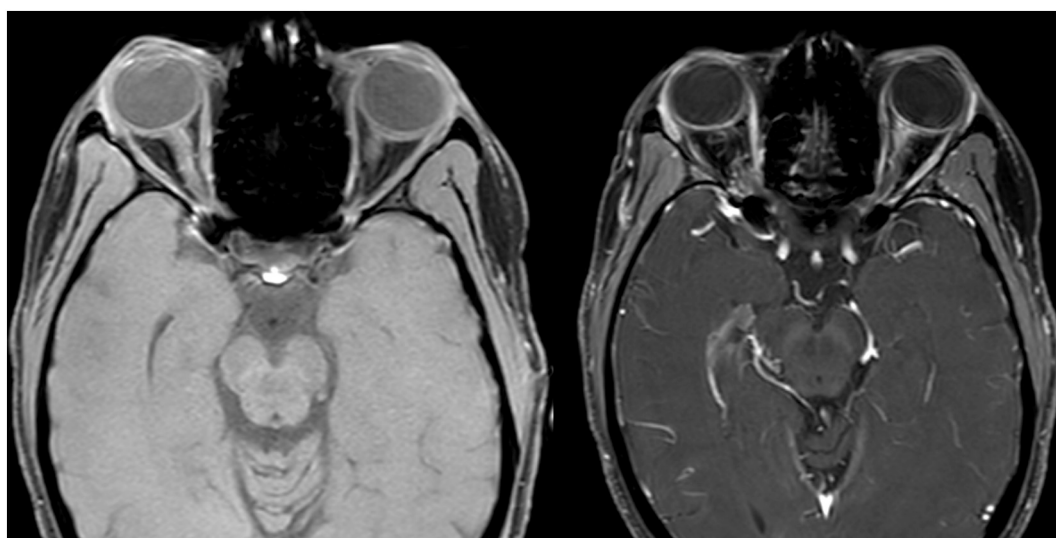


Fig. 3. Axial spectral presaturation with inversion recovery (SPIR) MRI images of the orbits for case 10, who presented with bilateral simultaneous optic neuritis, showing hyper-intense signal along most of the right optic nerve (left image) with bilateral optic nerve sheath enhancement (right image; more evident for left optic nerve).

tubercular therapy and dexamethasone for two weeks then with IVMP; case 7 was treated with penicillin G for 2 weeks before proceeding to IVMP. 36% (4/11) had plasma exchange (PLEX) after IVMP if there was no clinical response and/or MRI findings were suggestive of severe disease.

Just over half (6/11) of the patients were seen by a neurologist during the first presentation, and when compared to the remaining five cases, they had: (i) less relapse presentations before the diagnosis was made (average 1.3 vs 2.4 relapses); (ii) less delay to NMOSD diagnosis (average 2.3 months vs 7.4 months); and (iii) less disability when assessed at the end of our review period (average EDSS score of 3.6 vs 5.4).

All our NMOSD patients were commenced on long-term immunosuppression, although we did not have details for case 1 as she transferred her care to outside our facility during her acute illness and was lost to follow-up. For the remaining cases, the most frequently prescribed regimen was mycophenolate in 60% (6/10) of cases, with azathioprine (3/10) and rituximab (case 8 alone) being used in the remainder of the cohort. Average follow-up time was 25 months (range 9 to 48), with no difference if first seen by a neurologist.

Although case 3 was diagnosed with NMOSD at 7 months by one of the authors, appropriate immunosuppressive therapy was not commenced until 3 years later as the patient was lost to follow-up and sought treatment at various locations outside our institution and was managed as relapsing-remitting MS; during this time she had 3 further relapses with a relatively poor EDSS when she returned to our services. Case 4 was 3 months post-partum when she developed LETM, and was breastfeeding so she made an informed decision with her neurologist not to commence on immunosuppression after the positive serum AQP4-IgG result came out given the perceived risks. Unfortunately she relapsed with bilateral simultaneous ON, although with good recovery, within the same month at which point she decided to commence immunosuppression.

4. Discussion

4.1. Demographics

The NMOSD cohort at our institution was predominantly female with an average of 30 years, which is in keeping with what has been found in

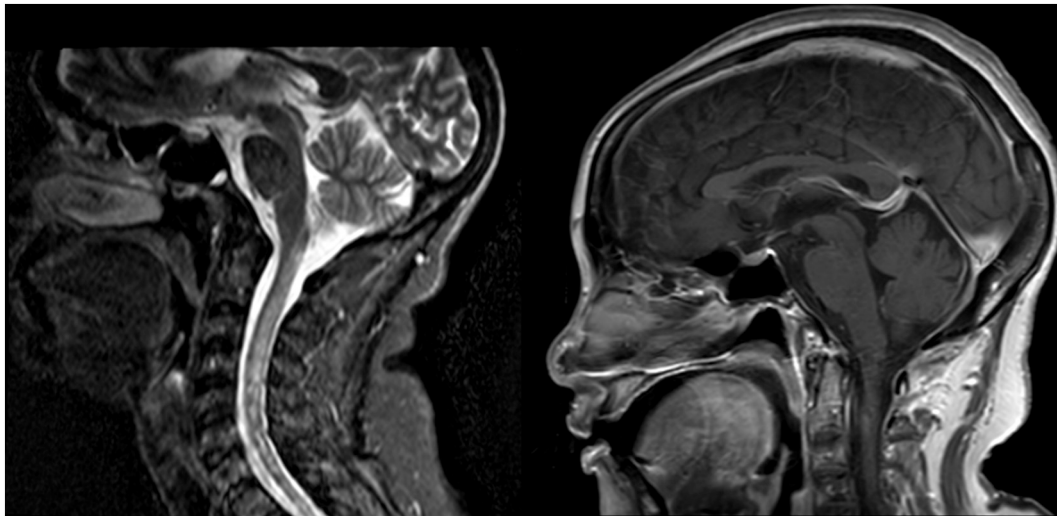


Fig. 4. Sagittal T2 with fat suppression (left image) and T1 with contrast (right image) MRI sequences of case 11 who presented with quadriplegia secondary to longitudinally extensive transverse myelitis.

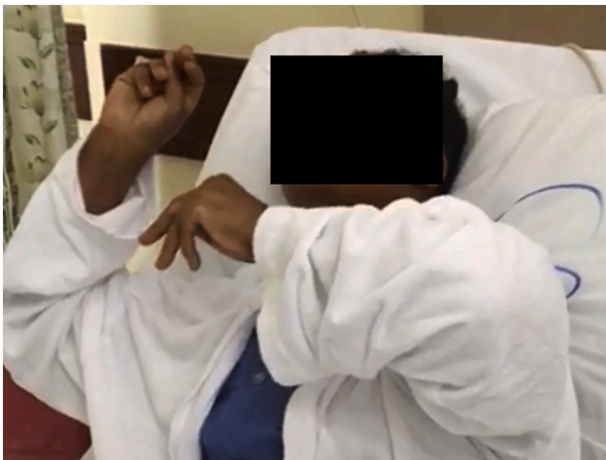

Fig. 5. Still of supplementary video 1 of case 5 demonstrating dystonic spasms pathognomonic of NMOSD.

other studies from Africa [13–17]. Similarly, ON and LETM were the most frequently reported symptoms at relapse presentation, with LETM being the most frequent overall (73%, and the Algerian cohort was 75% [17]), but the concomitant optico-spinal involvement i.e. classic Devic syndrome seemed to more prevalent in Morocco [13] and Senegal [16].

4.2. AQP4-IgG testing and status

AQP4-IgG seropositivity in our cohort was 64% (7/11), which is comparable to the range of 38% [17] to 62.5% [16] from African cohorts, although altogether much less when compared to 73–90% in international cohorts [28]. Two of the four seronegative patients (cases 9 and 11) fulfilled the clinical and radiological criteria for NMOSD diagnosis. The two remaining cases each had only one core clinical characteristic, but we included them in our cohort because: (i) both had NMOSD-concordant MRI findings; (ii) red flags for other differentials had been ruled out in the diagnostic workup; (iii) our laboratory only offers indirect immunofluorescence for detection of AQP4-IgG, which is known to be much less sensitive [29] than the cell-based assays recommended by the IPND (1); and (iv) both patients had monophasic illnesses, which are more likely to be seronegative when compared to those with established relapsing NMOSD [30]. Such risk stratification in

the absence of available and appropriate serology testing has been used in other African cohorts to justify immunosuppression e.g. 15.9% of the Algeria cases who did not fulfil the NMOSD criteria were put immunosuppression as they were deemed “high risk”.

MOG-Ab was not available at the time case 8 was last followed up, but was available for case 10 and it was negative, which again lends some support to NMOSD diagnosis. This lack of availability of diagnostic tests for NMOSD was shown in a recent survey, where Africa had the least accessibility to either AQP4-IgG or MOG-Ab testing [6]. The survey did not differentiate between the type of assay; whilst our institution does not have access to cell-based assays for AQP4-IgG, there is evidence that in some parts of Africa e.g. Egypt such assays are readily available [15]. This variable access to high-quality testing raises the question as to whether there needs to be an international effort to expand NMOSD diagnostics and make them more affordable, or whether to adjust the diagnostic criteria to cater for this chronic laboratory insufficiency in poorer countries. As a result of this study, we are in the process of identifying a laboratory that does provide cell-based assays for identifying AQP4-IgG antibodies, and will then recall the patients for retesting.

4.3. Impact of early neurologist review

One of our most important findings is the significant impact early involvement of a neurologist made to the timeline to diagnosis (average of 2.3 months from first presentation if seen by a neurologist first), number of relapses before diagnosis (1.3 vs 2.4 average relapses), and outcome of the patients as measured by EDSS (3.6 vs 5.4). Despite being the economic hub of the East Africa region, Kenya has only 18 neurologists for a population of 47 million, a neurology service gap that has been shown to be consistent across Africa [31]. The majority are based in the capital centre in institutions such as our regional referral hospital, which partly explains why 5/11 of our NMOSD cases did not see a neurologist at first presentation and led to the delayed diagnosis (7.4 months delay on average): three of these patients first presented with LETM but could not access a neurologist due to the towns they were living in (cases 6 and 7). Case 8 was seen by a neurosurgeon first because the MRI scan suggested a spinal cord tumour. One of the five patients (case 9) first presented with bilateral sequential ON but was managed on both occasions by an ophthalmologist who did not refer the patient forward, and then she had a devastating LETM relapse which led to her presentation to our hospital, from which she remained wheelchair-bound. Case 11 was admitted to the national public referral hospital

but was admitted under a physician first before being sent to the neurologist. Her diagnosis was made on clinical grounds after the second relapse with ON as she could not afford any investigations. Delays in diagnosis, which lead to delay in treatment, has been shown to be a significant factor contributing to long-term disability in NMOSD with a history of LETM [32], which explains why these patients in our cohort had a poorer outcome. Aside from increasing the neurology healthcare workforce in developing countries, simple measures such as standardised protocols for managing atypical ON and/or LETM have been shown to improve diagnoses rates, timely treatment, and overall outcomes in resource-poor settings for NMOSD patients [33], therefore national or regional guidelines for demyelinating diseases can mitigate some of the healthcare shortfalls highlighted by our cohort.

Case 3 was first seen by a neurologist but had the worst EDSS score of 7 when compared to the other five cases (average EDSS score 1.5) who were also seen by a neurologist at first presentation. This was because of a combinations of factors. Firstly, they were lost to follow-up after the second relapse which is when the AQP4-IgG was requested; the turn-around time for results from our referral laboratory is three weeks on average. The results came back positive but were not flagged up by our laboratory as AQP4-IgG does not feature as a critical result that requires verbal reporting to the attending clinician. We have logged this as a clinical incident and as a result our laboratory now has a protocol to have all positive AQP4-IgG results immediately telephoned to the neurologist in charge. Secondly, the patient self-referred to another neurologist outside our institution for a second opinion, and who was therefore not privy to her laboratory findings from the first two presentations. She was thus treated as a case of relapsing-remitting MS – a misdiagnosis that can happen in up to 40% of patients [24,30] – which may have contributed to her ongoing deterioration since it is now well established that disease-modifying drugs used in MS exacerbate NMOSD [34].

4.4. Concurrent CNS infections

It has been postulated that infections may be a trigger to the auto-immunity in NMOSD [35], and interestingly over half of AQP4-IgG seropositive patients in our cohort had a recent on concurrent infection, each of which have been reported to be associated with NMOSD onset: CNS tuberculosis in case 2 [36], HSV-2 in case 6 [37], and neurosyphilis in case 7 [35–38]. Case 1 had a sterile meningitis with no isolate; repeat CSF was only done 4 years later which was normal. Case 2 did not have CSF examination at presentation due to presence of pulmonary tuberculosis, and they were then lost to follow-up in the same year. Case 1 and 6 had lymphocytic CSF, and they declined follow-up CSF studies after their acute infections were treated. Case 8 had a lymphocytic CSF but negative microbiology and serology studies that excluded concurrent infection; treatment for NMOSD led to good outcome long-term and the attending clinician therefore decided against repeat CSF.

All acute neurology admissions at our institution are tested for infection by human immunodeficiency virus (HIV) as per a previously published protocol [39], but none of the NMOSD patients had concurrent HIV infection. There is some evidence from the South African cohort that post-infectious auto-immunity plays a role in NMOSD pathogenesis in HIV-infected patients, who tend to have more tumefactive CNS lesions [20].

4.5. Treatment of NMOSD

All acute relapses were treated with IVMP followed by a tapering dose of oral steroids, which is in keeping with what is practiced internationally [5,40] including in Africa [16,21]. All patients were also commenced on immunosuppression, with mycophenolate and azathioprine being used in the majority of cases as is recommended by NMOSD treatment guidelines [5], chiefly because of their affordability and

availability. In other African cohorts, cyclophosphamide is used more often [14,15], which we tend to avoid given the implications to fertility in a female-predominant disease. Rituximab is generally expensive and not easily available, and was only used in the management of case 8 as they did not like to daily tablets; it is used more frequently for NMOSD in other parts of Africa especially Egypt [15]. Only one patient (case 7) had a relapse due to non-compliance with the oral steroids and mycophenolate.

5. Conclusions

We have described the largest indigenous case series of NMOSD from the East Africa region. The demography in terms of gender and age were similar to other NMOSD cohorts reported internationally, but there were also some unique differences within our cases, mainly that majority of the sero-positive patients had other CNS infections, suggesting para-infectious pathogenesis. Documenting the patient journey from symptom onset to outcomes elucidated specific challenges: variable access to appropriate and affordable diagnostic testing, especially for cell-based assays to detect AQP4-IgG, and suboptimal availability of, and referral to, a neurologist at onset of the disease which is a very modifiable risk factor. Delayed and incorrect diagnoses negatively impacted on patient outcomes in terms of disability, which has implications on how neurology-specific healthcare infrastructure should be aligned and developed in order to improve the management of conditions such as NMOSD in relatively resource-poor settings.

Supplementary data to this article can be found online at <https://doi.org/10.1016/j.ensci.2021.100320>.

Data statement

The clinical information and imaging data used to support the findings of this study are included within the article. According to our institutional information governance regulations, the anonymised data can be requested from the corresponding author.

Funding source

This research did not receive any specific grant from funding agencies in the public, commercial, or not-for-profit sectors.

Declarations of interest

None.

Acknowledgements

The authors would like to acknowledge the help of Dr. Sheila Waa, consultant neuro-radiologist at the Aga Khan University Hospital, Nairobi, for providing the neuro-imaging pictures for the purposes of drafting this manuscript

References

- [1] D.M. Wingerchuk, B. Banwell, J.L. Bennett, P. Cabre, W. Carroll, T. Chitnis, et al., International consensus diagnostic criteria for neuromyelitis optica spectrum disorders, *Neurology*. 85 (2) (2015) 177–189.
- [2] S.H.M. Hamid, D. Whittam, K. Mutch, S. Linaker, T. Solomon, K. Das, et al., What proportion of AQP4-IgG-negative NMO spectrum disorder patients are MOG-IgG positive? A cross sectional study of 132 patients, *J. Neurol.* 264 (10) (2017) 2088–2094.
- [3] M. Jurynczyk, S. Messina, M.R. Woodhall, N. Raza, R. Everett, A. Roca-Fernandez, et al., Clinical presentation and prognosis in MOG-antibody disease: a UK study, *Brain*. 140 (12) (2017) 3128–3138.
- [4] M. Jurynczyk, A. Jacob, K. Fujihara, J. Palace, Myelin oligodendrocyte glycoprotein (MOG) antibody-associated disease: practical considerations, *Pract. Neurol.* 19 (3) (2019) 187–195.
- [5] J. Palace, M.I. Leite, A. Jacob, A practical guide to the treatment of neuromyelitis optica, *Pract. Neurol.* 12 (4) (2012) 209–214.

- [6] K. Holroyd, A. Vogel, K. Lynch, B. Gazdag, M. Voghel, N. Alakel, et al., Neuromyelitis optica testing and treatment: availability and affordability in 60 countries, *Mult. Scler. Relat. Disord.* 33 (2019) 44–50.
- [7] G.I. Ogbole, A.O. Adeyomoye, A. Badu-Pepurah, Y. Mensah, D.A. Nzeh, Survey of magnetic resonance imaging availability in West Africa, *Pan. Afr. Med. J.* 30 (2018) 240.
- [8] M.P. Alvarenga, S. Schmidt, R.P. Alvarenga, Epidemiology of neuromyelitis optica in Latin America, *Mult. Scler. J. Exp. Transl. Clin.* 3 (3) (2017), 2055217317730098.
- [9] R.A. Marrie, C. Gryba, The incidence and prevalence of neuromyelitis optica: a systematic review, *Int. J. MS Care.* 15 (3) (2013) 113–118.
- [10] J.Y. Hor, T.T. Lim, Y.K. Chia, Y.M. Ching, C.F. Cheah, K. Tan, et al., Prevalence of neuromyelitis optica spectrum disorder in the multi-ethnic Penang Island, Malaysia, and a review of worldwide prevalence, *Mult. Scler. Relat. Disord.* 19 (2018) 20–24.
- [11] W. Bukhari, K.M. Prain, P. Waters, M. Woodhall, C.M. O’Gorman, L. Clarke, et al., Incidence and prevalence of NMOSD in Australia and New Zealand, *J. Neurol. Neurosurg. Psychiatry* 88 (8) (2017) 632–638.
- [12] N. Kissani (Ed.), *Epidémiologie de la NMO en Afrique et dans le monde Le 3eme Congres De La Société Ivoirienne de Neurologie et la 3eme Conference Africaine Sur La Neuromyelite Optique (NMO)*, 2019 (Abidjan, COTE D’IVOIRE).
- [13] A. Bennis, H. El Otmani, N. Benkirane, I. Harrizi, B. El Moutawakil, M.A. Rafai, et al., Clinical course of neuromyelitis optica spectrum disorder in a moroccan cohort, *Mult. Scler. Relat. Disord.* 30 (2019) 141–148.
- [14] S. Salama, H. Marouf, M. Ihab Reda, A.R. Mansour, E.L. O, M. Levy, Clinical and radiological characteristics of neuromyelitis optica spectrum disorder in the north Egyptian Nile Delta, *J. Neuroimmunol.* 324 (2018) 22–25.
- [15] N.A.W. Kishk, N. Shalaby, A.H. Ragab, H. Shehata, A. Hassan, M. Hegazy, N. Abokresha, A.D. Doaa, S. Shawky, A. Elmazny, S. Sherif, A.M. Fouad, Demographics and clinical characteristics of Neuromyelitis Optica and Neuromyelitis Optica Spectrum Disorder in Egypt: first retrospective longitudinal study in a tertiary referral centre, *ECTRIMS Online Libr.* 278339 (2019) (P1137).
- [16] N.M. Gaye, M. Fall, A.M. Diop, S.M.L. Dadah, M. Ka, O. Cisse, et al., Neuromyelitis optica spectrum disorders (NMO-SD) in a sub-Saharan Africa country: a preliminary study of sixteen Senegalese cases, *Mult. Scler. Relat. Disord.* 27 (2019) 179–183.
- [17] S. Daoudi, M. Bouzar, Neuromyelitis optica spectrum disorders in Algeria: a preliminary study in the region of Tizi Ouzou, *Mult. Scler. Relat. Disord.* 6 (2016) 37–40.
- [18] H. Assadek, M. Toudou Daouda, E. Adehossi Omar, Z. Mamadou, F. Hassane Djibo, D. Douma Maiga, Inflammatory demyelinating diseases of the central nervous system in Niger, *Rev. Neurol. (Paris)* 175 (4) (2019) 261–268.
- [19] C.Y.-E.C. Kadjo, J. Kouakou, A. Loungou, C. Tanoh, R. Béné, M. Amon-Tanoh, D. E. Aka-Anghui, B. Assi, Devic’s optica neuromyelitis (NMOSD) in ivory coast: a second confirmed case report, *Afr. J. Neurol. Sci.* 38 (1) (2019).
- [20] A.I. Bhigjee, A.A. Moodley, I. Roos, C.L. Wells, P. Ramdial, M. Esser, The neuromyelitis optica presentation and the aquaporin-4 antibody in HIV-seropositive and seronegative patients in KwaZulu-Natal, South Africa, *South Afr. J. HIV Med.* 18 (1) (2017) 684.
- [21] M. Kaddumukasa, A. Musubire, M. Kaddumukasa, S. Matovu, E. Katabira, Neuromyelitis optica in a Ugandan woman: a case report, *J. Med. Case Rep.* 7 (2013) 177.
- [22] E.P. Flanagan, P. Cabre, B.G. Weinschenker, J.S. Sauver, D.J. Jacobson, M. Majed, et al., Epidemiology of aquaporin-4 autoimmunity and neuromyelitis optica spectrum, *Ann. Neurol.* 79 (5) (2016) 775–783.
- [23] M. Storoni, S.J. Pittock, B.G. Weinschenker, G.T. Plant, Optic neuritis in an ethnically diverse population: higher risk of atypical cases in patients of African or African-Caribbean heritage, *J. Neurol. Sci.* 312 (1–2) (2012) 21–25.
- [24] M.A. Mealy, D.M. Wingerchuk, B.M. Greenberg, M. Levy, Epidemiology of neuromyelitis optica in the United States: a multicenter analysis, *Arch. Neurol.* 69 (9) (2012) 1176–1180.
- [25] Y.D. Frago, N.A.C. Sousa, S.V. Alves-Leon, R.M. Dias, M.L.V. Pimentel, S. Gomes, et al., Clinical characteristics of 153 Brazilian patients with neuromyelitis optica spectrum disorder (NMOSD), *Mult. Scler. Relat. Disord.* 27 (2019) 392–396.
- [26] D. Sokhi, I. Jamal, P. Mativo, J. Hooker, M. Wallin, Diagnostic audit of the largest cohort of multiple sclerosis cases in Kenya referred to a tertiary hospital in Nairobi, *J. Neurol. Sci.* 381 (2017) 1061.
- [27] D. Weerasinghe, C. Lueck, Mimics and chameleons of optic neuritis, *Pract. Neurol.* 16 (2) (2016) 96–110.
- [28] S.H. Hamid, L. Elson, K. Mutch, T. Solomon, A. Jacob, The impact of 2015 neuromyelitis optica spectrum disorders criteria on diagnostic rates, *Mult. Scler.* 23 (2) (2017) 228–233.
- [29] P.J. Waters, S.J. Pittock, J.L. Bennett, S. Jarius, B.G. Weinschenker, D. M. Wingerchuk, Evaluation of aquaporin-4 antibody assays, *Clin. Exp. Neuroimmunol.* 5 (3) (2014) 290–303.
- [30] S. Jarius, K. Ruprecht, B. Wildemann, T. Kuempfel, M. Ringelstein, C. Geis, et al., Contrasting disease patterns in seropositive and seronegative neuromyelitis optica: a multicentre study of 175 patients, *J. Neuroinflammation* 9 (2012) 14.
- [31] WHO, Atlas: Country Resources for Neurological Disorders, 2nd Edition, WHO/WFN, 2017.
- [32] M.A. Mealy, S.E. Mossburg, S.H. Kim, S. Messina, N. Borisow, R. Lopez-Gonzalez, et al., Long-term disability in neuromyelitis optica spectrum disorder with a history of myelitis is associated with age at onset, delay in diagnosis/preventive treatment, MRI lesion length and presence of symptomatic brain lesions, *Mult. Scler. Relat. Disord.* 28 (2019) 64–68.
- [33] L. Pandit, S. Mustafa, R. Kunder, R. Shetty, Z. Misri, S. Pai, et al., Optimizing the management of neuromyelitis optica and spectrum disorders in resource poor settings: experience from the Mangalore demyelinating disease registry, *Ann. Indian Acad. Neurol.* 16 (4) (2013) 572–576.
- [34] S.H. Kim, W. Kim, X.F. Li, I.J. Jung, H.J. Kim, Does interferon beta treatment exacerbate neuromyelitis optica spectrum disorder? *Mult. Scler.* 18 (10) (2012) 1480–1483.
- [35] X. Zhong, Y. Zhou, T. Lu, Z. Wang, L. Fang, L. Peng, et al., Infections in neuromyelitis optica spectrum disorder, *J. Clin. Neurosci.* 47 (2018) 14–19.
- [36] N. Brey, F. Henning, Relapsing neuromyelitis optica temporally related to recurrent pulmonary tuberculosis, *Int. J. Tuberc. Lung Dis.* 18 (5) (2014) 632–633.
- [37] I.V. Marin Collazo, C.L. Howe, C.F. Lucchinetti, W.O. Tobin, Neuromyelitis Optica and herpes simplex virus 2: a viral trigger for Aquaporin-4 autoimmunity? *Neurologist.* 23 (3) (2018) 92–93.
- [38] R.A. Wilcox, J. Burrow, M. Slee, J. Craig, D. Thyagarajan, Neuromyelitis optica (Devic’s disease) in a patient with syphilis, *Mult. Scler.* 14 (2) (2008) 268–271.
- [39] D.S. Sokhi, C. Oxenham, R. Coates, M. Forbes, N.K. Gupta, D.J. Blackburn, Four-stage audit demonstrating increased uptake of HIV testing in acute neurology admissions using staged practical interventions, *PLoS One* 10 (9) (2015), e0134574.
- [40] I. Kleiter, A. Gahlen, N. Borisow, K. Fischer, K.D. Wernecke, B. Wegner, et al., Neuromyelitis optica: evaluation of 871 attacks and 1,153 treatment courses, *Ann. Neurol.* 79 (2) (2016) 206–216.