

ASPECTS OF MONOCLONAL ANTIBODY TECHNOLOGY
IN DIAGNOSIS AND THERAPY OF NEOPLASTIC MENINGITIS

ROBIN PETER MOSELEY BSc MB BS MRCP FRCS

THESIS SUBMITTED FOR THE DEGREE OF MD

UNIVERSITY COLLEGE, LONDON. 1990

ProQuest Number: 10797745

All rights reserved

INFORMATION TO ALL USERS

The quality of this reproduction is dependent upon the quality of the copy submitted.

In the unlikely event that the author did not send a complete manuscript and there are missing pages, these will be noted. Also, if material had to be removed, a note will indicate the deletion.



ProQuest 10797745

Published by ProQuest LLC (2018). Copyright of the Dissertation is held by the Author.

All rights reserved.

This work is protected against unauthorized copying under Title 17, United States Code
Microform Edition © ProQuest LLC.

ProQuest LLC.
789 East Eisenhower Parkway
P.O. Box 1346
Ann Arbor, MI 48106 – 1346

DEDICATION

TO MY WIFE CATHERINE IN RECOGNITION OF
HER LOVE AND UNFAILING SUPPORT.

ABSTRACT

This study includes an introductory review of current diagnostic, clinical and therapeutic aspects of neoplastic meningitis. Emphasis is placed on the importance of early detection of leptomeningeal tumour, as current therapeutic strategies are more effective against minimal disease. The enhancement of conventional diagnostic cytology by the addition of monoclonal antibody immunocytochemistry is discussed and, subsequently illustrated in a study of 12 patients with neoplastic meningitis. The use of monoclonal antibodies in radioimmunoassay methods is then demonstrated by the development of an immunoradiometric assay for the detection of Polymorphic Epithelial Mucin (PEM) in cerebrospinal fluid (CSF). This high molecular weight glycoprotein has not been previously assayed for in CSF and its potential value as a new diagnostic biochemical marker for carcinomatous meningitis is assessed. Finally, in a study of 15 patients with neoplastic meningitis, the potential therapeutic application of monoclonal antibodies as vectors of targeted radiation is explored. Monoclonal antibodies labelled with I-131 were administered directly into ventricular CSF, and demonstrable therapeutic responses were seen in 3/15 patients. Toxicity was seen in the form of bone marrow suppression in 3/15 patients and epilepsy in 2/15 patients.

ACKNOWLEDGEMENTS

I would like to thank Mr Hugh Coakham for his continued support and trust. Also Dr Michael Zalutsky for his significant contribution to the development of radiochemical methodology employed in this study. I thank Nicky Sullivan for her high standard of technical assistance in immunocytochemical and radioimmunoassay studies. Thanks are also due to Janet Wheeler and Wendy Fielden for providing the gamma camera service. I am also grateful to Dr Tim Moss and Dr Seth Love for their permission to photograph material from the department of Neuropathology. In addition, Caroline Plaice and Sheila Headford provided the excellent library facilities required for creation of this thesis. Monoclonal antibodies were kindly donated by Dr Joy Burchell, Dr Joyce Taylor-Papadimitriou and Professor Darell Bigner. Finally I would like to express my gratitude to Sally Normanton for her untiring efforts in the preparation of this manuscript. This work was generously funded by the Preuss Research Foundation, the Imperial Cancer Research Fund and the Bristol Brain Tumour Research Fund.

ABBREVIATIONS

- PBS - Phosphate Buffered Saline
- TCA - Trichloroacetic Acid
- TBS - Tris Buffered Saline
- CSF - Cerebrospinal Fluid
- CNS - Central Nervous System
- CT - Computerised Tomography
- HAMA - Human Anti-Mouse Activity
- DTPA - Diethylene-Triamine-Penta-Acetic Acid

CONTENTS

	Page
Title Page	1
Dedication	2
Abstract	3
Acknowledgements	4
Abbreviations	5
Contents	6
Chapter 1. Introduction	10
1.1 Neoplastic Meningitis: Definitions	11
1.2 Historical Review	13
1.3 Epidemiology	15
1.4 Clinical Perspective	17
1.5 Pathology	25
1.6 Pathogenesis	32
1.7 Diagnostic Cytology	35
1.8 Cerebrospinal Fluid Tumour Markers	43
1.9 Aspects of Therapy	50
1.10 Central Nervous System Prophylaxis	60
1.11 Neurotoxicity	64
1.12 Outline of Present Study	67
Chapter 2. General Techniques	69
2.1 Materials	70
2.2 Monoclonal Antibodies	71
2.3 Radiolabelling	76
2.4 Radioactivity Measurement	77

	Page
2.5 Quality Control of Radioimmunoconjugate	79
2.5.1 Trichloroacetic Acid (TCA) Precipitation	79
2.5.2 Gel Filtration Chromatography	79
2.5.3 Radiobinding Assay Techniques	82
Chapter 3. Diagnostic Cytology	86
3.1 Introduction	87
3.2 Methods	88
3.2.1 Patients	88
3.2.2 Monoclonal Antibodies	88
3.2.3 CSF Cytology	88
3.3 Results	91
3.4 Discussion	118
Chapter 4. Carcinomatous Meningitis: Diagnosis by Radioimmunoassay	120
4.1 Introduction	121
4.2 Methods	123
4.2.1 Patients	123
4.2.2 Mucin Immunoradiometric Assay Technique	125
4.3 Results	137
4.4 Discussion	142

	Page
Chapter 5. Neoplastic Meningitis: Treatment by Antibody Guided Radiation	148
5.1 Introduction	149
5.2 Methods	151
5.2.1 Patient Selection	151
5.2.2 Antibody Selection	151
5.2.3 Preparation of Radioimmunoconjugates	152
5.2.4 Patient Preparation and Administration of Immunoconjugate	152
5.2.5 Imaging	153
5.2.6 Pharmacokinetics	153
5.2.7 In Vitro Studies of Immune Complex Formation in Serum and CSF	154
5.2.8 Dosimetry	156
5.2.9 Detection of Human Anti-Mouse Activity (HAMA)	157
5.2.10 Evaluation of Clinical Response	160
5.3 Results	161
5.3.1 Patient Selection	161
5.3.2 Preparation and Quality Control of Radioimmunoconjugates	161
5.3.3 Biodistribution of Radioimmunoconjugate: Immunoscintigraphy	166
5.3.4 Pharmacokinetics: Blood Vascular Compartment	182
5.3.5 Pharmacokinetics: CSF	188
5.3.6 In Vitro Studies of Immune Complex Formation in Serum and CSF	192

	Page
5.3.7 Toxicity	192
5.3.8 Bone Marrow Dosimetry	194
5.3.9 Human Anti-Mouse Activity (HAMA)	197
5.3.10 Clinical Responses	200
5.4 Discussion	204
5.4.1 Selection of Monoclonal Reagents	204
5.4.2 Biological Activity of Immunoconjugate	204
5.4.3 Plasma Pharmacokinetics	205
5.4.4 CSF Pharmacokinetics	209
5.4.5 Studies of Iodinated Molecular Species	209
5.4.6 Immunoscintigraphy	210
5.4.7 Bone Marrow Dosimetry	213
5.4.8 Toxicity	216
5.4.9 Human Anti-Mouse Response to Therapy	218
5.4.10 Clinical Responses	220
 Chapter 6. Current Problems and Future Strategies	 222
 References	 228

CHAPTER 1

INTRODUCTION

1.1 NEOPLASTIC MENINGITIS: DEFINITIONS

Neoplastic meningitis is characterised by diffuse or multifocal infiltration of the leptomeninges by malignant tumour (Fig. 1.1). The disorder is essentially a metastatic manifestation of malignant disease, although occasional examples of primary neoplasia of leptomeningeal tissue have been reported (Garbes, 1983; Thibodeau et al., 1988). Neoplastic meningitis most commonly complicates systemic malignancy (Bigner and Johnston, 1984), but also frequently arises from meningeal dissemination of primary neuroectodermal tumours (Polmeteer and Kernohan, 1947; McFarland et al., 1969; Allen and Epstein 1982; Rorke, 1983; Ushio et al., 1987).

The term "neoplastic meningitis" encompasses all forms of malignant meningeal neoplasia. The term "carcinomatous meningitis" should be restricted to that form of meningeal neoplasia arising from systemic carcinoma. It is incorrectly used in referral to meningeal neoplasia arising from malignancies other than carcinomas. Less frequently used terminology such as leukaemic, lymphomatous or melanomatous meningitis is acceptable when referring to specific forms of neoplastic meningitis.

Fig. 1.1

Diffuse infiltration of cerebral leptomeninges by malignant melanoma.
Immunoperoxidase staining with monoclonal antibody NKI/C3 (x500).




Fig. 1.1

1.2 HISTORICAL REVIEW

The first report of infiltrative tumour growth within the subarachnoid space was probably that of Eberth, who described classical pathological features of carcinomatous meningitis in a patient with lung carcinoma (Eberth, 1870). He did not however, recognise the metastatic nature of the meningeal lesion and attributed it to an unassociated co-existing "endothelioma" of the meninges. The entity was well established however, by the turn of the century (Saenger, 1900; Lilienfeld and Benda, 1901) and Siefert introduced the term "Meningitis carcinomatosa" (Siefert, 1902).

Lilienfeld and Benda (1901) described a patient with carcinoma of the stomach presenting with progressive neurological deficit, in whom extensive carcinoma of the leptomeninges was noted in the absence of underlying disease of the brain parenchyma (Lilienfeld and Benda, 1901). Similar reports of pathologically confirmed "pure leptomeningeal carcinomatosis" in the absence of parenchymal disease soon followed (Rehn 1906). In 1907, Spiller is credited with the first well documented case of neoplastic meningitis arising from dissemination of a primary neuroectodermal tumour. He described diffuse meningeal neoplasia complicating an ependymoma of the fourth ventricle (Spiller, 1907). In 1912, Beerman reported an additional case of carcinomatous meningitis and introduced the term "meningeal carcinomatosis" as opposed to the term "meningitis carcinomatosa" which was prevalent in the German literature (Beerman, 1912). His patient died following a progressive illness involving headaches, hallucinations and dysphasia. Post-mortem examination was not

exhaustive as malignant disease was not suspected and no primary neoplasm was found. The brain appeared entirely normal and it was only several months later that routine microscopic examination was performed. This revealed carcinomatous meningitis in the absence of demonstrable tumour involvement of the underlying brain parenchyma. Beerman's report emphasized the presence of extensive carcinomatous meningitis seen microscopically in the absence of macroscopic disease. Subsequently, numerous reports have appeared describing a variety of clinical presentations and emphasizing the rarity of the disorder.

Bertrand and Aronson (1921) described a patient with headache, seizures and rapid onset of blindness. Although they considered the pathology as primary neoplasia of the meninges, this was undoubtedly a secondary invasion (Bertrand and Aronson, 1921). Walshe (1923) described a woman whose physical signs were confined to the left eye - sixth nerve palsy, blindness and primary optic atrophy. At autopsy a primary tumour was not found, but the basal leptomeninges and cranial nerve roots were infiltrated by an adenocarcinoma, thought to be derived from gut (Walshe, 1923). Greenfield (1938) described a patient with bronchial carcinoma who presented with dementia. Autopsy revealed extensive neoplastic meningitis with infiltration of cerebral parenchyma along perivascular spaces (Greenfield, 1938). The case of Alpers and Smith (1938) was notable for severe infiltration of the spinal meninges with relative sparing of the intracranial meninges. The authors remarked on the improbability of a haematogenous metastatic mechanism accounting for this asymmetry of neuraxial distribution (Alpers and Smith, 1938). In 1951, Madow and Alpers described four cases in which perivascular tumour infiltration was

notably prominent and introduced the term "carcinomatous encephalitis" (Madow and Alpers, 1951). The first major reviews of the literature were published in 1955 (Fischer-Williams et al., 1955; Grain and Karr, 1955). These authors addressed the clinical and pathological characteristics of neoplastic meningitis, and also discussed mechanisms of meningeal dissemination and the incidence of various primary neoplasms as the cause of the disorder. Subsequent reports have detailed refinements of diagnostic cytology (Marks and Marrack, 1960) and relationships of hypoglycorrhachia to meningeal neoplasia (Fishman, 1963; De Vita, 1966). The most extensive pathological review of leptomeningeal neoplasia was that of Olson in 1974 (Olson et al., 1974). The majority of recent accessions to the literature have discussed the therapeutic challenge of neoplastic meningitis and the use of intrathecally administered pharmacological reagents (Wasserstrom et al., 1982; Yap et al., 1982; Ongerboer de Visser et al., 1983; Lashford et al., 1988).

1.3 EPIDEMIOLOGY

The incidence of neoplastic meningitis is largely unknown, but is being increasingly recognised as a cause of neurological disability in cancer patients (Seeldrayers and Hildebrand 1984). In addition to greater awareness of this complication, this increase has been attributed to the use of systemic chemotherapeutic agents with poor penetration of the blood/brain barrier. This has effectively controlled progression of systemic disease with consequent prolonged survival, but malignant cells within the pharmacological sanctuary of the central nervous system have continued to proliferate (Aroney et

al., 1981). Increased leptomeningeal neoplasia was initially shown to follow prolonged survival in leukaemias and lymphomas (Evans et al., 1970; Griffin et al., 1971; Wolk et al., 1974), and subsequently has been reported in breast (Yap et al., 1978), ovarian (Mayer et al., 1978) and small cell lung carcinoma (Aisner et al., 1979), reflecting improved survival in this group of solid tumours.

Apart from primary neuroectodermal tumours and haemopoietic malignancies, other tumours that commonly lead to leptomeningeal spread include primary lesions of lung (Balducci et al., 1984), breast (Yap et al., 1978), gastro-intestinal tract (Meissner, 1953) and malignant melanoma (Amer et al., 1978). The distribution of primary tumours differs somewhat in various published series. Gastric carcinoma was the prominent cause of neoplastic meningitis in the earlier literature (Beerman, 1912; Jacobs and Richland, 1951; Spriggs, 1954; Grain and Karr, 1955), but is now implicated much less frequently (Olson et al., 1974). Lung and breast carcinomas have been the most common primary tumours causing neoplastic meningitis in all recent large published series (Olson et al., 1974; Little et al., 1974; Gonzalez-Vitale and Garcia-Bunuel, 1976; Wasserstrom et al., 1982). The change in incidence of primary tumour site may reflect true change in incidence of the primary tumour, but can also be accounted for by the development of new therapeutic strategies. The declining incidence of gastric carcinoma in the western hemisphere undoubtedly accounts for its less frequent implication in leptomeningeal neoplasia. In contrast, the incidence of leptomeningeal leukaemia increased dramatically with the advent of effective systemic chemotherapy, and was reported to occur in over 50%

of patients (Evans et al., 1970; Aur et al., 1972). Following the use of prophylactic therapy to the central nervous system, the incidence of leptomeningeal leukaemia has now declined and less than 10% of patients with ALL now develop this complication (Green et al., 1980; Sullivan et al., 1982).

Unusual causes of neoplastic meningitis are cited in most large series (Olson et al., 1974; Wasserstrom et al., 1982) and numerous case reports provide further examples of great rarity. These include cervical carcinoma (Weithman et al., 1987), basal cell carcinoma (Soffer et al., 1985), carcinoid tumour (Nagourney et al., 1985), myeloma (Sato et al., 1985), gall-bladder carcinoma (Naylor et al., 1988) and thymoma (Kleinert et al., 1985).

1.4 CLINICAL PERSPECTIVE

As neoplastic meningitis may involve the entire neuraxis, clinical features may be related to any part of the central nervous system. Consequently, infinite permutations of clinical presentation may occur, which are reflected in the numerous case reports describing the bizarre and unusual (McCrary et al., 1986; Sozzi et al., 1987; Broderick and Cascino, 1987). Leptomeningeal neoplasia is often only recognised at autopsy and difficulties in antemortem diagnosis have been attributed to the lack of localising signs and the protean nature of the disease (Fischer-Williams et al., 1955). However, with a high index of suspicion, it is the diversity of symptoms and multifocal findings that can lead to the diagnosis. Even when patients' complaints are unifocal, careful neurological examination may reveal

signs referable to multiple and widespread areas of the neuraxis (Olson et al., 1974; Posner, 1979).

The underlying pathological mechanisms of symptoms and signs in neoplastic meningitis remain unclear. Focal brain, spinal cord and nerve root dysfunction may arise from direct parenchymal invasion, obliteration of leptomeningeal vessels with consequent ischaemia or derangement of tissue metabolism (Olson et al., 1974). Hydrocephalus may present as a generalised cerebral dysfunction, and results from tumour obliteration of the subarachnoid space (Little et al., 1974; Wasserstrom et al., 1982).

Cerebral dysfunction may be suggested by dysphasia, coma, seizures, intellectual deterioration, hemiparesis, gait ataxia and papilloedema. Signs of cerebral dysfunction were reported in 42 of 90 patients in Wasserstrom's series (Wasserstrom et al., 1982), but more sensitive neuropsychological testing may reveal a significantly higher incidence (Siegal et al., 1985). Signs of meningeal irritation are often noted for their absence, but when present, appear to reflect the inflammatory response of the leptomeninges to tumour infiltration and are then commonly associated with a raised white blood count in the CSF (Olson et al., 1974).

Cranial nerve dysfunction is very frequently in evidence at presentation with neoplastic meningitis (Olson et al., 1974; Yap et al., 1978; Wasserstrom et al., 1982). Visual failure (Altrocchi et al., 1972), partial or complete ophthalmoplegia, facial weakness and numbness, dysarthria, hearing loss, tinnitus and dysphagia are common

abnormalities demonstrated (Yap et al., 1978; Theodore and Gendelman, 1981; Wasserstrom et al., 1982).

Spinal nerve root involvement is manifested as symptoms of limb weakness, paresthesiae, pain and sphincter dysfunction. Demonstrable limb weakness is often accompanied by sensory loss and reflex asymmetry. A significant percentage of patients present only with spinal root symptoms (Olson et al., 1974) and approximately 70% of patients have been reported to show signs of spinal root involvement at initial examination (Wasserstrom et al., 1982).

Earlier reports tended to exclude cases in which meningeal involvement was associated with discrete focal parenchymal metastases (Jacobs and Richland, 1951), but more recent authors have not differentiated between pure and complicated cases. The latter view is supported by the inability of most practitioners to distinguish between these forms of the disease on clinical criteria alone (Grain and Karr, 1955; Wasserstrom et al., 1982).

Although the primary tumour site is already known in the majority of patients, neoplastic meningitis may occasionally occur as the initial clinical manifestation of malignant disease (Bigner and Johnston, 1981; Bigner and Johnston, 1984; Heimann and Merino, 1986; McCrary et al., 1986; Csako and Chandra, 1986). This is seen most frequently with neoplasms exhibiting a short latency period between initial diagnosis and subsequent meningeal spread (Bigner and Johnston, 1984; Csako and Chandra, 1986). The interval between initial primary tumour diagnosis and onset of leptomeningeal neoplasia depends on the site

and histological type of primary neoplasm (Ehya et al., 1981). The interval is shortest in patients with carcinoma of the urinary bladder and lung (9 and 11 months respectively) and longest in patients with breast carcinoma and malignant melanoma (52 months). With regard to the histological type of primary neoplasm, small cell carcinoma of lung disseminates the leptomeninges early (average 8 months), in contrast to bronchioloalveolar carcinoma which has a long clinical interval (41 months) (Ehya et al., 1981). The histological type also has bearing on the propensity for meningeal spread as evidenced by the predominance of adenocarcinoma in most series of neoplastic meningitis (Stam, 1960; Dinsdale and Taghavy, 1964; El-Batata, 1968; Little et al., 1974).

The demonstration of malignant cells in the CSF is usually required to establish the diagnosis of neoplastic meningitis. Leptomeningeal neoplasia is often accompanied by a lymphocytic or polymorphonuclear leucocytosis with raised levels of CSF protein and lowered CSF glucose (Morganroth et al., 1972; Van Zanten et al., 1988b). However, these non-specific abnormalities of CSF are also characteristic of many inflammatory meningitides and not pathognomonic of neoplasm (Hughes et al. 1963; Little et al., 1974). It is also well recognised that the cellular, protein and glucose content of CSF may be entirely normal in the presence of extensive meningeal neoplasia (Olson et al., 1974). These non-specific parameters of meningeal disease are therefore of limited diagnostic value in neoplastic meningitis (Yap et al., 1978). More specific biochemical markers of meningeal neoplasia include beta-glucuronidase, beta-2-microglobulin, carcinoembryonic antigen and isoenzymes of lactate dehydrogenase (Schold et al., 1980). Although

useful in certain circumstances, clinical application has not been universal and their role in diagnosis and therapy has yet to be established.

Other investigations, whilst not diagnostic, are often helpful. Electroencephalography is abnormal in over 50% of patients with neoplastic meningitis and may correlate with deteriorating mental status and raised intracranial pressure (Olson et al., 1974; Yap et al., 1978). Both contrast-enhanced cranial CT scanning and myelography are relatively insensitive in detecting neoplastic meningitis (Olson et al., 1974; Enzmann et al., 1978; Ascherl et al., 1981). However, occasionally intra-arachnoid tumour nodules are visualised (Fig. 1.2) by these methods in the absence of positive exfoliative cytology (Wasserstrom et al., 1982; Pedersen et al., 1985). Abnormal CT findings indicative of leptomeningeal metastases include sulcal-cisternal enhancement, ependymal enhancement, irregular tentorial enhancement and hydrocephalus (Lee et al., 1984). Myelographic abnormalities include intra-arachnoid nodular filling defects, longitudinal striations, prominent and crowded nerve roots of the cauda equina and scalloping of the subarachnoid space (Kim et al., 1982).

Fig. 1.2

Water soluble contrast myelography showing intradural tumour deposits
of medulloblastoma.

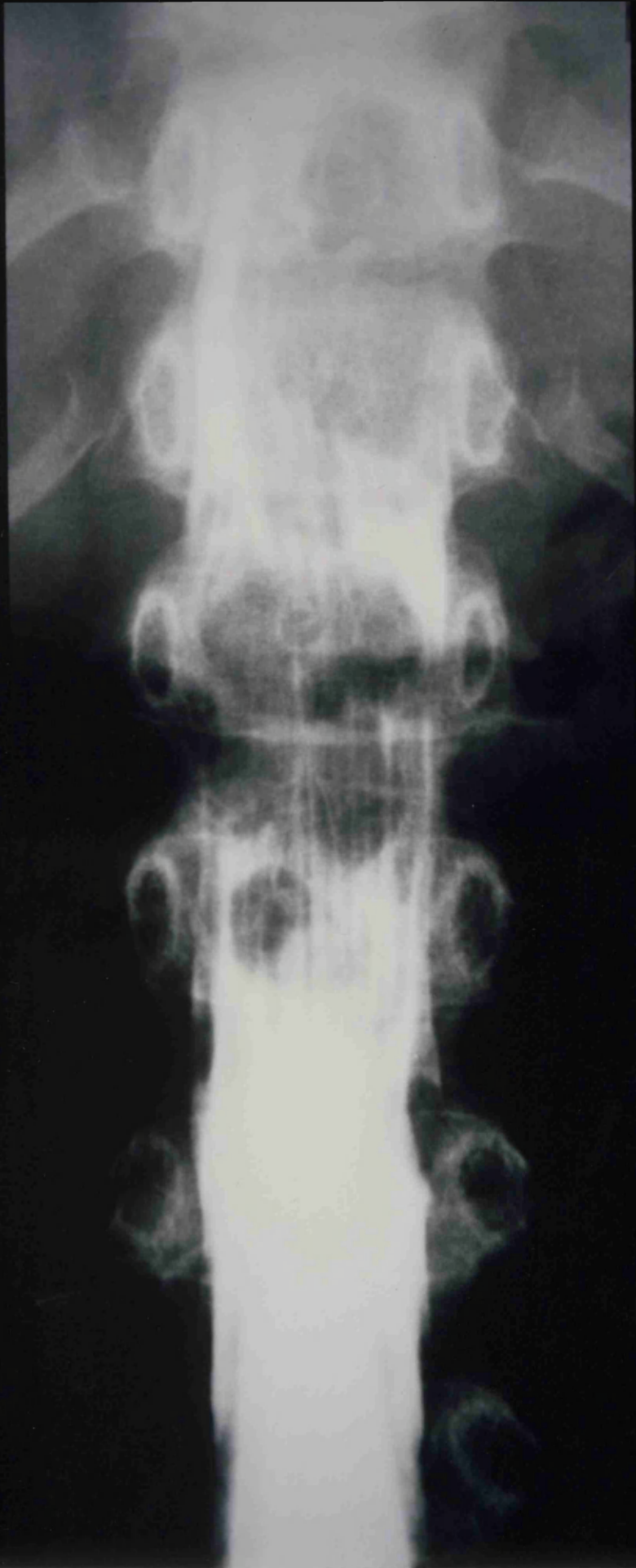

Fig. 1.2

Despite their relative insensitivity, contrast-enhanced CT and complete myelography with water-soluble contrast media are the radiological methods of choice in evaluating the CNS for the presence and extent of neoplastic involvement of the leptomeninges. At present, non-enhanced craniospinal magnetic resonance imaging appears to be even less sensitive in detecting these changes (Davis et al., 1987; Krol et al., 1988), although recent experience with gadolinium enhancement appears promising (Berns et al., 1988; Sze et al., 1988) (Fig. 1.3).

Fig. 1.3

Gadolinium-DTPA enhanced MRI scan of leptomeningeal medulloblastoma. High density enhancement is prominent over right frontal lobe convexity, within interhemispheric fissure and around brain-stem.

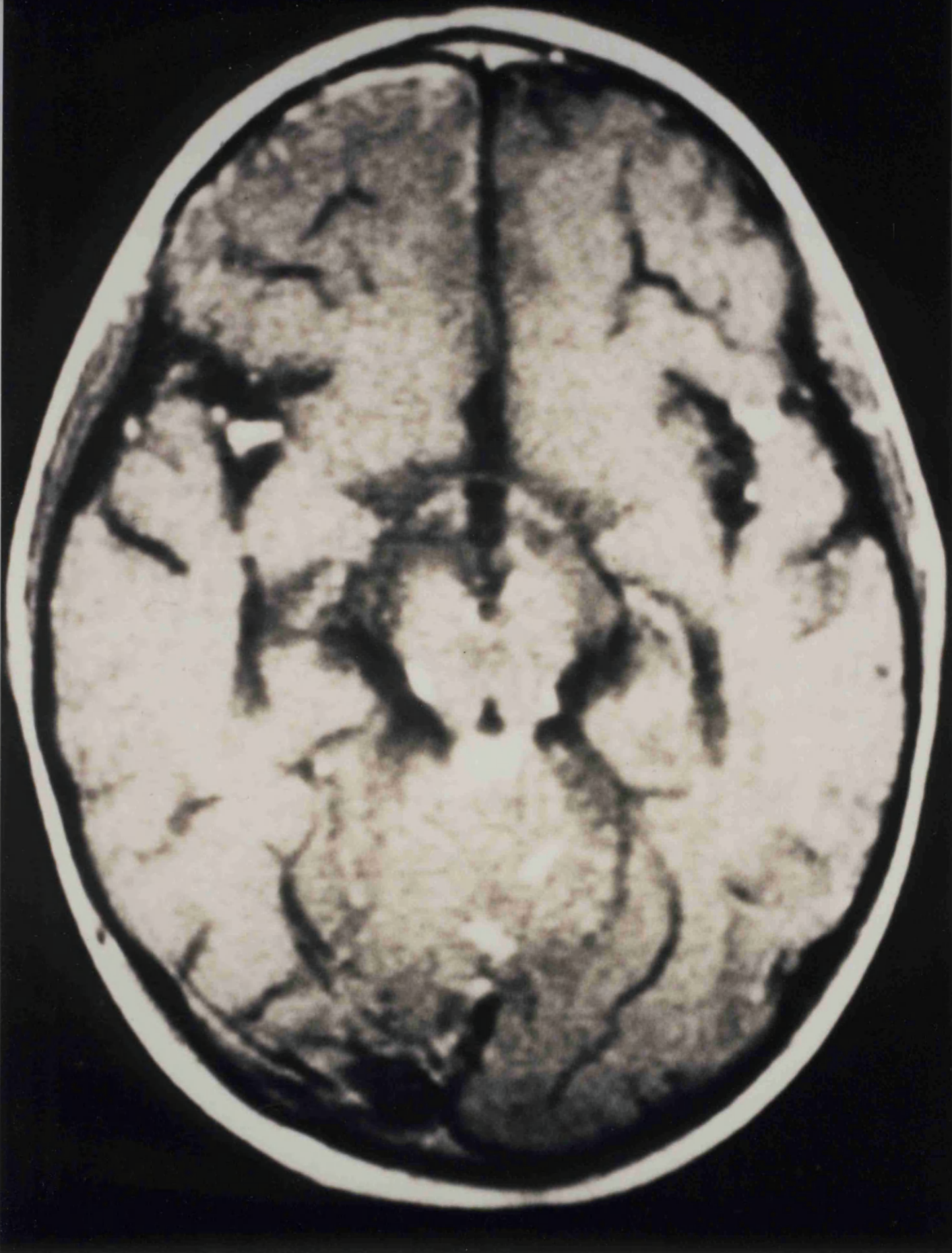


Fig. 1.3

1.5 PATHOLOGY

Meningeal neoplasia is characterised by diffuse or nodular infiltration of the leptomeninges. Macroscopically, tumour infiltration may be invisible to the naked eye and revealed only by microscopic study (Beerman, 1912; Stam, 1960; Griffin et al., 1971). Frequently, however, there is slight thickening and opacity of the leptomeninges with partial obscuration of underlying cortical blood vessels (Fischer-Williams et al., 1955); Henson and Urich, 1982). Nodular thickening of the cranial and spinal nerve roots is often apparent and frequently most prominent in the cauda equina where nerve roots may be matted together (Boyle et al., 1980). Leptomeningeal tumour is commonly seen over the basal surface of the brain and may be particularly extensive within the anterior sylvian fissures, chiasmatic cisterns, interpeduncular fossa and cerebello-pontine angles (Olson et al., 1974). Further favoured sites of tumour distribution include the superior cerebellar surface (Fig. 1.4), posterior spinal cord and cauda equina (Boyle et al., 1980; Henson and Urich, 1982).

Fig. 1.4

Leptomeningeal carcinoma involving superior cerebellar surface.

Immunoperoxidase staining with monoclonal antibody CAM 5.2 (x100).

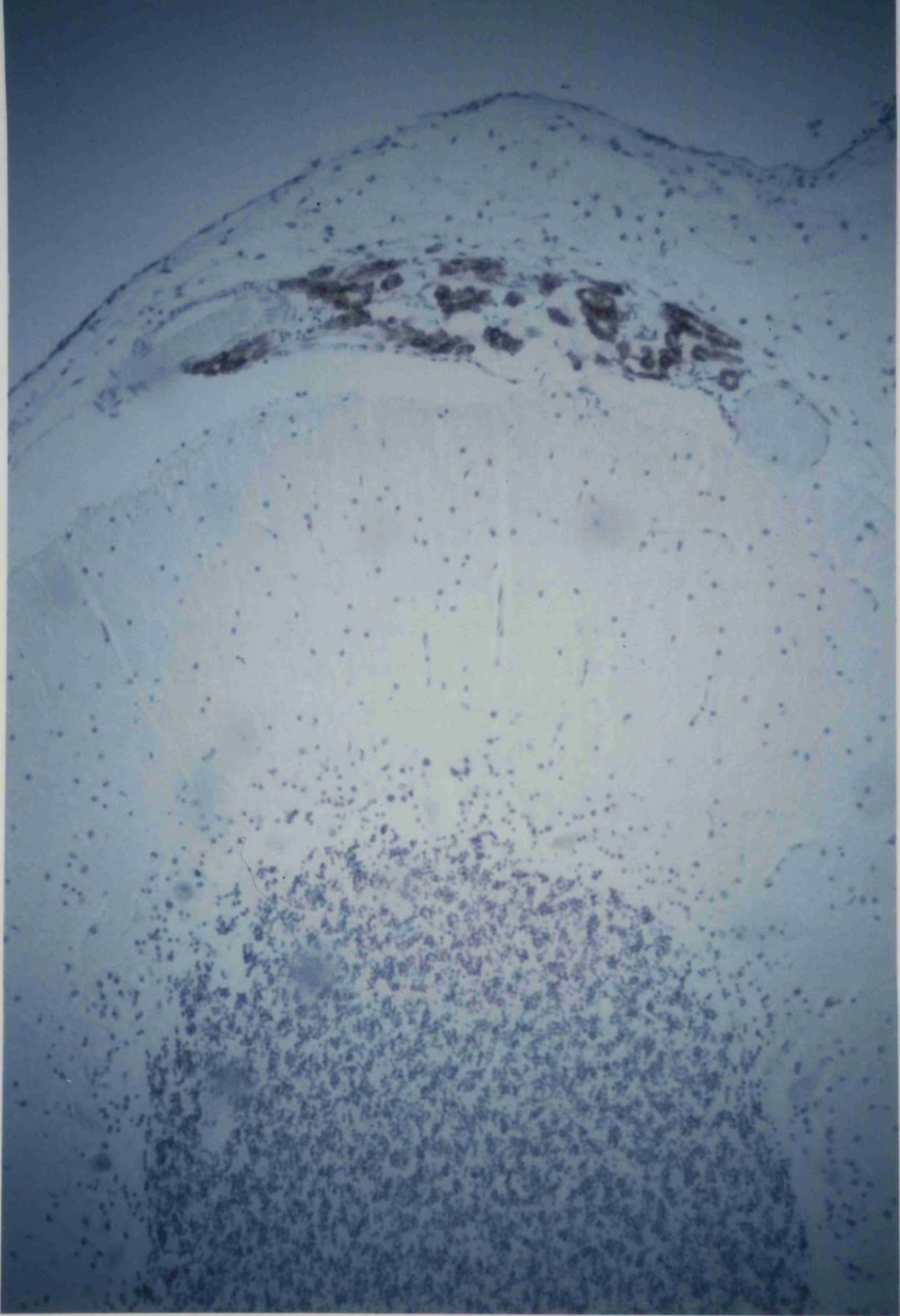


Fig. 1.4

It is probable that these distributional peculiarities reflect the influence of gravity (Willis, 1973). Occasionally, tumour deposits may be found on the ependymal surface of the cerebral ventricles and rarely may spread over the surface of the choroid plexus (Henson and Urich, 1982). Although generally distributed throughout the neuraxis, leptomeningeal tumour may occasionally be confined to the cranial (Redman et al., 1986) or spinal subarachnoid space (Dixon et al., 1946; Grain and Karr, 1955; Parsons, 1972). Within the subarachnoid space, tumour is commonly seen to ensheath leptomeningeal vessels within arachnoidal trabecula (Olson et al., 1974). This leptomeningeal perivascular tumour infiltration frequently extends to involve the deep perivascular (Virchow-Robin) spaces. Occasionally, tumour infiltration of the deep perivascular spaces is particularly prominent, and in such cases the disorder has been referred to as "carcinomatous encephalitis" (Madow and Alpers, 1951). The anatomy of the leptomeningeal tissues and vascular parenchymal interface has recently been elucidated (Krahn, 1982; Hutchings and Weller, 1986; Alcolado et al., 1988). It is now apparent that the deep perivascular or Virchow-Robin space is not an extension of the subarachnoid space. It is in anatomical continuity with the sub-pial space and separated from the subarachnoid space by leptomeningeal tissue. The glia limitans forms the external boundary of the neural parenchyma and the internal limit of the sub-pial and Virchow-Robin spaces (Fig. 1.5). Leptomeningeal tumour within the deep perivascular spaces is initially confined by the glia limitans, but eventually may penetrate the latter structure with invasion of the neural parenchyma (Aisner et al., 1981; Wasserstrom et al., 1982). Cranial and spinal nerve root infiltration is almost invariable (Fig. 1.6).

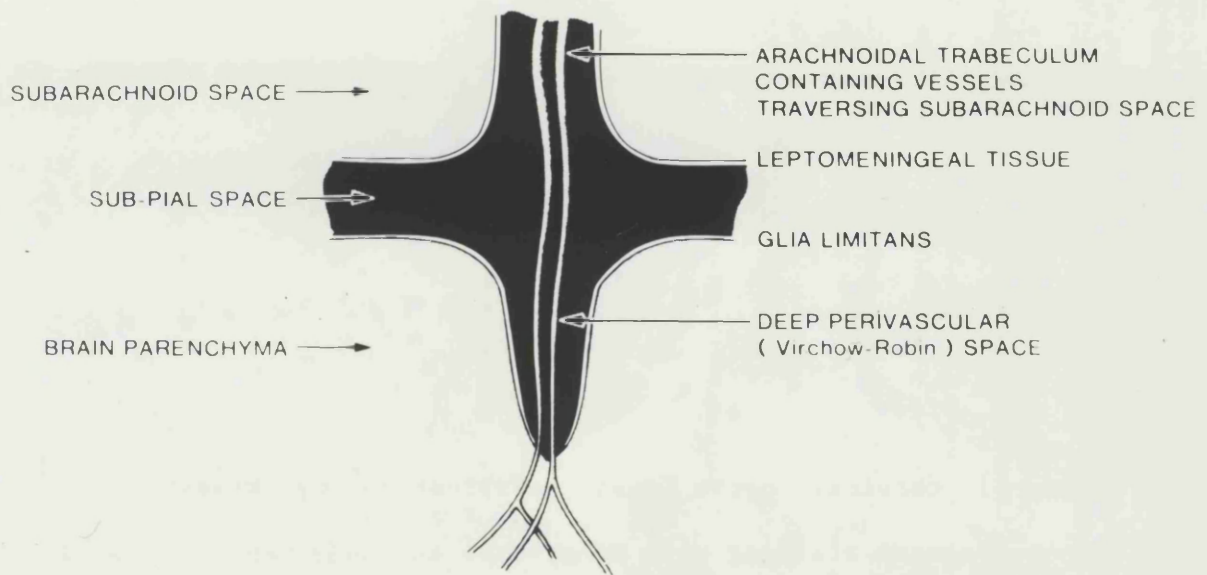


Fig. 1.5.

Microanatomy of the Leptomeningeal/Parenchymal Interface.

Fig. 1.6

Intradural cervical nerve root infiltration by breast carcinoma.

Immunoperoxidase staining with monoclonal antibody CAM 5.2 (x50).

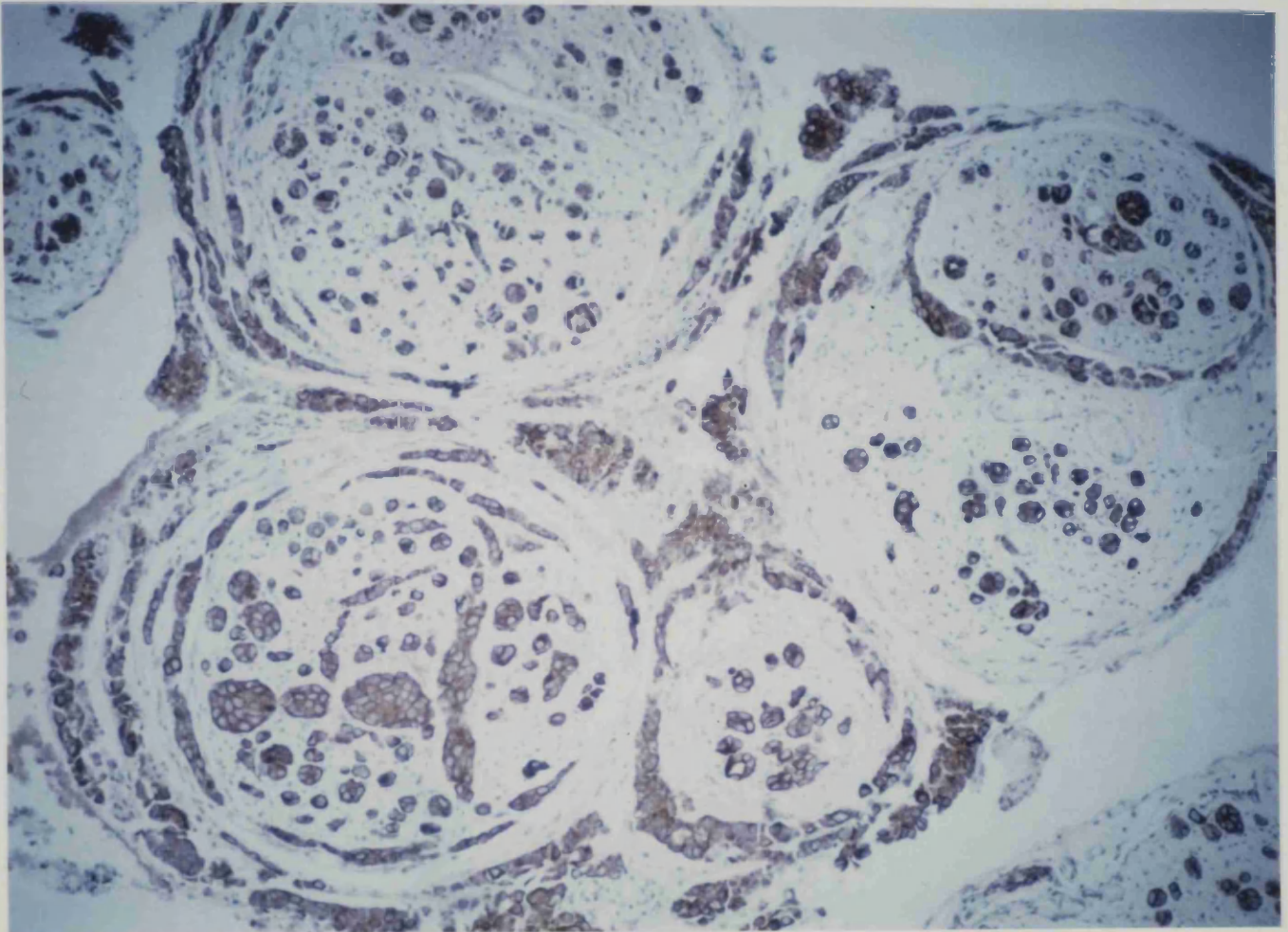


Fig. 1.6

Leptomeningeal reaction to neoplastic infiltration is variable. In many cases, the presence of tumour fails to invoke any host reaction, but occasionally a florid fibroblastic proliferation may occur with consequent obliteration of the subarachnoid space (Little et al., 1974; Olson et al., 1974; Behnam et al., 1984). In the latter situation, scattered tumour cells may be identified with difficulty within the predominating fibrous tissue mass (Henson and Urich, 1982). The fibroblastic leptomeningeal response in neoplastic meningitis appears to be independent of degree of tumour infiltration, duration of symptoms or therapy administered (Olson et al., 1974).

Direct infiltration of leptomeningeal tumour into the underlying neural parenchyma may occur in advanced disease of either primary neuroectodermal or systemic origin (Fig. 1.7). However, leptomeningeal malignancy arising from systemic neoplasia is commonly associated with independent multiple metastatic deposits within the cerebral parenchyma (Heathfield and Williams 1956; Posner and Chernik 1978; Theodore and Gendelman, 1981). Independent intracranial metastatic tumour deposits have been reported to occur in 72% of cases of neoplastic meningitis complicating systemic malignancy (Glass et al., 1979). Tumour, although confined to the leptomeninges, may induce pathological changes within the underlying neural parenchyma. These have been studied by immunohistochemical techniques which have revealed thickening of the glia limitans and astrocytic hypertrophy within the molecular layer of the cerebral cortex (Jamshidi et al., 1987). Other reported parenchymal changes include ischaemic neuronal damage which has been associated with direct parenchymal invasion of leptomeningeal tumour (Olson et al., 1974). Hydrocephalus of moderate

Fig. 1.7

Direct extension of leptomeningeal tumour into spinal cord parenchyma.
Immunoperoxidase staining with monoclonal antibody CAM 5.2 (large cell
lung carcinoma)(x50).

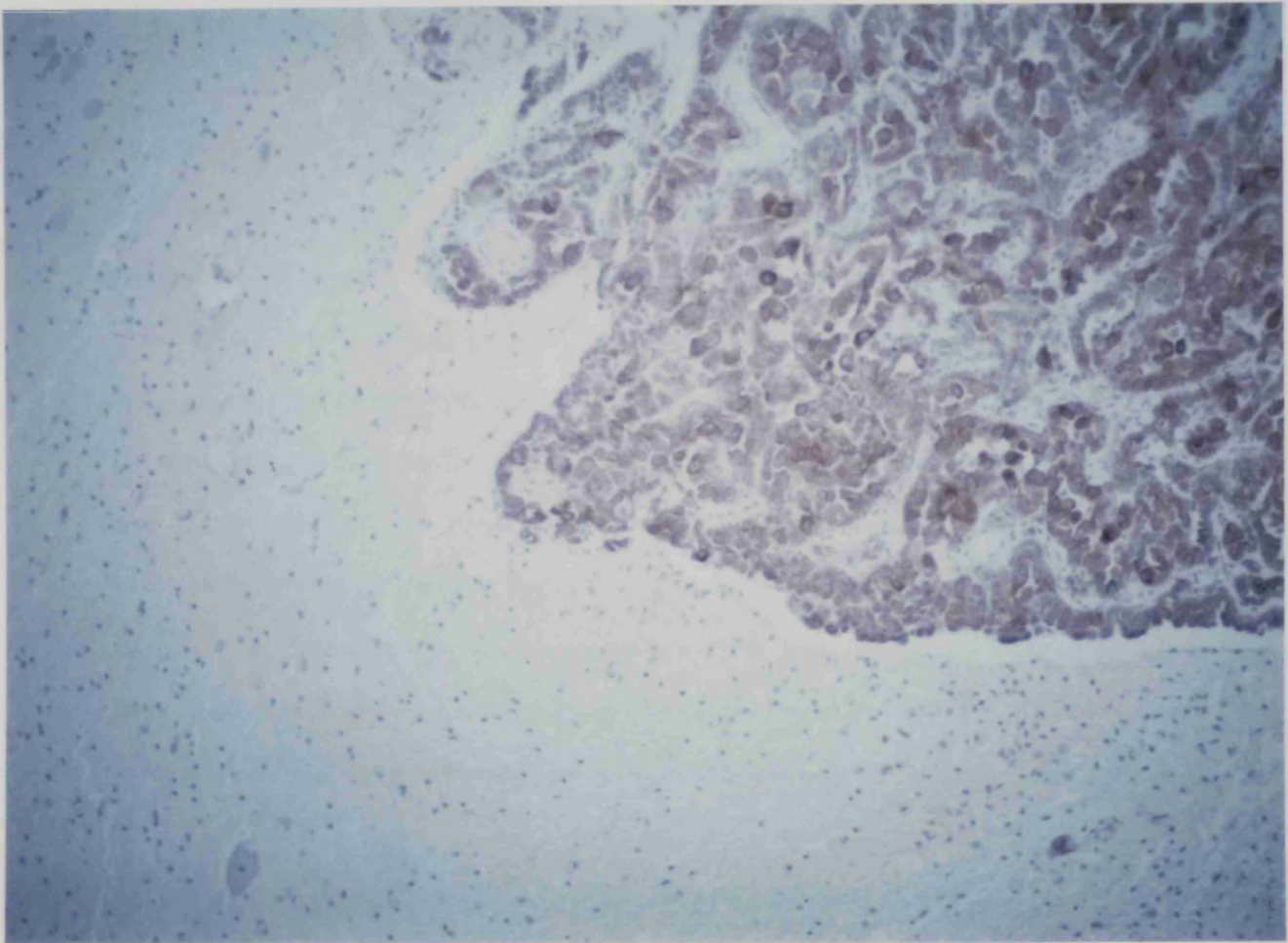


Fig. 1.7

to severe degree has been reported in approximately 50% of autopsies but occasionally the cerebral ventricles are reduced in size by parenchymal swelling (Olson et al., 1974). The degree of cerebral swelling appears to be unrelated to the amount of leptomeningeal or parenchymal tumour involvement (Olson et al., 1974).

1.6 PATHOGENESIS

It is still not entirely clear how systemic tumour reaches the leptomeninges. Several mechanisms have been proposed and individual case studies give some support to each of these, suggesting that several modes of entry into leptomeningeal tissues are possible. Extension of parenchymal tumour into the ventricular system or subarachnoid space is a frequently cited source of tumour spread to the leptomeninges (Wagner et al., 1960; Dinsdale and Taghavy, 1964). Although occasional cases provide striking examples of this, it has been the experience of many that the majority of parenchymal metastases invading the leptomeninges directly do not give rise to disseminated leptomeningeal neoplasia (Olson et al., 1974). Rupture of the pial surface is usually accompanied by a focal fibrotic reaction, which may prevent dissemination of exfoliated tumour cells (Henson and Urich, 1982). Rupture into the ventricular system would seem to provide a more favourable route since it is not accompanied by surrounding tissue reaction. In the autopsy study of Olson and colleagues, underlying parenchymal tumour could only be demonstrated in 13 of 30 patients with neoplastic meningitis. In only 3 of these cases subependymal tumour deposits had extended into the ventricular system (Olson et al., 1974).

Other investigators have suggested the deep perivascular space of Virchow-Robin as the primary metastatic site of systemic tumour reaching the leptomeninges (Lewis, 1925; Globus and Meltzler, 1942). The authors have suggested that tumour originating in these sites could extend centrifugally into the subarachnoid space.

Metastatic tumour deposits within the choroid plexus may represent a further potential source of leptomeningeal tumour dissemination (Heathfield and Williams, 1956; McMillan, 1962). Choroid plexus tissue is rarely sectioned for histological examination and the presence of small tumour foci may escape notice (Henson and Urich, 1982). Moburg and Reis found tumour in the choroid plexus in all 5 of their patients and concluded that this structure represented the primary source of systemic tumour metastases to the leptomeninges (Moburg and Reis, 1961). Many reports however, attest to the absence of choroid plexus involvement in the presence of extensive leptomeningeal neoplasia (Wasserstrom et al., 1982). It is also contested by some, that choroid plexus involvement by tumour is secondary to spread from pre-existing meningeal neoplasia (Gonzalez-Vitale and Garcia-Bunuel, 1976).

It has been stated (Dinsdale and Taghavy, 1964) that the only careful attempt to demonstrate anatomically the route taken by carcinomatous cells to reach the leptomeninges was that of Knierim in 1908 (Knierim, 1908). In a patient with gastric carcinoma, histopathological studies revealed permeation of tumour into perineural adventitial planes. Kneirim was able to demonstrate anatomical continuity of perineural tumour infiltrate from the primary tumour site to the central nervous

system and concluded that this was the route taken by the tumour to invade the spinal leptomeninges. Additional support for direct tumour infiltration of meningeal tissues has been obtained by histopathological studies of paravertebral soft tissues in patients with neoplastic meningitis. Tumour infiltration of perivascular and perineural adventitia with extension into intervertebral foramina was a universal finding in these sites (Gonzalez-Vitale and Garcia-Bunuel, 1976). Kokkoris in 1981 performed a retrospective study of 28 autopsy cases of neoplastic meningitis (Kokkoris, 1981). In all of his cases there was evidence of metastatic disease involving the vertebral column or paravertebral soft tissues. It was proposed that, on reaching these tissue sites, malignant cells infiltrated along perivascular and perineural adventitial planes eventually gaining access to the leptomeninges. Further circumstantial evidence supporting the predominance of this mode of leptomeningeal spread comes from observations of major meningeal neoplastic involvement occurring at sites adjacent to paravertebral tumour (Kokkoris, 1981; Redman et al., 1982).

This hypothesis for meningeal dissemination of systemic tumour is also consistent with the observation of Price and Johnson that the earliest abnormality demonstrated in meningeal leukaemia is leukaemic infiltration within the adventitia of leptomeningeal veins (Price and Johnson, 1973). In the latter situation, it is likely that leukaemic infiltration of cranial bone marrow extends along the adventitial planes of communicating venous channels (Thomas et al., 1964; Bunn et al., 1976; Azzarelli and Roessmann, 1977).

1.7 DIAGNOSTIC CYTOLOGY

The diagnosis of meningeal neoplasia is now most commonly established by the demonstration of exfoliated malignant cells within the CSF (Fig. 1.8). Although the first attempt at detection of malignant cells in CSF was by Widal in 1903 (Widal et al., 1903), Dufour is credited with their first demonstration in 1904 (Dufour, 1904). Several isolated case reports demonstrating tumour cells in the CSF then followed (Panton and Cantab, 1922; Boyd, 1925; Walt, 1939; Meissner, 1953). However, diagnostic CSF cytology was not widely practised until adequate cytopreparatory methods became established. Fifty years on from Dufour's demonstration, Spriggs commented on the scarcity of reported cases in which tumour cells had been detected in the CSF (Spriggs, 1954). He reviewed the literature to find only 66 acceptably documented examples and observed the predominance of systemic carcinoma as a cause of meningeal neoplasia. Primary neuroectodermal tumours only accounted for 19 of the cases in his historical survey. Spriggs outlined the general criteria for identification of malignant cells in CSF and correctly stated that neoplastic cells could not be distinguished by any single morphological feature.

Several investigators subsequently evaluated CSF cytological methods for the diagnosis of parenchymal intracranial neoplasms (Bischoff, 1961; Kline, 1962; Naylor, 1964; Bots et al., 1964; Sayk and Olischer, 1967). Data from these publications is exhibited in Table 1.1 which reveals marked variation in tumour cell detection rate. Metastatic tumours were more consistently detected than primary

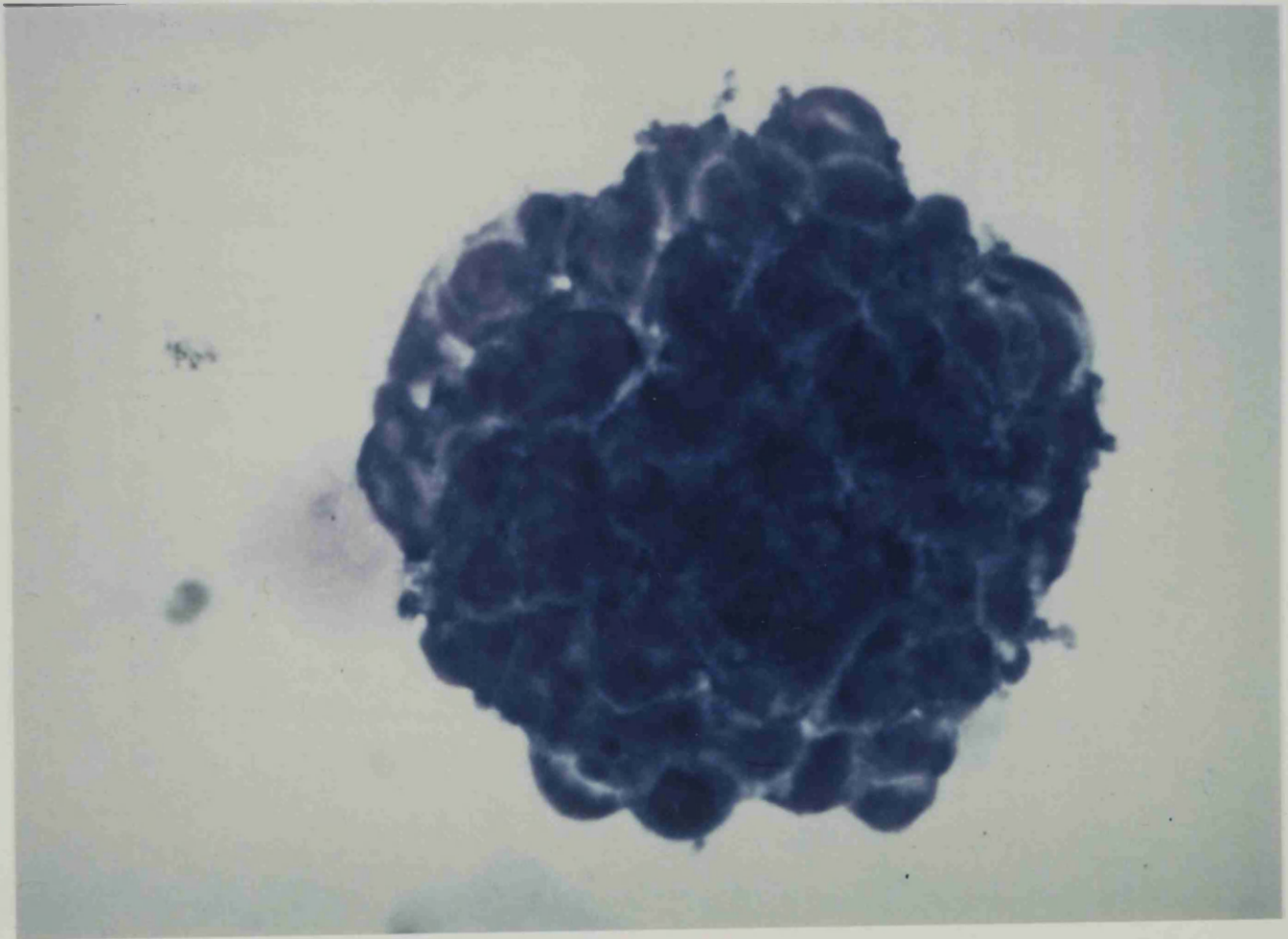


Fig. 1.8

tumours of the neuroectoderm and there was a high incidence of false-negative cytology in patients with histologically proven malignancy of the central nervous system.

Table 1.1

Detection Rate of Central Nervous System Tumours by Cytological Methods

	CNS Tumours Primary and Metastatic	CNS Tumours Metastatic
Biscoff, 1961	62.7%	91.7%
Kline, 1962	41%	48.4%
Naylor, 1964	25.5%	42.2%
Bots et al., 1964	50%	75%
Sayk and Olischer, 1967	7.3%	20%

The above mentioned investigators included patients with exclusively parenchymal tumours. Although it was considered by some that parenchymal tumours could be detected cytologically in the absence of leptomeningeal or ventricular extension (Choi and Anderson, 1979), this has not been the experience of other workers (Glass et al., 1979; Wasserstrom et al., 1982). In an extensive autopsy study of neoplastic meningitis with antemortem CSF cytology, it was clearly established that malignant cells could only be demonstrated in the CSF of patients harbouring parenchymal tumours if the pial or ventricular surface had been breached by neoplasm (Glass et al., 1979). These authors established a clear correlation of positive diagnostic cytology with the degree of meningeal tumour infiltration seen at autopsy. In patients with central nervous system malignancy complicating systemic neoplasia, the malignant cytology detection rate was 55.5% in the presence of leptomeningeal tumour infiltration and 0% in its absence. The detection incidence of malignant cells in patients with disseminated meningeal neoplasia was 66% in contrast to only 38% in patients with focal meningeal neoplasia. In view of these findings and the known risks of lumbar puncture in patients with parenchymal brain tumours (Richards and Towu-Aghantse, 1986), subsequent studies of CSF cytology have been confined to cases of suspected neoplastic meningitis. Data from these series is exhibited in Table 1.2.

Table 1.2

Detection rate of Neoplastic Meningitis by Cytological Methods

	Initial CSF Examinations	Subsequent CSF Examinations
Olson et al., 1974	45%	79%
Little et al., 1974	-	81%
Yap et al., 1978	92%	100%
Glass et al., 1979	-	59%
Theodore and Gendelman, 1981	72%	100%
Wasserstrom et al., 1982	54%	91%
Ongerboer de Visser, 1983	94%	100%
Coakham et al., 1984	-	94%

The variation in malignant cell detection rate seen in cytology series reflects a number of factors. Not unexpectedly, malignant cell detection rate appears to be high in studies without extensive autopsy investigation (Yap et al., 1978; Theodore and Gendelman, 1981; Ongerboer de Visser, 1983). Cytopreparatory techniques and staining methods have varied, and significant inter and intraobserver variability may occur in the interpretation of cytological preparations (Choi and Anderson, 1979; Pedersen et al., 1986). Another variable factor influencing the malignant cell detection rate in meningeal neoplasia is the number of CSF examinations per patient. Many clinical studies have reported a significant increase in tumour cell detection rate with multiple spinal taps (Olson et al., 1974;

Wasserstrom et al., 1982).

False-negative CSF cytology in patients with widely disseminated neoplastic meningitis remains a significant problem. Multiple CSF sampling undoubtedly increases the diagnostic sensitivity, but there remain patients who defy a cytological diagnosis (Fig. 1.9). Occasionally, exfoliated malignant cells are not uniformly distributed throughout the CSF compartment even in the absence of an obstruction within the CSF pathways (Murray et al., 1983). Consequently although cellular diagnostic yields are usually maximal in CSF obtained from the lumbar subarachnoid space, cisternal or ventricular CSF samples may provide positive cytology when previous lumbar puncture samples have been negative (Redman et al., 1986). In patients with clinical features of meningeal neoplasia in whom previous lumbar punctures have been non-diagnostic, attempts should be made at sampling CSF from more rostral sites of the neuraxis. In these circumstances optimum cellular yields are usually obtained at sites of the neuraxis corresponding to the predominant clinical features.

Some patients with disseminated neoplastic meningitis exfoliate very few malignant cells into the CSF, making cytological detection difficult. It would seem that meningeal tumours vary in their cohesiveness and hence their tendency to exfoliate into the CSF (Kline, 1962). Other tumours may incite an intense leptomeningeal fibrotic reaction which could conceivably prevent discharge of malignant cells into the CSF (Little et al., 1974).

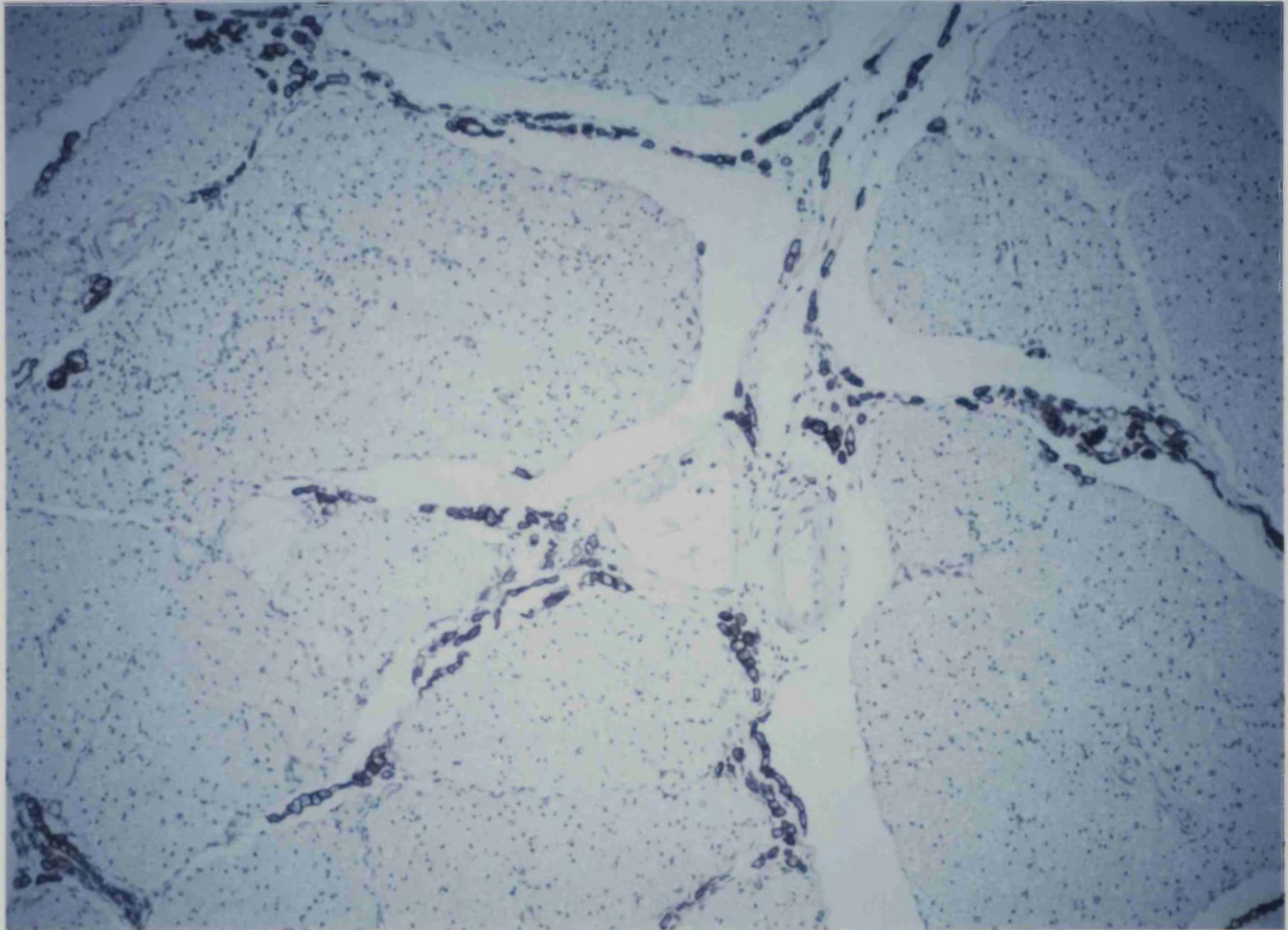


Fig. 1.9

Interpretive difficulties may be encountered when meningeal neoplasia is accompanied by an inflammatory response with exfoliation of large numbers of inflammatory cells into the CSF (Little et al., 1974; Conrad et al., 1986). In these circumstances, a scanty malignant cell infiltrate may be masked by a predominant leukocytosis with heterogeneous morphology (Coakham et al., 1984b). Spriggs has also commented on the "lymphoid" appearance of exfoliated medulloblastoma cells which could therefore be interpreted as reactionary cellular infiltrate (Spriggs, 1954).

False positive cytology, although less common is a more serious error and can even occur with experienced observers (Marks and Marrack, 1960; Naylor, 1964; Glass et al., 1979). In several cases, errors have arisen from misinterpretation of atypical lymphoid cells as malignant. In 1960, Wagner and colleagues drew attention to non-neoplastic cellular elements forming clusters in imitation of malignant cells (Wagner et al., 1960). The same authors also stressed the tendency for exfoliated cells of non-neoplastic origin to round up and imbibe fluid, thereby mimicking signet-ring cells of adenocarcinoma.

A major advance in CSF cytological technique arrived with the introduction of monoclonal antibody immunocytochemical methods (Hancock and Medley, 1983; Coakham et al., 1984a). The use of immunocytology in conjunction with conventional cytological techniques has been reported to increase diagnostic sensitivity in meningeal neoplasia (Coakham et al., 1984b; Moseley et al., 1989a). Although this is disputed by some (Boogerd et al., 1987), the immense value of

the technique is universally accepted when neoplastic meningitis is a manifestation of malignancy of unknown primary origin. In these circumstances, distinction between carcinoma, lymphoma or primary neuroectodermal tumour maybe impossible with conventional cytological techniques (Vick et al., 1987). However, the use of a diagnostic panel of monoclonal antibodies defining the major tumour groups involving the leptomeninges allows characterisation of the primary neoplasm. (Coakham et al., 1984a,b; Wechsler et al 1984; Vick et al., 1987; Moseley et ., al., 1989a).

1.8 CEREBROSPINAL FLUID TUMOUR MARKERS

Failure to demonstrate malignant cells in CSF occurs in a significant number of patients subsequently shown to have leptomeningeal tumour at autopsy (Glass et al., 1979). Persistently negative exfoliative cytology in patients with neoplastic meningitis leads to diagnostic delay which may result in reduced effectiveness of therapy (Schold et al., 1980; Ongerboer de Visser et al., 1983). Apart from only affording relative quantitation, cytological studies require skilful interpretation, are subject to inter-observer variability and may revert from positive to negative in the absence of intervening therapy (Pederson et al., 1986). These irregularities emphasize the requirement for new diagnostic methods, both as a means of making the initial diagnosis and also for assessing tumour response to therapy. A wide variety of compounds have been studied in CSF as potential biochemical markers of central nervous system neoplasia (Seldenfeld and Marton, 1979; Wasserstrom et al., 1981; Jaeckle, 1985). Some of these have gained acceptance as markers of neoplastic meningitis and

include lactate dehydrogenase (Wroblewski et al., 1958; Fleisher et al., 1981; Twijnstra et al., 1987a), beta-glucuronidase (Shuttleworth and Allen, 1968, 1980; Tallman et al., 1985), beta-2-microglobulin (Koch et al., 1983; Twijnstra et al., 1986a) and carcinoembryonic antigen (Yap et al., 1980; Klee et al., 1986).

Lactate dehydrogenase (LDH) is an intracytoplasmic glycolytic enzyme. It is an oligomeric protein of molecular weight 135 kDa. existing in different isoenzymic forms (LDH 1-5). It is a normal constituent of brain tissue and low levels of activity can be measured in normal CSF. Increased levels of LDH have been reported in a variety of neoplastic tissues (Goldman et al., 1964) and elevated CSF activity has been observed in tumours of the central nervous system (Green et al., 1958, 1959; Vara-Lopez and Vara-Thorbeck, 1971). Increased LDH activity within CSF has been frequently reported in neoplastic meningitis (Fleisher et al., 1981; Twijnstra et al., 1987a). However, elevated activity is also seen in cerebrovascular disease (Fleisher et al., 1957; Green et al., 1958), bacterial meningitis (Beaty and Oppenheimer, 1967; Nelson et al., 1975) and head injury (Fleisher et al., 1957). Whilst this may reflect intradural release of LDH from meningeal leucocytic infiltrate or damaged neural tissue, significant CSF activity may result from passive transfer of serum enzyme through the disrupted blood/brain barrier. Normal brain tissue exhibits a preponderance of the isoenzymes LDH 1 and 2 in contrast to the isoenzymes LDH 4 and 5 which are more prominently expressed in neoplastic tissues (Gerhardt et al., 1967; Sherwin et al., 1968). Determination of the isoenzymic distribution of LDH activity is thought by some to enhance the value of this diagnostic marker

(Gerhardt et al., 1967; Fleisher et al., 1981), but other investigators have disputed this (Rabow and Kristensson, 1977).

Beta-glucuronidase is a widely distributed lysosomal acid hydrolase enzyme with particularly high activity in epithelial tissues and leucocytes (Fishman and Anlyan, 1947). Enzymic activity is normally present in brain parenchyma, pia-arachnoid and choroid plexus. Low levels of beta-glucuronidase are also detected in normal CSF (Shuttleworth and Allen, 1980). Tissue activity of beta-glucuronidase is known to be increased with malignant transformation (Fishman and Anlyan, 1947; Anlyan and Gamble, 1950). Following the demonstration of increased beta-glucuronidase activity in malignant serous effusions (Anlyan and Fishman, 1947), CSF activity was investigated as a marker of central nervous system neoplasia (Anlyan and Starr, 1952). Striking elevations of CSF beta-glucuronidase activity were later observed in neoplastic meningitis by Shuttleworth and Allen (Shuttleworth and Allen, 1968), whose observations were subsequently confirmed by other investigators (Schold et al., 1978). However, significant elevation of beta-glucuronidase activity in CSF is also seen in a variety of infective meningitides (Shuttleworth and Allen, 1980; Wasserstrom et al., 1981). This may be a consequence of enzymic release from meningeal leucocytic infiltrate or damaged neural tissue. It also remains possible that the major contribution to CSF activity in these circumstances results from leakage of serum enzyme through the disrupted blood/brain barrier.

Beta-2-microglobulin is a protein component (MW 11,800) of the HLA histocompatibility antigen complex. Although present on the cell

surface of all nucleated cells, its expression is most prominent in lymphocytes and macrophages (Malkin and Posner, 1987). Beta-2-microglobulin is shed from the cell surface and is a normal component of serum, urine and CSF (Berggard and Bearn, 1968; Evrin et al., 1971). Rapid haemopoietic cellular turnover in myeloproliferative and lymphoproliferative disorders results in excessive liberation of beta-2-microglobulin into the circulation with consequent raised serum levels (Amlot and Adinolfi, 1978; Child et al., 1980). Elevation of beta-2-microglobulin in CSF has been reported by several investigators as a useful marker for lymphoid/myeloproliferative neoplastic meningitis (Mavligit et al., 1980; Koch et al., 1983). Its elevation in CSF has also been observed in cerebrovascular disease, bacterial meningitis and other disorders associated with impaired blood/brain barrier function (Tenhunen et al., 1978). In these circumstances, CSF beta-2-microglobulin levels predominantly reflect passive transgression of this low molecular weight protein through the disrupted blood/brain barrier (Mavligit et al., 1980). However, a significant intrathecal contribution may arise from leucocytic meningeal infiltrates or damaged neural tissues (Tenhunen et al., 1978).

Carcinoembryonic antigen (CEA) was first described by Gold and Freedman in 1965 (Gold and Freedman, 1965). Although initially thought to be specific for adult gastrointestinal tumours and foetal endodermal tissues, subsequent radioimmunoassay studies have also detected its presence in a wide range of normal adult tissues (Khoo et al., 1973). This high molecular weight glycoprotein (MW 200 kDa.) is liberated into body fluids and has been extensively investigated as a

serum marker for colorectal carcinoma (Thomson et al., 1969; Moore et al., 1971). Further studies have also revealed raised levels of serum CEA in non-endodermally derived tumours and a wide range of benign conditions, (Kupchick and Zamcheck, 1972; Logerfo et al., 1979). In normal individuals, refined radioimmunoassay techniques detect low levels of CEA in various biological fluids including CSF (Schold et al., 1980, Dearnaley et al., 1981; Wasserstrom et al., 1981). Several investigators have reported elevated levels of carcinoembryonic antigen in CSF of patients with neoplastic meningitis (Yap et al., 1980; Klee et al., 1986; Twijnstra et al., 1986c; Jacobi et al., 1986). Although this is more frequently observed in meningeal neoplasia of breast, lung and gastrointestinal origin, it has also been reported in malignant melanoma (Schold et al., 1980). Elevated levels of carcinoembryonic antigen in CSF have also been reported in the absence of neurological disease, when serum levels are grossly elevated (Schold et al., 1980). Despite the relatively high molecular weight of CEA, this observation implies some degree of passive transfer of serum CEA across the normal blood/brain barrier. Reports also attest to the elevation of CEA in CSF of patients with inflammatory meningitides (Jacobi et al., 1986). Although this has generally been solely attributed to passive leakage of serum CEA across a disrupted blood/brain barrier, sensitive radioimmunoassay techniques have revealed small quantities of CEA in normal brain (R. P. Moseley, unpublished observation) and this may be released into CSF in response to neural damage.

Studies using these individual markers appear to suggest beta-glucuronidase as the most sensitive and specific indicator of

neoplastic meningitis arising from solid tumours (Shuttleworth and Allen, 1980; Van Zanten et al., 1985). In contrast, leptomeningeal involvement with lymphoid/myeloproliferative disease appears to be most accurately detected with beta-2-microglobulin (Twijnstra et al., 1986a,b). Lactate dehydrogenase, although a sensitive marker of neoplastic meningitis, offers a relatively low degree of specificity (Van Zanten et al., 1986). Carcinoembryonic antigen as a marker of leptomeningeal neoplasia appears to be relatively insensitive, but exhibits a high degree of specificity (Twijnstra et al., 1986c).

Sensitivity and specificity are the most important parameters for any disease marker assay. Sensitivity refers to the ability of an assay to detect all patients with the disease. Specificity defines its ability to discriminate a control group of individuals who do not have the disease. Unfortunately, the latter parameter can vary significantly according to the control group of patients chosen to represent individuals with no disease. This point is well illustrated in the case of CSF markers for neoplastic meningitis. If normal patients are chosen as controls, then all of the aforementioned markers exhibit a high degree of specificity. However, if the control group of patients includes a large number of individuals with inflammatory meningitides, the specificity of these marker assays is significantly reduced. In clinical practice, a common diagnostic problem presenting to the physician is to distinguish neoplastic meningitis from a variety of chronic inflammatory meningitides (Hughes et al., 1963; Morganroth et al., 1972). In these circumstances, individual tumour markers of leptomeningeal neoplasia do not exhibit adequate levels of specificity and consequently their measurement has

not been universally adopted into standard practice.

The development of new tumour markers may improve diagnostic sensitivity and specificity, but this can also be achieved with refinements of existing technology. Such refinements include the use of multiple marker combinations, consistent sampling of CSF from the lumbar subarachnoid space and simultaneous detection of marker levels in serum and CSF.

The determination of multiple biochemical marker values in CSF (LDH, beta-2-microglobulin, CEA and beta-glucuronidase) has been shown to increase the sensitivity and specificity of this diagnostic technology (Twijnstra et al., 1986b; Van Zanten et al., 1988a).

Many investigators have reported lower concentrations of tumour markers in CSF obtained from the cerebral ventricles than that obtained by lumbar puncture (Schold et al., 1980; Wasserstrom et al., 1981; Twijnstra et al., 1987a, 1989). The observed concentration gradient of tumour markers within CSF remains unexplained, but is independent of the predominant site of tumour within the neuraxis. Assays for CSF tumour markers should achieve greater diagnostic sensitivity with samples obtained from the lumbar subarachnoid space.

As there are circumstances in which tumour markers may transgress the blood/brain barrier, resulting in passive leakage from serum into CSF, interpretation of CSF values should ideally not be made in the absence of a simultaneously determined serum value (Mavligit et al., 1980; Jacobi et al., 1986; Reiber et al., 1986).

Optimisation of biochemical tumour marker technology now offers increased diagnostic accuracy when used in conjunction with cytological techniques and also provides a measurable index of response to therapy (Twijnstra et al., 1987b). Diagnostic problems remain in patients with chronic inflammatory meningitides of unknown aetiology.

1.9 ASPECTS OF THERAPY

Treatment of leptomeningeal neoplasia must clearly be directed to the entire neuraxis. The current standard therapeutic approach to neoplastic meningitis involves the intrathecal administration of chemotherapeutic agents, and/or external beam irradiation. The primary central nervous system tumours - medulloblastoma, pineoblastoma and germinoma are extremely radiosensitive and exhibit a propensity to disseminate the leptomeninges (Packer et al., 1987; Ushio et al., 1987). Although neoplastic meningitis complicating these tumours may be eradicated by craniospinal irradiation alone, many physicians favour the addition of adjunctive intrathecal and/or systemic chemotherapy (Hagler et al., 1968; Ushio et al., 1987). In leptomeningeal neoplasia arising from non-leukaemic systemic malignancy, the role of radiotherapy is less well defined, as these tumours are generally much less radiosensitive. Although craniospinal irradiation alone has produced therapeutic responses (Heathfield and Williams, 1956), its administration in sufficient dosage risks development of severe myelosuppression (Posner, 1977; Wasserstrom et al., 1982). Consequently, administered radiation schedules vary significantly amongst practising clinicians and are always combined

with intrathecal chemotherapy. Those that include radiotherapy may restrict its application to the cranial cavity or sites of predominant neuraxial disease (Yap et al., 1982; Wasserstrom et al., 1982).

The increased incidence of neoplastic meningitis seen in recent years is a result of prolonged survival, and the ineffectiveness of many systemically active anti-neoplastic agents against malignant disease within the central nervous system (Bleyer, 1977a). The pharmacological sanctuary of the central nervous system has been well demonstrated in animal models of leukaemia (Thomas et al., 1962; Thomas et al., 1964; Thomas, 1965). In animals treated with ionised water soluble agents such as cyclophosphamide, proliferation of leptomeningeal tumour continued despite eradication of systemic disease. In contrast, animals administered the lipid soluble agent BCNU had complete eradication of systemic and central nervous system disease (Thomas, 1965).

Similar studies were later performed in animal models of solid tumour leptomeningeal neoplasia. In these studies, moderate therapeutic efficacy was demonstrated in animals administered water soluble agents exhibiting limited blood/brain barrier penetration (Ushio et al., 1977; Shimizu et al., 1980). This unexpected observation was attributed to partial blood/brain barrier disruption which was later shown to be a delayed event ushering the establishment of leptomeningeal disease (Ushio et al., 1981). Electron microscopy and dye diffusion studies have since provided morphological and physiological evidence of blood/brain barrier disruption in leptomeningeal tumour (Siegal et al., 1987).

Despite the demonstration of blood/brain barrier disruption in neoplastic meningitis, all animal studies have demonstrated significantly greater therapeutic effect with lipid soluble anti-neoplastic agents which rapidly penetrate into the normal central nervous system (Thomas, 1965; Ushio et al., 1977; Shimizu et al., 1980). This observation, together with clinical experience in childhood leukaemia (Moore et al., 1960), would suggest that the degree of blood/brain barrier disruption is insufficient to facilitate rapid entry of systemically administered ionised agents into leptomeningeal tumour. Successful treatment of sanctuary disease is therefore more likely to follow parenteral administration of lipid soluble agents. Therapeutic efficacy of ionised compounds might however be enhanced by maintenance of high systemic levels and/or use of techniques to further disrupt the blood/brain barrier in leptomeningeal tumour (Suzuki et al., 1983).

The administration of drugs directly into the cerebrospinal fluid followed recognition of the limited penetration of many systemically administered agents into the central nervous system (Whiteside et al., 1958). A further advantage conferred by this route of administration is the reduced volume of drug distribution. Cytocidal concentrations of anti-neoplastic agents in CSF may therefore be obtained following instillation of relatively small doses. In this way, systemic toxicity may be avoided. Furthermore, bolus instillations of anti-neoplastic agents into CSF exhibit minimal penetration into neural parenchyma and thus may afford relative sparing of central nervous system toxicity (Blasberg et al., 1975; Blasberg, 1977; Blasberg et al., 1977). However, complete distribution of drugs

throughout the CSF pathways is not guaranteed by their intrathecal instillation. In advanced disease, deep perivascular and parenchymal tumour infiltration is not unusual, and often associated with focal areas of subarachnoid space obliteration (Olson et al., 1974). Indeed irregularities of CSF flow have been observed with isotope ventriculography in 70% of patients with neoplastic meningitis (Grossman et al., 1982). In these circumstances, it seems doubtful that significant quantities of intrathecally administered drugs would reach tumour sites (Hustu et al., 1973; Aisner et al., 1981). Partial obstruction of CSF pathways may also predispose to drug related neurotoxicity (Shapiro et al., 1973).

Drug distribution within CSF is also significantly affected by the volume of injectate (Rieselbach et al., 1962) and the precise route of intrathecal instillation (Shapiro et al., 1975). Several studies have demonstrated incomplete CSF drug distribution following instillation into the lumbar subarachnoid space (Welch et al., 1975; Shapiro et al., 1975; Bleyer and Savitch, 1975; Kaiser and McGee, 1975). These studies have consistently revealed inadequate drug delivery into cerebral ventricular CSF and hence the creation of a sanctuary within a sanctuary (Bleyer and Savitch, 1975). Furthermore, several investigators have reported a significantly high failure rate of lumbar drug instillation (11%-24%), often accompanied by formation of extra-arachnoidal fluid collections (Benson et al., 1970; Kieffer et al., 1971; Larson et al., 1971; Posner, 1973; Rogoff et al., 1974). The latter may contribute to severe cauda equina neurotoxicity occasionally seen following intrathecal administration of radiopharmaceuticals (Gold et al., 1972; Sackmann-Muriel et al.,

1976). Finally, continued leakage of CSF from the puncture site may lead to poor distribution of drug over the cerebral hemisphere convexities (Welch et al., 1975). These problems are avoided by intra-ventricular administration via an Ommaya reservoir ventriculostomy, which provides reliable entry of drug into CSF, followed by rapid and complete distribution throughout the subarachnoid space (Shapiro et al., 1975). Apart from these theoretical considerations, the above technique causes less discomfort to patients and in several studies has been shown to provide significant therapeutic advantage (Shapiro et al., 1977; Bleyer and Poplack, 1979; Ongerboer de Visser, 1983).

The most extensive experience acquired with intrathecal chemotherapy has been with the folic acid antagonist Methotrexate (Sculier, 1985). Therapeutic efficacy has been clearly demonstrated with this agent in leptomeningeal neoplasia complicating leukaemia and solid tumours (Hyman et al., 1965; McKelvey, 1968; Yap et al., 1982; Wasserstrom et al., 1982; Ongerboer de Visser et al., 1983). Alternative drugs to Methotrexate have been less extensively studied as intrathecal agents and include Cytosine Arabinoside, Thiotepa, Bleomycin, Mitozantrone and L-Asparaginase. Experience with Cytosine Arabinoside has been predominantly in leptomeningeal leukaemia, where clear therapeutic responses have been demonstrated (Wang and Pratt, 1970; Band et al., 1973). Systemically administered Cytosine Arabinoside is rapidly inactivated by deamination. Following intrathecal administration, CSF concentration remains high and the compound is not deaminated until it diffuses back into the circulation (Burchenal, 1983). Although experience to date would suggest it is less active than Methotrexate,

this may reflect lack of maintenance therapy in trials of its use (Seeldrayers and Hildebrand, 1984). Therapeutic responses have been reported in leptomeningeal neoplasia complicating solid tumours (Fulton et al., 1982), but in most studies Cytosine Arabinoside has been used in conjunction with Methotrexate (Giannone et al., 1986; Hitchins et al., 1987). Preliminary investigations with the alkylating agent Thiotepa have also demonstrated therapeutic efficacy in leptomeningeal tumour (Gutin et al., 1976, 1977). However, this highly lipid soluble agent rapidly escapes from the subarachnoid space and thus presents a major theoretical disadvantage (Wasserstrom et al., 1982). Intrathecal administration of L-Asparaginase in CNS leukaemia offers no therapeutic advantage over conventional parenteral routes of administration (Bleyer, 1977). Only minimal experience is reported with intrathecal Bleomycin and Mitozantrone (Ushio et al., 1987; Zuiable et al., 1985). Evaluation of these agents must therefore await further clinical usage. Existing studies of drug combinations administered intrathecally appear to show no advantage over the use of single agents (Giannone et al., 1986; Hitchins et al., 1987).

Prognosis, survival and response to therapy in neoplastic meningitis varies widely for different tumours. Radiosensitive primary central nervous system tumours such as medulloblastoma, usually respond well to treatment. In patients exhibiting clinical evidence of leptomeningeal dissemination at initial presentation, five year survival rates of 47% have been reported with surgery and craniospinal irradiation (Berry et al., 1981). In contrast, a much poorer prognosis is seen in patients with relapsed medulloblastoma,

presenting with isolated leptomeningeal disease following neuraxial prophylaxis. In one study of four such patients, treated with intrathecal and systemic chemotherapy \pm radiotherapy, median survival was 14 months, with one long term survivor at three years (Ushio et al., 1987). In contrast to medulloblastoma and other radiosensitive primary central nervous system tumours, the prognosis following leptomeningeal dissemination of malignant astrocytic tumours is poor. Although childhood tumours may show limited therapeutic response (Kandt et al., 1984), leptomeningeal gliomatosis in adults is usually accompanied by inexorable deterioration and death within three months (Yung et al., 1980; Awad et al., 1986; Ushio et al., 1987).

Leptomeningeal leukaemia occurs in 5-10% of children with acute lymphoblastic leukaemia, irrespective of the method of central nervous system prophylaxis (Green et al., 1980; Sullivan et al., 1982). Intrathecal methotrexate and/or craniospinal irradiation provide the mainstay of treatment, but systemic chemotherapy is often intensified because of the known associated risk of bone marrow relapse (Pinkerton and Chessells, 1984). Central nervous system remission, is obtained in over 90% of patients relapsing with leptomeningeal disease (Pinkerton and Chessells, 1984; Kun et al., 1984). Median survival following central nervous system relapse was 92 weeks in the study of Pinkerton and Chessells (1984). Although complete eradication of leptomeningeal disease may not occur, survival is more closely related to bone marrow relapse, which occurs in over 50% of patients achieving central nervous system remission (Nesbit et al., 1981; Pinkerton and Chessells, 1984).

Neoplastic meningitis complicating non-leukaemic systemic malignancy is generally associated with a poor prognosis and response to therapy (Wasserstrom et al., 1982). Median survival with untreated disease is often reported as 4-6 weeks, although this may reflect delayed clinical diagnosis (Little et al., 1974; Olson et al., 1974). Clinical responses to therapy are reported in 41%-58% of patients with median survivals varying from 2-5.8 months (Shapiro et al., 1977; Wasserstrom et al., 1982; Giannone et al., 1986). Therapeutic response and prognosis for individual tumour types varies considerably (Shapiro et al., 1977; Wasserstrom et al., 1982). Survival and therapeutic response data appear consistently more favourable for breast carcinoma (Yap et al., 1982; Schabet et al., 1986) than lung carcinoma (Aisner et al., 1981; Aroney et al., 1981; Balducci et al., 1984). Several clinicians have reported occasional patients with breast carcinomatous meningitis surviving for longer than 2-3 years (McKelvey, 1968; Posner, 1977; Wasserstrom et al., 1982; Ongerboer de Visser et al., 1983). In the large case series of Wasserstrom and colleagues, median survival of patients with breast carcinoma was 7.2 months with a range of 1-29 months. In lung carcinoma, clinical responses were seen in only 39% of patients, with a median survival of four months and no survivors over one year. A similarly dismal prognosis was observed in patients with leptomeningeal malignant melanoma (Wasserstrom et al., 1982).

Prognosis and therapeutic response in leptomeningeal lymphoma is comparatively favourable (Griffin et al., 1971; Bunn et al., 1976; Shapiro et al., 1977). In some patients leptomeningeal disease was completely eradicated by combined radiotherapy and intrathecal

chemotherapy (Bunn et al., 1976). In leptomeningeal Burkitt's lymphoma, therapeutic responses were seen in all patients following intrathecal chemotherapy, and long term survivors of over three years were reported (Ziegler and Bluming, 1971).

The current standard methods of intrathecal chemotherapy and external beam irradiation do not adequately fulfil therapeutic requirements for neoplastic meningitis. The prognosis for most patients with leptomeningeal tumour of systemic non-leukaemic origin is poor, and treatment is relatively ineffective. Although excellent therapeutic responses have been observed in chemo-radiosensitive tumours, significant neurotoxicity has become manifest in long term survivors (Section 1.11). Alternative pharmacological strategies are therefore required to increase drug/radiation delivery more specifically to tumour.

Inadequacies of drug distribution following intrathecal injection are not infrequent in leptomeningeal neoplasia, and tumour may escape exposure to anti-neoplastic agents. In these circumstances, a more uniform and widespread delivery of drug into tumour may follow systemic administration. However, in order to obtain effective drug levels in tumour/CSF, systemic chemotherapy must be given at high dosage to maximise tissue penetration. Although therapeutic responses in leptomeningeal leukaemia have been reported with systemic BCNU, Methotrexate, Cytosine Arabinoside and Pyrimethamine, dose limiting toxicity has generally prevented eradication of disease (Nies et al., 1965; Seeldrayers and Hildebrand, 1984; Frick et al., 1984; Geils et al., 1971).

External beam irradiation in sufficient dosage to eradicate leptomeningeal tumour may cause severe myelosuppression and irreversible damage to central nervous system parenchyma. As a possible solution to this therapeutic dilemma, several investigators have advocated the intrathecal instillation of radioactive gold colloid for leptomeningeal tumour (D'Angio et al., 1968; Gold et al., 1972; Fuller et al., 1974). The bulk of the radiogold (>90%) is absorbed and phagocytosed by arachnoidal tissue and hence its distribution is identical to that of leptomeningeal tumour (Metz et al., 1982). Radioactivity is predominantly in the form of beta-emission with maximum range of 3.6 mm. Leptomeningeal tissues are therefore exposed to high radiation doses sufficient to eradicate residual disease, whilst sparing the central nervous system parenchyma. Short-range radiation of this nature is not effective for tumour of several millimetres thickness. Therefore, external beam irradiation is initially employed to reduce tumour bulk so that residual disease can be encompassed within the effective range of the beta-particles. Although these techniques have accomplished eradication of leptomeningeal medulloblastoma, severe cauda equina neurotoxicity (Gold et al., 1972) has limited enthusiasm for its use. An alternative beta-emitting radiopharmaceutical, Yttrium-90-DTPA has been used intrathecally for treatment of leptomeningeal leukaemia. Although no serious toxicity was observed, most of the administered dose escaped from the central nervous system rapidly and no therapeutic response was demonstrated (Smith et al., 1976).

Application of recent immunobiological developments may provide therapeutic effect in patients with neoplastic meningitis. Impressive

results have followed intrathecal administration of lymphokine-activated killer (LAK) cells, with no associated toxicity (Shimizu et al., 1987). In leptomeningeal leukaemia, a therapeutic response was seen in one of five patients following intrathecal interferon (Misset et al., 1981). The development of monoclonal antibody technology has rekindled interest in antibody targeting of toxins, drugs or radionuclides to tumours. In an animal model of leptomeningeal B-cell leukaemia, intrathecal administration of ricin immunoconjugate produced dramatic therapeutic response with prolonged survival (Zovickian and Youle, 1988). Intrathecal radioimmunoconjugates have also produced therapeutic responses in patients with neoplastic meningitis (Lashford et al., 1988). Immunotherapeutic approaches to neoplastic meningitis have clearly achieved relative success in some patients. However, further investigation must follow before the efficacy of these techniques is established.

1.10 CENTRAL NERVOUS SYSTEM PROPHYLAXIS

Primary central nervous system tumours noted for their tendency to disseminate the leptomeninges include medulloblastoma, primitive neuroectodermal tumours (PNETs), malignant astrocytic tumours of childhood and germ cell tumours (Packer et al., 1987). In a study of 430 patients with medulloblastoma, McFarland and colleagues reported a 33% incidence of leptomeningeal dissemination (McFarland et al., 1969). Before this complication was appreciated, long term survival was unusual and disease failure frequently occurred outside the primary tumour site (Chatty and Earle, 1971; Packer et al., 1985).

Subclinical leptomeningeal dissemination at initial presentation was subsequently recognised as a major problem. Prophylactic craniospinal irradiation resulted in a remarkable improvement in prognosis with reported five year survival rates of 40%-60% in large series (Evans et al., 1979; Berry et al., 1982). Radiation schedules recommended by most investigators include 3500 cGy to the craniospinal axis with a further 1500-2000 cGy to the primary tumour site (Hornback, 1986). Based on observations with medulloblastoma, prophylactic craniospinal irradiation has also been recommended for children with germ cell tumours (Wara et al., 1979), posterior fossa anaplastic gliomas (Salazar, 1981), PNETs (Packer et al., 1987) and infratentorial malignant ependymomas (Pierre-Khan et al., 1983; Salazar et al., 1983).

Neoplastic meningitis complicating a variety of systemic malignancies, has been increasingly recognised in recent years. The changing incidence of this complication is best observed in a study of childhood lymphoblastic leukaemia. In the early part of this century, leukaemia of the central nervous system was considered uncommon (Fried, 1926). However, with the development of effective systemic chemotherapy, and consequent prolonged survival, leptomeningeal leukaemia became clinically apparent in over 50% of patients (Evans et al., 1970; Aur et al., 1972). In the absence of craniospinal prophylaxis, central nervous system relapse usually occurs within three years of diagnosis.

In a sequential series of studies at the St. Jude Children's Research Hospital, various prophylactic radiation schedules were investigated

in an attempt to reduce the incidence of subsequent leptomeningeal leukaemia (Aur et al., 1971, 1972; Hustu et al., 1973). Craniospinal irradiation (2400 cGy) reduced the incidence of central nervous system relapse from 55% to 4.4%. Restriction of radiation to the cranium (2400 cGy), and the addition of intrathecal methotrexate (5 doses) was shown to be equally effective and less myelotoxic (Aur et al., 1973). Prophylaxis was not compromised by reduction of the cranial irradiation component to 1800 cGy (D'Angio et al., 1981). In an attempt to avoid radiation toxicity, pure chemotherapy protocols have been evaluated in central nervous system prophylaxis. Although intrathecal chemotherapy alone has been reported as providing less effective prophylaxis (Green et al., 1980), this was contradicted in studies where prophylaxis commenced with induction and continued as maintenance therapy (Sullivan et al., 1982; Komp et al., 1982). An alternative combined prophylactic strategy has involved the intrathecal administration of radioactive colloidal gold (Au-198) and methotrexate (Metz et al., 1982; Doge and Hliscs, 1984). This beta-emitting radionuclide irradiates the leptomeninges, but the underlying neural parenchyma is theoretically spared (section 1.9). The incidence of central nervous system relapse using this technique is reported as 6.8% (Metz et al., 1982). Although clearly effective, enthusiasm for this method of prophylaxis has been limited by reports of cauda equina toxicity following intrathecal administration of radiocolloids (Gold et al., 1972; Sackmann-Muriel et al., 1976).

With current prophylactic methods, less than 10% of patients now have central nervous system relapse (Green et al., 1980; Sullivan et al., 1982). This has resulted in great improvement in quality of life, but

it is still not possible to state unequivocally that the successful prevention of meningeal relapse has prolonged survival (Nesbit et al., 1981).

The earliest pathological manifestation of central nervous system leukaemia is the presence of malignant cells within arachnoidal trabecula. Leukaemic blasts are released into the cerebrospinal fluid only following rupture of these structures (Price and Johnson, 1973). Cytological diagnosis is therefore only possible relatively late in the progression of this disorder. Indeed, less than 10% of children with acute lymphoblastic leukaemia have positive CSF cytology at initial presentation (Melhorn et al., 1970). However, the studies of Aur and colleagues indicate that leptomeningeal leukaemic infiltration is present in over 50% of such children (Aur et al., 1972). Existing therapeutic modalities are capable of eradicating latent, undetected leptomeningeal leukaemia, but are significantly less effective when disease becomes clinically overt (Aur et al., 1972). Thus, unless prophylactic measures are administered, eradication of leptomeningeal leukaemia is unlikely.

The situation for non-leukaemic systemic malignancy is somewhat different. For the majority of patients with solid tumours (excluding lymphomas), control of systemic disease is poor. Patients usually die of progressive systemic disease before developing clinically overt neoplastic meningitis. Clearly, central nervous system prophylaxis is not indicated in these circumstances. Any therapy directed towards the leptomeninges should be considered palliative, but nevertheless worthwhile.

1.11 NEUROTOXICITY

Prognosis in childhood leukaemia and medulloblastoma has vastly improved in recent years. The development of therapeutic strategies including ionising radiation and cytotoxic chemotherapy are largely responsible for this. Unfortunately, this sensational progress has been tempered somewhat by the occurrence of associated neurotoxicity. Both acute and subacute adverse neurological reactions to therapy have been reported, but there is also increasing recognition of late central nervous system effects. Clinical neurotoxicity may be categorised according to time of onset after initiation of therapy. Acute toxicity occurs within hours to days of treatment; subacute reactions begin days to weeks later; delayed toxicity may not become manifest for several months or years. In general, acute and subacute toxicity is either relatively benign or reversible and delayed toxicity more serious and permanent.

Acute neurotoxicity following conventional CNS irradiation is unusual. Reactions that do occur are usually mild (headaches, nausea, vomiting, anorexia and drowsiness), reversible and generally avoidable with low dose fractionation schedules (Sheline, 1975). Subacute neurotoxicity following CNS irradiation is more commonly seen. Whole brain irradiation doses of 1800 cGy and above, are frequently followed by a somnolence syndrome 5 to 7 weeks later (Freeman et al., 1973). The pathophysiology of this reaction is unknown, but suspected to involve temporary inhibition of myelin synthesis. The syndrome is completely reversible and symptoms usually abate within three weeks when radiation doses are less than 2400 cGy (Bleyer, 1981). A similar

transient myelopathy may sometimes occur at 8-16 weeks following spinal cord irradiation. Studies in long term survivors of medulloblastoma have revealed a high incidence of disordered growth and thyroid function (Wara et al., 1977; Oberfield et al., 1986). These effects have been attributed to radiation damage sustained by the hypothalamic/pituitary complex and thyroid gland. Further retardation of growth may arise from radiation damage to bony vertebral end-plates (Probert et al., 1986). The most serious and feared manifestation of delayed radiation neurotoxicity is cerebral necrosis. This usually begins insidiously, several months or years after treatment and often progresses to severe functional impairment or death. Necrosis occurs in areas of brain exposed to more than 6000 - 6500 cGy and is an unusual complication of modern techniques (Mikhael, 1979).

Significant neurotoxicity has also been associated with intrathecal chemotherapy. An aseptic chemical meningitis has been reported following instillation of methotrexate (Duttera et al., 1973) and Cytosine Arabinoside (Wang and Pratt, 1970). An encephalopathy or myelopathy may develop days or weeks following intrathecal methotrexate (Gagliano and Costanzi, 1976; Pizzo et al., 1979). Although symptoms may be permanent, they generally resolve after the drug is discontinued or its dosage reduced. Paraparesis has been less frequently reported following intrathecal Cytosine Arabinoside (Breuer et al., 1977; Wolff et al., 1979). A necrotising demyelinating leukoencephalopathy may occur months to years after the onset of methotrexate therapy (Price and Jamieson, 1975; Bleyer, 1977c). The clinical presentation is one of progressive neurological deterioration

beginning insidiously and evolving into severe dementia, dysarthria, dysphagia, ataxia, spasticity, seizures and coma. This complication has followed intrathecal or intravenous methotrexate alone, but risks of its occurrence are significantly increased by the addition of cranial irradiation (Bleyer, 1981). Neurotoxicity following intrathecal methotrexate appears to be directly related to CSF drug concentration. However, toxicity may be enhanced by the presence of leptomeningeal tumour (Bleyer et al., 1973) and/or partial obstruction of CSF pathways (Shapiro et al., 1973).

The aforementioned examples of neurotoxicity are well established complications of central nervous system irradiation and/or intrathecal chemotherapy. However, more subtle subclinical neurotoxicity has become increasingly recognised from studies of long term survivors of childhood leukaemia and medulloblastoma (Moss et al., 1981; Le Baron, 1986). These studies have shown that intellectual, academic, motor and neuropsychological deficits are more frequent in these children, and presumably related to previous chemoradiotherapy. These findings are also consistent with the increased incidence of cranial CT scanning abnormalities detected in asymptomatic leukaemic children following central nervous system prophylaxis (Peylan-Ramu et al., 1978). It is now clearly apparent that long term neurotoxic sequelae are relatively common following therapy for medulloblastoma and leukaemia. Fortunately, for most patients, permanent neurological disability is minimal, but nevertheless reflects our inability to target conventional therapeutic modalities specifically to tumour.

1.12 OUTLINE OF PRESENT STUDY

A variety of relevant issues arise from the previous review of neoplastic meningitis, but two major problems are highlighted. Firstly, it is clear that current therapeutic methods are considerably more effective for minimal disease. This emphasizes the importance of early diagnosis and therefore the need to develop more sensitive diagnostic methods. Secondly, it is also apparent that with current therapy, delayed neurotoxic sequelae are not uncommon in long term survivors. This results from our inability to target conventional therapeutic modalities specifically to tumour. New therapeutic strategies are therefore required to target tumour more specifically, and so avoid the problems of dose limiting toxicity seen with current methods. This study investigates applications of monoclonal antibody technology in the development of refined methods of diagnosis and therapy in neoplastic meningitis.

The time-honoured method of diagnosis in neoplastic meningitis is the demonstration of malignant cells in CSF by cytological techniques. The addition of monoclonal antibody immunocytochemistry to existing cytological methods is studied in 12 patients with neoplastic meningitis. The value of this technique in terms of diagnostic refinement is assessed and discussed.

Biochemical tumour marker technology has offered the potential to achieve early diagnosis in neoplastic meningitis. However, assays for existing markers have not provided adequate sensitivity and specificity to ensure widespread clinical use. In this study the

discovery of a monoclonal antibody defined CSF tumour marker for carcinomatous meningitis is reported, together with the development of a radioimmunoassay for its detection. Its diagnostic value is assessed in a study of 100 patients (carcinomatous meningitis 20; non-carcinomatous neoplastic meningitis 20; systemic carcinoma - no neurological disease 20; demyelinating and inflammatory disorders 20; normal 20).

Finally, therapeutic applications of monoclonal antibodies are reported in a study of 15 patients with neoplastic meningitis. In all patients, I-131 radiolabelled monoclonal antibody was administered intrathecally via an Ommaya reservoir ventriculostomy. Pharmacokinetics and biodistribution of immunoconjugate are discussed together with aspects of dosimetry and clinical therapeutic response.

CHAPTER 2

GENERAL TECHNIQUES

2.1 MATERIALS

Monoclonal antibodies	Section 2.2
Phosphate buffered saline (PBS)	Sigma Chemical Company
Tris buffered saline (TBS)	Sigma Chemical Company
Sodium iodide - 125: IMS30	Amersham International PLC
Sodium iodide - 131: IBS30	Amersham International PLC
Sephadex G-50	Pharmacia Fine Chemicals
Polyclonal Mouse IgG	Sigma Chemical Company
Iodogen	Sigma Chemical Company
May-Grunwald staining solution	BDH Chemicals Ltd
Giemsa's staining solution	BDH Chemicals Ltd

2.2 MONOCLONAL ANTIBODIES

The monoclonal antibodies used in this study are referred to below. Their tissue binding characteristics as defined by immunohistochemical methods are briefly described, together with the nature of the defined antigen if known.

UJ13A IgG2a. This antibody was raised against an extract of 16 week human foetal brain and defines a glycoprotein antigen expressed by normal and neoplastic derivatives of neuroectoderm, with the exception of malignant melanoma (Allan et al., 1983) (Fig. 2.1).

UJ181.4 IgG1. This antibody was raised against an extract of 16 week human foetal brain and defines an oncofoetal antigen expressed by foetal brain and primitive neuroectodermal tumours. The antigen is not detected in adult brain by immunohistochemical methods (Bourne et al., 1989).

M340 IgG1. This antibody was raised against human medulloblastoma and defines an oncofoetal antigen expressed by human foetal brain and primitive neuroectodermal tumours. The antigen is not detected in adult brain by immunohistochemical methods. Although immunohistochemical reactivity is very similar to UJ181.4, the antibody defines a separate epitope (Bourne et al., 1989).

ME1-14 IgG2a. This antibody defines a 240 kDa. glycoprotein antigen expressed by neuroectodermal tumours and malignant melanoma (Carrel et al., 1980).

Fig. 2.1

Immunofluorescence staining of malignant glioma with monoclonal antibody UJ13A (x500).

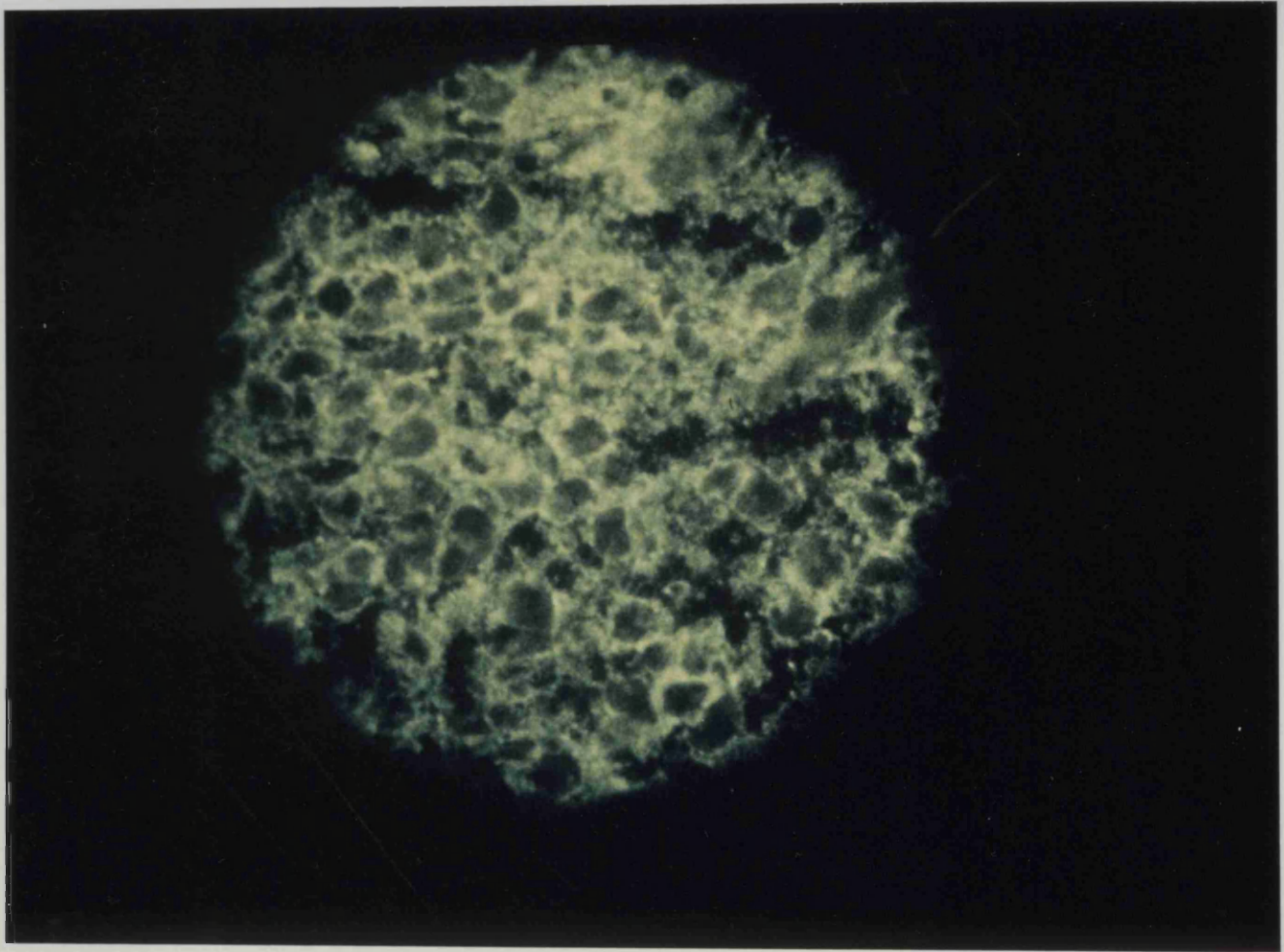


Fig. 2.1

9.2.27 IgG2a. This antibody defines a separate epitope to that of ME1-14 on the 240 kDa. melanoma associated glycoprotein. Immunohistochemical tissue staining characteristics are similar to those of ME1-14.

81C6 IgG2b. This antibody was raised against the human malignant glioma cell line U254 MG and defines a human glioma mesenchymal extracellular matrix antigen (GMEM) which is also expressed in the extracellular matrix of kidney, liver and spleen (Bourdon et al. 1983). The antigen has recently been identified as the oligomeric glycoprotein tenascin (Bourdon et al., 1985; Chiquet-Ehrismann et al., 1986).

HMFG1 IgG1. This antibody was raised against an extract of human milk fat globule and defines a glycoprotein antigen expressed by normal and neoplastic derivatives of epithelium (Taylor-Papadimitriou et al., 1981) (Fig. 2.2). The antigen has been identified as polymorphic epithelial mucin, PEM (Gendler et al., 1988; Burchell et al., 1989).

HMFC2 IgG1. This antibody was raised against human milk fat globule and cultured milk epithelial cells (Taylor-Papadimitriou et al., 1981). Its target antigen is human PEM, but it defines a separate epitope to HMFG1 (Gendler et al., 1988).

Fig. 2.2

Immunoperoxidase staining of ovarian carcinoma with monoclonal antibody
HMFG1 (x500).

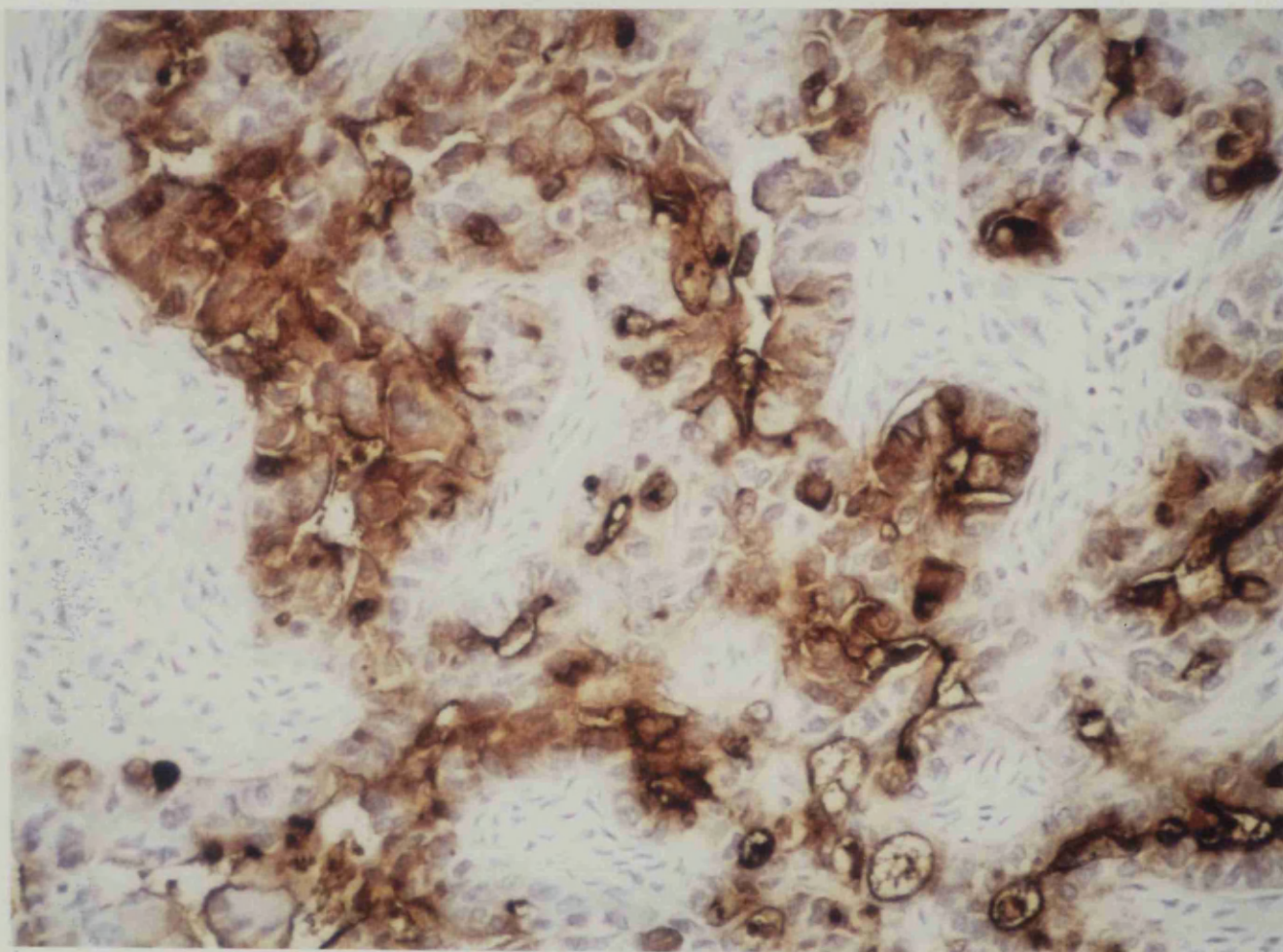


Fig. 2.2

CAM 5.2 IgG2a. This antibody was raised against the colon carcinoma cell line HT29 and defines the intracellular low molecular weight cytokeratins (39, 43 and 50 kDa) expressed by normal and neoplastic derivatives of epithelium (Makin et al., 1984).

AUA1 IgG1. This antibody defines a 35 kDa. cell surface antigen expressed by normal and neoplastic derivatives of epithelium (Arklie, 1981).

DAKO-LC IgG1. (Dakopatts, Denmark). The marketed preparation contains 2 monoclonal antibodies PD7/26 and 2B11. This cocktail defines the leucocyte common antigen (LCA) present on the surface of the majority of human leucocytes and their neoplastic counterparts (Warnke et al., 1983; Meis et al., 1986).

45.6 IgG2b. This monoclonal antibody is the product of mouse myeloma cell line 45.6 TG1.7 and exhibits no demonstrable binding to human tissues (Margulies et al., 1976).

2.3 RADIOLABELLING

Monoclonal antibody iodinations with I-131 and I-125 (Amersham International PLC. UK) were performed using the stationary phase chloramide, iodogen (Sigma Chemical Co. UK) (Fraker and Speck, 1978).

PREPARATION OF IODOGEN TUBES

Borosilicate glass vials (12 x 37 mm.) (Jencons Scientific Ltd. UK) were rinsed with acetone and air dried. Iodogen was dissolved in chloroform to a concentration of 100 ug/ml. 100 ul. aliquots of iodogen in chloroform (10 ug. iodogen) were then dispensed into the glass vials and evaporated under a stream of nitrogen gas. A fine deposit of iodogen remained at the base of the vials which were then sealed and stored at 4°C.

REACTION PROCEDURE

Monoclonal antibody in 0.15 M PBS was dispensed into an iodogen tube with a stoichiometrically appropriate quantity of radioiodine (sodium iodide). The reaction vessel was gently agitated for 10 minutes before removal of products. Radioiodinated monoclonal antibody was then separated from free radioiodine by passage through a sephadex G-50 column. Eluted radioimmunoconjugate was then diluted in 1% HSA in PBS prior to sterilisation by millipore filtration.

2.4 RADIOACTIVITY MEASUREMENT

Quantitative radioactivity measurement was performed with an automated gamma counter (Kontron Analytical, UK) interfaced with a BBC microcomputer for rapid data acquisition (Fig 2.3). Radionuclides used in this study were I-131 and I-125. Programmable rack systems were available for measurement of individual isotopic activities. A dual channel facility was also available for determining individual isotopic activities in mixtures of I-131 and I-125. In this situation, a correction was applied for spillover of I-131 radiation into the I-125 counting channel.



Fig. 2.3

2.5 QUALITY CONTROL OF RADIOIMMUNOCONJUGATES

Structural integrity of radioimmunoconjugate was assessed by trichloroacetic acid (TCA) precipitation and gel filtration chromatography. Biological function was assessed by radiobinding assay techniques to define the radioimmunoreactive fraction (Lindmo et al., 1984; Lindmo and Bunn, 1986).

2.5.1 TRICHLOROACETIC ACID (TCA) PRECIPITATION

200 ul. of cold 15% TCA was added to an equal volume of radioimmunoconjugate. Following vortex mixing and incubation at 4°C for 30 minutes, the suspension was centrifuged at 11,000 x g for 10 minutes. The supernatant was removed and a further 500 ul. of TCA added to the remaining precipitate. Following a repeat centrifugation, the second supernatant was removed. The precipitate and both supernatants were then assayed for radioactivity. Protein bound iodine was then estimated as the percentage of radioactivity within the precipitate.

2.5.2 GEL FILTRATION CHROMATOGRAPHY

Samples of radioimmunoconjugate were loaded onto a sephacryl S300 gel column (1.6 x 60 cm.) and eluted through the gel bed against gravity (Fig. 2.4). Elution buffer (PBS + 0.05% sodium azide) was pumped through the column at approximately 6 ml./hour and sequential 2 ml. fractions collected. Consecutive fractions were then assayed for radioactivity and displayed as an elution profile (Fig. 2.5).

Fig. 2.4

Sephacryl S300 gel chromatography column and automated fraction collector.



Fig. 2.4

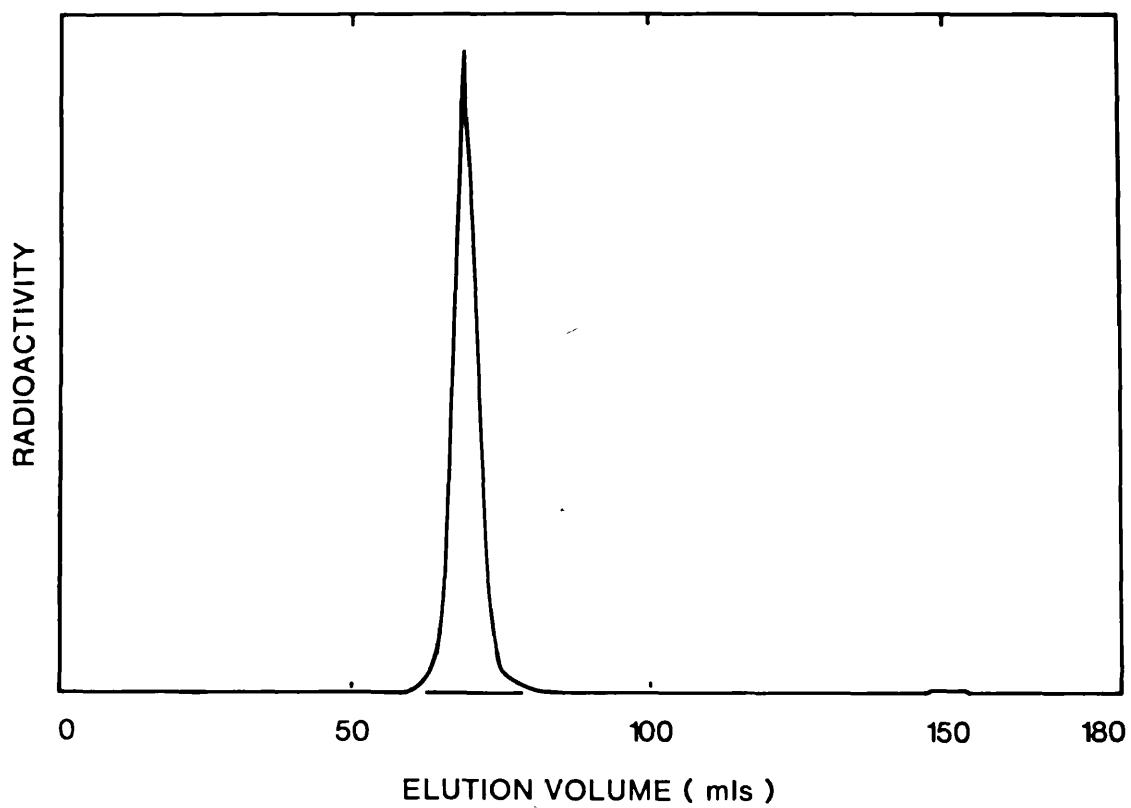


Fig. 2.5.

Elution Profile of Monoclonal Antibody ME1-14 Labelled
with I-131.

2.5.3 RADIOBINDING ASSAY TECHNIQUES

Solid and liquid phase radioimmunoassay (RIA) systems were developed to determine the immunoreactive fraction (immunoreactivity) of monoclonal antibody radioimmunoconjugates. This parameter reflects the percentage of radiolabelled molecules in a preparation that retain immunological binding activity. A solid phase RIA was used for monoclonal antibodies defining antigens associated with membrane fractions of tissue homogenates - 81C6, UJ13A, UJ181.4, M340 and ME1-14. Although monoclonal antibodies HMFG1 and HMFG2 define an epithelial membrane antigen (polymorphic epithelial mucin), this glycoprotein was extensively liberated into the buffer supernatant during tissue homogenisation. Prepared tissue extracts therefore contained little antigen and this was further reduced during centrifugation washing. Solid phase RIA systems to assess immunoreactivity of HMFG1 and HMFG2 were consequently unsatisfactory and so a liquid phase RIA was devised using purified preparations of the antigen. Both forms of immunoreactivity assay were performed in massive antigen excess.

SOLID PHASE RIA

D-54 MG (Malignant Glioma) homogenate was obtained from Professor D.D. Bigner (Preuss Laboratory for Brain Tumor Research, Duke University Medical Center, Durham, USA). This preparation contains extensive quantities of antigens defined by monoclonal antibodies 81C6 and ME1-14. Human adult brain homogenate was prepared in this laboratory to provide antigen extracts for monoclonal antibodies UJ13A, UJ181.4 and M340. Although the antigens defined by monoclonal antibodies

UJ181.4 and M340 are not detected in adult brain by immunohistochemical techniques (Bourne et al., 1989), significant quantities are detected by radioimmunoassay (R.P. Moseley, unpublished observation).

Fresh brain tissue was blended in PBS and the resulting slurry centrifuged at 1,500 x g for 15 minutes. Following discharge of the supernatant and a further centrifugation wash, the precipitate was resuspended in PBS. Brain tissue homogenate was then stored as 1.5 ml. aliquots in plastic microtubes (13 x 39 mm.) (Sarstedt, UK) at -70°C.

The solid phase immunoreactivity RIA was a double isotope differential radiobinding assay using monoclonal antibody 45.6 as a non-binding control. Extensive radioimmunoassay and immunohistochemical studies had previously failed to demonstrate binding of 45.6 to any human tissue (R. P. Moseley, unpublished observation). The test antibody labelled with I-131 was mixed with I-125 labelled 45.6 and diluted in PBS to a final concentration of 25-250 ng/ml. Aliquots of 200 ul. were then dispensed into triplicate homogenate tubes which were incubated at room temperature overnight. Tubes were then spun at 11,000 x g for 10 minutes and the supernatant discarded. Two further centrifugation washes were performed before counting the activity of both isotopes in the precipitate. Specific binding was determined by subtracting percentage binding of 45.6 from that of the This parameter was designated as the immunoreactive fraction (immunoreactivity).

LIQUID PHASE RIA

HMFG1 and HMFG2 bind separate antigenic determinants on the high molecular weight glycoprotein - polymorphic epithelial mucin, PEM (Gendler et al., 1988; Burchell et al., 1989). Although both epitopes are expressed on the fully glycosylated mucin, HMFG2 is exhibited more prominently when peripheral carbohydrate side-chains are stripped from the molecule by treatment with anhydrous hydrogen fluoride (Gendler et al., 1988). Concentrated solutions of fully glycosylated and partially stripped mucins in PBS were kindly provided by Dr Joyce Taylor-Papadimitriou (Department of Epithelial Cell Biology, ICRF, London, UK).

The assay procedure involved incubation of 5-25 ng. of radiolabelled HMFG1/HMFG2 with the appropriate mucin preparation in massive antigen excess. The antibody-antigen solution mixture was then passed through a sephacryl S 300 gel column (1.6 x 60 cm.) and fractions assayed for radioactivity. Radioactivity eluted as a bimodal profile with high molecular weight antibody-antigen complexes (bound antibody) appearing prior to unbound antibody (Fig. 2.6). The percentage of bound antibody was evaluated by integration of the elution profile and determined as the immunoreactive fraction (Fig. 2.7).

Fig 2.6

Sephacryl S300 gel chromatography of radiolabelled monoclonal antibody HMFG1. Solid line depicts elution profile following pre-incubation in HMFG1-mucin antigen excess.

Fig 2.7

Elution profile of radiolabelled monoclonal antibody HMFG1 pre-incubated in HMFG1-mucin antigen excess. Shaded area of profile represents bound antibody and the immunoreactive fraction is obtained by integration.

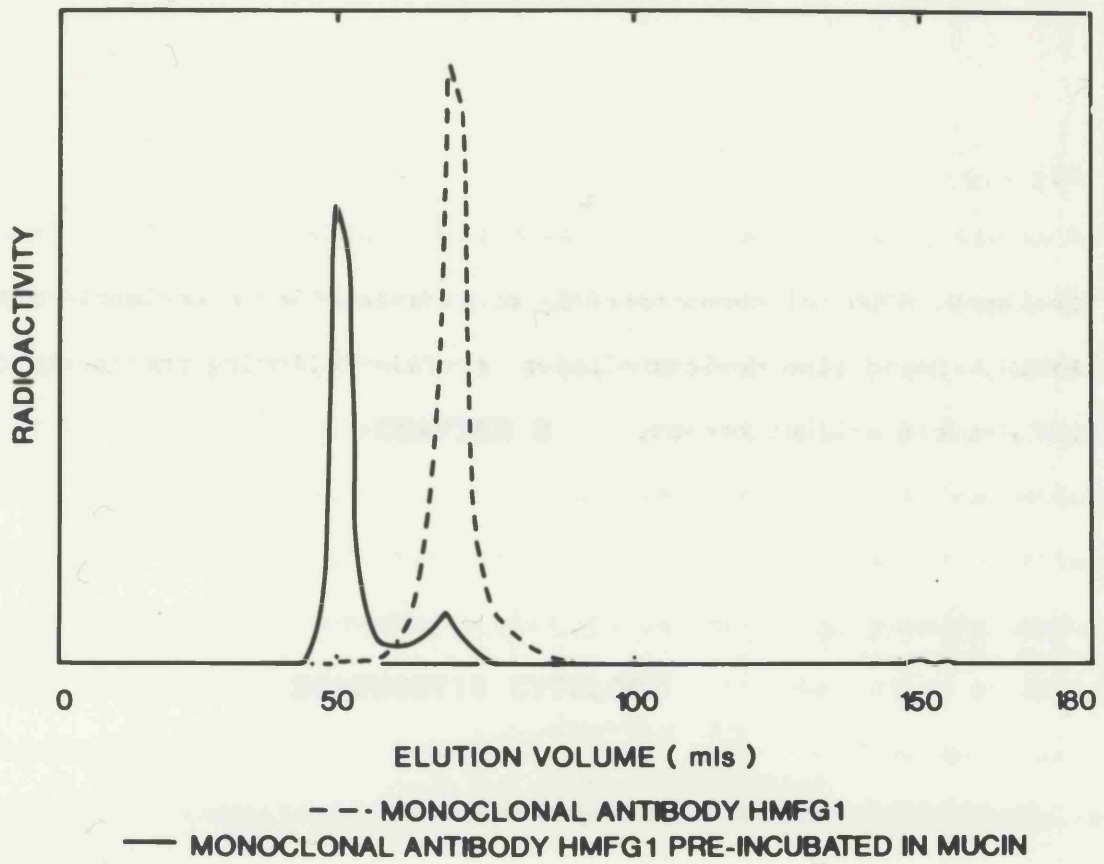


Fig. 2.6

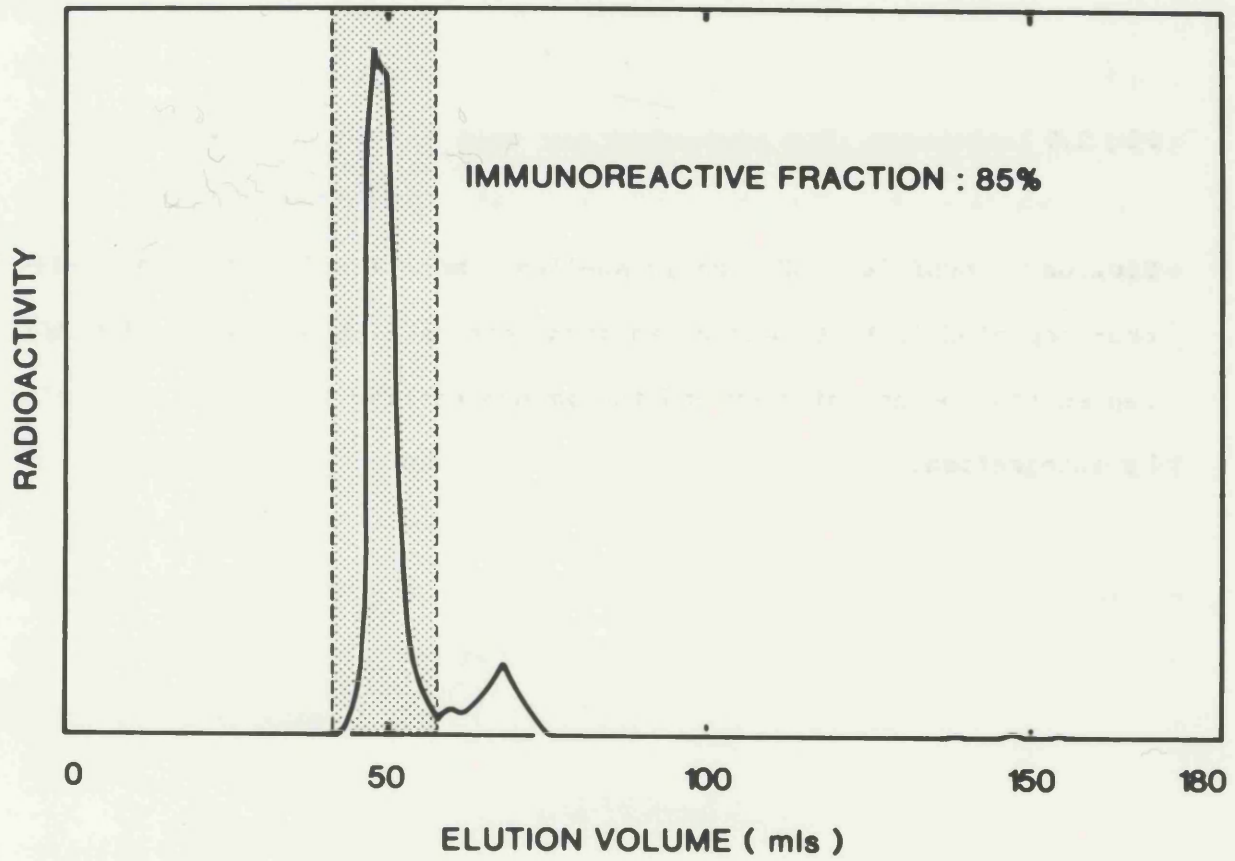


Fig. 2.7

CHAPTER 3

DIAGNOSTIC CYTOLOGY

3.1 INTRODUCTION

The time honoured method for diagnosis of neoplastic meningitis is by the demonstration of malignant cells in CSF. However, conventional CSF cytological methods are frequently unsatisfactory with wide variation in reported diagnostic sensitivity (Garson et al., 1985). When malignant cells are demonstrated by such techniques, it is frequently impossible to determine the neoplastic cell type, which can be of vital importance to clinical management when the nature of the primary tumour is unknown. The superior diagnostic accuracy of monoclonal antibody immunocytology of CSF has previously been reported (Coakham et al., 1984b) and continues to be used on a regular basis in our laboratory in conjunction with conventional cytological methods. When neoplastic meningitis is the first manifestation of malignant disease, the use of a diagnostic panel of monoclonal antibody markers enables characterisation of the primary tumour type (Coakham et al., 1984a,b; Vick et al., 1987). It is also our experience that monoclonal antibody immunocytology provides greater diagnostic sensitivity (Coakham et al., 1984b; Moseley et al., 1989a), although this is contested by some (Boogerd et al., 1987).

We have recently undertaken a study of 12 consecutive cases of neoplastic meningitis seen in the Department of Neurosurgery at Frenchay Hospital, Bristol. In all patients, lumbar CSF was examined by conventional and immunocytochemical methods, enabling an evaluation of these techniques.

3.2 METHODS

3.2.1 PATIENTS

Lumbar CSF was obtained from 12 patients with neoplastic meningitis. CSF cytospin preparations were examined by conventional and immunocytochemical methods.

3.2.2 MONOCLONAL ANTIBODIES

Immunocytochemistry was performed with a panel of monoclonal antibodies defining the major tumour categories associated with neoplastic meningitis. The panel of 8 monoclonal reagents comprised markers for neuroectodermal tumours, carcinomas, lymphoid tumours and melanoma.

Neuroectodermal tumours: UJ13A, UJ181.4 and M340

Carcinomas: HMFG1, CAM 5.2

Lymphomas: DAKO-LC

Melanoma: ME1-14, 9.2.27

3.2.3 CSF CYTOLOGY

Cytological preparations were made on gelatine coated slides using a Shandon Cytospin 2 cytocentrifuge (Shandon Southern Products Ltd, UK). Five drops of CSF were loaded into the cytospin chamber and centrifuged at 800 rpm. for 10 minutes. Slides were then air dried prior to staining with May-Grunwald Giemsa or immunocytochemical methods.

MAY-GRUNWALD GIEMSA (MGG) STAINING

Slides were immersed in May-Grunwald staining solution (BDH Chemicals Ltd, UK) for 3 minutes and then rinsed in distilled water. The slides were then placed in Giemsa's staining solution (BDH Chemicals Ltd, UK) diluted to 10% v/v in tap water. After 15 minutes, slides were rinsed in distilled water and air dried prior to mounting in DPX.

IMMUNOFLUORESCENCE CYTOCHEMISTRY

Slides were immersed in phosphate buffered saline (PBS) for 5 minutes. Excess PBS was removed and 50 ul. of the appropriately diluted primary antibody applied and incubated for 30 minutes at room temperature. Slides were then washed twice in PBS (2 x 5 minute washes) and incubated for a further 30 minutes at room temperature with 50 ul. of appropriately diluted fluorescein conjugated rabbit anti-mouse immunoglobulin (Dakopatts, Denmark). Unbound fluorescein immunoconjugate was removed by two further 5 minute washes in PBS and the slides finally mounted in 90% glycerol/10% PBS (Citifluor Ltd, London, UK). Slides were then examined using a Zeiss standard microscope equipped for epifluorescence.

IMMUNOPEROXIDASE CYTOCHEMISTRY

Dako Quick Staining Kit (Dako Ltd, USA).

Slides were immersed in Tris buffered saline (TBS) for 2 minutes. Excess TBS was removed and 50 ul. of the appropriately diluted primary

antibody applied and incubated for 2 minutes at room temperature. Slides were then washed twice in TBS (2 x 2 minute washes) and incubated for a further 3 minutes at room temperature with 50 ul. of appropriately diluted biotinylated rabbit anti-mouse immunoglobulin. Slides were then washed twice in TBS (2 x 2 minute washes) and incubated for a further 90 seconds at room temperature with 50 ul. of avidin-peroxidase conjugate. Unbound peroxidase conjugate was then removed by 3 further 2 minute washes in TBS. Hydrogen peroxide was diluted to 1 in 30 of distilled water and 100 ul. added to 10 mls. of freshly prepared 3, 3' - Diaminobenzidine tetrahydrochloride (Sigma Chemical Co., UK) in TBS (0.5 mgm./ml.). The solution was then filtered through a 0.45 micron millipore membrane directly onto the cytospin preparations and incubated for 10 minutes in a fume cupboard. Slides were then rinsed and washed 3 times for 5 minutes in TBS before counterstaining with 10% Harris's hematoxylin. Preparations were then placed in tap water for 5 minutes prior to dehydrating through alcohols and xylene. Slides were then mounted in DPX prior to examination by light microscopy.

3.3 RESULTS

Brief case studies are presented together with demonstrations of CSF cytospin preparations using conventional and immunocytochemical techniques (Figs. 3.1 - 3.12)

CASE 1

58 year old male presenting with a six week history of nausea, vomiting, weight loss and difficulty walking. Examination revealed left facial weakness and severe paraparesis. Chest X-ray revealed a left apical lung lesion. Cranial CT scanning and myelography were normal.

DIAGNOSIS: Large cell lung carcinoma .

Fig. 3.1a

CSF cytospin (MGG x 500). Tumour cells with pleomorphic
mononuclear cell infiltrate.

Fig. 3.1b

CSF cytospin (immunoperoxidase x 500). Clump of tumour cells staining
with monoclonal antibody HMFG1.

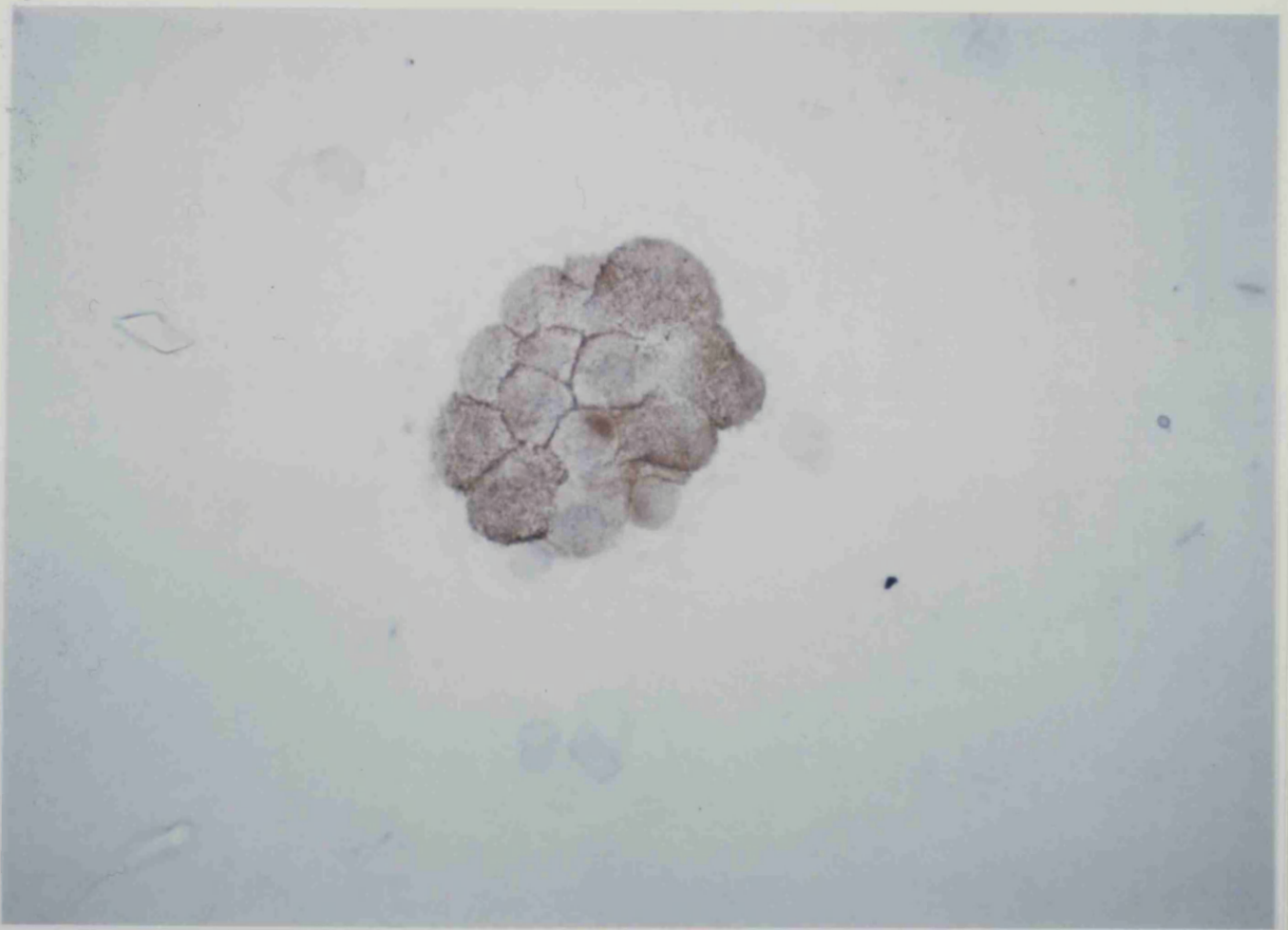
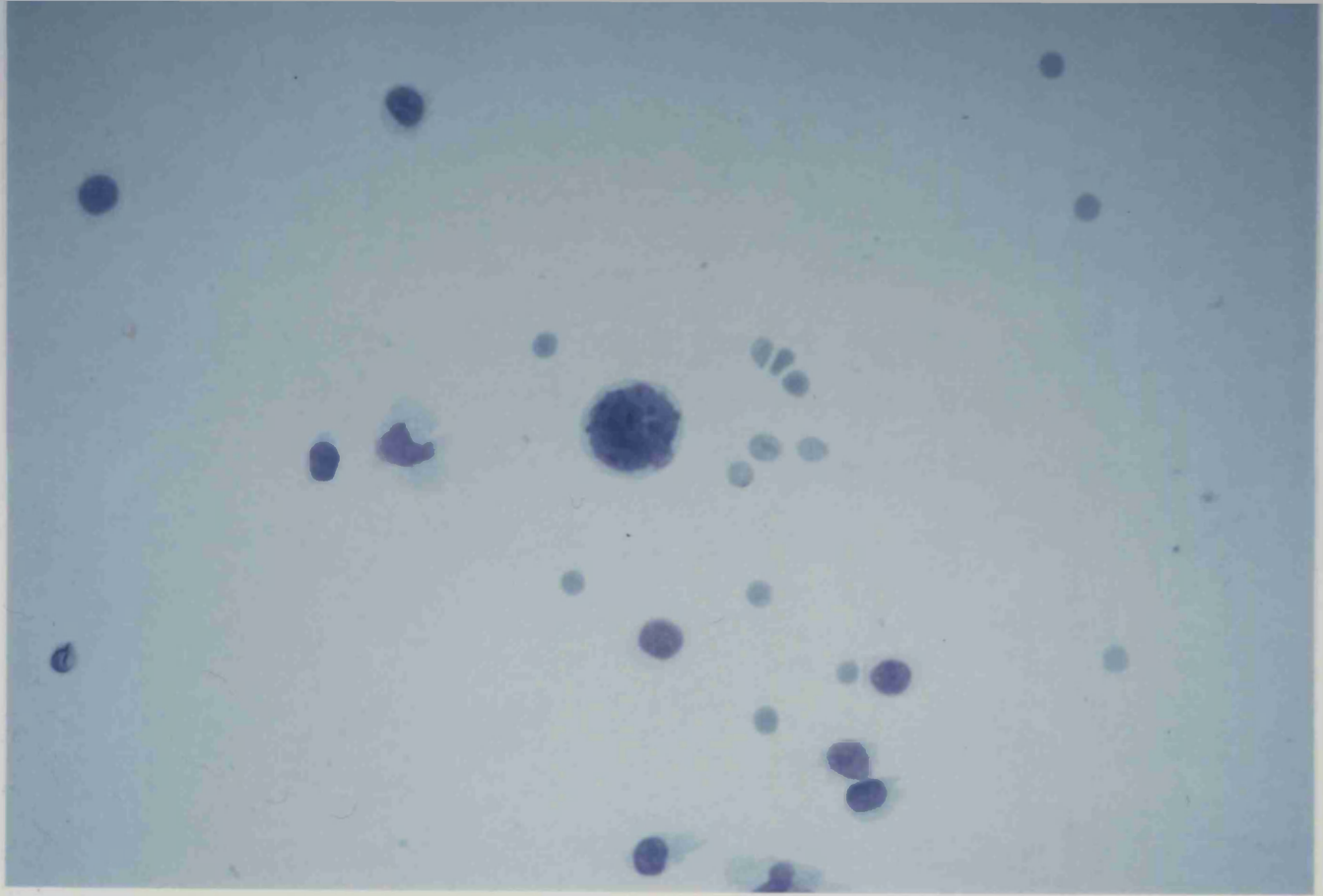


Fig. 3.1 a/b

CASE 2

65 year old male presenting with a three month history of progressive headaches and dementia. Examination revealed bilateral papilloedema and evidence of mental slowing. Chest X-ray was normal. Cranial CT scanning revealed a communicating hydrocephalus and myelography was normal.

DIAGNOSIS: Malignant lymphoma

Fig. 3.2a

CSF cytospin (MGG x 500). Numerous large malignant cells with erythrocyte rosetting.

Fig. 3.2b

CSF cytospin (immunoperoxidase x 500). Malignant cells staining with antibody DAKO-LC.

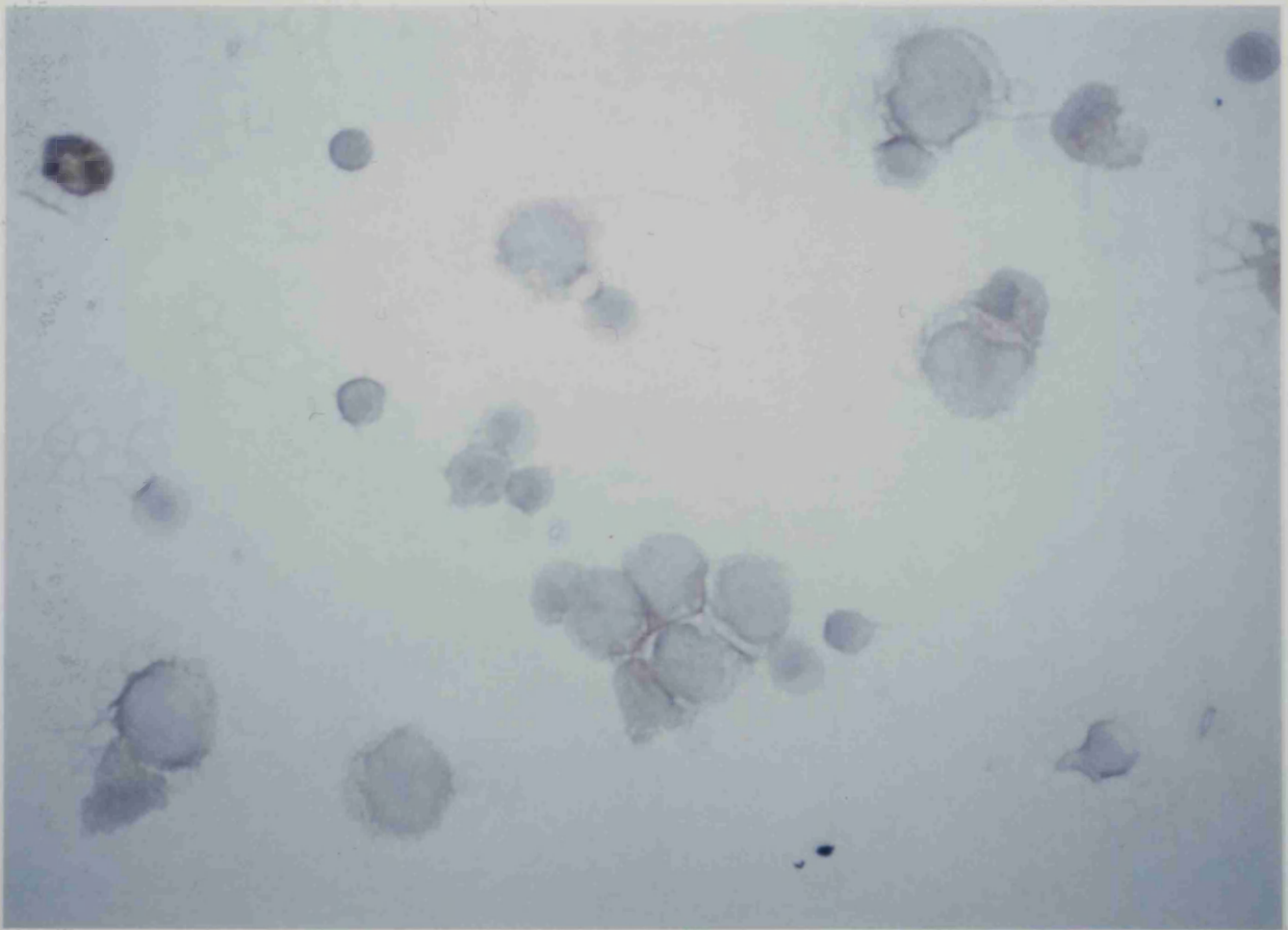
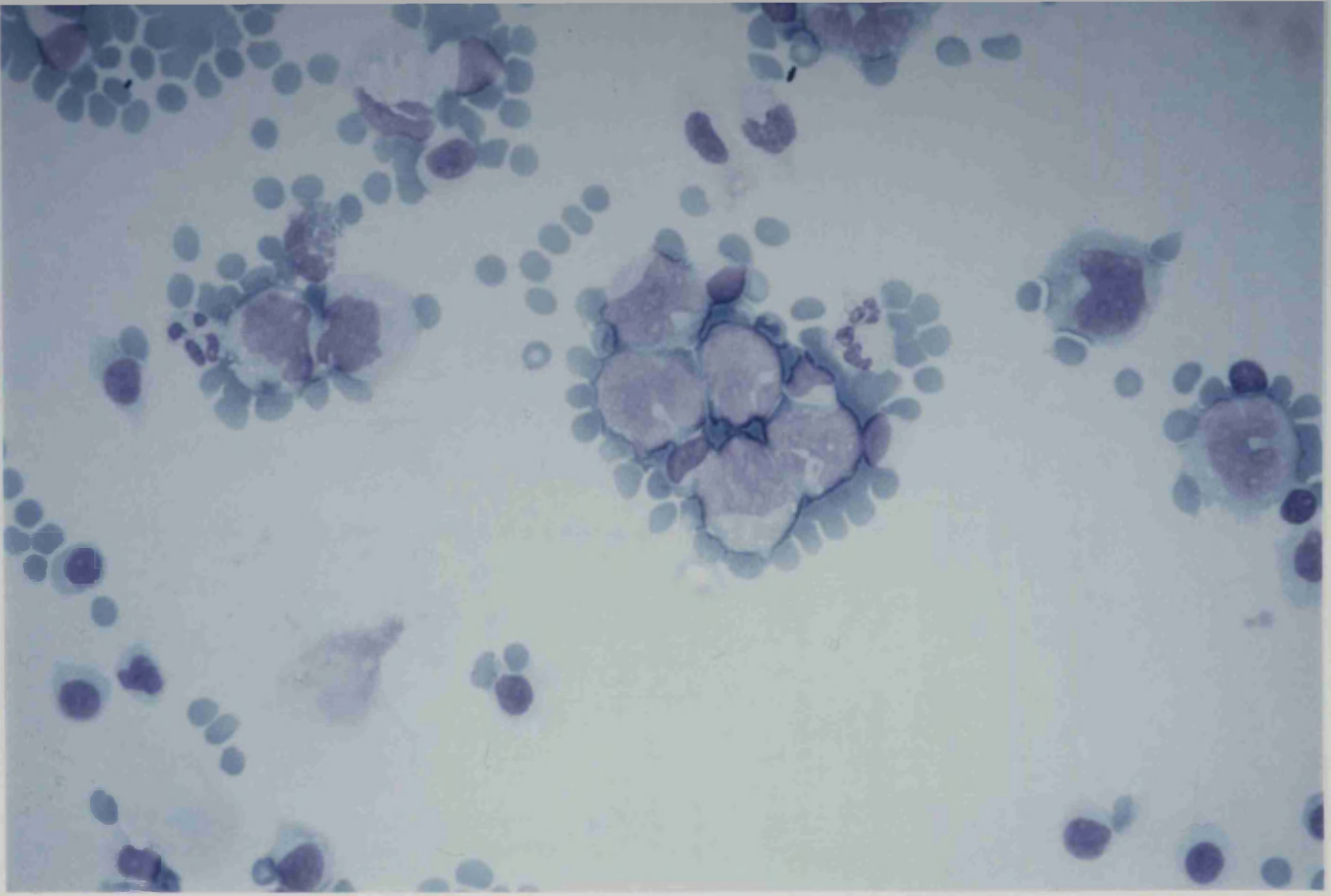


Fig. 3.2 a/b

CASE 3

68 year old male presenting with cough and haemoptysis over three months and more recent lower limb weakness. Examination findings revealed a moderately severe paraparesis. Chest X-ray revealed a hilar mass in the right lung. Cranial CT scanning was normal and myelography revealed multiple intradural tumour deposits.

DIAGNOSIS: Small cell lung carcinoma

Fig. 3.3a

CSF cytospin (MGG x 500). Pleomorphic mononuclear cell infiltrate with surrounding erythrocytes.

Fig. 3.3b

CSF cytospin (immunoperoxidase x 500). Carcinoma cell staining with monoclonal antibody CAM 5.2.

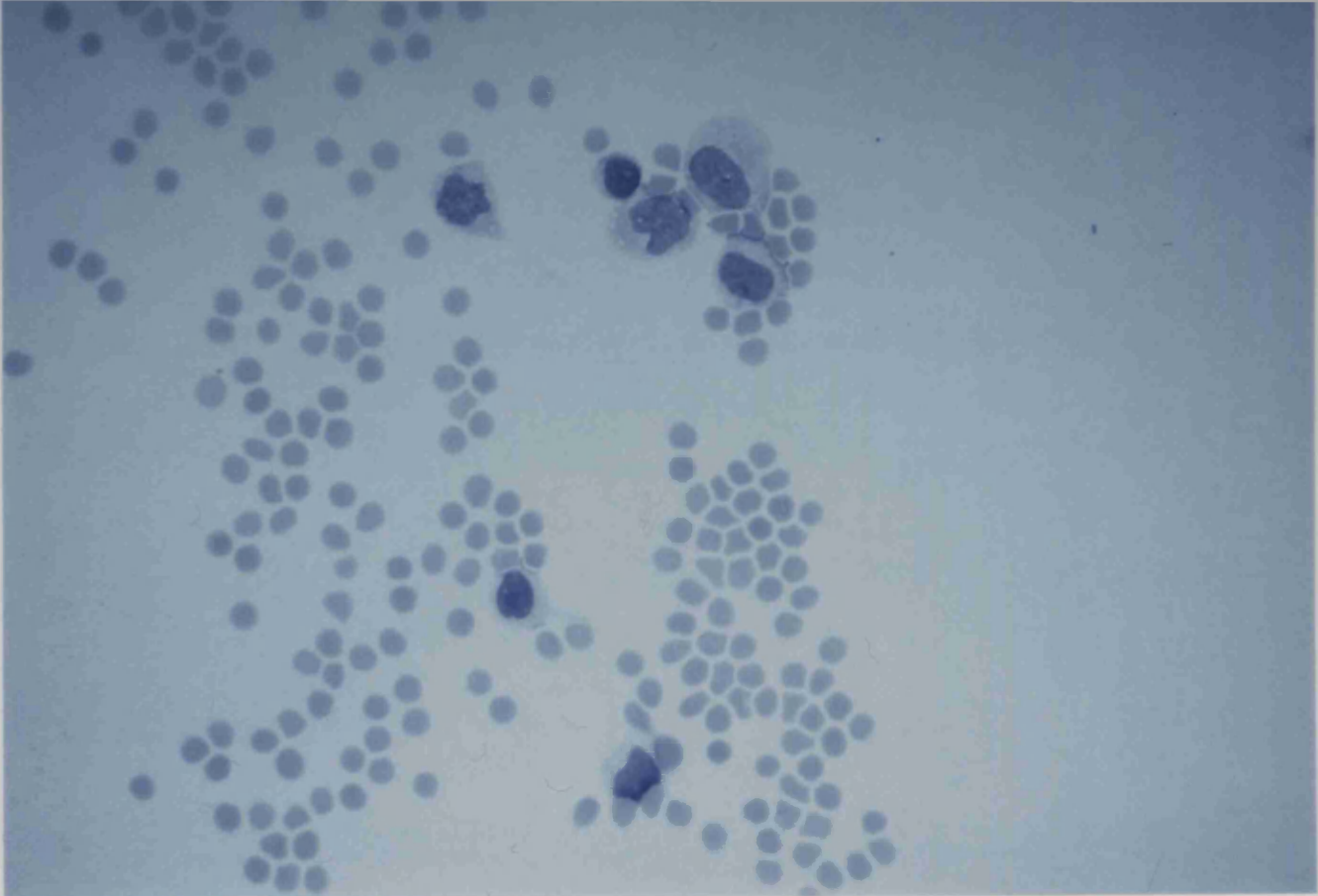


Fig. 3.3 a/b

CASE 4

36 year old female presenting with headaches, deafness, facial weakness and diplopia, following a mastectomy five years previously. Examination revealed bilateral papilloedema, unilateral facial weakness and deafness, together with bilateral sixth nerve palsies.

DIAGNOSIS: Breast carcinoma

Fig. 3.4a

CSF cytospin (MGG x 500). Clump of malignant cells.

Fig. 3.4b

CSF cytospin (immunoperoxidase x 400). Clump of tumour cells staining with monoclonal antibody CAM 5.2.

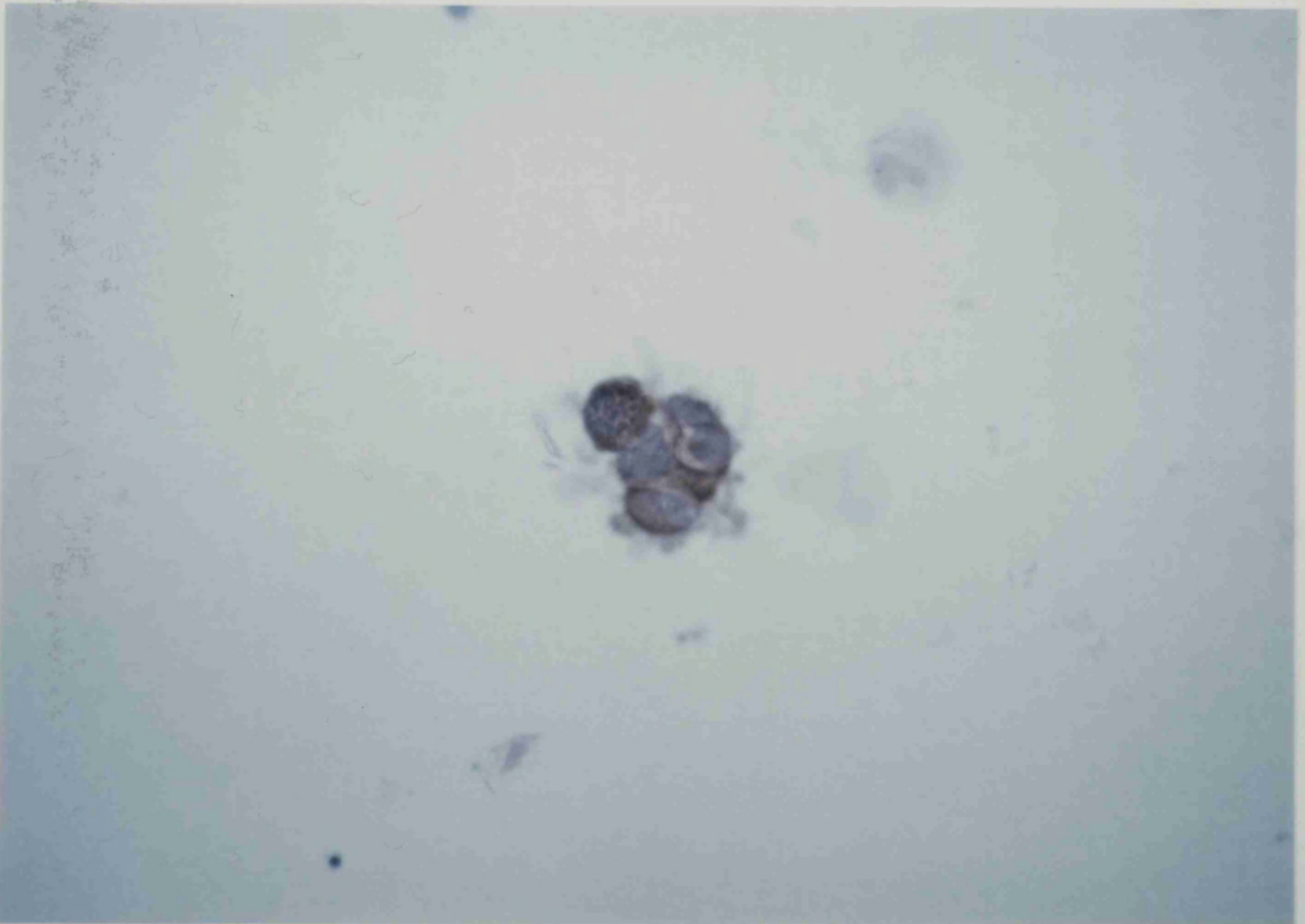
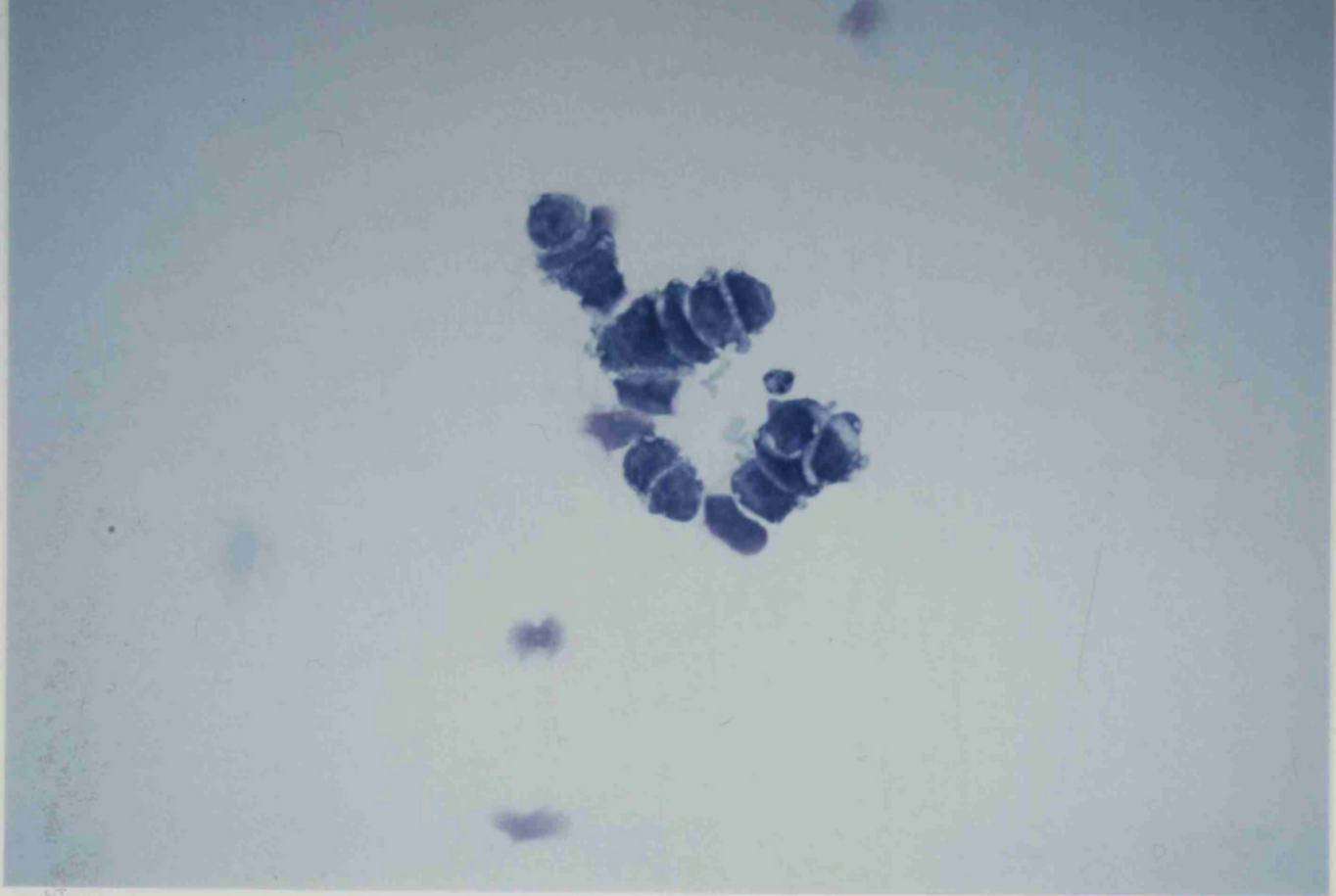

Fig. 3.4 a/b

CASE 5

64 year old male presenting with headaches, vomiting and sciatica six months following previous excision of a cutaneous malignant melanoma. Examination findings included meningism, drowsiness and bilateral papilloedema. Chest X-ray, cranial CT scan and myelography were normal.

DIAGNOSIS: Malignant melanoma

Fig. 3.5a

CSF cytospin (MGG x 500). Mononuclear cell infiltrate.

Fig. 3.5b

CSF cytospin (immunofluorescence x 500). Clump of cells staining with monoclonal antibody 9.2.27.

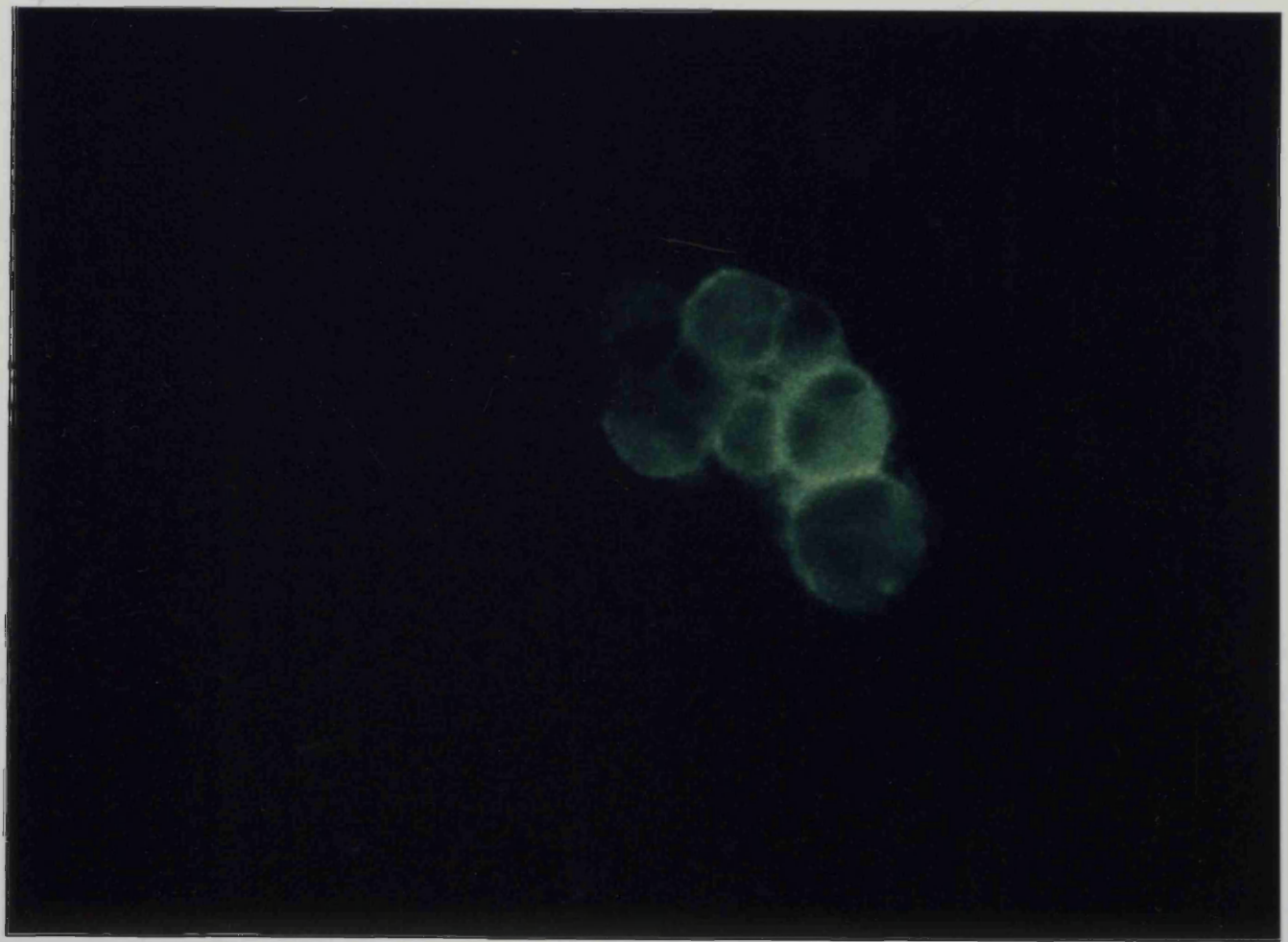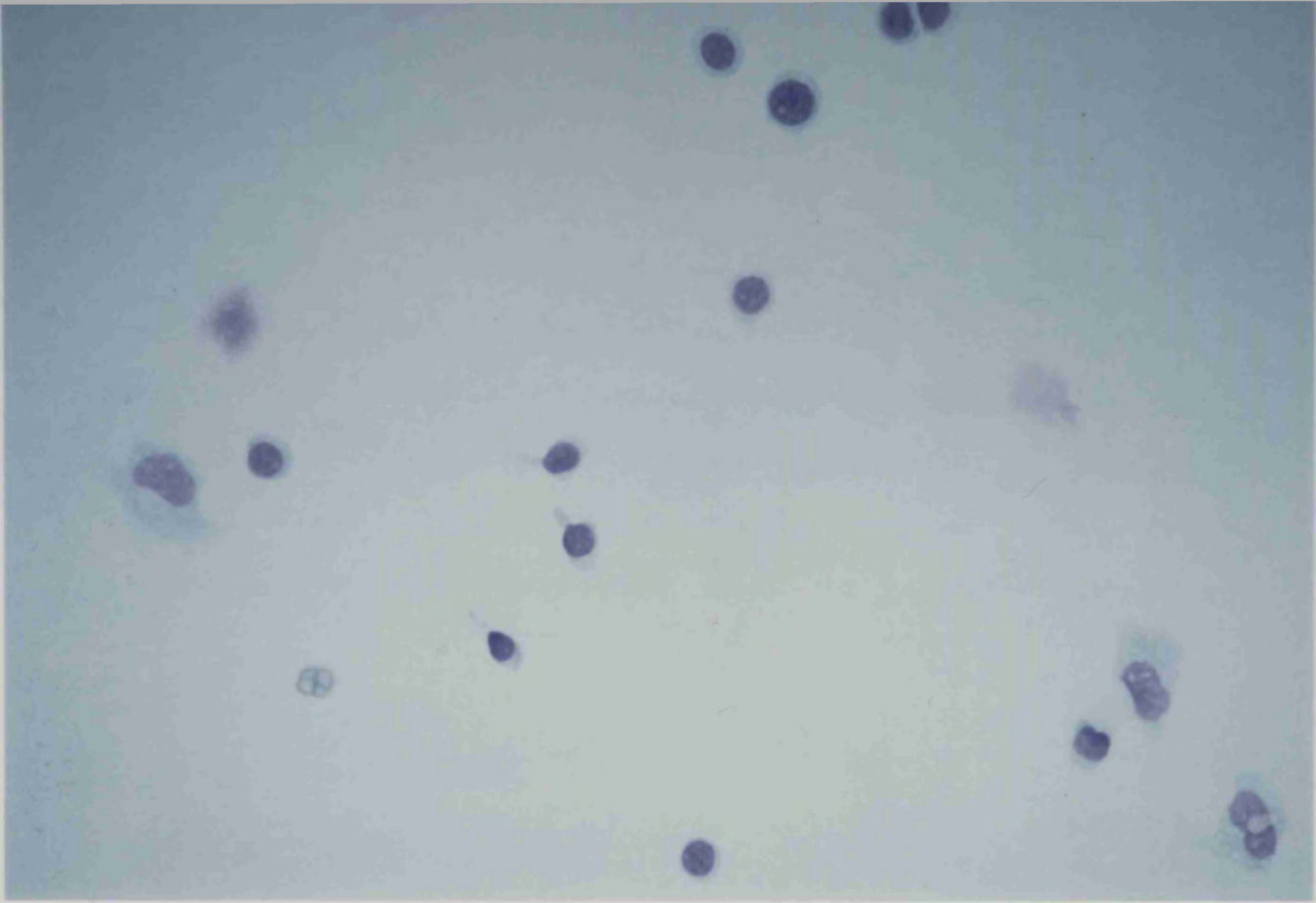


Fig. 3.5 a/b

CASE 6

13 year old female presenting with headaches, vomiting and diplopia over a three week period. She had undergone posterior fossa surgery and excision of a cerebellar medulloblastoma four years previously. Examination revealed meningism, bilateral papilloedema and unilateral facial weakness. Cranial CT scan revealed posterior fossa tumour recurrence and sulcal enhancement over the convexity hemisphere surface.

DIAGNOSIS: Medulloblastoma

Fig. 3.6a.

CSF cytospin (MGG x 1000). Clump of tumour cells with heterogenous morphology.

Fig. 3.6b

CSF cytospin (immunoperoxidase x 1000). Tumour cells staining with neuroectodermal marker M340.

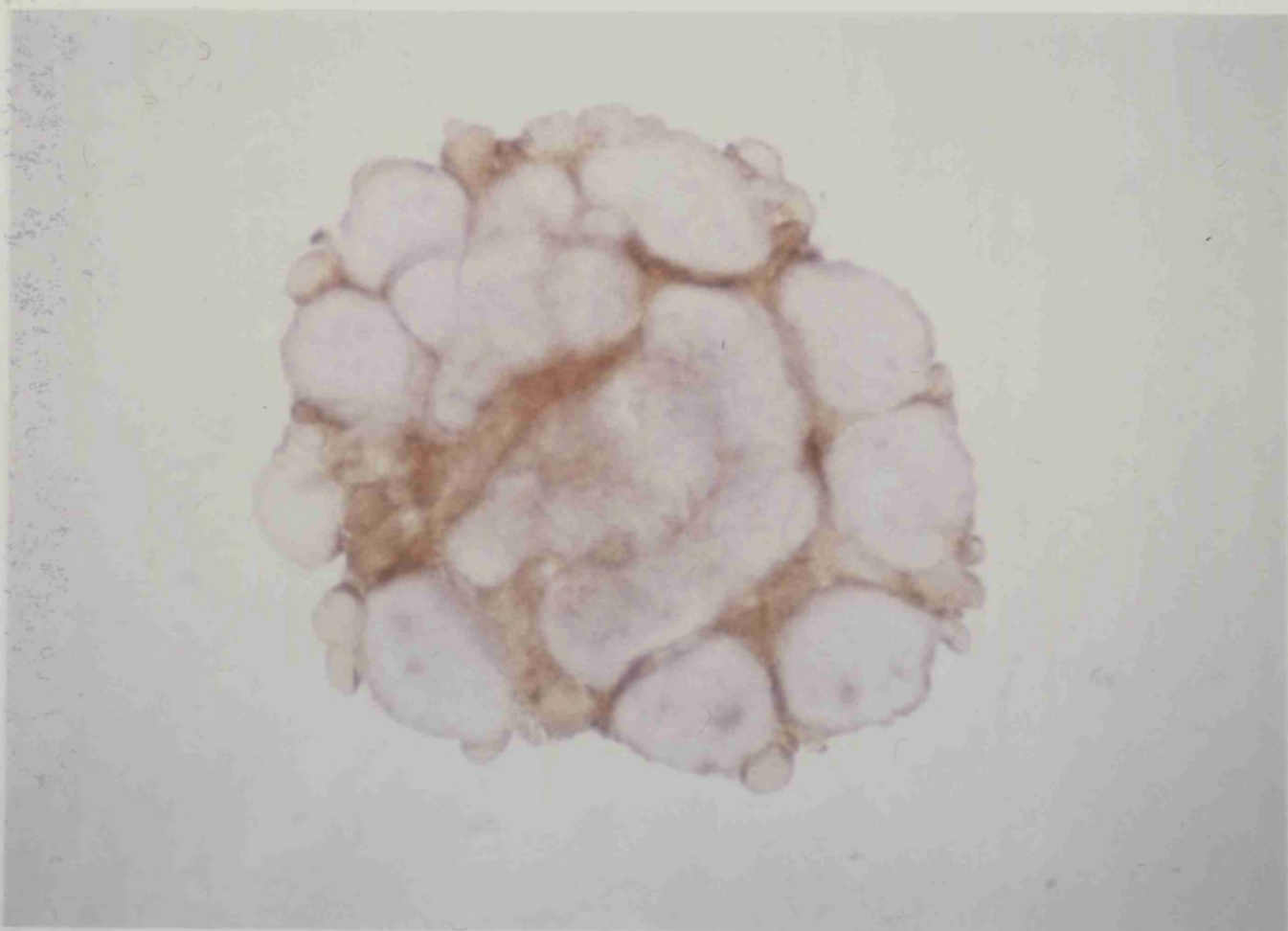
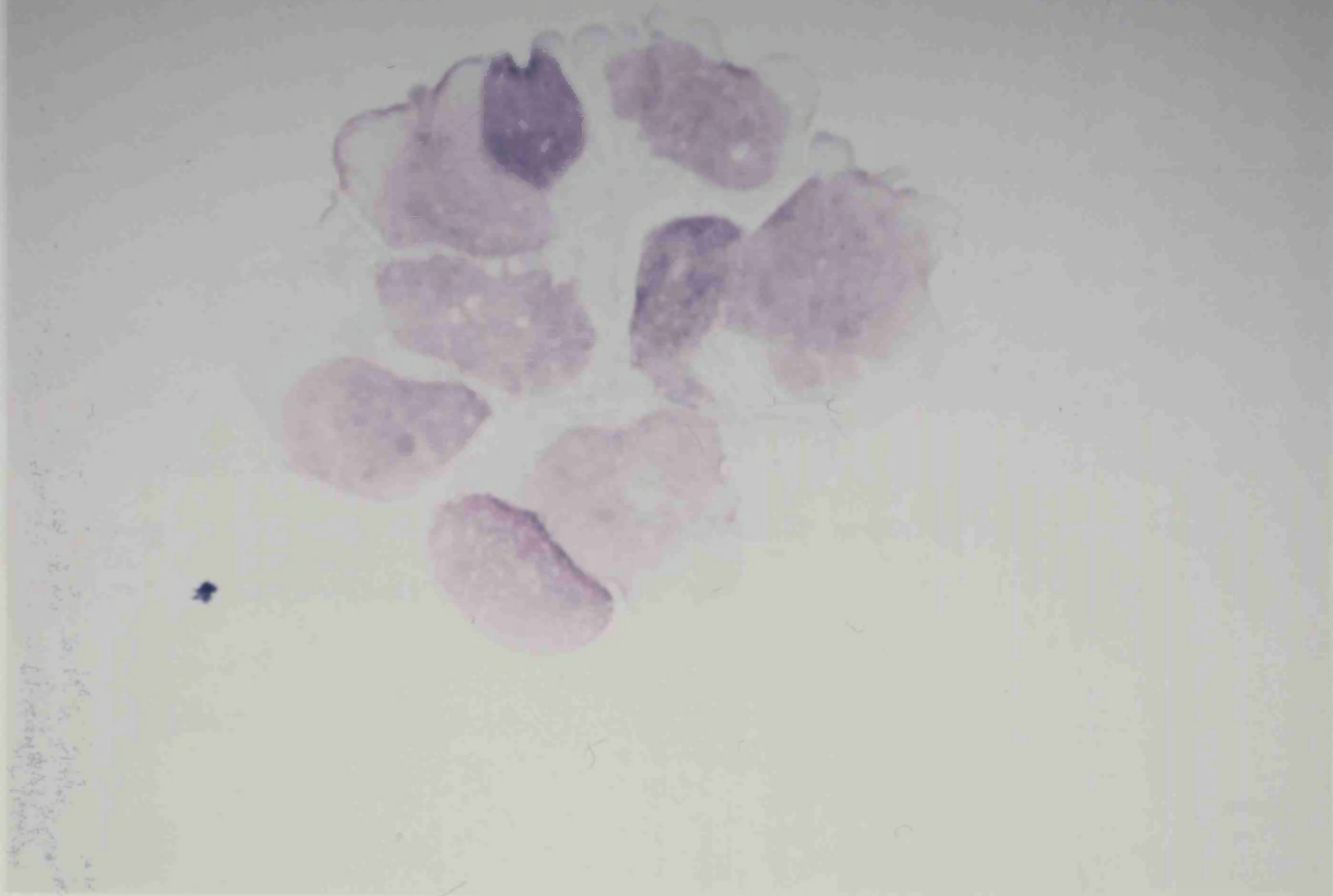


Fig. 3.6 a/b

CASE 7

45 year old male presenting with a three month history of headaches, facial numbness and weight loss. Three years previously he had undergone posterior fossa surgery for a fourth ventricular ependymoma. Examination revealed bilateral facial weakness and numbness together with temporalis muscle wasting. Cranial CT scanning and myelography revealed no evidence of tumour recurrence.

DIAGNOSIS: Ependymoma

Fig. 3.7a

CSF cytopsin (MGG x 500). Clumps of malignant cells.

Fig. 3.7b

CSF cytopsin (immunoperoxidase x 500). Tumour cells staining with the neuroectodermal marker UJ13A.

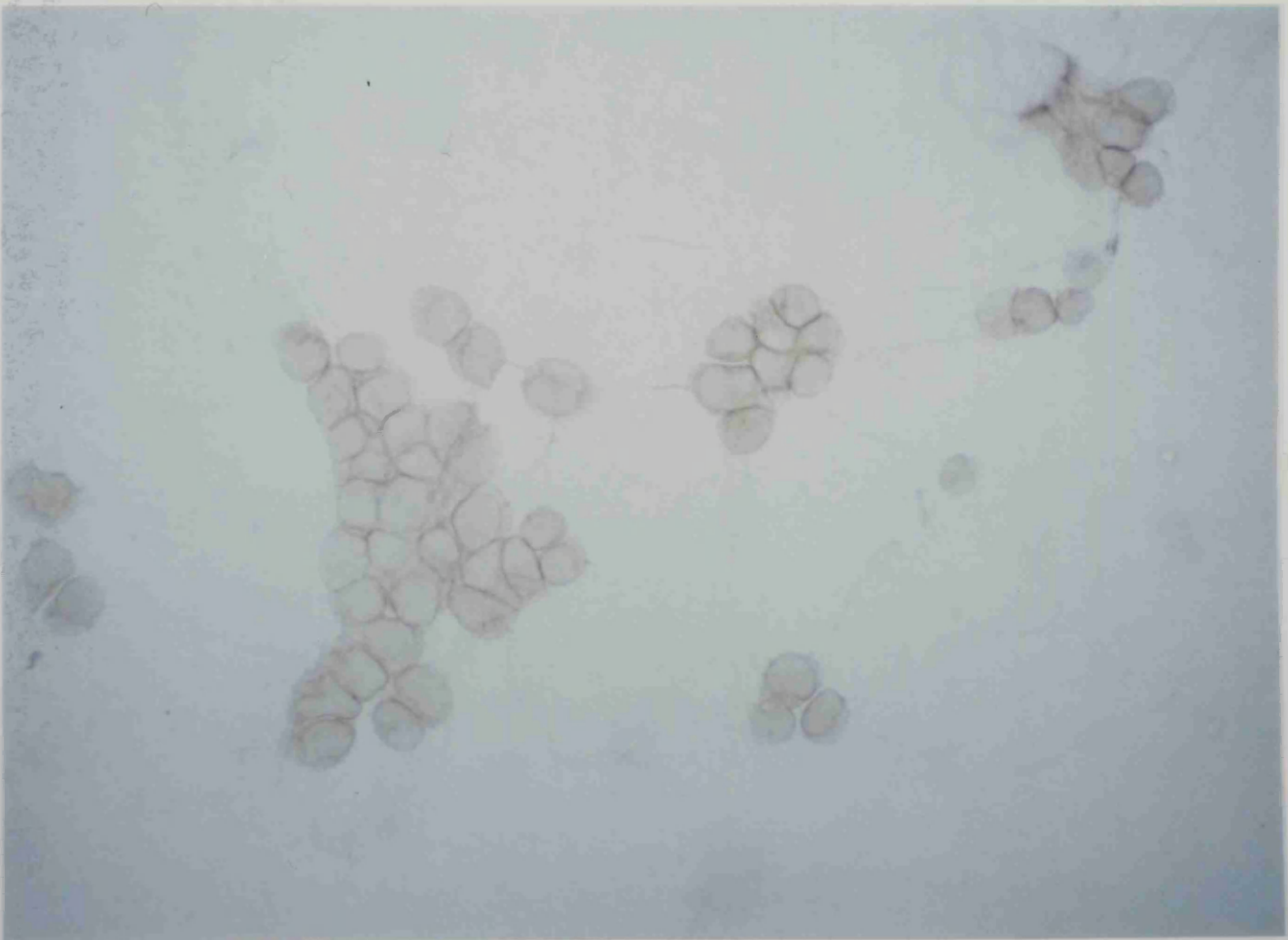
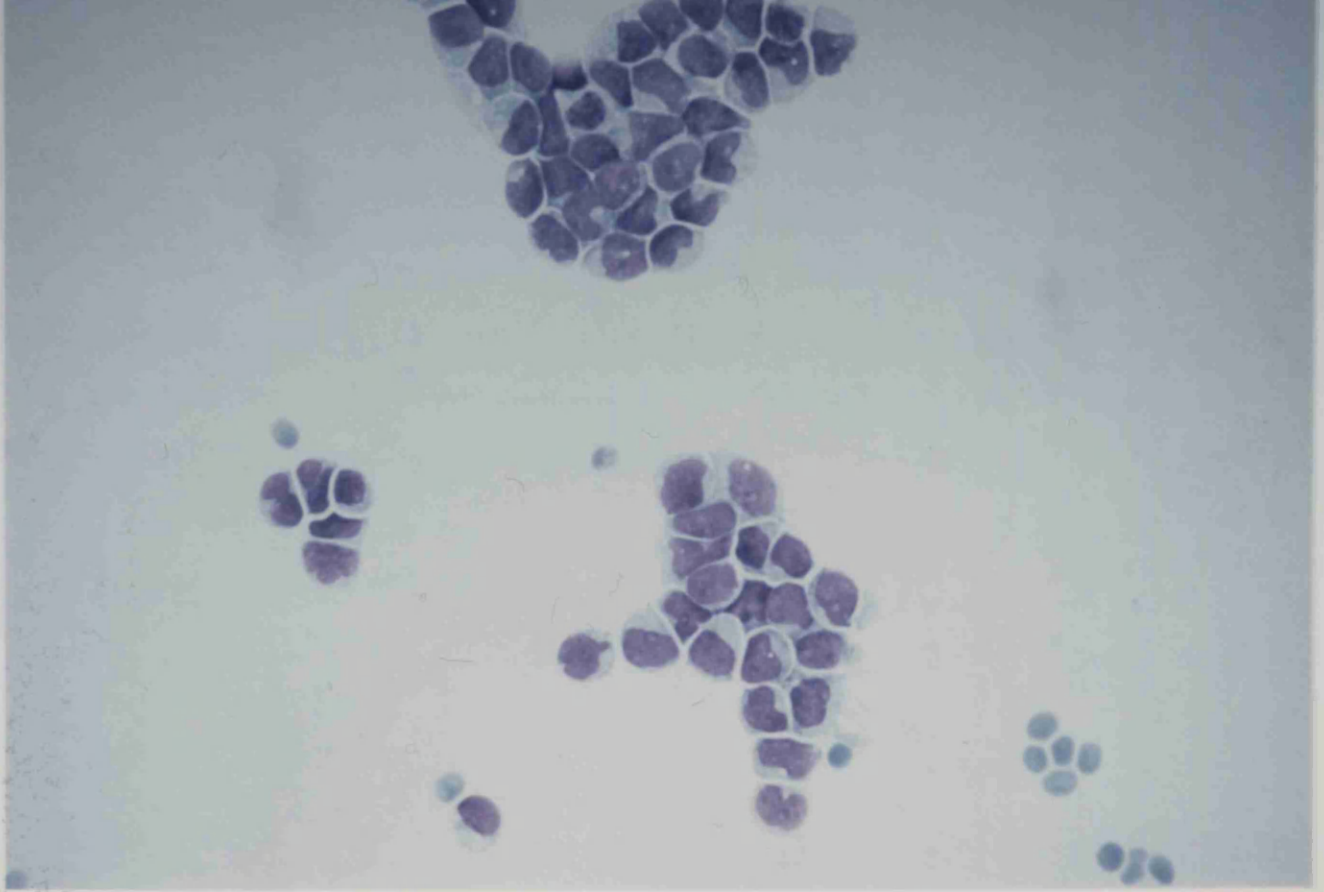


Fig. 3.7 a/b

CASE 8

58 year old male presenting with anorexia, weight loss and lower limb weakness over a four week period. Examination revealed a moderate paraparesis. Chest X-ray revealed a right hilar lung mass. Cranial CT scanning and myelography were normal.

DIAGNOSIS: Large cell lung carcinoma

Fig. 3.8a

CSF cytospin (MGG x 500). Numerous large malignant cells.

Fig. 3.8b

CSF cytospin (immunofluorescence x 500). Tumour cell staining brightly with monoclonal antibody HMFG1.

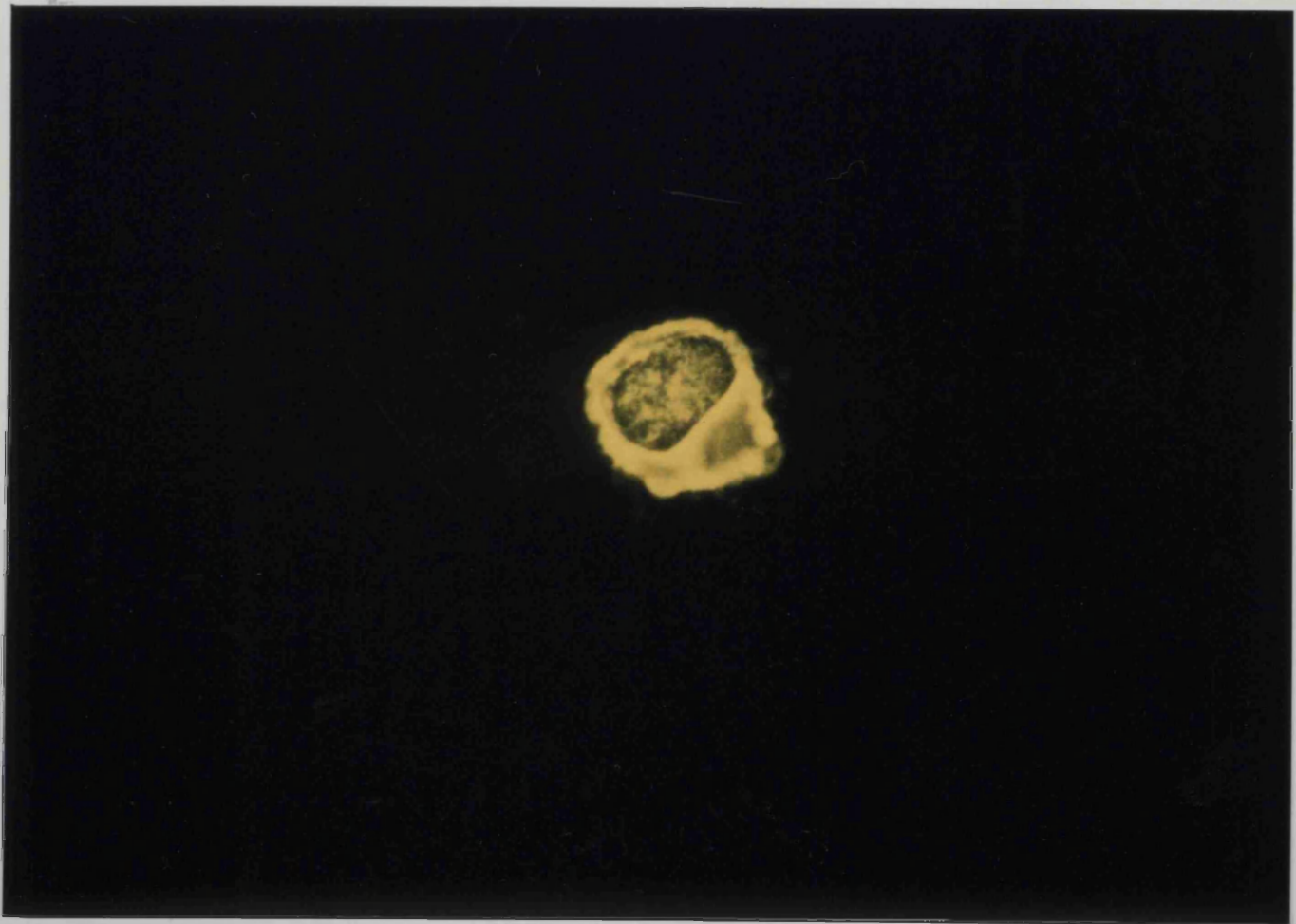
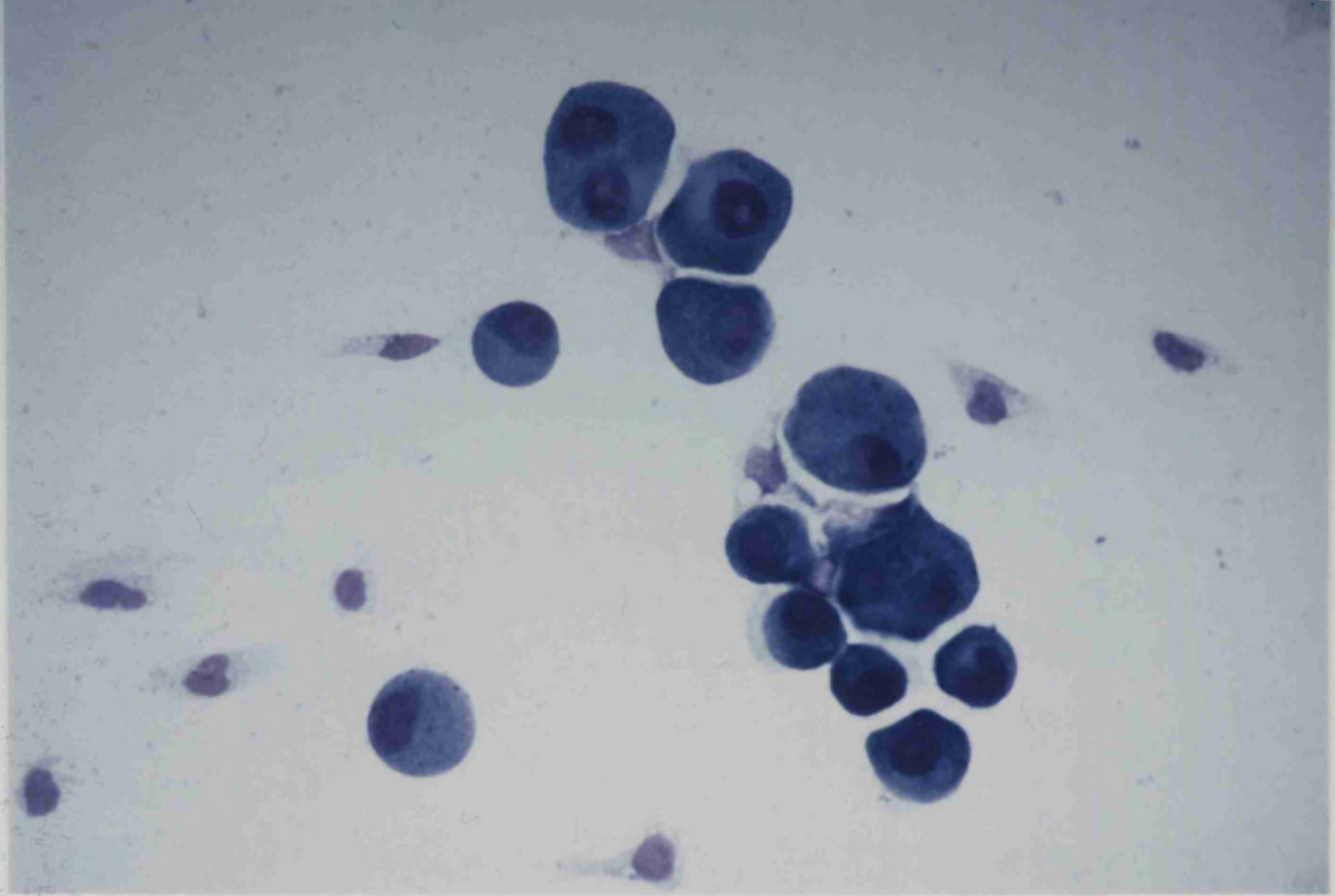


Fig. 3.8 a/b

CASE 9

38 year old male presenting with a four week history of headaches, facial weakness and sciatica. His initial presentation was four years previously with a primary cerebellar lymphoma which had been treated with surgery and radiotherapy. Examination findings revealed bilateral papilloedema, unilateral facial weakness and an absent left knee jerk. Cranial CT scanning revealed no evidence of tumour recurrence and myelography was normal.

DIAGNOSIS: Lymphoma

Fig. 3.9a

CSF cytospin (MGG x 500). Cluster of malignant cells.

Fig. 3.9b

CSF cytospin (immunoperoxidase x 500). Tumour cell clusters staining with antibody DAKO-LC.

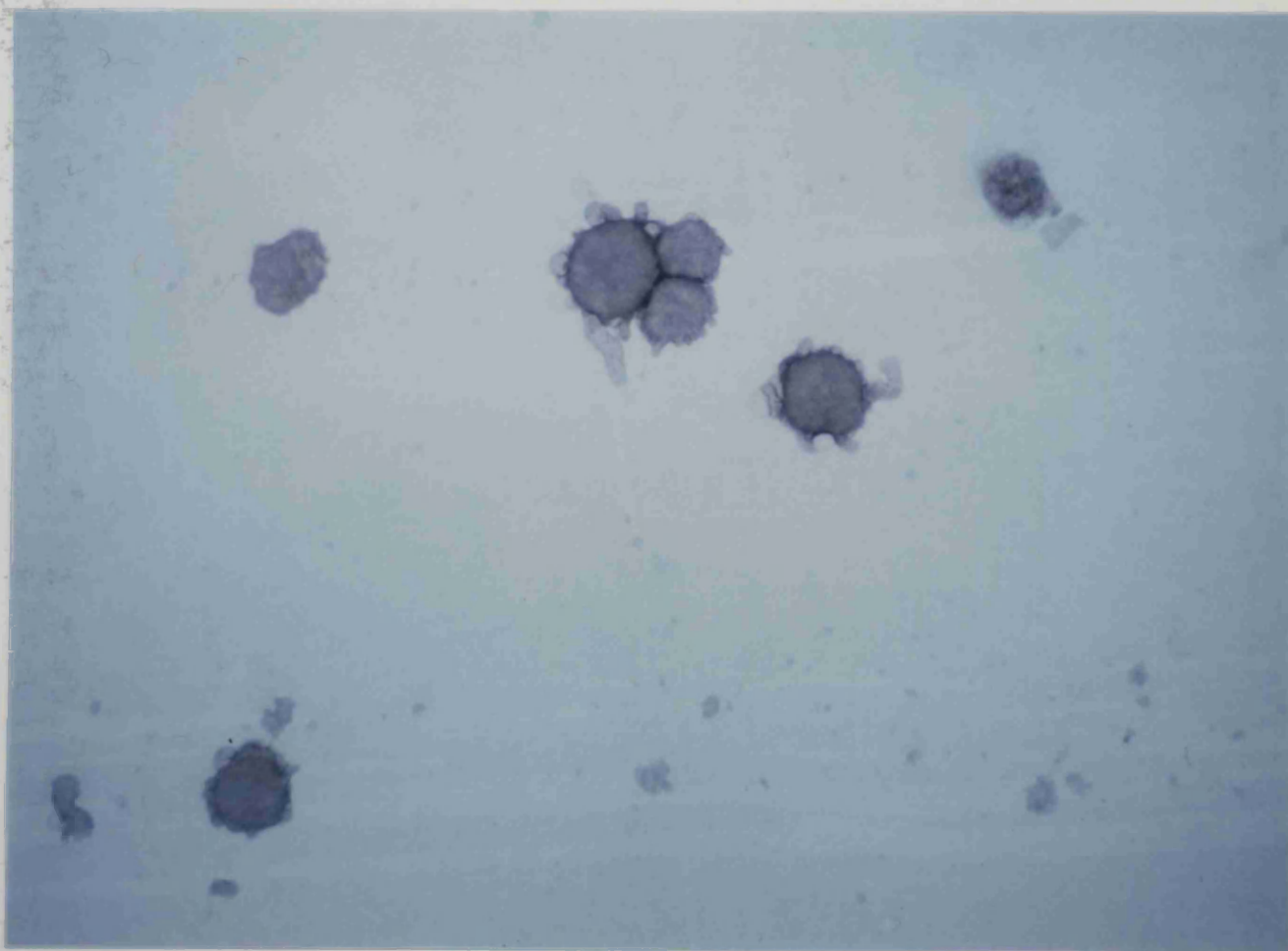
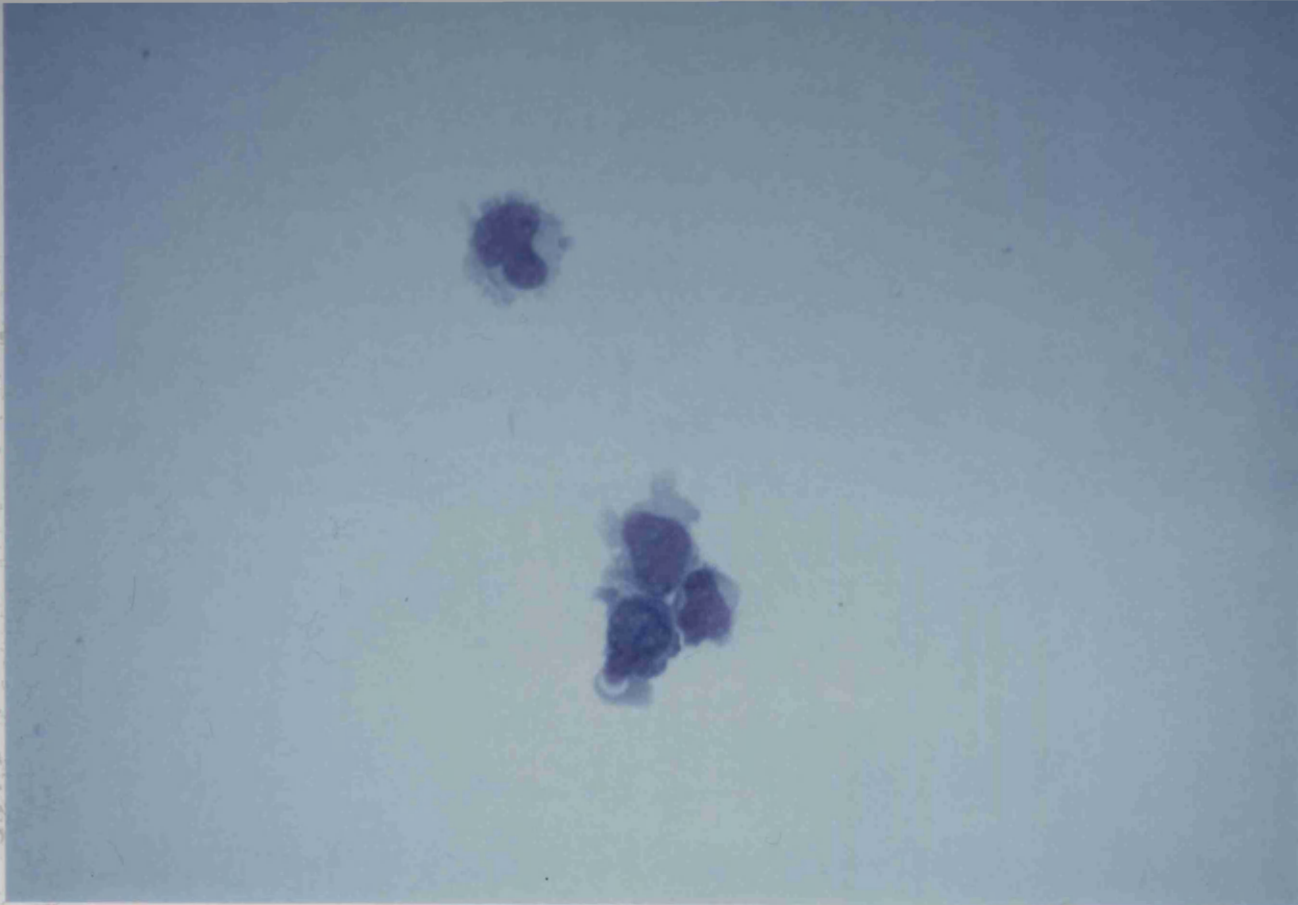


Fig. 3.9 a/b

CASE 10

2 year old girl presenting as failure to thrive with delayed motor skills. Examination revealed an unwell child with an abdominal mass and paraparesis. Chest X-ray normal. Cranial CT scanning was normal but myelography revealed mid-thoracic spinal cord compression.

DIAGNOSIS: Neuroblastoma

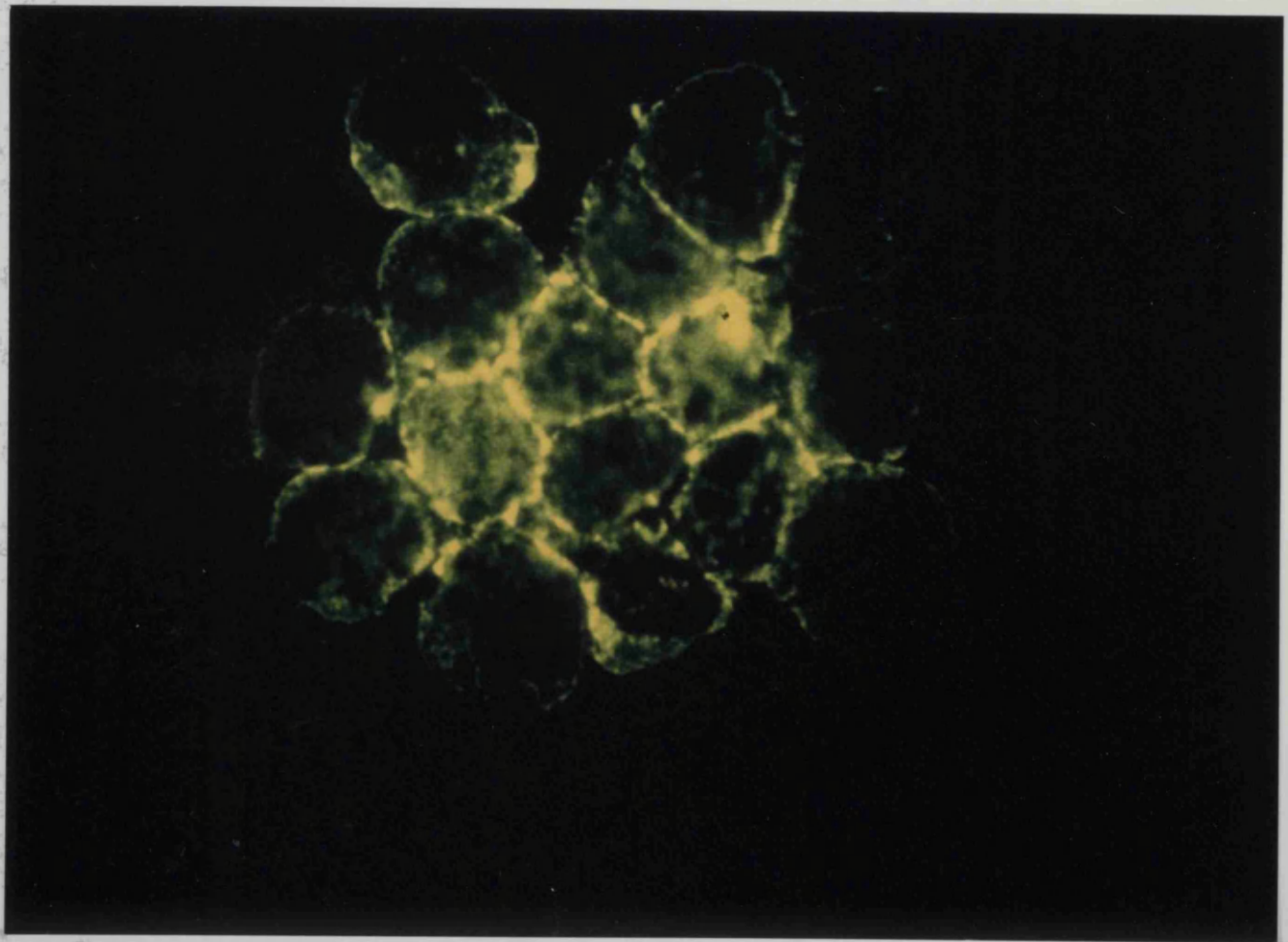
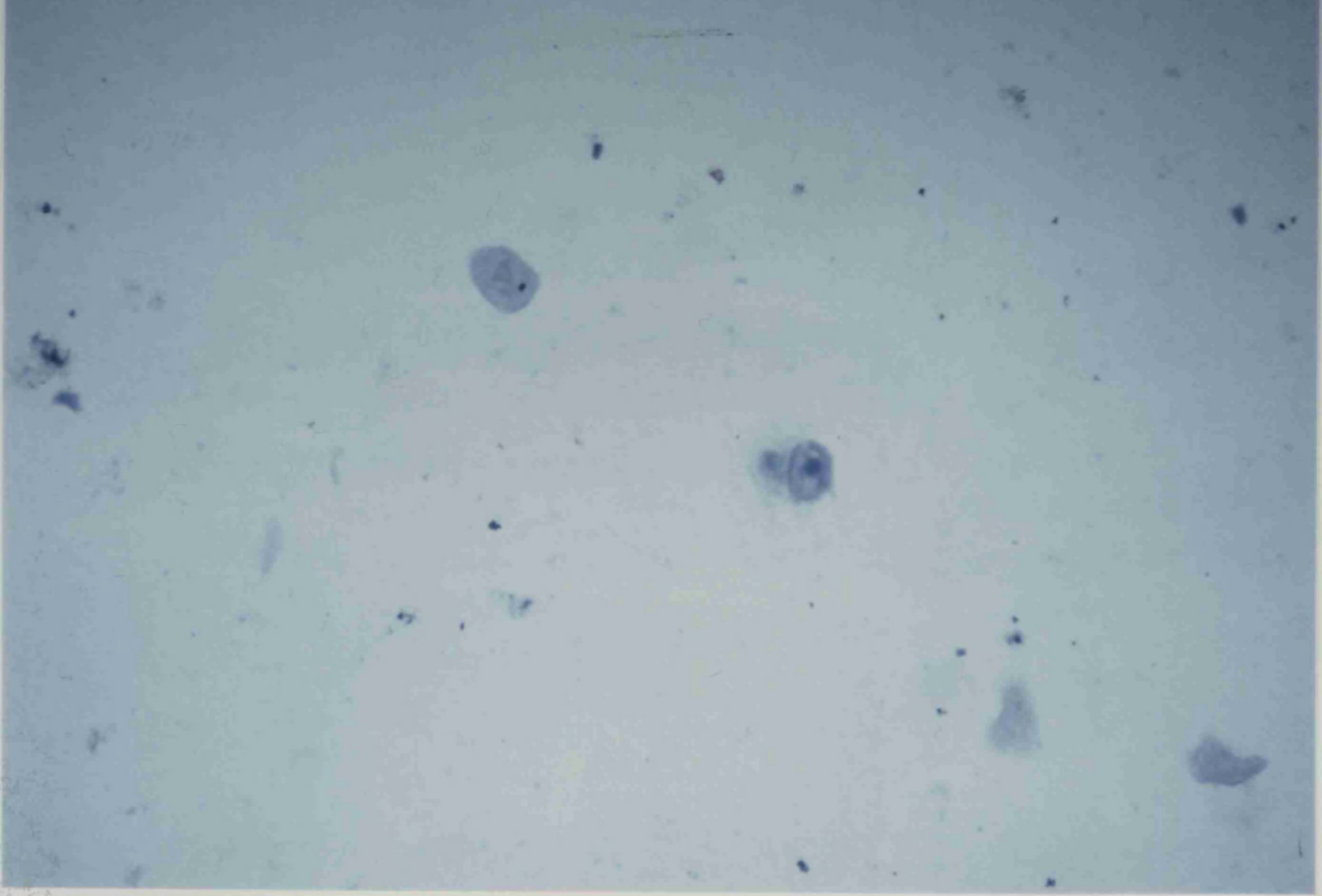


Fig. 3.10 a/b

CASE 11

57 year old male presenting with a four week history of progressive headaches, weight loss and dementia. Examination revealed bilateral papilloedema and impairment of mental faculties. Cranial CT scanning revealed communicating hydrocephalus.

DIAGNOSIS: Gastric carcinoma

Fig. 3.11a

CSF cytospin (MGG x 500). Carcinoma cells with mononuclear cell infiltrate.

Fig. 3.11b

CSF cytospin (immunoperoxidase x 500). Carcinoma cells staining with monoclonal antibody CAM 5.2.

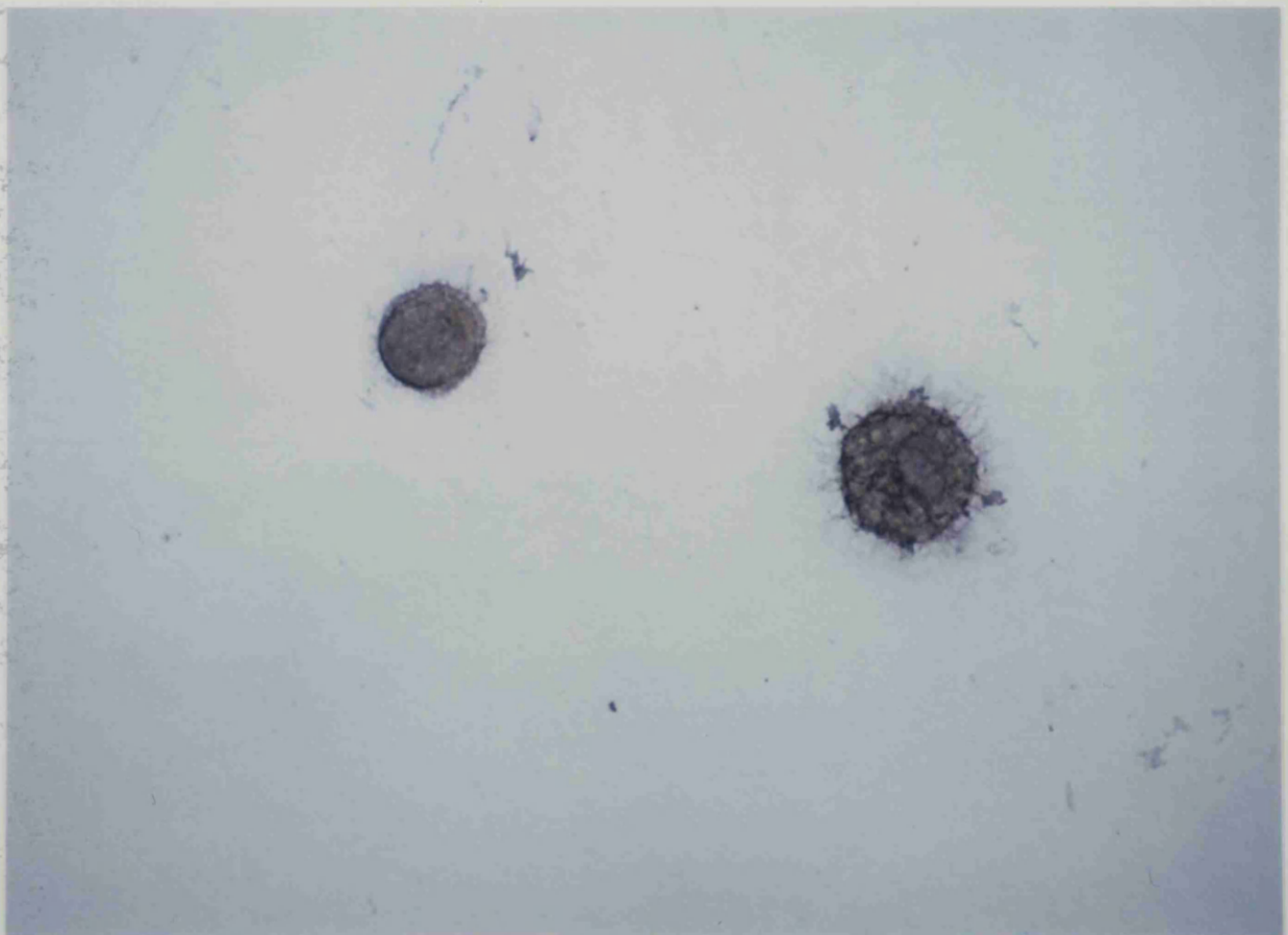
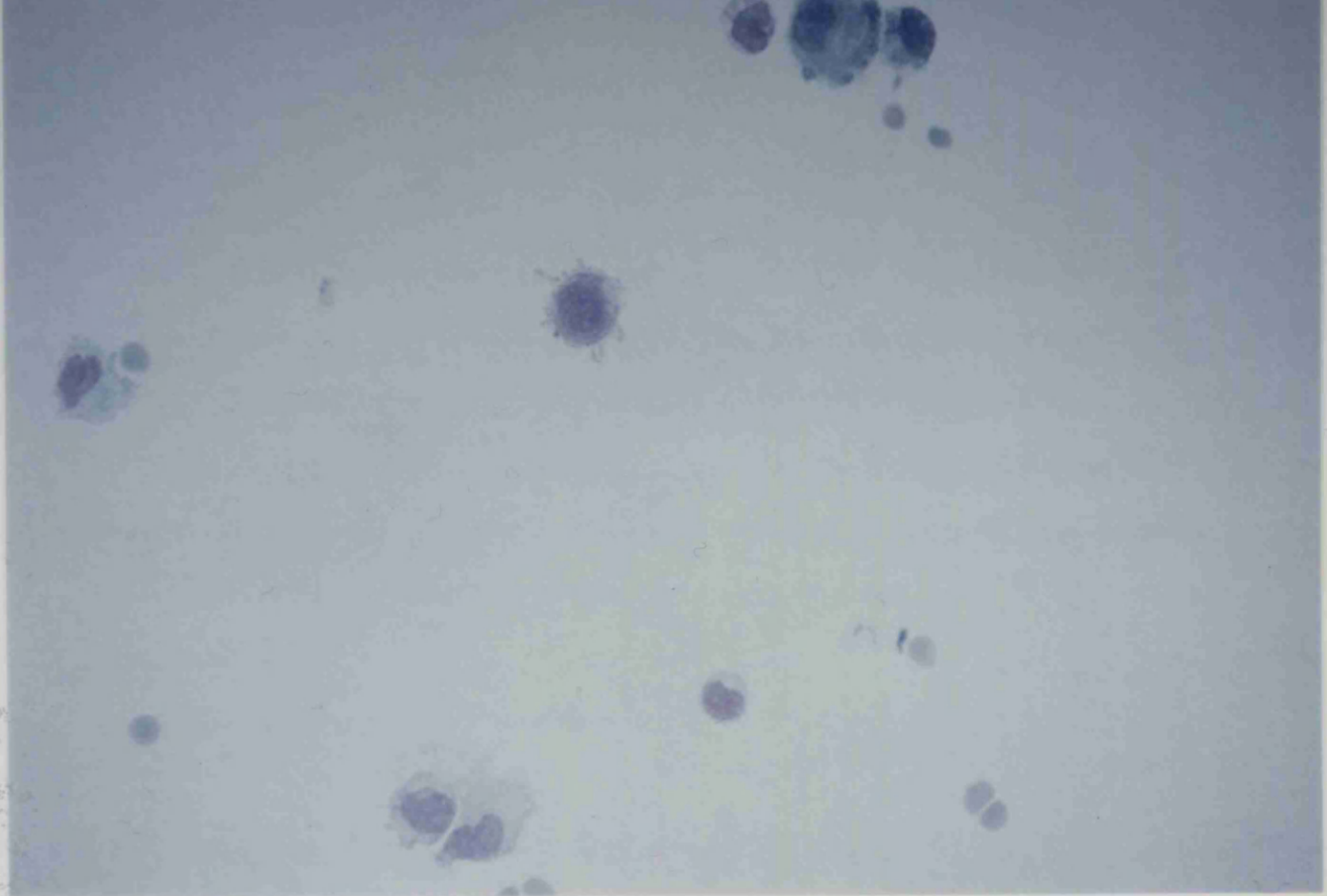


Fig. 3.11 a/b

CASE 12

25 year old male presenting with nausea, vomiting and sciatica over a six week period. Six months previously he had undergone craniotomy and partial excision of a malignant astrocytoma. Examination revealed mild meningism, right lower limb sensory loss and an absent left knee jerk. Cranial CT scanning revealed persisting primary tumour and myelography demonstrated tumour nodules within the cauda equina.

DIAGNOSIS: Malignant astrocytoma

Fig. 3.12a

CSF cytopsin (MGG x 500). Degenerate mononuclear cells and tumour cells.

Fig. 3.12b

CSF cytopsin (MGG x 500). Tumour cell demonstrated staining with monoclonal antibody UJ13A.

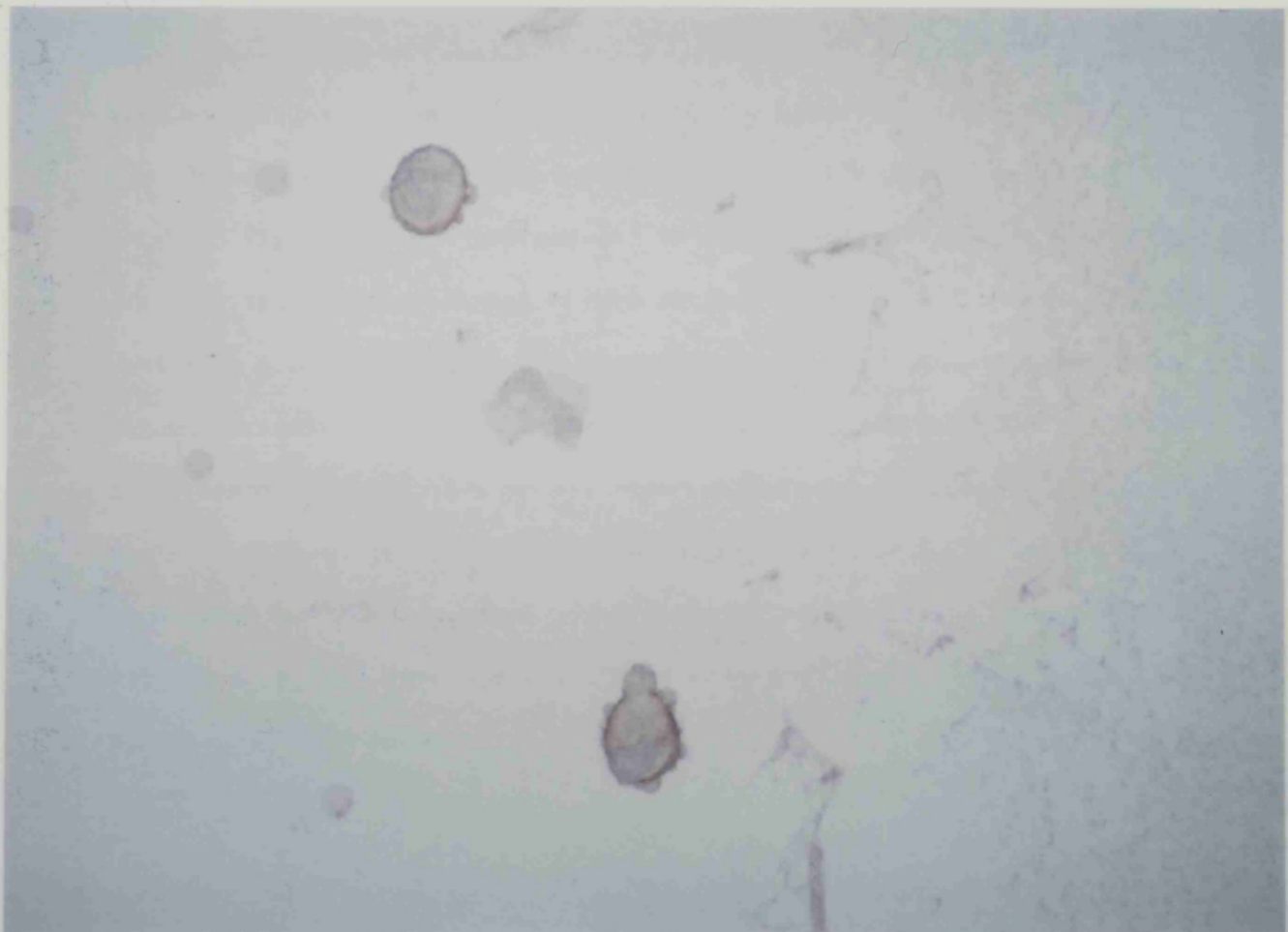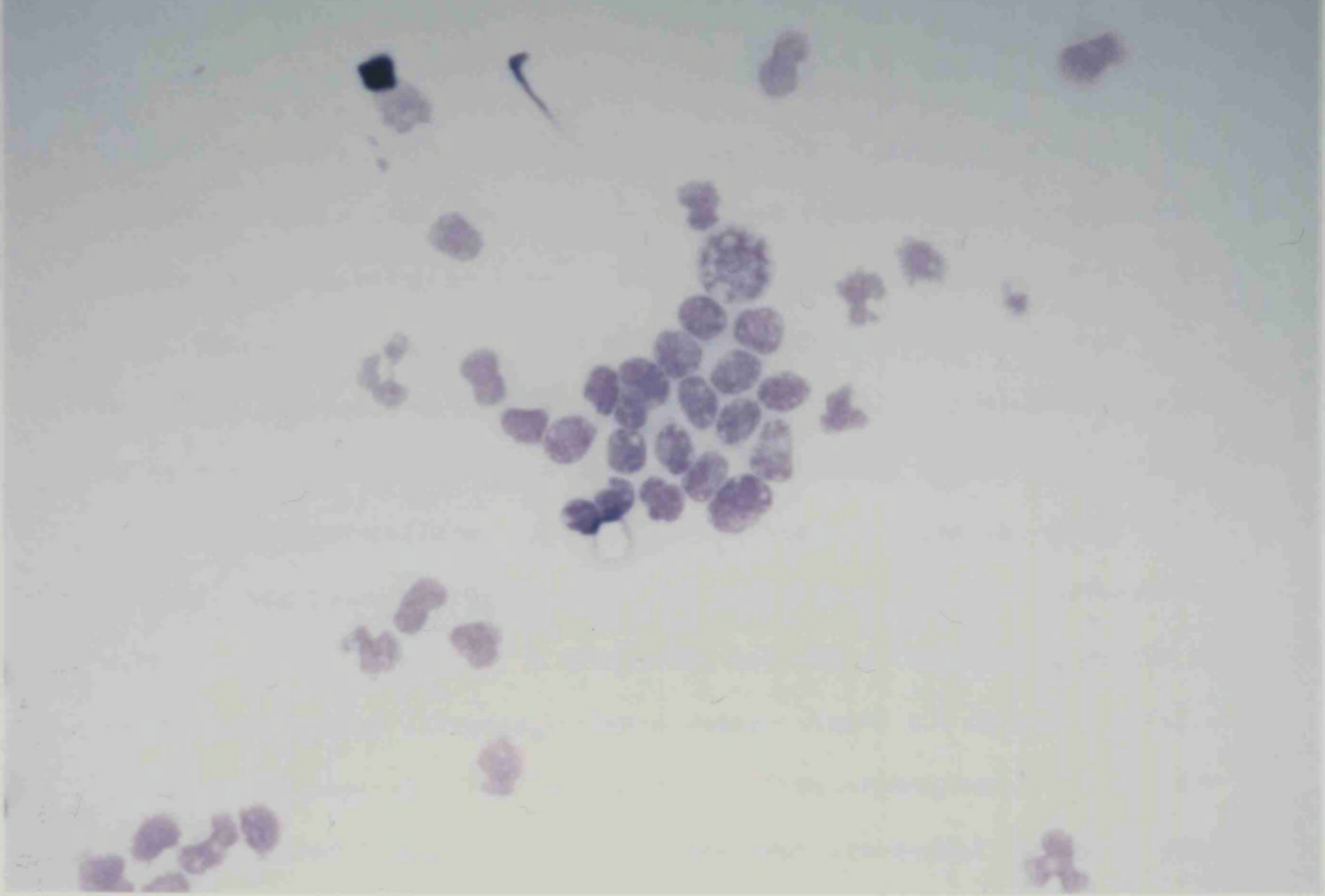


Fig. 3.12 a/b

In 2/12 patients with neoplastic meningitis (cases 3 and 5), CSF cytopsin preparations were non-diagnostic by conventional May-Grunwald Giemsa (MGG) staining methods. The diagnosis became apparent however with immunocytochemistry. In three patients (cases 2, 10 and 11), meningeal neoplasia was evident at the first clinical presentation with malignant disease. In these patients, the primary tumour was unknown and although conventional cytological methods revealed malignant cells in CSF, the tumour category could not be defined. Immunocytochemistry with a diagnostic panel of 8 monoclonal antibodies enabled diagnosis of the primary tumour category in these cases. Table 3.1 reveals details of the immunological staining profiles (immunophenotype) of all CSF samples tested (cases 1-12). All three neuroectodermal markers were positive on the primary neuroectodermal tumours, and notably case 3 (small cell lung carcinoma) expressed the UJ13A antigen. Our single case of malignant melanoma was detected by monoclonal antibody 9.2.27, but we were unable to demonstrate malignant cells positive to ME1-14. Notably, there was no expression of the antigen defined by UJ13A, despite the neuroectodermal origin of this tumour. ME1-14 and 9.2.27 were both positive on case 10 (neuroblastoma) and case 12 (malignant glioma). Both lymphomas expressed the antigen defined by DAKO-LC. These cells were negative to all other markers on the panel. Malignant cells positive to HMFG1 were detected in 4 of 5 patients with carcinoma, but not in case 11 (gastric carcinoma). CAM 5.2 was expressed by all carcinomas and generally provided greater definition of staining than HMFG1.

TABLE 3.1

IMMUNOCYTOCHEMICAL PANEL ANALYSIS
FOR 12 PATIENTS WITH NEOPLASTIC MENINGITIS

	HMFG1	CAM 5.2	DAKO-LC	UJ13A	UJ181.4	M340	ME1-14	9.2.27
1.	+	+	*	-	-	-	-	-
2.	-	-	+	-	-	-	-	-
3.	-	+	*	+	-	-	-	-
4.	+	+	-	-	-	-	-	-
5.	-	-	*	-	-	-	-	+
6.	-	-	-	+	+	+	-	-
7.	-	-	-	+	-	-	-	-
8.	+	+	-	-	-	-	-	-
9.	-	-	+	-	-	-	-	-
10.	-	-	-	+	+	+	+	+
11.	-	+	*	-	-	-	-	-
12.	-	-	-	+	-	-	+	+

* LYMPHOCYTIC INFILTRATE

3.4 DISCUSSION

Even in expert hands, CSF cytological diagnosis can be notoriously difficult. False-negative results may occur when small numbers of neoplastic cells are masked by a reactive leucocytosis (Coakham et al., 1984b). Less commonly, false-positive results may occur when non-neoplastic cells form clusters or adopt a spherical form and imbibe fluid, thus mimicking the signet ring cells of adenocarcinoma (Bigner and Johnston, 1981). When malignant cells are seen in the absence of a known primary neoplasm, it is often impossible to identify the type of primary malignancy from which they originated (Coakham et al., 1984a,b). Use of monoclonal antibody immunocytology for identification of malignant cells in serous effusions (Epenetos et al., 1982; Woods et al., 1982) was later followed by application of the technique to CSF (Hancock and Medley, 1983). Advantages reported by the use of these techniques include an increased diagnostic sensitivity and opportunities to characterise tumour cells from an unknown primary neoplasm (Garson et al., 1985). The present study was not designed to assess absolute diagnostic sensitivity of cytological methods, as only patients exhibiting positive cytology were included. Although not statistically significant, this small study revealed a diagnostic sensitivity advantage of monoclonal antibody immunocytology over conventional staining methods. In agreement with previous work, the study also confirmed the distinct advantages of immunocytology in situations where the primary neoplasm is unknown.

Generally, monoclonal antibodies do not have absolute cell specificity. Several different cell types may bind one specific monoclonal antibody

by sharing a common antigen. Quite frequently, cells that share a common antigen also share a common embryological derivation. By using combinations of characterised antibodies to form a diagnostic panel, a cell type can be accurately identified by its own unique antigenic profile. The antibodies chosen for inclusion in the diagnostic CSF panel reflect the common tumour categories that invade the CSF and have been reliably characterised by testing on a wide variety of tissues. Neoplasia of the CSF falls into four major tumour-antigen categories: carcinoma, neuroectodermal tumour, melanoma and lymphoma. The panel should consist of antibody markers for each of these major tumour categories, but additional antibodies may be added for more detailed cellular characterisation, or in cases where a specific tumour type is suspected. With reference to Section 2.2 it is clear that the melanoma markers cross react with other tumours of neuroectodermal origin. The value of the well characterised antibody UJ13A is revealed in this situation as it is known to bind a glycoprotein antigen present on all cells and tumours derived from neuroectoderm, with the one notable exception of melanoma (Allan et al., 1983). Therefore, in the presence of positive binding by antibodies which recognise neuroectodermal tumours, a negative response to UJ13A confirms the diagnosis of melanoma. This example therefore emphasizes the point, that for accurate cellular identification, it is the pattern of reactivity to the entire panel of antibodies that is diagnostic rather than reactions with single antibodies. The distinctive antigenic profile of any specific tumour is contributed as much from negative markers as from positive.

CHAPTER 4

CARCINOMATOUS MENINGITIS: DIAGNOSIS BY

MUCIN RADIOIMMUNOASSAY

4.1 INTRODUCTION

Carcinomatous meningitis is a devastating metastatic complication of systemic carcinoma, which may occur insidiously, accompanied by a confusing spectrum of clinical symptoms and signs. The diagnosis is traditionally established by the demonstration of malignant cells in the CSF and standard cytological techniques have been significantly enhanced by monoclonal antibody immunocytology (Coakham et al., 1984a,b). The disorder may present as a chronic progressive meningitis, requiring differential diagnosis from other causes such as tuberculosis and fungal infection (Hughes et al., 1963). Diagnostic imaging techniques are usually only helpful in excluding parenchymal disease (Lee et al., 1984; Davis et al., 1987), and cytological techniques requiring skilful interpretation, are occasionally negative in the presence of extensive meningeal disease (Wasserstrom et al., 1982). The estimation of biochemical tumour markers in CSF may offer the potential of reliable diagnosis in early disease states, prior to the appearance of exfoliated malignant cells. A variety of tumour markers in CSF have previously been investigated (Section 1.8), but diagnostic sensitivities and specificities obtained have not been sufficient to justify their widespread adoption into clinical practice.

Monoclonal antibody HMFG1 defines a high molecular weight glycoprotein (polymorphic epithelial mucin, PEM), which is expressed by many normal and neoplastic derivatives of epithelium (Ward et al., 1987a). The antigen is liberated from the cell surface and into the extracellular fluid. Previous studies have demonstrated its relative excess in the serum of patients with carcinoma and also noted its presence to a

lesser degree in normal population sera (Burchell et al., 1984). The antibody HMFG1 radiolabelled with I-131 was administered intrathecally to patients with carcinomatous meningitis (Chapter 5) and related studies revealed the presence of radioimmunoconjugate-PEM antigen complexes in CSF (section 5.2.7/5.3.6/5.4.5). The presence of PEM in CSF had not been previously reported and we considered that its detection might provide a diagnostic marker for carcinomatous meningitis. It was felt that PEM could be advantaged as a CSF diagnostic marker as its high molecular weight (>300 kDa.) might prevent transgression of the blood brain barrier and its consequent leakage from serum into CSF. We had also previously demonstrated the complete absence of this glycoprotein from the normal central nervous system using sensitive radioimmunoassay methods. Immunoradiometric assay techniques for the detection of PEM in serum had previously been reported (Burchell et al., 1984; Hilkens et al., 1986) and we elected to modify an existing system for its application to CSF studies (Moseley et al., 1989b).

4.2 METHODS

4.2.1 PATIENTS

100 patients were studied and had lumbar CSF samples taken, which were stored frozen at -20°C. Patients were divided into five disorder category groups of 20 patients (Table 4.1). Group 1 patients had carcinomatous meningitis. Group 2 patients had non-carcinomatous neoplastic meningitis complicating primary neuroectodermal tumours and malignant melanoma. Group 3 patients had systemic carcinoma, but no disease involvement of the central nervous system. Group 4 patients had either demyelinating or inflammatory disease of the central nervous system and group 5 patients were disease free and had normal CSF.

Table 4.1

Disorder Category Groups of Patients Studied

GROUP	DISORDER CATEGORY
1	CARCINOMATOUS MENINGITIS
2	NON-CARCINOMATOUS NEOPLASTIC MENINGITIS
3	SYSTEMIC CARCINOMA NO NEUROLOGICAL DISEASE
4	DEMYELINATING AND INFLAMMATORY DISORDERS
5	NORMAL PATIENTS

4.2.2 MUCIN IMMUNORADIOMETRIC ASSAY TECHNIQUE

Polymorphic epithelial mucin (PEM) is the target antigen for many monoclonal antibodies reactive with normal and neoplastic cellular derivatives of epithelium (Taylor-Papadimitriou, 1981; Price et al., 1985; Hilkens et al., 1984; Heyderman et al., 1985). This cell surface antigen is liberated into the extracellular fluid and has been evaluated as a serum marker for neoplastic disease in a number of assays (Burchell et al., 1984; Hilkens et al., 1986; Price et al., 1987). The approach most commonly used for antigen detection has been a double determinant immunoradiometric assay. Monoclonal antibody defining the antigen is adsorbed onto a solid phase, incubated with serum, and a labelled second antibody binding the antigen is added to "trace" the antigen (Fig. 4.1). The solid phase immobilised antibody is often referred to as the "capture" or "catcher" antibody, in contrast to the labelled antibody referred to as the "tracer". The same antibody can be used as "catcher" and "tracer" if the antigen is large and exhibits multiple repeated determinants. This feature was exploited in a mucin RIA developed for detection of PEM in CSF. In this assay, monoclonal antibody HMFG1 was used as the anti-mucin antibody. Monoclonal antibody HMFG2 has also subsequently been shown to detect PEM in CSF with this system. A modification of previously described techniques included the use of a control capture antibody of matched isotype to detect interference by spontaneously occurring anti-murine antibody in test samples (Boscato and Stuart, 1986; Janssen et al., 1989) (Fig. 4.2).

Fig. 4.1

Principles of mucin immunoradiometric assay. Radiolabelled 'tracer HMFG1' is linked to solid phase bound 'capture HMFG1' by PEM antigen.

Fig. 4.2

Interference in mucin immunoradiometric assay by polyvalent antibody binding substances.

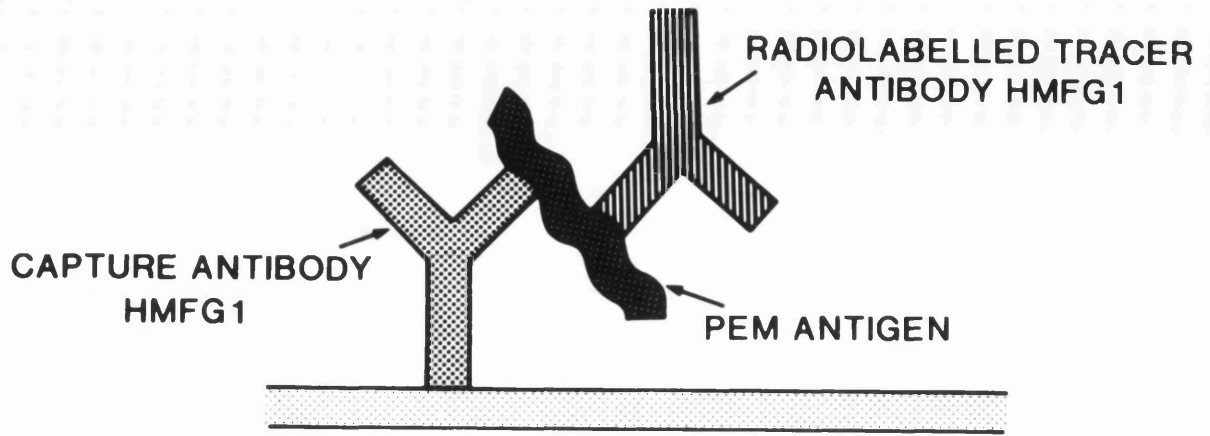


Fig. 4.1

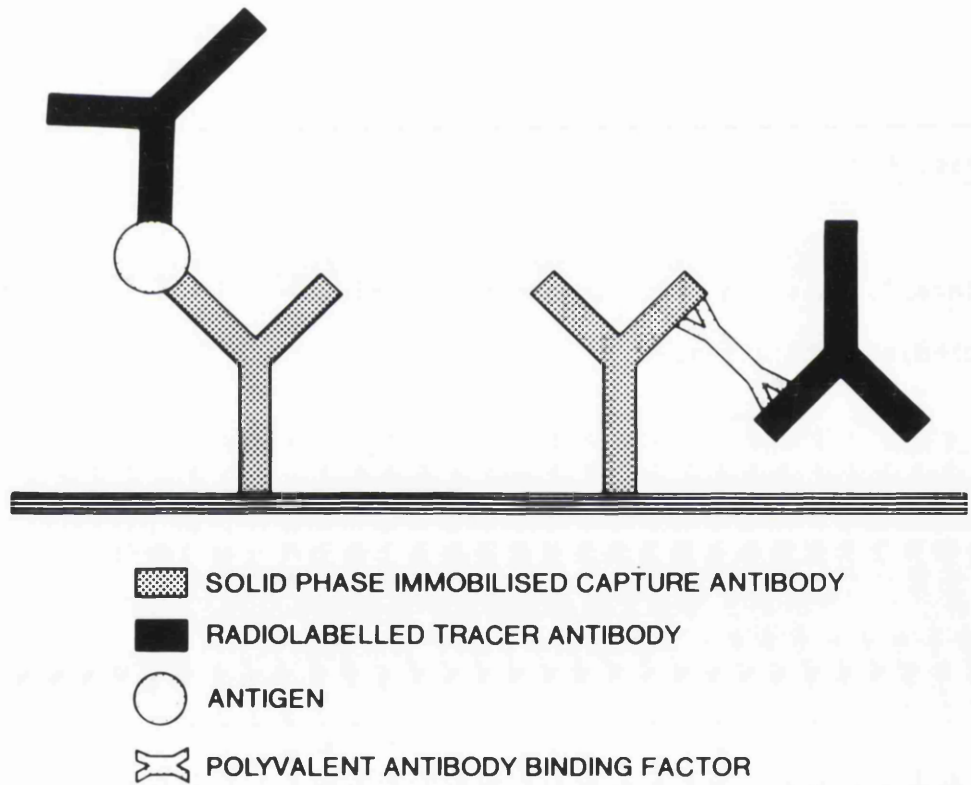


Fig. 4.2

The precise assay method involved the use of flat bottomed polyvinylchloride microtitre plates (Dynatech, UK) which were scored longitudinally to separate three rows of active and three rows of control wells (Fig. 4.3). In the designated active wells 0.5 ug. of monoclonal antibody HMFG1 in 50 ul. of PBS was allowed to evaporate to dryness at room temperature. The control wells were similarly activated with 0.5 ug. of monoclonal antibody AUA1 in 50 ul. of PBS. This activation process adsorbs small quantities of the unlabelled antibody onto the solid phase polyvinylchloride by strong non-covalent forces. The adsorbed antibody resists displacement by washing and is often referred to as the capture antibody. A schematic outline of sequential assay steps in active wells is shown (Fig. 4.4 - 4.10).

Fig. 4.3

PVC microtitre plate divided into areas of active and control wells.
Active wells activated with monoclonal antibody HMFG1. Control wells
activated with monoclonal antibody AUA1.

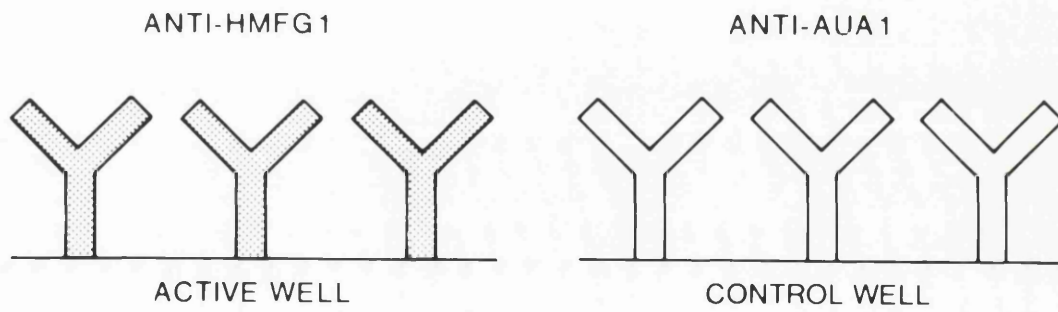



Fig. 4.3

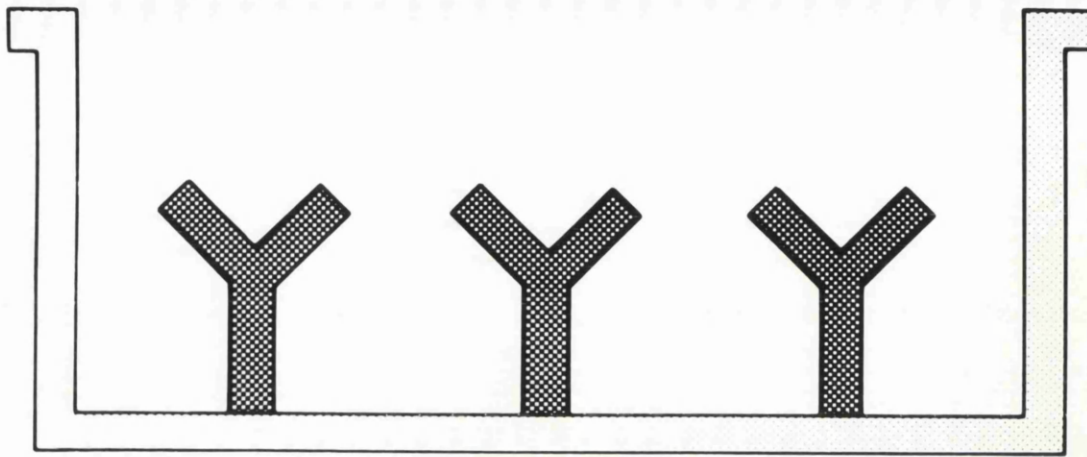
Following immobilisation of the capture antibodies, the plates were washed twice with PBS and then incubated with 2% human serum albumin in PBS for one hour at room temperature. The latter step effectively blocks non-specific protein binding sites on the solid phase. The plates were then washed again with PBS prior to the addition of the test CSF samples. Triplicate 50 ul. test samples of CSF were then added to both active and control wells in the plates and these were incubated for four hours at room temperature. During this incubation phase, any HMFG1 antigen present in the sample is bound to the solid phase polyvinylchloride by the capture antibody anti-HMFG1 in the active wells. No such binding should occur in the control wells where the capture antibody anti-AUA1 does not bind PEM. Following the incubation, the plates were washed three times with 0.05% Tween in PBS and then three times with PBS. 50 ul. aliquots of I-125 radiolabelled monoclonal antibody HMFG1 (10 mCi./mg.) containing approximately 2.5×10^5 cpm. activity were then added to active and control wells and incubated for two hours at room temperature. The microtitre plates were then washed with PBS, then three times with 0.05% Tween in PBS followed by three further washes with PBS. Individual wells were then cut out and measured for radioactivity in the gamma counter.

Fig. 4.4

Immunoabsorption of unlabelled capture antibody HMFG1 (anti-mucin) onto solid phase.


Fig. 4.5

Blocking of non-specific protein binding sites by addition of 2% human serum albumin.



UNLABELLED ANTI-MUCIN ANTIBODY

Fig. 4.4



UNLABELLED ANTI-MUCIN ANTIBODY

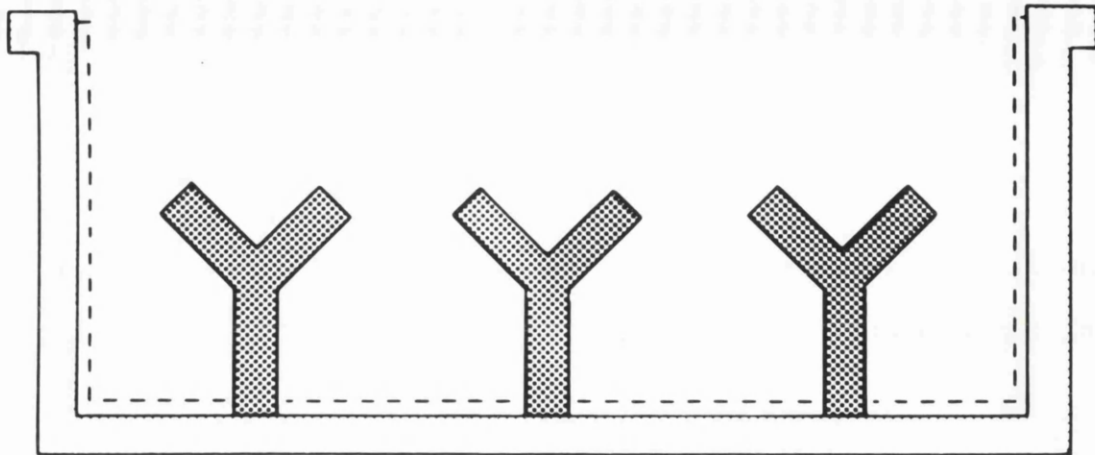
Fig. 4.5

Fig. 4.6

HMFG1 activated solid phase. Dashed line depicts 'non-stick' surface obtained by blockade of non-specific protein binding sites.

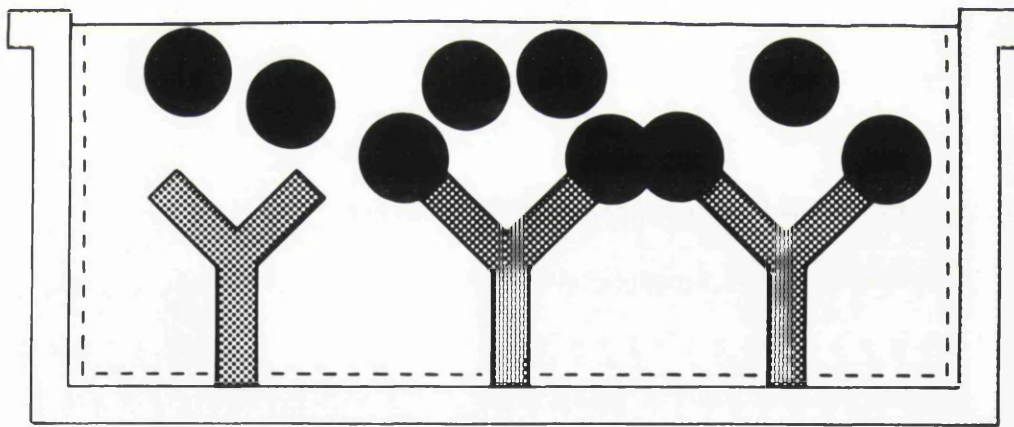
Fig. 4.7

Addition of serum/CSF containing PEM antigen.



UNLABELLED ANTI-MUCIN ANTIBODY

Fig. 4.6



UNLABELLED ANTI-MUCIN ANTIBODY



P.E.M.

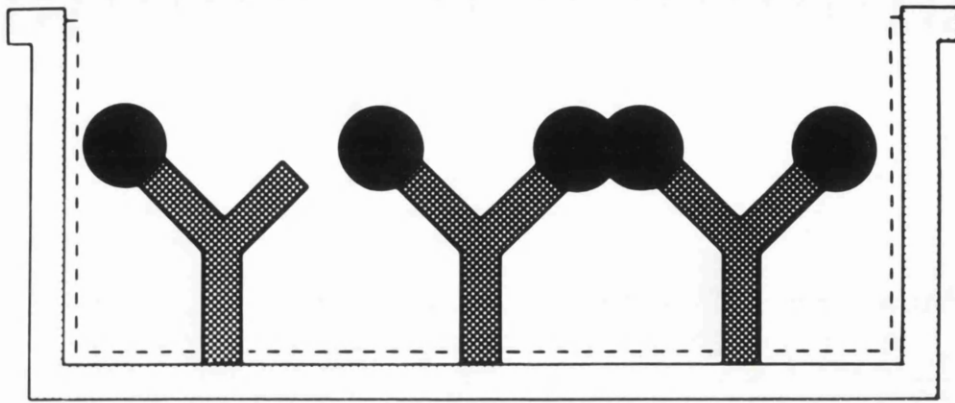
Fig. 4.7

Fig. 4.8

PEM antigen bound by capture antibody following removal of serum/CSF.

Fig. 4.9

Addition of I-125 labelled tracer HMFG1 (anti-mucin).

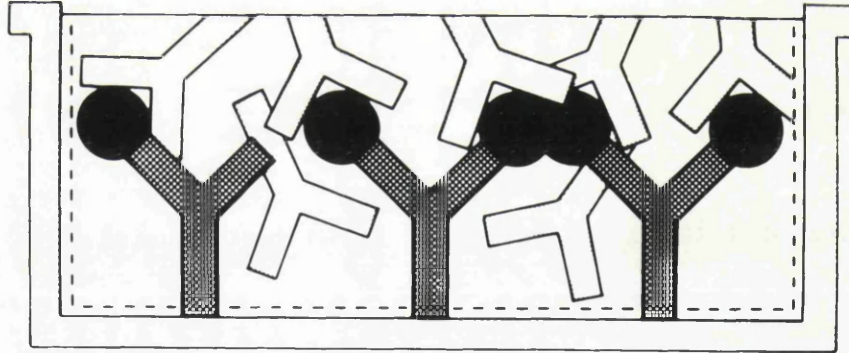


UNLABELLED ANTI-MUCIN ANTIBODY



P.E.M.

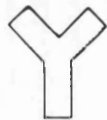
Fig. 4.8



UNLABELLED ANTI-MUCIN ANTIBODY



P.E.M.

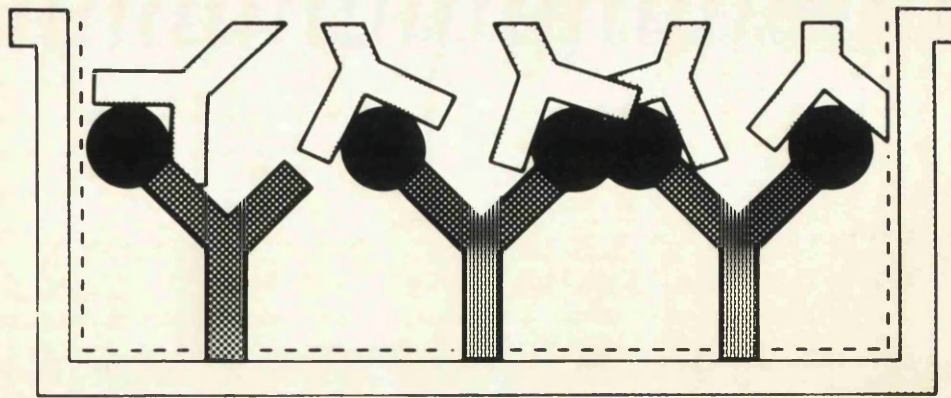


I - 125 LABELLED ANTI-MUCIN ANTIBODY

Fig. 4.9

Fig. 4.10

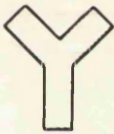Tracer I-125 labelled HMFG1 remains bound to solid phase via PEM antigen linkage.



UNLABELLED ANTI-MUCIN ANTIBODY



P.E.M.



I - 125 LABELLED ANTI-MUCIN ANTIBODY

Fig. 4.10

Control well activities were considered to represent non-specific molecular adhesion when less than 10^3 cpm. but when in excess of this, represented interference by spontaneously occurring heterophile antibodies. In the latter circumstances, estimation of mucin activity in test fluid was considered unreliable. The mean value of triplicate binding activities in control wells was subtracted from that in active wells to give an estimate of specific binding. The specific binding parameter was considered to reflect the HMFG1 antigen concentration and a radioimmunoassay calibration curve was produced with known standard sources of a purified HMFG1 antigen preparation (Fig. 4.11). This enabled approximate quantitation of HMFG1 antigen levels in test samples, but as there are no stoichiometrically defined preparations of the antigen available, arbitrary units of concentration were used. A series of 100 normal lumbar CSF specimens were tested with this assay system to determine a cut-off level of specific binding that could be designated a positive assay result.

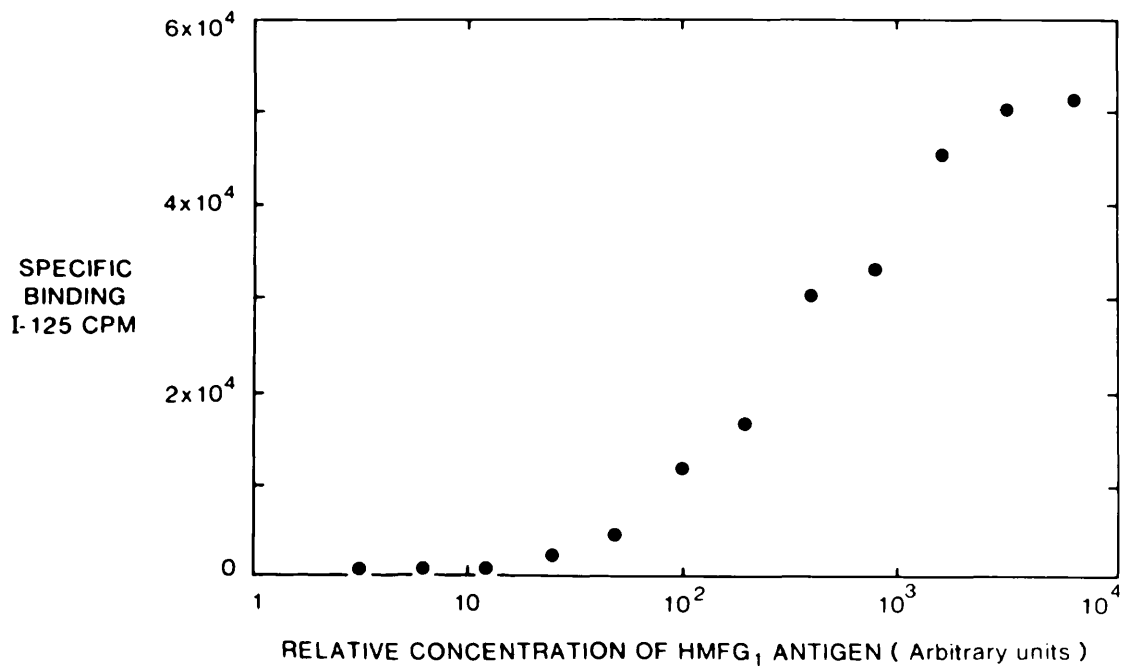


Fig. 4.11.

Radioimmunoassay Calibration Curve for HMFG₁ Antigen.

4.3 RESULTS

Specific binding activity values for our independently collected series of 100 normal CSF samples formed a scatter distribution with no values exceeding 250 cpm. A specific binding activity value of greater than 500 cpm. was arbitrarily designated as a positive assay result, and values below this were considered negative. Accurate quantitation of HMFG1 antigen concentration was only possible for specific binding activity values falling on the linear range of the standard curve (3,000-50,000 cpm.).

In our study, CSF HMFG1 antigen levels (displayed as specific binding activity) are presented graphically and categorised within the disorder groups previously defined (Fig. 4.12).

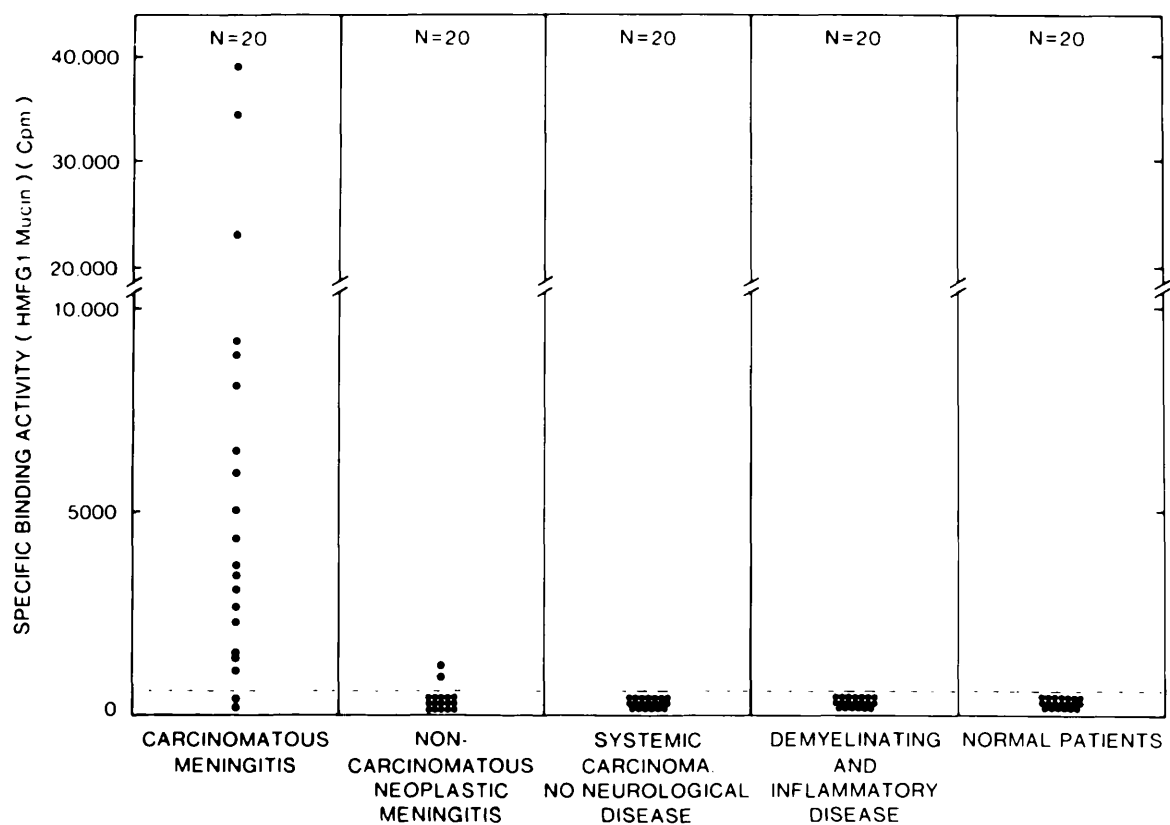


Fig. 4.12.

Cerebrospinal Fluid HMFG1 Antigen Levels in 100 Patients.

In 18 of 20 patients with carcinomatous meningitis, HMFG1 antigen levels were raised above normal. The range of specific binding activities seen in this group extended from 300 cpm. to 38,000 cpm. In 2 patients within the non-carcinomatous neoplastic meningitis group, HMFG1 antigen levels were marginally raised above normal. One patient had lymphomatous neoplastic meningitis and the other an extensive meningeal recurrence of medulloblastoma. All other CSF samples were negative to testing.

The potential diagnostic benefit conferred by the HMFG1 radioimmunoassay when used in conjunction with existing immunocytological techniques is illustrated by a study of the group 1 patients with carcinomatous meningitis. All of these patients had the diagnosis confirmed by CSF cytological examination or autopsy study. Table 4.2 compares the results of the diagnostic HMFG1 radioimmunoassay with existing CSF cytological diagnostic techniques in this group of patients.

TABLE 4.2

MONOCLONAL ANTIBODY IMMUNOCYTOCHEMISTRY AND
RADIOIMMUNOASSAY TECHNIQUES IN THE DIAGNOSIS OF
CARCINOMATOUS MENINGITIS

CASE NO.	PRIMARY NEOPLASM	CONVENTIONAL CYTOLOGY	IMMUNOCYTOLOGY	HMFG1 RIA
1	Ovary*	-	-	+
2	Bladder	+	+	+
3	Lung	+	+	+
4	Breast	+	+	+
5	Lung	-	-	+
6	Lung*	-	-	+
7	Stomach	+	NT	+
8	Breast	+	+	+
9	Breast	+	+	+
10	Colon	+	NT	+
11	Lung	+	NT	+
12	Breast	+	+	+
13	Lung	-	NT	+
14	Breast	+	+	+
15	Breast	+	NT	+
16	Breast	+	+	+
17	Breast	+	+	+
18	Lung	+	+	+
19	Stomach	-	-	-
20	SCLC	+	+	-

SCLC: SMALL CELL LUNG CARCINOMA

* : SUBSEQUENT CSF SAMPLES REVEALED POSITIVE CYTOLOGY

NT : NOT TESTED

Although carcinomatous meningitis was diagnosed in 18 or 20 cases with the radioimmunoassay, established cytological techniques were only successful in 15 of this group on initial testing. Subsequent CSF examination led to cytological diagnoses in 17 of 20 patients. In case 1, the CSF sample sent from abroad was 7 days old and the sample was non-diagnostic by cytological techniques. The implied diagnosis of carcinomatous meningitis by radioimmunoassay was confirmed several weeks later by conventional CSF cytology performed at the referring hospital. In case 5, a positive radioimmunoassay was not supported by a cytological diagnosis, despite multiple lumbar punctures. Carcinomatous meningitis was however confirmed at autopsy, and only demonstrated to involve the intracranial CSF pathways. The CSF sample of case 6, was inadvertently frozen in transport and was not diagnostic by cytological techniques. Subsequent CSF samples obtained from this patient were shown to contain carcinoma cells by cytological techniques. In case 13, a patient with primary lung adenocarcinoma was found to have extensive meningeal tumour infiltration at autopsy. He had previously been submitted to repeated lumbar puncture procedures which had been non-diagnostic cytologically but were positive to radioimmunoassay. Case 19 had neoplastic meningitis complicating a gastric primary tumour but was negative to all diagnostic methods. Case 20 had cytologically proven carcinomatous meningitis due to small cell lung carcinoma, but had no detectable HMFG1 antigen in his CSF. Immunohistochemical studies of tumour sections from cases 19 and 20 revealed no cellular expression of the antigens HMFG1 and HMFG2.

4.4 DISCUSSION

At present, the diagnosis of neoplastic meningitis is dependent upon the demonstration of exfoliated malignant cells within the CSF by cytological techniques. Monoclonal antibody immunocytology has significantly advanced the difficult field of diagnostic CSF cytology (Coakham et al. 1984a,b), which however still requires cytological expertise together with capture of sufficient numbers of exfoliated cells with well preserved morphology. There are significant theoretical advantages of biochemical assay systems for the detection of meningeal neoplasia. Such assays are of course independent of the presence of malignant cells in CSF samples. The molecular species assayed are also frequently non-labile and can be stored frozen for indefinite periods of time. Tumour markers may prove to be more accurate, especially in those patients with neoplastic meningitis in whom CSF cytology is persistently negative despite multiple lumbar punctures (Wasserstrom et al., 1982). Biochemical tumour marker assays may also offer a more quantitative and sensitive assessment of response to treatment. Our own experience with the HMFG1 radioimmunoassay would also suggest that tumour marker technology may be a more sensitive indicator of early disease, prior to the development of positive cytology or major neurological symptoms and signs.

In view of the potential advantages of biochemical systems for detection of neoplastic meningitis, it is disappointing that the numerous studies performed over the past three decades have failed to produce a tumour marker assay of high enough combined sensitivity and specificity for routine evaluation of CSF samples (Wasserstrom et al.,

1981). CSF tumour markers for neoplastic meningitis previously investigated have included the tumour associated glycoprotein carcinoembryonic antigen (Yap et al., 1980), specific isoenzymes of lactate dehydrogenase (Fleisher et al., 1981), beta-2-microglobulin (Mavligit et al., 1980). and beta-glucuronidase (Shuttleworth et al., 1980). The enzyme assays have generally lacked specificity and have consistently failed to distinguish neoplastic meningitis from chronic inflammatory meningitis. Beta-2-microglobulin similarly lacks specificity as a marker, as it is commonly raised in several conditions associated with blood/brain barrier disruption or leucocyte infiltration. Carcinoembryonic antigen (CEA) is a glycoprotein (molecular weight 200 KDa.) present in elevated quantities in the serum of many patients with a variety of systemic malignancies and inflammatory disorders (Macswen et al., 1972). In carcinomatous meningitis complicating breast carcinoma, elevated levels of CEA in the CSF have been reported in 70% of patients (Yap et al., 1980). Meningeal involvement with lung carcinoma and melanoma has also been associated with raised CSF CEA levels (Schold et al., 1980). Although CEA is usually non-detectable in the CSF (Snitzer et al., 1975), it has been reported that approximately 10% of patients without nervous system disease have small amounts of CEA within the CSF even when serum CEA is normal (Wasserstrom et al., 1981). It has also been established, that in the presence of grossly elevated serum CEA, significant quantities of this glycoprotein transgress the intact blood brain barrier producing detectable levels of CEA within the CSF in the absence of neurological disease (Schold et al., 1980). In view of the frequent absence of CEA in established neoplastic meningitis, and its occasional presence in normal CSF, this tumour associated antigen is of limited

value as a marker of meningeal neoplasia.

The monoclonal antibody HMFG1 binds to a large molecular weight glycoprotein, (Molecular Weight > 300 kDa.) which has been described as a mucin-like molecule containing at least 50% carbohydrate (Shimizu & Yamauchi, 1982). The molecular weight of the mucin can vary due to a genetic polymorphism in the core protein (Swallow et al., 1986) and the glycosylation of this core protein has been reported to be different in normal and malignant epithelial cells (Burchell et al., 1983).

The PEM mucin (polymorphic epithelial mucin) is shed from cells and has been detected in the sera of breast and ovarian cancer patients using a number of antibodies (Burchell et al., 1984; Ward and Cruickshank, 1987; Hayes et al., 1985; Hilkens et al., 1986; Dhokia et al., 1986; Price et al., 1987). Most of these assays also detect the mucin in a proportion of normal individuals, although certain epitopes appear to be preferentially expressed on the cancer associated mucin (Burchell et al., 1987).

Although the PEM mucin is present in some normal sera, it is theoretically unlikely to be present in normal CSF because the high molecular weight of the mucin should preclude transgression of the normal blood brain barrier. The data presented here suggests that even in more permeable blood/brain barrier states, passive transport of the antigen from serum is limited, as evidenced by the absence of antigen in most patients with non-carcinomatous neoplastic meningitis and inflammatory or demyelinating states. As we have been unable to demonstrate the presence of PEM mucin in normal central nervous system

by radioimmunoassay, we conclude that the presence of PEM mucin in the CSF implies the 'De Novo' synthesis of this compound within the central nervous system by metastatic carcinoma. It remains to be seen whether this hypothesis holds true in disease states accompanied by extensive disruption of the blood brain barrier.

In two patients with carcinomatous meningitis, PEM was not detected in CSF. One patient (case 19) presented with a rapidly progressive dementing illness before dying in coma. Multiple lumbar punctures were non-diagnostic. Autopsy revealed an unsuspected gastric carcinoma with extensive meningeal infiltration. Immunohistochemical studies of tumour tissue failed to demonstrate expression of HMFG1 or HMFG2 antigen. Our single patient with small cell lung carcinoma (case 20) was negative to testing by radioimmunoassay despite having easily demonstrable positive exfoliative CSF cytology. Again, immunohistochemical studies of tumour tissue failed to demonstrate expression of HMFG1 or HMFG2 antigen. As this tumour is of indeterminate histogenetic origin, it is conceivable that mucin synthesis might not be a constant feature of this neoplasm. In a small sample of SCLC patients, 67% of tumours have been reported to react positively with the HMFG1 antibody when tested by standard immunohistological techniques (Allan et al., 1987).

In two patients with non-carcinomatous neoplastic meningitis detectable levels of HMFG1 antigen were found in CSF. With extensive leptomeningeal tumour, there is effectively a large quantity of abnormal tissue within the central nervous system containing a widely fenestrated capillary vascular bed that allows free transgression of

macromolecules (Siegal et al., 1987). In this situation therefore the blood/brain barrier is disrupted, allowing permeation of relatively large molecular species into CSF. Detection of PEM in cerebrospinal fluid by assay systems could in these circumstances merely reflect leptomeningeal tumour bulk as opposed to specific antigens associated with the tumour type. Although the presence of epithelial membrane antigen (PEM) has been reported in immunohistochemical studies of malignant ependymal tumours (Cruz-Sanchez et al., 1988), we are unaware of its detection in medulloblastoma. However, in our patient with medulloblastoma, CSF concentration of PEM antigen was marginally greater than that in serum. This would suggest that PEM antigen can be expressed by medulloblastoma at levels below the sensitivity threshold of immunohistochemical techniques. Immunohistological studies of the original tumour failed to demonstrate the presence of epithelial membrane antigen. The low levels of HMFG1 activity detected in the CSF of our patient with lymphomatous meningitis probably also reflects true tumour expression of PEM mucin and this would be supported by a previous report of epithelial membrane antigen expression in lymphoid tissue (Delsol et al., 1984). Unfortunately, no tumour tissue from this patient was available for immunohistological examination.

In order to maximise diagnostic potential, other available antibodies to the PEM mucin which recognise epitopes different from the HMFG1 specific epitope should be tested. This is a particularly important point since because of the difference in glycosylation of the mucin produced by carcinoma cells, normally masked epitopes on the core protein may be exposed (Burchell et al., 1987) and different carbohydrate side chains may be added. Multiple assays using a panel

of anti-mucin antibodies could therefore be developed to specifically detect a number of epitopes on the PEM mucin whose expression might vary according to the degree of malignant transformation of an individual tumour. This may increase the diagnostic sensitivity of mucin radioimmunoassays for carcinomatous meningitis. It should be noted that cases 19 and 20, although negative for HMFG1 antigen, were positive for HMFG2 when this was tested for in the assay system.

In this study, the results obtained with the HMFG1 radioimmunoassay are encouraging, and appear to be more sensitive and specific than assays for other reported cancer markers in the CSF. A larger scale evaluation will be necessary to define the ultimate role of this mucin assay in the detection of carcinomatous meningitis. The sensitivity of this radioimmunoassay in comparison to existing cytological techniques for the detection of carcinomatous meningitis has yet to be established. Mucin radioimmunoassay techniques used in conjunction with other biochemical markers may offer a more sensitive diagnostic system for the early detection of carcinomatous meningitis. They may also afford quantitation of therapeutic response to treatment. It is hoped that similar assay systems for the detection of antigens expressed on neuroectodermal tumours may be developed. Such assays could potentially detect earlier meningeal dissemination of medulloblastoma and other childhood neuroectodermal tumours.

CHAPTER 5

NEOPLASTIC MENINGITIS: TREATMENT BY
ANTIBODY GUIDED RADIATION

5.1 INTRODUCTION

The development of monoclonal antibodies defining tumour associated antigens has significantly enhanced the field of diagnostic histopathology (Kemshead and Coakham, 1983; Gatter et al., 1985). As a natural extension of their success as immunocytochemical reagents, extensive investigation has explored their potential as vectors for targeting radionuclides (Larson et al., 1983; Carrasquillo et al., 1984), toxins (Jansen et al., 1982; Thorpe et al., 1985) or drugs (Embleton et al., 1983) to tumours. In animal xenograft tumour models, specific targeting of radioimmunoconjugates to tumour sites has been shown (Bourdon et al., 1984; Buchegger et al., 1986). Therapeutic efficacy has also been demonstrated in these models as evidenced by shrinkage and even cure of tumours (Jones et al., 1985; Lee et al., 1988a,b). In contrast to animal studies, the intravenous administration of monoclonal antibody immunoconjugates into patients with tumours has been consistently disappointing. In most studies, the percentage of the total injected dose of immunoconjugate localising within tumour tissue has been extremely low (approximately $10^{-3}\%$ of the injected dose per gram of tumour) and this has been attributed to several factors. Firstly, the volume of distribution of these radiopharmaceuticals in humans is several orders of magnitude greater than in laboratory animals and this dilutional effect clearly reduces the concentration of immunoconjugate at tumour sites (Sands, 1988). Secondly, the penetration of immunoconjugate into tumours may be severely restricted by limited permeability of these macromolecules across lipid membrane blood/tumour barriers (Sands et al., 1988). Other contributing factors cited have included the presence of tumour-shed

antigens (Zalutsky et al., 1988) and the removal of blood pool immunoconjugate by large systemic organs such as liver and spleen (Sands, 1988). Many of these problems are circumvented by the direct instillation of these reagents into body cavities where tumour cells are directly exposed to high concentration of immunoconjugate. These techniques were pioneered in the pleural, pericardial and peritoneal cavities (Epenetos et al., 1984, 1987; Pectasides et al., 1986). Monoclonal antibody immunoconjugates were subsequently instilled into the cerebrospinal fluid of patients with neoplastic meningitis (Lashford et al., 1988). Experience to date with intracavitary monoclonal antibody radioimmunotherapy has largely been with iodine-131 and yttrium-90. These predominantly beta-emitting radionuclides deliver short range energy to micrometastases, whilst sparing normal body tissues. Neoplastic meningitis is characterised by the existence of thin sheets of leptomeningeal tumour and free floating malignant cell clusters within the subarachnoid space. It is therefore theoretically amenable to specifically targeted short range radiation delivered via the CSF pathways. In preliminary studies of antibody guided radiation in neoplastic meningitis, demonstrable therapeutic responses were seen in patients with relatively radiosensitive forms of leptomeningeal neoplasia (Lashford et al., 1988; Coakham et al., 1988). We have subsequently undertaken a further study of 15 patients with neoplastic meningitis in order to evaluate this new therapeutic modality.

5.2 METHODS

5.2.1 PATIENT SELECTION

Fifteen patients with neoplastic meningitis were studied. Patients were considered for inclusion in the study if they had failed an adequate trial of conventional therapy and had evidence of leptomeningeal dissemination of tumour. In all patients, a full clinical evaluation of the disease was performed, supported by haematological and biochemical assessment. Cranial CT scanning was performed to exclude intracranial mass lesions prior to pan-myelography and CT cisternography with water soluble contrast medium ("Omnipaque", Nycomed, UK). CSF was obtained in all cases for diagnostic cytology and biochemical analysis.

Patients were not excluded from treatment on the basis of poor clinical condition, but were so if solid intraparenchymal mass lesions were demonstrated on cranial CT scanning. Patients were similarly excluded if myelography demonstrated obstruction to CSF flow by extensive tumour.

5.2.2 ANTIBODY SELECTION

Selection of a single monoclonal antibody for radiation targeting depended on the immunophenotype of the patient's tumour. The latter was established with a panel of monoclonal antibodies on tumour sections or CSF cytospin preparations. A further constraint imposed upon choice of antibody was based upon its immunohistochemical staining

reaction with normal tissue components of the central nervous system.

5.2.3 PREPARATION OF RADIOIMMUNOCONJUGATES

All immunoconjugate preparations were labelled with I-131 (IBS 30, Amersham International PLC, UK). Four patients received immunoconjugate radiolabelled with a modified chloramine-T technique by Dr J. T. Kemshead (cases 1, 2, 5 and 6) (Greenwood et al., 1963). All remaining preparations were radiolabelled with the iodogen technique previously described. All radiopharmaceuticals were sterilised by millipore filtration prior to administration to patients. Administered doses of I-131 immunoconjugate ranged from 20 - 60 mCi.

5.2.4 PATIENT PREPARATION AND ADMINISTRATION OF IMMUNOCONJUGATE

Thyroid blockade was undertaken in all patients and commenced approximately two weeks prior to therapy. This was achieved by administration of liothyronine 80 ug. once daily, potassium perchlorate 200 mg. three times daily and aqueous supersaturated potassium iodide solution (concentration 1 gm./ml.) 0.5 ml. three times daily. Thyroid blockade medication was continued for one month following therapy. All patients received dexamethasone 1 mg. three times daily to suppress chemical meningitis which was seen in earlier patients following intrathecal administration of immunoconjugate (Lashford et al. 1988). Intrathecal administration of immunoconjugate was by injection through an Ommaya reservoir ventriculostomy following an isovolumetric withdrawal of CSF. Administered immunoconjugate was flushed in by approximately 5 ml. of normal saline.

Patients were nursed in radioprotective facilities at Bristol Royal Infirmary until levels of radioactivity had fallen sufficiently to allow conventional nursing care to continue at Frenchay Hospital, Bristol.

5.2.5 IMAGING

Immunoscintigraphy of the neuraxis was performed with a General Electric MaxiCamera 400T equipped with a high energy parallel-hole collimator and linked to a DEC PDP 11/34 computer with gamma 11 software. Patients were scanned as soon and as often as their clinical condition permitted. Scanning usually commenced at approximately 5-7 days after therapy.

5.2.6 PHARMACOKINETICS

Blood and CSF samples were collected periodically following administration of immunoconjugate. Duplicate 2 ml. aliquots were counted for I-131 activity against standard sources of appropriate count rate. Concentration of immunoconjugate was expressed as a percentage of the injected dose per gram of blood/CSF, and displayed graphically as a function of time. Total immunoconjugate within the CSF compartment was also plotted as a function of time and for this purpose an approximate CSF volume of 120 ml. was assumed for all patients regardless of age. This was based on observations that only minimal central nervous system growth occurs beyond the age of five years (Bleyer, 1977b).

Serum samples were obtained by centrifugation of clotted blood at 800 x g for ten minutes. Protein bound radioactivity was estimated in all sera and CSF samples by TCA analysis. Selected sera and CSF samples were also analysed by gel filtration chromatography over a Sephacryl S300 column.

5.2.7 IN VITRO STUDIES OF IMMUNE COMPLEX FORMATION IN SERUM AND CSF

Serum and CSF samples were obtained from all 15 patients prior to therapeutic administration of murine monoclonal antibody. In vitro immune complex formation was studied by incubation of samples with a panel of I-125 radioimmunoconjugates - UJ13A, M340, 81C6 and HMFG1. I-131 labelled monoclonal antibody 45.6 was mixed with all I-125 radioimmunoconjugates to serve as a control non-binding antibody in serum/CSF incubations. All immunoconjugates were incubated overnight at room temperature in serum/CSF at an approximate concentration of 25 ng./ml. Immune complex formation was then detected by elution of incubated serum/CSF through a sephacryl S300 gel column (Fig. 5.1). When immune complex formation was demonstrated, its inhibition was attempted by pre-incubation of samples with (1) polyclonal mouse IgG (1 mg./ml.) and (2) the appropriate unlabelled monoclonal antibody UJ13A/M340/81C6/HMFG1 (1 mg./ml.). The methodology of this study was designed to characterise immune complexes as either antibody/antigen or antibody/anti-immunoglobulin species.

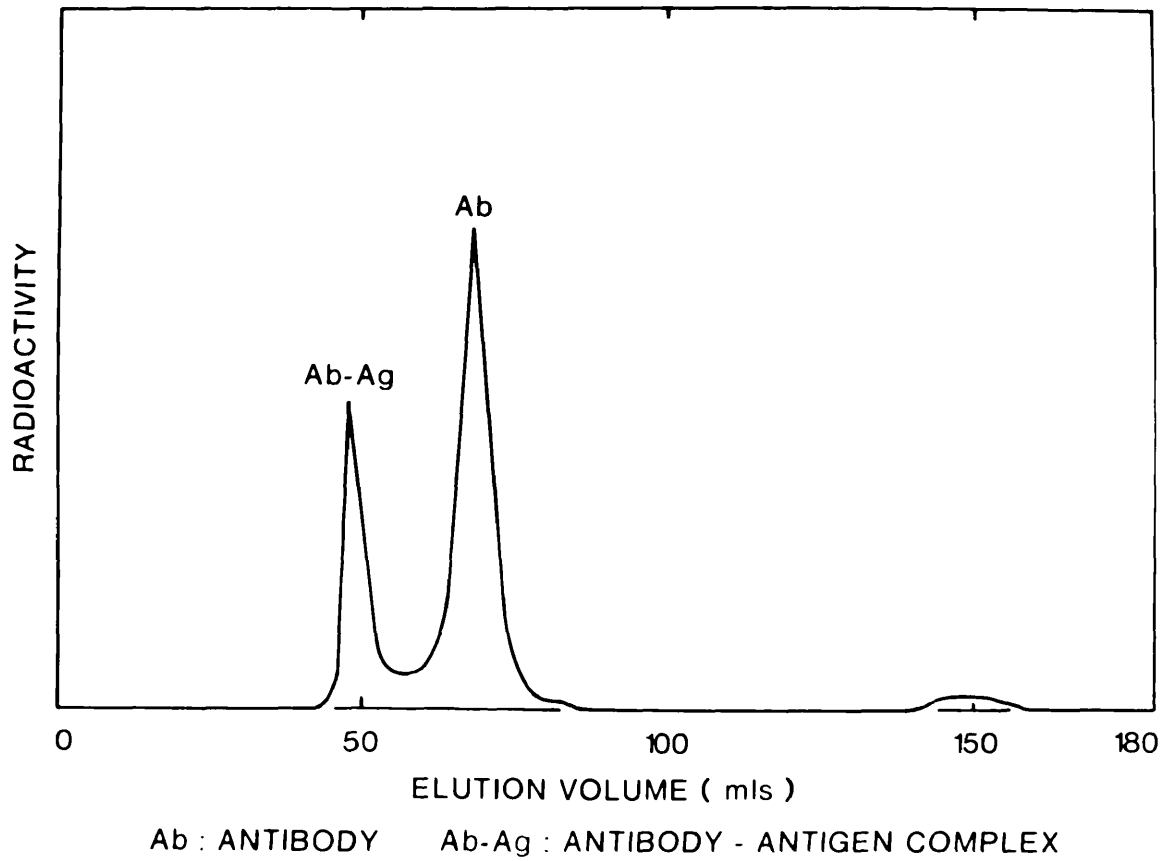


Fig. 5.1.

Elution Profile of Serum Incubated Monoclonal Antibody
HMFG1 Labelled with I-131 (Case 9).

5.2.8 DOSIMETRY

Planar scintigraphic imaging was insufficient to provide accurate quantitation of radioactivity in the central nervous system as a function of time. The fraction of central nervous system radioactivity bound to meningeal tissues was also unknown. We were therefore unable to provide meaningful radiation dose estimates for the central nervous system parenchyma and meningeal tissues.

Radiation dosimetry estimates to bone marrow were obtained indirectly from pharmacokinetic studies of immunoconjugate in blood. Estimates of total blood volume were made from standard nomograms (Geigy Scientific Tables 3, 1984) for each patient. Activity/time curves were constructed with total blood volume I-131 radioactivity (Becquerels) plotted as a function of time (seconds). The blood cumulative I-131 activity in Becquerel.seconds was then obtained by integration of these curves from time zero to infinity. In the absence of specific binding of immunoconjugates to bone marrow tissue components, it was assumed that the radioactivity source was located predominantly in blood, rather than in bone or other tissue. Active bone marrow is extremely vascular and cumulative I-131 activity within the marrow has been estimated as 40% of the integrated blood activity (Dr M.J. Myers, personal communication). Although proliferative marrow receives a radiation dose also from gamma rays in other body tissues, this amounts to 5% of the beta particle dose from activity inside the marrow and can be ignored in this context. The estimated marrow dose in cGy. was calculated from $A \times S \times \phi$ where A is the marrow cumulative I-131 activity in Becquerel.seconds, S is the S value for marrow as a source

and target organ (Snyder et al. 1978) (1.7×10^{-12} cGy/Becq.sec) and ϕ is the absorbed fraction for electrons in bone and marrow (Eckerman, 1985), here taken as a representative constant of 0.85.

5.2.9 DETECTION OF HUMAN ANTI-MOUSE ACTIVITY (HAMA)

HAMA was assayed for in serum and CSF of all patients prior to administration of immunoconjugate. In five patients with carcinomatous meningitis (cases 9, 11, 12, 13 and 15) serum and CSF was also obtained at six weeks following instillation of immunoconjugate. HAMA was assayed in these samples to ascertain the immunological response elicited by administration of murine monoclonal antibodies directly into the partial immunological sanctuary of the central nervous system.

IMMUNORADIOMETRIC ASSAY TECHNIQUE FOR HAMA

This solid phase immunoradiometric assay exploited the polyvalency of immunoglobulin species by use of the same antigen (polyclonal mouse IgG) as "catcher" and "tracer" reagent. Polyclonal mouse IgG (Sigma Chemical Co., UK) was adsorbed onto a polyvinylchloride solid phase, prior to incubation with serum or CSF. Human anti-mouse immunoglobulin, if present in the test sample, bound the solid phase immobilised polyclonal mouse IgG and was detected by the addition of I-125 radiolabelled tracer polyclonal mouse IgG. The labelled tracer was bound by free valencies of the immunologically captured human anti-murine immunoglobulin (Fig. 5.2).

The precise assay method involved the use of flat bottomed microtitre

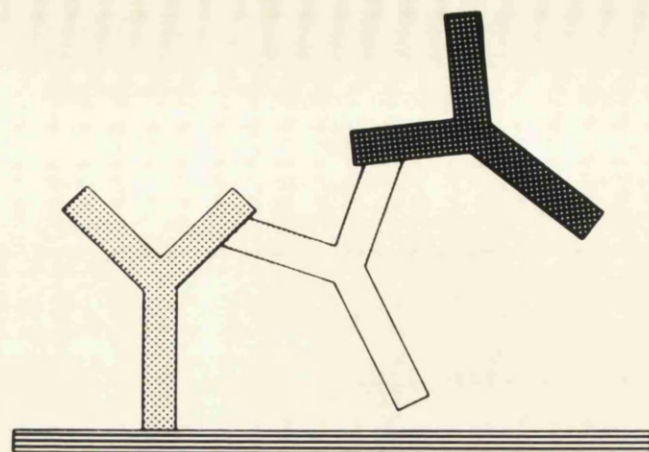
plates (Dynatech, UK) which were scored longitudinally to separate three rows of active and three rows of control wells. In the designated active wells, 0.5 ug. of polyclonal mouse IgG in 50 ul. of PBS was allowed to evaporate to dryness at room temperature. The control wells were similarly activated with PBS. Following immunoadsorption, the plates were washed twice with PBS and then incubated with 2% human serum albumin in PBS for one hour at room temperature. The plates were then washed once again with PBS prior to the addition of the test sera/CSF samples. Triplicate 50 ul. test samples of sera/CSF were then added to both active and control wells in the plates and these were incubated for four hours at room temperature. Following the incubation, the plates were washed three times with 0.05% Tween in PBS and then three times with PBS. I-125 radiolabelled mouse IgG (specific activity 10 mCi./mg.) was then added to active and control wells in aliquots of 50 ul. containing approximately 2.5×10^5 cpm. activity. Following a further two hour incubation period at room temperature, the plates were washed with PBS, then three times with 0.05% Tween in PBS followed by three further washes in PBS. Individual wells were cut out and assayed for radioactivity in a gamma counter. The mean value of triplicate binding activities in control wells was subtracted from that in active wells to give an estimate of specific binding. The specific binding parameter was considered to reflect anti-mouse activity within the test sample and a radioimmunoassay calibration curve was produced from a dilution series of goat anti-mouse immunoglobulin (Sigma Chemical Co., UK) (Fig 5.3). Baseline observations with the assay system were obtained by testing 100 normal sera and 100 normal lumbar CSF specimens.

Fig. 5.2

Principles of direct anti-murine immunoglobulin assay. Anti-murine antibodies link solid phase bound unlabelled 'capture' mouse IgG to I-125 labelled tracer mouse IgG.

Fig. 5.3

Anti-murine immunoglobulin radioimmunoassay calibration curve.






-  SOLID PHASE IMMOBILISED POLYCLONAL MOUSE IgG
-  HUMAN ANTI-MOUSE IMMUNOGLOBULIN
-  RADIOLABELLED TRACER POLYCLONAL MOUSE IgG

Fig. 5.2

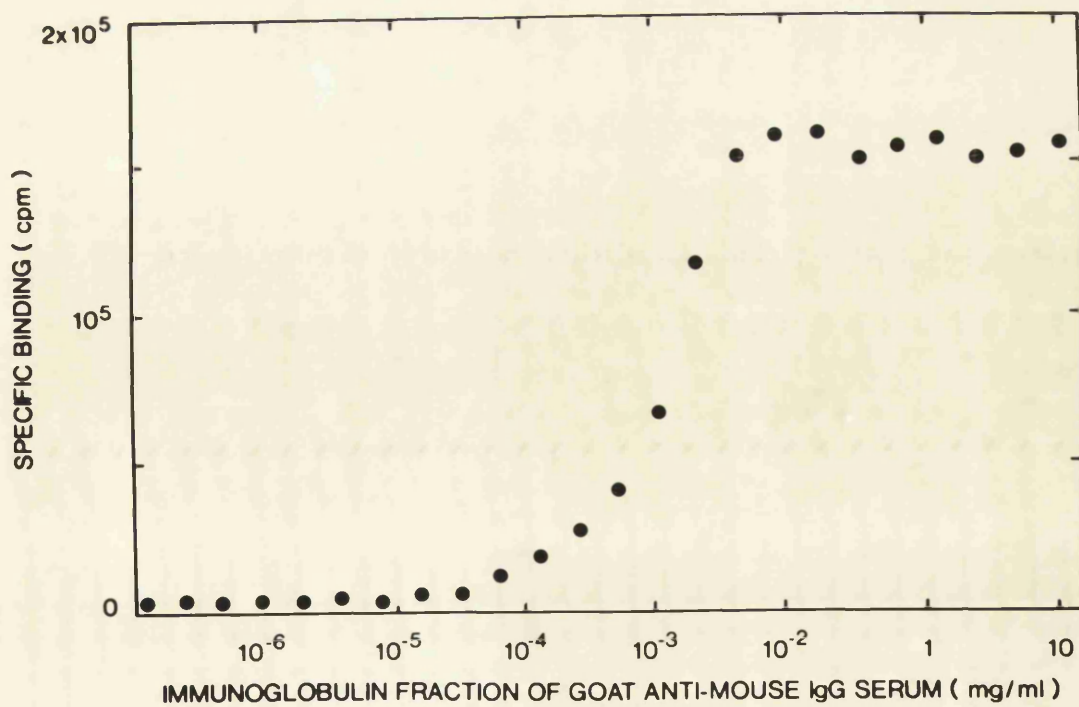


Fig. 5.3

5.2.10 EVALUATION OF CLINICAL RESPONSE

Patients were evaluated for response if they had received neither chemotherapy nor radiotherapy to all evaluable sites within the preceeding six weeks. These conditions were waived if the patients had clear evidence of disease progression in the intervening period. Response was assessed at three monthly intervals by clinical examination, cranial CT scanning and examination of CSF. Myelography was performed when possible at three months following therapy.

5.3 RESULTS

5.3.1 PATIENT SELECTION

Fifteen patients with neoplastic meningitis were studied. The age range was 8 - 60 years and there were seven males and eight females. Cases 1-8 had tumours derived from neuroectoderm and cases 9-15 had primary systemic carcinomas (carcinomatous meningitis) (Table 5.1).

5.3.2 PREPARATION AND QUALITY CONTROL OF RADIOIMMUNOCONJUGATES

Cases 1, 2, 5 and 6 received immunoconjugate prepared by a modified chloramine-T technique. The remaining cases received immunoconjugate prepared by the iodogen technique previously described. Specific activity of labelling ranged from 5-10 mCi./mg. of protein. Parameters of quality control for individual preparations are illustrated in Table 5.2.

TABLE 5.1 AGE, SEX AND PRIMARY TUMOURS
OF PATIENTS WITH NEOPLASTIC MENINGITIS

CASE NO.	PATIENTS	AGE IN YEARS	SEX	PRIMARY TUMOUR
1	JC	19	M	Medulloblastoma
2	LH	12	F	Medulloblastoma
3	DH	33	M	Malignant glioma
4	RB	8	M	Malignant glioma
5	HK	53	F	Malignant melanoma
6	JS	21	F	Medulloblastoma
7	LB	12	F	Medulloblastoma
8	RB	34	M	Ependymoma
9	MK	48	F	Ovarian carcinoma
10	HR	60	F	Bladder carcinoma
11	JW	44	F	Breast carcinoma
12	WS	57	M	Large cell lung carcinoma
13	KD	41	M	Lung adenocarcinoma
14	UR	36	F	Breast carcinoma
15	JJ	50	M	Large cell lung carcinoma

TABLE 5.2

IMMUNOCONJUGATE QUALITY CONTROL

CASE NO.	NAME	MONOCLONAL ANTIBODY	ADMINISTERED 1-131 RADIOACTIVITY mCi	% TCA SOLUBLE FRACTION	IMMUNOREACTIVE FRACTION %
1	JC	UJ181.4	46	4.3	34
2	LH	UJ181.4	33	13.1	2
3	DH	81C6	60	2.5	71
4	RB	81C6	40	1.6	72
5	KH	ME1-14	60	2.7	36
6	JS	UJ181.4	48	4	2
7	LB	M340	45	1.4	78
8	RB	UJ13A	20	20.8	62
9	MK	HMFG1	55	4.1	65
10	HR	HMFG1	55	1.7	70
11	JW	HMFG1	58	2.1	64
12	WS	HMFG1	56	2.1	65
13	KD	HMFG1	30	1.2	70
14	UR	HMFG1	60	3	52
15	JJ	HMFG1	54	8	60

In cases 2 and 6, the specific immunoreactive fraction of immunoconjugate was 2% and these preparations were considered biologically inactive.

TCA solubility of radioimmunoconjugate varied from 1.2%-20.8%. Sephacryl S300 gel filtration was performed on all radioimmunoconjugate preparations. In all except case 2, over 90% of radioactivity eluted as a single molecular weight species with retention time characteristic of IgG. In case 2, radioactivity eluted as a continuous irregular profile indicating aggregation and fragmentation of monoclonal antibody UJ 181.4 (Fig. 5.4). The specific immunoreactivity of immunoconjugates varied from 2%-78%.

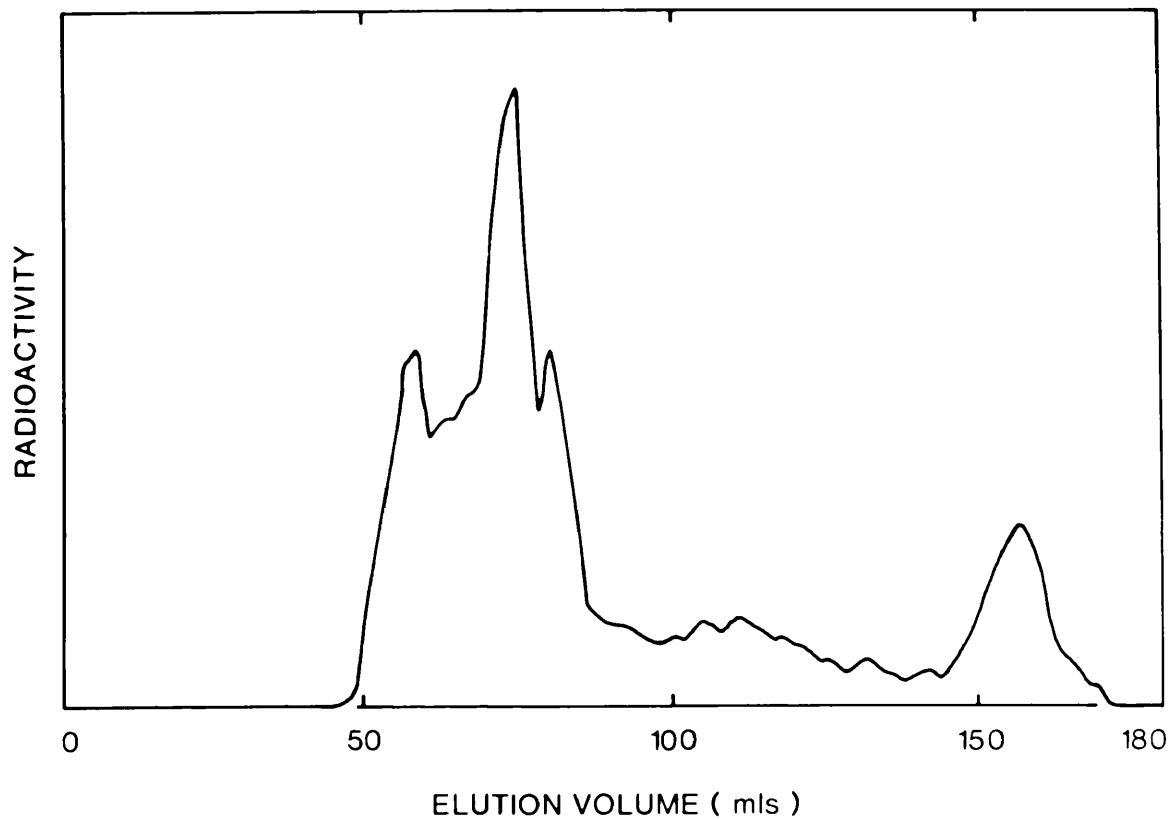


Fig. 5.4.

Elution Profile of Monoclonal Antibody UJ181.4 Labelled with I-131 (Case 2).

5.3.3 BIODISTRIBUTION OF RADIOIMMUNOCONJUGATE: IMMUNOSCINTIGRAPHY

Although neuraxial gamma scintigraphy revealed isotope within the cerebral ventricles and craniospinal subarachnoid space of most patients, its complete distribution throughout the whole CSF space was only seen in one patient (case 6). Paucity of isotope distribution was commonly seen over the cerebral hemisphere convexities or within the basal subarachnoid cisterns. Sites of increased neuraxial isotope uptake were frequently demonstrated at clinically suspected and/or radiologically demonstrated sites of disease (Tables 5.3 and 5.4) (Figs. 5.5-5.17). This was also evident in cases 2 and 6, who were administered biologically inactive immunoconjugate.

The lumbar/sacral canal was a common site of increased scintigraphic activity. Anatomical distribution of lumbar/sacral isotope was frequently observed to extend laterally beyond the confines of the dural sac. Sites of systemic isotope distribution varied significantly amongst patients. In case 4, an inadequately ligated ventriculo-peritoneal shunt resulted in escape of isotope into the peritoneal cavity. No scintigraphy was performed in cases 10 and 11.

TABLE 5.3

INTRATHECAL THERAPY: DIAGNOSTIC RADIOLOGY

CASE NO.	NAME	CT/MYELOGRAPHY
1	JC	Residual cerebellar tumour and thoracic spinal cord encasement by leptomeningeal tumour.
2	LH	Right cerebellar hemisphere cystic tumour recurrence and enhancing tumour nodule at periphery of left sylvian fissure.
3	DH	Residual right occipital lobe tumour with ependymal spread.
4	RB	Site of previous temporal lobe surgery demonstrated with no evidence of tumour recurrence.
5	KH	Site of previous frontal and occipital lobe surgery demonstrated but no evidence of tumour.
6	JS	Site of previous posterior fossa surgery demonstrated, but no evidence of local recurrence. Nodular leptomeningeal tumour involving cauda equina.
7	LB	Hydrocephalus. Site of previous posterior fossa surgery, demonstrated, but no evidence of local recurrence. Nodular leptomeningeal tumour involving cauda equina.
8	RB	Site of previous posterior fossa surgery demonstrated with evidence of leptomeningeal tumour in basal cisterns and cauda equina.
9	MK	Excess CSF over cerebral hemisphere convexities and nodular leptomeningeal tumour involving cauda equina.
10	HR	Hydrocephalus.
11	JW	Normal.
12	WS	Hydrocephalus. Nodular leptomeningeal tumour involving cauda equina.
13	KD	Multiple low density areas seen over cerebral hemisphere convexities. Nodular leptomeningeal tumour involving cauda equina.
14	UR	Hydrocephalus. Diffuse contrast enhancement over left cerebral hemisphere convexity.
15	JJ	Nodular leptomeningeal tumour involving cauda equina.

TABLE 5.4 INTRATHECAL THERAPY: IMMUNOSCINTIGRAPHY

CASE NO.	NAME	EXTENT OF NEURAXIAL DISTRIBUTION	SITES OF INCREASED NEURAXIAL DISTRIBUTION	SITES OF EXTRANEURAXIAL DISTRIBUTION
1	JC	Incomplete	Posterior fossa Thoracic spine	Liver
2	LH	Incomplete	Posterior fossa Lumbar/Sacral spine	Diffuse thoracic
3	DH	Incomplete	Left cerebral hemisphere Thoracic spine Lumbar/Sacral spine	Liver Spleen
4	RB	Incomplete	Third ventricular region Lumbar/Sacral spine	Thyroid Peritoneal cavity *
5	KH	Incomplete	Thoracic spine Lumbar/Sacral spine	Diffuse thoracic Spleen Bone Marrow
6	JS	Complete	Posterior fossa Thoracic spine Lumbar/Sacral spine	Diffuse thoracic
7	LB	Incomplete	Thoracic spine Lumbar/Sacral spine	Diffuse thoracic
8	RB	Incomplete	Lumbar/Sacral spine	Liver
9	MK	Incomplete	Cranial vertex Lumbar/Sacral spine	Thyroid Abdominal Foci
10	HR	—	—	—
11	JW	—	—	—
12	WS	Incomplete	Lumbar/Sacral spine	Spleen
13	KD	Incomplete	Left hemisphere convexity Lumbar/Sacral spine	Spleen
14	UR	Incomplete	Thoracic spine	Diffuse thoracic
15	JJ	Incomplete	Lumbar/Sacral spine	Diffuse thoracic

* Leakage through a patent VP. Shunt.

EMF
-51-55 .2 . . 10042 P.T. 2. 55-15-

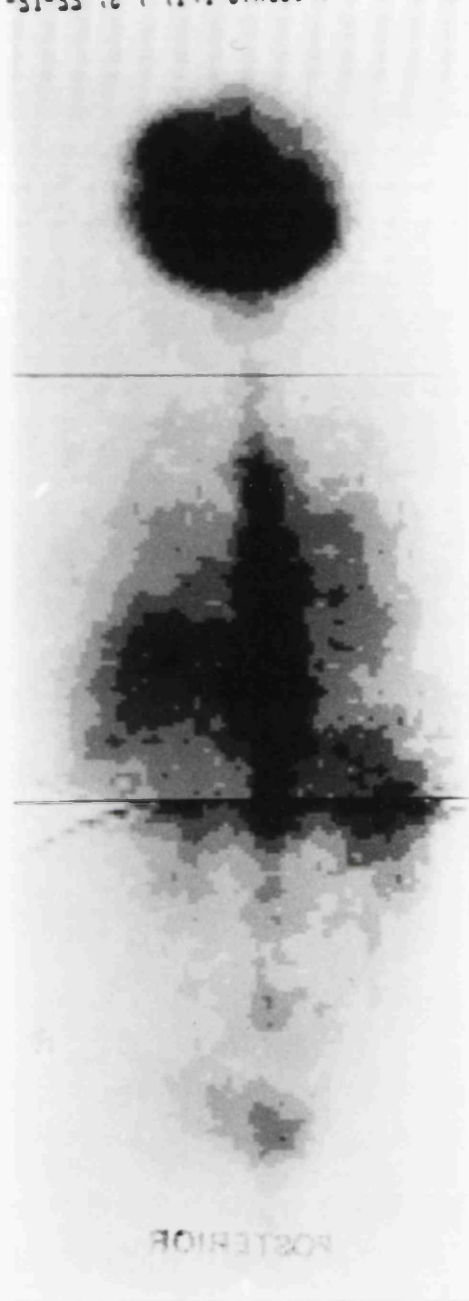


Fig. 5.5

Composite scintigram of case 1 (JC) at 10 days following intrathecal administration of I-131 labelled UJ181.4.



Fig. 5.6

Composite scintigram of case 2 (LH) at 7 days following intrathecal administration of I-131 labelled UJ181.4.

DAVID , 14DAYS P/T , ANTIBOT

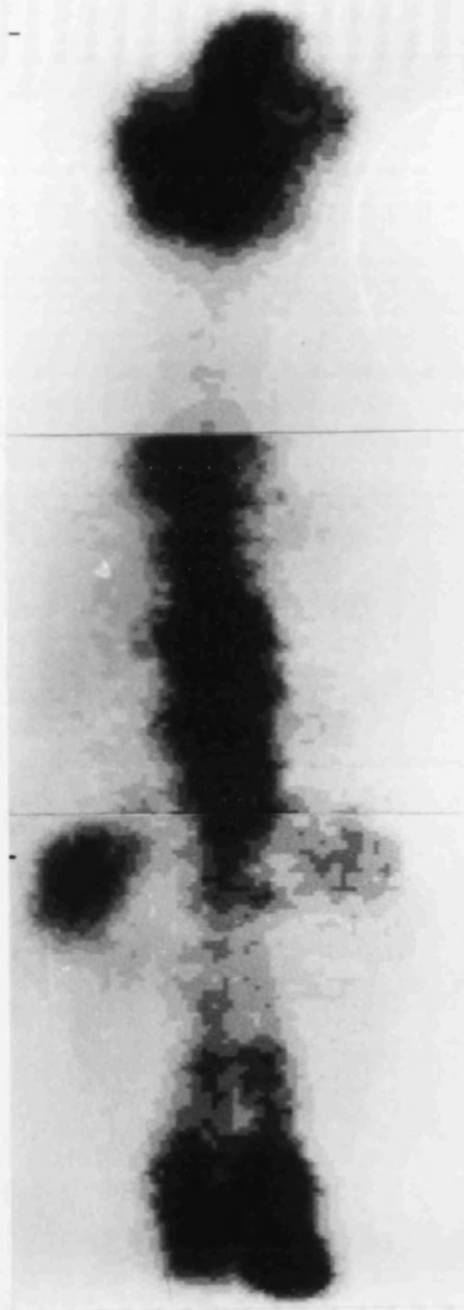


Fig. 5.7

Composite scintigram of case 3 (DH) at 14 days following intrathecal administration of I-131 labelled 81C6.

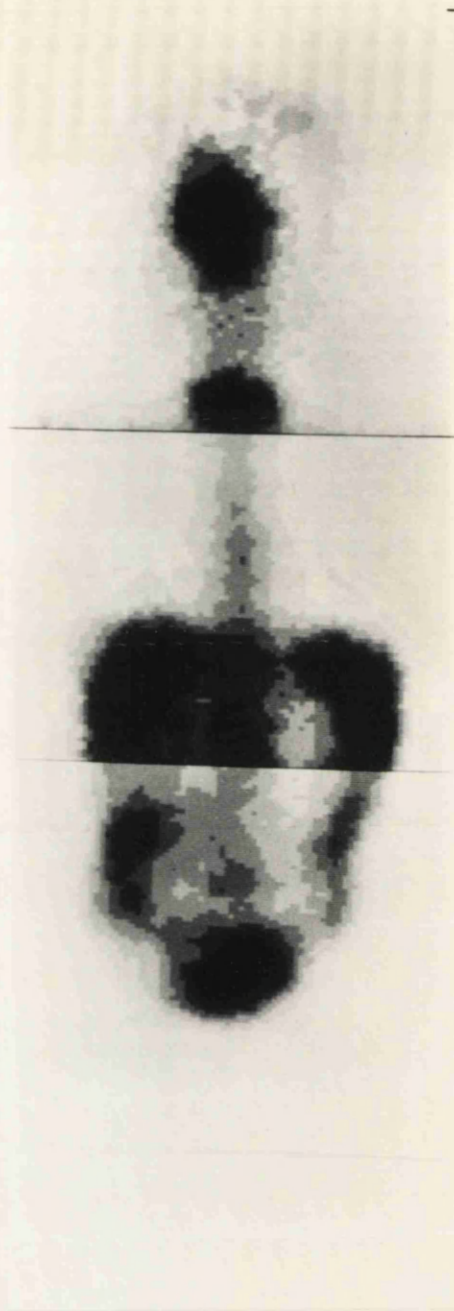


Fig. 5.8

Composite scintigram of case 4 (RB) at 10 days following intrathecal administration of I-131 labelled 81C6.

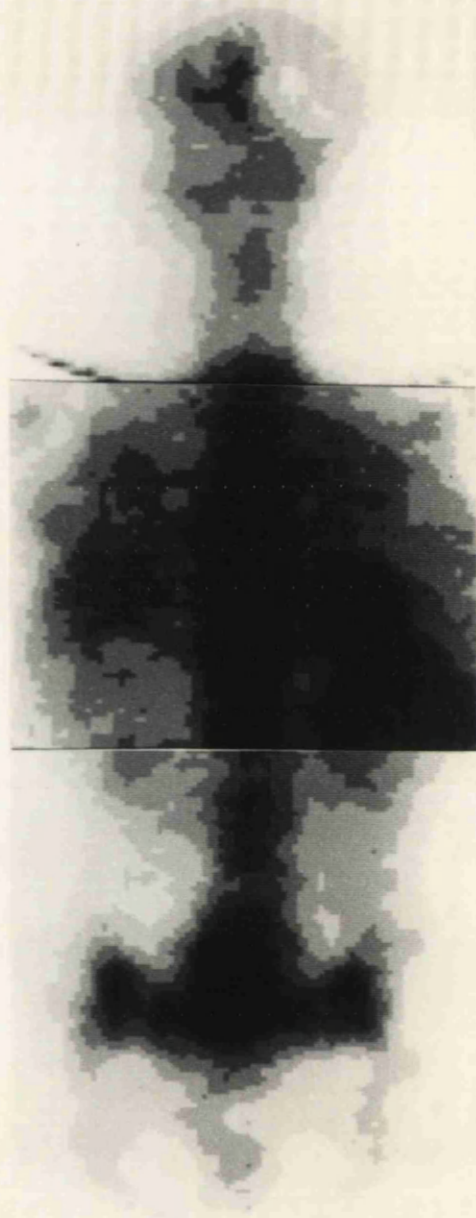


Fig. 5.9

Composite scintigram of case 5 (KH) at 11 days following intrathecal administration of I-131 labelled ME1-14.

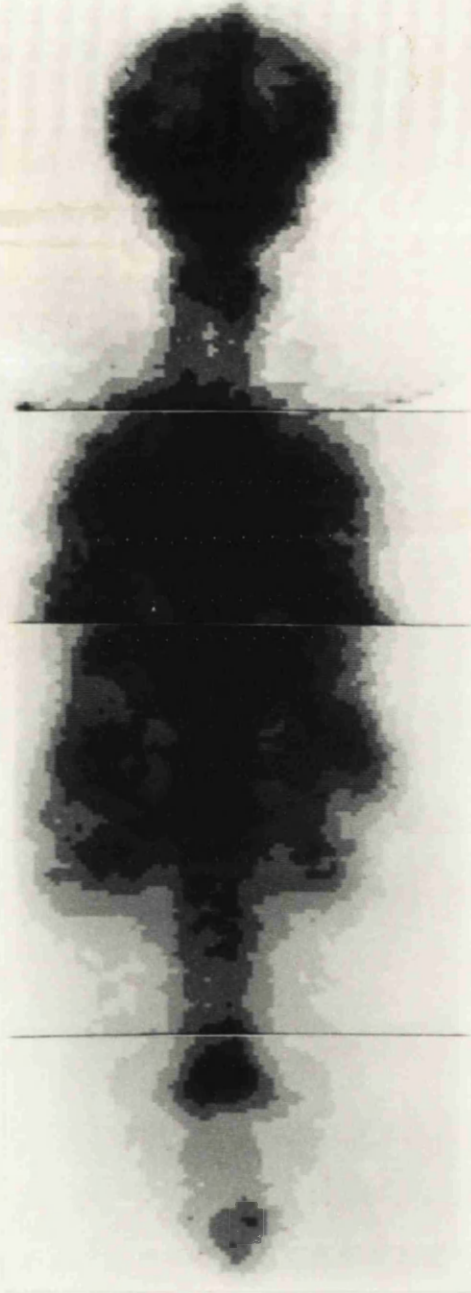


Fig. 5.10

Composite scintigram of case 6 (JS) at 6 days following intrathecal administration of I-131 labelled UJ181.4.

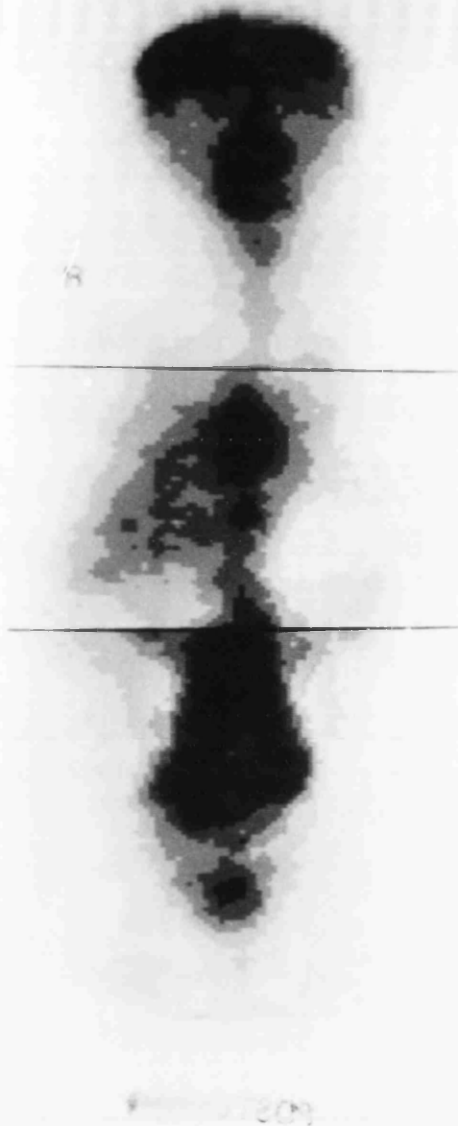


Fig. 5.11

Composite scintigram of case 7 (LB) at 6 days following intrathecal administration of I-131 labelled M340.

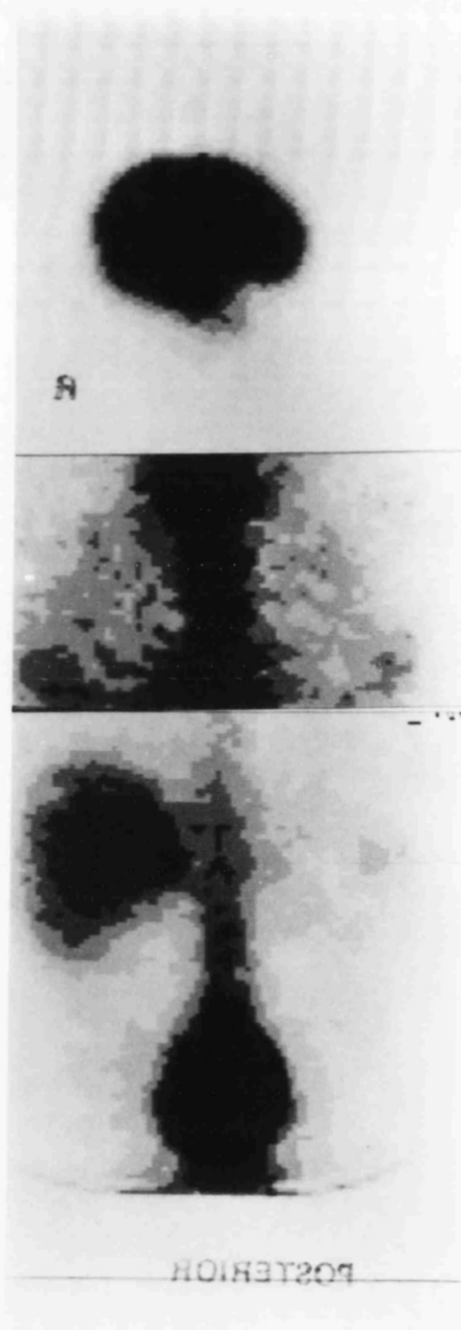


Fig. 5.12

Composite scintigram of case 8 (RB) at 4 days following intrathecal administration of I-131 labelled UJ13A.

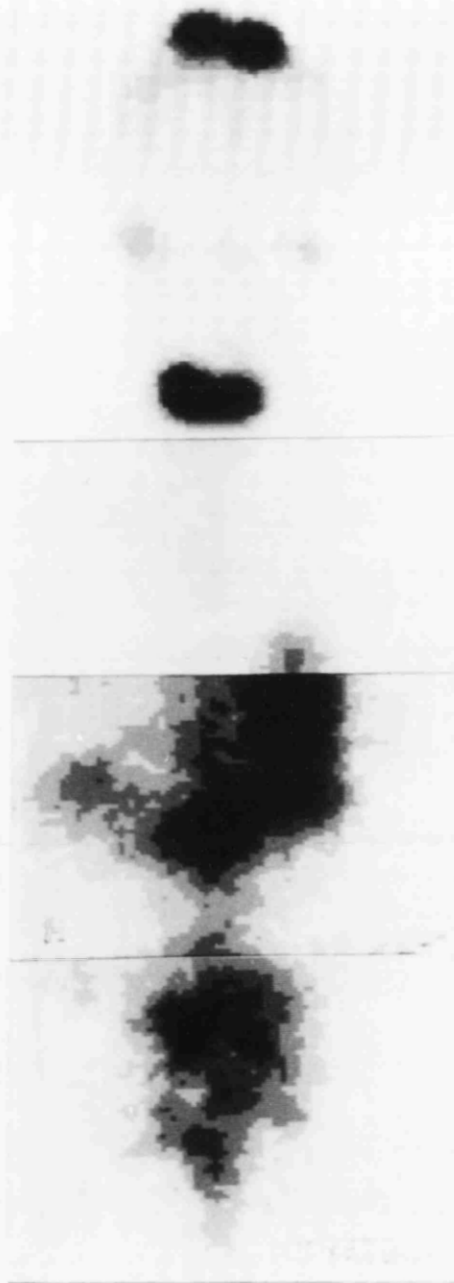


Fig. 5.13

Composite scintigram of case 9 (MK) at 10 days following intrathecal administration of I-131 labelled HMFG1.

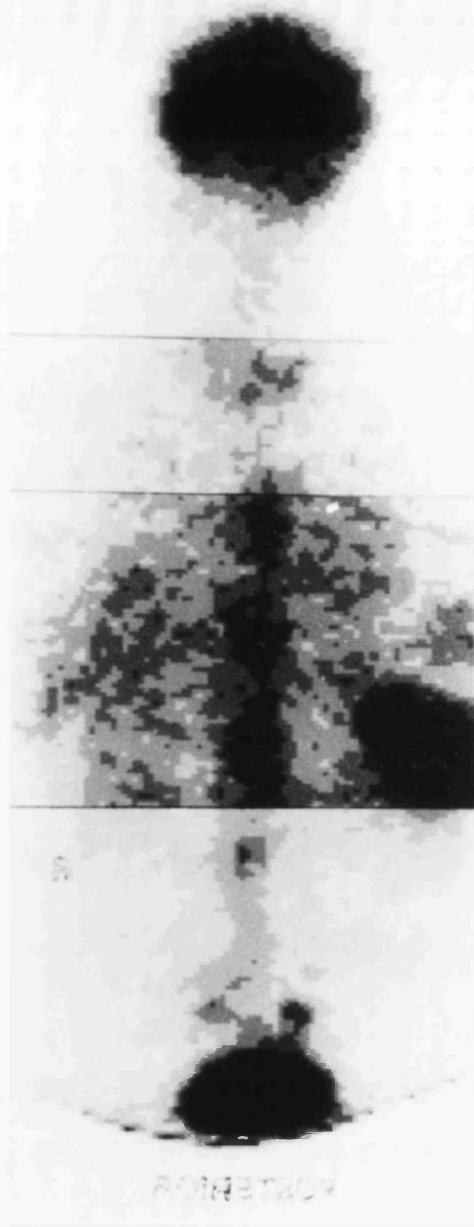


Fig. 5.14

Composite scintigram of case 12 (WS) at 7 days following intrathecal administration of I-131 labelled HMFG1.

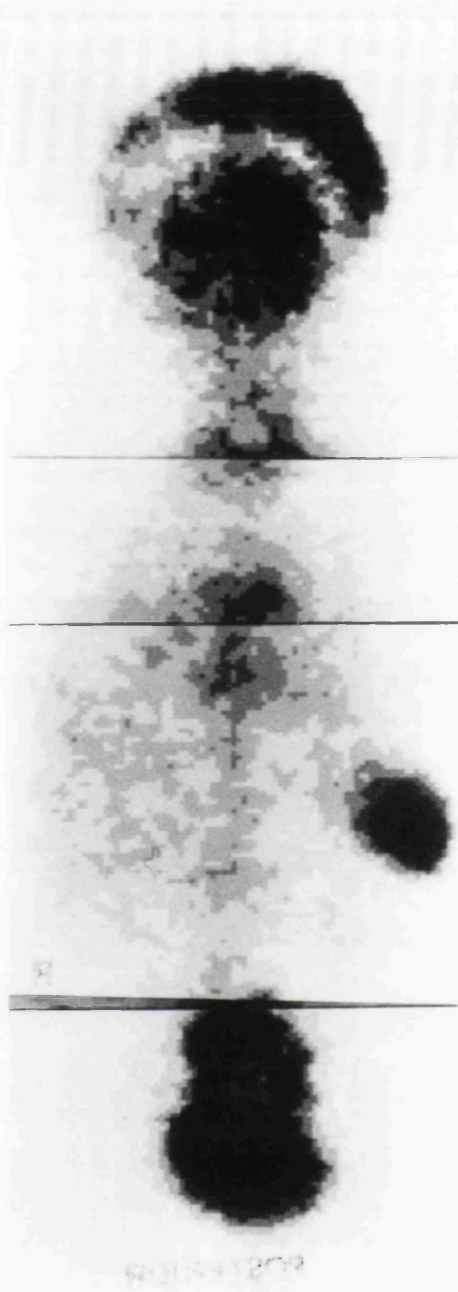


Fig. 5.15

Composite scintigram of case 13 (KD) at 8 days following intrathecal administration of I-131 labelled HMFG1.

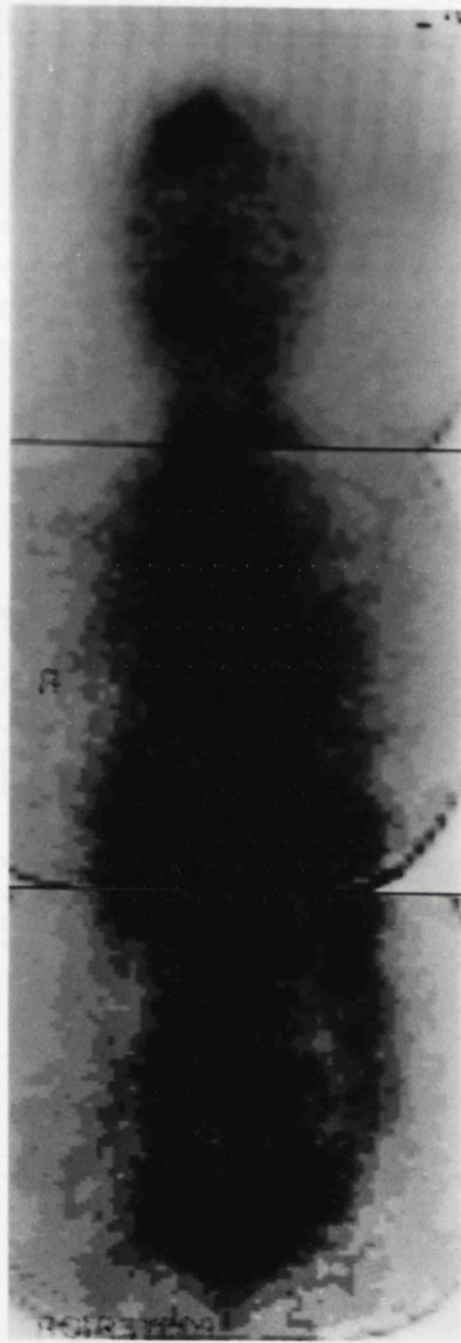


Fig. 5.16

Composite scintigram of case 14 (UR) at 13 days following intrathecal administration of I-131 labelled HMFG1.

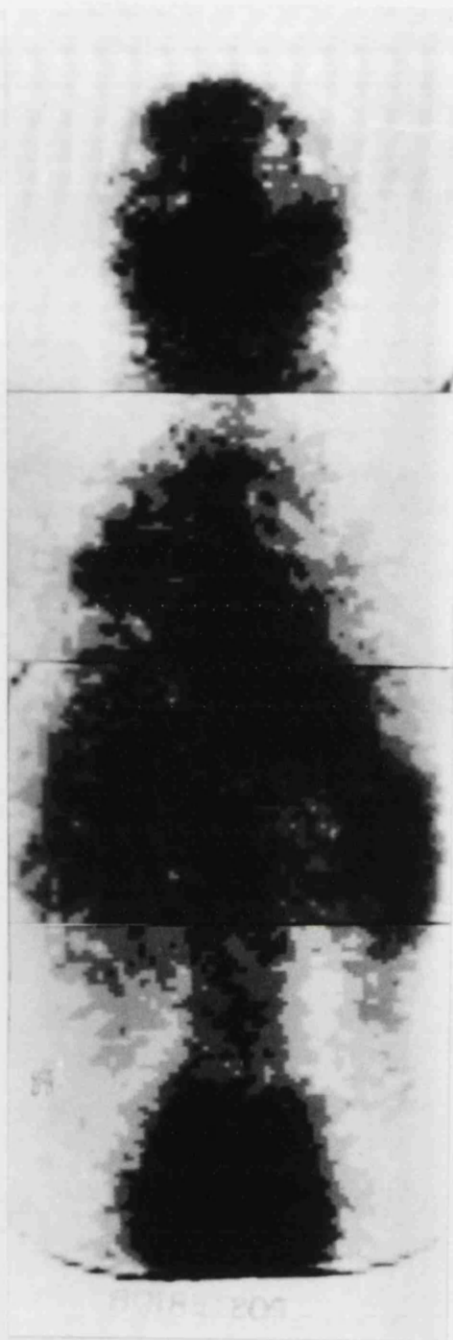


Fig. 5.17

Composite scintigram of case 15 (JJ) at 10 days following intrathecal administration of I-131 labelled HMFG1.

5.3.4 PHARMACOKINETICS: BLOOD VASCULAR COMPARTMENT

Transfer of isotope from the central nervous system to the systemic vascular compartment was fairly rapid with peak blood concentrations occurring at 12-48 hours. Concentration of immunoconjugate as a function of time was characteristically biphasic with ascending and descending components (Fig. 5.18). Curve fitting by digital computerised regression analysis failed to produce parameter estimates of acceptable statistical accuracy.

Fig. 5.18

Blood concentration/time curves for I-131 activity following intrathecal administration of monoclonal antibodies. Curves for individual patients (cases 1-15) depicted.

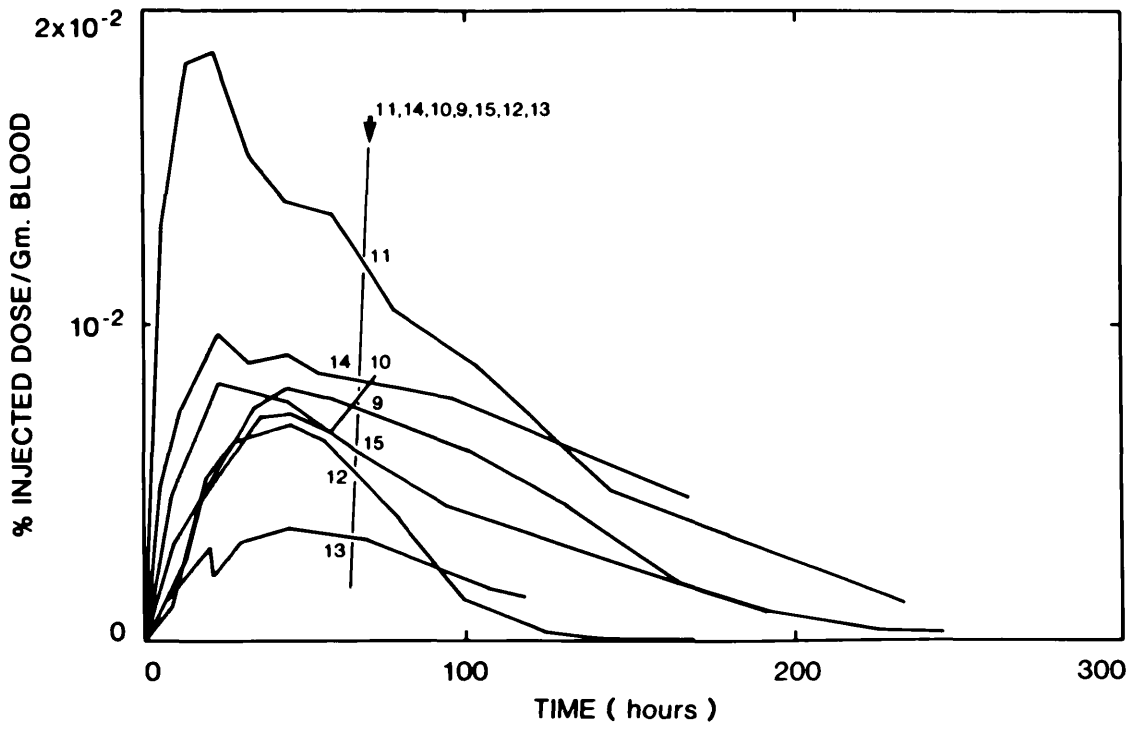
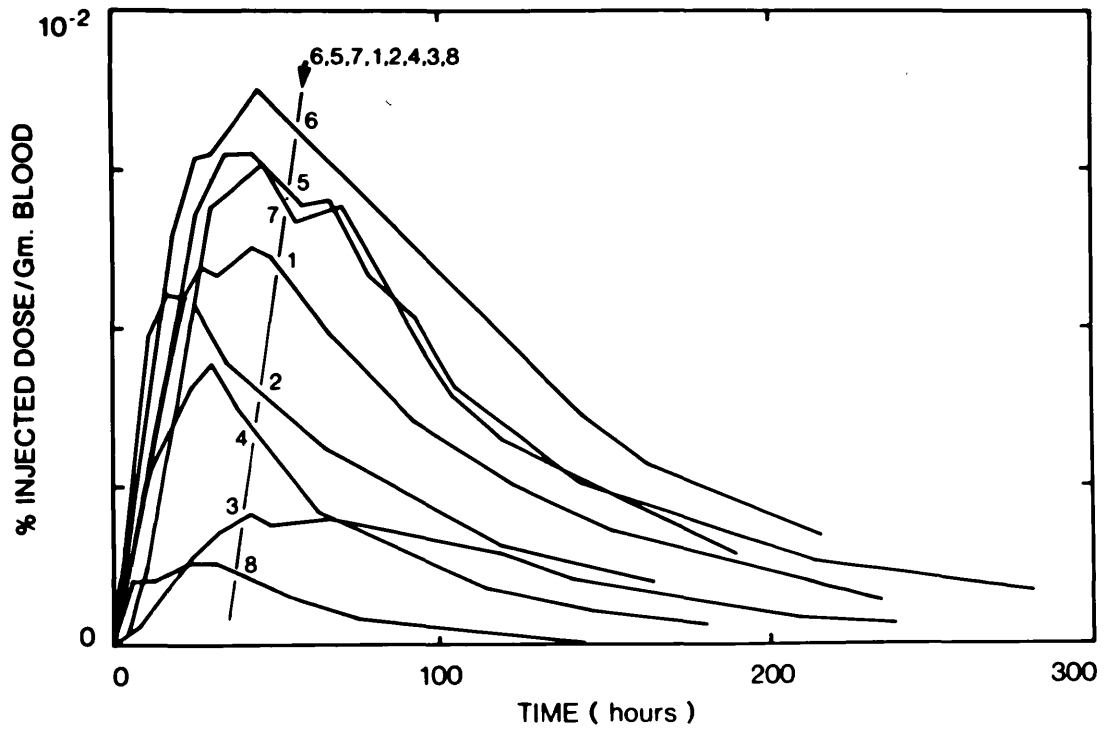


Fig. 5.18

TCA analysis of serum samples revealed isotope predominantly protein bound (Fig. 5.19). Early serum samples characteristically exhibited higher fractions of TCA soluble isotope. In some cases, the fraction of TCA soluble radioactivity subsequently increased in later samples.

Fig. 5.19

Percentage TCA soluble fraction of serum radionuclide following intrathecal administration of monoclonal antibodies. Curves for individual patients (cases 1-15) depicted.

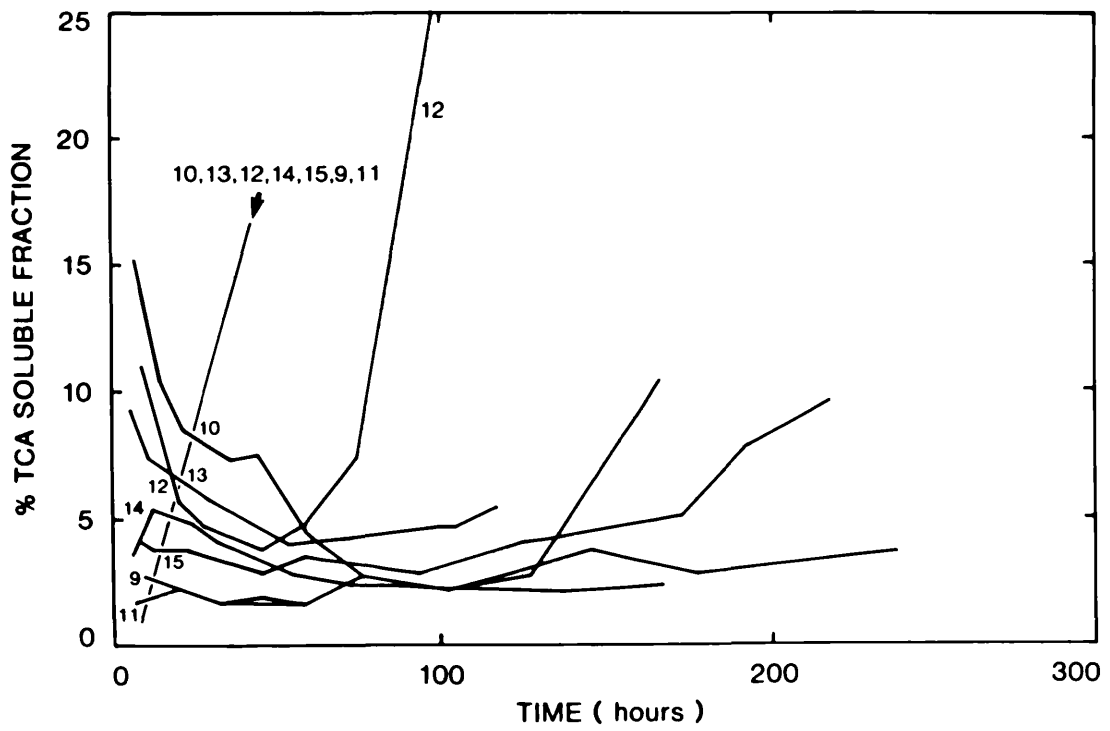
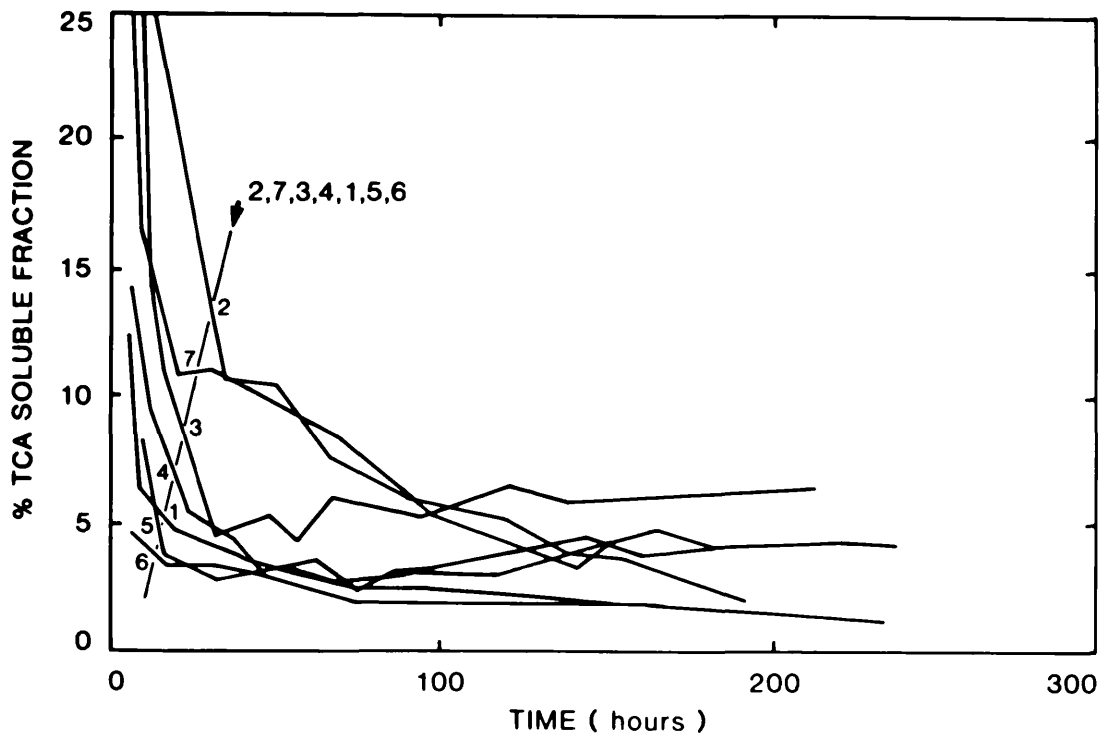


Fig. 5.19

Gel filtration chromatography of serum samples confirmed that transfer of isotope from CNS to circulating blood was predominantly as intact immunoconjugate. In cases 7-15, significant in-vivo immune complex formation was revealed in sera (Fig. 5.20).

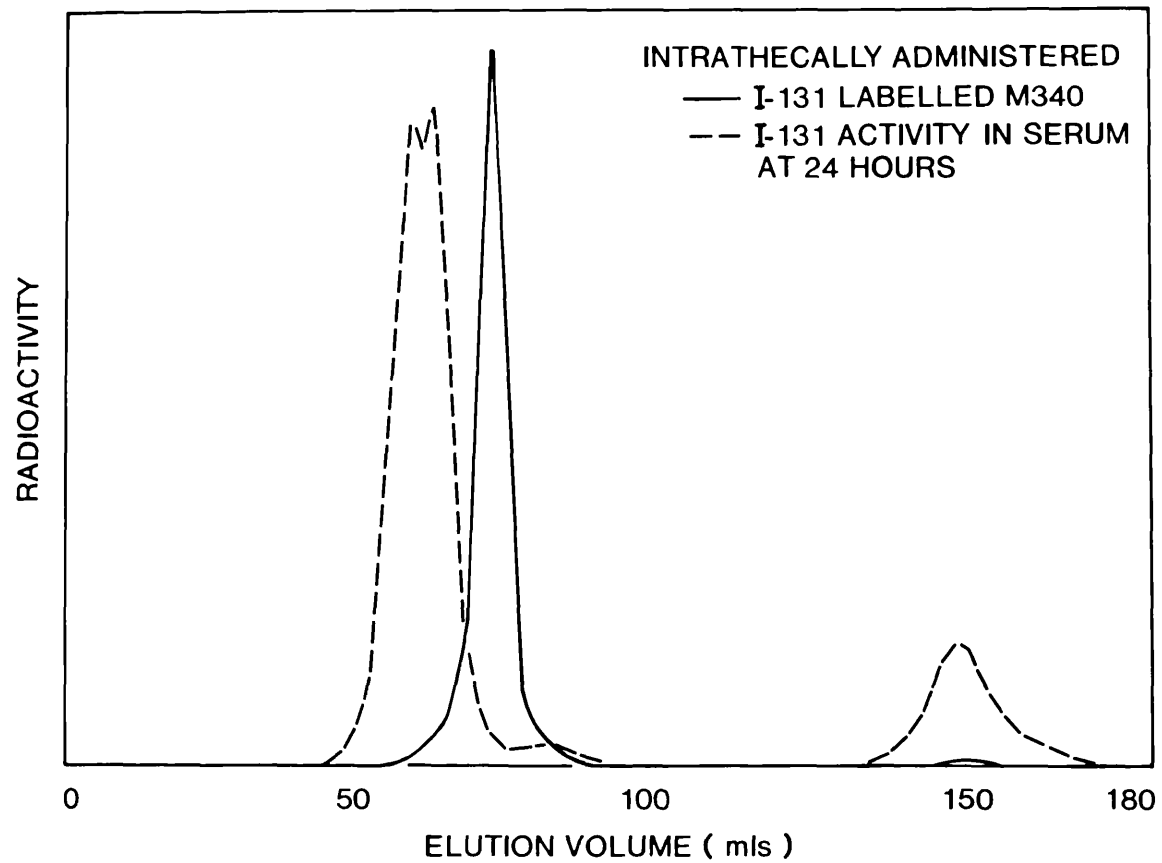


Fig. 5.20.

Elution Profile of Intrathecally Administered I-131
Labelled M340 and Serum I-131 Activity at 24 Hours (Case 7).

5.3.5 PHARMACOKINETICS: CSF

CSF sampling was performed in all patients except 9, 10 and 11, in whom the Ommaya reservoir ventriculostomy was only partially functioning. Early sampling was avoided to prevent significant loss of the injectate. The concentration of immunoconjugate fell exponentially (Fig. 5.21) and in all cases, less than 10% of the injected dose remained in the CSF at 48 hours.

Fig. 5.21

Ventricular CSF concentration/time curves for I-131 activity following intrathecal administration of monoclonal antibodies. Curves for individual patients depicted.

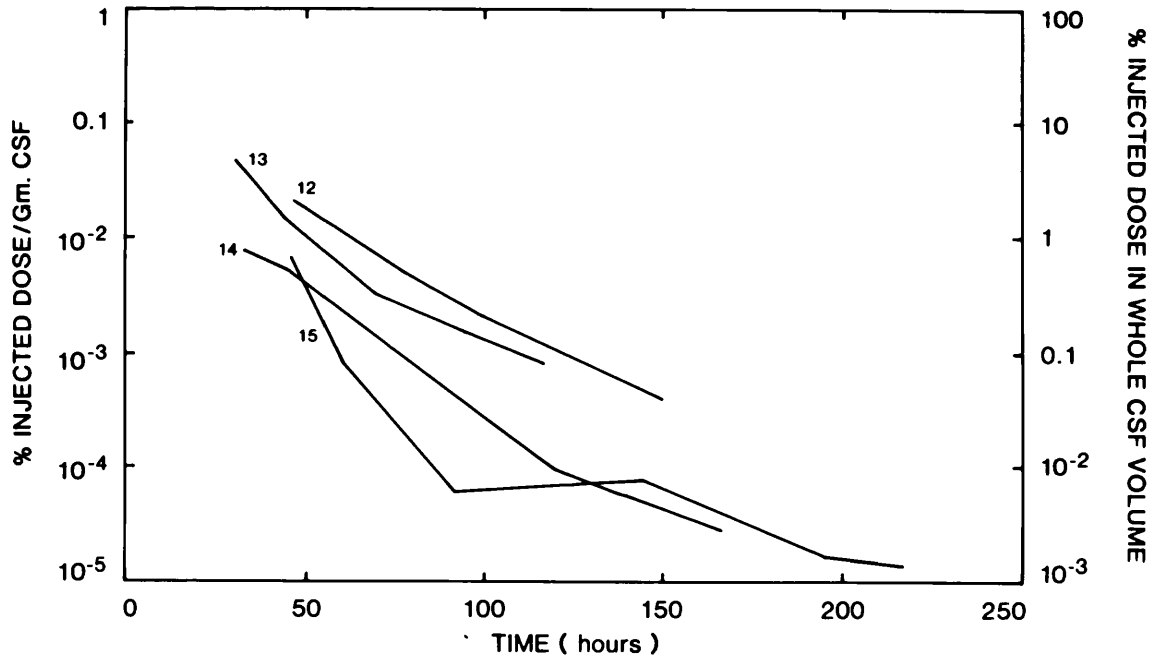
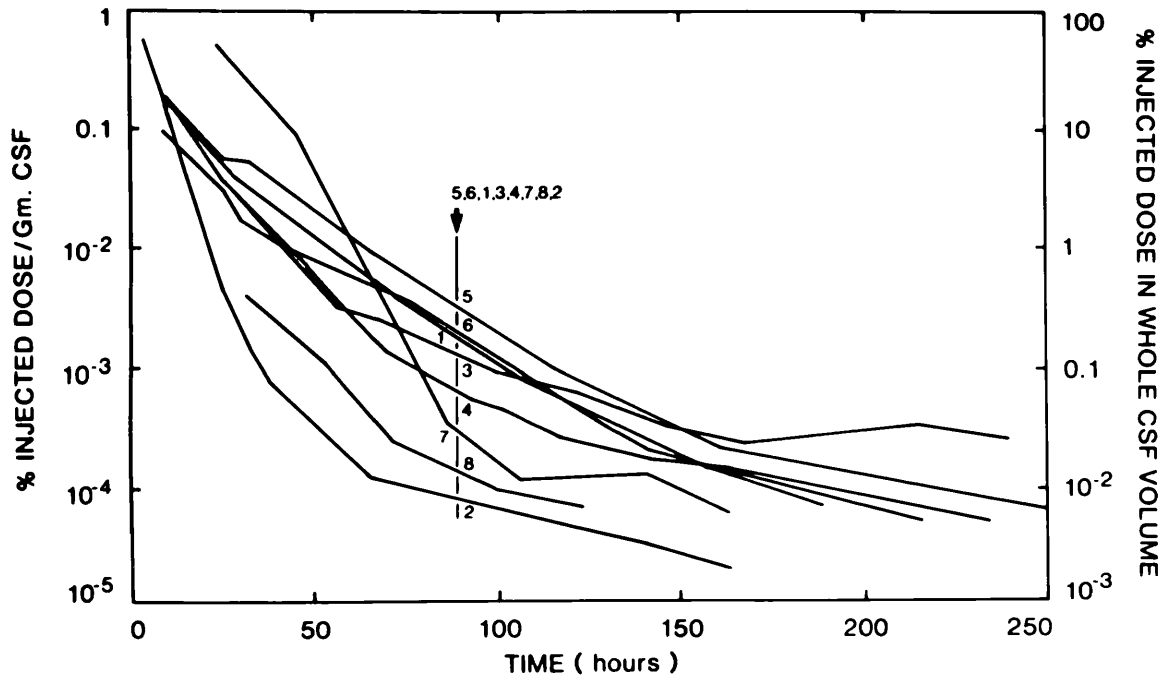


Fig. 5.21

TCA analysis of CSF samples revealed isotope predominantly protein bound, but the TCA soluble fraction increased with time (Fig. 5.22). Gel filtration chromatography of CSF samples revealed isotope predominantly as intact immunoconjugate and there was no evidence of immune complex formation.

Fig. 5.22

Percentage TCA soluble fraction of CSF radionuclide following intrathecal administration of monoclonal antibodies. Curves for individual patients depicted.

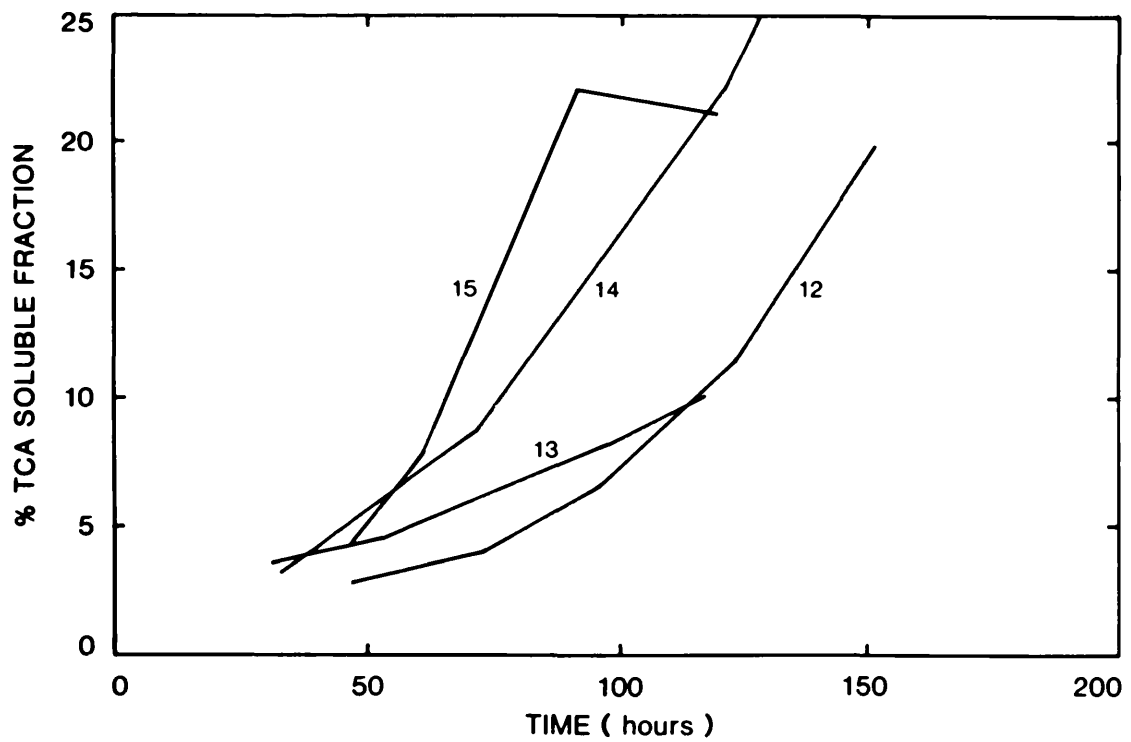
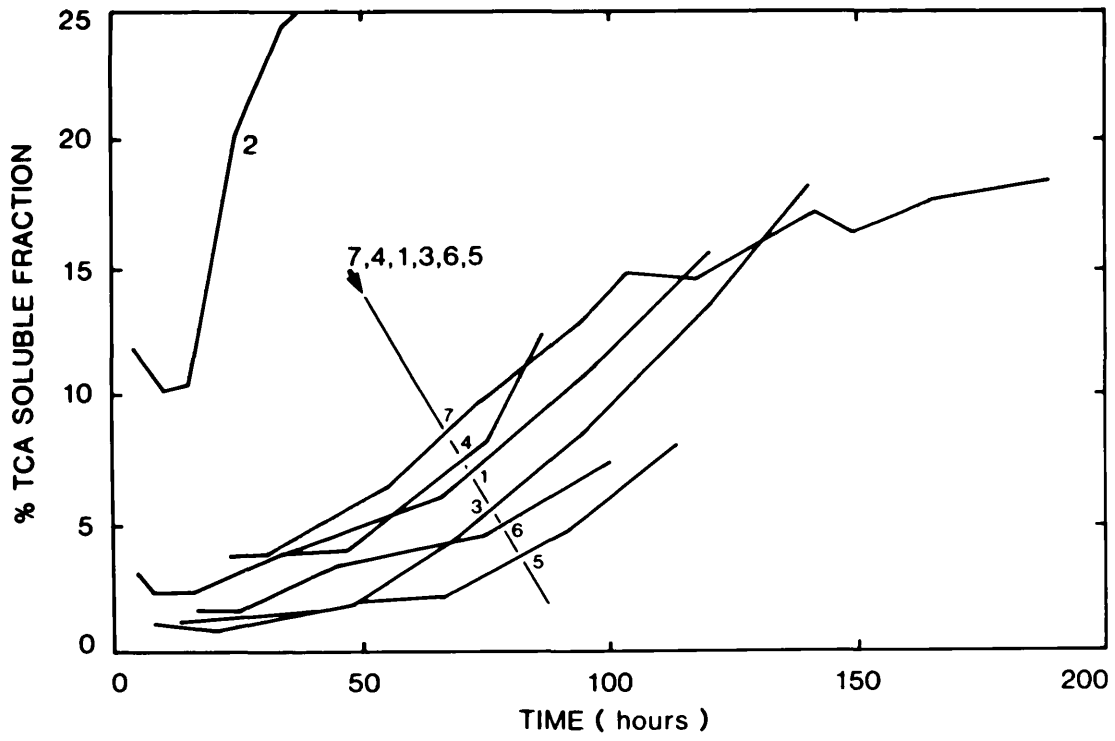


Fig. 5.22

5.3.6 IN VITRO STUDIES OF IMMUNE COMPLEX

FORMATION IN SERUM AND CSF

In case 7, all monoclonal antibody immunoconjugates were complexed in serum. Serum complexing was inhibited by pre-incubation with mouse IgG and by all unlabelled monoclonal antibodies. No demonstrable immune complex formation was seen in CSF. The antibody UJ13A was complexed in sera of 9/15 cases. With the exception of case 7, immune complex formation was not inhibited by mouse IgG, but only by unlabelled monoclonal antibody UJ13A. Complexing of UJ13A in CSF was not demonstrated. The antibody HMFG1 was complexed in serum of cases 7 and 9-15. Again, with the exception of case 7, immune complex formation was not inhibited by mouse IgG, but only by unlabelled monoclonal antibody HMFG1. Complexing of HMFG1 was also noted in CSF of cases 9-15 and was only inhibited by pre-incubation with unlabelled monoclonal antibody HMFG1. With the exception of case 7, complexing of antibodies in serum/CSF would appear to have been due to the presence of circulating free antigen. Monoclonal antibodies M340, 81C6 and 45.6 were only complexed by serum of case 7.

5.3.7 TOXICITY

The commonest form of toxicity experienced was an aseptic meningitis manifesting as headaches, nausea, vomiting, nuchal rigidity and pyrexia. This usually resolved over approximately 48 hours and its occurrence was unrelated to the dose of radioactivity administered.

The death of case 10 (H.R.) was an acute toxic complication of therapy

which occurred at approximately 72 hours after instillation of immunoconjugate. Autopsy studies revealed no obvious cause of her sudden death, but there was circumstantial evidence to suggest that this may have been due to unwitnessed epileptic seizures. Epilepsy was part of her presenting clinical syndrome and 12 hours prior to her death, she had been observed in a transient semi-comatose state lasting approximately 20 minutes. New onset epilepsy was subsequently seen in another patient (JW) at 10 days following administration of immunoconjugate.

Four patients developed bone marrow suppression (cases 5, 9, 11 and 14). In cases 5, 9 and 11, recovery of pancytopenia was spontaneous. The nadir in white cell count occurred at week 5 in patient 5 (WCC: $0.8 \times 10^9/\text{lit.}$), week 5 in patient 9 (WCC: $3.1 \times 10^9/\text{lit.}$) and week 4 in patient 11 (WCC: $2.1 \times 10^9/\text{lit.}$). A commensurate fall in platelet count was noted reaching $23 \times 10^9/\text{lit.}$, $86 \times 10^9/\text{lit.}$ and $76 \times 10^9/\text{lit.}$ respectively. A return to normal peripheral blood parameters was observed by week 9. In patient 14, the development of severe pancytopenia at four weeks (WCC: $0.8 \times 10^9/\text{lit.}$; platelets $6 \times 10^9/\text{lit.}$) was accompanied by a gram negative septicaemia requiring parenteral antibiotics and transfusion of blood products. It was noteworthy that a peripheral blood count prior to immunoconjugate administration revealed thrombocytopenia (platelets: $86 \times 10^9/\text{lit.}$) which may have reflected tumour infiltration of bone marrow. She died at 6 weeks following therapy and no autopsy was performed.

5.3.8 BONE MARROW DOSIMETRY

Cumulative I-131 blood activity for all patients was obtained by integration of radioactivity/time curves (Fig. 5.23). Estimates of radiation dosage to bone marrow are shown in Table 5.5. Bone marrow radiation dosage varied considerably amongst patients, even when administered similar quantities of I-131 radioactivity. This variation is reflected in the parameter - marrow dose per unit administered activity (cGy/mCi.), which is affected by multiple factors which are later discussed.

Fig. 5.23

Whole blood radioactivity/time curves for patients following intrathecal administration of monoclonal antibodies.

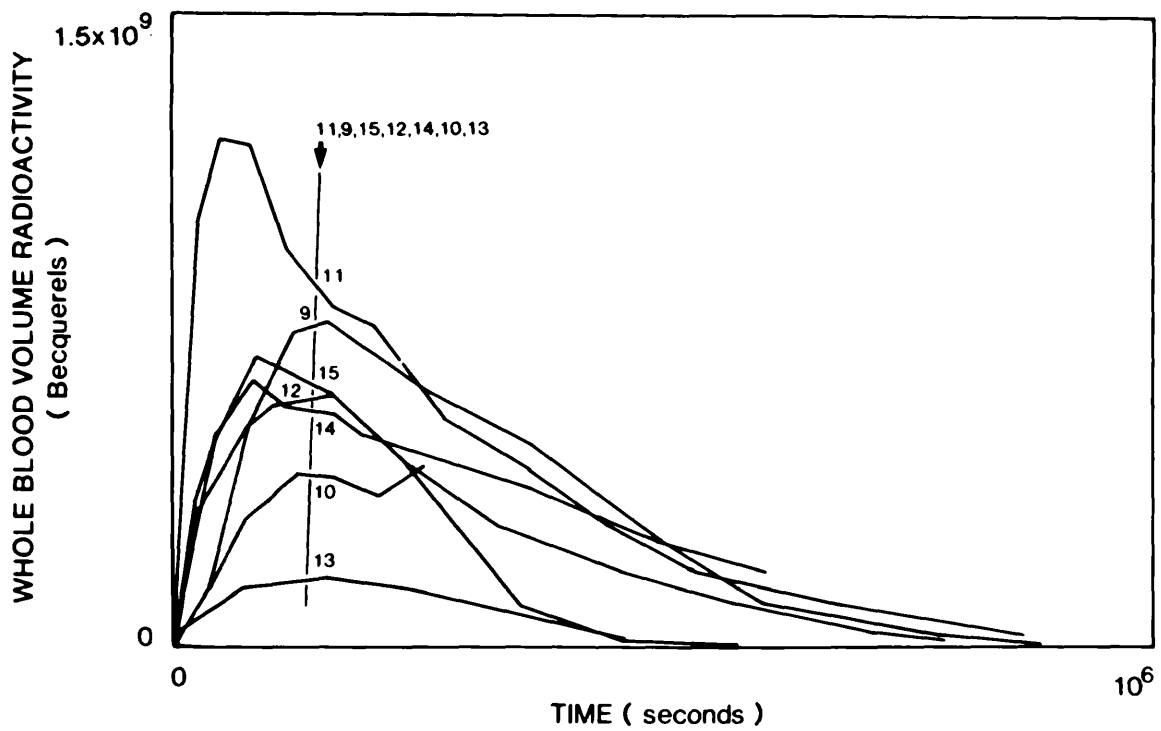
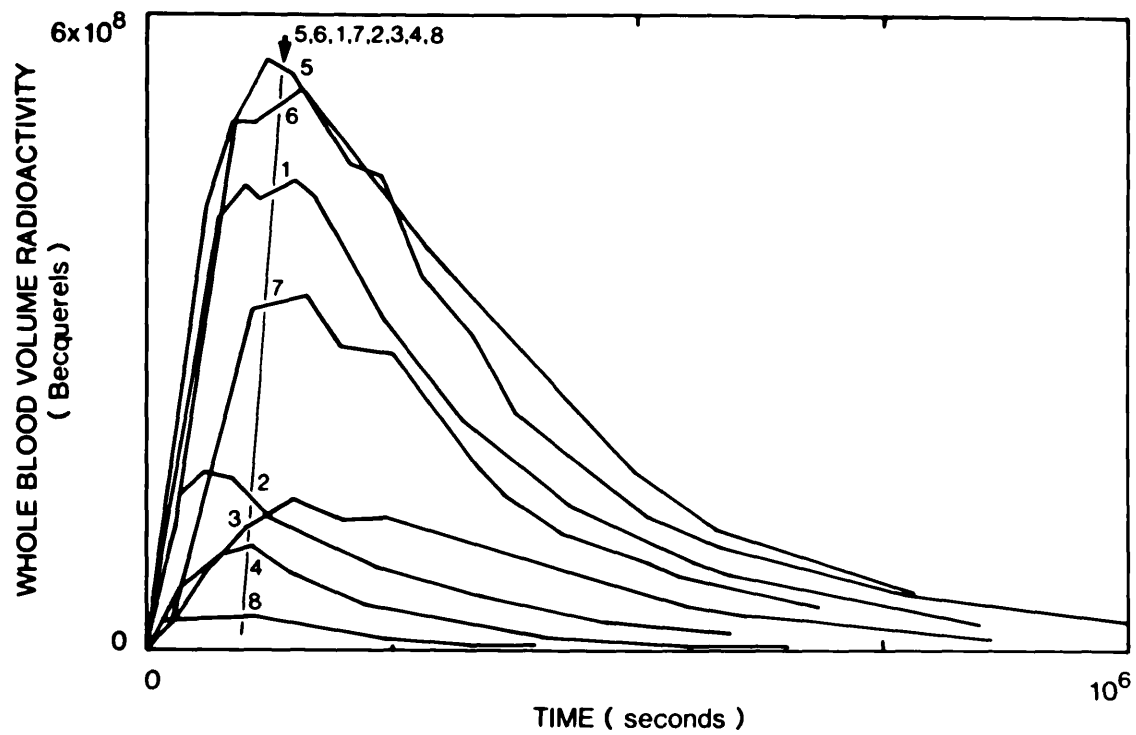


Fig. 5.23

TABLE 5.5 INTRATHECAL THERAPY: BONE MARROW DOSIMETRY

CASE NO.	NAME	WEIGHT INKGS	ADMINISTERED I-131 RADIOACTIVITY mCi	CUMULATIVE BLOOD ACTIVITY BECQ.SECONDS	ESTIMATED MARROW DOSE cGy	MARROW ADMINISTERED ACTIVITY cGy/mCi	MARROW SUPPRESSION
1	JC	60	46	1.54×10^{14}	87	1.89	-
2	LH	34	33	4.12×10^{13}	23	0.69	-
3	DH	45	60	5.58×10^{13}	31	0.51	-
4	RB	22.5	40	2.08×10^{13}	12	0.3	-
5	KH	54	60	1.89×10^{14}	106	1.76	+
6	JS	56	48	2.09×10^{14}	117	2.43	-
7	LB	38	45	1.1×10^{14}	61	1.35	-
8	RB	47	20	7.71×10^{14}	4.3	0.22	-
9	MK	95	55	2.85×10^{14}	160	2.9	+
10	HR	45	55	7.75×10^{13}	43	0.8	-
11	JW	45	58	3.54×10^{14}	198	3.4	+
12	WS	72	56	1.39×10^{14}	78	1.4	-
13	KD	63	30	4.8×10^{13}	27	0.9	-
14	UR	51	60	2.49×10^{14}	139	2.3	+
15	JJ	74	54	2.13×10^{14}	119	2.2	-

5.3.9 HUMAN ANTI-MOUSE ACTIVITY (HAMA)

No significant human anti-mouse activity (HAMA) was detected in 100 normal CSF specimens in which specific binding activities were uniformly below 500 cpm. Specific binding activities above 1000 cpm. were seen in 34% of normal population sera and were considered to represent various degrees of spontaneous HAMA (Fig 5.24). In our series of 15 patients, HAMA detected in pre-therapy sera was minimal with the exception of case 7 in whom marked activity was demonstrated (Fig. 5.25). No significant HAMA was detected in any pre-therapy CSF samples.

Fig. 5.24

Spontaneous serum anti-murine immunoglobulin activity in 100 normal blood donors.

Fig. 5.25

Spontaneous pre-existing serum human anti-murine immunoglobulin activity (HAMA) in patients administered intrathecal immunoconjugates.

SPONTANEOUS HUMAN ANTI-MOUSE ACTIVITY IN NORMAL POPULATION

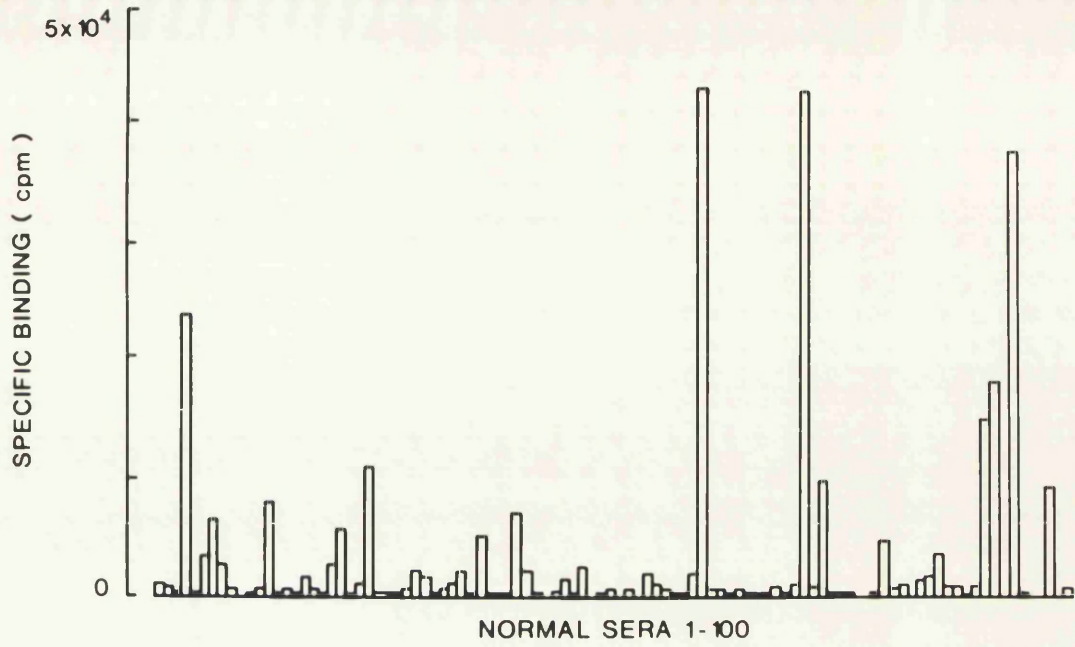


Fig. 5.24

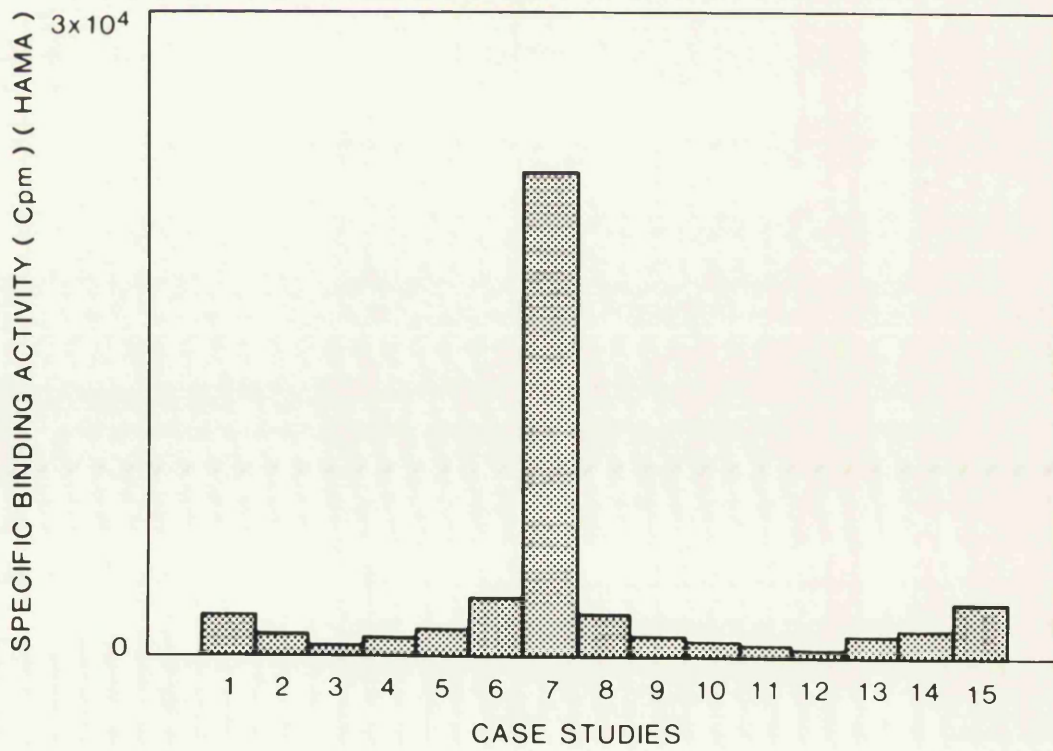


Fig. 5.25

In five cases (cases 9, 11, 12, 13 and 15), paired sera and CSF samples were obtained at six weeks following intrathecal monoclonal antibody administration. Varying degrees of HAMA were detected in all of these samples. In cases 11 and 13, CSF levels of HAMA exceeded those detected in the corresponding sera (Table 5.6). Quantitation of HAMA concentration in serum and CSF samples could not be achieved, as count activities were below the linear range of the radioimmunoassay curve.

Table 5.6

Serum and CSF HAMA Following Intrathecal Monoclonal Antibodies

Case No.	Serum	CSF
9	5030 \pm 110	3040 \pm 95
11	2452 \pm 116	3068 \pm 92
12	6984 \pm 78	5082 \pm 88
13	4982 \pm 108	7412 \pm 74
15	3352 \pm 112	2698 \pm 105

HAMA displayed as specific binding activity in counts per minute (cpm) \pm standard deviation.

5.3.10 CLINICAL RESPONSES

Pretreatment status and clinical responses in all 15 patients are shown in Tables 5.7 and 5.8. Clinical responses were assessed in terms of neurological response, CSF response and survival. Neurological response was categorised as complete (CR) if there was total resolution of symptoms and signs. Partial response (PR) implied some improvement in neurological symptoms and signs. When neurological symptoms/signs remained stable or deteriorated, this was categorised as no response (NR). CSF response was assessed on the presence or absence of malignant cells seen on cytological examination. A complete response (CR) indicated complete eradication of malignant cells from two consecutive CSF preparations. A partial response (PR) indicated a sustained reduction of malignant cell count in two consecutive CSF preparations. When malignant cell counts remained unaltered or increased, it was considered that no response (NR) to therapy had been demonstrated.

Cases 1, 2, 4, 6 and 10 were considered clinically inevaluable for response. Case 1 received conventional radiotherapy to all evaluable sites within six weeks of antibody therapy. Case 2 was administered a biologically inactive immunoconjugate. In case 4, administered immunoconjugate escaped from the CSF via a patent ventriculo-peritoneal shunt. Case 6 received conventional radiotherapy to all evaluable sites and also a biologically inactive immunoconjugate. Case 10 died suddenly at 72 hours and was categorised as an acute toxic death. The remaining ten patients were considered clinically evaluable for response. Neurological responses were seen in 3/10 patients (cases 7,

9 and 11). CSF responses were seen in 2/10 patients (5 and 11). There are two long term surviving patients in whom CSF disease remains in complete remission at 30 and 25 months (cases 5 and 11) (December 1989).

TABLE 5.7

INTRATHECAL THERAPY: PRETREATMENT STATUS

CASE NO.	NAME	PRIOR THERAPY (CNS)	DISEASE STATUS (CNS)	CLINICAL STATUS	CSF CYTOLOGY
1	JC	Surgery C/S. Radiotherapy	Recurrent Disease	Headaches Ataxia, Paraparesis	-
2	LH	Surgery C/S. Radiotherapy	Recurrent Disease	Nausea, Vomiting Gait Ataxia	+
3	DH	Surgery Cranial Radiotherapy VP. Shunt	Recurrent Disease	Headaches and Drowsiness	-
4	RB	Surgery Cranial Radiotherapy IV. Chemotherapy VP. Shunt	Recurrent Disease	Headaches and Drowsiness	+
5	KH	Surgery Cranial Radiotherapy	Recurrent Disease	Asymptomatic	+
6	JS	Surgery C/S. Radiotherapy IV. Chemotherapy	Recurrent Disease	Asymptomatic	-
7	LB	Surgery C/S. Radiotherapy	Recurrent Disease	Gait Ataxia	+
8	RB	Surgery C/S. Radiotherapy	Recurrent Disease	Nausea, Anorexia Diplopia	+
9	MK	C/S. Radiotherapy IT. Chemotherapy	Progressive disease on treatment	Diplopia Paraparesis Urinary incontinence	+
10	HR	VP. Shunt	New Disease	Dementia, Epilepsy Limb spasticity	+
11	JW	Cranial Radiotherapy IV. Chemotherapy	New Disease	Confusion Multiple cranial nerve palsies	+
12	WS	IT. Chemotherapy	Progressive disease on treatment	Paraparesis	+
13	KD	VP. Shunt	New Disease	Headache, Backache, Meningism	+
14	UR	IT. Chemotherapy	Progressive disease on treatment	Nausea, Vomiting Headache, Meningism	+
15	JJ	Cranial Radiotherapy	Progressive disease on treatment	Deafness, Paraparesis Facial weakness and numbness	+

C/S. Craniospinal
 IV. Intravenous
 IT. Intrathecal
 VP. Ventriculo-peritoneal

TABLE 5.8 INTRATHECAL THERAPY: CLINICAL RESPONSES (DECEMBER 1989)

CASE NO.	NAME	NEUROLOGICAL RESPONSE	CSF RESPONSE	SURVIVAL (MONTHS)	CURRENT DISEASE STATUS (CNS)
1	JC	CR	N/A	36	Extensive intracranial and spinal tumour recurrence 29 months after therapy.
2	LH	NR	NR	1.5 †*	—
3	DH	NR	N/A	1 †	—
4	RB	NR	NR	1.5 †	—
5	KH	N/A	CR	30	Remission
6	JS	N/A	N/A	28 *	Progressive thoracic spinal cord disease demonstrated 6 months after therapy.
7	LB	PR	NR	21	Leptomeningeal relapse demonstrated 3 months after therapy.
8	RB	NR	NR	7	Progressive disease
9	MK	PR	NR	7 †	—
10	HR	Toxic	Death	D	—
11	JW	PR	CR	25	Remission
12	WS	NR	NR	4 †	—
13	KD	NR	NR	3 †	—
14	UR	NR	NR	1.5 †	—
15	JJ	NR	NR	5 †	Progressive Disease

CR: Complete response

PR: Partial response

NR: No response

N/A: No available parameters

* Patient received biologically inactive immunoconjugate.

† Patient dead

D Patient died at 72 hours following injection.

5.4 DISCUSSION

5.4.1 SELECTION OF MONOCLONAL REAGENTS

Monoclonal antibodies selected for radiation targeting have been extensively screened against a wide variety of tissues using immunohistochemical techniques. With the exception of monoclonal antibody UJ13A, no binding has been demonstrated to normal central nervous system. However, using sensitive radioimmunoassay techniques, all of the monoclonal antibodies (UJ181.4, M340, UJ13A, ME1-14, 81C6) with the exception of HMFG1 have demonstrated specific binding of variable degree to normal central nervous system tissues (R.P. Moseley; unpublished observation). The significance of tissue binding below the sensitivity threshold of immunohistochemical analysis is unknown. It is also relevant to appreciate that in-vitro binding studies do not necessarily reflect the operational specificity of the antibody in-vivo.

5.4.2 BIOLOGICAL ACTIVITY OF IMMUNOCONJUGATE

The specific immunoreactive fraction of radiolabelled antibody preparations varied from 2% - 78%. Preparations 2 and 6 were considered biologically inactive, as differential binding of the specific I-131 immunoconjugate did not achieve statistical significance. Radioiodinations for cases 1, 2, 5 and 6 were performed using a modified chloramine-T technique. All remaining iodinations were with an iodogen method. Radioimmunoconjugates prepared with iodogen were of greater biological activity than those prepared with chloramine-T. This probably reflects differences in the oxidation

methods, but may be accounted for by difficulties in labelling monoclonal antibody UJ181.4. We have been unable to iodinate this antibody successfully with either oxidation method. The failure of oxidation radioiodination methods to produce UJ181.4 immunoconjugates of high immunoreactivity was consistent. This may have resulted from iodine substitution within the antibody binding site, but may also be due to contamination of UJ181.4 preparations with non-specific mouse immunoglobulin.

5.4.3 PLASMA PHARMACOKINETICS

Blood concentration of immunoconjugate as a function of time was characteristically biphasic with ascending and descending components. Characteristics of these curves bore resemblance to plasma pharmacokinetics of drugs administered orally or intramuscularly. The latter functions are usually defined mathematically by a one compartment model with first order input and output kinetics (Gibaldi and Perrier, 1975; Curry, 1980).

The equation defining this system is denoted below.

$$X_t = X_0 (e^{-qt} - e^{-pt})$$

where X_t = blood concentration at time t

p = absorption rate constant

q = elimination rate constant

X_0 is a constant term defined by $D/V_D \cdot (p/p-q)$

where D = total drug dose absorbed

V_D = apparent volume of drug distribution

Computer simulation of plasma drug concentration/time profiles following variation of individual parameters, generates a series of curves with characteristic features (Fig. 5.26). The maximum drug concentration is related to total drug dosage absorbed, apparent volume of drug distribution and both absorption and elimination rate constants. The time of maximum drug concentration (T_{MAX}) is independent of drug dose and apparent volume of distribution, but related to absorption and elimination rate constants only. T_{MAX} is delayed by reduction of either absorption and/or elimination rate constants. The area under the curve is defined by the expression $A = D/V_D \cdot q$ and is thus independent of the absorption rate constant. Although our blood concentration/time curves for immunoconjugate resembled simulated curves from the above model, we were unable to fit observed data within this system.

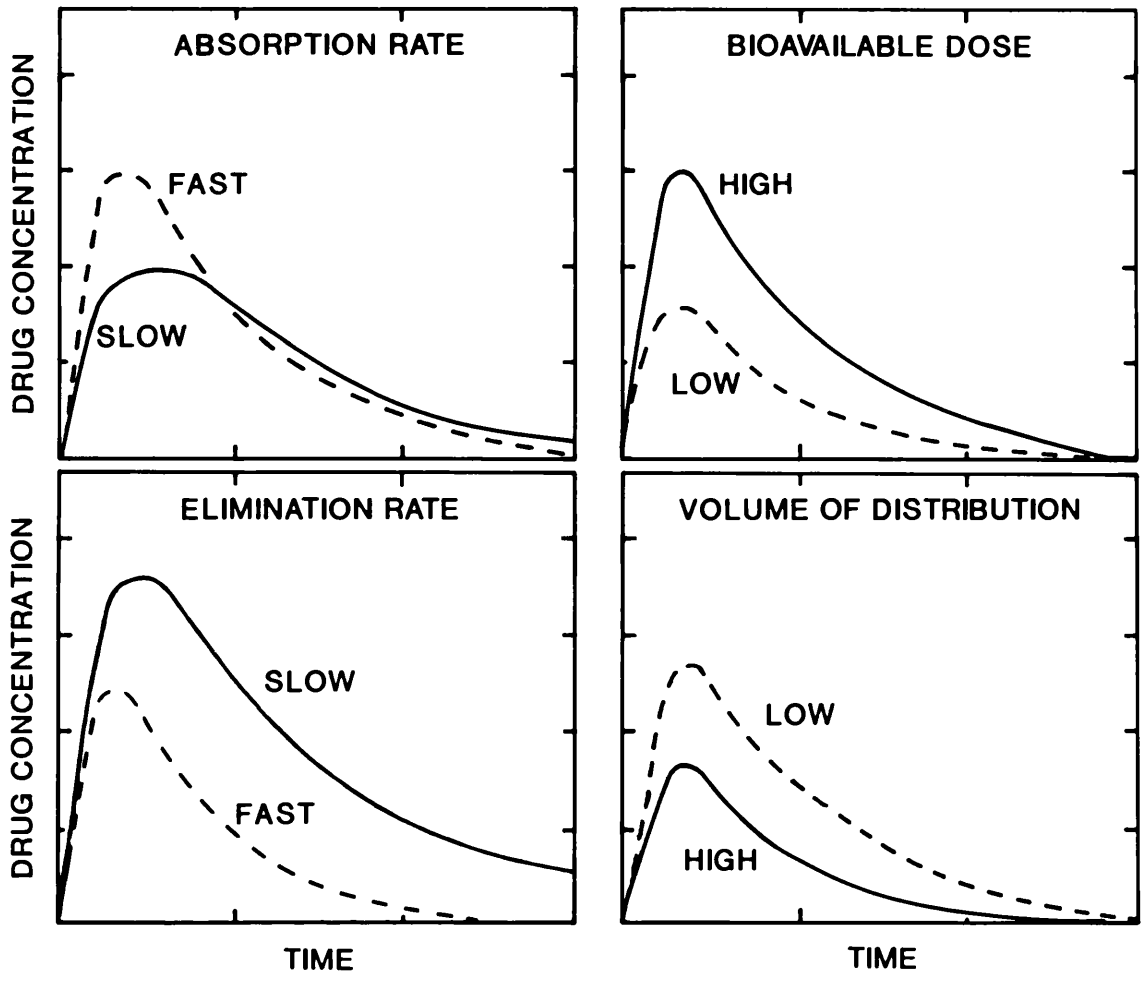


FIG. 5.26
COMPUTER SIMULATION OF PLASMA CONCENTRATION/TIME CURVES
FOLLOWING INTRATHECAL DRUG INSTILLATION. MODEL ASSUMES
SYSTEMIC COMPARTMENT AS SINGLE. FIRST ORDER KINETICS OF
ABSORPTION AND ELIMINATION ARE ALSO ASSUMED.

Deviation of observed data from the model system probably arose for several reasons. Firstly, antibody binding within the central nervous system is complex, and our assumption of first order kinetics of isotope transfer from CSF to blood may have been simplistic. Secondly, many of the antibodies studied exhibit significant binding to systemic antigen (eg. liver/spleen), and their kinetics of blood clearance are more accurately described by more complex polycompartmental models. Thirdly, our radiolabelling technique may have produced a heterogeneous pharmaceutical preparation. Direct oxidation methods of radiolabelling incorporate iodine covalently into tyrosine amino acid residues by hydrogen substitution. Immunoglobulin G species contain over 50 tyrosine sites, and although some of these exhibit preferential reaction tendency, iodination is unlikely to be site specific (Matzku et al., 1987). A spectrum of iodinated immunoglobulin molecules may thus emerge with tyrosine substitution occurring at variable distances from the antigen recognition site. Radioiodinated monoclonal antibody preparations are therefore likely to contain species of varying immunoreactivity and in consequence are not pharmacologically homogeneous. Finally, kinetic data relating to iodinated species must always be interpreted with caution. Apart from contaminating free iodide in preparations, enzymic dehalogenation also occurs in body tissues (Zimmer et al., 1985). Free iodine may therefore simulate antibody distribution.

Despite our failure to fit observed data to model systems, we were able to elucidate the major factors contributing to the shape of blood concentration/time curves, and the areas beneath them. Blood concentration/time curves varied widely amongst different patients,

even following administration of the same antibody (cases 9-15). This is not surprising given the parameters that affect the curves and the probability of their variation amongst individuals.

5.4.4 CSF PHARMACOKINETICS

All sampling was performed via an Ommaya reservoir ventriculostomy and so concentrations of immunoconjugate were assessed in ventricular CSF. This may not have reflected immunoconjugate concentration in lumbar CSF (Murrey et al., 1983). Clearance of immunoconjugate from CSF exhibited polyexponential kinetics. This complexity of clearance almost certainly reflects involvement of multiple elimination processes which include binding to tumour/neural parenchyma, permeation into neural parenchyma and normal CSF transport mechanisms.

5.4.5 STUDIES OF IODINATED MOLECULAR SPECIES

Gel filtration studies of serum and CSF revealed the major transfer of isotope from CSF to blood as intact immunoconjugate. The inevitable small quantities of contaminating free iodide within preparations were transported more rapidly, as evidenced by the high fraction of TCA soluble isotope in early serum samples. Sequential TCA analysis of sera revealed a subsequent reduction of low molecular weight activity with time, which was later followed by a substantial increase in some patients. Significant metabolism of iodinated molecular species occurs by enzymic dehalogenation (Zimmer et al., 1985). Variation of enzymic activity amongst individuals might account for differences observed in sequential studies of serum TCA isotope solubility.

In-vivo serum immune complex formation was observed in patients 7-15. In case 7 (LB) this was attributed to spontaneous serum human anti-mouse activity (HAMA). In cases 8-15, in-vitro studies revealed immune complexes formed by the association of immunoconjugate with free circulating serum antigen. The formation of serum immune complexes was not consistently followed by increased scintigraphic activity in liver and spleen. Although in-vitro studies revealed HMFG1 antibody-antigen complex formation in CSF, this was not observed in-vivo. The absence of demonstrable CSF complexing in-vivo was almost certainly due to obscuration of small quantities of antigen by the large protein dose in the injectate.

5.4.6 IMMUNOSCINTIGRAPHY

In all patients studied, sites of neuraxial isotope accumulation corresponded to areas of disease demonstrated clinically or radiologically. Although this observation may imply specific immunological binding, a similar distribution of isotope may result from non-specific protein accumulation at tumour sites. Non-specific isotope accumulation at tumour sites was seen in two patients administered biologically inactive immunoconjugate (cases 2 and 6).

Scintigraphy in 11/13 patients revealed increased accumulation of isotope in the lumbar/sacral region. In four patients (cases 2, 3, 4 and 5), no tumour was demonstrated myelographically, and autopsy studies of case 3 revealed no disease involvement of the cauda equina. Increased scintigraphic activity in the lumbar/sacral area may arise from leakage of isotope into epidural tissues following recent lumbar

puncture (Larson et al., 1971; Rogoff, 1974; Welch et al., 1975). However, in case 3 (DH), lumbar puncture had not been performed in the month prior to therapy. Non-specific accumulation of isotope in the lumbar/sacral region was therefore clearly demonstrated in this patient. Possible explanations for the predilection of isotope accumulation in this area relate to the anatomy of the cauda equina and spinal subarachnoid space. The cauda equina presents a large surface area of leptomeningeal tissue, and any degree of non-specific binding is likely to be increased at this site. However, the major contributing factor may relate to the existence of spinal CSF drainage pathways. The existence of spinal arachnoid granulations for drainage of CSF was first postulated by Elman (Elman, 1923), and subsequently confirmed by other investigators (Woollam and Millen, 1958; Kido et al., 1976). In animal studies, colloidal particles have been demonstrated in spinal arachnoid villi, peridural tissues and paravertebral lymph nodes following injection into CSF (Brierley and Field, 1948; Brierley, 1950; Woollam and Millen, 1958). It is conceivable that injected radioimmunoconjugate may escape from the lateral recesses of the lumbar/sacral subarachnoid space via these drainage mechanisms, so gaining access to peridural tissues and paravertebral lymphatic drainage systems. Persistence of isotope in these sites would create increased scintigraphic activity. Some evidence to support this hypothesis is provided by more detailed observation of scintigraphic data. In several patients, isotopic activity appears to extend beyond the lateral limits of the dural sac. This lateral spread of activity appears more prominent in the lumbar/sacral areas where lobulated irregular extensions are also occasionally seen (Fig. 5.27).

Fig. 5.27

Immunoscintigraphy of patient DH (Case 3) at 14 days following intrathecal administration of monoclonal antibody 81C6. Apart from liver and splenic uptake, diffuse lateral extension of isotope beyond the limits of the spinal canal is demonstrated in the region of the cauda equina. Subsequent autopsy studies revealed no intraspinal tumour and no anatomical abnormalities.

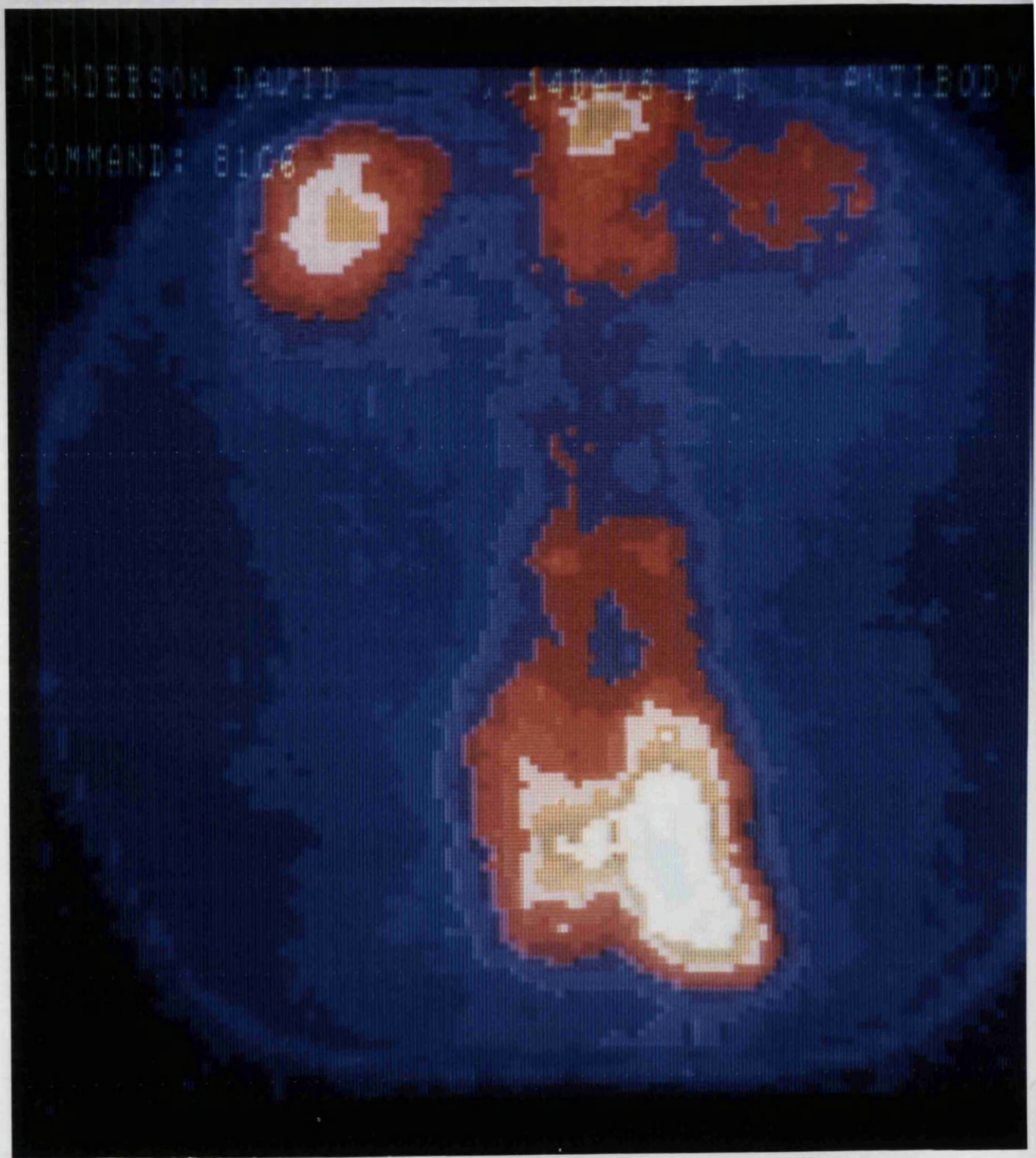


Fig. 5.27

Incomplete distribution of cranial isotope was observed in 14/15 patients. Asymmetry and/or paucity of scintigraphic activity was commonly seen over the hemisphere convexities, but distribution was complete in the spinal subarachnoid space of all patients. These observations concur with those of Grossman and colleagues who observed a 70% incidence of CSF flow abnormalities demonstrated by isotope ventriculography in patients with neoplastic meningitis (Grossman et al., 1982). The presence of CSF flow irregularities may significantly disadvantage therapeutic methods reliant on instillation of pharmaceutical agents into CSF.

5.4.7 BONE MARROW DOSIMETRY

Excluding case 10 (HR), the mean estimated radiation dose to bone marrow per unit administered activity in this whole group was 1.58 cGy/mCi. Bone marrow suppression was seen in 4 patients (cases 5, 9, 11 and 14). The estimated bone marrow radiation dosage in these patients was 106, 160, 198 and 139 cGy. respectively. Patient 5 (KH) was administered monoclonal antibody ME1-14 which exhibits specific binding to bone marrow (Behnke et al., 1988). Her radiation dose estimate of 106 cGy. is therefore likely to be a significant underestimation. The other three patients all received monoclonal antibody HMFG1 which does not exhibit binding to bone marrow.

Data from our patients receiving HMFG1 (cases 9-15, excluding 10) can be usefully compared with similar data obtained from patients administered intraperitoneal I-131 labelled HMFG1 for ovarian carcinoma (Stewart et al., 1989). For purposes of comparison, raw cumulative

blood activity data from the study of Stewart et al. was used to estimate bone marrow radiation dose by the method described in section 5.2.8. In HAMA negative patients (n=9), their corrected mean estimated bone marrow radiation dose per unit administered activity was 1.66 cGy/mCi. In our study of seven patients administered intrathecal HMFG1, case 10 was excluded from dosimetry studies as this patient died at 72 hours and meaningful data was therefore unobtainable. The mean estimated bone marrow radiation dose per unit administered activity was 2.8 cGy/mCi. The mean estimate of bone marrow dose per unit administered activity did not differ significantly between these two groups of patients. ($t=1.42$; $0.1 < p < 0.5$). Stewart et al. have observed bone marrow suppression at radiation doses in excess of approximately 115 cGy. This is consistent with our data, although two of our patients failed to show haematological toxicity following estimated bone marrow doses of 117 and 119 cGy.

The marrow dose per unit administered activity (cGy/mCi.) is, in effect, a measure of sensitivity of an individual patient to the bone marrow toxicity associated with administered immunoconjugate. In both our study and that of Stewart et al., there was a significant range of variation in this parameter amongst individuals. This presumably accounts for an apparent disparity between the two studies. Whereas bone marrow toxicity was not observed by Stewart et al. when activities of less than 100 mCi. were administered, toxicity in our study was observed following administered activities of 55, 58 and 60 mCi. (cases 9, 11 and 14). However, in concordance with Stewart et al., estimated bone marrow radiation doses in these three patients exceeded toxicity limits associated with haematological suppression. In our three

patients (9, 11 and 14), estimated marrow dose per unit administered activity was comparatively high (2.9, 3.4 and 2.3 respectively), and these individuals were therefore sensitive to the haematological toxicity associated with therapy. In contrast, marrow dose per unit administered activity was only 0.9 cGy/mCi. in case 13 (KD). This patient could theoretically have safely received in excess of 100 mCi. of I-131.

Bone marrow radiation dose is related to the administered activity and the pharmacokinetics of immunoconjugate in the circulating blood volume. Bone marrow dose per unit administered activity is directly proportional to the area under the blood concentration/time curve. If, as in our study, administered antibody doses are normalised to a value of 100%, then this area is dependent upon the apparent volume of distribution of immunoconjugate and its elimination rate constant. Monoclonal antibodies 81C6 and UJ13A exhibit a high apparent volume of distribution in consequence of their extensive liver binding. Areas beneath blood concentration/time curves for these antibodies are therefore small and this is reflected by low estimates of marrow dose per unit administered activity. Extensive binding of immunoconjugates to liver/spleen therefore protects bone marrow from radiation toxicity. Rapid elimination of immunoconjugate is also effective in reducing the area under blood concentration/time curves. This may occur as a variation of normal metabolism, but characteristically is often seen in HAMA positive patients (Stewart et al., 1989). However, in our single patient with positive HAMA (LB), marrow dose per unit administered activity was not significantly different from the remaining HAMA negative patients.

No statistical difference was observed between mean values of bone marrow dose per unit administered activity in patients administered intrathecal or intraperitoneal HMFG1 immunoconjugate. However, studies with larger numbers of patients may eventually reveal a significant difference in this parameter. Observation of present data would suggest that bone marrow toxicity might be greater following intrathecal administration. If this were to be the case, then differences in kinetics of immunoconjugate transfer from body cavity to blood circulation would probably account for this. Although the area under blood concentration/time curves is independent of the rate of immunoconjugate transfer from cavity to blood, it could be significantly affected by differences in bioavailability of administered immunoconjugate. If, for example, HMFG1 was administered into the peritoneal cavity of a patient with extensive peritoneal disease, a significant fraction of the injected dose might be bound by tumour and hence not bioavailable for transfer into blood. The volume of intraperitoneal neoplasm is likely to be much greater than that potentially occurring within the subarachnoid space and hence we would expect a greater fraction of intrathecally administered immunoconjugate to be bioavailable for transfer into blood. Blood pool immunoconjugate may therefore be greater following intrathecal administration and this would be associated with increased bone marrow toxicity.

5.4.8 TOXICITY

Acute toxicity in the form of an aseptic meningitis occurred in approximately 50% of patients and was unrelated to administered radiation dose. Similar toxicity has been reported following

intrathecal administration of Methotrexate (Duttera et al., 1973), Cytosine Arabinoside (Wang and Pratt, 1970) and radioiodinated human serum albumin (RISA) (Messert and Rieder, 1972). The reported incidence of aseptic meningitis following intrathecal RISA has been highly variable and this complication has been attributed to contaminating endotoxins (pyrogens) (Cooper and Harbert, 1975). Aseptic meningitis in our patients was unrelated to administered radioactivity dose, and observed intermittently. It is likely that the presence of contaminating pyrogens accounted for this complication, although radiopharmaceuticals were not tested for their presence. Epilepsy occurred in two patients. We have considered this a toxic response to therapy, but of course seizures occur as a natural event in the disorder (Wasserstrom et al., 1982). Delayed central nervous system toxicity has not been observed clinically in long term survivors, but an autopsy study on case 10 (HR) revealed extensive periventricular and brain stem subpial white matter oedema and astrocytic reaction (Benjamin et al., 1989). Autopsy studies on long term survivors have revealed deep white matter gliosis and periventricular scarring (Dr T. Moss, personal communication). The significance of these findings is as yet unknown.

Bone marrow suppression was seen in four patients, and appears to be the dose limiting toxicity of this form of therapy. Our data from patients administered HMFG1 would suggest risks of haematological toxicity increased above bone marrow doses of 120 cGy. Bone marrow radiation dose appears directly related to the plasma pharmacokinetics of immunoconjugate. In adults, it is conceivable that administered radioactivity doses as low as 40 mCi. might lead to haematological

toxicity, as pharmacokinetic parameters vary unpredictably amongst individuals. However, previous intrathecal studies using tracer quantities of radioimmunoconjugate have suggested that the pharmacokinetics of antibody biodistribution are independent of protein dose in the range 0.5-10 mg. (R.P. Moseley, unpublished observation). An initial tracer study with low dose immunoconjugate could therefore conceivably be performed to obtain pharmacokinetic data prior to therapy. In this way, a maximum dose of radioactivity could be estimated to avoid haematological toxicity.

5.4.9 HUMAN ANTI-MOUSE RESPONSE TO THERAPY

Human anti-mouse activity (HAMA) in serum is a well recognised phenomenon and may occur spontaneously (Courtenay-Luck et al., 1987) or following the administration of murine monoclonal antibodies (Schroff et al., 1985; Sears et al., 1985; Courtenay-Luck et al., 1986). HAMA has not previously been investigated in cerebrospinal fluid (CSF). Significant spontaneous anti-mouse activity was only seen in one patient (case 7), and this was present only in serum. In all five patients studied after therapy (cases 9, 11, 12, 13 and 15) some degree of HAMA response was observed in serum and CSF. In two patients, HAMA was significantly greater in CSF than in serum (cases 11 and 13), providing presumptive evidence of immunoglobulin synthesis within the central nervous system (CNS). Local IgG production in the CNS occurs in several chronic inflammatory disorders and has also been reported in carcinomatous meningitis (Schipper et al., 1988). The latter group of investigators attributed intrathecal immunoglobulin synthesis to lymphoid infiltrates within meningeal tumour. In the remaining three

patients (cases 9, 12 and 15), serum levels of HAMA were higher than those in CSF. In these circumstances, intrathecal HAMA may have arisen from leakage of immunoglobulin from serum to CSF. This may be facilitated by disruption of the blood/brain barrier, which is known to occur in neoplastic meningitis (Wasserstrom et al., 1982; Siegal et al., 1987).

The direct immunoassay technique employed in this study could not detect anti-idiotypic components of the HAMA response. However, HAMA responses following a single injection of monoclonal antibody HMFG1, have been predominantly against antigenic determinants on the constant regions of mouse immunoglobulin (Courtenay-Luck et al., 1986). Significant anti-idiotypic responses have only followed multiple administrations of HMFG1 (Courtenay-Luck et al., 1988). The molecular nature of the immune response has not been determined in this study. However, other investigators have reported serum HAMA responses consisting of both IgM and IgG (Shawler et al., 1985).

The central nervous system appears not to be an immunological sanctuary for intrathecally administered murine immunoconjugates. The development of HAMA response within the CNS might be of significance if repeated antibody instillations are planned. Murine immunoconjugates administered intrathecally in these circumstances might be inactivated with consequent reduction of therapeutic efficacy. The concurrent serum HAMA response in these circumstances may however be advantageous by facilitating rapid clearance of immunoconjugate and consequent reduction in systemic toxicity (Stewart et al., 1989).

5.4.10 CLINICAL RESPONSES

By our defined criteria, clinical responses were seen in 3/10 (30%) evaluable patients (cases 7, 9 and 11). CSF responses were seen in 2/10 (20%) evaluable patients (cases 5 and 11). Long term survivors remain in complete remission at 30 and 25 months (cases 5 and 11) (December, 1989). Before dismissing these clinical results as unimpressive, one should consider the devastating nature of this disease. Many of these patients had advanced disease, unresponsive to previous therapy. The important observation here is that therapeutic responses have been demonstrated.

As with other forms of oncolytic therapy, clinical results are more favourable with minimal disease. With the relative insensitivity of current diagnostic methods, opportunities to treat minimal disease are infrequent. As disease progresses, partial obliteration of the subarachnoid space may prevent complete distribution of immunoconjugate throughout the CSF pathways, and this clearly reduces the opportunity for therapeutic success. Future studies should therefore investigate this technique for central nervous system prophylaxis in leukaemia and medulloblastoma. If successful, the central nervous system sparing theoretically afforded may avoid the delayed neurotoxicity seen with conventional methods. In patients with overt disease, useful palliation can still be achieved. However, emphasis should be placed on establishing complete patency of the craniospinal subarachnoid space prior to therapy. The addition of Indium-111-DTPA ventriculography may compliment CT/myelography in this assessment (Grossman et al., 1982). In the presence of partial subarachnoid block, patients might be

offered preliminary external beam cranial irradiation.

CHAPTER 6

CURRENT PROBLEMS AND FUTURE STRATEGIES

The development by Kohler and Milstein (1975) of the mouse hybridoma procedure for monoclonal antibody production opened a new era in immunology (Kohler and Milstein, 1975). The clonal selection and immortality of hybridoma cell lines assure the monoclonality, monospecificity and permanent availability of their antibody products, thus liberating immunologists from the constraints and difficulties previously associated with the preparation and use of heteroantisera. These reagents have had a major impact on immunocytochemical and immunoassay procedures, but their role as therapeutic agents is yet to be established.

The idea of using polyclonal antibodies for the detection and treatment of cancer was first proposed by Pressman in 1953 (Pressman and Korngold, 1953; Pressman et al., 1957). However, the concept was refined following the development of monoclonal antibodies recognising human tumour associated antigens. In animal xenograft model systems, monoclonal antibody immunoconjugates have been shown to specifically localise to tumours and produce therapeutic effect (Bourdon et al., 1984; Jones et al., 1985; Lee et al., 1988a,b). However, in patients with cancer, the results have been disappointing. In most clinical trials, the absolute amount of immunoconjugate localising within tumour tissue is less than 10^{-3} of the injected dose per gram of tumour.

Dilutional effects, physiological barriers and sequestration of immunoconjugate within abdominal viscera have all contributed to these unimpressive results (Sands, 1988).

The limitations of intravenously administered monoclonal antibodies have led investigators to administer these reagents directly into body cavities (Epenetos et al., 1984, 1987; Pectasides et al., 1986). This strategy is theoretically advantaged by limiting dilution of antibody, increasing its time in contact with tumour, and reducing extratumorial factors which might limit delivery to tumour binding sites. In practice however, intracavitary administration may not necessarily increase antibody uptake into tumour. This has been investigated in peritoneal carcinomatosis by dual labelling studies with simultaneous injection of immunoconjugate by intravenous and intraperitoneal routes. Small peritoneal implants and free floating cells appear to be targeted more effectively by intraperitoneal administration, but intravenous administration gives more favourable uptake in larger tumour masses (Colcher et al., 1987; Ward et al., 1987b).

After intracavitary administration, the tumour is bathed in antibody. Large immunoglobulin molecules must then diffuse through layers of tumour cells. The mechanisms of absorption of large molecular weight proteins into tumours are largely unknown. One study designed to yield some information on these mechanisms was reported by Sutherland and colleagues (Sutherland et al., 1987). Spheroids of human colon cells 100 to 150 μm . in diameter were incubated with radioiodinated anti-CEA and its fragments. Four hours after addition of the antibody, the spheroids were washed and the penetration and binding of the radiolabelled antibody determined by autoradiography. Whole IgG remained associated with the outer layer of cells while the F(ab')_2 and Fab fragments penetrated further into the spheroid. Maximum penetration of the Fab fragment was approximately 10 cell

layers. These observations reveal a potential advantage of the use of fragments, but also demonstrate that penetration of immunoconjugates into tumour may still remain a problem, even with intracavitary administration.

Monoclonal antibodies conjugated with radionuclides, drugs or toxins have demonstrated cytotoxic effect in vitro and in animal tumour models (Jones et al., 1985; Lee et al., 1988a,b; Embleton et al., 1983; Zovickian and Youle, 1988). The choice of therapeutic agent involves several considerations. Drug and toxin immunoconjugates only kill specifically targeted cells. In contrast, radioimmunoconjugates may produce sufficient radiation crossfire to kill cells in close proximity that are not targeted by antibody. This may be useful when antibody penetration into tumour is incomplete and may also be advantageous with tumour antigen heterogeneity (Albino et al., 1981; Wikstrand et al., 1985). Plant toxins are highly toxic substances which can kill cells following entry of only a few molecules (Yamaizumi et al., 1978; Eiklid et al., 1980). Toxin immunconjugates should therefore ideally be highly specific for tumour specific antigens, as the consequences of delivery to inappropriate sites could be disastrous. However, with the exception of HTLV-induced leukaemias (Hinuma et al., 1981; Yoshida et al., 1982; Schuepbach et al., 1983), tumour specific antigens have not been identified in man. To date, monoclonal antibodies administered to cancer patients have defined tumour associated antigens, which are expressed to a lesser degree by other tissues. Further loss of specificity follows from the theoretical concept that a monoclonal antibody defining a specific epitope, is likely to bind other epitopes expressing similar molecular conformational geometry (Lane and

Koprowski, 1982). Given this lack of absolute specificity, drug or radionuclide immunoconjugates may be safer and associated with less toxicity. Most clinical studies have employed radionuclide conjugates.

Iodine-131 has remained a popular choice of radionuclide for clinical studies of radioimmunotherapy. Halogen labelling of proteins is well established, and apart from its effective beta-emission, I-131 also produces a 364 Kev. gamma photon which allows scintigraphic imaging of biodistribution. However, the type of radionuclide selected for radioimmunotherapy should ideally be tailored to tumour morphology (Humm, 1986). For large malignant cell clusters, the cross-fire radiation from long range beta-emitters such as yttrium-90, makes a significant contribution to tumour dose. As cell clusters become smaller, dose delivery from such radionuclides becomes less effective as beta-emissions may escape the tumour mass. Shorter range beta-emitters such as iodine-131 may produce more effective dose deposition in these circumstances. For very small clusters containing only a few cells, very short range alpha-emitters may be more appropriate (Mackliss et al., 1988). However, one obvious disadvantage of very short range emitting radionuclides, is that nearly all tumour cells must be targeted by antibody. Future studies may involve the use of antibody fragments labelled with radionuclides emitting very short range particles. In this way tumour penetration may be optimised and the comparatively rapid elimination of fragments should theoretically reduce systemic toxicity (De Nardo et al., 1983).

Despite the reservations and theoretical uncertainties of antibody guided radiation techniques, therapeutic responses have been reported

in peritoneal and leptomeningeal neoplasia (Epenetos et al., 1987; Lashford et al., 1988). The most important parameter for achieving useful therapeutic response appears to be the presence of minimal disease.

In conclusion, neoplastic meningitis is more frequently recognised following greater success with systemic chemotherapy. Greater diagnostic sophistication has followed the application of monoclonal antibodies to immunocytochemical and immunoassay techniques. Detection of minimal disease is thus more likely. In the presence of minimal disease, antibody fragments labelled with high energy short range alpha-emitting radionuclides may provide greater therapeutic effect. Future studies should concentrate on the detection of minimal disease and the development of more suitable radioimmunoconjugates for its elimination.

REFERENCES

- Aisner, J., Aisner, S.C., Ostrow, S., Govindan, S., Mummert, K. and Wiernik, P. Meningeal Carcinomatosis from Small Cell Carcinoma of the Lung: Consequence of Improved Survival. *Acta. Cytol.*, 23, 292-296 (1979).
- Aisner, J., Ostrow, S., Govindan, S. and Wiernik, P.H. Leptomeningeal Carcinomatosis in Small Cell Carcinoma of the Lung. *Med. Pediatr. Oncol.* 9, 47-59 (1981).
- Albino, A.P., Lloyd, K.O., Houghton, A.N., Oettgen, H.F. and Old, L.J. Heterogeneity in Surface Antigen and Glycoprotein Expression of Cell Lines Derived from Different Melanoma Metastases of the Same Patient: Implications for the Study of Tumor Antigens. *J. Exp. Med.* 154, 1764-1778 (1981).
- Alcolado, R., Weller, R.O., Parrish, E.P. and Garrod, D. The Cranial Arachnoid and Pia Mater in Man: Anatomical and Ultrastructural Observations. *Neuropathol. Appl. Neurobiol.*, 14, 1-17 (1988).
- Allan, P.M., Garson, J.A., Harper, E.I., Asser, U., Coakham, H.B., Brownell, B. and Kemshead, J.T. Biological Characterisation and Clinical Applications of a Monoclonal Antibody Recognising an Antigen Restricted to Neuroectodermal Tissues. *Int. J. Cancer*, 31, 591-598 (1983).
- Allan, S.G., Hay, F.G., McIntyre, M.A. and Leonard, R.C.F. Prognosis in small cell carcinoma of the lung - Relationship to human milk fat globule 2 (HMFG2) antigen and other small cell associated antigens. *Br. J. Cancer*, 56, 485-488 (1987).
- Allen, J.C. and Epstein, F. Medulloblastoma and Other Primary Malignant Neuroectodermal Tumours of the CNS. The Effects of Patient's Age and extent of Disease on Prognosis. *J. Neurosurg.*, 57, 446-451 (1982).
- Alpers, B.J. and Smith, O.N. Carcinomatosis of the Meninges of the Spinal Cord and Base of the Brain, Without Involvement of the Parenchyma, Secondary to Carcinoma of the Lung. *Am. J. Cancer*, 32, 361-366 (1938).
- Altrocchi, P.A., Reinhardt, P.H. and Eckman, P.B. Blindness and Meningeal Carcinomatosis. *Arch. Ophthalmol.*, 88, 508-512 (1972).
- Amer, M.H., Al-Sarraf, M. Baker, L.H. and Vaitkevicius, V.K. Malignant Melanoma and Central Nervous System Metastases. Incidence, Diagnosis, Treatment and Survival. *Cancer*, 42, 660-668 (1978).
- Amlot, P.L. and Adinolfi, M. Serum Beta-2-Microglobulin and Its Prognostic Value in Lymphomas. *Eur. J. Cancer*, 15, 791-796 (1978).

Anlyan, A.J. and Fishman, W.H. Beta-Glucuronidase Activity in Human Neoplastic Tissues and in Certain Body Fluids and Secretions. (Abstr.) Bull. Am. Coll. Surgeons 32, 262 (1947).

Anlyan, A.J., Gamble, J. and Hoster, H.A. Beta-Glucuronidase Activity of the White Blood Cells in Human Leukemias and Hodgkin's Disease. Cancer, 3, 116-123 (1950).

Anlyan, A.J. and Starr, A. Beta-Glucuronidase Activity of Spinal and Ventricular Fluids in Humans. Cancer, 5, 578-580 (1952).

Arklie, J. Studies of human epithelial cell surface using monoclonal antibodies. D. Phil. Thesis. Oxford University. 1981.

Aroney, R.S., Dalley, D.N., Chan, W.K., Bell, D.R. and Levi, J.A. Meningeal Carcinomatosis in Small Cell Carcinoma of the Lung. Am. J. Med., 71, 26-32 (1981).

Ascherl, G.F., Hilal, S.K. and Brisman, R. Computed Tomography of Disseminated Meningeal and Ependymal Malignant Neoplasms. Neurology (NY), 31, 567-574 (1981).

Aur, R.J.A., Simone, J., Hustu, H.O., Walters, T., Borella, L., Pratt, C. Pinkel, D. Central Nervous System Therapy and Combination Chemotherapy of Childhood Lymphocytic Leukemia. Blood, 37, 272-281 (1971).

Aur, R.J.A., Simone, J.V., Hustu, H.O. and Verzosa, M.S. A Comparative Study of Central Nervous System Irradiation and Intensive Chemotherapy Early in Remission of Childhood Acute Lymphocytic Leukemia. Cancer, 29, 381-391 (1972).

Aur, R.J.A., Hustu, H.O., Verzosa, M.S., Wood, A. and Simone, J.V. Comparison of Two Methods of Preventing Central Nervous System Leukemia. Blood, 42, 349-357 (1973).

Awad, I., Bay, J.W. and Rogers, L. Leptomeningeal Metastasis from Supratentorial Malignant Gliomas. Neurosurgery, 19, 247-251 (1986).

Azzarelli, B. and Roessmann, U. Pathogenesis of Central Nervous System Infiltration in Acute Leukemia. Arch. Pathol. Lab. Med., 101, 203-205 (1977).

Balducci, L., Little, D.D., Khansur, T. and Steinberg, M.H. Carcinomatous Meningitis in Small Cell Lung Cancer. Am. J. Med. Sci., 287, 31-33 (1984).

Band, P.R., Holland, J.F., Bernard, J., Weil, M., Walker, M. and Rall, D. Treatment of Central Nervous System Leukemia with Intrathecal Cytosine Arabinoside. Cancer, 32, 744-748 (1973).

Batson, O.V. The Function of the Vertebral Veins and Their Role in the Spread of Metastases. Ann. Surg., 112, 138-149 (1940).

Beaty, H.N. and Oppenheimer, S. Cerebrospinal Fluid Lactic Dehydrogenase and its Isoenzymes in Infections of the Central Nervous System. *N. Engl. J. Med.*, 279, 1197-1202 (1968).

Beerman, W.F. Meningeal Carcinomatosis. *J.A.M.A.*, 58, 1437-1439 (1912).

Behnam, K., Aguilera, A.J., Kornfeld, M., Jordan, S.W. and Hilgers, R.D. Meningeal Carcinomatosis from an Ovarian Primary: A Clinicopathologic Study. *Gynecol. Oncol.*, 19, 104-109 (1984).

Behnke, J., Mach, J-P., Buchegger, F., Carrel, S., Delaloye, B. and de Tribolet, N. In Vivo Localisation of Radiolabelled Monoclonal Antibody in Human Gliomas. *Br. J. Neurosurg.*, 2, 193-197 (1988).

Benjamin, J.C., Moss, T., Moseley, R.P., Maxwell, R. and Coakham, H.B. Cerebral Distribution of Immunoconjugate after Treatment for Neoplastic Meningitis Using an Intrathecal Radiolabeled Monoclonal Antibody. *Neurosurgery*, 25, 253-258 (1989).

Benson, D.F., LeMay, M., Patten, D.H. and Rubens, A.B. Diagnosis of Normal Pressure Hydrocephalus. *N. Engl. J. Med.* 283, 609-615 (1970).

Berns, D.H., Blaser, S., Ross, J.S., Masaryk, T.J. and Modic, M.T. Case Report: MR Imaging with Gd-DTPA in Leptomeningeal Spread of Lymphoma. *J. Comp. Assist. Tomog.*, 12, 499-500 (1988).

Berggard, I. and Bearn, A.G. Isolation and Properties of a Low Molecular Weight Beta-2-Globulin Occurring in Human Biological Fluids. *J. Biol. Chem.*, 243, 4095-4103 (1968).

Berry, M.P., Jenkin, D.T., Keen, C.W., Nair, B.D. and Simpson, W.J. Radiation Treatment for Medulloblastoma: A 21 Year Review. *J. Neurosurg.*, 55, 43-51 (1981).

Bertrand, I. and Aronson, L. Etude Anatomoclinique d'un Cancer Generalise des Meninges Cerebro-Spinales. *Rev. Neurol.*, 28, 145-153 (1921).

Bigner, S.H. and Johnston, W.W. The Cytopathology of Cerebrospinal Fluid. II. Metastatic Cancer, Meningeal Carcinomatosis and Primary Central Nervous System Neoplasms. *Acta Cytol.*, 25, 461-479 (1981).

Bigner, S.H. and Johnston, W.W. The diagnostic challenge of tumours manifested initially by the shedding of cells into cerebrospinal fluid. *Acta Cytologica*, 28, 29-36 (1984).

Bischoff, A. Erfahrungen mit der Tumorzell Diagnostik im Liquor Cerebrospinalis. *Acta Neurochir.*, 9, 510-524 (1961).

Blasberg, R.G., Patlak, C. and Fenstermacher, J.D. Intrathecal Chemotherapy: Brain Tissue Profiles After Ventriculo-Cisternal Perfusion. *J. Pharmacol. Exp. Ther.*, 195, 73-83 (1975).

Blasberg, R.G. Methotrexate, Cytosine Arabinoside, and BCNU Concentration in Brain After Ventriculocisternal Perfusion. *Cancer Treat. Rep.*, 61, 625-631 (1977).

Blasberg, R.G., Patlak, C.S. and Shapiro, W.R. Distribution of Methotrexate in the Cerebrospinal Fluid and Brain After Intraventricular Administration. *Cancer Treat. Rep.* 61, 633-641 (1977).

Bleyer, W.A., Drake, J.C. and Chabner, B.A. Neurotoxicity and Elevated Cerebrospinal-Fluid Methotrexate Concentration in Meningeal Leukemia. *N. Engl. J. Med.*, 289, 770-773 (1973).

Bleyer, W.A. and Savitch, J. - Letter - *New Engl. J. Med.*, 293, 1152 (1975).

Bleyer, W.A. Current Status of Intrathecal Chemotherapy for Human Meningeal Neoplasms. *Natl. Cancer Inst. Monogr.*, 46, 171-178 (1977a).

Bleyer, W.A. Clinical Pharmacology of Intrathecal Methotrexate. II. An Improved Dosage Regimen Derived From Age-Related Pharmacokinetics. *Cancer Treat. Rep.*, 61, 1419-1425 (1977b).

Bleyer, W.A. Methotrexate: Clinical Pharmacology, Current Status and Therapeutic Guidelines. *Cancer Treat. Rev.*, 4, 87-101 (1977c).

Bleyer, W.A. and Poplack, D.G. Intraventricular Versus Intralumbar Methotrexate for Central-Nervous-System Leukemia: Prolonged Remission with the Ommaya Reservoir. *Med. Pediatr. Oncol.*, 6, 207-213 (1979).

Bleyer, W.A. Neurologic Sequelae of Methotrexate and Ionizing Radiation: A New Classification. *Cancer Treat. Rep.*, 65, 89-98 (1981).

Boogerd, W., Vroom, T.M., Van Heerde, P, Brutel de la Riviere, G., Peterse, J.L., Van der Sande, J.J. CSF cytology versus immunocytochemistry in meningeal carcinomatosis. *J. Neurol. Neurosurg. Psychiatry*, 51, 142-145 (1988).

Boscato, L.M. and Stuart, M.C. Incidence and Specificity of Interference in Two-Site Immunoassays. *Clin. Chem.*, 32, 1491-1495 (1986).

Bots, G.T.A.M., Went, L.N. and Schaberg, A. Results of a Sedimentation Technique for Cytology of Cerebrospinal Fluid. *Acta. Cytol.*, 8, 234-241 (1964).

Bourdon, M.A., Wikstrand, C.J., Furthmayr, H., Matthews, T.J. and Bigner, D.D. Human Glioma-Mesenchymal Extracellular Matrix Antigen Defined by Monoclonal Antibody. *Cancer Res.*, 43, 2796-2805 (1983).

Bourdon, M.A., Coleman, R.E., Blasberg, R.G., Groothuis, D.R. and Bigner, D.D. Monoclonal Antibody Localization in Subcutaneous and Intracranial Human Glioma Xenografts: Paired-Label and Imaging Analysis. *Anticancer Res.*, 4, 133-140 (1984).

Bourdon, M.A., Matthews, T.J., Pizzo, S.U. and Bigner, D.D. Immunochemical and Biochemical Characterization of a Glioma-Associated Extracellular Matrix Glycoprotein. *J. Cell Biochem.*, 28, 183-195 (1985).

Bourne, S., Pemberton, L., Moseley, R., Lashford, L. S., Coakham, H.B. and Kemshead, J.T. Monoclonal Antibodies M340 and UJ181.4 Recognize Antigens Associated with Primitive Neuroectodermal Tumours/Tissues. *Hybridoma*, 8, 415-426 (1989).

Boyd, W. Diffuse Tumors of the Meninges. *Am. J. Pathol.*, 1, 583-593 (1925).

Boyle, R., Thomas, M. and Hume Adams, J. Diffuse Involvement of the Leptomeninges by Tumour - A Clinical and Pathological Study of 63 Cases. *Postgrad. Med. J.*, 56, 149-158 (1980).

Bramlet, D., Giliberti, J. and Bender, J. Meningeal carcinomatosis: Case report and review of the literature. *Neurology*, 26, 287-290 (1976).

Breuer, A.C., Pitman, S.W., Dawson, D.M. and Schoene, W.C. Paraparesis Following Intrathecal Cytosine Arabinoside. *Cancer*, 40, 2817-2822 (1977).

Brierley, J.B. and Field, E.J. The Connexions of the Spinal Sub-arachnoid Space with the Lymphatic System. *J. Anatomy*, 82, 153-166 (1948).

Brierley, J.B. The Penetration of Particular Matter from the Cerebrospinal Fluid into the Spinal Ganglia, Peripheral Nerves, and Perivascular Spaces of the Central Nervous System. *J. Neurol. Neurosurg. Psychiat.*, 13, 203-215 (1950).

Broderick, J.P. and Cascino, T.L. Case Report: Nonconvulsive Status Epilepticus in a Patient with Leptomeningeal Cancer. *Mayo Clin. Proc.*, 62, 835-837 (1987).

Buchegger, F., Mach, J-P, Leonnard, P. and Carrel, S. Selective Tumor Localization of Radiolabeled Anti-Human Melanoma Monoclonal Antibody Fragment Demonstrated in the Nude Mouse Model. *Cancer*, 58, 655-662 (1986).

Bunn, P.A., Schein, P.S., Banks, P.M. and DeVita, V.T. Central Nervous System Complications in Patients with Diffuse Histiocytic and Undifferentiated Lymphoma: Leukemia Revisited. *Blood*, 47, 3-10 (1976).

Burchell, J., Durbin, H., and Taylor-Papadimitriou, J. Complexity of expression of antigenic determinants, recognised by monoclonal antibodies HMFG1 and HMFG2, in normal and malignant human mammary epithelial cells. *J. Immunol.*, 131, 508-513 (1983)

Burchell, J., Wang, D., and Taylor-Papadimitriou, J. Detection of the tumour-associated antigens recognised by the monoclonal antibodies HMFG1 and 2 in serum from patients with breast cancer. *Int. J. Cancer*, 34, 763-768 (1984).

Burchell, J., Gendler, S., Taylor-Papadimitriou, J., Girling, A., Lewis, A., Millis, R. and Lampert, D. Development and characterization of breast cancer reactive monoclonal antibodies directed to the core protein of the human milk mucin. *Cancer Res.*, 47, 5476-5482 (1987).

Burchell, J., Taylor-Papadimitriou, J., Boshell, M., Gendler, S. and Duhig, T. A Short Sequence Within the Amino Acid Tandem Repeat of a Cancer Associated Mucin, Contains Immunodominant Epitopes. *Int. J. Cancer*, 44, 691-696 (1989).

Burchenal, J.H. History of Intrathecal Prophylaxis and Therapy of Meningeal Leukemia. *Cancer Drug Deliv.*, 1, 87-92 (1983).

Carrasquillo, J.A., Krohn, K.A., Beaumier, P., McGuffin, R.W., Brown, J.P., Hellstrom, K.E., Hellstrom, I. and Larson, S.M. Diagnosis Of And Therapy For Solid Tumours With Radiolabelled Antibodies And Immune Fragments. *Cancer Treat. Rep.*, 68, 317-328 (1984).

Carrel, S., Accolla, R.S., Carmagnola, A.L. and Mach, J-P. Common Human Melanoma-Associated Antigen(s) Detected by Monoclonal Antibodies. *Cancer Res.*, 40, 2523-2528 (1980).

Chatty, E.M. and Earle, K.M. Medulloblastoma. A Report of 201 Cases with Emphasis on the Relationship of Histologic Variants to Survival. *Cancer*, 28, 977-989 (1971).

Child, J.A., Spati, B., Illingworth, S., Barnard, D., Corbett, S., Simmons, A.V., Stone, J., Worthy, T.S. and Cooper, E.H. Serum Beta-2-Microglobulin and C-Reactive Protein in the Monitoring of Lymphomas: Findings in a Multicentre Study and Experience in Selected Patients. *Cancer*, 45, 318-326 (1980).

Chiquet-Ehrismann, R., Mackie, E.J., Pearson, C.A. and Sakakura, T. Tenascin: An Extracellular Matrix Protein Involved in Tissue Interactions During Fetal Development and Oncogenesis. *Cell*, 47, 131-139 (1986).

Choi, H.H. and Anderson, P.J. Diagnostic Cytology of Cerebrospinal Fluid by the Cyto centrifuge Method. *Am. J. Clin. Pathol.*, 72, 931-943 (1979).

Coakham, H.B., Harper, E.I., Garson, J.A., Brownell, B. and Lane, E.B. Carcinomatous meningitis diagnosed with monoclonal antibodies. *Br. Med. J.*, 288, 1272 (1984a).

Coakham, H.B., Garson, J.A., Brownell, B., Allan, P.M., Harper, E.I., Lane, E.B. and Kemshead, J.T. Use of monoclonal antibody panel to identify malignant cells in cerebrospinal fluid. *Lancet*, 1, 1095-1098 (1984b).

Coakham, H.B., Richardson, R.B., Davies, A.C., Bourne, S.P., Eckert, H. and Kemshead, J.T. Neoplastic meningitis from a pineal tumour treated by antibody-guided irradiation by the intrathecal route. *Brit J. Neurosurg.*, 2, 193-204 (1988).

Colcher, D., J. Estebain, J., Carrasquillo, J.A., Sugarbaker, P., Reynolds, J.C., Bryant, G., Larson, S.M. and Schlom, J. Complementation of Intracavitary and Intravenous Administration of a Monoclonal Antibody (B72.3) in Patients with Carcinoma. *Cancer Res.*, 47, 4218-4224 (1987).

Conrad, K.A., Gross, J.L. and Trojanowski, J.Q. Leptomeningeal Carcinomatosis Presenting as Eosinophilic Meningitis. *Acta. Cytol.*, 30, 29-31 (1986).

Cooper, J.F. and Harbert, J.C. Endotoxin as a Cause of Aseptic Meningitis after Radionuclide Cisternography. *J. Nucl. Med.*, 16, 809-813 (1975).

Courtenay-Luck, N.S., Epenetos, A.A., Moore, R., Larche, M., Pectasides, D., Dhokia, B. and Ritter, M.A. Development Of Primary And Secondary Immune Responses To Mouse Monoclonal Antibodies Used In The Diagnosis And Therapy Of Malignant Neoplasms. *Cancer Res.*, 46, 6489-6493 (1986).

Courtenay-Luck, N.S., Epenetos, A.A., Winearls, C.G. and Ritter M.A. Pre-existing Human Anti-Murine Immunoglobulin Reactivity Due To Polyclonal Rheumatoid Factors. *Cancer Res.*, 47, 4520-4525 (1987).

Courtenay-Luck, N.S., Epenetos, A.A., Sivolapenko, G.B., Larche, M., Barkans, J.R. and Ritter, M.A. Development of Anti-Idiotypic Antibodies Against Tumour Antigens and Autoantigens in Ovarian Cancer Patients Treated Intraperitoneally with Mouse Monoclonal Antibodies. *Lancet*, 2, 894-897 (1988).

Cruz-Sanchez, F.F., Rossi, M.L., Esiri, M.M. and Reading, M. Epithelial Membrane Antigen Expression in Ependymomas. *Neuropathol. Appl. Neurobiol.*, 14, 197-205 (1988).

Csako, G. and Chandra, P. Bronchioloalveolar Carcinoma Presenting with Meningeal Carcinomatosis: Cytologic Diagnosis in Cerebrospinal Fluid. *Acta. Cytol.*, 30, 653-656 (1986).

Curry, S.H. Drug Disposition and Pharmacokinetics with a Consideration of Pharmacological and Clinical Relationships. Blackwell Scientific Publications (1980).

D'Angio, G.J., French, L.A., Stadlan, E.M. and Kieffer, S.A. Intrathecal Radioisotopes for the Treatment of Brain Tumors. *Clin. Neurosurg.*, 15, 288-300 (1968).

D'Angio, G.J., Littman, P., Nesbit, M., Sather, H., Hittle, R., Ortega, J., Donaldson, M. and Hammond, D. Evaluation of Radiation Therapy Factors in Prophylactic Central Nervous System Irradiation For Childhood Leukemia: A Report From the Children's Cancer Study Group. *Int. J. Radiat. Oncol. Biol. Phys.*, 7, 1031-1038 (1981).

Davis, P.C., Friedman, N.C., Fry, S.M., Malko, J.A., Hoffman Jr., J.C. and Braun, I.F. Leptomeningeal metastasis: MR imaging. *Radiology*, 163, 449-454 (1987).

Dearnaley, D.P., Patel, S., Powels, T.J. and Coombes, R.C. Carcinoembryonic Antigen Estimation in Cerebrospinal Fluid in Patients with Metastatic Breast Cancer. *Oncodev. Biol. Med.*, 2, 305-311 (1981)

Delsol, G., Gatter, K.C., Stein, H., Erber, W.N., Pulford, K.A.F., Zinne, K. and Mason, D.Y. Human lymphoid cells express epithelial membrane antigen. *Lancet*, 2, 1124-1128 (1984).

DeNardo, S.J., DeNardo, G.L., Peng, J-S. and Colcher, D. Monoclonal Antibody Radiopharmaceuticals for Cancer Radioimmunotherapy. In Burchiel, S.W. and Rhodes, B.A. (eds): *Radioimmunoimaging and Radioimmunotherapy*. pp 409-417. Elsevier Science Publishing Co. Inc. (1983).

De Vita, V.T. and Canellos, G.P. Hypoglycorrhachia in Meningeal Carcinomatosis. *Cancer*, 19, 691-694 (1966).

Dhokia, B., Pectasides, D., Self, C., Habib, N.A., Herschman, M., Wood, C.B., Munro, A.J. and Epenetos, A.A. A low ph enzyme linked immunoassay using two monoclonal antibodies for the serological detection and monitoring of breast cancer. *Br. J. Cancer*, 54, 885-889 (1986).

Dinsdale, H.B. and Taghavy, A. Carcinomatosis of the Meninges. *J. Canad. Med. Assoc.*, 90, 505-512 (1964).

Dixon, G.J., Kerr, A.S. and Sharp, M.E. Meningitis Carcinomatosa: A Report of Two Cases. *Brain*, 69, 223-232 (1946).

Doge, H. and Hliscs, R. Intrathecal Therapy with Au-198-Colloid for Meningosis Prophylaxis. *Eur. J. Nucl. Med.*, 9, 125-128 (1984).

Dufour, H. Meningite Sarcomateuse Diffuse Avec Envahissement de la moelle et Das Racines: Cytologie Positive et Speciale du Liquide cephalo-rachidien. *Rev. Neurol.*, 12, 104-106 (1904).

Duttera, M.J., Bleyer, W.A., Pomeroy, T.C., Leventhal, C.M. and Leventhal, B.G. Irradiation, Methotrexate Toxicity, and the Treatment of Meningeal Leukaemia. *Lancet*, 2, 703-707 (1973).

Eberth, K.F. Zur Entwicklung des Epithelioms (Cholesteatoms) der Pia und der Lunge. *Virchow Arch.*, 49, 51-63, (1870).

Eckerman, K.F. Aspects of the Dosimetry of Radionuclides with the Skeleton with Particular Emphasis on the Active Marrow. In: Schlafke-Stelson, E.D., Watson, E.E., (eds.): Fourth International Radiopharmaceutical Dosimetry Symposium. Oak Ridge Assoc. Univ. Publications, pp 514-534 (1985).

Ehya, H., Hajdu, S. and Melamed, M. Cytopathology of Nonlymphoreticular Neoplasms Metastatic to the Central Nervous System. *Acta. Cytol.*, 25, 599-610 (1981).

Eiklid, K., Olsnes, S. and Pihl, A. Entry Of Lethal Doses Of Abrin, Ricin And Modeccin Into The Cytosol Of HeLa Cells. *Exp. Cell Res.*, 126, 321-326 (1980).

El-Batata, M. Cytology of Cerebrospinal Fluid in the Diagnosis of Malignancy. *J. Neurosurg.*, 28, 317-326 (1968).

Elman, R. Spinal Arachnoid Granulations With Especial Reference To The Cerebrospinal Fluid. *Johns Hopkins Hospital Bulletin*, 34, 99-104 (1923).

Embleton, M.J., Rowland, G.F., Simmonds, R.G., Jacobs, E., Marsden, C.H. and Baldwin, R.W. Selective Cytotoxicity Against Human Tumour Cells By A Vindesine-Monoclonal Antibody Conjugate. *Br. J. Cancer*, 47, 43-49 (1983).

Enzmann, D.R., Krikorian, C.Y. and Hayward, R. Computed Tomography in Leptomeningeal Spread of Tumour. *J. Comput. Assist. Tomogr.*, 2, 448-455 (1978).

Epenetos, A.A., Canti, G., Taylor-Papadimitriou, J., Curling, M. and Bodmer, W.F. Use Of Two Epithelium-Specific Monoclonal Antibodies For Diagnosis of Malignancy In Serous Effusions. *Lancet*, 2, 1004-1006 (1982).

Epenetos, A.A.; Hammersmith Hospital Oncology Group and Imperial Cancer Research Fund. Antibody-guided Irradiation of Malignant Lesions: Three Cases Illustrating a New Method of Treatment. *Lancet*, 1, 1441-1443 (1984).

Epenetos, A.A., Munro, A.J., Stewart, S., Rampling, R., Lambert, H.E., McKenzie, C.G., Soutter, P., Rahemtulla, A., Hooker, G., Sivolapenko, G.B., Snook, D., Courtenay-Luck, N., Dhokia, B., Krausz, T., Taylor-Papadimitriou, J., Durbin, H. and Bodmer, W.F. Antibody-Guided Irradiation of Advanced Ovarian Cancer with Intraperitoneally Administered Radiolabeled Monoclonal Antibodies. *J. Clin. Oncol.*, 5, 1890-1899 (1987).

Evans, A.E., Gilbert, E.S. and Zandstra, R. The Increasing Incidence of Central Nervous System Leukemia in Children (Children's Cancer Study Group A). *Cancer*, 26, 404-409 (1970).

Evans, A.E., Anderson, J., Chang, C., Jenkins, R.D.T., Kramer, S., Schornfeld, D. and Wilson, C. In: Paoletti P., Walker, M.D., Butti, G. and Knerich, R. (eds): Multidisciplinary Aspects of Brain Tumor Therapy. pp 219-222. Elsevier/North-Holland Biomedical Press (1979).

Evrin, P.E., Peterson, P.A., Wide, L. and Berggard, I. Radioimmunoassay of Beta-2-Microglobulin in Human Biological Fluids. Scand. J. Clin. Lab. Invest. 28, 439-443 (1971).

Fischer-Williams, M., Bosanquet, F.D. and Daniel P.M. Carcinomatosis of the Meninges: A Report of Three Cases. Brain, 78, 42-58 (1955).

Fishman, R.A. Studies of Transport of Sugars Between Blood and Cerebrospinal Fluid in Normal States and in Meningeal Carcinomatosis. Trans. Am. Neurol. Assoc., 88, 114-118 (1963).

Fishman, W.H. and Anlyan, A.J. Beta-Glucuronidase Activity in Human Tissues; Some Correlations with Processes of Malignant Growth and with the Physiology of Reproduction. Cancer Res., 7, 808-817 (1947).

Fleisher, G.A., Wakin, K.G. and Goldstein, N.P. Glutamic-Oxalacetic Transaminase and Lactic Dehydrogenase in Serum and Cerebrospinal Fluid of Patients with Neurological Disorders. Mayo Clin. Proc., 32, 188-197 (1957).

Fleisher, M., Wasserstrom, W.R. Schold, S.C., Schwartz, M.K. and Posner, J.B. Lactic dehydrogenase isoenzymes in the cerebrospinal fluid of patients with systemic cancer. Cancer, 47, 2654-2659 (1981).

Fraker, P.J. and Speck, J.C. Protein and cell membrane iodinations with a sparingly soluble chloroamide 1, 3, 4, 6 - tetrachloro, 3a - 6a diphenylglycoluril. Biochem. Biophys. Res. Commun., 80, 849-857 (1978).

Freeman, J.E., Johnston, P.G. and Voke, J.M. Somnolence After Prophylactic Cranial Irradiation in Children With Acute Lymphoblastic Leukaemia. Br. Med. J., 4, 523-525 (1973).

Fried, B.M. Leukemia And The Central Nervous System; With A Review Of Thirty Cases From The Literature. Arch. Pathol. (Chicago), 2, 23-40 (1926).

Frick, J., Ritch., P.S., Hansen, R.M. and Anderson, T. Successful Treatment of Meningeal Leukemia Using Systemic High-Dose Cytosine Arabinoside. J. Clin. Oncol., 2, 365-368 (1984).

Fuller, L.G.A., Rogoff, E., Deck, M., Galicich, J., Ghavimi, F., Levitt, S., Smith, C.E. and D'Angio, G.J. Recent Experience with Intrathecal Radiogold for Medulloblastoma and Ependymoblastoma: A Progress Report. Am. J. Roentgenol. Radium Ther. Nucl. Med., 122, 75-79 (1974).

Fulton, D.S., Levin, V.A., Gutin, P.H., Edwards, M.S.B., Seager, M.L., Stewart, J. and Wilson, C.B. Intrathecal Cytosine Arabinoside for the Treatment of Meningeal Metastases from Malignant Brain Tumors and Systemic Tumors. *Cancer Chemother. Pharmacol.*, 8, 285-291 (1982).

Gaglano, R.G. and Costanzi, J.J. Paraplegia Following Intrathecal Methotrexate: Report of a Case and Review of the Literature. *Cancer*, 37, 1663-1668 (1976).

Garbes, A.D. Cytological Presentation of Primary Leptomeningeal Sarcomatosis. *Acta. Cytol.*, 28, 709-712 (1984).

Garson, J.A., Coakham, H.B., Kemshead, J.T., Brownell, B. Harper, E.I., Allan, P. and Bourne, S. The Role of Monoclonal Antibodies in Brain Tumour Diagnosis and Cerebrospinal Fluid (CSF) Cytology. *J. Neuro-Oncol.*, 3, 165-171 (1985).

Gatter, K.C., Alcock, C., Heryet, A. and Mason, D.Y. Clinical Importance of Analysing Malignant Tumours of Uncertain Origin with Immunohistological Techniques. *Lancet*, 1, 1302-1305 (1985).

Geils, G.F., Scott, C.W., Baugh, C.M. and Butterworth, C.E. Treatment of Meningeal Leukemia with Pyrimethamine. *Blood*, 38, 131-137 (1971).

Gendler, S., Taylor-Papadimitriou, J, Duhig, T., Rothbard, J. and Burchell, J. A Highly Immunogenic Region of a Human Polymorphic Epithelial Mucin Expressed by Carcinomas is made up of Tandem Repeats. *J. Biol. Chem.*, 263, 12820-12823 (1988).

Gerhardt, W., Clausen, J., Christensen, E. and Riishede, J. Lactate Dehydrogenase Isoenzymes in the Diagnosis of Human Benign and Malignant Brain Tumours. *J. Natl. Cancer Inst.*, 38, 343-356 (1967).

Giannone, L., Greco, F.A. and Hainsworth, J.D. Combination Intraventricular Chemotherapy for Meningeal Neoplasia. *J. Clin. Oncol.*, 4, 68-73 (1986).

Gibaldi, M. and Perrier, D. *Drugs and the Pharmaceutical Sciences: vol. 1, Pharmacokinetics.* Marcel Dekker, Inc. (1975).

Glass, J.P., Melamed, M, Chernik, N.L. and Posner, J.B. Malignant Cells in Cerebrospinal Fluid (CSF): The meaning of a positive CSF cytology. *Neurology*, 29, 1369-1375 (1979).

Globus, J.H. and Meltzer, T. Metastatic Tumors of the Brain. *Arch. Neurol. Psychiatry*, 48, 163-226 (1942).

Gold, L.H.A., Kieffer, S.A., D'Angio, G.J., Fallon, V.T. and Long, D.M. Current Status of Intrathecal Radiogold in the Treatment of Medulloblastoma. *Acta. Radiologica. Ther. Phys. Biol.*, 11, 329-340 (1972).

Gold, P. and Freedman, S.O. Demonstration of Tumor-Specific Antigens in Human Colonic Carcinomata by Immunological Tolerance and Absorption Techniques. *J. Exp. Med.*, 121, 439-462 (1965).

- Goldman, R.D., Kaplan, N.O. and Hall, T.C. Lactic Dehydrogenase in Human Neoplastic Tissues. *Cancer Res.*, 24, 389-399 (1964).
- Gonzalez-Vitale, J.C. and Garcia-Bunuel, R. Meningeal Carcinomatosis. *Cancer*, 37, 2906-2911 (1976).
- Grain, G.O. and Karr, J.P. Diffuse leptomeningeal carcinomatosis: Clinical and Pathological Characteristics. *Neurology*, 5, 706-722 (1955).
- Green, D.M., Freeman, A.I., Sather, H.N., Sallan, H.N., Nesbit, M.E., Cassady, J.R., Sinks, L.F., Hammond, D. and Frei, E. Comparison of Three Methods Of CNS Prophylaxis in Childhood Acute Lymphoblastic Leukaemia. *Lancet*, 1, 1398-1402 (1980).
- Green, J.B., Oldewurtel, H.A., O'Doherty, D.S. and Forster, F.M. Cerebrospinal Fluid Transaminase and Lactic Dehydrogenase Activities in Neurologic Disease. *Arch. Neurol. & Psychiat.* 80, 148-156 (1958).
- Green, J.B., Oldewurtel, H.A. and Forster, F.M. Glutamic-Oxalacetic Transaminase and Lactic Dehydrogenase Activities. *Neurology (Minneapolis)*, 9, 540-544 (1959).
- Greenfield, J.G., *Proc. Roy. Soc. Med.*, 31 (Part 2), 1450-1453 (1937-8)
- Greenwood, F.C., Hunter, W.M. and Glover, J.S. The Preparation of I-131 Labelled Human Growth Hormone of High Specific Radioactivity. *Biochem. J.*, 89, 114-123 (1963).
- Griffin, J.W., Thompson, R.W., Mitchinson, M.J., de Kiewiet, J.C. and Welland, F.H. Lymphomatous Leptomeningitis. *Am. J. Med.*, 51, 200-208 (1971).
- Grossman, S.A., Trump, D.L., Chen, D.C.P., Thompson, G. and Camargo, E.E. Cerebrospinal Fluid Flow Abnormalities in Patients with Neoplastic Meningitis: An Evaluation using ¹¹¹Indium-DTPA Ventriculography. *Am. J. Med.*, 73, 641-647 (1982).
- Gutin, P.H., Weiss, H.D., Wiernik, P.H. and Walker, M.D. Intrathecal N, N', N"-Triethylenethiophosphoramidate [Thio-Tepa (NSC 6396)] in the Treatment of Malignant Meningeal Disease. Phase I-II Study. *Cancer*, 38, 1471-1475 (1976).
- Gutin, P.H., Levi, J.A., Wiernik, P.H. and Walker, M.D. Treatment of Malignant Meningeal Disease with Intrathecal ThioTEPA: A Phase II Study. *Cancer Treat. Rep.*, 61, 885-887 (1977).
- Hagler, S., Currimbhoy, A.A. and Tinsley, M. Cerebellar Medulloblastoma: Chemotherapeutic Remission with Vincristine, Cyclophosphamide and Methotrexate. *Cancer*, 21, 912-919 (1968).
- Hancock, W.W. and Medley, G. Monoclonal Antibodies to Identify Tumour Cells in CSF. *Lancet*, 2, 739-740 (1983).

Hayes, D.F., Sekine, H., Ohno, T., Abe, M., Keefe, K. and Kufe, D.W. Use of a Murine Monoclonal Antibody for Detection of Circulating Plasma DF3 Antigen Levels in Breast Cancer Patients. *J. Clin. Invest.*, 75, 1671-1678 (1985).

Heathfield, K.W.G. and Williams, J.R.B. Carcinomatosis of the Meninges: Some Clinical and Pathological Aspects. *Br. Med. J.*, 1, 328-330 (1956).

Heimann, A. and Merino, M.J. Carcinomatous Meningitis as the Initial Manifestation of Breast Cancer. *Acta. Cytol.*, 30, 25-28 (1986).

Henson, R.A. and Urich, H. Cancer and the Central Nervous System: The Neurological Manifestations of Systemic Malignant Disease. pp. 100-119, Blackwell Scientific Publications (1982).

Heyderman, E., Strudley, I., Powell, G., Richardson, T.C., Cordell, J.L. and Mason, D.Y. A New Monoclonal Antibody to Epithelial Membrane Antigen (EMA)-E29. A Comparison of its Immunocytochemical Reactivity with Polyclonal Anti-EMA Antibodies and with Another Monoclonal Antibody, HMFG2. *Br. J. Cancer*, 52, 355-361 (1985).

Hilkens, J., Buijs, F., Hilgers, J., Hageman, Ph., Calafat, J., Sonnenberg, A. and Van Der Valk, M. Monoclonal Antibodies Against Human Milk-Fat Globule Membranes Detecting Differentiation Antigens of the Mammary Gland and its Tumors. *Int. J. Cancer*, 34, 197-206 (1984).

Hilkens, J., Kroezen, V., Bonfrer, J.M.G., De Jong-Bakker, M. and Bruning, P.F. MAM-6 Antigen, a New Serum Marker for Breast Cancer Monitoring. *Cancer Res.*, 46, 2582-2587 (1986).

Hinuma, Y., Nagata, K., Hanaoka, M., Nakai, M., Matsumoto, T., Kinoshita, K.I., Shirakawa, S. and Miyoshi, I. Adult T-Cell Leukemia: Antigen in an ATL Cell Line and Detection of Antibodies to the Antigen in Human Sera. *Proc. Natl. Acad. Sci. (USA)*, 78, 6476-6480 (1981).

Hitchins, R.N., Bell, D.R., Woods, R.L. and Levi, J.A. A Prospective Randomized Trial of Single-Agent Versus Combination Chemotherapy in Meningeal Carcinomatosis. *J. Clin. Oncol.*, 5, 1655-1662 (1987).

Hornback, N.B. Radiation Therapy in Treatment of Medulloblastoma in Childhood. In: Zeltzer, P.M. and Pochedly, C. (eds.): *Medulloblastomas in Children; New Concepts in Tumor Biology, Diagnosis and Treatment*. Praeger Publishers (1986).

Hughes, I.E., Hume Adams, J and Ilbert, R.C. Invasion of the Leptomeninges by Tumour: The Differential Diagnosis from Tuberculous Meningitis. *J. Neurol. Neurosurg. Psychiat.*, 26, 83-89 (1963).

Humm, J.L. Dosimetric Aspects of Radiolabeled Antibodies for Tumor Therapy. *J. Nucl. Med.*, 27, 1490-1497 (1986).

Hustu, H.O., Aur, R.J.A., Verzosa, M.S., Simone, J.V. and Pinkel, D. Prevention of Central Nervous System Leukemia By Irradiation. *Cancer*, 32, 585-597 (1973).

Hutchings, M. and Weller, R.O. Anatomical Relationships of the Pia Mater to Cerebral Blood Vessels in Man. *J. Neurosurg.* 65, 316-325 (1986).

Hyman, C.B., Bogle, J.M., Brubaker, C.A., Williams, K. and Hammond, D. Central Nervous System Involvement by Leukemia in Children. II. Therapy with Intrathecal Methotrexate. *Blood*, 25, 13-22 (1965).

Jacobi, C, Reiber, H. and Felgenhauer, K. The Clinical Relevance of Locally Produced Carcinoembryonic Antigen in Cerebrospinal Fluid. *J. Neurol.* 233, 358-361 (1986).

Jacobs, L.L. and Richland, K.J. Carcinomatosis of the Leptomeninges: Review of Literature and Report of Four Cases. *Bull. Los Angeles Neurol. Soc.*, 16, 335-356 (1951).

Jaeckle, K.A., Assessment of Tumor Markers in Cerebrospinal Fluid. *Clin. Lab. Med.*, 5, 303-315 (1985).

Jamshidi, J, Yoshimine, T., Ushio, Y., Hayakawa, T., Morimoto, K. and Mogami, H. Pathology of Brain Parenchyma in Meningeal Carcinomatosis: Immunohistochemical Study with Astroprotein (GFAP) and Tubulin. *J. Neuro-Oncol.*, 5, 65-71 (1987).

Jansen, F.K., Blythman, H.E., Carriere, D., Casellas, P., Gros, O., Gros, P., Laurent, J.C., Paolucci, F., Pau, B., Poncelet, P., Richer, G., Vidal, H. and Voisin, G.A. Immunotoxins: Hybrid Molecules Combining High Specificity and Potent Cytotoxicity. *Immunol. Rev.*, 62, 185-216 (1982).

Janssen, J.A.M.J.L., Blankestijn, P.J., Docter, R., Blijenberg, B.G., Splinter, T.A.W., Van Toor, H., Schalekamp, M.A.D.H., Lamberts, S.W.J. and Krenning, E.P. Effects of Immunoscintigraphy with Monoclonal Antibodies in Assays of Hormones and Tumour Markers. *Br. Med. J.*, 298, 1511-1513 (1989).

Jones, D.H., Goldman, A., Gordon, I., Pritchard, J., Gregory, B.J. and Kemshead, J.T. Therapeutic Application of a Radiolabelled Monoclonal Antibody in Nude Mice Xenografted with Human Neuroblastoma: Tumoricidal Effects and Distribution Studies. *Int. J. Cancer*, 35, 715-720 (1985).

Kaiser, A.B. and McGee, Z.A. Aminoglycoside Therapy of Gram-Negative Bacillary Meningitis. *New Engl. J. Med.* 293, 1215-1220 (1975).

Kandt, R.S., Shinnar, S., D'Souza, B.J., Singer, H.S., Wharam, M.D. and Gupta, P.K. Cerebrospinal Metastases in Malignant Childhood Astrocytomas. *J. Neuro-Oncol.*, 2, 123-128 (1984).

Kemshead, J.T. and Coakham, H.B. The Use of Monoclonal Antibodies for the Diagnosis of Intracranial Malignancies and the Small Round Cell Tumours of Childhood. *J. Pathol.*, 141, 249-257 (1983).

Khoo, S.K., Warner, N.L., Lie, J.T. and Mackay, I.R. Carcinoembryonic Antigenic Activity of Tissue Extracts: A Quantitative Study of Malignant and Benign Neoplasms, Cirrhotic Liver, Normal Adult and Fetal Organs. *Int. J. Cancer*, 11, 681-687 (1973).

Kido, D.K., Gomez, D.G., Pavese, A.M. and Potts, D.G. Human Spinal Arachnoid Villi and Granulations. *Neuroradiology*, 11, 221-228 (1976).

Kieffer, S.A., Wolff, J.M., Prentice, W.B. and Loken, M.K. Scintiscisternography in Individuals Without Known Neurological Disease. *Am. J. Roentgenol. Radium Ther. Nucl. Med.*, 112, 225-236 (1971).

Kim, K.S., Ho, S.U., Weinberg, P. and Lee, C. Spinal Leptomeningeal Infiltration by Systemic Cancer: Myelographic Features. *AJR.*, 139, 361-365 (1982).

Klee, G.G., Tallman, R.D., Goellner, J.R. and Yanagihara, T. Elevation of Carcinoembryonic Antigen in Cerebrospinal Fluid Among Patients With Meningeal Carcinomatosis. *Mayo Clin. Proc.*, 61, 9-13 (1986).

Kleinert, R., Walter, G.F. and Kleinert, G. Carcinomatous Meningeosis as Exclusive Metastasizing Pattern in a Malignant Thymoma. *Acta Neuropathol. (Berl.)*, 67, 329-331 (1985).

Kline, T.S. Cytological Examination of the Cerebrospinal Fluid. *Cancer*, 15, 591-597 (1962).

Knierim, G. Uber Diffuse Meningealkarcinose Mit Amaurose und Taubheit bei Magenkrebs. *Beitr. Pathol. Anat.*, 44, 409-427 (1908).

Koch, T.R., Lichtenfeld, K.M. and Wiernik, P.H. Detection of Central Nervous System Metastasis with Cerebrospinal Fluid Beta-2-Microglobulin. *Cancer*, 52, 101-104 (1983).

Kohler, G. and Milstein, C. Continuous Cultures of Fused Cells Secreting Antibody of Predefined Specificity. *Nature*, 256, 495-497 (1975).

Kokkoris, C.P. Leptomeningeal Carcinomatosis: How Does Cancer Reach the Pia-Arachnoid? *Cancer*, 51, 154-160 (1983).

Komp, D.M., Fernandez, C.H., Falletta, J.M., Ragab, A.H., Humphrey, G.B., Pullen, J., Moon, T. and Shuster, J. CNS Prophylaxis in Acute Lymphoblastic Leukemia: Comparison of Two Methods - A Southwest Oncology Group Study. *Cancer*, 50, 1031-1036 (1982).

Krahn, V. The Pia Mater at the Site of the Entry of Blood Vessels Into the Central Nervous System. *Anat. Embryol.*, 164, 257-263 (1982).

Krol, G., Sze, G., Malkin, M. and Walker, R. MR of Cranial and Spinal Meningeal Carcinomatosis: Comparison with CT and Myelography. *AJNR*, 9, 709-714 (1988).

Kun, L.E., Camitta, B.M., Mulhern, R.K., Lauer, S.J., Kline, R.W., Casper, J.T., Kamen, B.A., Kaplan, B.M. and Barber, S.W. Treatment of Meningeal Relapse in Childhood Acute Lymphoblastic Leukemia. I. Results of Craniospinal Irradiation. *J. Clin. Oncol.*, 2, 359-364 (1984).

Kupchick, H. and Zamcheck, N. Carcinoembryonic Antigen in Liver Disease. II. Isolation from Human Cirrhotic Liver and Serum and from Normal Liver. *Gastroenterology*, 63, 95-101 (1972).

Landberg, T.G., Lindgren, M.L., Cavallin-Stahl, E.K., Svahn-Tapper, G.O., Sundbarg, G., Garwicz, S., Lagergren, J.A., Gunnesson, V.L., Brun, A.E. and Cronqvist, S.E. Improvements in the Radiotherapy of Medulloblastoma, 1946-1975. *Cancer*, 45, 670-678 (1980).

Lane, D. and Koprowski, H. Molecular Recognition and the Future of Monoclonal Antibodies. *Nature*, 296, 200-202 (1982).

Larson, S.M., Schall, G.L. and Di Chiro, G. The Influence of Previous Lumbar Puncture and Pneumoencephalography on the Incidence of Unsuccessful Radioisotope Cisternography. *J. Nucl. Med.*, 12, 555-557 (1971).

Larson, S.M., Carrasquillo, J.A., Krohn, K.A., Brown, J.T., McGuffin, R.W., Ferens, J.M., Graham, M.M., Hill, L.D., Beaumier, P.L., Hellstrom, K.E. and Hellstrom, I. Localisation of I-131-labelled P97-Specific Fab Fragments in Human Melanoma as a Basis for Radiotherapy. *J. Clin. Invest.*, 72, 2101-2114 (1983).

Lashford, L.S., Davies, A.G., Richardson, R.B., Bourne, S.P., Bullimore, J.A., Eckert, H., Kemshead, J.T. and Coakham, H.B. A Pilot Study of 131-I Monoclonal Antibodies in the Therapy of Leptomeningeal Tumors. *Cancer* 61, 857-868 (1988).

Le Baron, S. Neuropsychological Sequelae in Survivors of Medulloblastoma. In: Zeltzer, P.M. and Pochedly, C. (eds.): *Medulloblastomas in Children; New Concepts in Tumor Biology, Diagnosis and Treatment.* pp 237-250. Praeger Publishers (1986).

Lee, Y-Y., Glass, P., Geoffray, A., and Wallace, S. Cranial Computed Tomographic Abnormalities in Leptomeningeal Metastasis. *A.J.R.* 143, 1035-1039 (1984).

Lee, Y.S., Bullard, D.E., Zalutsky, M.R., Coleman, R.E., Friedman, H.S., Colapinto, E.V. and Bigner, D.D. Therapeutic Efficacy of Murine Monoclonal Antibody 81C6 in a Human Glioma Xenograft Model. *Cancer Res.*, 48, 559-566 (1988a).

Lee, Y., Bullard, D.E., Humphrey, P.A., Colapinto, E.V., Friedman, H.S., Zalutsky, M.R., Coleman, R.E. and Bigner, D.D. Treatment of Intracranial Human Glioma Xenografts with I-131-labeled Anti-Tenascin Monoclonal Antibody 81C6. *Cancer Res.*, 48, 2904-2910 (1988b).

Lewis, N.D.C. An Unusual Manifestation of Metastatic Miliary Carcinomatosis of the Central Nervous System. *Am. J. Psychiat.*, 5, 171-187 (1925).

Lilienfeld, J. and Benda, C. Fall von Metastischer Karcinose der Neivenund Hirnhaute. *Berlin Klin Wochenschr*, 38, 729-730 (1901).

Lindmo, T., Boven, E., Cuttitta, F., Fedorko, J. and Bunn, P.A. Determination of the Immunoreactive Fraction of Radiolabeled Monoclonal Antibodies by Linear Extrapolation to Binding at Infinite Antigen Excess. *J. Immunol. Methods*, 72, 77-89 (1984).

Lindmo, T. and Bunn, P.A. Determination of the True Immunoreactive Fraction of Monoclonal Antibodies after Radiolabeling. *Methods in Enzymology*, 121, 678-691 (1986).

Little, J.R., Dale, A.J.D., Okazaki, H.M.D. Meningeal Carcinomatosis - Clinical Manifestations. *Arch. Neurol.*, 30, 138-143 (1974).

LoGerfo, P., Krupey, J. and Hansen, H.J. Demonstration of an Antigen Common to Several Varieties of Neoplasia: Assay using Zirconyl Phosphate Gel. *N. Engl. J. Med.*, 285, 138-141 (1971).

Macsween, J.M., Warner, N.L. and Mackay, I.R. Carcinoembryonic Antigen in Whole Serum, *Br. J. Cancer*, 26, 356-358 (1972).

Macklis, R.M., Kinsey, B.M., Kassis, A.I., Ferrara, J.L.M., Atcher, R.W., Hines, J.J., Coleman, C.N., Adelstein, S.J. and Burakoff, S.J. Radioimmunotherapy with Alpha-Particle-Emitting Immunoconjugates. *Science*, 240, 1024-1026 (1988).

Madow, L. and Alpers, B.J. Encephalitic Form of Metastatic Carcinoma. *Arch. Neurol. Psychiatry*, 65, 161-173 (1951).

Makin, C.A., Bobrow, L.G. and Bodmer, W.F. Monoclonal Antibody to Cytokeratin for Use in Routine Histopathology. *J. Clin. Pathol.*, 37, 975-983 (1984).

Malkin, M.G. and Posner, J.B. Cerebrospinal Fluid Tumor Markers for the Diagnosis and Management of Leptomeningeal Metastases. *Eur. J. Cancer Clin. Oncol.*, 23, 1-4 (1987).

Margulies, D.H., Kuehl, W.M. and Scharff, M.D. Somatic Cell Hybridization of Mouse Myeloma Cells. *Cell*, 8, 405-415 (1976).

Marks, V. and Marrack, D. Tumour Cells in the Cerebrospinal Fluid. *J. Neurol. Neurosurg. Psychiat.*, 23, 194-201 (1960).

Matzku, S., Kirchgessner, H. and Nissen, M. Iodination of Monoclonal IgG Antibodies at a Sub-Stoichiometric Level: Immunoreactivity Changes Related to the Site of Iodine Incorporation. *Int. J. Radiat. Appl. Instrum. Part B*, 14, 451-457 (1987).

Mavligit, G.M., Stuckey, S.E., Cabanillas, F.F., Keating, M.J., Tourtellotte, W.W., Schold, S.C. and Freireich, E.J. Diagnosis of Leukemia or Lymphoma in the Central Nervous System by Beta-2-Microglobulin Determination. *New Engl. J. Med.*, 303, 718-721 (1980).

Mayer, R.J., Berkowitz, R.S. and Griffiths, C.T. Central Nervous System Involvement by Ovarian Carcinoma: A Complication of Prolonged Survival with Metastatic Disease. *Cancer*, 41, 776-783 (1978).

McCrary, J.A., Patrinely, J.R. and Font, R.L. Progressive Blindness Caused by Metastatic Occult Signet-Ring Cell Gastric Carcinoma. *Arch. Ophthalmol.*, 104, 410-413 (1986).

McFarland, D.R., Horwitz, H., Saenger, E.L. and Bahr, G.K. Medulloblastoma: A Review of Prognosis and Survival. *Br. J. Radiol.*, 42, 198-214 (1969).

McKelvey, E.M. Meningeal Involvement with Metastatic Carcinoma of the Breast Treated with Intrathecal Methotrexate. *Cancer*, 22, 576-580 (1968).

McMillan, J.A. Meningitis due to Carcinomatosis: Case with Free Carcinoma Cells in Cerebrospinal Fluid. *Br. Med. J.*, 1, 1452-1453 (1962).

Meis, J.M., Osborne, B.M. and Butler, J.J. A Comparative Marker Study of Large Cell Lymphoma, Hodgkin's Disease, and True Histiocytic Lymphoma in Paraffin-Embedded Tissue. *Am. J. Clin. Pathol.*, 86, 591-599 (1986).

Meissner, G.F. Carcinoma of the Stomach with Meningeal Carcinosis: Report of Four Cases. *Cancer*, 6, 313-318 (1953).

Melhorn, D.K., Gross, S., Fisher, B.J. and Newman, A.J. Studies on the Use of "Prophylactic" Intrathecal Amethopterin in Childhood Leukemia. *Blood*, 36, 55-60 (1970).

Messert, B. and Rieder, M.J. RISA Cisternography: Study of Spinal Fluid Changes associated with Intrathecal RISA Injection. *Neurology*, 22, 789-792 (1972).

Metz, O., Stoll, W. and Plenert, W. Meningosis Prophylaxis with Intrathecal Au-198-Colloid and Methotrexate in Childhood Acute Lymphocytic Leukemia. *Cancer*, 49, 224-228 (1982).

Mikhael, M.A. Radiation Necrosis of the Brain: Correlation Between Patterns on Computed Tomography and Dose of Radiation. *J. Comput. Assist. Tomogr.*, 3, 241-249 (1979).

Misset, J.L., Mathe, G. and Horoszewicz, J.S. Intrathecal Interferon in Meningeal Leukemia. *N. Engl. J. Med.*, 304, 1544 (1981).

Moberg, A. and Reis, G.V. Carcinosis Meningum. *Acta. Medica Scandinavica*, 170, 747-755 (1961).

Moore, E.W., Thomas, L.B., Shaw, R.K. and Freireich, E.J. The Central Nervous System in Acute Leukemia: A Postmortem Study of 117 Consecutive Cases, with Particular Reference to Hemorrhages, Leukemic Infiltrations, and the Syndrome of Meningeal Leukemia. *AMA Arch. Intern. Med.*, 105, 451-468 (1960).

Moore, T.L., Kupchick, H.Z. and Marcon, N. Carcinoembryonic Antigen (CEA) Assay in Cancer of the Colon and Pancreas and Other Digestive Tract Disorders. *Am. J. Dig. Dis.*, 16, 1-7 (1971).

Morganroth, J., Deisseroth, A., Winokur, S. and Schein, P. Differentiation of Carcinomatous and Bacterial Meningitis. *Neurology (Minneapolis)*, 22, 1240-1242 (1972).

Moseley, R.P., Davies, A.G., Bourne, S.P., Popham, C., Carrel, S., Monro, P. and Coakham, H.B. Neoplastic meningitis in malignant melanoma: diagnosis with monoclonal antibodies. *J. Neurol. Neurosurg. Psychiat.* 52, 881-886 (1989a).

Moseley, R.P., Oge, K., Shafqat, S., Moseley, C.M., Sullivan, N.M., Badley, R.A., Burchell, J., Taylor-Papadimitriou, J. and Coakham, H.B. HMFG1 Antigen: A New Marker for Carcinomatous Meningitis. *Int. J. Cancer*, 44, 440-444 (1989b).

Moss, J.A., Nannis, E.D. and Poplack, D.G. The Effects of Prophylactic Treatment of the Central Nervous System on the Intellectual Functioning of Children with Acute Lymphocytic Leukemia. *Am. J. Med.*, 71, 47-52 (1981).

Murray, J.J., Greco, F.A., Wolff, S.N. and Hainsworth, J.D. Neoplastic Meningitis: Marked Variations of Cerebrospinal Fluid Composition in the Absence of Extradural Block. *Am. J. Med.*, 75, 289-294 (1983).

Nagourney, R.A., Hedaya, R., Linnoila, M., and Schein, P.S. Carcinoid Carcinomatous Meningitis. *Ann. Int. Med.* 102, 779-782 (1985).

Naylor, B. The Cytologic Diagnosis of Cerebrospinal Fluid. *Acta. Cytol.*, 8, 141-149 (1964).

Naylor, A.R., MacGregor, J.E., Hutcheon, A.W. and Best, P.V. Meningeal Carcinomatosis from a Clinically Undiagnosed Signet-Ring Cell Primary in the Gallbladder. *Surg. Neurol.* 29, 315-318 (1988).

Nelson, P.V., Carey, W.F. and Pollard, A.C. Diagnostic Significance and Source of Lactic Dehydrogenase and Its Isoenzymes in Cerebrospinal Fluid of Children with a Variety of Neurologic Disorders. *J. Clin. Pathol.*, 28, 828-833 (1975).

Nesbit, M.E., D'Angio, G.J., Sather, H.N., Robison, L.L., Ortega, J., Donaldson, M. and Hammond, G.D. Effect of Isolated Central Nervous System Leukaemia on Bone Marrow Remission and Survival in Childhood Acute Lymphoblastic Leukaemia. *Lancet*. 1, 1386-1388 (1981).

- Nies, B.A., Thomas, L.B. and Freireich, E.J. Meningeal Leukemia: A Follow-up Study. *Cancer*, 18, 546-553 (1965).
- Oberfield, S.E., Allen, J.C., Pollack, J., New, M.I. and Levine, L.S. Long-Term Endocrine Sequelae After Treatment of Medulloblastoma: Prospective Study of Growth and Thyroid Function. *J. Pediatr.*, 108, 219-223 (1986).
- Olson, M.E., Chernik, N.L. and Posner J.B. Infiltration of the Leptomeninges by Systemic Cancer: A Clinical and Pathological Study. *Arch. Neurol.*, 30, 122-137 (1974).
- Ongerboer de Visser, B.W., Somers, R., Nooyen, W.H., Van Heerde, R., Hart, A.A.M. and McVie, J.G. Intraventricular Methotrexate Therapy of Leptomeningeal Metastasis from Breast Carcinoma. *Neurology (Cleveland)*, 33, 1565-1572 (1983).
- Packer, R.J., Siegel, K.R., Sutton, L.N., Litmann, P., Bruce, D.A. and Schut, L. Leptomeningeal Dissemination of Primary Central Nervous System Tumors of Childhood. *Ann. Neurol.* 18, 217-221 (1985).
- Packer, R.J., Schut, L. and Siegel, K.R. Dissemination of Primary Central Nervous System Tumors of Childhood: Incidence and Clinical Implications. *Prog. Exp. Tumor Res.*, 30, 206-214 (1987).
- Panton, P.N. and Cantab, B.C. The Detection of Malignant Cells in Body Fluids. *Lancet*, 2, 762 (1922).
- Parsons, M. The Spinal Form of Carcinomatosis meningitis. *Q. J. Med.* 41, 509-518 (1972).
- Pectasides, D., Stewart, S., Courtenay-Luck, N., Rampling, R., Munro, A.J., Krausz, T., Dhokia, B., Snook, D., Hooker, G., Durbin, H., Taylor-Papadimitriou, J., Bodmer, W.F. and Epenetos, A.A. Antibody-Guided Irradiation of Malignant Pleural and Pericardial Effusions. *Br. J. Cancer*, 53, 727-732 (1986).
- Pedersen, A.G., Paulson, O.B. and Gyldensted, C. Metrizamide Myelography in Patients with Small Cell Carcinoma of the Lung Suspected of Meningeal Carcinomatosis. *J. Neuro-Oncol.*, 3, 85-89 (1985).
- Pedersen, A.G., Olson, J. and Nasiell, M. Cerebrospinal Fluid Cytology Diagnosis of Meningeal Carcinomatosis in Patients with Small-Cell Carcinoma of the Lung: A study of Interobserver and Intraobserver Variability. *Acta. Cytol.*, 30, 648-652 (1986).
- Peylan-Ramu, N., Poplack, D.G., Pizzo, P.A., Adornato, B.T. and Di Chiro, G. Abnormal CT Scans of the Brain in Asymptomatic Children with Acute Lymphocytic Leukemia after Prophylactic Treatment of the Central Nervous System with Radiation and Intrathecal Chemotherapy. *New. Engl. J. Med.*, 298, 815-818 (1978).
- Pierre-Khan, A., Hirsh, J.F., Roux, F.X., Renier, D. and Sainte-Rose, C. Intracranial Ependymomas in Childhood, Survival and Functional Results in 47 Cases. *Childs Brain*, 10, 145-156 (1983).

- Pinkerton, C.R. and Chessells, J.M. Failed Central Nervous System Prophylaxis in Children with Acute Lymphoblastic Leukaemia: Treatment and Outcome. *Br. J. Haematol.*, 57, 553-561 (1984).
- Pizzo, P.A., Poplack, D.G. and Bleyer, W.A. Neurotoxicities of Current Leukemia Therapy. *Am. J. Pediatr. Hematol. Oncol.*, 1, 127-140 (1979).
- Polmeteer, F.E. and Kerhohan, J.W. Meningeal Gliomatosis: A Study of Forty-two Cases. *Arch. Neurol.* 57, 593-616 (1947)
- Posner, J.B. Reservoirs For Intraventricular Chemotherapy. *N. Engl. J. Med.*, 288, 212 (1973).
- Posner, J.B. Management of Central Nervous System Metastases. *Semin. Oncol.*, 4, 81-91 (1977).
- Posner, J.B. and Chernik, N.L. Intracranial Metastases from Systemic Cancer. *Adv. Neurol.* 19, 579-592 (1978).
- Posner, J.B. Neurological Complications of Systemic Cancer. *Med. Clin. North. Am.*, 63, 783-800 (1979).
- Pressman, D. and Korngold, L. The In-Vivo Localization of Anti-Wagner-Osteogenic-Sarcoma Antibodies. *Cancer (Phila.)*, 6, 619-623 (1953).
- Pressman, D., Day, E.D. and Blau, M. The Use of Paired Labeling in the Determination of Tumor-Localizing Antibodies. *Cancer Res.*, 17, 845-850 (1957).
- Price, R.A. and Johnson, W.W. The Central Nervous System in Childhood Leukemia: 1. The Arachnoid. *Cancer*, 31, 520-533 (1973).
- Price, R.A. and Jamieson, P.A. The Central Nervous System in Childhood Leukemia. II. Subacute Leukoencephalopathy. *Cancer*, 35, 306-318 (1975).
- Price, M.R., Edwards, S., Owainati, A., Bullock, J.E., Ferry, B., Robins, R.A. and Baldwin, R.W. Multiple Epitopes on a Human Breast-Carcinoma-Associated Antigen. *Int. J. Cancer*, 36, 567-574 (1985).
- Price, M.R., Crocker, G., Edwards, S., Nagra, I.S., Robins, R.A., Williams, M., Blamey, R.W., Swallow, D.M. and Baldwin, R.W. Identification of a Monoclonal Antibody-defined Breast Carcinoma Antigen in Body Fluids. *Eur. J. Cancer Clin. Oncol.*, 23, 1169-1176 (1987).
- Probert, J.C., Parker, B.R. and Kaplan, H.S. Growth Retardation in Children after Megavoltage Irradiation of the Spine. *Cancer*, 32, 634-639 (1973).
- Rabow, L., and Kristensson, K. Changes in Lactate Dehydrogenase Isoenzyme Patterns in Patients with Tumours of the Central Nervous System? *Acta. Neurochir. (Wien)*, 36, 71-81 (1977).

Redman, B.G., Tapazoglou, E. and Al-Sarraf, M. Meningeal Carcinomatosis in Head and Neck Cancer: Report of Six Cases and Review of the Literature. *Cancer*, 58, 2656-2661 (1986).

Rehn, E. Uber echte und falsche Strangdegenerationen bei Sekundarer Karzinomatose der Ruckenmarkshaute. *Vichows Archiv. fur Pathologische Anatomie*, 186, 307-319 (1906).

Reiber, H., Jacobi, C. and Felgenhauer, K. Sensitive Quantitation of Carcinoembryonic Antigen in Cerebrospinal Fluid and Its Barrier-Dependent Differentiation. *Clin. Chim. Acta.*, 156, 259-270 (1986).

Richards, P.G. and Towu-Aghantse, E. Dangers of Lumbar Puncture. *Br. Med. J.*, 292, 605-606 (1986).

Rieselbach, R.E., Di Chiro, G., Freireich, E.J. and Rall, D.P. Subarachnoid Distribution of Drugs After Lumbar Injection. *New Engl. J. Med.*, 267, 1273-1278 (1962).

Rogoff, E.E., Deck, M.D.F. and D'Angio, G. The Second Sac: A Complicating Factor in Regimens Based on Intrathecal Medications. *Am. J. Roentgenol. Radium Ther. Nucl. Med.* 120, 568-572, (1974).

Rorke, L.B. The Cerebellar Medulloblastoma and its Relationship to Primitive Neuroectodermal Tumour. *J. Neuropath. Exp. Neurol.*, 42, 1-15 (1983).

Sackmann-Muriel, F., Schere, D., Barengols, A., Eppinger-Helft, M., Braier, J.L., Pavlovsky, S., Macchi, G.H. and Guman, J. Remission Maintenance Therapy for Meningeal Leukaemia: Intrathecal Methotrexate and Dexamethasone Versus Intrathecal Craniospinal Irradiation with a Radiocolloid. *Br. J. Haematol.*, 33, 119-127 (1976).

Saenger, A. Uber Hirnsymptome bei Carcinomatose. *Munchener Medizinische Wochenschrift*, 47, 341-342 (1900).

Salazar, O.M. Primary Malignant Astrocytomas in Children: A Signal for Postoperative Craniospinal Irradiation. *Int. J. Radiat. Oncol. Biol. Phys.*, 7, 1661-1665 (1981).

Salazar, O.M., Castro-Vita, H., Van Houtie, P., Rubin, P. and Aygun, C. Improved Survival in Cases of Intracranial Ependymoma After Radiation Therapy: Late Report and Recommendations. *J. Neurosurg.*, 59, 652-659 (1983).

Sands, H. Radioimmunoconjugates: An Overview of Problems and Promises. *Antibody, Immunoconjugates, and Radiopharmaceuticals*, 1, 213-226 (1988).

Sands, H., Jones, P.L., Shah, S.A., Palme, D., Vessella, R.L. and Gallagher, B.M. Correlation of Vascular Permeability and Blood Flow with Monoclonal Antibody Uptake by Human Clouser and Renal Cell Xenografts. *Cancer Res.*, 48, 188-193 (1988).

- Sato, Y., Mizoguchi, K., Fujito, H., Ohta, Y. and Kaji, M. Meningeal Involvement of Myeloma. *Kurume Med. J.*, 32, 109-113 (1985).
- Sayk, J. and Olischer, R.M. Fortschritte Der Liquorzytologie Bei Der Diagnostik Bosartiger Hirngeschwulste (3. Mitteilung). *Psychiatr. Neurol. Med. Psychol. (Leipz)*, 19, 88-89 (1967).
- Schabet, M., Kloeter, I., Adam, T., Heidemann, E. and Wietholter, H. Diagnosis and Treatment of Meningeal Carcinomatosis in Ten Patients with Breast Cancer. *Eur. Neurol.*, 25, 403-411 (1986).
- Schipper, H.I., Bardosi, A., Jacobi, C. and Felgenhauer, K. Meningeal Carcinomatosis: Origin of local IgG production in the CSF. *Neurology*, 38, 413-416 (1988).
- Schold, S.C., Fleisher, M., Schwartz, M. and Posner, J.B. CSF Biochemical "Markers" of CNS Metastasis. *Trans. Am. Neurol. Assoc.*, 103, 179-181 (1978).
- Schold, S.C., Wasserstrom, W.R., Fleisher, M., Schwartz, M.K. and Posner, J.B. Cerebrospinal Fluid Biochemical Markers of Central Nervous System Metastases. *Ann. Neurol.*, 8, 597-604 (1980).
- Schroff, R.W., Foon, K.A., Beatty, S.M., Oldham, R.K. and Morgan, A.C. Human Anti-Murine Immunoglobulin Responses in Patients Receiving Monoclonal Antibody Therapy. *Cancer Res.*, 45, 879-885 (1985).
- Schuepbach, J., Kalyanaraman, V.S., Sarngadharan, M.G., Blattner, W.A. and Gallo, R.C. Antibodies Against Three Purified Proteins of the Human Type C Retrovirus, Human T-Cell Leukemia-Lymphoma Virus, in Adult T-Cell Leukemia-Lymphoma Patients and Healthy Blacks from the Caribbean. *Cancer Res.*, 43, 886-891 (1983).
- Sculier, J.P. Treatment of Meningeal Carcinomatosis. *Cancer Treat. Rev.*, 12, 95-104 (1985).
- Sears, H.F., Herlyn, D., Steplewski, Z. and Koprowski, H. Phase II Clinical Trial of a Murine Monoclonal Antibody Cytotoxic for Gastrointestinal Adenocarcinoma. *Cancer Res.*, 45, 5910-5913 (1985).
- Seeldrayers, P. and Hildebrand, J. Treatment of Neoplastic Meningitis. *Eur. J. Cancer Clin. Oncol.*, 20, 449-456 (1984).
- Seldenfeld, J. and Marton, L.J. Biochemical Markers of Central Nervous System Tumors Measured in Cerebrospinal Fluid and Their Potential Use in Diagnosis and Patient Management: A Review. *J. Natl. Cancer Inst.*, 63, 919-931 (1979).
- Shapiro, W.R., Chernik, N.L. and Posner, J.B. Necrotizing Encephalopathy Following Intraventricular Instillation of Methotrexate. *Arch. Neurol.*, 28, 96-102 (1973).
- Shapiro, W.R., Young, D.F. and Mehta, B.M. Methotrexate: Distribution in Cerebrospinal Fluid After Intravenous, Ventricular and Lumbar Injections. *N. Engl. J. Med.*, 293, 161-166 (1975).

Shapiro, W.R., Posner, J.B., Ushio, Y., Chernik, N.L. and Young, D.F. Treatment of Meningeal Neoplasms. *Cancer Treat. Rep.*, 61, 733-743 (1977).

Shawler, D.L., Batholomew, R.M., Smith, L.M. and Dillman, R.O. Human Immune Response to Multiple Injections of Murine Monoclonal IgG. *J. Immuno.*, 135, 1530-1535 (1985).

Sheline, G.E. Radiation Therapy of Tumours of the Central Nervous System in Childhood. *Cancer*, 35, 957-964 (1975).

Sherwin, A.L., LeBlanc, E.E. and McCann, W.P. Altered LDH Isoenzymes in Brain Tumours. *Arch. Neurol.*, 18, 311-315 (1968).

Shimizu, K., Ushio, Y., Hayakawa, T. and Mogami, H. Combination Chemotherapy with 1-(4-Amino-2-Methyl-5-Pyrimidinyl)Methyl-3-(2-Chloroethyl)-3-Nitrosourea Hydrochloride and Bleomycin in Meningeal Carcinomatosis in Rats. *Cancer Res.* 40, 1341-1343 (1980).

Shimizu, K., Okamoto, Y., Miyao, Y., Yamada, M., Ushio, Y., Hayakawa, T., Ikeda, H. and Mogami, H. Adoptive Immunotherapy of Human Meningeal Gliomatosis and Carcinomatosis with LAK Cells and Recombinant Interleukin-2. *J. Neurosurg.*, 66, 519-521 (1987).

Shimizu, M. and Yamauchi, K. Isolation and Characterization of Mucin-like Glycoprotein in Human Milk Fat Globule Membrane. *J. Biochem. (Tokyo)*, 91, 515-524 (1982).

Shuttleworth, E. and Allen, N. Early Differentiation of Chronic Meningitis by Enzyme Assay. *Neurology*, 18, 534-542 (1968).

Shuttleworth, E. and Allen, N. CSF Beta-Glucuronidase Assay in the Diagnosis of Neoplastic Meningitis. *Arch. Neurol.*, 37, 684-687 (1980).

Siefert, E. Uber die Multiple Karzinomatose des Zentralnervensystems. *Munchener Medizinische Wochenschrift*, 49, 826-828 (1902).

Siegal, T., Mildwolf, B., Stein, D. and Melamed, E. Leptomeningeal Metastases: Reduction in Regional Cerebral Blood Flow and Cognitive Impairment. *Ann. Neurol.* 17, 100-102 (1985).

Siegal, T., Sandbank, U., Gabizon, A., Siegal, T., Mizrachi, R. Ben-David, E and Catane, R. Alteration of Blood-Brain-CSF Barrier in Experimental Meningeal Carcinomatosis: A Morphologic and Adriamycin-Penetration Study. *J. Neuro-Oncol.* 4, 233-242 (1987).

Smith, P.H.S., Thomas, P.R.O., Steere, H.A., Beatty, H.E., Dawson, K.B. and Peckham, M.J. Therapeutic Irradiation of the Central Nervous System Using Intrathecal Y-90-DTPA. *Br. J. Radiol.*, 49, 141-147 (1976).

Snitzer, L.S., McKinney, E.C., Tejada, F., Sigel, M.M., Rosomoff, H.L. and Zubrod, C.G. Cerebral metastases and carcinoembryonic antigen in CSF. *N. Engl. J. Med.*, 293, 1101 (letter) (1975).

Snyder, W.S., Ford, M.R. and Warner, G.G. Estimates of Specific Absorbed Dose Fractions for Photon Sources Uniformly Absorbed in Various Organise of a Heterogeneous Phantom. In: Medical Internal Radiation Dose (MIRD), Pamphlet No. 5 revised (Society of Nuclear Medicine, New York), 5-67.

Soffer, D., Kaplan, H. and Weshler, Z. Meningeal Carcinomatosis due to Basal Cell Carcinoma. Hum. Pathol. 16, 530-532 (1985).

Sozzi, G., Marotta P. and Piatti, L. Vagoglossopharyngeal neuralgia with syncope in the course of carcinomatous meningitis. Ital. J. Neurol. Sci., 8, 271-276 (1987).

Spiller, W.G. Gliomatosis of the Pia and Metastasis of Glioma. J. Nerve Ment. Dis., 34, 297-302 (1907).

Spriggs, A.I. Malignant Cells in Cerebrospinal Fluid. J. Clin. Path., 7, 122-130 (1954).

Spurr, N.K., Durbin, H., Sheer, D., Parkar, M., Bobrow, L. and Bodmer, W.F. Characterization and Chromosomal Assignment of a Human Cell Surface Antigen Defined by the Monoclonal Antibody AUA1. Int. J. Cancer, 38, 631-636 (1986).

Stam, F.C. Leptomeningeal Carcinosis. Psychiat. Neurol. Neurochir., 63, 2-7 (1960).

Stewart, J.S.W., Hird, V., Snook, D., Sullivan, M., Hooker, G., Courtenay-Luck, N., Sivolapenko, G., Griffiths, M., Myers, M.J., Lambert, H.E., Munro, A.J. and Epenetos, A.A. Intraperitoneal Radioimmunotherapy for Ovarian Cancer: Pharmacokinetics, Toxicity, and Efficacy of I-131 Labeled Monoclonal Antibodies. Int. J. Radiation Oncology Biol. Phys., 16, 405-413 (1989).

Sullivan, M.P., Chen, T., Dymont, P.G., Hvizdala, E. and Steuber, C.P. Equivalence of Intrathecal Chemotherapy and Radiotherapy as Central Nervous System Prophylaxis in Children with Acute Lymphatic Leukemia: A Pediatric Oncology Group Study. Blood, 60, 948-958 (1982).

Sutherland, R., Buchegger, F., Schreyer, M., Vacca, A. and Mach, J.P. Penetration and Binding of Radiolabeled Anti-Carcinoembryonic Antigen Monoclonal Antibodies and their Antigen Binding Fragments in Human Colon Multicellular Tumor Spheroids. Cancer Res., 47, 1627-1633 (1987).

Suzuki, M., Abe, I. and Sato, H. Changes in Drug Delivery (by Blood-Brain Barrier Dysfunction) on Arachnoid Leukemia: Implication for CNS Leukemic Dissemination. Clin. Expl. Metastasis, 1, 163-171 (1983).

Swallow, D.M., Griffiths, B., Bramwell, M., Wiseman, G. and Burchell, J. Detection of the Urinary "PUM" Polymorphism by the Tumour-Binding Monoclonal Antibodies Ca1, Ca2, Ca3, HMFG1 and HMFG2. Dis. Markers., 4, 247-254 (1986).

Sze, G., Abramson, A., Krol, G., Liu, D., Amster, J., Zimmerman, R.D. and Deck, M.D.F. Gadolinium-DTPA in the Evaluation of Intradural Extramedullary Spinal Disease. *AJNR*, 9, 153-163 (1988).

Tallman, R.D., Kimbrough, S.M., O'Brien, J.F., Goellner, J.R. and Yanagihara, T. Assay for Beta-Glucuronidase in Cerebrospinal Fluid: Usefulness for the Detection of Neoplastic Meningitis. *Mayo Clin. Proc.* 60, 293-298 (1985).

Taylor-Papadimitriou, J., Peterson, J.A., Arklie, J., Burchell, J., Ceriani, R.L. and Bodmer, W.F. Monoclonal Antibodies to Epithelium-Specific Components of the Human Milk Fat Globule Membrane: Production and Reaction with Cells in Culture. *Int. J. Cancer*, 28, 17-21 (1981).

Tenhunen, R., Iivanainen, M. and Kovanen, J. Cerebrospinal Fluid Beta-2-Microglobulin in Neurological Disorders. *Acta. Neurol. Scandinav.*, 57, 366-373 (1978).

Theodore, W.H. and Gendelman, S. Meningeal Carcinomatosis. *Arch. Neurol.*, 38, 696-699 (1981).

Thibodeau, L.L., Ariza, A. and Piepmeier, J.M. Primary leptomeningeal sarcomatosis: Case report. *J. Neurosurg.*, 68, 802-805 (1988).

Thomas, L.B., Chirigo, M.A., Humphreys, S.R. and Goldin, A. Pathology of the Spread of L1210 Leukemia in the Central Nervous System of Mice and Effect of Treatment with Cytosan. *J. Natl. Cancer Inst.*, 28, 1355-1368 (1962).

Thomas, L.B., Chirigos, M.A., Humphreys, S.R. and Goldin, A. Development of Meningeal Leukemia (L1210) During Treatment of Subcutaneously Inoculated Mice with Methotrexate. *Cancer.*, 17, 352-360 (1964).

Thomas, L.B. Pathology of Leukemia in the Brain and Meninges: Postmortem Studies of Patients with Acute Leukemia and of Mice Given Inoculations of L1210 Leukemia. *Cancer Res.*, 25, 1555-1571 (1965).

Thomson, D.M.P., Krupet, J. and Freedman, S.O. The Radioimmunoassay of Circulating Carcinoembryonic Antigen of the Human Digestive System. *Proc. Natl. Acad. Sci. (Wash.)*, 64, 161-167 (1969).

Thorpe, P.E., Brown, A.N., Bremner, J.A., Foxwell, B.M. and Stirpe, F. An Immunotoxin Composed of Monoclonal Anti-Thy 1.1 Antibody and a Ribosome-Inactivating Protein from *Saponaria Officinalis*: Potent Antitumour Effects In Vitro and In Vivo. *JNCI*, 75, 151-159 (1985).

Twijnstra, A., Van Zanten, A.P., Nooyen, W.J., Hart, A.A.M. and Ongerboer de Visser, B.W. Cerebrospinal Fluid Beta-2-Microglobulin: A Study in Controls and Patients with Metastatic and Non-Metastatic Neurological Diseases. *Eur. J. Cancer Clin. Oncol.*, 22, 387-391 (1986a).

Twijnstra, A., Van Zanten, A.P., Nooyen, W.J. and Ongerboer de Visser, B.W. Sensitivity and Specificity of Single and Combined Tumour Markers in the Diagnosis of Leptomeningeal Metastasis from Breast Cancer. *J. Neurol. Neurosurg. Psychiat.*, 49, 1246-1250 (1986b).

Twijnstra, A., Nooyen, W.J., Van Zanten, A.P., Hart, A.A.M. and Ongerboer de Visser, B.W. Cerebrospinal Fluid Carcinoembryonic Antigen in Patients with Metastatic and Nonmetastatic Neurological Diseases. *Arch. Neurol.*, 43, 269-272 (1986c).

Twijnstra, A., Van Zanten, A.P., Hart, A.A.M. and Ongerboer de Visser, B.W. Serial Lumbar and Ventricle Cerebrospinal Fluid Lactate Dehydrogenase Activities in Patients with Leptomeningeal Metastases from Solid and Haematological Tumours. *J. Neurol. Neurosurg. Psychiat.*, 50, 313-320 (1987a).

Twijnstra, A., Ongerboer de Visser, B.W. and Van Zanten, A.P. Diagnosis of Leptomeningeal Metastasis. *Clin. Neurol. Neurosurg.*, 89, 79-85 (1987b).

Twijnstra, A., Ongerboer de Visser, B.W., Van Zanten, A.P., Hart, A.A.M. and Nooyen, W.J. Serial Lumbar and Ventricular Cerebrospinal Fluid Biochemical Marker Measurements in Patients with Leptomeningeal Metastases from Solid and Hematological Tumors. *J. Neuro-Oncol.*, 7, 57-63 (1989).

Ushio, Y., Posner, J.B. and Shapiro, W.R. Chemotherapy of Experimental Meningeal Carcinomatosis. *Cancer Res.*, 37, 1232-1237 (1977).

Ushio, Y., Shimizu, K., Aragaki, Y., Arita, N., Hayakawa, T. and Mogami, H. Alteration of Blood-CSF Barrier by Tumor Invasion into the Meninges. *J. Neurosurg.*, 55, 445-449 (1981).

Ushio, Y., Arita, N., Hayakawa, T., Yamada, K., Koh, S., Nagatani, M., Yoshimine, T and Mogami, H. Leptomeningeal Dissemination of Primary Brain Tumors in Children: Clinical and Experimental Studies. *Prog. Exp. Tumor Res.*, 30, 194-205 (1987).

Van Zanten, A.P., Twijnstra, A., Van Benthem, V., Hart, A.A.M and Ongerboer de Visser, B.W. Cerebrospinal fluid Beta-Glucuronidase Activities in Patients with Central Nervous System Metastases. *Clin. Chim. Acta.*, 147, 127-134 (1985).

Van Zanten, A.P., Twijnstra, A., Hart, A.A.M. and Ongerboer de Visser, B.W. Cerebrospinal Fluid Lactate Dehydrogenase Activities in Patients with Central Nervous System Metastases. *Clin. Chim. Acta.*, 161, 259-268 (1986).

Van Zanten, A.P., Twijnstra, A., Ongerboer de Visser, B.W., Hart, A.A.M. and Nooyen, W.J. Tumour Markers in the Cerebrospinal Fluid of Patients with Central Nervous System Metastases from Extracranial Malignancies. *Clin. Chim. Acta.*, 175, 157-166 (1988a).

Van Zanten, A.P., Twijnstra, A. and Ongerboer de Visser, B.W. Routine Investigations of the CSF with Special Reference to Meningeal Malignancy and Infectious Meningitis. *Acta. Neurol. Scand.*, 77, 210-214 (1988b).

Vara-Lopez, R. and Vara-Thorbeck, R. Modification in the Activity of Some Enzymes of the Cerebrospinal Fluid in Patients with Intracranial Tumors. *J. Neurosurg.*, 34, 749-752 (1971).

Vick, W.W., Wikstrand, C.J., Bullard, D.E., Kemshead, J., Coakham, H.B., Schlom, J., Johnston, W.W., Bigner, D.D. and Bigner, S.H. The Use of a Panel of Monoclonal Antibodies in the Evaluation of Cytological Specimens from the Central Nervous System. *Acta. Cytol.*, 31, 815-824 (1987).

Wagner, J.A., Frost, J.K. and Wisotzkey, J. Subarachnoid Neoplasia: Incidence and Problems of Diagnosis. *South Med. J.*, 53, 1503-1508 (1960).

Walshe, F.M.R. A Case of Secondary Carcinomatous Infiltration of the Pia-Arachnoid of the Brain, Presenting Exclusively Ocular Symptoms During Life; Meningitis Carcinomatosa. *Brit. J. Opth. (Lond.)*, 7, 113-123 (1923).

Walt, F. A Medulloblastoma in an Infant with Abnormal Cells in the Cerebrospinal Fluid. *Arch. Dis. Child.*, 14, 84-86 (1939).

Wang, J.J. and Pratt, C.B. Intrathecal Arabinosyl Cytosine in Meningeal Leukemia. *Cancer*, 25, 531-534 (1970).

Wara, W.M., Richards, G.E., Grumbach, M.M., Kaplan, S.L., Sheline, G.E. and Conte, F.A. Hypopituitarism after Irradiation in Children. *Int. J. Radiat. Oncol. Biol. Phys.*, 2, 549-552 (1977).

Wara, W.M., Jenkin, R.D., Evans, A., Ertel, I., Hittle, R., Ortega, J., Wilson, C.B. and Hammond, D. Tumors of the Pineal and Suprasellar Region: Childrens Cancer Study Group Treatment Results 1960-1975: A Report from Childrens Cancer Study Group. *Cancer*, 43, 698-701 (1979).

Ward, B.G., Lowe, D.G. and Shepherd, J.H. Patterns of Expression of a Tumor Associated Antigen, Defined by the Monoclonal Antibody HMFG2, in Human Epithelial Ovarian Carcinoma. Comparison with Expression of the HMFG1, AUA1, and F36/22 Antigens. *Cancer*, 60, 787-793 (1987a).

Ward, B.G., Mather, S.J., Hawkins, L.R., Crowther, M.E., Shepherd, J.H., Granowska, M., Britton, K.E. and Slevin, M.L. Localisation of Radioiodine Conjugated to the Monoclonal Antibody HMFG2 in Human Ovarian Carcinoma: Assessment of Intravenous and Intraperitoneal Routes of Administration. *Cancer Res.*, 47, 4719-4723 (1987b).

Ward, B.G. and Cruickshank, D.J. Circulating Tumour-Associated Antigen Detected by the Monoclonal Antibody HMFG2 in Human Epithelial Ovarian Cancer. *Int. J. Cancer*, 39, 30-33 (1987).

Warnke, R.A., Gatter, K.C., Falini, B., Hildreth, P., Woolston, R.E., Pulford, K., Cordell, J.L., Cohen, B., De Wolf-Peters, C. and Mason, D.Y. Diagnosis of Human Lymphoma with Monoclonal Anti-Leucocyte Antibodies. *N. Engl. J. Med.*, 309, 1275-1281 (1983).

Wasserstrom, W.R., Schwartz, M.K., Fleisher, M. and Posner, J.B. Cerebrospinal Fluid Biochemical Markers in Central Nervous System Tumors: A Review. *Ann. Clin. Lab. Sci.*, 11, 239-251 (1981).

Wasserstrom, W.R., Glass, J.P. and Posner, J.B. Diagnosis and Treatment of Leptomeningeal Metastases from Solid Tumors: Experience with 90 Patients. *Cancer*, 49, 759-772 (1982).

Wechsler, L.R., Gross, R.A. and Miller, D.C. Meningeal gliomatosis with "negative" CSF cytology: The value of GFAP staining. *Neurology (Cleveland)*, 34, 1611-1615 (1984).

Weithman, A., Morrison, G. and Ingram, E.A. Meningeal Metastasis of Squamous-Cell Carcinoma of the Uterine Cervix: Case Report and Review of the Literature. *Diagn. Cytopathol.* 3, 170-172 (1987).

Welch, D.M., Coleman, R.E. and Siegel, B.A. Cisterographic Imaging Patterns: Effects of Partial Extra-Arachnoid Radiopharmaceutical Injection and Postinjection CSF Leakage. *J. Nucl. Med.*, 16, 267-269 (1975).

Whiteside, J.A., Philips, F.S., Dargeon, H.W. and Burchenal, J.H. Intrathecal Amethopterin in Neurological Manifestations of Leukemia. *AMA Arch. Int. Med.*, 101, 279-285 (1958).

Widal, I., Sicard, L. and Ravaut, G.J. A Propos du Cytodiagnostic du Tabes. *Rev. Neurol.*, 6, 289-292 (1903).

Wikstrand, C.J., Grahmann, F.C., McComb, R.D. and Bigner, D.D. Antigenic Heterogeneity of Human Anaplastic Gliomas and Glioma-Derived Cell Lines Defined by Monoclonal Antibodies. *J. Neuropathol. Exp. Neurol.*, 44, 229-241 (1985).

Willis, R.A. *The Spread of Tumours in the Human Body.* (Third edition) London: Butterworth, (1973).

Wolff, L., Zigelboim, J. and Gale, R.P. Paraplegia Following Intrathecal Cytosine Arabinoside. *Cancer*, 43, 83-85 (1979).

Wolk, R.W., Masse, S.R., Conklin, R. and Freireich, E.J. The Incidence of Central Nervous System Leukemia in Adults with Acute Leukemia. *Cancer*, 33, 863-869 (1974).

Woods, J.C., Spriggs, A.I., Harris, H. and McGee, J. O'D. A New Marker for Human Cancer Cells 3. Immunocytochemical Detection of Malignant Cells in Serous Fluids with the Ca1 Antibody. *Lancet*, 2, 512-514 (1982).

Woollam, D.H.M. and Millen, J.W. The Perivascular Spaces of the Mammalian Central Nervous System and Their Relation to the Perineuronal and Subarachnoid Spaces. *J. Anatomy*, 89, 193-200 (1955).

Wroblewski, F., Decker, B. and Wroblewski, R. The Clinical Implications of Spinal-Fluid Lactic Dehydrogenase Activity. *New Engl. J. Med.*, 258, 635-639 (1958).

Yamaizumi, M., Mekada, E., Uchida, T. and Okada, Y. One Molecule of Diphtheria Toxin Fragment A Introduced into a Cell Can Kill the Cell. *Cell*, 15, 245-250 (1978).

Yap, B-S., Yap, H-Y., Fritsche, H.A., Blumenschein, G. and Bodey, G.P. CSF Carcinoembryonic Antigen in Meningeal Carcinomatosis From Breast Cancer. *JAMA*, 244, 1601-1603 (1980).

Yap, H-Y., Yap, B-S., Tashima, C.K., DiStefano, A. and Blumenschein, G.R. Meningeal Carcinomatosis in Breast Cancer. *Cancer*, 42, 283-286 (1978).

Yap, H-Y., Yap, B-S., Rasmussen, S., Levens, M.E., Hortobagyi, G.N. and Blumenschein, G.R. Treatment for Meningeal Carcinomatosis in Breast Cancer. *Cancer*, 49, 219-212 (1982).

Yoshida, M., Miyoshi, I. and Hinuma, Y. Isolation and Characterisation of Retrovirus from Cell Lines of Human Adult T-Cell Leukemia and its Implication in the Disease. *Proc. Natl. Acad. Sci. (USA)*, 79, 2031-2035 (1982).

Yung, W.A., Horten, B.C. and Shapiro, W.R. Meningeal Gliomatosis: A Review of 12 Cases. *Ann. Neurol.*, 8, 605-608 (1980).

Zalutsky, M.R., Knapp, R.C. and Bast, R.C. Influence of Circulating Antigen on Blood Pool Activity of a Radioiodinated Monoclonal Antibody. *Int. J. Radiat. Appl. Instrum. Part B*, 15, 431-437 (1988).

Ziegler, J.L. and Bluming, A.Z. Intrathecal Chemotherapy in Burkitt's Lymphoma. *Br. Med. J.*, 3, 508-512 (1971).

Zimmer, A.M., Rosen, S.T., Spies, S.M., Polovina, M.R., Minna, J.D., Spies, W.C. and Silverstein, E.A. Radioimmunoimaging of Human Small Cell Lung Carcinoma with I-131 Tumor Specific Monoclonal Antibody. *Hybridoma*, 4, 1-11 (1985).

Zovickian, J. and Youle, R.J. Efficacy of Intrathecal Immunotoxin Therapy in an Animal Model of Leptomeningeal Neoplasia. *J. Neurosurg.*, 68, 767-774 (1988).

Zuible, A., Maitland, J., Nandi, A., Clink, H.M. and Powles, R.L. Intrathecal Mitozantrone for Resistant Leukaemia. *Lancet*, 2, 1060 (1985).