

Aus der Augenklinik  
Universitätsklinikum des Saarlandes UKS, Homburg/Saar  
(Direktor: Prof. Dr. Berthold Seitz)

---

**Impact of dextran in organ culture media for  
preservation of DMEK (Descemet Membrane  
Endothelial Keratoplasty) pre-cut tissue**

*Dissertation zur Erlangung des Grades eines Doktors der Medizin*

**der Medizinischen Fakultät**  
der UNIVERSITÄT DES SAARLANDES  
2019

vorgelegt von: **ALAA DIN ABDIN**  
geb. am: 18.10.1984 in Damaskus, Syrien

**Tag der Promotion:** 03.07.2020  
**Dekan:** Prof. Dr. M. D. Menger  
**Berichterstatter:** Prof. B. Seitz  
Prof. C. Meier  
Prof. M. Montenarh

# Outline

- List of Abbreviations .....6
- Declaration.....8
- Abstract in English.....10
- Abstract in German.....11
  
- 1. Background:** .....12
  - 1.1.** History of corneal transplantation.....12
  - 1.2.** Evolution of endothelial keratoplasty.....12
  - 1.3.** Descemet membrane endothelial keratoplasty DMEK .....13
    - 1.3.1. Evolution of DMEK.....13
    - 1.3.2. Advantages.....13
    - 1.3.3. Challenges.....14
    - 1.3.4. Evolution of precut tissue.....14
    - 1.3.5. Indications for DMEK.....15
    - 1.3.6. Preoperative evaluation.....17
    - 1.3.7. DMEK Complications.....17
      - 1.3.7.1. Intraoperative complications.....17
      - 1.3.7.2. Postoperative complications.....18
    - 1.3.8. Role of Optical Coherence Tomography in DMEK.....19
  - 1.4.** Developments in corneal banking.....20
    - 1.4.1. Role of Eye Banking.....20
    - 1.4.2. Tissue evaluation.....20

1.4.3. Graft preservation media.....	21
1.4.3.1. Hypothermic storage.....	21
1.4.3.2. Organ culture storage.....	21
<b>1.5. Purpose of study .....</b>	<b>22</b>
<b>2. Patients and Methods .....</b>	<b>23</b>
<b>2.1. Description of study groups.....</b>	<b>23</b>
<b>2.2. Surgical procedure.....</b>	<b>25</b>
<b>2.3. Postoperative management.....</b>	<b>25</b>
<b>2.4. Main outcome measures.....</b>	<b>26</b>
<b>2.5. Statistics.....</b>	<b>28</b>
<b>3. Results.....</b>	<b>29</b>
<b>3.1. Best corrected visual acuity .....</b>	<b>29</b>
<b>3.2. Central corneal thickness .....</b>	<b>30</b>
<b>3.3. Endothelial cell density .....</b>	<b>31</b>
<b>3.4. Rate of Repeat Keratoplasty .....</b>	<b>32</b>
<b>4. Discussion.....</b>	<b>34</b>
<b>4.1. Function of corneal endothelial cells.....</b>	<b>35</b>
<b>4.2. Graft survival.....</b>	<b>36</b>
<b>5. Conclusions .....</b>	<b>40</b>

<b>6. References</b> .....	41
<b>8. Dank</b> .....	50

## List of Abbreviation

AC	Anterior Chamber
AC-IOL	Anterior Chamber Intraocular Lens
ALK	Anterior Lamellar Keratoplasty
AS-OCT	Anterior Segment Optical Coherence Tomography
BCVA	Best Corrected Visual Acuity
BSS	Balanced Salt Solution
CCT	Central Corneal Thickness [ $\mu\text{m}$ ]
CMV	Cytomegalovirus
DALK	Deep Anterior Lamellar Keratoplasty
DLEK	Deep Lamellar Endothelial Keratoplasty
DM	Descemet Membrane
DMAEK	Descemet Membrane Automated Endothelial Keratoplasty
DMEK	Descemet Membrane Endothelial Keratoplasty
DSAEK	Descemet Stripping Automated Endothelial Keratoplasty
DSEK	Descemet Stripping Endothelial Keratoplasty
EBV	Epstein Barr Virus
ECD	Endothelial Cell Density [ $\text{cells}/\text{mm}^2$ ]
EDM	Endothelium Descemet Membrane Layer
EEBA	European Eye Bank Association
EK	Endothelial Keratoplasty
FECD	Fuchs Endothelial Corneal Dystrophy
HSV-1	Herpes Simplex Virus type-1
ICE	Iridocorneal Endothelial
IOL	Intraocular Lens

IOP	Intraocular Pressure
OCT	Optical Coherence Tomography
PBK	Pseudophakic Bullous Keratopathy
PC-IOL	Posterior Chamber Intraocular Lens
PEX	Pseudoexfoliation
PKP	Penetrating Keratoplasty
PLK	Posterior Lamellar Keratoplasty





## Declaration:

Data, illustrations and text of this dissertation are part of a published article:

**Abdin A, Daas L, Pattmüller M, Suffo S, Langenbacher A, Seitz B. Negative impact of dextran in organ culture media for pre-stripped tissue preservation on DMEK (Descemet membrane endothelial keratoplasty) outcome. *Graefes Arch Clin Exp Ophthalmol* 2018;256:2135-2142.**

## Author contributions

Author Name	Research design	Collected the Data	Contributed data or analysis tools	Performed the analysis	Wrote the paper	Final approval
Abdin A	X	X	X	X	X	X
Daas L			X			X
Pattmüller M	X		X			X
Suffo S	X		X			X
Langenbacher A				X		X
Seitz B	X					X

Author Name	Signature
Abdin A	
Daas L	L. Daas
Pattmüller M	
Suffo S	
Langenbacher A	
Seitz B	B. Seitz



## Performance of the study

<b>Selection of patients</b>	Prof. Dr. med. B. Seitz
<b>Performing of surgeries</b>	Prof. Dr. med. B. Seitz and Dr. med. M. El-Husseiny
<b>Cultivation of DMEK tissue until assessment</b>	Team of LIONS Eye Bank
<b>Follow-up of patients</b>	Team of the Department of Ophthalmology, UKS
<b>Statistics</b>	Prof. A. Langenbacher
<b>Photographs</b>	A. Abdin
<b>Creation of the illustrations</b>	A. Abdin
<b>Writing of the text</b>	A. Abdin

**Note:** This is a retrospective study; after few months of recognizing the different clinical outcomes during follow-up, the idea of this retrospective study came up in our department.

## **Abstract in English:**

### **Impact of dextran in organ culture media for preservation of DMEK (Descemet Membrane Endothelial Keratoplasty) precut tissue**

**Purpose:** To compare the morphological and functional outcomes of Descemet Membrane Endothelial Keratoplasty (DMEK) performed with precut tissue preserved in organ culture medium with dextran to tissue preserved in organ culture medium without dextran.

**Methods:** In this retrospective study, 103 patients underwent DMEK surgery with precut tissue in our Department of Ophthalmology between June 2015 and September 2016. We preserved the precut tissue in an organ culture medium for a maximum period of 48 hours. For group 1 49 tissues were preserved in medium 1 (without dextran), for group 2 54 tissues were preserved in medium 2 (with 6% dextran T-500) after stripping of the donor. The best-corrected visual acuity (BCVA), central corneal thickness (CCT) and endothelial cell density (ECD), measurements were taken at 2 weeks, 6 weeks and 6 months interval after surgery. Repeat keratoplasty rates were also compared.

**Results:** BCVA was statistically significantly better in group 1 at each time point ( $p < 0.05$ ). Group 1 had a significantly lower CCT compared to group 2 at 2 weeks and 6 months after surgery ( $p < 0.05$ ). There was no significant difference in the ECD between donor grafts before surgery, but it was significantly higher in group 1 after 2 and 6 weeks ( $p < 0.05$ ). Repeat keratoplasty rates (i.e. repeat DMEK or subsequent penetrating keratoplasty PKP) were significantly higher in group 2 ( $p < 0.05$ )

**Conclusions:** Patients who underwent DMEK performed with precut tissue preserved in organ culture medium without dextran have better visual acuity, thinner corneas and higher endothelial cell density. The rate of repeat keratoplasty was also significantly lower. These findings show that dextran has an undesirable impact on the preservation of DMEK precut tissue.

## **Abstract in German:**

### **Einfluss von Dextran im Organkulturmedium zur Konservierung vorpräparierter DMEK (Descemet Membrane Endothelial Keratoplasty) Transplantate**

**Ziel:** Ziel der Studie war es, die morphologischen und funktionellen Ergebnisse bei vorpräparierten DMEK-Transplantaten mit und ohne Dextran-Kultur-Medium zu vergleichen.

**Patienten und Methoden:** In dieser retrospektiven Studie wurden die Daten von 103 Patienten ausgewertet, die in unserer Klinik zwischen Juni 2015 und September 2016 eine DMEK mit vorpräpariertem Gewebe bekamen. Das Gewebe wurde nach der kompletten Spenderpräparation bei allen Patienten in einem Gewebekulturmedium für maximal 48 Stunden konserviert. In Gruppe 1 wurden 49 DMEK-Röllchen in Medium 1 (Gewebekulturmedium ohne Dextran) konserviert, und in Gruppe 2 wurden 54 DMEK-Röllchen in Medium II (Gewebekulturmedium mit 6 % Dextran T500) konserviert. Der bestkorrigierte Visus, die zentrale Hornhautdicke im Vorderabschnitt-OCT (VAA-OCT) sowie die Endothelzelldicke (EZD) wurden nach 2 Wochen, nach 6 Wochen und nach 6 Monaten postoperativ untersucht. Die Zahl der Re-Keratoplastiken wurde ebenso verglichen.

**Ergebnisse:** In den Verlaufskontrollen zeigte sich in Gruppe 1 ein statistisch signifikant besserer Visus im Vergleich zu Gruppe 2 ( $p < 0.05$ ) zu allen Untersuchungs-Zeitpunkten. Die mittlere zentrale Hornhaut-Dicke war nach 2 Wochen und nach 6 Monaten postoperativ signifikant niedriger in Gruppe 1 im Vergleich zu Gruppe 2 ( $p < 0.05$ ). Die mittlere EZD der Spender-Transplantaten vor der DMEK war vergleichbar, war aber signifikant höher in Gruppe 1 nach 2 Wochen und nach 6 Wochen. Die Notwendigkeit für eine Re-Keratoplastik (Re-DMEK oder perforierende Re-Keratoplastik) in Gruppe 2 war signifikant höher ( $p < 0.05$ ).

**Schlussfolgerung:** Insgesamt haben die Patienten mit DMEK-Röllchen, die in einem Gewebekulturmedium ohne Dextran konserviert wurden, einen höheren Visus, eine dünnere zentrale Hornhaut und eine höhere Endothelzelldicke. Die Re-Keratoplastik-Rate war auch signifikant niedriger. Damit lässt sich schlussfolgern, dass Dextran einen negativen Einfluss auf die Lagerung der DMEK-Röllchen nach der Präparation hat.

# 1. Background

## 1.1. History of corneal transplantation

The first successful corneal transplant was performed in 1905 by Eduard Konrad Zirm, MD, in Olmütz, which was the real start of the long trip of developing corneal transplantation techniques and research [1]. The penetrating keratoplasty (PKP) has traditionally been the treatment of choice for corneal opacifications [2]. Over the last 20 years, new anterior and posterior lamellar techniques have become available that selectively replace only the diseased layers of the cornea while retaining healthy layers. However, PKP is still the gold standard therapy for several indications [3].

## 1.2. Evolution of endothelial keratoplasty (EK)

Posterior lamellar keratoplasty (PLK), which comprises partial corneal transplantation of the posterior cornea, has developed significantly over the past two decades to become a suitable alternative to PKP in the management of endothelial dysfunction [4].

Tillet performed the first PLK in 1956 [5]. In 1964 and 1980, Polack and Jose Barraquer, respectively, described new endokeratoplasty techniques with some modifications [6]. Dr. Gerrit Melles laid the foundation for modern EK [7]. In 1998, he was the first to suggest that a posterior graft could be placed on recipient stroma without sutures, calling it ‘posterior lamellar keratoplasty’ [8]. A modification of PLK, called deep lamellar endothelial keratoplasty (DLEK), was presented by Terry et al. [9] and involved the use of an artificial anterior chamber (AC) for manual preparation of the donor tissue [10-12]. In 2004, Melles described a new technique called descemetorhexis, which involved removal of the DM and the dysfunctional endothelium from the recipient eye only, leaving the posterior stromal lamella intact [13]. This technique was adopted, modified and popularized by Price et al. as ‘Descemet stripping endothelial keratoplasty’ (DSEK) [14]. DSEK has been considered a reliable surgical PLK technique for a long time, especially in the United States [15, 16].

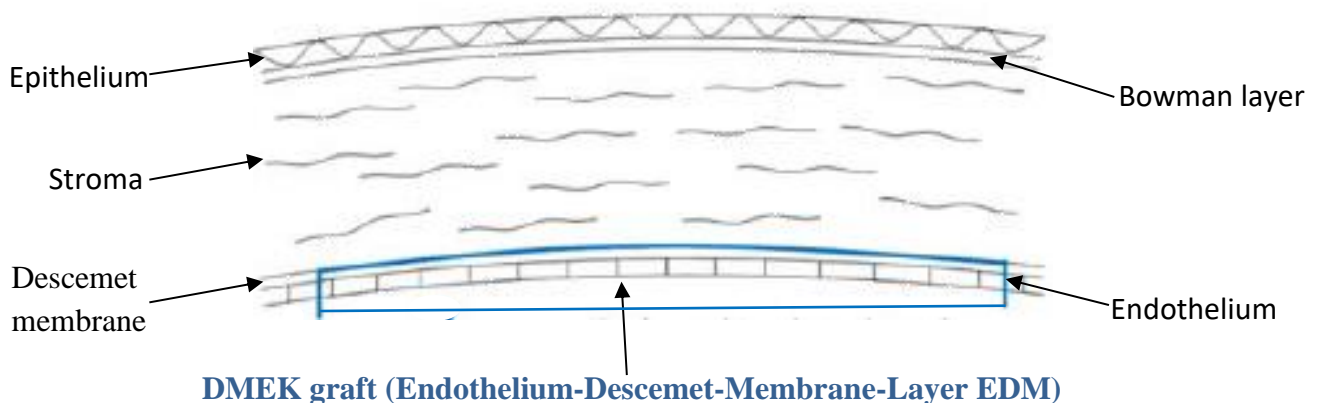
DSEK has demonstrated marked improvements in visual outcomes. However, it is not easy to achieve 20/20 results, which could be due to the haze at the graft-host interface [16]. Another modification of EK, which was also suggested by Melles, is to transplant only donor DM and endothelial cells without stromal tissue. This procedure is referred to as Descemet membrane endothelial keratoplasty (DMEK), which will be the main subject of the present study.

## 1.3. Descemet membrane endothelial keratoplasty

### 1.3.1. Evolution of DMEK

DMEK is a relatively new technique introduced in 2006 by Melles et al. [17]. In this procedure, the transplanted graft includes the thin endothelium-Descemet membrane (EDM) layer only, avoiding any stroma-to-stroma interface in the host cornea [18] (Fig. 1).

Kymionis et al. also described Descemet membrane automated endothelial keratoplasty (DMAEK), which involved the use of an epikeratome for automated lamellar dissection of the tissue similar to DSAEK [19], but this technique is not widely adopted.



**Fig 1. Schematic overview displaying Descemet's membrane endothelial keratoplasty (DMEK)**

Figure is based on a sketch published by: Riau AK, Mehta JS. Current progress in femtosecond laser-assisted endothelial keratoplasty. In: Zhang Y. Femtosecond Lasers. Nova Science Publishers 2013:297-311.

### 1.3.2. Advantages

DMEK provides several advantages over PKP [12, 20-24]:

- Better preservation of ocular integrity by avoiding the period of “open sky”, which exposes ocular content.
- Reduced risk of immunological graft rejection by 15-times compared to PKP; it depends on fewer sutures, which results in less vascularization and reduces the risk of epithelial ingrowth and graft rejection.
- A lower rate of intraoperative complications, including expulsive hemorrhage.

- A lower rate of postoperative complications, including wound dehiscence and astigmatism, which leads to faster and better visual recovery.
- Reduced susceptible risk of rupture from minor postoperative trauma.
- Preservation of the normal corneal innervation, which avoids the problems that arise with epithelial breakdown.

### ***1.3.3. Challenges***

Despite of the advantages of DMEK over PKP, the technique still has some challenges:

- Firstly, the procedure is surgically challenging due to an extended learning curve, increased risk of donor tissue loss during preparation and the relative difficulty of intraocularly manipulating the thin and friable tissue [18-25].
- Secondly, graft attachment is more challenging in DMEK than DSEK, as it requires more often repeated air reinjection (re-bubbling) to ensure complete donor attachment [26].
- DMEK is not the best EK technique in all cases [27]. Examples include:
  - Eyes with a previous pars plana vitrectomy, as the deep AC makes unfolding the donor tissue more difficult.
  - Aphakic eyes or eyes with a large iris defect as in iridocorneal endothelial (ICE) syndrome with severe iris involvement or aniridia, as these eyes do not have a closed AC to prevent tissue loss.
  - Eyes with glaucoma tubes due to the potential inappropriate contact during and after the surgery.
  - Eyes with anterior chamber intraocular lenses (AC-IOLs).
  - Eyes with a previous PKP <8 mm in diameter.

### ***1.3.4. Evolution of precut tissue***

EDM preparation remains a challenge despite recent improvements in instrumentation and surgical techniques. Several technical strategies are available for the preparation of DMEK grafts [28-33], including:

- Free scroll preparation: The graft is completely separated from the stroma.

- Partially peeled with storage on the stroma: The graft is peeled until only a small peripheral hinge of tissue remains (at least 90% of tissue peeled), and then the graft is reapposed to the stroma.
- Fluid bubble separation: Organ culture fluid is injected until separation occurs between the DM and stroma (seen as a small peripheral ‘bubble’), and it is continued until it extends to the trabecular meshwork in all areas.
- Gas bubble separation: Air is injected into the residual donor tissue using a 30-G needle from the endothelial side to detach the DM.

However, high rates of unsuccessful graft preparation with potential loss of donor tissue have been reported, discouraging widespread use of this relatively new technique [18, 26].

Thus, it is important to evaluate the use of precut tissue, which was first described by Bachmann et al. at the Association for Research in Vision and Ophthalmology (ARVO) meeting in 2012, in order to reduce tissue loss and ensure the availability of suitable grafts at the time of surgery, which could also help make the procedure available to surgeons who do not have an eye bank in their department [34]. Accordingly, a recent paper by Godinho et al. reported that preloaded DMEK provides a possible solution for the DMEK challenges and could reduce costs [35].

He et al. confirmed also that preparing DMEK precut tissue with the Muraine technique and shipping away can be used safely by eye banks [36].

Currently, in our department the donor tissue is prepared in the operating room 1 or 2 days before the scheduled DMEK procedure in order to improve both the patient flow and the organization of our schedule in the operating room.

On the other hand, the literature describes some challenges related to the precut tissue technique, such as difficulty of unfolding the graft during surgery due to the tight rolling of the EDM without anatomical stromal support [37].

### ***1.3.5. Indications for DMEK***

Indications for DMEK are endothelial layer diseases leading to stromal edema without stromal scars, some of these indications are listed in table 1:

Table 1. Main indications for DMEK					
Indication	Pathology	Incidence	Clinical findings	Management	
<b>Fuchs endothelial corneal dystrophy</b>	Endothelial cells are larger (polymegathism), pleomorphic, and are disrupted by excrescences of excess collagen → dysfunction of endothelial cells → increased corneal swelling and thickening of the DM [37-38]	Presents in the fifth or sixth decade of life [40]	<ul style="list-style-type: none"> <li>• Cornea guttata</li> <li>• DM folds</li> <li>• Increased endothelial pigmentation</li> <li>• Increased central corneal thickness (CCT)</li> <li>• Microcystic edema (epithelial bullae)</li> <li>• Subepithelial fibrosis [39-41]</li> </ul>	<ul style="list-style-type: none"> <li>• Topical hyperosmotic drops</li> <li>• EK like DMEK</li> <li>• PKP: in cases of anterior corneal scarring [37-41]</li> </ul>	
<b>Pseudophakic bullous keratopathy</b>	A damage of endothelial cells caused by intraocular surgery, especially cataract surgery causes decrease in the endothelial cells density (ECD) → corneal edema progressing towards the intercellular epithelial region with characteristic formation of bullae [42, 43]	Approximately 1-2% of post-cataract surgery patients [44]	<ul style="list-style-type: none"> <li>• DM folds</li> <li>• Increased CCT</li> <li>• Pain</li> <li>• Epithelial bullae or erosions [44, 45]</li> </ul>	<ul style="list-style-type: none"> <li>• Topical hyperosmotic drops or topical corticosteroid drops</li> <li>• EK like DMEK</li> <li>• PKP: in cases of anterior corneal scarring [42-45]</li> </ul>	
<b>Pseudoexfoliation (PEX) with endothelial decompensation</b>	A reduced preoperative ECD of 10.5 to 11.1% has been demonstrated in patients with PEX syndrome undergoing cataract surgery [15, 46, 47]	<ul style="list-style-type: none"> <li>• The prevalence of PEX ranges from 6 to 10%</li> <li>• More in women and increases with age [46]</li> </ul>	<ul style="list-style-type: none"> <li>• DM folds</li> <li>• Increased endothelial pigmentation</li> <li>• Secondary glaucoma</li> <li>• Increased CCT [46, 47]</li> </ul>	<ul style="list-style-type: none"> <li>• Topical hyperosmotic drops</li> <li>• EK like DMEK</li> <li>• PKP: in cases of anterior corneal scarring [47]</li> </ul>	
<b>Endothelitis of viral cause</b>	Many viruses, e.g., Epstein Barr Virus (EBV), Herpes Simplex Virus type-1 (HSV-1), Cytomegalovirus (CMV) and varicella zoster [48-50], can cause endothelitis leading to endothelial dysfunction, which results in corneal edema secondary to endothelial decompensation [51]	<ul style="list-style-type: none"> <li>• Bilateral in 4-6% of patients</li> <li>• Higher incidence in children [51, 52]</li> <li>• More frequent and more severe in females [53]</li> </ul>	<ul style="list-style-type: none"> <li>• DM folds</li> <li>• Increased CCT</li> <li>• Scarring associated with recurrent keratitis [52]</li> </ul>	<ul style="list-style-type: none"> <li>• PKP: in complicated cases [53]</li> <li>• EK like DMEK [55]</li> <li>• Anti-viral medication to reduce the risk of recurrence [56]</li> </ul>	
<b>Endothelial decompensation in congenital glaucoma „Buphthalmus“ [54]</b>					
PEX Pseudoexfoliation, DM Descemet Membrane, ECD Endothelial Cell Density, CCT Central Corneal Thickness, EK Endothelial Keratoplasty, DMEK Descemet Membrane Endothelial Keratoplasty, PKP Penetrating Keratoplasty.					



### ***1.3.6. Preoperative evaluation***

There are some important prerequisites to consider in the preoperative evaluation [57]:

- Recipient's cornea transparency (exclude any stroma scar)
- AC depth: DMEK is safer and easier with a shallow AC and relatively hypotonous (e.g. eyes with high axial myopia can have a deep AC, which is more difficult to modulate)
- Lens status (phakic or pseudophakic and IOL-type)
- Ocular comorbidities that could be considered relative or absolute contraindications
- Patient motivation and capability maintaining optimal postoperative position.

It is very important to provide adequate support to the DMEK graft in the immediate postoperative period to reduce risk of graft separation. This could be provided by the injection of 20% sulfur hexafluoride (SF6) at the end of the operation without forgetting the patient's positioning (supine), which plays an important role. Any gas fill <80% leaves the graft's inferior quadrants incompletely supported when the patient is upright. Therefore, it is important that patients are capable of lying supine immediately after surgery to maximize bubble contact with the entire surface of the DMEK graft. Musculoskeletal disorders of the neck and lower back can limit this position and should be discussed during the preoperative evaluation.

### ***1.3.7. Complications***

#### **1.3.7.1. Intraoperative complications**

Complications that can occur during DMEK include:

- Incomplete removal of the DM and endothelium
- Intraocular hyphema and blood in the interface
- Endothelial cell loss due to excessive manipulation of the donor tissue
- Posterior dislocation of the donor tissue behind the iris or even in the vitreous body
- Disorientation during placement of the donor tissue, leading to placement of the endothelium "upside down" against the host stromal cornea [58].

### **1.3.7.2. Postoperative complications**

- On the first postoperative day, the graft should be well centered without fluid in the interface. Typically, there is a 40-60% air bubble.
- Over a 3- to 4-day period, the air bubble is absorbed and the cornea clear.
- After 6 months, it is difficult to visualize the interface.

#### **Pupillary block:**

Pupillary block may occur due to migration of the air behind the iris, closing the angle. It occurs mostly when the intraoperative air fill is inadequate or if the patient inadvertently leans his/her head forward.

This complication can be avoided with an inferior iridotomy at 6 o'clock [58].

#### **Dislocation of the donor graft:**

One of the most common complications in the first 2 days, particularly after trauma from eye rubbing or a sudden blow, is interface fluid, significant graft displacement or complete graft dislocation into AC.

A partial detachment may reattach spontaneously, whereas large, central or complete detachments are managed by the reinjection of air, which should be performed in the operating room. Graft detachment may require one or more air injections into the AC [58].

#### **Cataract progression:**

The risk of cataract progression in phakic DMEK is high, particularly in patients with narrow ACs. Therefore, the new triple procedure, which combines DMEK with cataract extraction and IOL implantation is highly recommended in patients older than 50 years of age. Clinical studies have not reported any increase in the risk of graft dislocation, endothelial cell loss or other complications in the new triple procedure compared to DMEK [59].

#### **Graft failure:**

Complications common to DMEK include primary or secondary graft failure due to poor-quality donor tissue, unhealthy recipient circumstances (e.g. vessels, infection) or poor surgical experience and technique.

**Corneal graft rejection:**

Immunological graft rejection manifests in DMEK with multiple keratic precipitates scattered across the cornea, whereas the classic endothelial rejection line is not typically seen.

The rejection rate after primary DMEK is 0–6% during the first year. Most rejection episodes are reversible with topical steroids [60]. The lower incidence may be related to the low amount of transferred antigenic tissue and lack of corneal sutures, which reduces the risk of inflammation and secondary vascularization. Thus, signs of inflammation are important risk factors and should be controlled well before and after surgery [20, 60-62].

**Endothelial cell loss:**

Clinical studies have reported a greater endothelial cell loss of about one third in DMEK compared to PKP during the early postoperative phase, which could be due to the high amount of manipulation required during the preparation, orientation and unfolding of the graft within the AC, and the primary injection of air or SF<sub>6</sub>-Gas to facilitate graft adherence or re-bubbling to treat dislocated grafts [63].

**Other complications:**

Some other less common complications that have been reported include retinal detachment and cystoid macular edema [64].

***1.3.8. Role of optical coherence tomography in DMEK***

Reliance on anterior segment optical coherence tomography (AS-OCT) for EK management is becoming more commonplace.

As DMEK grafts are so thin, their visualization with a slit lamp, especially through an edematous host cornea, is often difficult. Therefore, preoperative and postoperative evaluation and management of DMEK grafts is more dependent on AS-OCT imaging as it provides a qualitative and quantitative method of examining the graft and graft-host interface before and after DMEK. The most common complication after DMEK that can be visualized by AS-OCT is graft-edge folds and detachment, which could be an indication for re-bubbling depending on the size of the detachment.

When imaging endothelial grafts, AS-OCT has the ability to change the imaging axis for formal scans and the capacity to actively scan the entire graft-host interface. The axis of the AS-OCT scan can be rotated 360°, allowing the graft-host junction and possible graft detachments occurring at any axis to be imaged. However, in order to obtain the best reading, the clinician should consider being present for the scan [65].

## **1.4. Developments in corneal banking**

### ***1.4.1. Role of eye banking***

Eye banks play the main role in the preservation and preparation of donor corneas and other ocular tissues for surgical use. In addition, they can sometimes be used for research purposes to develop a fundamental understanding of the human eye and strategies for potential treatment measures [66].

### ***1.4.2. Tissue evaluation***

The morphological and functional status of the cornea tissue, especially the endothelium, is a key factor in the success of keratoplasty and considered an indicator for donor cornea quality. Direct functional tests are not easy; therefore, the cornea is evaluated mostly by morphological parameters. Some essential biological characteristics are required for the graft to be suitable for keratoplasty, such as the absence of an interrupted epithelial layer and stroma opacities, regular endothelium and an ECD  $>2200$  cell/mm<sup>2</sup>.

The tissue should be evaluated by general slit lamp examination of the cornea after in situ excision, combined with specular microscopy and possibly tomographic screening using a clinical optical coherence tomography (OCT) device to reveal potential pathologies in corneal donors before keratoplasty and to avoid post-refractive surgery and surface irregularities caused by keratoconus so the donors can be excluded as candidates for full-thickness corneal transplantation [67-69].

### ***1.4.3. Graft preservation media***

The main target for corneal graft preservation in all types of corneal transplantation is increased storage time for cadaver tissue while maintaining endothelial viability after corneal excision, which is necessary to maintain corneal clarity [70, 71]. Two preservation methods for corneal grafts were introduced in the United States in the 1970s and are currently still applied: hypothermic storage [72, 73] and organ culture preservation [74-76].

#### **1.4.3.1. Hypothermic storage**

Corneas are preserved at 4°C in tissue culture medium supported with antibiotics and dehydrating agents (dextran, chondroitin sulphate) to prevent corneal swelling. The original M-K (McCarey and Kaufman) medium [72,73] has been supplemented with solutions, such as K-sol<sup>®</sup>, Dexsol<sup>®</sup> and Likorol<sup>®</sup>, potentially allowing a 10-day preservation period, which is thought to be the maximum for the M-K medium.

#### **1.4.3.2. Organ culture storage**

Corneas are preserved in organ culture media at 28–37°C. The standard organ culture medium (Medium 1) consists of MEM-Earle's supported with penicillin/streptomycin/amphotericin B, L-glutamine, HEPES buffer and NaHCO<sub>3</sub>. This medium provides a preservation period for 30 days [77]. However, it causes significant corneal swelling up to 1000–1500 µm, which should be reversed with a deswelling period (1-3 days) before transplantation. In this period, the graft is placed in a "transport medium" (Medium 2) consisting of medium 1 with an additional osmotic agent (Dextran T-500, 4-8%), a hydrophilic macromolecule that produces colloid osmotic pressure and reduces corneal thickness by extracting water from the stroma to achieve a corneal graft thickness similar to that of the recipient's cornea at the time of surgery [66, 70].

Hypothermic storage has been accepted by many eye banks worldwide, whereas organ culture is considered in the guidelines of the European Eye Bank Association (EEBA). However, the disadvantages of organ culture are the high costs and need for deswelling before corneal transplantation.

Many clinical reports referred to a potential negative impact of dextran during the deswelling period. In regards to these reports, dextran accumulates in endothelial cells, reaching its peak

on the third day. This accumulation can cause severe morphological and necrotic changes in these cells, which could lead to a remarkable decrease in the ECD [77-79].

This potential negative impact of dextran in organ culture media (with dextran) seems to be important in the context of DMEK. The deswelling period could affect the behavior of the posterior stroma during the stripping of EDM [37]. However, it is still not known, whether clinical outcomes vary based on the type of organ culture medium used to preserve the EDM complex after stripping it from the donor stroma [79].

The first DMEK in our department was done in the year 2012. At that time, it was not clear which medium should be used to preserve precut tissues after preparation. According to the penetrating keratoplasty guidelines, surgeons initially used the transport medium with dextran. After that, clinical DMEK results suggested the potential negative impact of dextran on precut tissue. Thus, surgeons subsequently gradually changed their practice [79].

## **1.5. Study purpose**

This study aimed to detect the potentially undesirable impact of dextran on the preservation of DMEK precut tissue by comparing the functional and morphological outcomes of DMEK performed with precut tissue preserved in organ culture media with and without dextran [79].

## 2. Patients and Methods

### 2.1. Description of study groups

In this *retrospective* study, we reviewed clinical records of 103 patients who underwent DMEK surgery with precut tissue in our Department between June 2015 and September 2016 [79].

All grafts were preserved according to the guidelines of the EEBA in the LIONS Eye Bank Saar-Lor-Lux, Trier/Westpfalz located in our Ophthalmology Department.

Grafts were preserved in an organ culture media without dextran at a temperature of 34-35°C and transferred to a deswelling organ culture medium containing 6% dextran T 500 before EDM preparation. The preservation time (in days) in each medium is described in detail in table 2.

The patients were divided into two groups: group 1 comprised 49 EDM stripped and preserved in Medium 1 (dextran-free organ culture medium) (Biochrom GmbH, Berlin, Germany), whereas group 2 comprised 54 EDM stripped and preserved in Medium 2 (organ culture medium supplemented with 6% Dextran T-500).

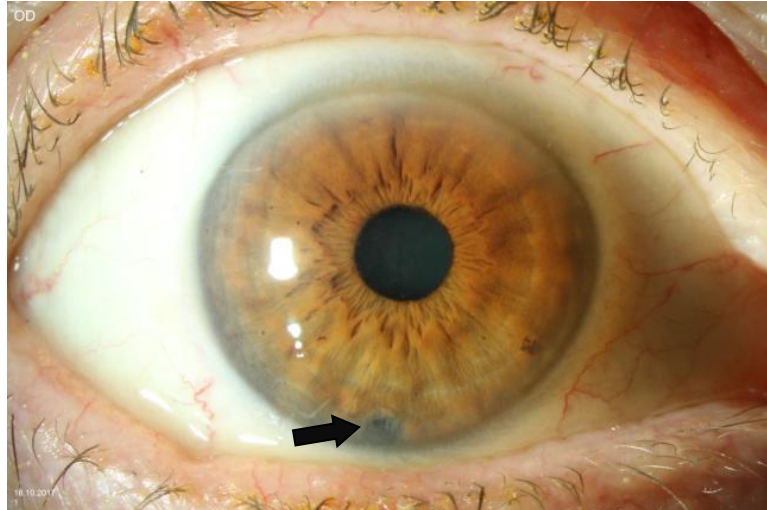
Patients with stromal scars, aphakic eyes, iris atrophy, ICE syndrome or glaucoma tubes were excluded. These comorbidity conditions could make the surgical technique more difficult or affect the functional and morphological outcomes [79]. However, patients with other comorbidities limiting visual acuity were not excluded. In table 3, we listed the number of patients who had other co-morbidities, which were not related to the cornea, in each study group.

All patients were asked to undergo large YAG laser iridotomy at the 6 o'clock position some weeks before surgery to avoid bleeding or pigment dispersion by intraoperative or day-before iridotomy (Fig. 2).

DMEK was performed either sequentially in pseudophakic eyes (if the cataract was the leading pathology) or simultaneously with phacoemulsification and posterior chamber intraocular lens (PC-IOL) implantation (so-called New Triple DMEK). No phakic DMEK was performed.

The following donor details were considered [64]:

- Age: >50 years due to easier unfolding in the AC
- Comorbidities: Diabetic donors were avoided because of the high risk of tearing during donor preparation [80].
- Pseudophakia: Avoided due to the high risk of radial tears near the incisions.



**Fig 2. Patient with large YAG laser iridotomy at the six o'clock position that was done before DMEK surgery. Photo was taken from a patient file in the Department of Ophthalmology, Saarland University Medical Center.**

The patients' baseline characteristics are summarized in table 2.

<b>Table 2. Baseline characteristics of the patients</b>				
<b>Variable</b>	<b>Group 1 (n=49)</b>	<b>Group 2 (n=54)</b>	<b>All patients (n=103)</b>	<b>P-value</b>
Gender (male:female)	51%:49%	48%:52%	50%:50%	0.61
Eye (right:left)	57%:43%	52%:48%	53%:47%	0.94
Mean age at time of surgery (years)	63±15	73±12	70±14	0.01
Preservation time in organ culture: Med 1 /Med 2 (days)	18±10/2±2	14±10/3±1	16±12/2±3	0.32
Donor age (years)	73±10	74±10	74±10	0.56
Postmortem time at retrieval (hours)	10±5	10±6	10±6	0.14
<p><b>The data are given as ratios or mean±SD. Med 1: dextran-free organ culture medium, Med 2: organ culture medium supplemented with 6% dextran T-500. P values refer to statistical differences between group 1 and group 2. P values refer to statistical differences between group 1 and group 2 (nonparametric statistics, Mann-Whitney-U test).</b></p>				



<b>Table 3. Number of patients, who had other ocular co-morbidities</b>				
	<b>Retinal diseases</b>	<b>Amblyopia</b>	<b>Glaucoma</b>	<b>All</b>
<b>Group 1 (n=49)</b>	4	1	2	7
<b>Group 2 (n=54)</b>	9	2	4	15

## **2.2. Surgical procedure**

All surgeries were performed under general anesthesia by two experienced surgeons (Prof. Dr. med. B. Seitz and Dr. med. M. El-Husseiny).

For both groups, the EDM was prepared by the same two surgeons, who had performed the DMEK approximately 48 hours before DMEK.

EDM preparation, preparation of the EDM injection system and DMEK surgery were performed as described in detail by Seitz et al. [18, 79, 81].

## **2.3. Postoperative management**

- After surgery, patients were asked to lie down on their backs for 4 to 5 days.
- The IOP was measured every 2 hours on the first day by applanation tonometry.
- On the fifth day, the patients were typically discharged.
- Treatment at discharge included [79]:
  - Topical hyperosmolar eye drops for 2 weeks
  - Topical antibiotics for 1 week
  - Prednisolone acetate hourly for 1 week and then five times per day, slowly tapering over at least 6 months
  - Lubricants as required.
- The patient was seen again 2 weeks after surgery to remove the two corneoscleral single sutures and was sometimes accommodated for rebubbling if there was any (new) graft dehiscence.
- To avoid any possible complications, after DMEK the surgeon indicated which existing paracentesis should be used for rebubbling, ideally opposite the EDM detachment area to avoid

iatrogenic folding of the graft. Today, we prefer an 90% fill of the AC with 20% SF6 gas because of gas expansion.

- The next outpatient follow-up occurred 6 weeks, 6 months and 1 year postoperatively.

- Postoperative routine diagnostics include:

- Best corrected visual acuity (BCVA)
- Slit lamp examination
- Applanation tonometry
- ECD as measured by EM 3000 (Tomey, Nagoya, Japan)
- AS-OCT (CASIA SS-1000, Tomey, Nagoya, Japan)
- Before discharge and during the outpatient follow-up, a macula OCT was performed to recognize and, if needed, treat cystoid macular edema immediately [82,83].

- The patient was asked to see an ophthalmologist or come to our department immediately if [18]:

- their sight began to worsen (mainly in the morning),
- halos were seen around light sources,
- segmental clouding was seen,
- or the eye turned red or hurts.

Our motto is “**Do not wait three days and hope.**”

## **2.4. Main outcome measures**

Successful DMEK surgery was determined by [84]:

- Best corrected visual acuity (BCVA)

In this study, we tested the best-corrected visual acuity in decimal lines using Snellen test chart. The top number equates to the distance (in 6 meters) at which the test chart was presented. The bottom number identifies the position on the chart of the smallest line read by the 'subject'. E.g. 6/60 (0.1) means the subject can only see the top letter at the test chart when viewed at 6 m.

However, the decimal visual acuity chart is not standard and easy to use for statistical analysis. Therefore and as presented regularly in literature, it requires a transformation into LogMar units [85].

When using the LogMAR chart, visual acuity is scored with reference to the Logarithm of the Minimum Angle of Resolution. A subject who can resolve details as small as 1 minute of visual angle scores LogMAR 0, since the base-10 logarithm of 1 is 0; a subject who can resolve details as small as 2 minutes of visual angle scores LogMAR 0.3, since the base-10 logarithm of 2 is approximately 0.3.

In contrast to the decimal chart, the logarithmic chart has an arithmetic progression and a constant interval between lines. The LogMar chart makes statistical analysis of visual acuity easy. Change in visual acuity is calculated directly by subtracting LogMar data, while the average visual acuity is obtained with the arithmetic mean value of the LogMar data. Finally, the mean acuity expressed in LogMar units can be transformed into a decimal chart for a more comprehensive result.

The formulas for going from decimal to LogMar and back are [85]:

$$\text{LogMAR} = -\text{Log}(\text{Decimal Acuity}) \quad (1)$$

$$\text{Decimal acuity} = \text{antilog}(-\text{LogMar}) = 10^{-\text{LogMAR}} \quad (2)$$

In this study, we used nonparametric statistics for BCVA in LogMAR. Mean decimal VA is reported for VA improvement as supplementary data.

- Endothelial cell density ECD as measured by EM 3000 (Tomey, Nagoya, Japan).

The EM-3000 specular microscope is a noninvasive method to evaluate human endothelial cells in vivo. It captures images depending on the reflection from the optical interface between the endothelium and aqueous humor. It captures automatically 15 images per measurement using an optical magnification of  $\times 190$  and can count up to 300 cells per image within an area of  $0.1 \text{ mm}^2$ . This device includes an inbuilt automatic analysis software, which displays the cell density, mean cell area, coefficient of variation and hexagonality. It can provide quantitative endothelial cell measurements that have been satisfactorily repeatable in clinical studies [86].

- Central corneal thickness CCT as measured by Anterior Segment Optical Coherence Tomography (AS-OCT) (CASIA SS-1000, Tomey, Nagoya, Japan).

AS-OCT is a non-contact high-resolution device. Using low-coherence interferometry, it captures multiple A-scans from a two-dimensional image of the anterior segment. The CCT will be automatically computed using built-in analysis software, which marks the boundaries of the anterior and posterior surface of the cornea. These automated

measurements were used for the comparative analysis. According to the clinical studies, the reliability for the measurement of CCT using AS-OCT was excellent [87].

Comparisons were made 2 weeks, 6 weeks and 6 months after surgery [79].

Repeat keratoplasty rates were also compared (repeat DMEK, subsequent PKP) between the two groups.

The most common indication to repeat keratoplasty (repeat DMEK or subsequent PKP) in the present study is **primary or secondary graft failure**.

Primary graft failure was defined as persistent decompensation or missing clarity within the first four weeks postoperatively [79, 88].

## **2.5. Statistics**

Data were analyzed using SPSS 20.0 for windows (SPSS, Inc., Chicago, IL).

A Kruskal Wallis test was performed to check for normal distribution. A Mann-Whitney-U test (nonparametric statistics) was performed to compare differences between the postoperative outcomes of DMEK performed with pre-cut tissue preserved in organ culture medium with dextran (group 2) and tissue preserved in organ culture medium without dextran (group 1) at specific time-points.

To compare repeat PKP rates a Chi-square test was used. This could not be used to compare repeat DMEK rates because one field was filled with a zero, therefore it was presented descriptively.

Data were presented as mean  $\pm$  standard deviation. P values referred to statistical differences between group 1 and group 2. Results were considered statistically significant if P values were  $< 0.05$ .

### 3. Results

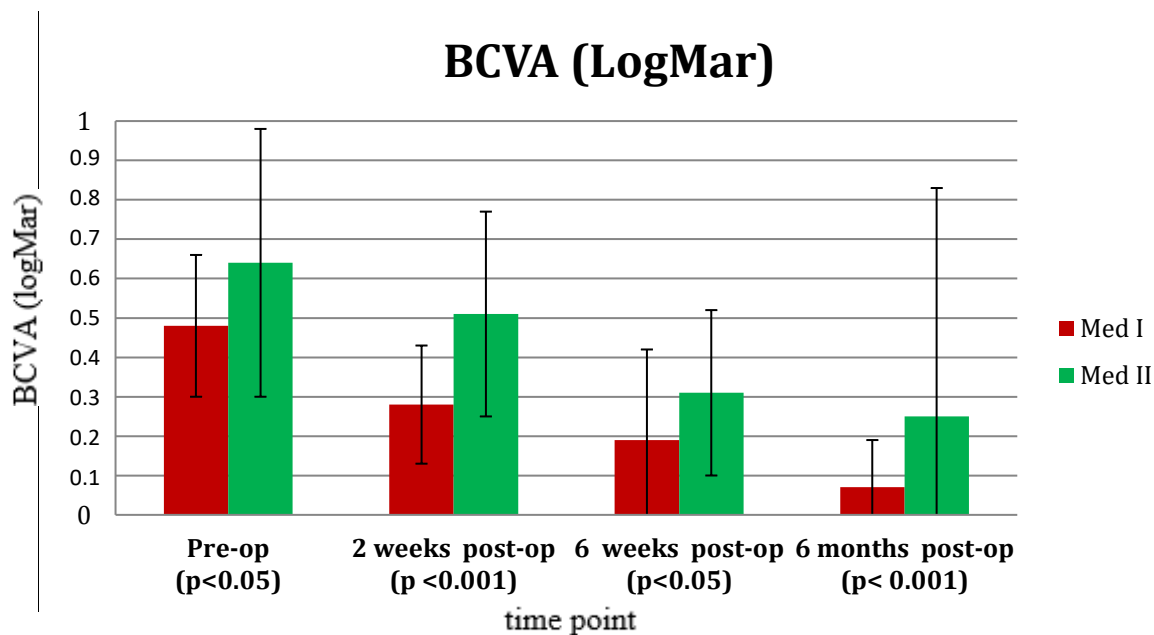
#### 3.1. Best corrected visual acuity (BCVA)

In this part, we try to explore whether BCVA varies based on the type of organ culture medium used to preserve the EDM complex after stripping it from the donor stroma.

For group 1 the postoperative BCVA (logMar) was improved from  $0.48 \pm 0.18$  (one day preoperatively) to  $0.28 \pm 0.15$  after 2 weeks,  $0.19 \pm 0.23$  after 6 weeks and  $0.07 \pm 0.12$  after 6 months. For group 2 BCVA was improved from  $0.64 \pm 0.34$  (one day preoperatively) to  $0.51 \pm 0.26$  after 2 weeks,  $0.31 \pm 0.21$  after 6 weeks and  $0.25 \pm 0.58$  after 6 months (Fig. 3) [79].

For group 1 vs group 2, the preoperative to postoperative visual improvement (Decimal) was  $0.18 \pm 0.22$  vs  $0.03 \pm 0.17$  at 2 weeks ( $p=0.04$ ),  $0.34 \pm 0.24$  vs  $0.15 \pm 0.22$  at 6 weeks ( $p=0.13$ ) and  $0.47 \pm 0.25$  vs  $0.20 \pm 0.18$  at 6 months ( $p<0.001$ ). The percentage of grafts achieving 0.5 or better (Decimal) in group 1 was 96% and in group 2 it was only 66%.

Differences between the groups were statistically significant at each time point ( $p < 0.05$ ) [79].



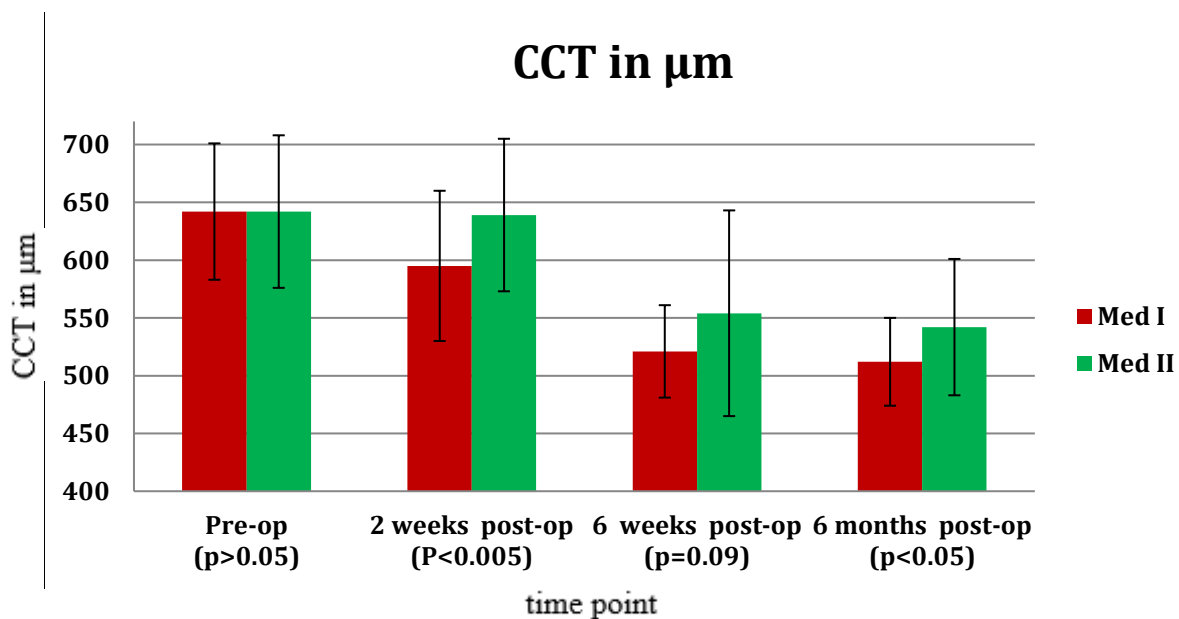
**Fig 3. Best corrected visual acuity (BCVA) in both groups for each time point before and after the surgery. Med 1: dextran-free organ culture medium, Med 2: organ culture medium supplemented with 6% dextran T-500. Results are given as (means  $\pm$  standard deviation), P values refer to statistical differences between group 1 and group 2 (nonparametric statistics, Mann-Whitney-U test).**

BCVA was significantly better when using precut tissue preserved in dextran-free medium (Medium 1) at each time point after surgery.

### 3.2. Central corneal thickness (CCT)

In this part, we explore whether CCT varies based on the type of organ culture medium used to preserve the EDM complex after stripping it from the donor stroma.

For group 1 vs group 2, the CCT was comparable one day before surgery  $642\pm 59$  vs  $642\pm 66$   $\mu\text{m}$  ( $p=0.5$ ) and decreased to  $595\pm 65$  vs  $639\pm 66$   $\mu\text{m}$  ( $p=0.002$ ) at 2 weeks,  $521\pm 40$  vs  $554\pm 89$   $\mu\text{m}$  ( $p=0.09$ ) at 6 weeks and  $512\pm 38$  vs  $542\pm 59$   $\mu\text{m}$  ( $p=0.04$ ) at 6 months (Fig. 4) [79].



**Fig 4.** Central corneal thickness (CCT) in both groups for each time point before and after the surgery. Med 1: dextran-free organ culture medium, Med 2: organ culture medium supplemented with 6% dextran T-500. Results are given as (means  $\pm$  standard deviation), P values refer to statistical differences between group 1 and group 2 (nonparametric statistics, Mann-Whitney-U test).

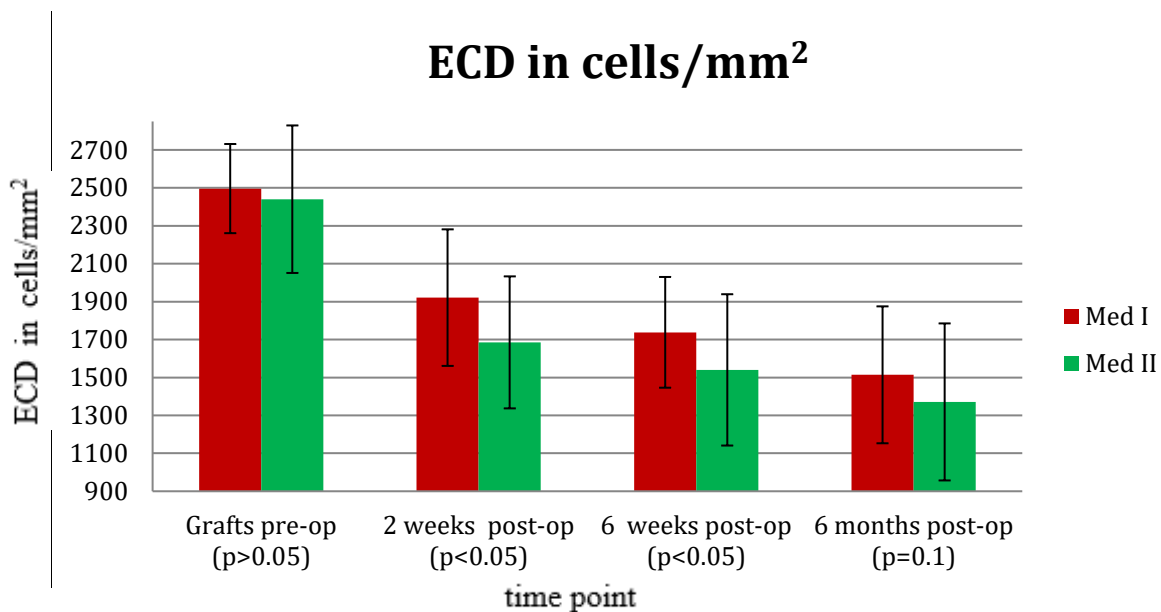
Precut tissue for DMEK preserved in dextran-free medium (Medium 1) resulted in significantly thinner corneas for 2 weeks and 6 months after surgery.

### 3.3. Endothelial cells density (ECD)

In this part, we explore whether ECD varies based on the type of organ culture medium used to preserve the EDM complex after stripping it from the donor stroma.

The ECD was comparable between the donor grafts one day before surgery  $2496 \pm 235$  vs  $2440 \pm 389$  cells/mm<sup>2</sup> ( $p > 0.05$ ).

However, the ECD was significantly different between groups 1 and 2 after 2 weeks  $1921 \pm 360$  vs  $1685 \pm 348$  cells/mm<sup>2</sup> ( $p = 0.01$ ) and after 6 weeks  $1738 \pm 292$  vs  $1540 \pm 399$  cells/mm<sup>2</sup> ( $p = 0.04$ ), but not after 6 months  $1514 \pm 361$  vs  $1371 \pm 414$  cells/mm<sup>2</sup> ( $p = 0.1$ ) (Fig. 5) [79].

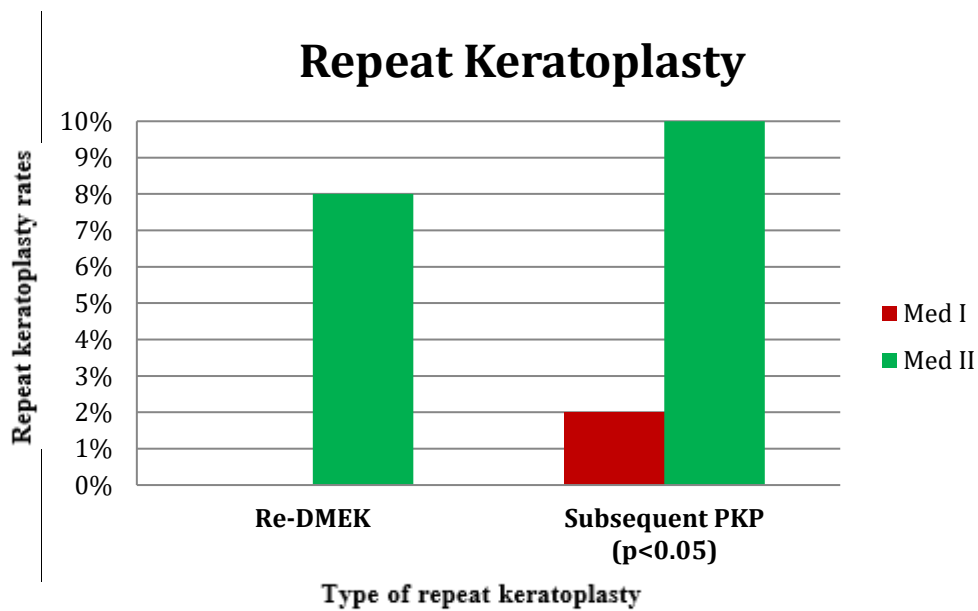


**Fig 5. Endothelial cell density (ECD) in both groups for each time point before and after the surgery. Med 1: dextran-free organ culture medium, Med 2: organ culture medium supplemented with 6% dextran T-500. Results are given as (means  $\pm$  standard deviation), P values refer to statistical differences between group 1 and group 2 (nonparametric statistics, Mann-Whitney-U test).**

Precut tissue for DMEK preserved in dextran-free medium (Medium 1) resulted in significantly higher endothelial cell density for 2 weeks and 6 weeks after surgery.

### **3.4. Rate of repeat keratoplasty**

In this part, we explore whether rates of repeat keratoplasty vary based on the type of organ culture medium used to preserve the EDM complex after stripping it from the donor stroma. A clinically significant difference between the two groups was noticed regarding the repeat keratoplasty rates. Repeat DMEK was necessary in 0% in group 1 vs. 8% in group 2 and subsequent PKP was necessary in 2% in group 1 vs. 10% in group 2 ( $p < 0.05$ ) (Fig. 6) [79].



**Fig 6. Type of repeat keratoplasty rates in both group. Med 1: dextran-free organ culture medium, Med 2: organ culture medium supplemented with 6% dextran T-500. P values refer to statistical differences between group 1 and group 2 (Chi-square test).**

Negligible rates of repeat keratoplasty were detected when using pre-cut tissue preserved in dextran-free medium (Medium 1).

The stripping time was  $11 \pm 4$  and  $16 \pm 4$  minutes for groups 1 and 2, respectively ( $p < 0.05$ ).

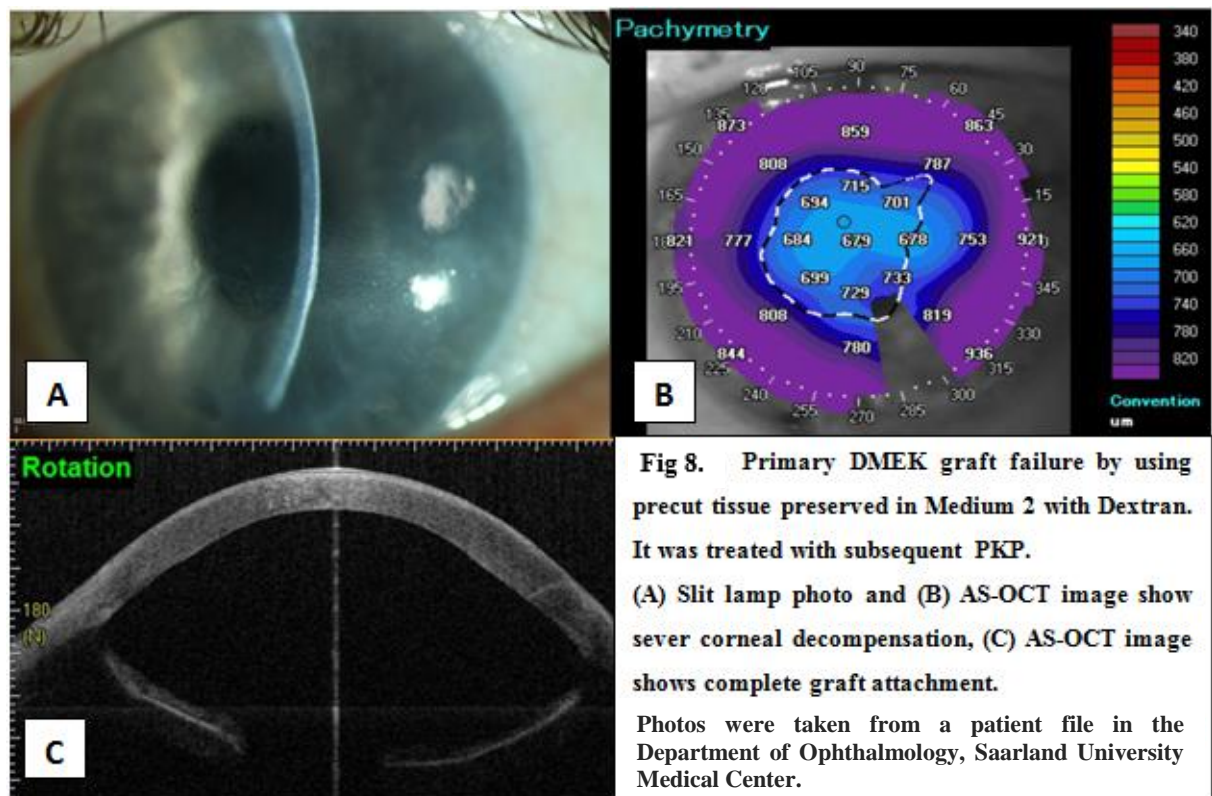
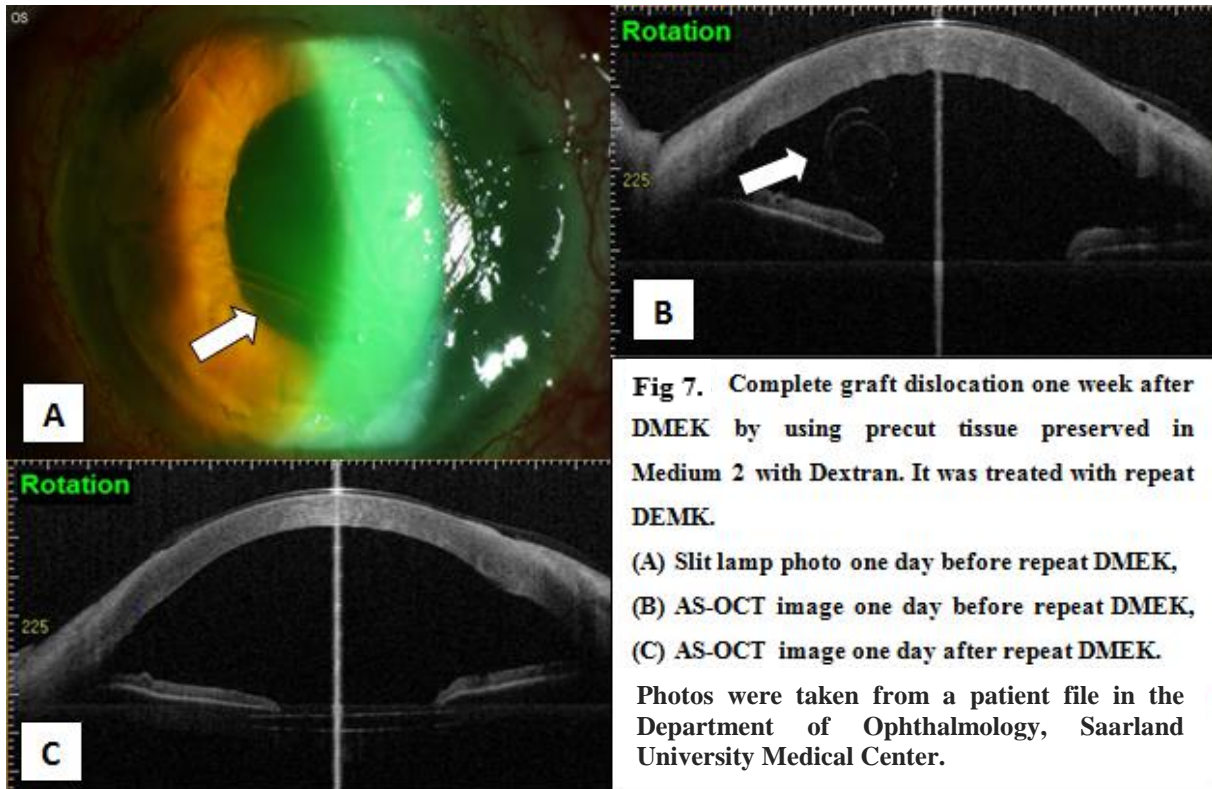
The unfolding time was  $5 \pm 8$  and  $5 \pm 5$  minutes in groups 1 and 2, respectively ( $p > 0.05$ ).

#### **Complications after Surgery:**

In our study, 58% needed re-bubbling due to partial graft detachment in group 1 and 44% needed re-bubbling due to partial graft detachment in group 2 during the first half year of follow-up ( $P = 0.3$ ). 2 patients underwent repeat DMEK for total graft detachment in group 2 (Fig. 7) and no total graft detachment was reported in group 1. 8 patients underwent repeat keratoplasty for failure of graft clarity in group 2 (Fig. 8). Decompensated glaucoma was



evident in two cases in group 2 but none in group 1. No retinal detachment occurred in both groups. In the present study, there were no immunological rejection episodes documented [79].



## 4. Discussion

The potential differences between both types of organ culture media (with or without dextran) seem to be important in the context of lamellar surgery, especially DMEK. Separation of the EDM is influenced by the biomechanical properties of the cornea, and swelling and deswelling also obviously affect the behavior of the posterior stroma during EDM preparation. However, whether clinical outcomes vary based on the type of organ culture medium used to preserve the EDM complex after stripping it from the donor stroma is not known.

In order to answer this question, we compared the functional outcome (BCVA) after DMEK using precut tissue stored in organ culture medium with or without dextran. The BCVA was better when using precut tissue preserved in dextran-free medium (Medium 1) at each follow-up after surgery. BCVA was worse for group 2 preoperatively. However, it has to be taken into consideration that we did not exclude patients with co-morbidities that might affect visual acuity. Therefore, it is possible that factors not related to the cornea were responsible for the difference in BCVA. In table 3, we listed these potential factors. Furthermore, the preoperative to postoperative visual improvement value was statistically significantly better for group 1 at 2 weeks and 6 months postoperatively. In addition, the percentage of grafts achieving 0.5 or better after 6 months was significantly ( $P < 0.001$ ) greater in group 1 (96%) than in group 2 (66%) [79].

Unlike PKP, for which functional results depend on all layers of the corneal graft, endothelial cell function is the sole determinant of success in DMEK. On the other hand, one of the advantages of DMEK over PKP is the fast postoperative restoration of the CCT to its normal range. Moreover, thinner postoperative corneas provide more rapid improvements in postoperative outcome after DMEK surgery [89,90]. Therefore, we also investigated how dextran affects the ECD and CCT as measures of the viability and function of corneal endothelial cells. The results showed thinner corneas and higher endothelial cell counts when precut tissue was preserved for a maximum of 2 days in medium without dextran.

One of the major findings of this study was the observation of a negligible rate of repeat keratoplasties after DMEK using precut tissue preserved in medium without dextran [79].

## **4.1. Function of corneal endothelial cells**

Endothelial cell damage could be considered as a major challenge for all PLK surgeries. For this reason and in order to ensure long-term graft survival, an ECD > 2200 cells/mm<sup>2</sup> at the time of transplantation has been commonly recommended [91].

According to the amount of manipulation required during the preparation and the unfolding of the DMEK graft, clinical studies reported a greater ECD loss within the first few days after DMEK compared to PKP [63].

The postoperative endothelial cell loss could be affected by many factors such as surgical technique, donor characteristics (including donor age and graft rolewidth), graft unfolding time, endothelial cell migration after surgery, contact with dextran in the deswelling process and intraoperative trauma [78-79, 92-98].

The **unfolding time** could be affected by donor age. The younger the graft, the longer is the unfolding time and the higher the potential endothelial cell loss [78].

The greater endothelial cell loss in grafts smaller than the descemetorhexis could be explained with the **migration of transplanted endothelial cells** after DMEK towards the gap surrounding the graft peripherally [79, 92]. On the other hand, a recent study did not find any significant association between postoperative central ECD and DMEK graft diameter especially in healthy peripheral host endothelium such as in Fuchs Dystrophy[93].

**EDM stripping** during preparation cause an immediate endothelial cell loss, which can be detected using a specular microscope. This loss could be focal or linear according to the forceps manipulation and tissue stretching during preparation [94-96].

Many clinical studies reported remarkable decrease in the ECD during the **storage period** and **deswelling process** [97-99]. The major CCT decline could be achieved within the first 24 hours of deswelling [91]. Afterwards, dextran accumulates in endothelial cells, reaching its peak on the third day. This accumulation can cause severe morphological changes in these cells [78, 100] such as multiple endothelial necrosis, intracytoplasmic vacuoles, granules, deposits on the endothelial surface and widening of the intercellular spaces [101]. Therefore, most studies have recommended a deswelling period of less than 24 to 30 hours before penetrating keratoplasty [79, 91, 102].

The extent of deswelling could depend on the dextran concentration, varying from 4–8% in the different eye banks [91]. However, Van der Want et al. reported a remarkable decrease in the

ECD in a medium containing 8% dextran T 500 [97]. Other studies demonstrated also a similar decrease in the ECD in culture medium containing 5% dextran T 500 [90, 91]. These results may indicate that the negative impact of dextran on ECD might not depend mainly on the dextran concentration in the range between 4% und 8%.

The accumulation of dextran in endothelial cells makes the EDM stickier and more difficult to unfold in the AC. This might cause more endothelial cell damage and a reduced attachment rate resulting from the intensive iatrogenic manipulations during the unfolding process [37]. However, the comparable unfolding time ( $5\pm 8$  vs  $5\pm 5$  minutes) in our study does not support this theoretical consideration [79].

According to the old guidelines in Germany from 2014 [103], all corneal grafts were placed in a transport medium (Medium 2) for a deswelling process prior to preparation. This meant that DMEK grafts had also to be prepared from deswollen corneas. These recommendations have been changed in the revised edition of the German Medical Association guidelines in 2018 [89, 104]. This edition confirmed that the use of a transport medium is no more mandatory for preparation of donor tissue for posterior lamellar keratoplasty. Results from Freiburg [37] and Homburg [79] had a major impact on the change of the regulation in the German Medical Association guidelines.

In the present study, all these relevant factors (donor age, ECD of grafts before surgery, surgical technique and time of the deswelling process) were comparable between our two groups. However, ECDs were lower and CCTs were higher in group 2 postoperatively, meaning that the preservation of precut tissue after preparation in Medium 2 (which contained dextran) for an extra 48 hours might be considered as an unfavorable long contact with dextran and probably affected the morphological and functional features [79].

## **4.2. Graft survival**

The common situations which can lead to repeat keratoplasty (repeat DMEK, subsequent PKP) after DMEK are corneal graft rejection, complete dislocation of the donor graft or graft failure [58, 79, 105].

During the first year, the rejection rate after primary DMEK is around 0–6% [60,106]. In the present study, there were no rejection episodes documented.

Generally, the dislocation could be seen due to a lack of adherence of the graft to the recipient posterior stroma. It may be the most frequent complication in EK.

Until now, the mechanism of attachment of EDM grafts to the host stroma has been unclear. Factors providing attachment could depend on properties of either the host stroma or the EDM graft.

In this study, we assumed that the quality of the grafted EDM was affected by the longer exposure to dextran, which affects graft adhesion and graft survival. The anterior stromal face of the DM contains various extracellular matrix proteins with adhesive properties, such as fibronectin, vitronectin and amyloid P, as well as proteoglycans such as dermatan, keratan, heparan and chondroitin sulfate proteoglycans [107-110].

Although the influence of culture media on the biochemical composition of the DM is not currently known, a previous study provided evidence that organ culture with dextran alters the distribution of stromal proteoglycans, resulting in the formation of collagen-free lakes containing high levels of proteoglycans in the corneal stroma [95].

Furthermore, some distinct histological changes, especially in the posterior stroma, have been detected after using organ culture. The posterior stroma exhibits an increased number of vacuoles and enlarged spaces between collagen fibers [111].

All of these structural alterations on the biochemical level could play an important role in the adhesive properties of EDM complexes towards the host posterior stroma.

The results of our study may refer to a negative input of a long dextran contact time on these structural alterations leading to reduce adhesive properties of EDM complexes towards the host posterior stroma, which may have led to the higher rate of repeat keratoplasty in group 2.

On the other hand, the rate of graft failure after DMEK in general is around 1.6% - 8% [112].

Primary graft failure was defined as persistent decompensation or missing clarity within the first four weeks postoperatively [79, 88].

Relating to this point, Schmidt et al. discussed the ultrastructural changes in the DM in eyes with graft failure after DMEK. These changes included intrinsic abnormal inclusions in the DM and posterior collagen deposits of the membrane [113]. All of these abnormal changes might be considered as an indication and signs for peri- and postoperative endothelial dysfunction

[114]. However, this study also demonstrated that upside down attachment of the graft might be another major reason for major primary graft failure [113].

Heinzelmann et al. reported that the storage in dextran was as a risk factor for these ultrastructural changes that could lead to primary graft failure after DMEK, especially in precut tissues [37]. Furthermore, the higher rate of repeat keratoplasty after DMEK in group 2 of the present study can also support the consideration that dextran in precut tissue had a negative impact on graft survival and should be avoided [79].

Our data were also supported by a report from Salla et al., which assessed the quality and quantity of corneal endothelial cells in DMEK grafts preserved in organ culture medium with dextran compared to grafts preserved in organ culture medium without dextran [115]. They found significantly higher ECD, lower endothelial cell loss and lower ATP/protein ratios in corneas stored in medium without dextran after 24 and 72 hours of preservation. These results suggest that preservation of DMEK precut tissue in Medium 2 with dextran is not required and should be discouraged [115].

Rickmann et al. reported the clinical outcome for 22 patients after DMEK with precut tissue that was stored in dextran-containing medium [116]. The BCVA was evaluated using Snellen visual acuity chart and presented as LogMar. By comparing the clinical outcomes of this study with the clinical outcomes of our study, we found better mean BCVA, lower mean CCT and higher mean ECD after 6 months for group 1 in our study (storage in dextran-free medium) (table 4).

<b>Study</b>	<b>Medium</b>	<b>Patients</b>	<b>BCVA LogMar</b>	<b>ECD cells/mm<sup>2</sup></b>	<b>CCT μm</b>
<b>Rickmann et al.</b>	with dextran	22	0.2±0.14	1505±260	544±31
<b>Abdin et al.</b>	without dextran	47	0.07±0.12	1514±361	512±38
	with dextran	54	0.2±0.58	1371±414	542±59

This comparison also supports the possible unfavorable effect of dextran on the clinical outcome of DMEK using precut tissue [79].

In contrast to other studies, Parekh et al. evaluated the adhesive and stiffness properties of six DMEK precut tissues using different preservation media [117]. They demonstrated that precut tissues in medium 2 (with dextran) expressed, even after preservation for 4 days, adherent proteins and showed lower stiffness. Moreover, they found an important role for dextran in

preserving ECD before and after preparation of DMEK precut tissue, which suggests that dextran may be suitable for preservation of DMEK grafts before and after preparation [118]. However, Yoeuek et al., who studied 20 corneoscleral rims in organ-culture could not demonstrate any advantages of dextran for the deswelling period in the preparation of DMEK grafts [119].

## **5. Conclusions**

DMEK performed with pre-cut tissue preserved in organ culture medium that does not contain dextran resulted in better visual acuity, thinner corneas and higher endothelial cell density. The rate of repeat keratoplasty was also significantly lower, which might suggest that dextran could have an undesirable impact on the preservation of DMEK pre-cut tissue.

The new regulations of the German Medical Association even allow us to use donor corneas in Medium I without dextran before donor preparation, which might have an additional positive effect on the DMEK graft quality.



## 6. References

1. Zirm E. [A successful total keratoplasty]. *Arch Ophthalmol* 1906;64:580–593.
2. Cassidy D, Sharma N, Vajparyee RB. Evolution of endothelial keratoplasty. New Delhi: Jaypee Highlights Medical Publishers, Inc.; 2013.
3. Seitz B, Szentmary N, Langenbucher A, et al. [PKP for keratoconus – from hand/motor trephine to excimer laser and back to femtosecond laser]. *Klin Monatsbl Augenheilkd* 2016;233:727–736.
4. Zhu L, Zha Y, Cai J, Zhang Y. Descemet stripping automated endothelial keratoplasty versus descemet membrane endothelial keratoplasty: a meta-analysis. *Int Ophthalmol* 2018;38:897–905.
5. Tillett CW. Posterior lamellar keratoplasty. *Am J Ophthalmol* 1956;41:530–533.
6. Polack FM, Smelser GK, Rose J. Long-term survival of isotopically labeled stromal and endothelial cells of corneal homografts. *Am J Ophthalmol* 1964;57:67–78.
7. Melles GR, Eggink FA, Lander F, et al. A surgical technique for posterior lamellar keratoplasty. *Cornea* 1998;17:618–626.
8. Melles GR, Lander F, Beekhuis WH, et al. Posterior lamellar keratoplasty for a case of pseudophakic bullous keratopathy. *Am J Ophthalmol* 1999;127:340–341.
9. Terry MA, Ousley PJ. Endothelial replacement without surface corneal incisions or sutures: topography of the deep lamellar endothelial keratoplasty procedure. *Cornea* 2001;20:14–18.
10. Terry MA, Ousley PJ. Replacing the endothelium without corneal surface incisions or sutures. *Ophthalmology* 2003;110:755–764.
11. Anshu A, Price MO, Tan DTH, et al. Endothelial keratoplasty: a revolution in evolution. *Surv Ophthalmol* 2012;57:236–252.
12. Price FW JR, Price MO. Evolution of endothelial keratoplasty. *Cornea* 2013;32:28–32.
13. Melles GR, Wijdh RH, Nieuwendaal CP. A technique to excise the descemet membrane from a recipient cornea (descemetorhexis). *Cornea* 2004;23:286–288.
14. Gorovoy M, Price FW Jr. New technique transforms corneal transplantation. *Cataract Refract Surg Today* 2005;11:55–58.
15. 2016 Eye Banking Statistical Report. Eye Bank Association of America. Available at: [www.restore sight.org](http://www.restore sight.org) . Accessed 2018.
16. Gorovoy MS. Descemet-stripping automated endothelial keratoplasty. *Cornea* 2006;25:886–889.

17. Melles GR, San Ong T, Ververs B, et al. Descemet membrane endothelial keratoplasty (DMEK). *Cornea* 2006;25:987-990.
18. Seitz B, Daas L, Bischoff-Jung M, et al. Anatomy-Based DMEK-Wetlab in Homburg/Saar – Novel aspects of donor preparation and host maneuvers to teach Descemet Membrane Endothelial Keratoplasty. *Clin Anat* 2018;31:16-27.
19. Kymionis GD, Yoo SH, Diakonis VF, et al. Automated donor tissue preparation for Descemet membrane automated endothelial keratoplasty (DMAEK): an experimental study. *Ophthalmic Surg Lasers Imaging* 2011;42:158–161.
20. Anshu A, Price MO, Price FW Jr. et al. Risk of corneal transplant rejection significantly reduced with Descemet's membrane endothelial keratoplasty. *Ophthalmology* 2012;119:536–540.
21. Hos D, Matthaei M, Bock F, et al. Immune reactions after modern lamellar (DALK, DSAEK, DMEK) versus conventional penetrating corneal transplantation. *Prog Retin Eye Res* 2019; doi: 10.1016/j.preteyeres.2019.07.001. [Epub ahead of print]
22. Ham L, Dapena I, Van Luijket C, et al. Descemet membrane endothelial keratoplasty (DMEK) for Fuchs endothelial dystrophy: review of the first 50 consecutive cases. *Eye* 2009;23:1990–1998.
23. Fernandez MM, Afshari NA. Endothelial keratoplasty: from DLEK to DMEK. *Middle East Afr J Ophthalmol* 2010;17:5–8.
24. Nagra PK, Hammersmith KM, Rapuano CJ, et al. Wound dehiscence after penetrating keratoplasty. *Cornea* 2006;25:132–135.
25. Kymionis GD, Mikropoulos DG, Portaliou DM, et al. New perspectives on lamellar keratoplasty. *Adv Ther* 2014;31:494–511.
26. Price MO, Giebel AW, Fairchild KM, et al. Descemet's membrane endothelial keratoplasty: prospective multicenter study of visual and refractive outcomes and endothelial survival. *Ophthalmology* 2009;116:2361-2368.
27. Price FW Jr, Price MO. DSEK: What you need to know about endothelial keratoplasty. Thorofare, NJ: Slack Incorporated; 2009.
28. Kruse FE, Laaser K, Cursiefen C, et al. A stepwise approach to donor preparation and insertion increases safety and outcome of Descemet membrane endothelial keratoplasty. *Cornea* 2011;30:580–587.
29. Groeneveld van Beek EA, Lie JT, van der Wees J, et al. Standardized no-touch donor tissue preparation for DALK and DMEK: harvesting undamaged anterior and posterior transplants from the same donor cornea. *Acta Ophthalmol* 2013;91:145–150.

30. Muraine M, Gueudry J, He Z, et al. Novel technique for the preparation of corneal grafts for Descemet membrane endothelial keratoplasty. *Am J Ophthalmol* 2013;156:851-859.
31. Busin M, Scorcia V, Patel AK, et al. Pneumatic dissection and storage of donor endothelial tissue for Descemet's membrane endothelial keratoplasty: a novel technique. *Ophthalmology* 2010;117:1517–1520.
32. Parekh M, Ruzza A, Salvalaio G, et al. Descemet membrane endothelial keratoplasty tissue preparation from donor corneas using a standardized submerged hydro-separation method. *Am J Ophthalmol* 2014;158:277–285.
33. Bhogal M, Matter K, Balda MS, et al. Organ culture storage of pre-prepared corneal donor material for Descemet's membrane endothelial keratoplasty. *Br J Ophthalmol* 2016;100:1576–1583.
34. Bachmann BO, Schlötzer-Schrehardt U, Börgel M, et al. A novel method to generate pre-cut tissue for Descemet Membrane Endothelial Keratoplasty (DMEK). *Invest Ophthalmol Vis Sci* 2012;53:6306.
35. Godinho JV, Mian SI. Update on Descemet membrane endothelial keratoplasty. *Curr Opin Ophthalmol* 2019;30,271-274.
36. He Z, Gueudry J, Toubeau D, et al. Endothelial quality of eye bank-prestripped DMEK prepared from organ-cultured corneas with the Muraine technique. *Cell Tissue Bank* 2018;19:705-716.
37. Heinzelmann S, Böhringer D, Eberwein P, et al. Graft dislocation and graft failure following Descemet membrane endothelial keratoplasty (DMEK) using pre-cut tissue: a retrospective cohort study. *Graefes Arch Clin and Exp Ophthalmol* 2017;255:127-133.
38. Seitz B, Hager T. Clinical phenotypes of Fuchs Endothelial Corneal Dystrophy (FECD), disease progression, differential diagnosis, and medical therapy. In: Cursiefen C, Jun A, editors. *Current Treatment Options for Fuchs Endothelial Dystrophy*. Springer International Publishing Switzerland 2017:25–50.
39. Baratz KH, Tosakulwong N, Ryu E. E2-2 protein and Fuchs's corneal dystrophy. *N Engl J Med* 2010;363:1016–1024.
40. Li YJ, Minear MA, Rimmler J, et al. Replication of TCF4 through association and linkage studies in late-onset Fuchs endothelial corneal dystrophy. *PloSOne* 2011;6:e18044.
41. Terry MA. Endothelial keratoplasty: history, current state, and future directions. *Cornea* 2006;25:873-878.

42. Wynn P, Graff JM, Goins KM. Pseudophakic bullous keratopathy: Deep lamellar endothelial keratoplasty (DLEK) and intraocular lens (IOL) exchange with anterior vitrectomy [Internet]. *Eyeroounds.org*. November 17, 2005 [cited November 29, 2017]; Available from: <http://www.eyeroounds.org/cases/40-Pseudophakic-Bullous-Keratopathy-DLEK-w-IOL-exchange.htm>.
43. Damgude S, Guliani B. Pseudophakic bullous keratopathy. *Dos-Times* 2009;14:38-47
44. Lugo M, Cohen EJ, Eagle RC, et al. The Incidence of preoperative endothelial dystrophy in pseudophakic bullous keratopathy. *Ophthalmic Surg* 1988;19:16-19.
45. Ishikawa A. Risk factors for reduced corneal endothelial cell density before cataract surgery. *J Cataract Refract Surg* 2002;28:1982-1992.
46. Wirbelauer C, Anders N, Pham DT, et al. Early postoperative endothelial cell loss after corneoscleral tunnel incision and phacomulsification in pseudoexfoliation syndrome. *Ophthalmologie* 1997;94:332-336.
47. Nguyen NX, Lattermann V, Schlötzer-Schrehardt U, Seitz B. [Functional outcomes after penetrating keratoplasty for keratopathy in pseudoexfoliation syndrome (PEX-Keratopathy)]. *Klin Monatsbl Augenheilkd* 2004;221:819-824.
48. Suzuki T, Ohashi Y. Corneal endotheliitis. *Semin Ophthalmol* 2008;23:235-240.
49. Babu MS, Balammal G, Sangeetha G, et al. A review on viral keratitis caused by herpes simplex virus. *J Sci Infect* 2011;1:1-10.
50. Amano S, Oshika T, Kaji Y, et al. Herpes simplex virus in the trabeculae of an eye with corneal endotheliitis. *Am J Ophthalmol* 1999;127:721-722.
51. Kaye S, Choudhary A. Herpes simplex keratitis. *Prog Retin Eye Res* 2006;25:355-380
52. Fiorentzis M, Szentmáry N, Seitz B. [Bilateral vascularized disciform corneal scar of herpetic origin in a child]. *Ophthalmologie* 2015;112:162-165.
53. Tullo A. Pathogenesis and management of herpes simplex virus keratitis. *Eye* 2003;17:919-922
54. Asi F, Daas L, Milioti G, Suffo S, Seitz B. Triple Descemet membrane endothelial keratoplasty for Haab striae with endothelial decompensation in congenital glaucoma. *JCRS Online Case Rep*. 2019;7:38-41.
55. Asi F, Milioti G, Seitz B. DMEK is a successful treatment option in corneal decompensation due to herpes simplex virus endotheliitis. *J Cataract Refract Surg* 2018;44:106-108.
56. Zarei-Ghanavati S, Alizadeh R, Yoo SH. Herpes Simplex Virus endotheliitis following descemet's membrane endothelial keratoplasty. *J Ophthalmic Vis Res* 2015;10:184-186.

57. Sáles CS, Mayko ZM, Terry MA, et al. Descemet Membrane Endothelial Keratoplasty (DMEK) surgery with a standardized technique. In: Jacob S. Mastering Endothelial Keratoplasty. Springer India 2016:144-170.
58. Jacob S, Sumathi A. Endothelial keratoplasty versus penetrating keratoplasty. In: Jacob S. Mastering Endothelial Keratoplasty. Springer India 2016:57-72.
59. Terry MA, Shamie N, Chen ES, et al. Endothelial keratoplasty for Fuchs' dystrophy with cataract: complications and clinical results with the new triple procedure. *Ophthalmology* 2009;116:631–639.
60. Price MO, Scanameo A, Feng MT, et al. Descemet's membrane endothelial keratoplasty: risk of immunologic rejection episodes after discontinuing topical corticosteroids. *Ophthalmology* 2016;123:1232–1236.
61. Panda A, Vanathi M, Kumar A, Dash Y, Priya S. Corneal graft rejection. *Surv Ophthalmol* 2007;52:375-369.
62. Figueiredo GS, Jones MN, Krishna Y, et al. Transplant rejection following endothelial keratoplasty and penetrating keratoplasty in the United Kingdom: incidence and survival. *Am J Ophthalmol* 2015;160:416–421.
63. Heinzelmann S, Böhringer D, Eberwein P, et al. Outcomes of Descemet Membrane Endothelial Keratoplasty, Descemet stripping Automated Endothelial Keratoplasty and penetrating keratoplasty from a single centre study. *Graefes Arch Clin and Exp Ophthalmol* 2016;254:515-522.
64. Inoda S, Hayashi T, Takahashi H, et al. Risk factors for cystoid macular edema after Descemet Membrane Endothelial Keratoplasty. *Cornea* 2019;38:820-824.
65. Wade M, Farid M, Garg S, et al. Role of optical coherence tomography in Endothelial Keratoplasty. In: Jacob S. Mastering Endothelial Keratoplasty. Springer India 2016:89-104.
66. Ponzin D, Salvalioia G, Ruzza A, et al. Development in Corneal Banking. In: Hjortdal J. Corneal Transplantation. Springer Heidelberg, New York, Dordrecht, London 2016:27-29.
67. Eye Bank Association of America. Medical Standards. <http://www.restore sight.org>.
68. Wiffen SJ, Nelson LR, Ali AF, et al. Morphologic assessment of corneal endothelium by specular microscopy in evaluation of donor corneas for transplantation. *Cornea* 1995;14:554–561.

69. Damian A, Seitz B, Langenbucher A, et al. Optical coherence tomography-based topography determination of corneal grafts in eye bank cultivation. *J Biomed Opt* 2017;22:16001.
70. Pels L. Organ culture: the method of choice for preservation of human donor corneas. *Br J Ophthalmol* 1997;81:523–525.
71. Stocker FW. The endothelium of the cornea and its clinical implications. *Trans Am Ophthalmol Soc* 1953;51:669–786.
72. McCarey BE, Kaufman HE. Improved corneal storage. *Invest Ophthalmol Vis Sci* 1974;13:165–173.
73. Bigar F, Kaufman HE, McCarey BE, et al. Improved corneal storage for penetrating keratoplasties in man. *Am J Ophthalmol* 1975;79:115–120.
74. Doughman DJ, Van Horn DL, Harris JE, et al. The ultrastructure of human organ-cultured corneal endothelium. *Arch Ophthalmol* 1974;92:516–523.
75. Summerlin WT, Miller GE, Harris JE, et al. The organ-cultured cornea: an in vitro study. *Invest Ophthalmol Vis Sci* 1973;12:176–180.
76. Doughman DJ, Harris JE, Schmidt KM. Penetrating keratoplasty using 37°C organ-cultured cornea. *Am Acad Ophthalmol Otol* 1976;81:778–793.
77. Pels E, Schuchard Y. Organ culture and endothelial evaluation as a preservation method for human corneas. In: Brightbill FS, ed. *Corneal surgery*. 2nd ed. *St Louis: Mosby*, 1986:93–102.
78. Redbrake C, Salla S, Nilius R, et al. A histochemical study of the distribution of dextran 500 in human corneas during organ culture. *Curr Eye Res* 1997;16:405–411.
79. Abdin A, Daas L, Pattmüller M, Suffo S, Langenbucher A, Seitz B. Negative impact of dextran in organ culture media for pre-stripped tissue preservation on DMEK (Descemet membrane endothelial keratoplasty) outcome. *Graefes Arch Clin Exp Ophthalmol* 2018;256:2135–2142.
80. Greiner MA, Rixen JJ, Wagoner MD, et al. Diabetes mellitus increases risk of unsuccessful graft preparation in Descemet membrane endothelial keratoplasty: a multicenter study. *Cornea* 2014; 33:1129–1133.
81. Bachmann BO, Laaser K, Cursiefen C, et al. A method to confirm correct orientation of Descemet membrane during Descemet membrane endothelial keratoplasty. *Am J Ophthalmol* 2010;149:922–925.
82. Heinzelmann S, Maier P, Böhringer D, et al. Cystoid macular oedema following Descemet membrane endothelial keratoplasty. *Br J Ophthalmol* 2015;99:98–102.

83. Hoerster R, Stanzel TP, Bachmann BO, et al. Intensified topical steroids as prophylaxis for macular edema after posterior lamellar keratoplasty combined with cataract surgery. *Am J Ophthalmol* 2016;163:174–179.
84. Sugar A, Gal RL, Kollman C, et al. Factors associated with corneal graft survival in the cornea donor study. *JAMA Ophthalmol* 2015;133:246–254.
85. Touzeau O [Calculating the mean visual acuity and the change in visual acuity with a decimal acuity chart]. *J Fr Ophtalmol* 2003;26:586-590.
86. Luft N, Hirschschall N, Schuschitz S, Draschl P, Findl O. Comparison of 4 specular microscopes in healthy eyes and eyes with cornea guttata or corneal grafts. *Cornea* 2015;34:381–386.
87. Doors M, Cruysberg, LPJ, Berendschot TTJM, et al. Comparison of central corneal thickness and anterior chamber depth measurements using three imaging technologies in normal eyes and after phakic intraocular lens implantation. *Graefes Arch Clin Exp Ophthalmol* 2009;247:1139-1146.
88. Ham L, Van Der Wees J, Melles GR. Causes of primary donor failure in Descemet Membrane Endothelial Keratoplasty. *Am J Ophthalmol* 2008;145:639 – 644.
89. Dapena I, Ham L, Melles GR. Endothelial keratoplasty: DSEK/DSEK or DMEK - the thinner the better? *Curr Opi Ophthalmol* 2009;20:299-307.
90. Neff KD, Biber JM, Holland EJ. Comparison of central corneal graft thickness to visual acuity outcomes in endothelial keratoplasty. *Cornea* 2011;30:388-391.
91. Wolf AH, Welge-Lüssen UC, Priglinger S, et al. Optimizing the deswelling process of organ-cultured corneas. *Cornea* 2009;28:524–529.
92. Dirisamer M, Dapena I, Ham L, et al. Patterns of corneal endothelialization and corneal clearance after descemet membrane endothelial keratoplasty for Fuchs endothelial dystrophy. *Am J Ophthalmol* 2011;152:543–555.
93. Schrittenlocher S, Bachmann B, Cursiefen C. Impact of donor tissue diameter on postoperative central endothelial cell density in Descemet Membrane Endothelial Keratoplasty. *Acta Ophthalmol* 2019;97:e618-e622.
94. Bayyoud T, Röck D, Hofmann J, et al. Precut technique for Descemet's membrane endothelial keratoplasty, preparation and storage in organ culture. *Klin Monatsbl Augenheilkd* 2012;229:621–623.
95. Lie JT, Birbal R, Ham L, et al. Donor tissue preparation for Descemet membrane endothelial keratoplasty. *J Cataract Refract Surg* 2008;34:1578–1583.

96. Krabcova I, Studeny P, Jirsova K, et al. Endothelial cell density before and after the preparation of corneal lamellae for descemet membrane endothelial keratoplasty with a stromal rim. *Cornea* 2011;30:1436-1441.
97. Van der Want HJ, Pels E, Schuchard Y, et al. Electron microscopy of cultured human corneas. Osmotic hydration and the use of a dextran fraction (dextran T 500) in organ culture. *Arch Ophthalmol* 1983;101:1906–1920.
98. Borderie VM, Baudrimont M, Lopez M, et al. Evaluation of the deswelling period in dextran-containing medium after corneal organ culture. *Cornea* 1997;16:215–223.
99. Menzel-Severing J, Walter P, Plum WJ, Kruse FE, Salla S. Assessment of corneal endothelium during continued organ culture of pre-stripped human donor tissue for DMEK surgery. *Curr Eye Res* 2018;43:1439-1444.
100. Redbrake C, Salla S, Frantz A. Changes in human donor corneas preserved for longer than 4 weeks. *Cornea* 1998;17:62-65.
101. Lin CP, Böhnke M, Draeger J. Effect of dextran on predamaged corneal endothelium:an organ culture study. *Ophthal Res* 1992;24:125-128.
102. Schnitzler AC, Salla S, Hamsley N, et al. Role of the endothelial layer in the deswelling process of organ-cultured human corneas before transplantation. *Cornea* 2016;35:1216-1221.
103. Board of the Federal German Medical Association. [Guideline for the acquisition of donor corneas and for guiding an eye cornea bank]. *Dtsch Arztebl* 2014;111:31–32.
104. Board of the Federal German Medical Association. [Decision of the Federal Medical Association on the first circumscribed continuation of the guideline for the acquisition of donor corneas and for guiding an eye cornea bank]. *Dtsch Arztebl* 2018;115:A- 262/B-226 /C-226.
105. Agha B, Shajari M, Slavik-Lencova A, et al. Functional outcome of repeat Descemet membrane endothelial keratoplasty (DMEK) for corneal decompensation following graft failure after primary DMEK. *Clin Ophthalmol* 2019;13:477-482.
106. Hos D, Tuac O, Schaub F et al. Incidence and clinical course of immunereactions after Descemet Membrane Endothelial Keratoplasty. *Ophthalmology* 2017;124:512-518
107. Beuerman RW, Pedroza L. Ultrastructure of the human cornea. *Microsc Res Tech* 1996;33:320-335.
108. Bairaktaris G, Lewis D, Fullwood NJ, et al. An ultrastructural investigation into proteoglycan distribution in human corneas. *Cornea* 1998;17:396-402.



109. Kabosova A, Azar D.T, Bannikov G.A, et al. Compositional differences between infant and adult human corneal basement membranes. *Invest Ophthalmol Vis Sci* 2007;48:4989-4999.
110. Levy SG, McCartney AC, Moss J. The distribution of fibronectin and P component in Descemet's membrane: an immunoelectron microscopic study. *Curr Eye Res* 1995;14:865-870.
111. Müller LJ, Pels E, Vrensen GF. The effects of organ-culture on the density of keratocytes and collagen fibers in human corneas. *Cornea* 2001;20:86-95.
112. Quilendrino R, Rodriguez-Calvo de Mora M, Baydoun C, et al. Prevention and management of Descemet membrane endothelial keratoplasty complications. *Cornea* 2017;36:1089–1095.
113. Schmidt I, Schlötzer-Schrehardt U, Langenbacher A, et al. Ultrastructural findings in graft failure after Descemet membrane endothelial keratoplasty (DMEK) and new triple procedure. *Medicine (Baltimore)* 2019;98:e15493.
114. Weller JM, Schlötzer-Schrehardt U, Tourtas T, et al. Influence of ultrastructural corneal graft abnormalities on the outcome of Descemet membrane endothelial keratoplasty. *Am J Ophthalmol* 2016;169:58–67.
115. Salla S, Kruse FE, Walter P, et al. Supplementation of organ culture medium with dextran is not required in pre-stripped human donor tissue for DMEK surgery. *Cell Tissue Bank* 2019;20:193-200.
116. Rikmann A, Wahl S, Hofmann N, et al. Precut DMEK using dextran-containing storage medium is equivalent to conventional DMEK: A prospective pilot study. *Cornea* 2019;38:24-29.
117. Parekh M, Ruzza A, Di Mundo R, et al. Role of dextran in maintaining adhesive and stiffness properties of prestripped DMEK lenticules. *Eur J Ophthalmol* 2017;27:270–277.
118. Parekh M, Ruzza A, Ferrari S, et al. Preservation of preloaded DMEK lenticules in dextran and non-dextran-based organ culture medium. *J Ophthalmol* 2016;2016:5830835.
119. Yoeruek E, Hofmann J, Bartz-Schmidt K-U. Comparison of swollen and dextran deswollen organ-cultured corneas for Descemet membrane dissection preparation: histological and ultrastructural findings. *Invest Ophthalmol Vis Sci* 2013;54:8036–8040

## 8. Dank

An dieser Stelle möchte ich meinen besonderen Dank nachstehenden Personen entgegenbringen, ohne deren Mithilfe die Anfertigung dieser Promotionsschrift niemals zustande gekommen wäre:

Mein Dank gilt zunächst Herrn Professor Dr. Berthold Seitz, meinem Doktorvater, Direktor der Klinik für Augenheilkunde am Universitätsklinikum des Saarlandes, für seine stets freundliche und konstruktive Gesprächsbereitschaft, seine lehrreiche Hilfe sowie die uneingeschränkte Möglichkeit, seine Klinik für meine Arbeit zu nutzen.

Ich danke Herrn Suffo, Leitender Oberarzt der Klinik für Augenheilkunde am Universitätsklinikum des Saarlandes, für die Überlassung des Themas, sowie die hilfsbereite und wissenschaftliche Betreuung.

Ferner danke ich Herrn Prof. Langenbacher, Leiter des Instituts für Experimentelle Ophthalmologie an der Universität des Saarlandes, für die Hilfe bei der Ausarbeitung der Statistik sowie die kritische und gewissenhafte Durchsicht des Manuskripts dieser Dissertationsschrift.

Jedem einzelnen Mitarbeiter der Augenklinik danke ich für die offene Aufnahme, das angenehme Arbeitsklima sowie die stets freundliche Hilfsbereitschaft.

Tief verbunden und dankbar bin ich meiner Frau Dana für ihre unglaublich hilfreiche Unterstützung und ihr Verständnis bei der Anfertigung dieser Doktorarbeit.

Mein ganz besonderer Dank gilt meinen Eltern, die mir meinen bisherigen Lebensweg ermöglichten und denen ich diese Arbeit widme.

Abschließend danke ich jedem, der auf seine Weise dazu beigetragen hat, dass diese Arbeit erfolgreich fertiggestellt werden konnte.