



[www.fmshk.org](http://www.fmshk.org)

THE HONG KONG 香港醫訊  
*MEDICAL DIARY*

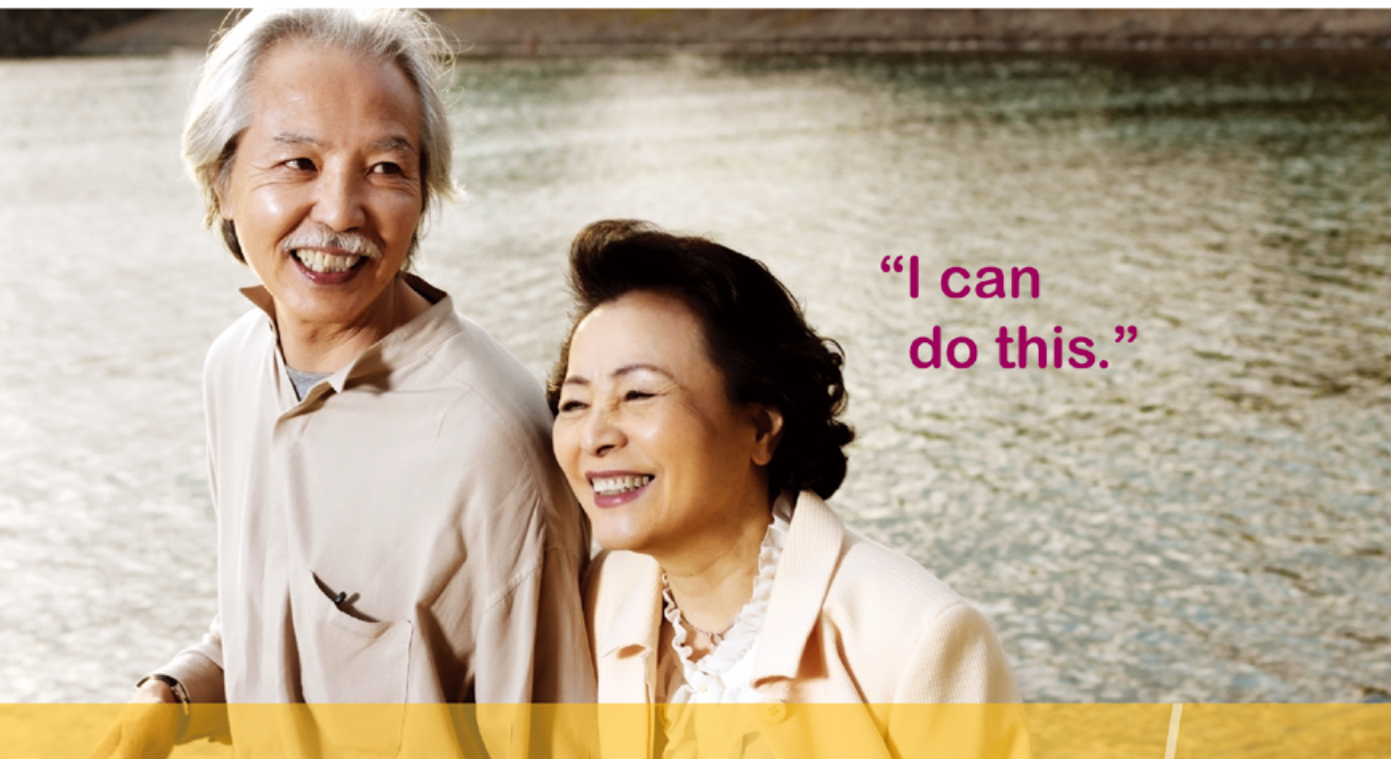*VOL.19 NO.6 June 2014*

*Dentistry*

**Humalog<sup>®</sup> KwikPen<sup>™</sup>**  
insulin lispro (rDNA origin) injection

**Humalog<sup>mix25</sup><sup>™</sup> KwikPen<sup>™</sup>**  
25% insulin lispro (rDNA origin) injection  
75% insulin lispro protamine suspension

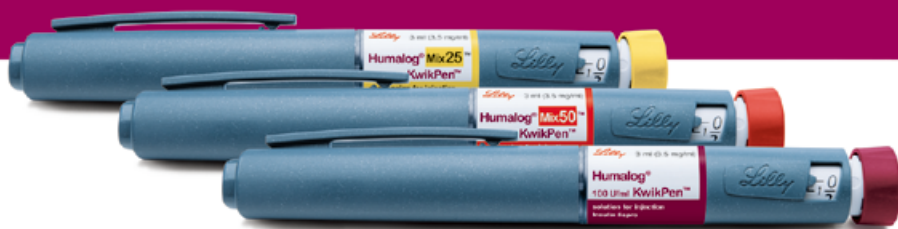**Humalog<sup>mix50</sup><sup>™</sup> KwikPen<sup>™</sup>**  
50% insulin lispro (rDNA origin) injection  
50% insulin lispro protamine suspension



“I can  
do this.”

It gets patients the insulin they need  
without getting in the way of life.

Humalog



- Easy to learn, easy to use<sup>1</sup>
- Low, smooth injection force<sup>2</sup>
- Lightweight<sup>2</sup>

For complete instructions on Humalog<sup>®</sup> KwikPen<sup>™</sup>, Humalog<sup>®</sup> Mix25<sup>™</sup> KwikPen<sup>™</sup>, Humalog<sup>®</sup> Mix50<sup>™</sup> KwikPen<sup>™</sup> please refer to the full user manual provided with the Pen.

References:

1. Ignat DA, Schwartz SL, Sarwat S and Murphy HL. *Diabetes Educ* 2009;35:789-798.  
2. Ignat DA, Opincar M and Lenox S. *J Diabetes Sci Technol* 2008;2:533-537.

Further information is available upon request.

**Lilly**

Eli Lilly Asia, Inc.  
Unit 3203-3208, 32/F Ace Tower Windsor House, 311 Gloucester Road, Causeway Bay, Hong Kong  
Tel: (852) 2572 0160 Fax: (852) 2572 7893  
www.lilly.com.hk

HQJAD0411J51  
Vial Base#HK11026/022JAA



## Contents

### Editorial

- **Elderly Dentistry** 2  
*Dr Albert MP LEE*

### Dental Bulletin

- **Mesenchymal Stem Cell Approach for Maxillary Sinus Grafting** 4  
*Dr Laddawun SUNUNLIGANON & Prof Lim-kwong CHEUNG* CME
- **MCHK CME Programme Self-assessment Questions** 8
- **Dental Care to Older People in Hong Kong** 10  
*Dr Frankie HC SO & Prof Edward CM LO*
- **Cracked Tooth – a Syndrome or Conundrum?** 13  
*Prof Gary SP CHEUNG*
- **Prosthodontic Management of Edentulous Patients** 18  
*Dr Tsz-leung WONG*

### Life Style

- **An Expedition to Mount Vinson, the Highest Point in Antarctica** 23  
*Dr Haston WM LIU*

### Dental Quiz

- **Dental Quiz** 21  
*Dr Shiu-yin CHO*

### Medical Diary of June

29

### Calendar of Events

30



## Scan the QR-code

To read more about  
The Federation of Medical  
Societies of Hong Kong

## New Edition of Medical and Dental Directory Submit your data NOW!

<http://www.fmskhk.org/directory2012.php>


## Disclaimer

All materials published in the Hong Kong Medical Diary represent the opinions of the authors responsible for the articles and do not reflect the official views or policy of the Federation of Medical Societies of Hong Kong, member societies or the publisher.

Publication of an advertisement in the Hong Kong Medical Diary does not constitute endorsement or approval of the product or service promoted or of any claims made by the advertisers with respect to such products or services.

The Federation of Medical Societies of Hong Kong and the Hong Kong Medical Diary assume no responsibility for any injury and/or damage to persons or property arising from any use of execution of any methods, treatments, therapy, operations, instructions, ideas contained in the printed articles. Because of rapid advances in medicine, independent verification of diagnoses, treatment method and drug dosage should be made.

## The Cover Shot



### 花霧情 A foggy spring

I was depicting an impressionist painting style with this double exposure photograph. It was taken handheld in the sakura garden at Nijō Castle in Kyoto, Japan (京都市元離宮二条城桜の園), as no tripod was allowed.



**Dr Siu-fai LEUNG**

BDS (HK) MSc (Lond)  
FRACDS  
Specialist in Endodontics  
Private Practice



**Published by**  
The Federation of Medical Societies of Hong Kong

**EDITOR-IN-CHIEF**

Dr MOK Chun-on  
莫鎮安醫生

**EDITORS**

Prof CHAN Chi-fung, Godfrey  
陳志峰教授 (Paediatrics)  
Dr CHAN Chi-kuen  
陳志權醫生 (Gastroenterology & Hepatology)  
Dr KING Wing-keung, Walter  
金永強醫生 (Plastic Surgery)  
Dr LO See-kit, Raymond  
勞思傑醫生 (Geriatric Medicine)

**EDITORIAL BOARD**

Dr AU Wing-yan, Thomas  
區永仁醫生 (Haematology and Haematological Oncology)  
Dr CHAK Wai-kwong  
翟偉光醫生 (Paediatrics)  
Dr CHAN Chun-kwong, Jane  
陳真光醫生 (Respiratory Medicine)  
Dr CHAN Hau-ngai, Kingsley  
陳厚毅醫生 (Dermatology & Venereology)  
Dr CHAN, Norman  
陳諾醫生 (Diabetes, Endocrinology & Metabolism)  
Dr CHEUNG Fuk-chi, Eric  
張復熾醫生 (Psychiatry)  
Dr CHIANG Chung-seung  
蔣忠想醫生 (Cardiology)  
Prof CHIM Chor-sang, James  
詹楚生教授 (Haematology and Haematological Oncology)  
Dr CHONG Lai-yin  
莊禮賢醫生 (Dermatology & Venereology)  
Dr CHUNG Chi-chiu, Cliff  
鍾志超醫生 (General Surgery)  
Dr FONG To-sang, Dawson  
方道生醫生 (Neurosurgery)  
Dr HSUE Chan-chee, Victor  
徐成之醫生 (Clinical Oncology)  
Dr KWOK Po-yin, Samuel  
郭寶賢醫生 (General Surgery)  
Dr LAM Siu-keung  
林兆強醫生 (Obstetrics & Gynaecology)  
Dr LAM Wai-man, Wendy  
林慧文醫生 (Radiology)  
Dr LEE Kin-man, Philip  
李健民醫生 (Oral & Maxillofacial Surgery)  
Dr LEE Man-piu, Albert  
李文彪醫生 (Dentistry)  
Dr LI Fuk-him, Dominic  
李福謙醫生 (Obstetrics & Gynaecology)  
Prof LI Ka-wah, Michael, BBS  
李家驊醫生 (General Surgery)  
Dr LO Chor Man  
盧礎文醫生 (Emergency Medicine)  
Dr LO Kwok-wing, Patrick  
盧國榮醫生 (Diabetes, Endocrinology & Metabolism)  
Dr MA Hon-ming, Ernest  
馬漢明醫生 (Rehabilitation)  
Dr MAN Chi-wai  
文志衛醫生 (Urology)  
Dr NG Wah Shan  
伍華山醫生 (Emergency Medicine)  
Dr PANG Chi-wang, Peter  
彭志宏醫生 (Plastic Surgery)  
Dr TSANG Kin-lun  
曾建倫醫生 (Neurology)  
Dr TSANG Wai-kay  
曾偉基醫生 (Nephrology)  
Dr WONG Bun-lap, Bernard  
黃品立醫生 (Cardiology)  
Dr YAU Tsz-kok  
游子覺醫生 (Clinical Oncology)  
Prof YU Chun-ho, Simon  
余俊豪教授 (Radiology)  
Dr YUEN Shi-yin, Nancy  
袁淑賢醫生 (Ophthalmology)

**Design and Production**

A-PRO MULTIMEDIA LTD www.apro.com.hk

# Elderly Dentistry

## Dr Albert MP LEE

BDS, MSc, FRACDS, FCDShK (Paed Dent),  
FHKAM (Dental Surgery)

Editor



Dr Albert MP LEE

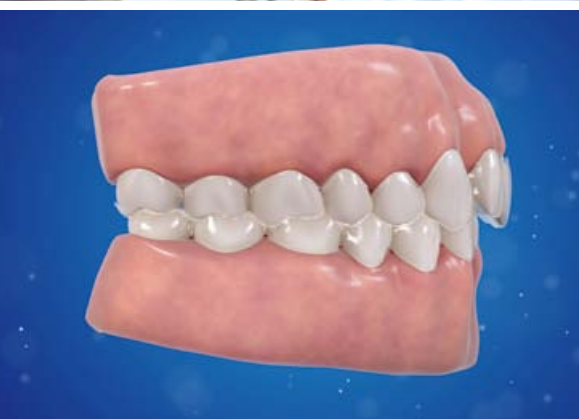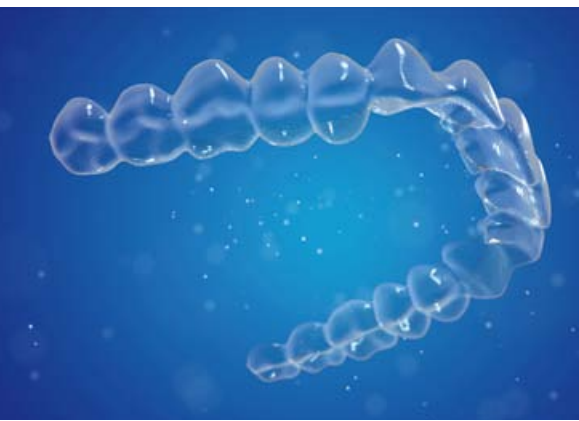
With the decline in the birth rate and the growth of the older population in Hong Kong, the pattern of needs and demands for dental services has changed in the last decade. According to the Oral Health Survey 2011 of the Department of Health, the oral health of the 65 to 74-years old non-institutionalised older persons (NOP) in Hong Kong has improved slightly as compared to 2001. This was reflected in fewer tooth loss and lesser tooth decay experience over the past ten years. Despite the general improvement of oral health in the NOP group, the gum condition in the older population was still poor with 97% of the dentate NOP having gum bleeding and 60% of the dentate NOP having gum pockets of 4mm or more. Moreover there are still 6% of the 65 to 74-years old NOP with total tooth loss and half of them are still affected by decayed teeth. The high prevalence of dental diseases in the older population is complicated by the low utilisation of dental services even though there were symptoms of severe toothache in 60% of the age group. According to the survey, the major barrier to seeking earlier dental attention was due to high and unpredictable treatment costs as perceived by the elderly.

Apart from the institutionalised older persons (IOP), most of the NOPs are under the care by general dental practitioners (GDP) in the private sector in the community. However the incentive for the older population to seek dental treatments and maintenance is low with only 22% of NOPs having regular dental checkup habits. The poor utilisation of dental services by the older population will result in further tooth loss when preventive and curative treatments could not be implemented in an earlier stage of the developing diseases. As a result, a vicious cycle promulgates further with more problems in oral rehabilitation in the elderly people which is essential to their masticatory function and general health.

The dental treatments of the elderly are also complicated by common medical conditions like cardiovascular, metabolic and geriatric diseases. With the increasing use of anticoagulants and anti-platelet drugs for the treatment and prevention of cardiovascular conditions, dentists are faced with the challenges in treatment planning for maintaining the optimal oral health condition of the aged population. Similarly, the common usage of Bisphosphonates and related drugs for the treatment of osteoporosis has made the decision for dental extractions more difficult for dentists. Modern dental technologies have their limitations in treating the elderly patients, there is always a conflict in between an ideal dental treatment plan and the patient's physical and medical conditions. Hence elderly dentistry is taking a different prospective with the growth of the older population in the community.

# Treat deep bite with confidence.

Invisalign's first malocclusion solution: **Invisalign<sup>G5</sup>**



The latest clinical innovations are designed to help doctors treat deep bite confidently and predictably.

#### **New SmartForce™ features for deep bite:**

- Improved control of intrusion
- Improved control of premolar extrusion and anchorage
- Improved treatment efficiency with Precision Bite Ramps

#### **For more information**

Please contact (852) 3106 8678 or email to [doctor-hk@aligntech.com](mailto:doctor-hk@aligntech.com)



# Mesenchymal Stem Cell Approach for Maxillary Sinus Grafting

**Dr Laddawun SUNUNLIGANON**

DDS (PSU), Grad dip in ClinSc: (OMFS: MU), MDS (OMFS-HKU), PhD(OMFS-HKU), LLB (RU)

Assistant Professor, Oral and Maxillofacial Surgery  
Faculty of Dentistry, Thammasat University, Thailand

**Prof Lim-kwong CHEUNG**

BDS, PhD, FFD RCS (Irel), FDS RCPS (Glasg), FRACDS, FRACDS (OMS)  
FHKAM (Dental Surgery), FCDSHK (OMS), FDS RCSEd, FFGDP

Specialist in Oral and Maxillofacial Surgery  
Honorary Clinical Professor, Faculty of Dentistry, the University of Hong Kong



Prof Lim-kwong CHEUNG Dr Laddawun SUNUNLIGANON

*This article has been selected by the Editorial Board of the Hong Kong Medical Diary for participants in the CME programme of the Medical Council of Hong Kong (MCHK) to complete the following self-assessment questions in order to be awarded 1 CME credit under the programme upon returning the completed answer sheet to the Federation Secretariat on or before 30 June 2014.*

## Abstract

Autogenous bone has long been a gold standard grafting material for bone defects. It possesses osteogenic, osteoinductive and osteoconductive properties ideal for bone healing. However, the need of a donor site surgery and related morbidities remain a major concern to the patients. Therefore, bone substitutes have been recognised to be alternatives to autogenous bone. Since they are cell-free materials providing at their best only osteoconductive property, the concept of introducing mesenchymal stromal cells (MSCs) creates a lot of interest. This MSCs strategy can potentially contribute all the three osteo-regenerative properties similar to autogenous bone graft. The MSCs are commonly harvested by aspiration methods from the posterior hip of the same host. The cell number can be amplified by culturing in the laboratory for a period of time or concentrated using a centrifuge and dedicated systems to achieve sufficient quantity for immediate transplantation. Its application in oral and maxillofacial regions, particularly on maxillary augmentation for dental implant rehabilitation, has been researched with promising clinical results.

## Introduction

Through innovative strategy of tissue engineering, there is now the possibility to regenerate tissues. Key determinants for tissue regeneration involve an incorporation of cells, scaffolds and signals. The Mesenchymal stromal cell (MSC) approach has been researched extensively in the laboratory and in animals for bone regeneration of surgical defects. MSCs can proliferate and differentiate to bone progenitor cells guided by environmental stimulation.<sup>1</sup> MSCs also participate in angiogenesis as well as secreting various trophic factors, such as growth factors, cytokines and chemokines.<sup>2</sup> Bone marrow has been utilised as a promising source of MSCs either for immediate or culture-expanded application. In considering the pros and cons of both methods, an immediate bone marrow MSCs application has many advantages, especially in the avoidance of cross contamination of genetic materials that may have unforeseeable consequences. The quantity of MSCs is a key factor for the success of tissue regeneration. Different bone marrow concentration methods have been developed to

serve this purpose.<sup>3</sup> The immediate use of bone marrow aspirate concentrate (BMAC) in combination with scaffolds has been introduced and investigated as a new strategy for bone augmentation of the atrophic jaw as a means to improve the dental implant success for this compromised region.

## Mesenchymal stem cells

Bone marrow-derived mesenchymal stromal cells (BM-MSCs) are a group of non-haematopoietic cells residing within the bone marrow. Friedenstein first described MSC as osteogenic progenitors in bone marrow and named as "osteogenic stem cell" because of their plastic-adherent capacity.<sup>4</sup> These cells are fibroblast-like cells and able to form colonies, proliferate and differentiate to other tissues. They were subsequently also named as "stromal cells", "mesenchymal stem cells" (Caplan), or "skeletal stem cells" (Bianco and Robey). The International Society for Cellular Therapy (ISCT) had recommended using a broader term called "multipotent mesenchymal stromal cells" for the cells that can differentiate to different cellular types and tissues under different culture environments. For the cellular fractions that fit to the stem cell criteria, these cells can be called "mesenchymal stem cells" as a reflection of their biological properties.<sup>5-7</sup>

Any stem cell should possess the biological characteristics of long term self-renewal and the capability to differentiate into specialised cell types. The ISCT defined that the stem cells are referred to those cells that possess the following abilities: 1) Plastic adherence in culture; 2) Expression of certain CD markers (CD105, CD73, CD90) and coincidental absence of CD34, CD45, CD14 or CD11b, CD97 $\alpha$  or CD19, HLA-DR; and 3) Cell differentiation to osteoblasts, chondroblasts, and adipocytes in vitro.<sup>8,9</sup>

## Culture-expansion of MSC for bone regeneration

Culture-expanded cells can be used alone or in combination with other bioactive molecules (growth factors, cytokines, etc.) or scaffolds. A variety of techniques have been developed, such as an injectable composite graft of culture-expanded MSCs and platelet rich plasma (PRP). Several research teams have found



that they can provide predictable bone regeneration as well as dental implant success in maxillary and mandibular defects<sup>10-12</sup>. In a case report of alveolar bone grafting by this composite graft, radio-opacity suggesting of spontaneous ossification was noted on the CT scan 3 months after transplantation. This regenerated bone facilitated the eruption of a tooth in a 9-years-old clefted patient.<sup>13</sup> In addition, this injectable graft material also showed promising results on periodontal tissue regeneration.<sup>14</sup>

The culture-expansion method, however, requires a strictly regulated laboratory processing to avoid possible contamination, which can be time consuming, expensive, and requires a high quality control before being able to transfer back to patients. The other major ethical concerns include risk of genetic material contamination or chance of tumour transmission from stem cells, of which many are generated from tumour cell lines. Therefore, direct transplantation of autologous bone marrow cells was introduced recently. This technique may offer all the desirable properties for bone regeneration; osteogenic, osteoinductive and osteoconductive properties, as well as provides various bioactive molecules such as cytokines and growth factors to enhance bone formation. Besides, auto-transplantation of MSCs from the same host also has no problems of immune-rejection or disease transmission from other hosts.<sup>15-17</sup>

## Application of bone marrow for bone regeneration

Bone marrow is a promising source of osteo-progenitor cells providing bone regeneration and it has been proven for the osteogenic property either using as fresh bone marrow or culture-expanded MSCs.<sup>18</sup> However, osteogenic differentiation potential of culture-expanded MSCs was reported to fade with the increase in number of subcultures.<sup>19,20</sup> Furthermore, intra-operative autologous bone marrow methods, either as fresh bone marrow or bone marrow concentrate, have been established. Bone marrow fluid is most commonly aspirated from the posterior hip bone, although other bone sources are also available but with less quantity. This technique has been widely used by the haematologists for harvesting marrow cells for treatment of leukaemia. The aspirate contains a mixture of cells and molecules including mesenchymal stem cells, progenitor cells, growth factors, cytokines as well as fibrin that facilitates tissue regeneration.

## Progenitor cells in the bone marrow

MSCs are just a fraction of nucleated cells in the bone marrow cell population in animal and human bone marrow. There the quantity of MSCs harvested from the bone marrow is quite variable<sup>21</sup> and it was found to be affected by a combination of genetic, age and environmental factors, etc. In a canine model, it revealed that there were 250 million nucleated cells in 1ml of bone marrow but only one osteo-progenitor cell among 2x10<sup>4</sup> nucleated cells.<sup>22</sup> The prevalence of human MSC from bone marrow aspirate was reported to be as small as 0.001-0.01% of nucleated cells<sup>23,24</sup>. The proportion of MSC per nucleated cell had been reported as one MSC

out of 104-105 nucleated cells<sup>25</sup>, or one out of 3-3.4x10<sup>4</sup> nucleated cells<sup>26,27</sup>.

## Immediate use of bone marrow aspirate

The simplest approach of using bone marrow aspirate (BMA) is by percutaneous injection to the recipient site. This method would result in enhancement of bone healing in treatment of fresh fracture<sup>28</sup>, non-union or delayed union of long bones<sup>29</sup>, spinal fusion<sup>30</sup>, etc. Furthermore, BMA incorporated in demineralised bone matrix was confirmed to generate bone in both intra- and extra-skeletal sites in rats<sup>31</sup> and increased bone healing in non-union fracture of canines.<sup>32</sup> An injection of BMA mixed with demineralised bone matrix also achieved effective treatment of bone cyst cavity. The bone marrow aspirate can alternatively be enriched with platelet rich plasma and mixed with tricalcium phosphate before use. It was found to exhibit good healing for spinal fusion in rabbits.<sup>33</sup>

The scarcity of MSC in BMA is a crucial factor affecting the quantity of bone formation and methods of its application. An effective concentration of osteo-progenitor cells for successful bone healing was reported of needing more than 1,500 progenitors cells/cm<sup>3</sup> or 54,962 ± 17,431 progenitors cells in treatment of a tibia non-union<sup>26</sup>.

## Concentration of bone marrow aspirate

MSCs of bone marrow can be concentrated to enrich the quantity of nucleated cells as well as amplify the osteogenic capacity for either immediate use or through culture-expansion methods<sup>18,34,35</sup>. Unwanted portions, such as red blood cells and poor plasma, can be removed thus the remaining minute volume can be used more effectively in many clinical conditions. The concentration method is simple, inexpensive, minimally time consuming and decreases risks of infection. An increase in cell number after concentration would result in reduction in oxygen level due to competitive oxygen consumption. Though, hypoxic conditions in culture had arisen, MSCs were reported to have been able to proliferate and differentiate in this compromised environment<sup>26,36</sup>. An additional advantage of using BMAC is the concomitant enrichment of CD34+ cells, which has the property to promote neovascularisation during tissue healing.<sup>37</sup>

Various systems have been launched to extract nucleated cell as well as MSCs from bone marrow, such as density gradient separation, centrifugation, and commercially available bone marrow concentration systems.

The density gradient separation (FICOLL, PERCOLL) is a complicated method using mononuclear cells isolated in the laboratory. It requires laboratory support and is time consuming (at least 1 hour), which is not clinically practical for immediate transplantation. Simple centrifugation techniques also reported an increase in the number of MSCs in animal experiments, which proved their osteogenesis in vitro.<sup>38</sup> Applications of simple centrifugation were also adapted for bone marrow preparation in human studies. A conventional manual blood bag was applied

using double centrifugation as a chair-side procedure, which demonstrated a satisfactory increase in number of nucleated cells and MSCs at a factor of 7 and 5, respectively.<sup>39</sup>

There are many commercial bone marrow concentration systems introduced in the bio-technology markets in the last 10 years e.g. MarrowStim™, Res-Q™, Harvest®, SmartPreP™, Sepax®, Accelerate®, Cobe 2991, Regenexx™, etc.. The principles of separation are based on either one or two steps centrifugation, with or without the use of a filtration method. Many researchers found that this method is more convenient, less time consuming as well as more user-friendly than other methods. Some machines are designed for multipurpose use of whole blood component separation whereas some are specifically designed for bone marrow concentration. The quantity of marrow fluid required is also variable, e.g. the Harvest® system demands 60 ml of aspirate for centrifugation. Alternatively, MarrowStim™ only requires 27 ml of fluid for centrifugation. These systems can also be used to extract platelet rich plasma and fibrin glue on its own or to supplement BMAC.

## MSC approach for maxillofacial reconstruction

The MSCs approach for bone healing has been used in oral and maxillofacial reconstructions, such as maxillary sinus augmentations. There have been attempts in harvesting from intra-oral sites, such as periosteum and maxillary tuberosity as well.

## Applications of culture-expanded MSC for maxillary sinus grafting

An application of MSCs on a cell-free scaffold is aimed to ensure for more tissue formation and shorten the healing period. Culture-expanded cells seeded on biomaterials have been applied in maxillary sinus augmentations in both animal and human models.<sup>40-46</sup>

In a beagle dog experiment, autogenous osteoblasts were compared with  $\beta$ -TCP and autogenous bone for maxillary sinus grafting. More new bone areas were observed at 4 weeks in beta-tricalcium phosphate ( $\beta$ -TCP) with tissue-engineered bone, although there were no significant differences of new bone among all materials at 12 weeks.<sup>40</sup>

A MSC culture-expanded method for maxillary sinus grafting in humans has also been established.<sup>41</sup> However, intra-oral periosteum-derived MSCs seeded on a bio-material did not show much promising results. More post-operative complications and less bone formation were detected in the periosteum-derived MSCs seeded on polymer fleeces (Ethisorb®) when compared to autogenous bone in 35 patients. In addition, more dental implant failures were also documented, especially in a large volume of augmentations. Zizelmann et al. demonstrated a 90% resorption rate at 3 months post-operation in periosteum-derived MSC seeding on poly-glycolide polylactide (PLGA) scaffolds while autogenous bone revealed a much less resorption rate at 29% only.<sup>42</sup> In contrast, Trautvetter et al. conducted

a study of 5 years follow up using autologous tissue-engineered periosteal bone grafts seeded on a resorbable polymer demonstrated an admirable result in clinical outcomes and radiological assessment.<sup>43</sup> On the other hand, adequate bone formation and acceptable result after dental implantation in grafted maxillary sinus with cultures-expanded bone cells on bovine HA and culture expanded bone marrow derived MSCs on TCP/HA were reported.<sup>44-46</sup>

A meta-analysis of *in vivo* studies about cell-based treatment for maxillary sinus grafting revealed a larger amount of newly formed bone in the cell-based approach group. However, It showed no significant differences from the controls of each study. One of the reasons may be related to the inherent heterogeneity and small sample size of these studies.<sup>47</sup>

## Applications of BMAC in maxillary sinus grafting

Osteogenic potential of BMAC had been confirmed by combining with bovine bone mineral (BBM) and assessed at 8 and 16 weeks after grafting. A split-mouth design,<sup>48</sup> for maxillary sinus grafting in an animal model had been carried out in adult sheep. This study used BMAC obtaining from density gradient separation (FICOLL) and then mixed with bovine bone mineral (BBM). Different control groups were set up for comparison, such as autogenous bone and BBM alone. In the mixed graft group, the histology revealed newly formed bone of 19% and 29% at 8 and 16 weeks. While in autogenous bone group, the newly formed bone was 20% and 16% at the same time point. In addition, the mixed graft demonstrated a considerably faster bone formation at 49% when compared with BBM alone.<sup>49</sup>

Concerning immediate use of BMAC in humans, density gradient (FICOLL) separation for MSCs isolation is a relatively complicated open system when compared with commercially available closed systems. Therefore, a study comparing these two systems was performed using BBM as scaffolds in maxillary sinus grafting in humans. Comparable new bone formation at 19.9% from the closed method and 15.5% from the FICOLL method was found at biopsy at 4 months. It confirms that a closed concentration system can provide a reliable outcome and can replace the FICOLL separation method. The results also showed a shorter healing time as well as achieving dental implant success after grafting.<sup>50</sup> In addition, a report of atrophic maxilla using BMAC plus autologous thrombin and BBM for maxillary sinus grafting supported more bone formation at 26.9% and a shorter healing time in 3 months post-operation when compared with BBM and venous blood.<sup>51, 52</sup> In conclusion, BBM mixed with BMAC provides comparable or higher bone volume than a mixture of BBM and autogenous bone (70:30) in maxillary sinus grafting at 3-4 months post-operation.<sup>53,54</sup>

## Conclusion

Mesenchymal stem cells can be extracted from bone marrow via aspiration methods and applied clinically as a source of osteogenic cells for clinical tissue





engineering. Although the quantity of mesenchymal cells is small, the bone marrow aspirate can be amplified by culture-expansion in the laboratory and transplanted back to the same host with the advantage of no immune-rejection. However, it requires a high quality laboratory to minimise disease transmission. Alternatively, the bone marrow can be separated into different fractions using simple centrifugation methods, either as open or closed systems. Many commercially available closed systems are available for clinical use. Some of the systems have proven that BMAC being used alone or combined with scaffolds can enhance bone formation. This has been tried in animals and in humans that maxillary sinus augmentation with promising results achieved with this clinical tissue engineering method.

## References

- Chen, Y., et al., Mesenchymal stem cells: A promising candidate in regenerative medicine. *The International Journal of Biochemistry & Cell Biology*, 2008. 40(5): p. 815-820.
- da Silva Meirelles, L., et al., Mechanisms involved in the therapeutic properties of mesenchymal stem cells. *Cytokine & Growth Factor Reviews*, 2009. 20(5-6): p. 419-427.
- Jäger, M., et al., Bone Marrow Concentrate: A Novel Strategy for Bone Defect Treatment. *Current Stem Cell Research & Therapy*, 2009. 4: p. 34-43.
- Friedenstein, A.J., et al., Heterotopic of bone marrow. Analysis of precursor cells for osteogenic and hematopoietic tissues. *Transplantation*, 1968. 6(2): p. 230-47.
- Horwitz, E., et al., Clarification of the nomenclature for MSC: The International Society for Cellular Therapy position statement. *Cytotherapy*, 2005. 7(5): p. 393-395.
- Chang, Y.J., et al., Characterization of two populations of mesenchymal progenitor cells in umbilical cord blood. *Cell Biology International* 2006. 30: p. 495-49.
- Gronthos, S., et al., Stem Cell Properties of Human Dental Pulp Stem Cells. *J DENT RES* 2002 81: 531, 2002. 81: p. 531-535.
- Dominici, M., et al., Minimal criteria for defining multipotent mesenchymal stromal cells. The International Society for Cellular Therapy position statement. *Cytotherapy*, 2006. 8(4): p. 315-317.
- Janicki, P. and G. Schmidmaier, What should be the characteristics of the ideal bone graft substitute? Combining scaffolds with growth factors and/or stem cells. *Injury*, 2011. 42: p. S77-S81.
- Yamada, Y., et al., Translational Research for Injectable Tissue-Engineered Bone Regeneration Using Mesenchymal Stem Cells and Platelet-Rich Plasma: From Basic Research to Clinical Case Study *Cell Transplantation*, 2004. 13(4): p. 343-355.
- Ueda, M., et al., Clinical case reports of injectable tissue-engineered bone for alveolar augmentation with simultaneous implant placement. *Int J Periodontics Restorative Dent*, 2005. 25(2): p. 129-37.
- Ueda, M., et al., Injectable Bone Applied for Ridge Augmentation and Dental Implant Placement: Human Progress Study. *Implant Dent* 2008. 17(1): p. 82-90.
- Hibi, H., et al., Alveolar cleft osteoplasty using tissue-engineered osteogenic material. *International Journal of Oral and Maxillofacial Surgery*, 2006. 35(6): p. 551-555.
- Yamada, Y., et al., A novel approach to periodontal tissue regeneration with mesenchymal stem cells and platelet-rich plasma using tissue engineering technology: A clinical case report. *The International journal of periodontics & restorative dentistry*, 2006. 26(4): p. 363-9.
- Marion, N.W. and J.J. Mao, *Mesenchymal Stem Cells and Tissue Engineering*, in *Method in Enzymology* 2006, Elsevier Inc.
- Pittenger, M.F., et al., Multilineage Potential of Adult Human Mesenchymal Stem Cells. *Science*, 1999. 284(143).
- Caplan, A. and J. Dennis, Mesenchymal stem cells as trophic mediators. *J Cell Biochem*, 2006. 98(5): p. 1076-1084.
- Connolly, J., et al., Development of an osteogenic bone-marrow preparation. *J of Bone and Joint Surgery Am*, 1989. 71: p. 684-691.
- Brugge, P.J.t. and J.A. Jansen, *In Vitro* Osteogenic Differentiation of Rat Bone Marrow Cells Subcultured with and without Dexamethasone. *Tissue Engineering*, 2002. 8(2): p. 321-331.
- Goshima, J., V.G. VM, and A. Caplan, The osteogenic potential of culture-expanded rat marrow mesenchymal cells assayed *in vivo* in calcium phosphate ceramic blocks. *Clin Orthop Relat Res*, 1991. 262: p. 298-311.
- Hernigou, P. and F. Beaujean, Treatment of Osteonecrosis With Autologous Bone Marrow Grafting. *Clinical Orthopaedics and Related Research*, 2002(405): p. 14-23.
- Muschler, G.F., et al., Spine fusion using cell matrix composites enriched in bone marrow-derived cells. *Clin Orthop Relat Res*, 2003. 407: p. 102-18.
- Murawski, C. and J. Kennedy, Percutaneous internal fixation of proximal fifth metatarsal bones fractures. *Am J Sports Med*, 2011. 39(6): p. 1295-301.
- Pountos, I., et al., Mesenchymal stem cell tissue engineering: Techniques for isolation, expansion and application. *Injury*, 2007. 38, Supplement 4(0): p. S23-S33.
- Pittenger, M.F., et al., Multilineage Potential of Adult Human Mesenchymal Stem Cells. *Science*, 1999. 284: p. 143-147.
- Hernigou, P., et al., Percutaneous Autologous Bone-Marrow Grafting for Nonunions: Influence of the Number and Concentration of Progenitor Cells *J Bone Joint Surg Am*, 2005. 87: p. 1430-1437.
- Wexler, S., et al., Adult bone marrow is a rich source of human mesenchymal 'stem' cells but umbilical cord and mobilized adult blood are not. *Br J Haematol*, 2003. 121(2): p. 368-74.
- Liu, S., J. Zhang, and L. Pan, Treatment of fresh fractures with autografting of bone marrow. *The Chinese Medical Journal of Metallurgical Industry*, December 1998, Vol. 15 No. 6, 1998. 15(6): p. 332-333.
- Sim, R., T.S. Liang, and B.K. Tay, Autologous marrow injection in the treatment of delayed and non-union long bone. *Singapore Med J*, 1993. 34: p. 412-417.
- Shen, F.H., D. Samartzis, and H.S. An, Cell technologies for spinal fusion. *The Spine Journal*, 2005. 5: p. 2315-2395.
- Lindholm, T.S., D.S. Nilsson, and T.C. Lindholm, Extraskelatal and intraskelatal new bone formation induced by demineralized bone matrix combined with bone marrow cells. *Clin Orthop Relat Res*, 1982. 171: p. 251-5.
- Tiedeman, J.J., et al., Treatment of nonunion by percutaneous injection of bone marrow and demineralized bone matrix. An experimental study in dogs. *Clinical Orthopaedics and Related Research*, 1991(268): p. 294-302.
- Choi, L.S., et al., Bone marrow aspirate with or without platelet concentrates as a bone graft substitute for posterolateral spinal fusion: A randomized, controlled study using an animal model, in 52nd Annual Meeting of the Orthopaedic Research Society. Paper No: 1742.
- Cuomo, A.V., et al., Mesenchymal Stem Cell Concentration and Bone Repair: Potential Pitfalls from Bench to Bedside. *J Bone Joint Surg Am*, 2009. 91: p. 1073-1083.
- Friedenstein, A.J., et al., Bone marrow stromal colony formation requires stimulation by haemopoietic cells *Bone and Mineral*, 1992. 18(3): p. 199-213.
- Das, R., et al., The role of hypoxia in bone marrow-derived mesenchymal stem cells: considerations for regenerative medicine approaches. *Tissue Eng Part B Rev*, 2010. 16(2): p. 159-68.
- Yasuhara, S., et al., Efficacy of Bone Marrow Mononuclear Cells to Promote Bone Regeneration Compared With Isolated CD34+ Cells From the Same Volume of Aspirate. *Artificial Organs*, 2010. 34(7): p. 594-599.
- Thoesen, M., et al., Use of a centrifugation-based, point-of-care device for production of canine autologous bone marrow and platelet concentrates. *Am J Vet Res*, 2006. 67(10): p. 1655-61.
- Sakai, S., et al., Concentration of bone marrow aspirate for osteogenic repair using simple centrifugal methods. *Acta Orthopaedica*, 2008. 79(3): p. 445-448.
- Jianga, X.-q., et al., Sequential Fluorescent Labeling Observation of Maxillary Sinus Augmentation by a Tissue-engineered Bone Complex in Canine Model. *Int J Oral Sci* 2009. 1(1): p. 39-46.
- Voss, P., et al., Bone regeneration in sinus lifts: Comparing tissue-engineered bone and iliac bone. *British Journal of Oral and Maxillofacial Surgery*, 2009.
- Zizelmann, C., et al., Bone formation after sinus augmentation with engineered bone. *Clin. Oral Impl Res*, 2007. 18: p. 69-73.
- Trautvetter, W., et al., Tissue-Engineered Polymer-Based Periosteal Bone Grafts for Maxillary Sinus Augmentation: Five-Year Clinical Results. *Journal of Oral and Maxillofacial Surgery*, 2011. 69(11): p. 2753-2762.
- Fuerst, G., et al., Are culture-expanded autogenous bone cells a clinically reliable option for sinus grafting? *Clin Oral Implants Res*, 2009. 20(2): p. 135-139.
- Mangano, C., et al., Engineered Bone by Autologous Osteoblasts on Polymeric Scaffolds in Maxillary Sinus Augmentation: Histologic Report. *Journal of Oral Implantology*, 2010. 36(6): p. 491-496.
- Shayesteh, Y.S., et al., Sinus augmentation using human mesenchymal stem cells loaded into a B-tricalcium phosphate/hydroxyapatite scaffold. *Oral Surg, Oral Med, Oral Path, Oral Rad, and Endo*, 2008. 106(2).
- Park, J., Use of cell-based approaches in maxillary sinus augmentation procedures. *J Craniofac Surg*, 2010. 21(2): p. 557-560.
- Gutwald, R., et al., Mesenchymal stem cells and inorganic bovine bone mineral in sinus augmentation: comparison with augmentation by autologous bone in adult sheep. *British Journal of Oral and Maxillofacial Surgery*, 2010. 48(4): p. 285-290.
- Sauerbier, S., et al., Mesenchymal Stem Cells and Bovine Bone Mineral in Sinus Lift Procedures—An Experimental Study in Sheep. *Tissue Engineering Part C: Methods*, 2010. 16(5): p. 1033-1039.
- Sauerbier, S., et al., *In Vivo* Comparison of Hard Tissue Regeneration with Human Mesenchymal Stem Cells Processed with Either the FICOLL Method or the BMAC Method. *TISSUE ENGINEERING: Part C*, 2009. 15: p. 1-10.
- Schmelzeisen, R., et al., Making bone II: maxillary sinus augmentation with mononuclear cells-case report. *Br J Oral Maxillofac Surg*, 2010.
- Yildirim, M., et al., Maxillary sinus augmentation using xenogenic bone substitute material Bio-Oss in combination with venous blood. A histologic and histomorphometric study in humans. *Clin Oral Implants Res*, 2000. 11(3): p. 217-29.
- Sauerbier, S., et al., Bone Marrow Concentrate and Bovine Bone Mineral for Sinus Floor Augmentation: A Controlled, Randomized, Single-Blinded Clinical and Histological Trial—Per-Protocol Analysis. *Tissue Engineering Part A*, 2011. 17(17-18): p. 2187-2197.
- Rickert, D., et al., Maxillary sinus floor elevation with bovine bone mineral combined with either autogenous bone or autogenous stem cells: a prospective randomized clinical trial. *Clin Oral Implants Res*, 2011. 22(3): p. 251-8.



MCHK CME Programme Self-assessment Questions

Please read the article entitled "Mesenchymal Stem Cell Approach for Maxillary Sinus Grafting" by Dr Laddawun SUNUNLIGANON and Prof Lim-kwong CHEUNG and complete the following self-assessment questions. Participants in the MCHK CME Programme will be awarded CME credit under the Programme for returning completed answer sheets via fax (2865 0345) or by mail to the Federation Secretariat on or before 30 June 2014. Answers to questions will be provided in the next issue of The Hong Kong Medical Diary.

Questions 1-10: Please answer T (true) or F (false)

- 1. Mesenchymal stem cells are derived from the non-haematopoietic cell fraction of the bone marrow.
2. The differentiation ability of the MSCs deriving from a culture-expanded cell method and a bone marrow concentration method is the same.
3. The optimum number of MSCs for bone regeneration is 1500 progenitor cells/cm3.
4. The centrifugation method is the only way to enrich cell quantity.
5. The centrifugation method is safer than the cell expansion method in generating stem cells in sufficient quantities.
6. The key components for tissue regeneration include the cells, scaffolds and bioactive molecules.
7. Immediate stem cell application requires complicated laboratory support.
8. Maxillary sinus augmentation with bone marrow aspirate concentrate alone promotes better bone healing than its use in combination with scaffolds.
9. Both the culture-expanded cell method and BMAC application can amplify the osteogenic capacity of MSCs.
10. The reason for using BMAC in combination with scaffolds is to provide better bone healing.

ANSWER SHEET FOR JUNE 2014

Please return the completed answer sheet to the Federation Secretariat on or before 30 June 2014 for documentation. 1 CME point will be awarded for answering the MCHK CME programme (for non-specialists) self-assessment questions.

Mesenchymal Stem Cell Approach for Maxillary Sinus Grafting

Dr Laddawun SUNUNLIGANON

DDS (PSU), Grad dip in ClinSc: (OMFS: MU), MDS (OMFS-HKU), PhD(OMFS-HKU), LLB (RU) Assistant Professor, Oral and Maxillofacial Surgery Faculty of Dentistry, Thammasat University, Thailand

Prof Lim-kwong CHEUNG

BDS, PhD, FFD RCS (Irel), FDS RCPS (Glasg), FRACDS, FRACDS (OMS) FHKAM (Dental Surgery), FCDSHK (OMS), FDS RCSEd, FFGDP Specialist in Oral and Maxillofacial Surgery Honorary Clinical Professor, Faculty of Dentistry, the University of Hong Kong

1 [ ] 2 [ ] 3 [ ] 4 [ ] 5 [ ] 6 [ ] 7 [ ] 8 [ ] 9 [ ] 10 [ ]

Name (block letters): \_\_\_\_\_ HKMA No.: \_\_\_\_\_ CDSHK No.: \_\_\_\_\_

HKID No.: \_\_\_ - \_\_\_ X X (X) HKDU No.: \_\_\_\_\_ HKAM No.: \_\_\_\_\_

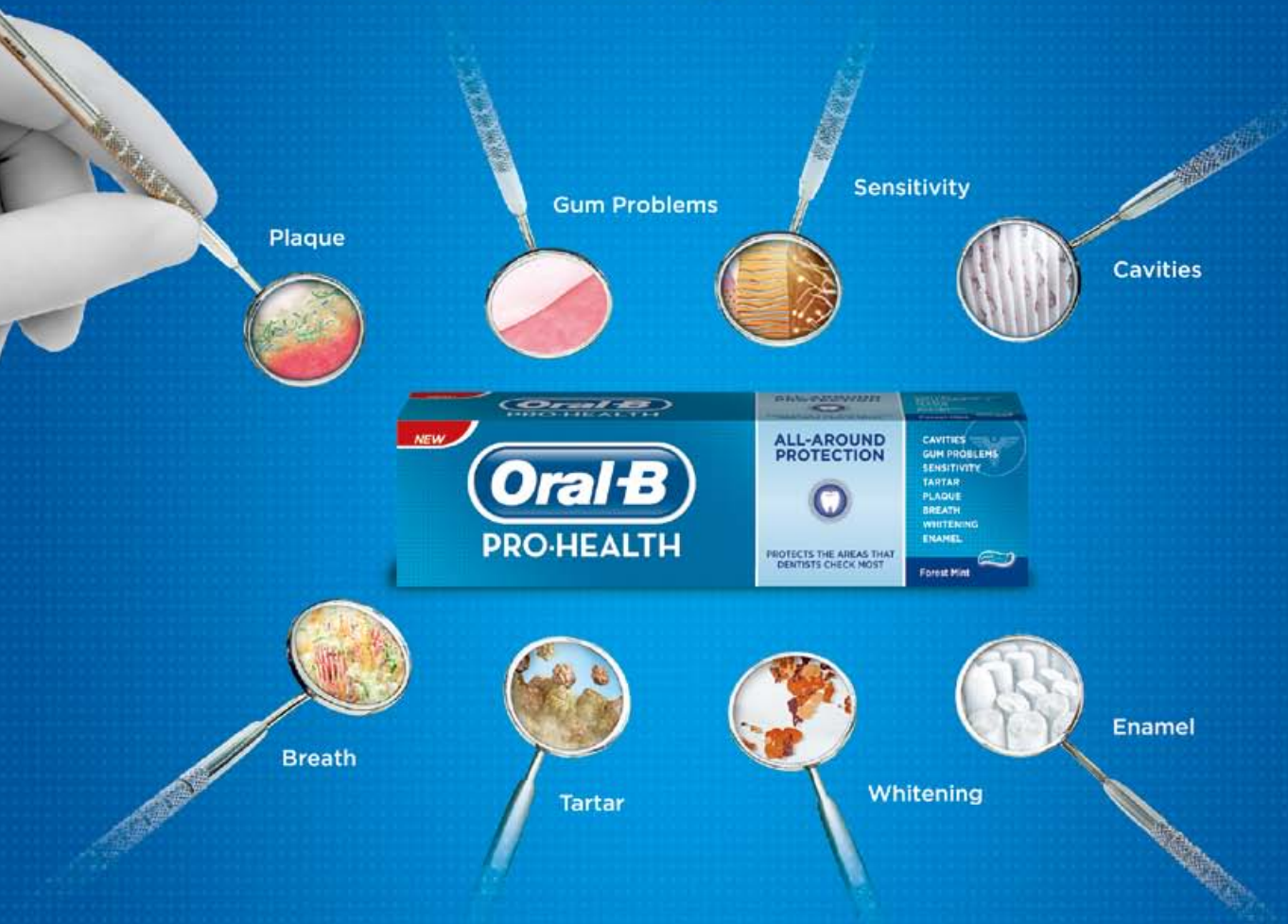Contact Tel No.: \_\_\_\_\_ MCHK No.: \_\_\_\_\_ (for reference only)

Answers to May 2014 Issue

Growth Hormone Treatment for children and adolescents in Hong Kong

- 1. F 2. T 3. T 4. F 5. F 6. F 7. T 8. T 9. F 10. F

In HK, only Oral-B has stabilised  
Stannous & Fluoride System to offer you  
an unbeatable range of benefits.\*



Oral-B PRO-HEALTH features a breakthrough formulation of **Stabilised Stannous & Fluoride System**. Many years of research and numerous clinical studies have enabled this biggest innovation in 60 years.<sup>1</sup>

For more information of Oral-B PRO-HEALTH, please contact your professional representative.  
[www.oralb.com](http://www.oralb.com)

<sup>1</sup> References available on request

\* based on these areas that dentists check most.

continuing the care that starts in your chair



## Dental Care to Older People in Hong Kong

### Dr Frankie HC SO

BDS, MDS, FCDSHK(ComDent), FHKAM(Dental Surgery)  
Dental Officer, Department of Health, HKSAR Government

### Prof Edward CM LO

BDS, MDS, PhD, FCDSHK(ComDent), FHKAM(Dental Surgery)  
Chair Professor, Faculty of Dentistry, University of Hong Kong



Dr Frankie HC SO

Prof Edward CM LO

Ageing of the population is posing challenges to the medical as well as the dental health professionals Hong Kong. The Oral Health Survey (OHS) 2011 conducted by the Department of Health found that the older adults in Hong Kong receiving long-term care (LTC users) not only had fewer teeth remaining compared with the non-institutionalised older persons (NOP), but also had a higher proportion of their remaining teeth affected by untreated dental caries.<sup>1</sup> The caries in a high proportion of these decayed teeth was so severe that the crowns were completely destroyed with only the roots retained (Table). While the smaller mean number of remaining teeth among the LTC users can be partly explained by the higher proportions of subjects older than 74 years in this group, the higher proportion of teeth with advanced caries is likely related to the physical and cognitive impairments commonly found in the LTC users.

Table. Tooth loss and dental caries among different groups of older adults in Hong Kong.

	NOP	HCCS users	DE users	IOP
Age (years)	65-74	65+	65+	65+
% with no natural teeth	5.6%	26.9%	19.3%	29.6%
Mean no. of remaining teeth	19.3	10.3	12.5	9.4
Mean no. of decayed teeth	1.3	2.3	2.2	3.0
Mean no. of retained root	0.5	1.4	1.4	2.0

Source: Oral Health Survey 2011

Since most of the IOP have impaired health status and poor social and financial support, it is not surprising that they have great difficulties in accessing traditional dental care services. Outreach dental services have been shown to be a feasible way to provide the needed preventive and simple curative dental care to the IOP in Hong Kong.<sup>2</sup> Recognising the oral health implications of population ageing, the government introduced a 3-year pilot project in 2011 to support non-governmental organisations (NGO) to provide basic dental care services to the IOP and DE users. Thirteen NGOs with a total of 24 outreach dental teams participated in this pilot project.<sup>3</sup> The outreach dental teams provided basic dental care (such as examination, prevention, scaling and training to caregivers) in the elderly homes for the IOP using portable dental equipment and instruments. Arrangements were also made to provide treatments to the IOP, as indicated, in the dental clinics of the NGOs. As announced in the Policy Address 2014, the pilot project will be converted into a regular programme starting from the financial year 2014-15.

Another recent development in the provision of dental care to the older people in Hong Kong is the support

from the Community Care Fund to subsidise the older people who are not CSSA (Comprehensive Social Security Allowance) recipients but are receiving home care services to receive denture and other related necessary dental treatments from private and NGO clinics.

While dental health professionals are working hard to enhance the provision of dental services to the older people in Hong Kong, health professionals working in primary health settings should recognise that prevention of dental diseases is equally important in the promotion of oral health for the older population. Dental caries and periodontal diseases are in fact preventable by adoption of healthy life-styles such as effective brushing of teeth twice daily with fluoride toothpaste, adopting a good dietary habit by reducing the frequency of intake of sugar-rich food or drinks, and refraining from smoking. Adoption of healthy lifestyles can prevent dental diseases, as well as the discomfort and sufferings, and the time and cost that have to be spent consequential to the dental diseases. Thus, public health efforts should be placed on the promotion of the healthy lifestyles among the older adults in Hong Kong.

However, physical and cognitive impairments may render the affected persons unable to perform good oral hygiene self-care and unable to seek professional dental care services. This may result in development of dental caries and periodontal disease, and the diseases being untreated. Providing dental treatments to physically or cognitively impaired older people is challenging. The amount of stress involved in undergoing dental treatment can pose health risks to some medically compromised elderly patients and limit the potential benefit of the treatment. In some cases, the patient's medical or cognitive status may even make it impossible to deliver dental treatment in a normal setting.<sup>4</sup> The OHS 2011 found that 21% of the institutionalised older persons (IOP), 6% of the day care centres for the elderly users (DE) and 7% of the home and community care services users (HCCS) assessed as requiring dental treatment were, in the examining dentists' view, not suitable for treatment. Dentists involved in providing dental care services to physically or cognitively impaired elders frequently face the ethical dilemma between adopting the practical or the ideal approaches, with the former bearing the risk of inadequate care while the latter having the risk of overtreatment.<sup>5-7</sup> A good way to prevent such ethical dilemma is to reduce the curative treatment need by commencing prevention of dental diseases through medical-dental collaboration as early as possible in the trajectories of physical and cognitive impairment.

<sup>1</sup>Older LTC users include institutionalised older persons (IOP), users of Day care centres / units for the Elderly (DE), and users of home and community care services (HCCS).



The most commonly found chronic conditions associated with physical or cognitive impairment among the IOP were stroke and dementia.<sup>8</sup> It has been shown that impaired manual dexterity had affected the stroke survivor's ability to clean their teeth, and the periodontal health of a group of Hong Kong older stroke survivors on hospital discharge and six months later was poorer than the community dwelling healthy control group.<sup>9</sup> Dental professionals should be involved at the early stage of multi-disciplinary care of demented older adults and stroke survivors to enhance their overall care. The recently published Seattle Care Pathway stressed the importance of communication to dentists involved in the multi-disciplinary care of dependent older persons.<sup>10</sup> When providing dental care services to the elders, emphasis should be placed on early identification of risks to oral health, management of oral problems with consideration of viability of oral health, and aggressive prevention to prevent the onset of oral diseases.

Medical and health care providers in primary care settings can contribute to the prevention of dental diseases for older people. It is glad to see the inclusion of oral hygiene promotion and periodical assessment for oral health problems in the "Hong Kong Reference Framework for Preventive Care for Older Adults in Primary Care Settings".<sup>11</sup> Dental care to elders in Hong Kong should involve close collaboration between the medical and the dental health professionals, with an aim to achieve better general and oral health of the present and the coming cohorts of older people in Hong Kong.

### References

1. Department of Health. Report on Oral Health Survey 2011. Hong Kong: Department of Health, 2013.
2. Lo ECM, Luo Y, Dyson JE. Outreach dental service for persons with special needs in Hong Kong. *Special Care Dent* 2004;24:80-85.
3. Dental care policy and pilot project on outreach primary dental care services for elderly in residential care homes and day care centres. LC Paper No. CB(2)1315/12-13(05). (<http://legco.gov.hk/yr12-13/english/panels/hs/agenda/hs20130617.htm>) Accessed 7 May 2014
4. Ettinger RL. Rational dental care: Part 1. Has the concept changed after 20 years? *J Can Dent Assoc* 2006;72:441-445.
5. Bryant SR, MacEntee MI, Browne A. Ethical issues encountered by dentists in the care of institutionalized elders. *Spec Care Dent* 1995;15:79-82.
6. Chen X, Chen H, Douglas C, Preisser JS, Shuman SK. Dental treatment intensity in frail older adults in the last year of life. *J Am Dent Assoc* 2013;144:1234-1242.
7. MacEntee MI, Mathu-Muju KR. Confronting dental uncertainty in old age. *Gerodontology* 2014;31:37-43.
8. Census and Statistics Department. Socio-demographic profile, health status and self-care capability of older persons. Thematic Household Survey Report No.40. Hong Kong: Census and Statistics Department, 2009.
9. Pow EHN, Leung KCM, Wong MCM, Li LSW, McMillan AS. A longitudinal study of the oral health condition of elderly stroke survivors on hospital discharge into the community. *Int Dent J* 2005;55:319-324.
10. Pretty IA, Ellwood RP, Lo ECM, MacEntee MI, Müller F, Rooney E et al. The Seattle Care Pathway for securing oral health in older patients. *Gerodontology* 2014;31:77-87.
11. Department of Health. Hong Kong Reference Framework for Preventive Care for Older Adults in Primary Care Settings. Hong Kong: Department of Health, 2013.

**CERTIFICATE COURSE FOR HEALTH PROFESSIONAL CME / CNE Course Course No. C233**

## Certificate Course on Occupational Hygiene Practice 2014

Jointly organised by



The Federation of  
Medical Societies of  
Hong Kong



Hong Kong Institute of  
Occupational and  
Environmental Hygiene

Date	Topics	Speakers
16 July	Exposure risk assessment and ventilation controls of Chemicals in Health-care	Mr. Mo-tsun TO <i>Health, Safety and Environment Manager The Hong Kong University of Science and Technology</i>
23 July	Emergency preparedness and response to chemical incidents	
30 July	Common cancers in Hong Kong and the related occupation and environment	Prof. Shelly TSE <i>Associate Professor JC School of Public Health and Primary Care The Chinese University of Hong Kong</i>
6 Aug	Radiation hazards and controls	Mr. Sung-tat YIP <i>Laboratory Safety Officer (Radiation) University Safety Office The Chinese University of Hong Kong</i>
13 Aug	Infection control and ventilation	Mr. Tai-wa TSIN <i>Adjunct Assistant Professor, School of Public Health The Chinese University of Hong Kong Adjunct Associate Professor, The University of Hong Kong</i>
20 Aug	OSH Management for Health Care Facilities	Mr. Yuk-wah LAI <i>Senior Nursing Officer &amp; Hospital OSH Coordinator Kwong Wah Hospital</i>

**Enquiry :** The Secretariat of The Federation of Medical Societies of Hong Kong  
Tel.: 2527 8898 Fax: 2865 0345 Email: [info@fmshk.org](mailto:info@fmshk.org)

Enhancing the practice of primary care physicians as our goal to serve the medical profession and the Society

## Postgraduate Diploma in Diagnosis and Therapeutics in Internal Medicine (PDipIntMed&Therapeutics)

醫學內科診斷及治療深造文憑

Calling for Enrolment in September 2014

A Quotable Qualification by  
The Hong Kong Medical Council

#### PROGRAM FEES

Composition fee for the 2-year program is HK\$23,000 (subject to approval)

#### ADMISSION REQUIREMENTS

Holder of a primary medical degree with post registration experience of no less than 12 months

To submit an application:

On-line: <http://www.medic.hku.hk/postdip.htm>

#### DEADLINE OF APPLICATION

31 August 2014

#### VENUE

William MW Mong Block  
Faculty of Medicine Building  
21 Sassoon Road  
Pok Fu Lam, Hong Kong

#### ORGANIZER

Department of Medicine  
The University of Hong Kong  
Queen Mary Hospital, Hong Kong



LI KA SHING FACULTY OF MEDICINE  
THE UNIVERSITY OF HONG KONG

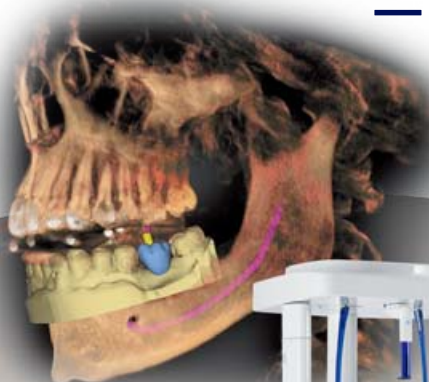
香港大學李嘉誠醫學院

## Prosthetic driven Implantology

## — Digital Dentistry



made  
in  
Germany



ORTHOPHOS XG 3D  
- Digital Imaging System

CEREC - Chairside Solution

Sirona Dental Systems (HK) Ltd.  
Add: Room 2712, 27/F, K. Wah Center, 191 Java Road  
North Point, Hong Kong  
Tel: +852-2115 9884 Fax: +852-2115 9994

The Dental Company

sirona



# Cracked Tooth – a Syndrome or Conundrum?

**Prof Gary SP CHEUNG**

BDS, MDS, MSc(London), PhD, FHKAM(Dental Surgery), FCDSHK(Endodontics), FRACDS, FAMS, FDSRCS(Edinburgh)

Postgraduate Programme Director in Endodontics & Associate Dean (Undergraduate Education)  
University of Hong Kong Faculty of Dentistry



Prof Gary SP CHEUNG

The term, *Cracked Tooth Syndrome*, was coined by Dr Cameron, who published in the Journal of American Dental Association in 1964, to describe a painful condition arising from cracking of the coronal portion (crown) of a tooth that manifests as chewing pain with episodes of sensitivity to cold or digital pressure.<sup>1</sup> Other terms that have been used to describe a similar condition include: cuspal fracture odontalgia, fissural fracture, incomplete tooth fracture, greenstick fracture, incomplete crown-root fracture, and cracked cusp syndrome.<sup>2</sup>

A syndrome is defined as “a group of signs and symptoms that occur together and characterise a particular abnormality or condition” (Merriam-Webster Dictionary). On the other hand, cracked teeth can give rise to a myriad of symptoms that may roughly correspond to the extent of crack propagation (Table 1).<sup>3</sup> Hence, it does not really fit into the classic definition of a *syndrome*. From a review of the literature, *Cracked Tooth Syndrome* often refers to the manifestation of incomplete (akin to greenstick) fracture of the crown of a vital tooth; this meaning will be used whenever the term is mentioned below. The purpose of this article is to suggest the approach for diagnosis and the principle of management of a cracked tooth.

## The crack origin

Many dental cracks first appear as an extension of the natural fissure pattern on a tooth (Fig. 1), or at the base of a cavity beneath a dental filling (Fig. 2). The direction of crack propagation depends on the location of its origin and the thickness of the dentine or cavity wall. Those cracks extending vertically down the tooth root (to variable depths) tend to associate with more symptoms (Fig. 3); whereas for teeth with a large restoration the crack tends to be more superficial,<sup>4</sup> and usually leads to cuspal fracture (Fig. 4).

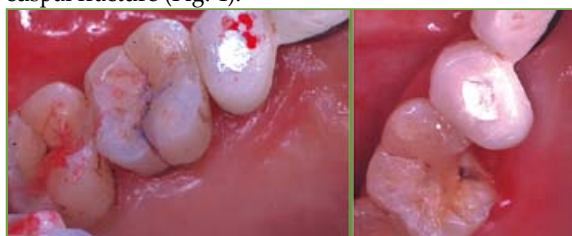

Fig. 1 (LEFT) Patient complaining of mild, diffuse pain on chewing and sensitivity to cold, but clinical examination failed to reveal anything significant. Notice that the staining on the palatal fissure of the upper first molar was not removed and microscopic examination was not performed. (RIGHT) Patient returned about 2 weeks later reporting a broken tooth, as well as disappearance of the symptoms. [Acknowledgment: Diagrams from HKDA Newsletter (2012)<sup>3</sup>; reprinted with permission.]

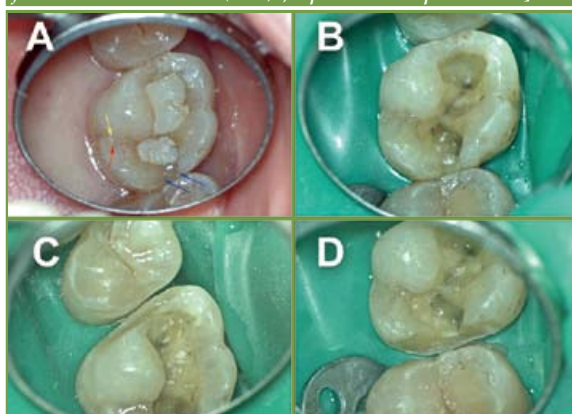
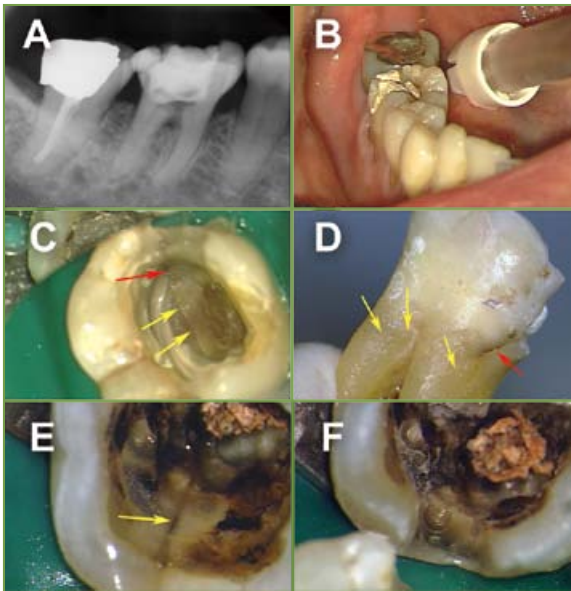


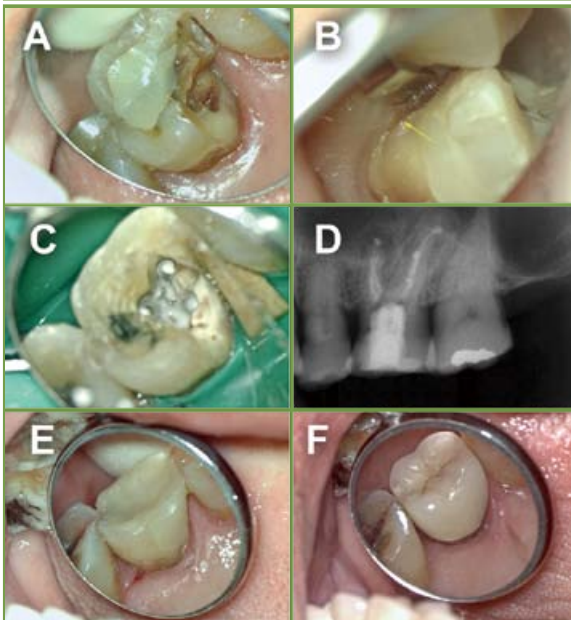
Fig. 2 Patient complaining of poorly defined pain on chewing with no temperature sensitivity affecting mostly the right side: (A) her upper right first molar had a palatal crack line [red arrow] that detoured from the original fissure [yellow]; there were also a pair of crack lines [blue] at the distal marginal ridge with underlying grey-brownish coloration. (B) Removal of the filling revealed a stained crack running along the cavity floor in the mesial-distal direction. Axial reduction showed that the crack ended above gingival sulcus on the mesial (C), and distal (D) surface, indicating a good prognosis after full coverage restoration.

Table 1 Variation of symptoms for different stages of tooth cracking\*

Crack extent	Visible features	Symptoms
Craze line	Enamel only; generally straight and vertical (occlusal-gingival) oriented	<ul style="list-style-type: none"> <li>• Nil</li> </ul>
Cracked tooth	Magnification; staining; wedge (biting) test; transillumination (May need to remove existing restoration for visualisation of the crack)	<ul style="list-style-type: none"> <li>• Variable symptoms depending on extent of cracking and pulpal involvement</li> <li>• Usually, sharp pain on chewing</li> <li>• Some with (unexplained) sensitivity to cold and, for severe case, heat</li> <li>• Isolated deep pocket (when there is breakdown of periodontium approximating the crack)</li> </ul>
Fractured cusp	Visual (magnification); probing to check for mobile fragment; transillumination	<ul style="list-style-type: none"> <li>• Pain on chewing</li> <li>• Symptoms of dentine sensitivity or inflamed pulp</li> <li>• Fragment might be felt as mobile, or actually dislodged</li> </ul>
Split tooth	Visual; staining; probing to check for mobile fragment	<ul style="list-style-type: none"> <li>• Pain (usu. dull) on chewing</li> <li>• Fragment felt to be mobile</li> </ul>
Vertical (apical) root fracture	Radiograph (limited usefulness); operating microscope; explorative surgery	<ul style="list-style-type: none"> <li>• Pain (usu. dull) on chewing</li> <li>• Isolated deep pocket(s)</li> <li>• Sinus (sometimes multiple sinuses arising from same tooth)</li> </ul>

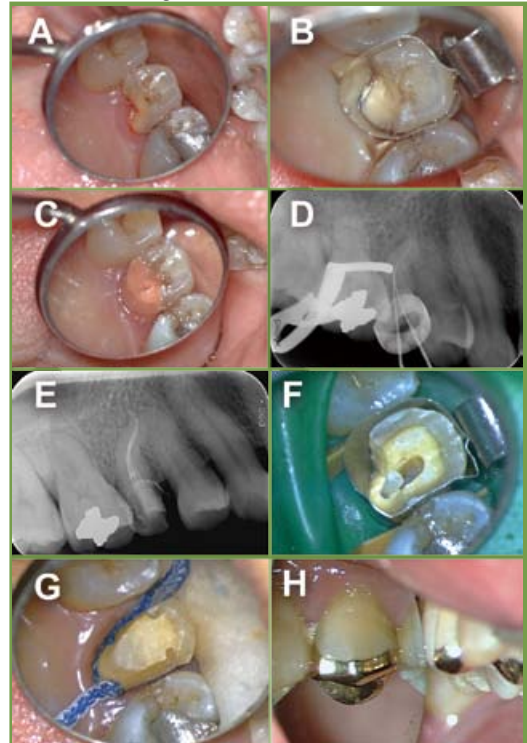


**Fig. 3** (A,B) Patient referred for tenderness in chewing on the right side; root canal treatment of the lower right first molar was attempted with little improvement. (C,D) On removal of the filling, a crack line [arrows] that was partly stained [red arrow] was noted running across the floor of the pulp chamber in the mesial-distal direction; the tooth was extracted revealing the extent of cracking. (E) The filling in the lower second molar was also removed revealing a crack [arrow] along its mesial surface; the crack was traced and removed (F).



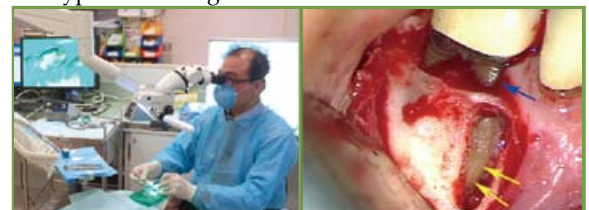**Fig. 4** Patient reported a catastrophic fracture of a previously-restored upper left first molar (A), with pain and obvious exposure of the pulp. (B) Microscopic examination of the extent of crack [arrow indicating the apical-most extension on the tooth surface] was paramount to determine the prognosis of restoration. (C,D) The tooth was isolated for root canal treatment and, finally, restored with a composite resin build-up (E), followed by a full-coverage crown (F).

and is poorly localised. There may be some sensitivity to hot or cold, which cannot be traced to any dentine sensitivity due to gingival recession or an exposed root surface. The obscure symptoms are often forgotten until the patient experiences a sharp, intense pain during a meal when s/he then notices a broken piece falling off from the tooth (Fig. 1 and 5).



**Fig. 5** Patient reported a catastrophic fracture of the upper right second premolar (A), with pulp exposure and intense pain on touching the site; patient did not recall any previous symptoms or warning signs. The fracture area could be isolated (B) and temporarily restored (C). Then, a stainless-steel plain orthodontic band was cemented before commencing root canal treatment (D). After obturation, a fibre-post was placed in the palatal canal for foundation build-up (E,F). The tooth was finally prepared (G), for a three-quarter crown to preserve the tooth structure on its buccal aspect (H).

Cracks can also originate from the tip of the root and travel coronally (Fig. 6). Yeh<sup>5</sup> described a phenomenon of fatigue cracking of the root of vital teeth that extends from the root apex towards the crown. This condition seems to affect mostly Asians, especially in teeth with short and slender roots.<sup>6</sup> Its usual symptom is pain on chewing, but temperature sensitivity seldom occurs for this type of cracking.



**Fig. 6** (RIGHT) Use of a surgical operating microscope during dental treatment; (LEFT) Examination of the root surface at 16x magnification during periapical surgery showing a root fracture [yellow arrows] extending from the root tip toward the crown, with no cracking at the neck of the tooth [blue arrow].

The pain arising from an incomplete crown fracture is usually vague. Indeed, there may not be any discomfort if the crack has not extended into dentine. For those with dentine involvement, the discomfort initially is neither spontaneous nor severe, is triggered by chewing,





## Differential Diagnosis

*Cracked tooth syndrome* is difficult to diagnose, due to the dimension of the defect (if any) and the nature of pain that may arise. Pain from a cracked, vital tooth originates from the dental pulp, which typically is poorly localised. The pain is often referred to other area(s) innervated by the trigeminal nerve on the same side. Some other conditions may give rise to similar symptoms and should be considered when formulating the diagnosis (Table 2).

## Diagnosis of cracks: a shift in paradigm

A good knowledge of the symptomatology is the first step in the diagnosis of dental cracks. Clinically, symptoms from cracked teeth are pain on chewing and unexplained sensitivity to thermal changes.<sup>2</sup> However, due to the poor localisation of the pain, special investigations are usually required to identify the offending tooth.

The so-called “wedge test” is commonly advocated, which is done by placing a firm object against a suspected cuspal incline and asking the patient to bite. A bi-convex rubber disk, golf-tee, or a “tooth slooth” has been advocated for this purpose. With controlled wedging of the tooth, a positive response (in the form of pain on release of pressure) would indicate the presence of a crack. Another method is by transillumination, or through the use of a dye, such as methylene blue. At times, the crack line is already stained by chromogenic oral bacteria, food or drink (Fig. 3D). For cracks situated in a restored tooth, they may only be visualised after the overlying restoration has been removed (Fig. 2). Once diagnosed, direct observation of the fracture line is required to: (i) confirm its presence and location; and (ii) assess the crack extension which governs the prognosis.

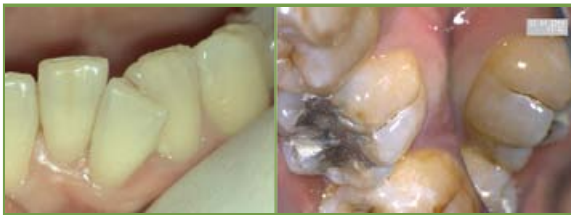A crack is dimensionally small and often escapes attention during visual examination with naked eyes. Magnification and good illumination are paramount for accurate diagnosis of any cracking of the coronal tooth structure, especially when the affected part remains firmly attached and has not fractured off. A surgical operating microscope is an ideal tool (Fig. 6), as a magnification of 16x or above is preferred. Important findings include not only the location and orientation

of the crack, but also any subtle changes in colour of the adjacent and subjacent tooth structure. Prior to microscopic examination, the tooth surface should be free of plaque and dry. Below are some common microscopic appearances that one may observe.

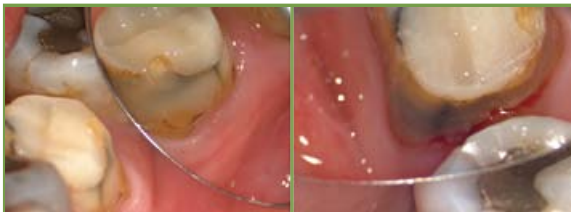- (1) Enamel cracks or craze lines – limited to the enamel layer, linear, usually vertically oriented, with no symptoms, crevice (gap) or subsurface coloration (Fig. 7). A small risk of underlying pathology or crack extension is anticipated, and no treatment is required.
- (2) Wedge-shaped defects, stained or filled with debris (Fig. 8) – this type of cracking is usually associated with clinical symptoms, if the dental pulp has not already become necrotic. It is important to incorporate and completely include the apical extent of the crack to ensure longevity of the restored tooth (Fig. 8). Root canal treatment is required, as the pulp is inflamed and giving rise to variable degree of pain. Failing to reveal and incorporate the entire extent of the crack usually means that the restorative prognosis is uncertain.
- (3) Crack lines that detour from anatomical grooves (Fig. 2A) – if such line is limited to one location of the tooth, and in the absence of subjacent coloration or symptoms, then it may be observed and reviewed regularly. Any overlying restoration should be removed for examination
- (4) Pairs of cracks that outline part of the cusp or marginal ridge, with subjacent coloration (Fig. 2). This usually indicates a significant risk of associated pathology and extension of the fracture involving the root. It is advisable to trace such cracks and determine the “restorability” of the tooth.
- (5) Split teeth – that is, crack extending across the entire occlusal surface (mesial-distally for “naturally occurring” cracks, or buccal-lingually for fractures induced by overzealous use of spreaders in COLD lateral compaction of gutta-percha). There is usually little problem in identifying a split tooth. Once diagnosed, any split tooth has to be extracted.

Table 2. Summary of symptoms for some selected conditions that may give rise to pain on biting

	Pain on chewing	Pain intensity	Ability to pin-point the pain location	Hot/cold sensitivity	Pain disturbs sleep	Mobility of offending tooth	Others
Cracked tooth syndrome	+	++ (sharp, on biting only)	No	+ to +++ (variable depending on pulpal status)	+/- (depending on pulpal status)	No (Fractured part may be mobile)	Long-standing deep crack may give rise to an isolated deep pocket
Acute irreversible pulpitis	+/-	+++ (spontaneous)	No	+++ (Lingering pain, even after removal of stimulus)	Yes	No	
Acute apical abscess	+++	+++ (spontaneous)	Yes	+/-	+/-	+	Tooth appears “high”, compared with neighbouring teeth
Periodontal abscess (adv. perio. disease)	+	+	Yes	+/-	No	++	Generalised loss of periodontal attachment
Myofascial pain dysfunction	++	+ to +++ (Diffuse, radiating, long-lasting)	No	+/-	+/-	+/-	Pain on palpating the masticatory muscles



*Fig. 7 (LEFT) Craze lines running vertically along the enamel surface of the lower incisors; the one on the lower left central incisor had acquired some stains. (RIGHT) Enamel crack extending from the apical end of the buccal fissure of a lower molar.*



*Fig. 8 Wedge-shaped cracks on the mesial-buccal (LEFT) and distal-lingual (RIGHT) corners of a lower left first molar, both ending above the gingiva.*

**References**

1. Cameron CE. Cracked tooth syndrome. J Am Dent Assoc 1964; 68: 405-11.
2. Kahler W. The crack tooth conundrum: Terminology, classification, diagnosis and management. Am J Dent 2008; 21(5): 275-282.
3. Cheung GSP. Dental cracks: endodontic and restorative challenge. HKDA Newsletter 2012; 3: 11-14.
4. Roh BD, Lee YE. Analysis of 154 cases of teeth with cracks. Dent Traumatol 2006; 22: 118-123.
5. Yeh C-J. Fatigue root fracture: a spontaneous root fracture in non-endodontically treated teeth. Br Dent J 1997; 182(7): 261-216.
6. Chan CP, Tseng SC, Lin CP, et al. Vertical root fracture in nonendodontically treated teeth – A clinical report of 64 cases in Chinese patients. J Endod 1998; 24(10): 678-681.
7. Tan L, Chen NN, Poon CY, et al. Survival of root filled cracked teeth in a tertiary institution. Int Endod J 2006; 39(11): 886-889.
8. American Association of Endodontists. Cracking the cracked tooth code: Detection and treatment of various longitudinal tooth fractures. Colleagues for Excellence 2008 summer; internet document (assessed 1/5/2014): [http://www.aae.org/uploadedfiles/publications\\_and\\_research/endodontics\\_colleagues\\_for\\_excellence\\_newsletter/ecfesum08.pdf](http://www.aae.org/uploadedfiles/publications_and_research/endodontics_colleagues_for_excellence_newsletter/ecfesum08.pdf).

**Management**

At present, there is no technology that can join or “fuse” two parts of a tooth together without leaving a gap or porous interface. The principle of managing the cracked tooth is to protect the crack (gap) from bacterial colonisation and further propagation. This is typically done by fitting a full-coverage crown that encircles the entire crack beyond its apical extent. Thus, being able to visualise the apical end of the crack line is important (Fig. 4).

Any crack line that is associated with an adjacent, isolated, deep pocket would indicate the presence of periodontal breakdown as a result of an infected gap or crevice. Such tooth can hardly be maintained without continuous loss of attachment; extraction is advisable.

The survival rate of teeth with variable crack extension and restored with a full-coverage crown has been estimated to be 85% over a 2-year period.<sup>7</sup> Those extending to the root tended to have a higher odds of failure, although that failed to attained statistical significance in that study because of the small sample size. Exploring and incorporating the whole extent of the crack should improve the longevity. Teeth that have already fractured should be assessed for “restorability”; every effort should be directed to preserve the remaining tooth structure (Fig. 5).

The American Association of Endodontists published a classification of dental cracks: craze line, fractured cusp, cracked tooth and split tooth.<sup>8</sup> This article is not aimed to provide an elaborated account of these various types of cracks but, hopefully, the examples here will help to improve the understanding in the diagnosis and management of cracked teeth. In summary, dental cracks that have not involved the root can be managed successfully with the tooth predictably maintained, if diagnosed early and accurately.

Classified Advertisement

Rental /  
For Sale

Vacancies

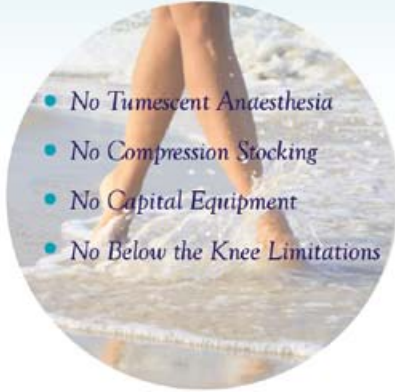Commencement  
of Practice

Please contact the Federation Secretariat at **2527 8898**  
for placement of classified advertisement.



The VenaSeal Saphoon Closure System uses an advanced medical adhesive to safely and effectively close the diseased vein segment. The procedure can be performed in an office-based setting with virtually no time away from work, and rapid relief of symptoms.

## The future of Varicose Veins Treatment... Today



- No Tumescant Anaesthesia
- No Compression Stocking
- No Capital Equipment
- No Below the Knee Limitations

VenaSeal eliminates the need for tumescant anaesthesia and pre-procedure sedatives.

A small bandage will be placed at the access site after the VenaSeal procedure. The patient is able to return to normal activities immediately following the treatment and there are no special precautions need to take.

Immediate relief of the uncomfortable symptoms and visible varicose veins are routine reported by patients receiving treatments.



Distributor  
**Synapse Therapeutics Limited**  
 Unit 902, 9/F, Exchange Tower  
 33 Wang Chiu Road, Kowloon Bay  
 Kowloon, Hong Kong  
 Tel : +852 3188 1538  
 Fax : +852 3188 4466  
 Email : info@synapse.com.hk

**CME/CNE Course**

**Certificate Course for Healthcare Professionals**

**Course No. C235**

# Certificate Course on Lean for Healthcare

Jointly organised by



The Federation of Medical Societies of Hong Kong



Six Sigma Institute

Date	Topics	Speaker
4 July	<ul style="list-style-type: none"> <li>• Introduction to Lean Concept for Healthcare</li> <li>• Selecting Improvement Opportunities</li> <li>• Case Example</li> <li>• Map the Value Stream – Current State</li> <li>• Group Exercise - Blood Draw Case I</li> <li>• Identification of Individual Project</li> </ul>	<p>Dr. Y. K. CHAN            Chairman of Six Sigma Institute</p>
11 July	<ul style="list-style-type: none"> <li>• Evaluate Current State and Identify Improvement Actions</li> <li>• Map the Value Stream – Future State</li> <li>• Implement Actions and Compare Results</li> <li>• Group Exercise - Blood Draw Case II</li> </ul>	
18 July	<ul style="list-style-type: none"> <li>• Presentation – Individual Projects</li> <li>• Case Example 1 –Recovery Room Time</li> <li>• Case Example 2 - Long Queuing Time for Patient Blood-taking</li> <li>• Exercise 1 - 改進藥房的服務能力</li> <li>• Exercise 2 - 注射流感疫苗</li> </ul>	

**Enquiry :** The Secretariat of The Federation of Medical Societies of Hong Kong  
 Tel.: 2527 8898 Fax: 2865 0345 Email: info@fmsk.org

# Prosthodontic Management of Edentulous Patients

## Dr Tsz-leung WONG

BDS, FRACDS, MDS, AdvDipProsthodont, MRD RCSEd (Pros), FCDSHK (Pros), FHKAM (Dental Surgery)

Senior Dental Officer, Dental Service, Department of Health, HKSAR Government  
Hon. Clinical Assistant Professor, Oral Rehabilitation, Faculty of Dentistry, HKU



Dr Tsz-leung WONG

## Introduction

Edentulism (total tooth loss) is generally the result of removal of all teeth because of dental caries (tooth decay) and periodontal disease. It is a condition that can represent considerable disability. Its prevalence varies across countries. It is the trend in the developed countries that people retain more teeth in advanced age. Hong Kong is no exception. This can be shown by the local territory-wide survey among the elderly group (non-institutionalised, aged 65 to 74) that the rate of edentulism drops from 8.6% in 2001 to 5.6% in 2011.<sup>1</sup> This can be explained partly by the changes in extraction practices among the dental profession, but more importantly, reflects the increased dental awareness and improved oral health among the population.

On the other hand, the average life expectancy of Hong Kong people is among the longest in the world and with improved community health services, continuously increasing. According to the Census and Statistics Department, there were 13% of the population aged over 65 in 2011 but it is projected to rise to 30% in 2041. Therefore, with this growing ageing population in Hong Kong, the need for prosthodontic treatment (tooth replacement) for the edentulous patients will not decrease, despite the lowering effect of declining rates of edentulism.

## Conventional removable dentures

Extensive tooth loss affects not only the chewing function and appearance of patients but also their nutrition and quality of life. A set of upper (maxillary) and lower (mandibular) removable complete (full) dentures have long been the only prosthodontic solution in oral rehabilitation to those with total tooth loss before the introduction of implants. In contrast to the removable partial dentures that may have wire clasps to gain retention from the remaining teeth, complete dentures basically rely on their close adaptation to the oral mucosal tissues for support and through the "suction effect" to retain them in position during function.

**Functional performance and patient satisfaction** Studies showed the chewing function of complete denture wearers is about 20% of the chewing function of patients with natural dentition.<sup>2</sup> To achieve a successful outcome of treatment with conventional complete dentures, strong emphasis has been placed to follow traditional prosthodontic rules to optimise retention, support & stability of the dentures. Yet, there is no

evidence that a more complex fabrication technique, e.g. facebow registration or use of a sophisticated articulator, results in a better clinical outcome.<sup>3</sup> Interestingly, Carlsson found that there is poor correlation between the quality of dentures and patient satisfaction. Psychosocial factors, especially a good relationship between the dentist and the patient, are more important than prosthodontic factors for a positive outcome.<sup>3</sup> Most complete denture wearers report satisfaction with denture usage.<sup>4</sup> But, not all edentulous patients are able to adapt to their dentures even if their dentures are made by the most exacting technique and fulfil all conventional prosthodontic criteria.<sup>5</sup>

Common reasons for those not satisfied are pain or discomfort associated with denture wearing, poor denture stability and difficulty in chewing. A number of patient factors, other than the technical qualities of the dentures, are thought to be associated with and adversely affect the functional performance of conventional complete dentures. These include poor denture-supporting tissues quality (e.g. severe alveolar bone resorption, thin overlying mucosa), reduced salivary flow (that commonly results from medications) and reduced oral muscle control. Indeed, it can be difficult to provide for the denture a stable and retentive base on resorbed and flat alveolar ridges, especially the lower (mandibular) one. However, no strong correlation has been shown to exist between the quality of the denture-supporting tissues and the treatment outcome with complete dentures.<sup>5</sup> The use of complete dentures also requires considerable oral neuromuscular control. It is not surprising to find out in a survey that dentists might not recommend new denture treatment when the concerned patient is found to be physically or cognitively impaired even the patient has total tooth loss with no dentures.<sup>1</sup> It should also be realised that there are some simply having no dentures at all because of socio-economic reasons.

## Denture adhesives

A denture adhesive (cream) is an over-the-counter product, applied in small amounts to the fitting surface of a denture, mainly a complete denture, in order to keep it in place during normal daily activities. Denture adhesives, because of their cohesive and adhesive behaviour with the acrylic denture base and the supporting oral mucosa, may enhance denture retention and performance. However, there is insufficient evidence that they improve chewing function. Furthermore, while daily thorough removal of the



adhesive product is essential, it can be rather difficult to remove the residue adhesive and clean the oral mucosa and the denture fitting surface, giving a "messy" perception to the users. It was reported that only one out of five patients who had tried denture cream continued to use it.<sup>6</sup> Therefore, denture adhesives are usually not necessary for well-made complete dentures. Nevertheless, in certain specific patient groups, such as patients with neuromuscular adaptation problems, denture adhesives may be useful.

### *Improper use of denture adhesives and Zinc overdose*

Some denture adhesives contain zinc in the formulation to provide a greater cohesive strength and longer duration. However, in the neurology literature, there have been recent reported cases in the U.S. showing the association of various neurological abnormalities to zinc overdose (hyperzinaemia) and copper deficiency (hypocupraemia) in patients with chronic use of excessively large amounts of denture cream.<sup>7</sup> In that case report, four patients with various neurologic abnormalities were identified. They wore dentures and used two or more tubes of denture cream per week for years when one tube would normally be enough for 3-10 weeks when used as instructed. While denture adhesives may provide additional adhesion to well-fitting dentures, denture adhesives are not the solution for the retention of ill-fitting dentures, in which case large amounts in excess of the recommended quantity are often used.

Therefore, extended use of denture adhesives should not be advised without regular assessment of the oral condition and the denture quality by a dentist. Zinc-free formulations can be considered if adverse systemic effects are a concern.

## Denture relining

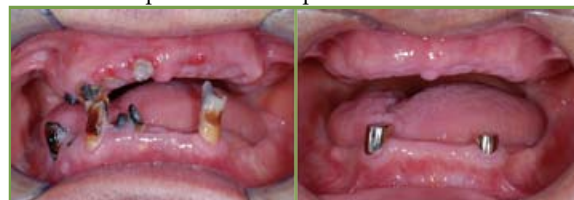Continuous bone resorption under denture bases is inevitable. These changes may be insidious or rapid, leading to denture looseness and irritation and pain of the supporting tissues in those patients who have worn the dentures comfortably and satisfactorily previously. Denture relining is a procedure that resurfaces the tissue side of a denture to compensate for these resorptive changes and provides accurate adaptation to the changed denture-foundation area. This can be carried out chair-side using self-cure materials to produce an instant reline, or processed in the laboratory. Relining can be done simply, accurately and inexpensively with reduced number of appointments needed.

## Tooth-borne overdenture

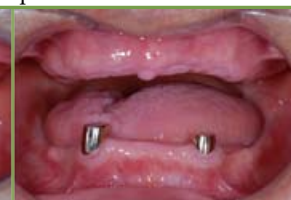Occasionally, there may be some remaining teeth that are badly broken, severely worn down, or for some reasons not suitable as partial denture abutments, and a complete denture will be the ultimate treatment modality. (Fig.1) Instead of total clearance, retaining one or two tooth root(s) in well selected cases and converting it (them) into an overdenture abutment(s) can remarkably improve the lower denture performance. This is because a retentive attachment system, e.g. magnets, can be retained on top of the root

for added retention of the denture. (Fig.2,3) The tooth-borne overdenture can also better resist the biting force as well as the destabilising force during jaw movements.

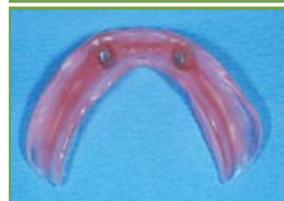It should also be emphasised that there is a higher prevalence of prosthodontic complications for overdentures compared with the conventional ones, e.g. fracture of the overdenture base material. This can result from the thinner denture base around the root abutment and/or fulcrum movement around contacts with abutment. Complications of the attachment components, e.g. dislodgement of magnets, is also another common maintenance problem to the patient.



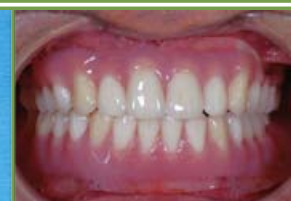*Fig.1 Intra-oral frontal view showing multiple carious and badly broken remaining teeth*



*Fig.2 The two lower canine roots being retained with gold caps incorporated as overdenture abutments*



*Fig.3 A lower complete denture with two magnets incorporated at the canine regions: tooth-borne overdenture*



*Fig.4 Intra-oral frontal view with upper and lower complete dentures biting in occlusion*

## Implant therapy

Osseointegrated dental implants are biocompatible root analogues, titanium being most commonly used, placed surgically into jaw bones. They can make a significant contribution to assist in addressing problems related to denture retention, support, and stability. For the last two decades, dental implants have become increasingly popular in Hong Kong. Without dispute, dental implants have added options to successful prosthodontic rehabilitation formerly unavailable to complete edentulous as well as partially dentate patients fortunate enough to receive them.

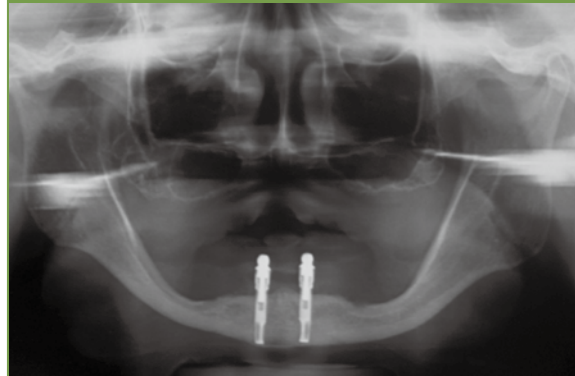### *Implant prostheses*

For edentulous patients, implants can be used to support and retain:

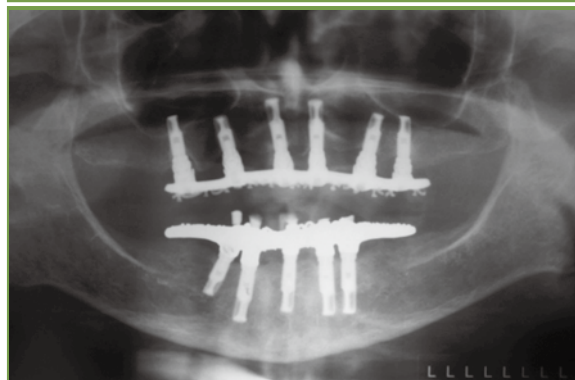- a removable complete denture (implant overdenture), (Fig.5,7,8) or
- a fixed full arch bridge. (Fig.6,9,10)

The fabrication of implant-supported fixed prostheses requires more implants, and the initial treatment cost is much higher than the implant overdenture option. Yet, Palmquist et al found little difference between implant-retained overdentures and implant fixed bridges in terms of functional performance and patient satisfaction.<sup>8</sup> Anatomical factors that may favour the implant overdenture option include the need for soft

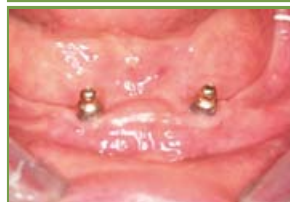tissue (cheek and lip) support, unfavourable inter-arch relation, unfavourable implant location or insufficient number of implants due to anatomical or financial reasons. The patient's preference to a fixed or removable option should also be taken into consideration. It is generally considered that a removable implant prosthesis is easier to be kept clean by the patient. Also, a removable implant overdenture offers advantages related to aesthetics and speech.<sup>9</sup>



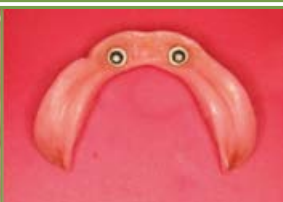**Fig.5** Panoramic radiograph showing two implants with ball attachments in the anterior mandible



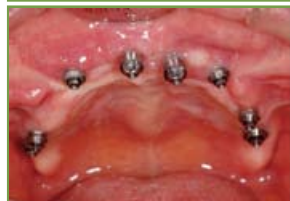**Fig.6** Panoramic radiograph showing upper and lower fixed prostheses supported by multiple implants on the maxilla and mandible



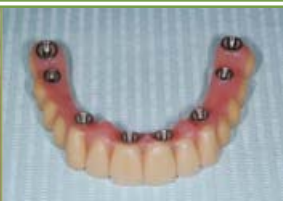**Fig.7** Intra-oral view showing two ball attachments in the anterior region of an edentulous mandible



**Fig.8** A lower implant overdenture with two retentive caps incorporated at the anterior region



**Fig.9** Intra-oral view of an edentulous maxilla with eight implants for support of a fixed bridge



**Fig.10** An upper full arch implant bridge

### Indications

Complete denture wearers are usually able to wear a maxillary denture without problems, but many struggle to eat with a complete mandibular denture because it is often loose and associated with chewing discomfort or pain. This is due to mobility of the floor of the mouth and intolerance to loading resulting from the relatively thin mucosa and reduced support area of the lower jaw. Thus, the most obvious indication for implant placement is the treatment of the edentulous mandible to improve retention, stability and support.<sup>10</sup> Implant therapy is also useful for the management of those maladaptive complete denture wearers.<sup>5</sup>

### Function improvement and patient satisfaction

The maximum occlusal force of an implant overdenture is twice that of a new conventional complete denture while still less than half of that of the dentate. The number of implants placed between the two mental foramina does not appear to positively influence force magnitude when compared with overdentures supported by two implants.<sup>11</sup> It appears that the type of implant and attachment has a limited impact on patient satisfaction.<sup>12</sup>

It has been shown in some studies that patients with mandibular two-implant overdentures, when comparing with conventional dentures are significantly more satisfied.<sup>10</sup> They chew significantly easier and speak more easily, and the quality of life ratings (diets and nutritional state) are higher. In the Western countries, a two- or even one-implant retained overdentures is increasingly regarded as a standard of care for the edentulous mandible.<sup>10</sup>

For the edentulous maxilla (upper jaw), however, the same may not be true. Patients already satisfied with their current denture have almost no significant improvement in general satisfaction when restored with an upper implant overdenture.<sup>13</sup>

### Treatment consideration

Clinical outcomes with implant therapy for the edentulous mandible have been shown so successful in studies, yet implants cannot solve all problems related to tooth loss. Fitzpatrick in his literature review argues that there is no strong evidence supporting a single treatment modality (mandibular two-implant overdentures) for the edentulous mandible because of great individual patient variations, e.g. functional demands, socio-economic status and adaptive capacity.<sup>14</sup> Undoubtedly, non-dental factors, such as the individual patient's preference and physical health conditions should also be taken into consideration during treatment planning in oral rehabilitation. For the functionally dependent older group, it is generally accepted by the dental profession that treatment planning should be rational rather than "technically ideal".<sup>1</sup> For example, implant surgical procedures will not be appropriate for those with complicated medical conditions if the risks of treatment outweigh the benefits. Similarly, sophisticated and lengthy treatment procedures may also be difficult due to poor patient cooperation. Moreover, the treatment and maintenance cost concerned is greater. Its routine prescription for the financially disadvantaged is unrealistic. Furthermore, it was shown in a study that 36% of edentulous volunteers refused the offer of free



implants for mandibular overdentures, mainly because they feared the surgical risks or considered their complete dentures good enough.<sup>15</sup>

Therefore, while implant therapy has improved the therapeutic possibilities, implants probably are not an option for the majority. Conventional complete dentures will continue, at least in the near future, to remain as a safe, predictable and cost-effective treatment modality to the majority of edentulous patients.

## Conclusion

Health care workers should be aware of the various prosthodontic treatment options and their limitations for the edentulous patients. A consideration of individual patient's circumstances and functional needs is important in the selection of appropriate treatment modality so as to best meet the needs of the patient and ensure treatment success.

### References

1. Oral Health Survey 2011. Hong Kong: Department of Health; 2013.
2. Hasaldson T, Karlsson U, Carlsson GE. Bite force and oral function in complete denture wearers. *J Oral Rehabil* 1979 Jan; 6(1):41-48.
3. Carlsson GE. Facts and fallacies: an evidence base for complete dentures. *Dent Update* 2006 Apr; 33(3):134-6, 138-40, 142.

4. Berg E. Acceptance of full dentures. Review. *Int Dent J* 1993; 43(Suppl 1):299-306.
5. Carlsson GE, Omar R. The future of complete dentures in oral rehabilitation. A critical review. *J Oral Rehabil* 2010; 37:143-156.
6. Coates AJ. Usage of denture adhesives. *J Dent* 2000 Feb; 28(2): 137-140.
7. Nations SP, Boyer PJ, Love LA, et al. Denture cream: an unusual source of excess zinc, leading to hypocupremia and neurologic disease. *Neurology* 2008 Aug; 71(9):639-643.
8. Palmquist S, Owall B, Schou S. A perspective randomized clinical study comparing implant-supported fixed prostheses and overdentures in the edentulous mandible: prosthodontic production time and cost. *Int J Prosthodont* 2004; 17:231-235.
9. Heydecke G, Boudrias P, Awad MA, De Albuquerque RF, Lund JP, Feine JS. Within-subject comparisons of maxillary fixed and removable implant prostheses: patient satisfaction and choice of prostheses. *Clin Oral Impl Res* 2003; 14:125-130.
10. Feine JS, Carlsson GE, Awad MA, Chehade A, Duncan WJ, Gizani S. The McGill Consensus Statement on overdentures. *Int J Prosthodont* 2002; 15:413-414.
11. Mericske-Stern R, Zarb GA. In vivo measurements of some functional aspects with mandibular fixed prostheses supported by implants. *Clin Oral Impl Res* 1996; 7:153-161.
12. Fueki K, Kimoto K, Ogawa T, Garrett N. Effect of implant-supported or retained dentures on masticatory performance: a systematic review. *J Prosthet Dent* 2007; 98:470-477.
13. Eckert SE, Carr AB. Implant-retained maxillary overdentures. *Dent Clin North Am* 2004; 48:585-601.
14. Fitzpatrick B. Standard of care for the edentulous mandible: A systematic review. *J Prosthet Dent* 2006; 95:71-78.
15. Walton JN, MacEntee MI. Choosing or refusing oral implants: a prospective study of edentulous volunteers for a clinical trial. *Int J Prosthodont*. 2005; 18:483-488.


## Dental Quiz



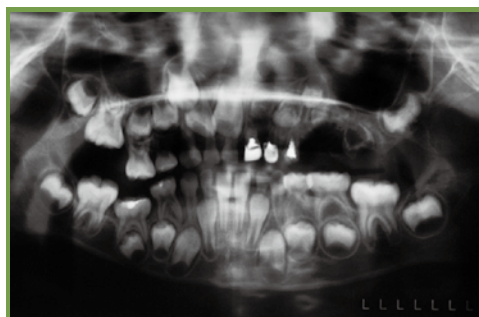
## Dental Quiz

### Dr Shiu-yin CHO

Senior Dental Officer, Fanling School Dental Clinic, Department of Health



Dr Shiu-yin CHO



A 6-years-8-months old boy attended the author's clinic for dental examination. His chief complaint was multiple malformed teeth. His medical history was unremarkable, and there was no family history of similar dental problems. He had received restorative and surgical treatments from other dentists previously. An orthopantomogram was taken and showed grossly malformed teeth 61 to 63, and 21 to 26. What is the diagnosis of this condition?

(See P.32 for answers)

CME/CNE Course

Certificate Course for Healthcare Professionals

Course No. C236

Certificate Course on

# TOC - A Breakthrough Approach for Healthcare Improvement

Jointly organised by

The Federation of Medical  
Societies of Hong Kong

Six Sigma Institute

Date	Topics	Speaker
3 Sep	<ul style="list-style-type: none"> <li>The Current Issues of Healthcare Services</li> <li>How the Theory of Constraints (TOC) can tackle these Issues</li> <li>Video Show</li> <li>Constraint Management Framework</li> </ul>	<b>Dr. Y. K. CHAN</b> <i>Chairman of Six Sigma Institute</i>
12 Sep	<ul style="list-style-type: none"> <li>Application of TOC 7-Focus Steps with Healthcare Examples</li> <li>1. Determine the system's goal</li> <li>2. Establish global performance measures</li> <li>3. Identify the system constraint</li> <li>4. Decide how to exploit the constraint</li> </ul>	
19 Sep	<ul style="list-style-type: none"> <li>5. Subordinate the rest of the system to the constraint</li> <li>6. Elevate and break the constraint</li> <li>7. Overcome the inertia</li> <li>Case Examples</li> <li>Individual Project Presentation</li> <li>The Planning Game</li> </ul>	

**Enquiry :** The Secretariat of The Federation of Medical Societies of Hong Kong  
 Tel.: 2527 8898 Fax: 2865 0345 Email: info@fmshk.org

CME/CNE Course

Certificate Course for Healthcare Professionals

Course No. C237

Certificate Course on

# Six Sigma for Healthcare

Jointly organised by

The Federation of Medical  
Societies of Hong Kong

Six Sigma Institute

Date	Topics	Speaker
1 Sep	<ul style="list-style-type: none"> <li>Introduction to Six Sigma</li> <li>Case Example</li> <li>Define Phase</li> <li>1. Project Charter 2. SIPOC Chart 3. Voice of Patient</li> </ul>	<b>Dr. Y. K. CHAN</b> <i>Chairman of Six Sigma Institute</i>
8 Sep	<ul style="list-style-type: none"> <li>Measure Phase</li> <li>1. Baseline Measure 2. <math>Y=f(X's)</math></li> <li>3. Identification of Potential Cause</li> <li>4. Selection of Critical Causes 5. Measure Plan</li> <li>Process Capability</li> <li>Exercises</li> </ul>	
15 Sep	<ul style="list-style-type: none"> <li>Verify Root Causes</li> <li>Develop Solutions</li> <li>Pilot Solutions</li> <li>Case Example1 – Lean Sigma Deployment in Hospitals</li> </ul>	
22 Sep	<ul style="list-style-type: none"> <li>Full Scale Implementation</li> <li>Control Plan</li> <li>Case Example 2 - 縮短急診生化檢驗報告時間</li> <li>Case Example 3 – Improvement of Medical Imaging Center</li> </ul>	

**Enquiry :** The Secretariat of The Federation of Medical Societies of Hong Kong  
 Tel.: 2527 8898 Fax: 2865 0345 Email: info@fmshk.org





## An Expedition to Mount Vinson, the Highest Point in Antarctica

**Dr Haston WM LIU**

FCDSHK (Family Dentistry), FHKAM (Dental Surgery), MGDS, RCS (Edinburgh), MFGDP (UK), P'Dip DS (HK), BDS (HK)

*Specialist in Family Dentistry*



Dr Haston WM LIU



*The southernmost city in South America, Punta Arenas. We travelled there via Johannesburg, South Africa; Buenos Aires, Argentina; and Santiago, Chile.*

Antarctica: a vast, unspoiled continent covered with ice miles deep, a place of beauty and mystery. Mount Vinson, her highest point, and also of the fifth highest mountain of the Seven Summits (the highest points of each of the Seven Continents). The mountain is probably one of the most remote areas on Earth. Strong winds coupled with cold air temperatures (averaging  $-30^{\circ}\text{C}$ , to  $-50^{\circ}\text{C}$  on the top even in summer) result in brutally low wind-chill temperatures; combined with the high altitude, avalanches and crevasses, posing the greatest threat to climbers. My trip there was in January of 2012, together with my training buddy, John Tsang and his friend, Raymond Ko. John is the only man from Hong Kong to have summited Mt. Qomolangma from both the Nepalese and Tibetan sides; he was there to complete his Seven Summits, before he would attempt the Mt. Qomolangma summit again from the Tibetan side in June of 2013. As we only had three people from Hong Kong, we joined the Russian team for safety and logistical reasons.

Just the trip from Hong Kong to Punta Arenas (the southernmost city in South America, the starting point of our expedition), already took us more than 40 hours.

As the weather was unstable there even in summer, we needed to be in Punta Arenas a few days before our scheduled flight to Antarctica. During this period, we prepared our food, fuel, and climbing equipment.



*The city of wind. The wind usually calms down after three in the afternoon*



*John Chi Sang Tsang (left), Raymond Ko (middle), Haston Wai Ming Liu (right)*

Finally the day came for us to board an Ilyushin 76TD, a Russian-made, robust aircraft built for off-strip takeoffs with a payload of 17 tonnes.



*The interior of the Ilyushin, carrying us and all our climbing equipment and supplies*

It took us six hours from Punta Arenas to the Union Glacier, a transition base for all inland Antarctica expeditions and research trips. Landing on the icy runway was a thrilling experience for us since brakes could not be used to stop the plane. The aircraft must land precisely on the blue ice, with the flaps raised to increase the air resistance to slow down the plane.



The moment we got out of the plane was awesome. The -30°C cold air with the panoramic icy mountains made one believe the stories described in the National Geographic might really exist!



*The Ilyushin landed on the blue ice runway*

The Union Glacier is the only private seasonally occupied camp there, usually during the months of November to January. It is operated by the Antarctic Logistics & Expeditions (ALE), a company providing expedition support and transportation logistics to the interior of Antarctica. From there we were still more than five hundred kilometres from our base camp. We stayed for two more days for our final preparation and briefing of the trip.



*The arrived passengers gathered outside the catering tent of the Union Glacier*

ALE has strict criteria for taking independent groups to the mountain to avoid costly and dangerous rescues. Finally, we continued on a ski-equipped Twin Otter airplane to the Vinson Massif Base Camp at 2150m.



*Waiting for transit to the Vinson base camp by a smaller plane*

Our base camp was located at the Sentinel Range (Ellsworth Mountains), lying in the west of Antarctica, 1200km from the South Pole.

Mount Vinson is the coldest of the Seven Summits. Atmospheric pressure is lower at the Poles than elsewhere on Earth, so air will be pulled over Antarctica, resulting in cold air rapidly descending over the continent, and then fanning out as high winds.



*The icy runway of the Vinson base camp*

Our base camp was located at the base of the Branscomb Glacier and sheltered from the high winds, but even with 24-hour sun, when the base camp was in shade, the temperature could drop to minus 40°C at that height. Going out at that time to toilet was a life-threatening event!



*Accommodations at the base camp, the mountains around provided shelter from high winds*

After we had tidied up at the base camp, we started our acclimatisation outing and transportation of our food, camp gear and climbing equipment to the higher camps. Even though the expedition from the base camp to the summit and back may only last for 10 days; we needed to carry extra food and fuel as a precaution for bad weather. Carrying a 60 litre backpack on our shoulders and towing another 30kg of supplies on snow sheds uphill was far more demanding than imagined. Life became simple at that moment; our only goal was to return to the base camp for a hot meal.



*Climbers carried their gear and supplies in backpacks and on snow sheds*



We had a rest day on 1 Jan of 2012 to celebrate our New Year there with the Russian expedition team, of course with plenty of Vodka, Brandy and Whisky.



*Celebration of Hong Kong, Moscow and Siberian New Year.*

On 3 Jan, we packed up all our gear and advanced to Camp 2 (the Low Camp) at 2750m. 650m of ascent took us 6 hours in a gradually rising glacier with plenty of crevassing.



*Approaching the low camp (2750m)*

The day we got there was fine but a snow storm approached soon after we had pitched our camp. Luckily, the storm only lasted for 24 hours.



*Pitching tents in the low camp. The one red in colour was the kitchen tent (Alaskan style)*



*The temperature dropped to minus 40°C during the white out.*

After the storm was over, we repeated what we had done from the base camp to the low camp, transporting our supplies and equipment to the high camp at 3900m, with an ascent of 1020m, including 1200m fixed rope sections up to 45 degrees with rocky sections and plenty areas of blue ice.



*Climbing up to the high camp with rocky sections up to 45 degrees*

Even with the assistance of ice crampons, fixed rope ascenders and ice axes, ascending a 45 degrees slope with 30kg of load on our shoulders was seriously challenging at such altitudes. After another day of rest, we started our ascent on 6 Jan to the High Camp.



*View of the Vinson Massif*



*Ascending the fixed rope section*

Antarctica is a pristine continent, it is also a giant freezer; anything one leaves there will remain unchanged till the end of the world. Climbing expeditions there have a very strict waste management protocol; we must carry all garbage and faeces back to the base camp, only pee & grey water go in pee holes at each camp, and we can only pee in pee bottles on the route. All the waste collected at

the base camp would then be transported back to Chile for disposal. In contrast to the expedition I had before, the weight of our load carrying back to the base camp was heavier than when we started as our faeces contained more water than our food carried up there. Even though we had minimised our waste as much as possible, there were a lot to carry back! This was an excellent lesson for us to learn there; 1. Don't shit around. 2. Take care of your own shit. 3. Leave no shit behind.



*The view of the summit from the high camp*

Soon after we had settled at the high camp, we needed to make our summit plan. As another storm was closing in in a few days, we decided to make our summit on the morning of 7 Jan. Going from the high camp to the Summit would be an ascent of 1120m with around 9 to 12 hours on the return trip, with gradually rising valleys with some 40 degrees of slopes and rocky ridges on the summit pyramid.



*Going up from the high cam to the summit. All climbers were roped up for safety reasons.*



*Approaching the summit pyramid, the rocky sections were challenging as it was difficult to climb on rocks with crampons.*

When we moved up from the valley to the summit ridge, the temperature was only minus 50 degree with occasionally gusting winds, but the view was fascinating when we look down to the Branscomb Glacier on the

right, and the Sublime Peak 4865 and Corbet Peak 4822 on the left.



*The view of the summit of Mount Vinson.*



*The second batch of HK people up to the top of Antarctica, totally 4 till now.*

Finally, we reached the highest point of Antarctica, an exciting moment I have been looking forward for a long time. John Tsang completed his Seventh Summit and I have four more to go including Mt. Qomolangma! After spending a short while there, we started our descent to the high camp and then the low camp carrying all our gear, equipment and waste in one go, making use of the short window of good weather. Although we were going downhill, the descent seemed to be eternal! Up in Mount Vinson, everything would be all on our own, planned and unexpected: only making it safely back to the base camp could our trip be called complete.



*The photo of the Russian and HK climbing teams in the 2012 Mount Vinson Expedition.*

This was an exhilarating trip, not just for the breathtaking views, or the invigorating mountain air, but also the deep emotions stirred up when one faced such an extreme and remote area on Earth.

# Certificate Course on Off-Street Emergency Medicine

緊急情況下的急救治理證書課程

Jointly organised by



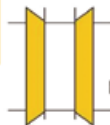The Federation of Medical Societies of Hong Kong



Hong Kong Society for Emergency Medicine and Surgery

Date	Topics	Speakers
21 Jul	File 1 : An athletic injured in the sports field, the management and can he return to play? 檔案 1. 運動員於運動場上受傷時的處理方法及是否可以繼續完成餘下的比賽?	Dr. Ken WU 胡永祥醫生 香港急症科醫學院院士
28 Jul	File 2 : A person knocked down by a car outside your clinic, can you help? 檔案 2. 你可以怎樣協助因被車撞倒的傷者?	Dr. Fong-lun LEE 李方倫醫生 香港急症科醫學院院士
4 Aug	File 3 : A person collapsed in street, legal aspects and medical treatment. 檔案 3. 如何提供適當及合法的醫療治理予在街上暈倒的途人。	Dr. Abraham WAI 衛家聰醫生 香港急症科醫學院院士
11 Aug	File 4 : A person you meet with shortness of breath, chest pain or dizziness during mountain trekking, what should I do? 檔案 4. 如目睹行山人士呼吸困難、胸口痛楚及出現暈眩症狀，可怎樣提供協助?	Dr. Axel SIU 蕭粵中醫 香港急症科醫學院院士
18 Aug	File 5 : A kid accidentally taken wild plants in the park, what can I do? 檔案 5. 兒童在園內胡亂採摘野生植物而中毒，可怎樣處理?	Dr. Man-li TSE 謝萬里醫生 香港急症科醫學院院士
25 Aug	File 6 : A person bitten by animal, snake, dog, cat or stung by insect? 檔案 6. 怎樣適當地處理被動物、蛇、狗、貓咬傷或昆蟲刺傷?	Dr. Ralph CHEUNG 張冠豪醫生 香港急症科醫學院院士

Enquiry : The Secretariat of The Federation of Medical Societies of Hong Kong  
Tel: 2527 8898 Fax: 2865 0345 Email: info@fmskh.org



香港無障牙科學會  
Hong Kong Special Care Dentistry Association

### Special Care Dentistry (SCD)

SCD concerns about the provision of oral care services for the improvement of oral health of adolescents and adults who are unable to receive routine dental care because of certain physical, intellectual, medical, emotional, sensory, mental or social impairment factors or a combination of more than one of these factors.

The Hong Kong Special Care Dentistry Association is a new organization formed by a group of individuals, composed of dental and medical practitioners, social workers and businesspersons, who have the following:

#### Vision

To build a community with SCD for the needy in Hong Kong and its neighbouring region

#### Mission


- To promote SCD to the dental and health professionals, allied health professionals and the community
- To serve the community requiring SCD
- To facilitate the establishment of the specialty of SCD in Hong Kong

Please connect with us by visiting our website:  
[www.hksca.org](http://www.hksca.org)

## Postgraduate Diploma in Molecular and Diagnostic Pathology (PDipMDPath) 分子及診斷病理學深造文憑

## Postgraduate Certificate in Molecular and Diagnostic Pathology (PCMDPath) 分子及診斷病理學深造證書

**PDipMDPath**  
A Quotable Qualification by the Hong Kong Medical Council



Application & Enquiries  
Further details can be found at:  
<http://www.patho.hku.hk/pdip.html>

Contact Person:  
Ms MK Tang (Tel: 2255 3967)  
Email: [pdip@pathology.hku.hk](mailto:pdip@pathology.hku.hk)

DEADLINE FOR APPLICATION  
3 October 2014



Department of Pathology  
Li Ka Shing Faculty of Medicine  
The University of Hong Kong

Want to upgrade your knowledge and skills in the care of patients?

## Department of Family Medicine and Primary Care

The University of Hong Kong



www.fmpg.hku.hk



### 2014/2015 Part-time Postgraduate Courses

Postgraduate Diploma in 社區精神醫學深造文憑

## COMMUNITY PSYCHOLOGICAL MEDICINE

Exclusively catered for practising doctors who are seeing patients with difficulty to sleep, feeling stressed and depressed, being anxious, panic and confused etc.

2-hour Interactive seminar	20 Saturday afternoons between Sep 2014 - Jan 2015
2-hour Clinical Attachment	20 weekday afternoons between Jan - Jun 2015



Postgraduate Diploma in **COMMUNITY GERIATRICS** 社區老年醫學深造文憑

Admission is now open for practising doctors and L.M.C. candidates.

Distance Learning	10 weeks & 6 short assignments
Interactive Workshop	Sep 13, 27; Oct 11, 25; Nov 15 (Saturdays 14:30-17:15)
Clinical Attachment	25 weekday afternoons (14:00-16:00)
Nov 2014-May 2015	Or weekday evenings (18:00-20:00)



Tuition fee for a single course: HKD 42,000

**Extended** Closing Date for Application: **31 Jul 2014**

Web: (for details) [www.fmpg.hku.hk](http://www.fmpg.hku.hk)

(online application) [www.asa.hku.hk/admission/tpg](http://www.asa.hku.hk/admission/tpg)

Certificate Course in **CLINICAL DERMATOLOGY** 臨床皮膚醫學證書課程

Date	October-December 2014 (10 seminars, every Saturday afternoon)
Time	14:30-16:30
Venue	Duke of Windsor Social Service Building, WanChai
Tuition Fee	(full course) HKD5,000 (per seminar) HKD 700

Closing Date for Application for the Certificate Course in Clinical Dermatology: **5 Sep 2014**

Tel: 2518 5682 Fax: 2814 7475 E-mail: [fmpg@hku.hk](mailto:fmpg@hku.hk)

Department of Family Medicine and Primary Care, 3/F., Ap Lei Chau Clinic, 161 Main Street, Ap Lei Chau, HK



Sunday	Monday	Tuesday	Wednesday	Thursday	Friday	Saturday
<ul style="list-style-type: none"> <li>* HKMA Table-Tennis Tournament 2014</li> </ul> <p><b>1</b></p>	<ul style="list-style-type: none"> <li>* A man presented with umbilical pain with fever</li> </ul> <p><b>2</b></p>	<ul style="list-style-type: none"> <li>* HKMA Tai Po Community Network - Hypertension Guideline Update 2014</li> <li>* HKMA Council Meeting</li> <li>* FMSHK Officers' Meeting</li> </ul> <p><b>3</b></p>	<ul style="list-style-type: none"> <li>* MPS - Workshop - Mastering Professional Interactions</li> </ul> <p><b>4</b></p>	<ul style="list-style-type: none"> <li>* HKMA Kowloon East Community Network - Unmet Medical Needs on Osteoporosis Management and Novel Treatment Guidelines in Place</li> <li>* HKMA New Territories West Community Network - 1st Series Certificate Course on Dementia for Early Clinical Doctors (Session 1): Dementia - Core Clinical Features and Diagnostic Criteria</li> <li>* MPS Workshop - Mastering Difficult Interactions with Patients</li> </ul> <p><b>5</b></p>	<ul style="list-style-type: none"> <li>* HKMA Shatin Doctors Network - New Era of Seasonal Influenza Prevention</li> </ul> <p><b>6</b></p>	<ul style="list-style-type: none"> <li>* HKMA Youth Committee Career Seminar 2014</li> </ul> <p><b>7</b></p>
<ul style="list-style-type: none"> <li>* HKMA Tenpin Bowling Tournament 2014</li> <li>* HKMA Table-Tennis Tournament 2014</li> </ul> <p><b>8</b></p>	<ul style="list-style-type: none"> <li>* HKMA Tai Po Community Network - Holistic Approach to the Diagnosis and Management of Airway Diseases</li> <li>* MPS Workshop - Mastering Adverse Outcomes</li> </ul> <p><b>9</b></p>	<ul style="list-style-type: none"> <li>* HKNS Monthly Academic Meeting - Low Grade Glioma</li> <li>* HKMA Central, Western &amp; Southern Community Network - Update Management of Infectious Diarrhoea</li> <li>* MPS Workshop - Mastering Your Risk</li> </ul> <p><b>10</b></p>	<ul style="list-style-type: none"> <li>* HKMA Hong Kong East Community Network - Optimal Nutrition from Preconception to Pregnancy for Healthy Pregnancy</li> <li>* HKMA Structured CME Programme with Hong Kong Sanatorium &amp; Hospital Year 2014 - Update on Infertility</li> <li>* MPS Workshop - Mastering Shared Decision Making</li> </ul> <p><b>11</b></p>	<ul style="list-style-type: none"> <li>* HKMA Hong Kong East Community Network - Optimal Nutrition from Preconception to Pregnancy for Healthy Pregnancy</li> <li>* HKMA Structured CME Programme with Hong Kong Sanatorium &amp; Hospital Year 2014 - Update on Infertility</li> <li>* MPS Workshop - Mastering Shared Decision Making</li> </ul> <p><b>12</b></p>	<ul style="list-style-type: none"> <li>* "1st Series Certificate Course on Dementia for Primary Care Doctors"</li> <li>Topic 3. Medical and Community Collaboration - Case Management in Community</li> <li>* NSCP 2014 Party</li> </ul> <p><b>13</b></p>	<ul style="list-style-type: none"> <li>* HKMA CME - Refresher Course for Health Care Providers 2013/2014</li> <li>* MPS Workshop - Mastering Difficult Interactions with Patients</li> </ul> <p><b>14</b></p>
<ul style="list-style-type: none"> <li>* RSCP Dragon Boat Race 2014</li> </ul> <p><b>15</b></p>	<p><b>16</b></p>	<ul style="list-style-type: none"> <li>* HKMA Central, Western &amp; Southern Community Network - Breast Cancer Detection &amp; Screening in 2014: What the Family Physician Needs to Know</li> <li>* MPS Workshop - Mastering Professional Interactions</li> </ul> <p><b>17</b></p>	<ul style="list-style-type: none"> <li>* Paediatric Infectious Disease and Immunology Course 2014</li> <li>* HKMA New Territories West Community Network - 1st Series Certificate Course on Dementia for Early Clinical Doctors (Session 2): Dementia - Treatment Strategies for Pharmacological Intervention for Dementia</li> <li>* MPS Workshop - Mastering Adverse Outcomes</li> <li>* FMSHK Executive Committee Meeting</li> </ul> <p><b>18</b></p>	<ul style="list-style-type: none"> <li>* Paediatric Infectious Disease and Immunology Course 2014</li> <li>* HKMA New Territories West Community Network - 1st Series Certificate Course on Dementia for Early Clinical Doctors (Session 2): Dementia - Treatment Strategies for Pharmacological Intervention for Dementia</li> <li>* MPS Workshop - Mastering Adverse Outcomes</li> <li>* FMSHK Executive Committee Meeting</li> </ul> <p><b>19</b></p>	<ul style="list-style-type: none"> <li>* Paediatric Infectious Disease and Immunology Course 2014</li> </ul> <p><b>20</b></p>	<ul style="list-style-type: none"> <li>* The 7th Annual Scientific Meeting and 8th Annual General Meeting of the Hong Kong Society for Paediatric Immunology and Infectious Diseases</li> <li>* KECCN / HKCFP / UCH - CME Course for Health Personnel 2014 - Common Eye Infections</li> </ul> <p><b>21</b></p>
<ul style="list-style-type: none"> <li>* HKMA Tenpin Bowling Tournament 2014</li> <li>* HKMA Table-Tennis Tournament 2014</li> </ul> <p><b>22</b></p>	<p><b>23</b></p>	<ul style="list-style-type: none"> <li>* HKMA Kowloon West Community Network - Advancement of Meningococcal Conjugate Vaccine &amp; Global Practice</li> <li>* HKMA Tai Po Community Network - Updated Management in Allergic Rhinitis</li> <li>* Council Election Forum</li> </ul> <p><b>24</b></p>	<ul style="list-style-type: none"> <li>* HKMA Central, Western &amp; Southern Community Network - "Eye-land mines" in Daily Practice: Be Very Careful About "Red Eye" &amp; in Talking About Cataract Surgery</li> </ul> <p><b>25</b></p>	<ul style="list-style-type: none"> <li>* HKMA Central, Western &amp; Southern Community Network - "Eye-land mines" in Daily Practice: Be Very Careful About "Red Eye" &amp; in Talking About Cataract Surgery</li> </ul> <p><b>26</b></p>	<ul style="list-style-type: none"> <li>* "1st Series Certificate Course on Dementia for Primary Care Doctors" Topic 4. Case Demonstration</li> <li>* HKMA Wine Dinner - Yarra Yering - A Hidden Gem in the Valley</li> </ul> <p><b>27</b></p>	<p><b>28</b></p>
<ul style="list-style-type: none"> <li>* HKMA Tenpin Bowling Tournament 2014</li> <li>* HKMA Table-Tennis Tournament 2014</li> </ul> <p><b>29</b></p>	<p><b>30</b></p>					



Date / Time	Function	Enquiry / Remarks
<b>1 SUN</b> 2:00pm	<b>HKMA Table-Tennis Tournament 2014</b> Organiser: The Hong Kone Medical Association, Chairman: Dr. KOO Hok Tin, Hilton, Venue: Dr. Stephen HUI Sports Hall, LG, Lam Woo International Conference Centre, Hong Kong Baptist University, Renfrew Road, Kowloon Tong	Mr. Ian KWA Tel: 2527 8285
<b>3 TUE</b> 1:45pm	<b>HKMA Tai Po Community Network - Hypertension Guideline Update 2014</b> Organiser: HKMA Tai Po Community Network, Speaker: Dr. TONG Chun Yip, Peter, Venue: Chiuchow Garden Restaurant (潮江春) Shop 001-003, 1/F, Uptown Plaza (新達廣場), No.9 Nam Wan Road, Tai Po	Ms. Joyce TSUNG Tel: 2664 3808 1 CME Point
<b>8:00pm</b>	<b>HKMA Council Meeting</b> Organiser: The Hong Kong Medical Association, Chairman: Dr. TSE Hung Hing, Venue: HKMA Head Office (5/F, Duke of Windsor Social Service Building, 15 Hennessy Road, Hong Kong)	Ms. Christine WONG Tel: 2527 8285
<b>8:00pm</b>	<b>FMSHK Officers' Meeting</b> Organiser: The Federation of Medical Societies of Hong Kong, Venue: Gallop, 2/F., Hong Kong Jockey Club Club House, Shan Kwong Road, Happy Valley	Ms. Nancy CHAN Tel: 2527 8898
<b>4 WED</b> 6:30pm	<b>MPS - Workshop - Mastering Professional Interactions</b> Organisers: The Hong Kong Medical Association & Medical Protection Society, Speaker: Dr. LEE Wai Hung, Danny, Venue: HKMA Dr. Li Shu Pui Professional Education Centre, 2/F, Chinese Club Building, 21-22 Connaught Road, Central	HKMA CME Dept Tel: 2527 8452 2.5 CME Point
<b>5 THU</b> 1:00pm	<b>HKMA Kowloon East Community Network - Unmet Medical Needs on Osteoporosis Management and Novel Treatment Guidelines in Place</b> Organiser: HKMA Kowloon East Community Network, Chairman: Dr. AU Ka Kui, Gary, Speaker: Dr. WU Yee Ming, Jimmy, Venue: Lei Garden Restaurant (利苑酒家) Shop no. L5-8, apm, Kwun Tong, No. 418 Kwun Tong Road, Kowloon	Miss Hana YEUNG Tel: 2527 8285 1 CME Point
<b>1:00pm</b>	<b>HKMA New Territories West Community Network - 1st Series Certificate Course on Dementia for Primary Care Doctors (Session 1): Early Clinical Diagnosis of Dementia – Core Clinical Features and Diagnostic Criteria</b> Organiser: HKMA New Territories West Community Network and Institute of Alzheimer's Education (IAE) of Hong Kong Alzheimer's Disease Association (HKADA), Speaker: Dr. David DAI, Venue: Plentiful Delight Banquet (元朗喜尚嘉喜酒家), 1/F., Ho Shun Tai Building, 10 Sai Ching Street, Yuen Long	Miss Hana YEUNG Tel: 2527 8285 1 CME Point
<b>1:00pm</b>	<b>MPS Workshop - Mastering Difficult Interactions with Patients</b> Organiser: The Hong Kong Medical Association & Medical Protection Society, Speaker: Dr. Cheng Ngai Shing, Justin, Venue: Eaton Hotel	HKMA CME Dept Tel: 2527 8452 2.5 CME Point
<b>6 FRI</b> 1:00pm	<b>HKMA Shatin Doctors Network - New Era of Seasonal Influenza Prevention</b> Organiser: HKMA Shatin Doctors Network, Chairman: Dr. MAK Wing Kin, Speaker: Dr. SO Man Kit, Thomas, Venue: Jasmine Room, Level 2, Royal Park Hotel, 8 Pak Hok Ting Street, Shatin	Ms. Yvonne YEUNG Tel: 3189 8626 1 CME Point
<b>7 SAT</b> 3:00pm	<b>HKMA Youth Committee Career Seminar 2014</b> Organiser: HKMA Youth Committee, Chairman: Dr. SIN Pui Yee, Helena, Venue: HKMA Central Premises, Dr. Li Shu Pui Professional Education Centre, 2/F, Chinese Club Building, 21-22 Connaught Road, Central, Hong Kong	Miss Phoebe WONG Tel: 2527 8285
<b>9 MON</b> 7:30pm	<b>A man presented with umbilical pain with fever</b> Organiser: Hong Kong Urological Association, Chairman: Dr. Mak Siu King, Speaker: Dr. LI Kai Man Joseph, Venue: Multi-disciplinary Simulation and Skills Centre, 4/F, Block F, QEH	Ms Tammy HUNG Tel: 96096064 1 CME Point
<b>10 TUE</b> 1:45pm	<b>HKMA Tai Po Community Network - Holistic Approach to the Diagnosis and Management of Airway Diseases</b> Organiser: HKMA Tai Po Community Network, Speaker: Dr. WONG Ka Chun, Venue: Chiuchow Garden Restaurant(潮江春) Shop 001-003, 1/F, Uptown Plaza (新達廣場), No.9 Nam Wan Road, Tai Po	Mr. Kiev WONG Tel: 9045 5058 1 CME Point
<b>6:30pm</b>	<b>MPS Workshop - Mastering Adverse Outcomes</b> Organisers: The Hong Kong Medical Association & Medical Protection Society, Speaker: Dr. LEUNG Kwok Ling, Ares, Venue: HKMA Dr. Li Shu Pui Professional Education Centre, 2/F, Chinese Club Building, 21-22 Connaught Road, Central	HKMA CME Dept Tel: 2527 8452 2.5 CME Point
<b>11 WED</b> 7:30am	<b>Hong Kong Neurosurgical Society Monthly Academic Meeting –Low Grade Glioma</b> Organiser: Hong Kong Neurosurgical Society, Chairman: Dr KWAN Cheuk Lun, Speaker: Dr HUNG Cheung Yu, Venue: Seminar Room, Ground Floor, Block A, Queen Elizabeth Hospital	Dr. LEE Wing Yan, Michael Tel: 2595 6456 1.5 CME Point
<b>1:00pm</b>	<b>HKMA Central, Western &amp; Southern Community Network - Update Management of Infectious Diarrhoea</b> Organiser: HKMA Central, Western & Southern Community Network, Speaker: Dr. SO Man Kit, Thomas, Venue: HKMA Central Premises, Dr. Li Shu Pui Professional Education Centre, 2/F, Chinese Club Building, 21-22 Connaught Road, Central	Miss Hana YEUNG Tel: 2527 8285 1 CME Point
<b>6:30pm</b>	<b>MPS Workshop - Mastering Your Risk</b> Organisers: The Hong Kong Medical Association & Medical Protection Society, Speaker: Dr. LEE Wai Hung, Danny, Venue: HKMA Dr. Li Shu Pui Professional Education Centre, 2/F, Chinese Club Building, 21-22 Connaught Road, Central, Hong Kong	HKMA CME Dept Tel: 2527 8452 2.5 CME Point
<b>12 THU</b> 1:00pm	<b>HKMA Hong Kong East Community Network - Optimal Nutrition from Preconception to Pregnancy for Healthy Pregnancy</b> Organiser: HKMA Hong Kong East Community Network, Chairman: Dr. LEUNG Kwan Kui, Terence, Speaker: Dr. KUN Ka Yan, Venue: The HKMA Wanchai Premises	Miss Hana YEUNG Tel: 2527 8285 1 CME Point
<b>2:00pm</b>	<b>HKMA Structured CME Programme with Hong Kong Sanatorium &amp; Hospital Year 2014 - Update on Infertility</b> Organisers: The Hong Kong Medical Association & Hong Kong Sanatorium & Hospital, Speaker: Dr. Lok Hung, Ingrid, Venue: HKMA Central Premises, Dr. Li Shu Pui Professional Education Centre, 2/F, Chinese Club Building, 21-22 Connaught Road, Central	HKMA CME Dept Tel: 2527 8452 1 CME Point
<b>6:30pm</b>	<b>MPS Workshop - Mastering Shared Decision Making</b> Organisers: The Hong Kong Medical Association & Medical Protection Society, Speaker: Dr. FUNG Shu Yan, Anthony, Venue: HKMA Dr. Li Shu Pui Professional Education Centre, 2/F, Chinese Club Building, 21-22 Connaught Road, Central	HKMA CME Dept Tel: 2527 8452 2.5 CME Point
<b>13</b> 1:00pm	<b>"1st Series Certificate Course on Dementia for Primary Care Doctors" Topic 3. Medical and Community Collaboration – Case Management In Community</b> Organiser: HKMA YTM Community Network & HKADA - Institute of Alzheimer's Education, Chairman: Dr. LAM King Hei, Stanley, Speaker: Ms. Viggie TANG, Venue: Pearl Ballroom, Level 2, Eaton, Hong Kong, 380 Nathan Road, Kowloon	Miss Hana YEUNG Tel: 2527 8285 1 CME Point





Date / Time	Function	Enquiry / Remarks
<b>13 FRI</b> 7:00pm	<b>RSCP 2014 Party</b> Organiser: Recreation and Sports Club for Hong Kong Professional Bodies (RSCP), Venue: The Grand Stage, Des Voeux Road Central 323, Hong Kong	Miss Nadia HO Tel: 2527 8285
<b>14 SAT</b> 2:15pm	<b>HKMA CME - Refresher Course for Health Care Providers 2013/2014</b> Organisers: Hong Kong Medical Association, HK College of Family Physicians & HA - Our Lady of Maryknoll Hospital, Speaker: Ms. Chan Yim Ting, Tina, Venue: Our Lady of Maryknoll Hospital, 118 Shatin Pass Road, Shatin	Ms. Clara Tsang Tel: 2354 2440 2 CME Point
2:30pm	<b>MPS Workshop - Mastering Difficult Interactions with Patients</b> Organisers: The Hong Kong Medical Association & Medical Protection Society, Speaker: Dr. CHENG Ngai Shing, Justin, Venue: HKMA Dr. Li Shu Pui Professional Education Centre, 2/F, Chinese Club Building, 21-22 Connaught Road, Central	HKMA CME Dept Tel: 2527 8452 2.5 CME Point
<b>18 WED</b> 1:00pm	<b>HKMA Central, Western &amp; Southern Community Network - Breast Cancer Detection &amp; Screening in 2014: What the Family Physician Needs to Know</b> Organiser: HKMA Central, Western & Southern Community Network, Speaker: Dr. WONG Chun Kuen, Venue: HKMA Dr. Li Shu Pui Professional Education Centre, 2/F, Chinese Club Building, 21-22 Connaught Road, Central	Miss Hana YEUNG Tel: 2527 8285 1 CME Point
6:30pm	<b>MPS Workshop - Mastering Professional Interactions</b> Organisers: The Hong Kong Medical Association & Medical Protection Society, Speaker: Dr. CHENG Ngai Shing, Justin, Venue: Eaton Hotel	HKMA CME Dept Tel: 2527 8452 2.5 CME Point
<b>19 THU</b> 9:00am (20)	<b>HKMA CME - Refresher Course for Health Care Providers 2013/2014</b> Organisers: Hong Kong Medical Association, HK College of Family Physicians & HA - Our Lady of Maryknoll Hospital, Speaker: Ms. Chan Yim Ting, Tina, Venue: Our Lady of Maryknoll Hospital, 118 Shatin Pass Road, Shatin	Ms. Clara Tsang Tel: 2354 2440 2 CME Point
1:00pm	<b>HKMA New Territories West Community Network - 1st Series Certificate Course on Dementia for Primary Care Doctors (Session 2): Drug Treatment - Strategic Pharmacological Intervention for Dementia</b> Organiser: HKMA New Territories West Community Network and Institute of Alzheimer's Education (IAE) of Hong Kong Alzheimer's Disease Association (HKADA), Chairman: , Speaker: Dr. Stanley TAM, Venue: Plentiful Delight Banquet (元朗喜尚嘉喜酒家), 1/F., Ho Shun Tai Building, 10 Sai Ching Street, Yuen Long	Miss Hana YEUNG Tel: 2527 8285 1 CME Point
6:30pm	<b>MPS Workshop - Mastering Adverse Outcomes</b> Organisers: The Hong Kong Medical Association & Medical Protection Society, Speaker: Dr. HUNG Chi Wan, Emily, Venue: Eaton Hotel	HKMA CME Dept Tel: 2527 8452 2.5 CME Point
8:00pm	<b>FMSHK Executive Committee Meeting</b> Organiser: The Federation of Medical Societies of Hong Kong, Venue: Council Chamber, 4/F, Duke of Windsor Social Service Building, 15 Hennessy Road, Wanchai, Hong Kong	Ms. Nancy CHAN Tel: 2527 8898
<b>21 SAT</b> 12:30pm	<b>The 7th Annual Scientific Meeting and 8th Annual General Meeting of the Hong Kong Society for Paediatric Immunology and Infectious Diseases</b> Organiser: Hong Kong Paediatric Immunology and Infectious Diseases, Chairman: Dr CW LEUNG, Speakers: Prof Ronald de GROOT & Prof Adrian THRASHER	Dr Mike KWAN Tel: 2990 2872 Pending CME Point
1:30pm	<b>KECN / HKCFP / UCH - CME Course for Health Personnel 2014 - Common Eye Infections</b> Organiser: HKMA Kowloon East Community Network, Hong Kong College of Family Physicians & United Christian Hospital, Chairman: Dr. SHIU Ka Lok, Ivan, Speaker: Dr. MAK Shiu Ting, Theresa, Venue: United Christian Hospital, 130 Hip Wo Street, Kwun Tong	Ms. Polly TAI / Ms. Cordy WONG Tel: (Ms. TAI) 3513 3430 / (Ms. WONG) 3513 3087 Fax: 3513 5505 1.5 CME Point
<b>22 SUN</b>	<b>RSCP Dragon Boat Race 2014</b> Organiser: Recreation and Sports Club for Hong Kong Professional Bodies (RSCP), Venue: Stanley	Mr. Andie HO Tel: 2527 8285
<b>24 TUE</b> 1:00pm	<b>HKMA Kowloon West Community Network - Advancement of Meningococcal Conjugate Vaccine &amp; Global Practice</b> Organiser: HKMA Kowloon West Community Network, Speaker: Dr. Tong Kai Sing, Venue: Crystal Room I-III, 30/F., Panda Hotel, 3 Tsuen Wah Street, Tsuen Wan	Miss Hana YEUNG Tel: 2527 8285 1 CME Point
1:45pm	<b>HKMA Tai Po Community Network - Updated Management in Allergic Rhinitis</b> Organiser: HKMA Tai Po Community Network, Speaker: Dr. HO Nga Yi, Fiona, Venue: Chiuchow Garden Restaurant(潮江春) Shop 001-003, 1/F, Uptown Plaza (新達廣場), No.9 Nam Wan Road, Tai Po	Mr. Kiev WONG Tel: 9045 5058 1 CME Point
9:00pm	<b>Council Election Forum</b> Organiser: The Hong Kone Medical Association, Venue: HKMA Central Premises, Dr. Li Shu Pui Professional Education Centre, 2/F, Chinese Club Building, 21-22 Connaught Road, Central, Hong Kong	
<b>25 WED</b> 1:00pm	<b>HKMA Central, Western &amp; Southern Community Network - "Eye-land mines" in Daily Practice: Be Very Careful About "Red Eye" &amp; in Talking About Cataract Surgery</b> Organiser: HKMA Central, Western & Southern Community Network, Speaker: Dr. LAW Wai Kee, Venue: HKMA Central Premises, Dr. Li Shu Pui Professional Education Centre, 2/F, Chinese Club Building, 21-22 Connaught Road, Central	Miss Hana YEUNG Tel: 2527 8285 1 CME Point
<b>27 FRI</b> 1:00pm	<b>"1st Series Certificate Course on Dementia for Primary Care Doctors" Topic 4. Case Demonstration</b> Organiser: HKMA YTM Community Network & HKADA - Institute of Alzheimer's Education, Chairman: Dr. LAM Siu Keung, Speaker: Dr. CHAN Chun Chung, Ray, Venue: Jade Ballroom, Level 2, Eaton, Hong Kong, 380 Nathan Road, Kowloon	Miss Hana YEUNG Tel: 2527 8285 1 CME Point
7:30pm	<b>HKMA Wine Dinner - Yarra Yering - A Hidden Gem in the Valley</b> Organiser: The Hong Kone Medical Association, Chairman: Dr. LEUNG Kay Tai, Franky, Dr. LEUNG Yu Lung, Dexter, Venue: HKMA Central Premises, Dr. Li Shu Pui Professional Education Centre, 2/F, Chinese Club Building, 21-22 Connaught Road, Central	Mr. Benjamin CHAN Tel: 2527 8285
<b>29 SUN</b> 2:00pm	<b>HKMA Tenpin Bowling Tournament 2014</b> Organiser: The Hong Kone Medical Association, Chairman: Dr. HO King Yip, Anthony, Venue: South China Athletic Association (SCAA), 1/F, Sports Centre, 88 Caroline Hill Road, Causeway Bay	Mr. Andie HO Tel: 2527 8285
2:00pm	<b>HKMA Table-Tennis Tournament 2014</b> Organiser: The Hong Kone Medical Association, Chairman: Dr. KOO Hok Tin, Hilton, Venue: Dr. Stephen HUI Sports Hall, L.G, Lam Woo International Conference Centre, Hong Kong Baptist University, Renfrew Road, Kowloon Tong	Mr. Ian KWA Tel: 2527 8285





# Conference & Exhibition

*Quality Healthcare Professionals - Quality Care*

優質醫護 保健康民

18<sup>th</sup> & 19<sup>th</sup> October 2014  
KOWLOON SHANGRI-LA HOTEL

## Distinguished Guests and Speakers:

**Dr Ko Wing-man, BBS, JP**

**Prof. John Leong, OBE, SBS, JP**

**Mr Gao Qiang**

**Mr Anthony Wu, GBS, JP**

**Dr Leung Pak-yin, JP**

**Prof. Francis Chan, JP**

**Prof. Chan Wai-sum**

**Prof. Fung Hong, JP**

**Prof. Gabriel Leung, GBS**

**Prof. Tiwari Agnes Fung-yee**

**Prof. E K Yeoh, OBE, GBS, JP**

**Ms Angela Lee**

**Mr Jacob Tse**

And Many Others ...

Secretary for Food and Health, Food and Health Bureau

Founding Patron, MSHP / Chairman, Hospital Authority

Former Minister of Health, People's Republic of China

Standing Committee Member, Chinese People's Political Consultative Conference National Committee

Chief Executive, Hospital Authority

Dean of the Faculty of Medicine, CUHK

Professor of Department of Finance, CUHK

Honorary Professor of School of Public Health and Primary Care, CUHK

Dean of the Li Ka Shing Faculty of Medicine, HKU

Head of School of Nursing, HKU

Professor of Public Health, CUHK

Senior Vice President, Director of SE Asia, Healthcare Group, HKS

Partner, Mayer Brown JSM



## Conference Topics:

Healthcare Trends and Reforms in China

Performance Management for quality patient services

Clinician/ Manager for Tomorrow

Healthcare Financing - The Case for Medical Insurance

Quality Healthcare Services Planning

Leadership in Healthcare

Nursing Profession: Facing Technology Challenges and Opportunities

Comparative health systems

Green Hospitals

Issues and Challenges in the increasingly litigious healthcare environment

## Registration Fees:

**Early Bird: \$1,500**  
(on or before 18<sup>th</sup> July, 2014)

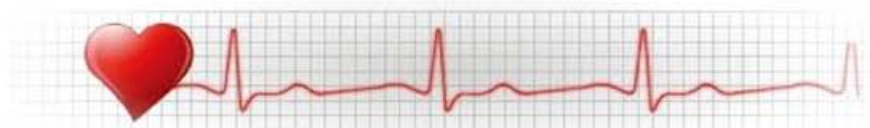**Local: \$1,800**

**Group: Buy 4 get 1 free**

**Non-local: \$2,300**

**On-site: \$2,300**

**Need medical or dental equipment,  
but don't want huge capital outlay?**



Our **Equipment Finance** helps you expand your business and improve efficiency by offering you ready cash to acquire business installations and equipment.

What benefits will you enjoy?

Preferential  
Interest Rate

Simple  
application and  
quick  
processing

Borrow up to  
100% of  
equipment's  
purchase price

Flexible  
payment term  
as long as  
36 months



Hitachi Capital Corporation (a member of Hitachi Group company) was founded in 1957 and is listed on Tokyo Stock Exchange as an integrated financial services group which has overseas operations in 7 countries worldwide.

Hitachi Capital (HK) Limited as her subsidiary company was established in 1975.