



Title	Defining clinically relevant values for developmental spinal stenosis: a large-scale magnetic resonance imaging study
Author(s)	Cheung, JPY; Samartzis, D; Shigematsu, H; Cheung, KMC
Citation	Spine, 2014, v. 39 n. 13, p. 1067-1076
Issued Date	2014
URL	http://hdl.handle.net/10722/203252
Rights	This is a non-final version of an article published in final form in Spine, 2014, v. 39 n. 13, p. 1067-1076

**DEFINING CLINICALLY-RELEVANT VALUES FOR DEVELOPMENTAL
SPINAL STENOSIS: A LARGE SCALE MRI STUDY**

Authors: Jason Pui-Yin Cheung¹, MBBS(HK),

Dino Samartzis¹, DSc

Hideki Shigematsu², M.D.

Kenneth Man-Chee Cheung¹, M.D.

Affiliations: ¹Department of Orthopaedics and Traumatology, Queen Mary Hospital, The University of Hong Kong, Pokfulam, Hong Kong SAR, China

²Department of Orthopaedics Surgery, Nara Medical University, Kahihara, Nara, Japan

Corresponding author: Kenneth Man-Chee Cheung

Jessie Ho Professor in Spine Surgery

Head, Department of Orthopaedics & Traumatology

The University of Hong Kong

Queen Mary Hospital, Pokfulam Road

Hong Kong SAR, China

Tel: (+852) 2255-4341

Fax: (+852) 2817-4392

Email: cheungmc@hku.hk

Ethics approval from local institutional review board achieved.

Work supported by grants from Hong Kong Theme-Based Research Scheme (T12-708/12N) and the Hong Kong Area of Excellence programme (AoE/M04/04).

Abstract

Study Design: Case-control study

Objective: The aim of this study was to define clinically-relevant relative and critical (absolute) MRI values of lumbar spinal stenosis in a cohort of 100 surgical cases and 100 asymptomatic controls.

Summary of Background Data: Developmental spinal stenosis is a precipitating factor in patients presenting with lumbar canal stenosis. Yet due to a lack of agreement on definitions and methods of assessment, as well as ethnic-specific normative values, its prevalence and significance is not known.

Methods: This was a case-control study comparing 100 age and sex-matched asymptomatic, volunteers to that of 100 patients who underwent surgery for spinal stenosis. All patients were of Chinese ethnicity and their details were blinded to two observers. Spinal stenosis parameters were measured based on axial (pedicle level) and sagittal (mid-sagittal) MRI scans.

Results: Anteroposterior (AP) spinal canal diameters changes with levels. At each level, patients were found to have significantly narrower AP canal diameters compared with controls. By use of receiver operating characteristic (ROC) curve, we defined developmental spinal stenosis if the AP canal diameter at L1<20mm, L2<19mm, L3<19mm, L4<17mm, L5<16mm and at S1<16mm based on a value including 50% of controls and demonstrated best sensitivity and specificity. Furthermore, for L4, L5 and S1, critical stenosis values could be defined, below which almost all subjects needed surgery, these were L4<14mm, L5<14mm and S1<12mm.

Discussion: This is the largest MRI-based study with standardized measurements and comparable groups to determine clinically-relevant radiographic criteria for lumbar spinal stenosis. The findings strongly suggest that developmental stenosis plays an important role in the pathogenesis of symptomatic spinal stenosis. Critical values of stenosis below which symptoms were highly likely were defined. These will need to be validated by longitudinal studies in future. However, they may possess clinical utility in determining the appropriate levels requiring canal-widening surgery.

Key Words: Developmental; Spinal; Stenosis; MRI; Axial; Sagittal; Bony; Canal; Diameter; Critical

Key Points

1. Patients requiring surgery for spinal stenosis were found to have narrower bony spinal canal diameters than normal subjects.
2. Critical values of stenosis by axial AP diameter of the bony spinal canal were defined for L4 (14mm), L5 (14mm), and S1 (12mm) which indicated the patients who require decompression surgery.
3. Values of developmental spinal stenosis were defined as L1:20mm, L2:19mm, L3:19mm, L4:17mm, L5:16mm and in S1:16mm which identified subjects with a probable chance of developing symptoms of spinal stenosis requiring surgery and should be closely followed-up.

Mini-Abstract

In this MRI-based study of 200 cases and controls, patients were found to have narrower bony lumbar spinal canal diameters than controls, strongly implicating developmental stenosis in the pathogenesis of symptomatic lumbar stenosis. Critical values of narrowing predicting the need for surgery, and level-specific values of developmental stenosis were defined.

1 INTRODUCTION

2
3
4
5
6
7
8
9
10
11
12
13
14
15
16
17
18
19
20
21
22
23
24
25
26
27
28
29
30
31
32
33
34
35
36
37
38
39
40
41
42
43
44
45
46
47
48
49
50
51
52
53
54
55
56
57
58
59
60
61
62
63
64
65

1 Lumbar developmental spinal stenosis is likely a genetic disturbance during both fetal and postnatal development of the lumbar vertebrae until maturity.¹⁻³ Several mutations have been associated with spinal stenosis such as COL9A2, Trp2 and Trp3 indicating that genetic factors have an important role in its pathogenesis.⁴⁻⁶ These findings suggest that the genetic predisposition is similar to that of disc degeneration.^{4,7,8} In the presence of a narrow lumbar canal, changes associated with degeneration or aging, such as intervertebral disc bulging and facet hypertrophy, may readily cause compressive symptoms.

10 Verbiest² defined developmental narrowing of the lumbar canal by an abnormally short antero-posterior diameter on plain radiographs (**Figure 1**), and an absolute value of less than 10mm as developmental stenosis. This is still a commonly accepted criterion although the rationale for this value is not known. Throughout the years, numerous other criteria have been proposed^{2,3,9-16} based on imaging (**Table 1**). However, these studies utilized inconsistent imaging modalities including radiographs, CT and MRI,^{3,9,12,15,16} some were based on heterogeneous populations,^{3,9,10,12,15,17,18} some lacked control groups,^{3,9,10,12,18} while others based definitions on generalized measurements of the entire lumbar spine.^{3,9,10,12,15-18} In addition, absolute values of anatomic parameters are likely to vary between ethnic groups, and no comparative anatomic studies have been carried out in the Chinese population, which represent a third of the world's population.

1
2
3
4 21 Due to the limitations of our understanding of developmental lumbar spinal stenosis as
5
6 22 stated above, the aim of this study was multi-faceted. For one, we aimed to confirm whether
7
8
9 23 patients presenting for surgery with symptoms of spinal stenosis had narrower canals when
10
11 24 compared to an asymptomatic control group. Secondly, we aimed to define the value for lumbar
12
13
14 25 spinal stenosis for a Chinese population. Thirdly, we endeavored to define a critical value of
15
16 26 anatomic narrowing of the lumbar bony spinal canal that has diagnostic utility in determining
17
18
19 27 surgical candidates.
20
21
22 28

29 **MATERIALS AND METHODS**

30
31

32 *Study Design*

33
34

35 32 Following approval by the institutional review board, a case-control study design assessing
36
37
38 33 100 asymptomatic individuals and 100 patients who underwent surgery for spinal stenosis
39
40 34 between December 2001 and December 2011 was performed. All subjects were of Chinese
41
42
43 35 ethnicity. The control group was sex- and age-matched, and randomly selected based on those
44
45 36 criteria from the Hong Kong Disc Degeneration Cohort Study.¹⁹⁻²² This is a population-based
46
47
48 37 cohort of approximately 3,500 individuals with MRI information, whose recruitment was not
49
50 38 predicated on condition. Control subjects for the current study were only selected if there was no
51
52
53 39 past history of low back or leg pain, spinal pathologies or surgery. The 100 surgical patients were
54
55 40 selected at random from a pool of patients who underwent surgery for spinal stenosis in the past
56
57 41 10 years. All included patients were diagnosed to have spinal stenosis by a senior spine surgeon

1
2
3
4 42 based on symptoms of neurogenic claudication. All patients required MRI assessment to confirm
5
6 43 the diagnosis and level of involvement. Patients were offered decompression surgery if
7
8 44 symptoms persisted despite 6 weeks of conservative management that includes avoidance of
9
10 45 spine extension positions, physical therapies (core muscle strengthening and aerobic
11
12 46 conditioning), and non-steroidal anti-inflammatory medications. Subjects with congenital
13
14 47 deformities, previous infections, tumors, trauma or spondylolisthesis of the lumbar spine were
15
16 48 excluded from the study.
17
18
19
20
21
22 49

23 24 25 50 *Measurements*

26
27
28
29 51 Sagittal and axial MRI images of the lumbar spine from L1-S1 were utilized for all
30
31 52 subjects. Lumbar sagittal T2-weighted and axial T1 or T2-weighted MRIs from L1-S1 were
32
33 53 assessed in all subjects. All controls had T1-weighted axial MRI films. Eight subjects of the
34
35 54 patient group only had T2-weighted axial MRI films for measurement. Data was collected as
36
37 55 usual as our previous study had shown that T1 and T2-weighted MRI films have comparable
38
39 56 spinal canal measurements.²³ Two investigators (JPYC, HS), blinded to all clinical information,
40
41 57 performed the measurements. A consensus on the standardized method of measurements was
42
43 58 made prior to data collection. For reliability testing, ten random subjects retrieved from the
44
45 59 cohort of controls were used for intra-observer and inter-observer reliability assessments. The
46
47 60 first and second round of measurements was performed at least one month apart. All images
48
49 61 were measured using the Centricity Enterprise Web V3.0 (GE Medical Systems, 2006),
50
51 62 VirtualDrive Pro (FarStone) and ImageJ (version 1.45) software.
52
53
54
55
56
57
58
59
60
61
62
63
64
65

1
2
3
4 63 Measurements were performed in both MRI axial (**Figure 2 and 3**) and sagittal (**Figure**
5
6 64 **4**) scans. The axial image used for measurement was the cut with the thickest pedicle diameter
7
8
9 65 while the sagittal image used was the mid-sagittal cut that bisected the spinous processes.
10
11 66 Measurements in the axial scan (**Figure 2**) included: midline anteroposterior (AP) vertebral body
12
13 67 diameter, mid-vertebral body width, midline AP bony spinal canal diameter, midline AP dural
14
15 68 sac diameter, bony spinal canal width/interpedicular distance, pedicle width (right and left), and
16
17 69 lamina angle (**Figure 3**): angle made from two lines crossing from the base of the spinous
18
19 70 process along the lamina to the base of the pedicles. Measurements in the sagittal scan (**Figure**
20
21 71 **4**) included the midline AP body diameter, mid-vertebral body height and AP bony spinal canal
22
23 72 diameter (from the most prominent tip of the spinous process, taking a perpendicular line to the
24
25 73 vertebral body).

26
27
28
29
30 74 Most measurements, except for the AP bony spinal canal diameter and the lamina angle,
31
32 75 in this study have been previously reported.^{2,3,9,10,13,15,16,24-29} The lamina angle was a bony
33
34 76 measurement used to assess spinal stenosis since it could represent the lamina shape and were
35
36 77 measured with an angle from the base of the spinous process to the pedicles. This measurement
37
38 78 had not been verified by previous studies and was constructed by the authors at the start of the
39
40 79 study. It was postulated that a more acute lamina angle (narrower space between the laminae)
41
42 80 would lead to a narrower bony spinal canal.
43
44
45
46
47

48 81 49 50 82 *Statistical Analysis*

51
52
53 83 Descriptive and frequency statistics were performed of the data. Reliability assessment
54
55 84 was based on Cronbach's alpha analysis. Excellent and good reliability were noted in alpha
56
57 85 values of 0.90-1.00 and 0.80-0.89, respectively.³⁰ Following normality testing of the data using
58
59
60
61
62
63
64
65

1
2
3
4 86 the Shapiro-Wilk test, paired t-tests were performed to detect image measurement differences
5
6
7 87 between the two groups. A p-value of less than 0.05 was considered significant.
8

9 88 Receiver operating characteristic (ROC) curve was used to identify the most significant
10
11 89 imaging measurement based on area under the curve (AUC) analysis. ROC analysis was also
12
13
14 90 used to identify cut-off critical values for symptomatic developmental spinal stenosis between
15
16 91 the control and patient groups. The critical values for absolute spinal stenosis were noted as the
17
18
19 92 value with the highest sensitivity in symptomatic cases. Absolute stenosis or critical stenosis acts
20
21 93 as the cut-off value for the axial bony spinal canal AP diameter; therefore, any subject with a
22
23
24 94 narrow canal diameter regarded as having absolute stenosis would most likely require surgery for
25
26 95 spinal stenosis. For relevant stenosis or developmental stenosis, the defining value was based on
27
28
29 96 the cut-off value of AP bony spinal canal diameter for patients that would include approximately
30
31 97 50% of the controls and also demonstrating the best sensitivity and specificity for identifying this
32
33
34 98 subject group. These relative values indicate which subjects are likely to develop spinal stenosis
35
36 99 symptoms requiring surgery in the future. Although having the 50% cut-off point may not
37
38 100 include all patients with developmental narrowing, the authors believe that a clinically useful
39
40
41 101 definition that has a bearing on the future risk of symptom development is preferable. As such,
42
43 102 using the proposed criteria, half of the subjects with diameters less than this value have
44
45
46 103 developed symptoms. Having a respectable sensitivity and specificity is important to determine a
47
48 104 cut-off value that does not miss many actual patients with developmental narrowing and avoids
49
50
51 105 including too many normal subjects, which would heavily burden a follow-up clinic for these
52
53 106 patients.
54

55 107

58 108 **RESULTS**

109

110 The mean age for controls was 45 years (SD \pm 1.4, range 20-69) while the patient group
111 was 62.6 years (SD \pm 14.9, range 15-86). There were 50 males and 50 females in the control
112 group and 48 males and 52 females in the patient group. Good to excellent inter-observer
113 reliability (α =0.88-0.97) and excellent intra-observer reliability between the two observers
114 (α =0.94-0.99 and α =0.94-0.99) were noted. The mean body weight was 63.4 kilograms (SD
115 \pm 12.5, range 43-98), body height was 1.65 meters (SD \pm 0.1, range 1.45-1.84) and the BMI was
116 23.1 kg/m² (SD \pm 3.5, range 16.1-34.1). No differences were found after age stratification for
117 gender (p=0.984), body weight (p=0.821), body height (p=0.135) and BMI (p=0.262) between
118 groups.

119 Comparing the two subject groups, controls had significantly wider AP bony spinal canal
120 diameters than patients (**Table 2/Figure 5**). While, as would be expected for symptomatic
121 subjects, the AP dural diameter was narrower (**Table 3**). For other measured MRI parameters of
122 the spinal canal (**Table 3**), there were no statistically significant differences between the two
123 groups.

124 Based on AUC analysis of the measured imaging dimensions, axial AP bony spinal canal
125 diameter was deemed most predictive for developmental spinal stenosis (**Table 4**). Since all
126 patients had symptomatic levels at L4, L5 or S1, absolute stenosis values of only these three
127 levels were reported (**Table 5**). Level-specific values of relative stenosis were also suggested
128 (**Table 5**).

129

1
2
3
4 130 **DISCUSSION**

5
6
7 131
8
9
10
11 132 Our results showed significantly wider bony spinal canal diameters in controls as
12
13 133 compared to patients. Thus, confirming our hypothesis that patients with symptomatic spinal
14
15 134 stenosis requiring surgery have narrowed canals making them more prone to developing
16
17 135 symptoms. Moreover by use of the ROC curve, we were able to identify critical values of canal
18
19 136 diameter below which was evident in all patients who require surgery for spinal stenosis. Since
20
21 137 defining critical stenosis requires a comparison of control and symptomatic subjects, and that the
22
23 138 majority of patients presented with symptoms only between L4 and S1, we could only define
24
25 139 critical stenosis values for these three levels. Nevertheless, excellent sensitivity and specificity
26
27 140 results for these three levels were obtained. As all controls had wider bony spinal canal
28
29 141 diameters, any subject with canal sizes reaching these critical levels may potentially benefit from
30
31 142 pre-emptive canal widening surgery. Further longitudinal studies based on these observed values
32
33 143 are required to demonstrate any benefit of surgery for asymptomatic canal narrowing. By
34
35 144 performing a single stage canal widening surgery initially, these patients may avoid repeat
36
37 145 surgery at adjacent levels; however, further studies are needed to assess the clinical utility of our
38
39 146 observed values in this context.

40
41
42 147 There are no guidelines as to how developmental stenosis could be defined. Since in a
43
44 148 population, such measurements are a continuous variable, to have an arbitrary cut-off at a
45
46 149 specific diameter, may not be usefully clinically. Thus, we based the definition of developmental
47
48 150 stenosis on a value that includes approximately 50% of the controls with demonstrated best
49
50 151 possible sensitivity and specificity results to identify this at-risk group. These relative values are

1
2
3
4 152 indicative with adequate sensitivity and specificity as to which subjects may develop future
5
6 153 spinal stenosis symptoms requiring surgery. The 50% cut-off point was an arbitrary yet
7
8
9 154 appropriate value since it would only be relevant if we could at least distinguish 50% of our
10
11
12 155 possible patients. By applying this cut-off value, individuals with relatively narrowed spinal
13
14 156 canals can still be followed-up without overloading a busy clinic.

15
16 157 Based on our criteria, it is highly likely that patients who require surgery for spinal
17
18
19 158 stenosis would have critically narrowed axial bony spinal canal AP diameters; while patients
20
21 159 with relatively narrowed axial bony spinal canal AP diameters should be closely followed-up
22
23 160 because at least 50% of patients have similar sized spinal canals.

24
25
26 161 Reoperation is not an uncommon event and occurs in 13% of patients with approximately
27
28
29 162 50% of reoperations performed at adjacent levels.³¹ This leads to an average reoperation rate of
30
31 163 3.3% of patients per year. Other studies showed that reoperation after decompressive
32
33 164 laminectomy varied from 5-23%.³²⁻³⁴ Based on this study, one could hypothesize that patients
34
35
36 165 with pre-existing narrow canals are more likely to develop symptoms of spinal stenosis, and are
37
38 166 also more at risk from developing symptoms from adjacent level degeneration.

39
40
41 167 Obtaining accurate measurement of different variables was important for comparison. It
42
43
44 168 has been demonstrated that measurements of canal diameters using either T1 or T2-weighted
45
46 169 MRI images were comparable and accurate.²³ Hence both types of images were used in the
47
48
49 170 current study. The key measured variable discussed in this study was the AP bony spinal canal
50
51 171 diameter. Also known as the pedicle length, this parameter equated to the space available for the
52
53
54 172 neural elements to coexist with other pathologies such as osteophytes, disc protrusions or
55
56 173 hypertrophied soft tissues. Most studies lacked a uniform method of measurement for the bony
57
58
59 174 spinal canal diameter.^{2,9,10,13-16,24,25,28} Some studies used the mid-vertebral level on sagittal cuts,

1
2
3
4 175 while others used the disc or endplate level on axial and sagittal cuts. These methods may be
5
6 176 subject to wide variability as the posterior curvature of the vertebral body may affect mid-
7
8
9 177 vertebral level assessments at the sagittal level and disease may affect the accuracy of
10
11 178 measurements at the disc and endplate levels. In this study, the bony spinal canal diameter can be
12
13
14 179 better appreciated at the pedicle level because of the consistent landmarks.

15
16 180 Inevitably, this study had some limitations. Of note was that the MRI protocol was not
17
18
19 181 standardized between the groups. This might have led to some errors in measurement if the cuts
20
21 182 were not absolutely comparable between the controls and patients. Sagittal scans might have
22
23
24 183 posed some problems since the mid-sagittal cut might not be consistent in the presence of
25
26 184 scoliosis or poor patient positioning in the MRI scanner. Sagittal vertebral body width and height
27
28
29 185 were subject to the individual's degree of degenerative disc disease and this might affect the
30
31 186 accuracy of measurements. In such instances, special attention was required to avoid pitfalls,
32
33
34 187 such as including osteophytes found on the edge of the vertebral bodies (usually more
35
36 188 hypointense than the bone in the vertebral body) and degenerated disc spaces and endplates
37
38 189 (hypointense lining) into the measurements. This was likely the cause of finding controls to have
39
40
41 190 taller and wider vertebral bodies on the sagittal scan than patients. The height might be decreased
42
43 191 due to collapse from elderly age and difficulty in distinguishing the bony contour from the
44
45
46 192 endplates or osteophytes which again was more prominent in the older subjects. Thus, there was
47
48 193 a limitation in direct comparison between the controls and patients for vertebral body
49
50
51 194 measurements.

52
53 195 This is the largest MRI based study (**Table 1**) on lumbar spinal stenosis conducted in a
54
55
56 196 Chinese population. Patient parameters were blinded to the two observers and the measurement
57
58 197 techniques were uniform. Inter and intra-observer reliability analyses were performed, noted as

1
2
3
4 198 good to excellent. Patients were found to have narrower bony spinal canal diameters than
5
6
7 199 controls. Our study identified absolute critical values of spinal stenosis of L4 to S1. Furthermore,
8
9 200 our study noted level-specific suggested values from L1-S1 of developmental spinal stenosis.
10
11
12 201

15 202 **CONCLUSIONS**

17
18
19 203
20
21
22 204 Our study further broadens the understanding of developmental spinal stenosis.
23
24 205 Understanding its critical values throughout the lumbar spine may provide the rationale and
25
26
27 206 patient selection for preemptive canal widening surgery to prevent future development of
28
29
30 207 symptoms. However, to confirm this, future prospective follow-up studies of these at risk
31
32 208 subjects would be required to see whether they develop symptoms at developmentally stenotic
33
34
35 209 levels. This study also further elaborates on the phenotype of stenosis, which may serve as the
36
37 210 foundation for future genetic analysis. For genome-wide association studies, these quantitative
38
39
40 211 values described in this study can help differentiate study subjects into having either normal or
41
42 212 developmentally narrowed spinal canals. By identifying the gene polymorphisms responsible for
43
44 213 spinal canal narrowing, functional genes and possible gene therapies can be introduced.
45
46
47 214

50 215 **ACKNOWLEDGEMENT**

51
52
53
54 216 This work was supported by grants from the Hong Kong Theme-Based Research Scheme
55
56
57 217 (T12-708/12N) and the Hong Kong Area of Excellence programme (AoE/M-04/04). We would
58
59
60
61
62
63
64
65

1
2
3
4
5
6
7
8
9
10
11
12
13
14
15
16
17
18
19
20
21
22
23
24
25
26
27
28
29
30
31
32
33
34
35
36
37
38
39
40
41
42
43
44
45
46
47
48
49
50
51
52
53
54
55
56
57
58
59
60
61
62
63
64
65

218 like to thank Mrs. Yu Pei from the Department of Biochemistry, The University of Hong Kong
219 for her help with this study.

References

1. Kirkaldy-Willis WH, Wedge JH, Yong-Hing K, Reilly J. Pathology and pathogenesis of lumbar spondylosis and stenosis. *Spine (Phila Pa 1976)* 1978;3(4):319-28.
2. Verbiest H. Further experiences on the pathological influence of a developmental narrowness of the bony lumbar vertebral canal. *J Bone Joint Surg Br* 1955;37-B(4):576-83.
3. Verbiest H. Fallacies of the present definition, nomenclature, and classification of the stenoses of the lumbar vertebral canal. *Spine* 1976;1:217-25.
4. Hyun SJ, Park BG, Rhim SC, Bae CW, Lee JK, Roh SW, et al. A haplotype at the COL9A2 gene locus contributes to the genetic risk for lumbar spinal stenosis in the Korean population. *Spine (Phila Pa 1976)* 2011;36(16):1273-8.
5. Noponen-Hietala N, Kyllonen E, Mannikko M, Ilkko E, Karppinen J, Ott J, et al. Sequence variations in the collagen IX and XI genes are associated with degenerative lumbar spinal stenosis. *Ann Rheum Dis* 2003;62(12):1208-14.
6. Sebastian A, Matsushita T, Kawanami A, Mackem S, Landreth GE, Murakami S. Genetic inactivation of ERK1 and ERK2 in chondrocytes promotes bone growth and enlarges the spinal canal. *J Orthop Res* 2011;29(3):375-9.
7. Aladin DM, Cheung KM, Chan D, Yee AF, Jim JJ, Luk KD, et al. Expression of the Trp2 allele of COL9A2 is associated with alterations in the mechanical properties of human intervertebral discs. *Spine (Phila Pa 1976)* 2007;32(25):2820-6.
8. Jim JJ, Noponen-Hietala N, Cheung KM, Ott J, Karppinen J, Sahraravand A, et al. The TRP2 allele of COL9A2 is an age-dependent risk factor for the development and severity of intervertebral disc degeneration. *Spine (Phila Pa 1976)* 2005;30(24):2735-42.

9. Bolender NF, Schonstrom NS, Spengler DM. Role of computed tomography and myelography in the diagnosis of central spinal stenosis. *J Bone Joint Surg Am* 1985;67(2):240-6.
10. Chatha DS, Schweitzer ME. MRI criteria of developmental lumbar spinal stenosis revisited. *Bull NYU Hosp Jt Dis* 2011;69(4):303-7.
11. Cheung KM, Ruan D, Chan FL, Fang D. Computed tomographic osteometry of Asian lumbar pedicles. *Spine (Phila Pa 1976)* 1994;19(13):1495-8.
12. Fang D, Cheung KM, Ruan D, Chan FL. Computed tomographic osteometry of the Asian lumbar spine. *J Spinal Disord* 1994;7(4):307-16.
13. Hamanishi C, Matukura N, Fujita M, Tomihara M, Tanaka S. Cross-sectional area of the stenotic lumbar dural tube measured from the transverse views of magnetic resonance imaging. *J Spinal Disord* 1994;7(5):388-93.
14. Inui Y, Doita M, Ouchi K, Tsukuda M, Fujita N, Kurosaka M. Clinical and radiologic features of lumbar spinal stenosis and disc herniation with neuropathic bladder. *Spine (Phila Pa 1976)* 2004;29(8):869-73.
15. Lee HM, Kim NH, Kim HJ, Chung IH. Morphometric study of the lumbar spinal canal in the Korean population. *Spine (Phila Pa 1976)* 1995;20(15):1679-84.
16. Singh K, Samartzis D, Vaccaro AR, Nassr A, Andersson GB, Yoon ST, et al. Congenital lumbar spinal stenosis: a prospective, control-matched, cohort radiographic analysis. *Spine J* 2005;5(6):615-22.
17. Boden SD, Davis DO, Dina TS, Patronas NJ, Wiesel SW. Abnormal magnetic-resonance scans of the lumbar spine in asymptomatic subjects. A prospective investigation. *J Bone Joint Surg Am* 1990;72(3):403-8.

18. Lee SU, Lee JI, Butts K, Carragee E, Fredericson M. Changes in posterior lumbar disk contour abnormality with flexion-extension movement in subjects with low back pain and degenerative disk disease. *PM & R : the journal of injury, function, and rehabilitation* 2009;1(6):541-6.
19. Cheung KM, Samartzis D, Karppinen J, Luk KD. Are "patterns" of lumbar disc degeneration associated with low back pain?: new insights based on skipped level disc pathology. *Spine (Phila Pa 1976)* 2012;37(7):E430-8.
20. Mok FP, Samartzis D, Karppinen J, Luk KD, Fong DY, Cheung KM. ISSLS prize winner: prevalence, determinants, and association of Schmorl nodes of the lumbar spine with disc degeneration: a population-based study of 2449 individuals. *Spine (Phila Pa 1976)* 2010;35(21):1944-52.
21. Samartzis D, Karppinen J, Chan D, Luk KD, Cheung KM. The association of lumbar intervertebral disc degeneration on magnetic resonance imaging with body mass index in overweight and obese adults: a population-based study. *Arthritis Rheum* 2012;64(5):1488-96.
22. Samartzis D, Karppinen J, Mok F, Fong DY, Luk KD, Cheung KM. A population-based study of juvenile disc degeneration and its association with overweight and obesity, low back pain, and diminished functional status. *J Bone Joint Surg Am* 2011;93(7):662-70.
23. Cheung JP, Shigematsu H, Cheung KM. Verification of measurements of lumbar spinal dimensions in T1 and T2-weighted MRI sequences. *Spine J* 2013 [In Press].
24. Eisenstein S. Measurements of the lumbar spinal canal in 2 racial groups. *Clin Orthop Relat Res* 1976(115):42-6.

25. Epstein BS, Epstein JA, Jones MD. Lumbar spinal stenosis. *Radiol Clin North Am* 1977;15(2):227-39.
26. Modic MT, Masaryk T, Boumprey F, Goormastic M, Bell G. Lumbar herniated disk disease and canal stenosis: prospective evaluation by surface coil MR, CT, and myelography. *AJR Am J Roentgenol* 1986;147(4):757-65.
27. Modic MT, Ross JS. Magnetic resonance imaging in the evaluation of low back pain. *Orthop Clin North Am* 1991;22(2):283-301.
28. Schonstrom NS, Bolender NF, Spengler DM. The pathomorphology of spinal stenosis as seen on CT scans of the lumbar spine. *Spine (Phila Pa 1976)* 1985;10(9):806-11.
29. Speciale AC, Pietrobon R, Urban CW, Richardson WJ, Helms CA, Major N, et al. Observer variability in assessing lumbar spinal stenosis severity on magnetic resonance imaging and its relation to cross-sectional spinal canal area. *Spine (Phila Pa 1976)* 2002;27(10):1082-6.
30. Vangeneugden T, Laenen A, Geys H, Renard D, Molenberghs G. Applying concepts of generalizability theory on clinical trial data to investigate sources of variation and their impact on reliability. *Biometrics* 2005;61(1):295-304.
31. Radcliff K, Curry P, Hilibrand A, Kepler C, Zhao W, Lurie J, et al. Risk for Adjacent Segment and Same Segment Reoperation After Surgery for Lumbar Stenosis: A subgroup analysis of the Spine Patient Outcomes Research Trial (SPORT). *Spine (Phila Pa 1976)* 2012.
32. Deyo RA, Martin BI, Kreuter W, Jarvik JG, Angier H, Mirza SK. Revision surgery following operations for lumbar stenosis. *J Bone Joint Surg Am* 2011;93(21):1979-86.

33. Jansson KA, Nemeth G, Granath F, Blomqvist P. Spinal stenosis re-operation rate in Sweden is 11% at 10 years--a national analysis of 9,664 operations. *Eur Spine J* 2005;14(7):659-63.
34. Javalkar V, Cardenas R, Tawfik TA, Khan IR, Bollam P, Banerjee AD, et al. Reoperations after surgery for lumbar spinal stenosis. *World neurosurgery* 2011;75(5-6):737-42.
35. Santiago FR, Milena GL, Herrera RO, Romero PA, Plazas PG. Morphometry of the lower lumbar vertebrae in patients with and without low back pain. *Eur Spine J* 2001;10(3):228-33.
36. Jensen MC, Brant-Zawadzki MN, Obuchowski N, Modic MT, Malkasian D, Ross JS. Magnetic resonance imaging of the lumbar spine in people without back pain. *N Engl J Med* 1994;331(2):69-73.

TABLES

Table 1: Previous studies addressing developmental spinal stenosis

Author	Journal (Year)	Imaging	Subjects	Age	Findings	Limitations
Boden¹⁷	Journal of Bone and Joint Surgery (American) (1990)	MRI ⁺	67 asymptomatic subjects	20-80yrs	35% had bulging discs	Subjective readings only
Bolender⁹	Journal of Bone and Joint Surgery (American) (1985)	CT* and cadaveric	24 patients	Unknown	Narrowed dural sac equates to stenosis	Unknown measurement level
Chatha¹⁰	Bulletin NYU (2011)	MRI ⁺	100 patients	4-94yrs	0.9cm as cut-off for stenosis	Uncertain method of obtaining patients
Fang¹²	Journal of Spinal disorders (1994)	CT*	100 patients	18-60yrs Chinese population	Canal narrows with level Minimum sagittal diameter 10.8mm	No controls
Lee¹⁵	Spine (1995)	Cadaveric	90 (cadaveric)	19-70yrs	Narrowing of canal AP from cranial to caudal then widens at L4-5 (14.5-15.4mm)	Cadaveric study
Santiago³⁵	European Spine Journal (2001)	CT*	119 patients, 39 controls	Mean 42yrs	No difference in central canal	No standardized measuring level

Singh¹⁶	The Spine Journal (2005)	MRI ⁺ and XR [#]	15 patients, 15 controls	41-65yrs	Body to pedicle length ratio: 0.36 is critical value in MRI and 0.43 for XR	Small sample size Arbitrary endpoint for pedicle length measurement
Verbiest³	Spine (1976)	XR [#]	116 patients	Unknown	Absolute stenosis: <10mm Relative stenosis: 10-12mm	All vertebral levels measured Generalized criteria

⁺: Magnetic Resonance Imaging.

^{*}: Computed tomography.

[#]: X-ray radiograph.

Table 2: Comparison of anteroposterior bony spinal canal diameters between control subjects and patients

	Controls	Patients	p-value
	Mean (\pmSD)	Mean (\pmSD)	
L1	21.8 (2.5)	19.7 (2.3)	<0.001*
L2	21.9 (2.5)	19.7 (3.5)	<0.001*
L3	22.4 (3.0)	19.2 (3.5)	<0.001*
L4	20.2 (2.9)	17.3 (3.3)	<0.001*
L5	19.6 (2.9)	16.0 (2.8)	<0.001*
S1	12.9 (7.8)	16.1 (2.7)	<0.001*

* Asterisk denoted statistical significance.

Table 3: Measurement comparisons between control subjects and patients

Measurement	Controls	Patients	p-value
	Mean mm (\pm SD), except for angle [#] ($^{\circ}$)	Mean mm (\pm SD), except for lamina angle [#] ($^{\circ}$)	
Axial AP⁺ vertebral body diameter			
L1	28.6 (2.6)	28.5 (3.7)	0.899
L2	30.1 (2.9)	30.3 (3.5)	0.701
L3	31.7 (2.8)	31.8 (3.2)	0.803
L4	31.8 (3)	31.9 (3.2)	0.958
L5	32.5 (3.1)	32.4 (3.6)	0.808
S1	24.3 (14.5)	33 (3.6)	<0.001*
Axial vertebral body width			
L1	37.5 (3.2)	37.7 (4)	0.749
L2	38.4 (3.7)	37.8 (4)	0.385
L3	38.8 (3.9)	39.5 (4.4)	0.268
L4	41.5 (3.9)	41.5 (4)	0.973
L5	44.7 (4.8)	47.1 (5.4)	0.001*
S1	26 (27.5)	52.3 (4.9)	<0.001*
Axial Spinal Canal AP⁺ diameter			
L1	21.8 (2.5)	19.7 (2.3)	<0.001*
L2	21.9 (2.5)	19.7 (3.5)	<0.001*
L3	22.4 (3)	19.2 (3.5)	<0.001*
L4	20.2 (2.9)	17.3 (3.3)	<0.001*
L5	19.6 (2.9)	16 (2.8)	<0.001*

S1	12.9 (7.8)	16.1 (2.7)	<0.001*
-----------	------------	------------	---------

Axial Dural Sac AP⁺ diameter
--

L1	16 (1.8)	14.8 (1.7)	0.004*
L2	15.4 (1.9)	13.8 (2.5)	<0.001*
L3	15 (2.1)	12.6 (1.9)	<0.001*
L4	13.6 (2.1)	11.3 (2)	<0.001*
L5	13.4 (2.6)	11 (2.4)	<0.001*
S1	8.3 (5.5)	10.3 (3.5)	0.004*

Axial interpedicular distance

L1	22.5 (1.9)	23.5 (2.3)	0.026*
L2	22.8 (1.9)	23.1 (1.7)	0.339
L3	24 (1.9)	24.2 (1.8)	0.298
L4	25.3 (2.2)	25.3 (2.1)	0.974
L5	30 (2.8)	30.7 (3.2)	0.043*
S1	25.2 (14.8)	33.3 (2.3)	<0.001*

Axial right pedicle width

L1	6.1 (1.4)	5.2 (1.6)	0.005*
L2	6.1 (1.5)	5.9 (1.4)	0.408
L3	7.8 (2)	7.3 (1.7)	0.093
L4	9.7 (2.1)	9.1 (1.9)	0.033*
L5	14.2 (2.6)	13.2 (2.4)	0.005*
S1	13.3 (8.9)	18.4 (3.1)	<0.001*

Axial left pedicle width

L1	6.4 (1.7)	5.6 (1.5)	0.038*
-----------	-----------	-----------	--------

L2	6.4 (1.6)	6.3 (1.5)	0.718
L3	7.6 (1.9)	7.7 (1.8)	0.584
L4	9.7 (2.3)	9.7 (1.9)	0.835
L5	13.3 (2.7)	13.3 (2.8)	0.962
S1	13.3 (8.9)	18.5 (3.3)	<0.001*

Axial lamina angle[#]

L1	120.6 (8.5)	119.5 (7.2)	0.523
L2	120.5 (8.8)	121.7 (11.5)	0.489
L3	118.4 (8.7)	121.2 (9.5)	0.031*
L4	111 (10.1)	110.6 (8.6)	0.757
L5	94.6 (27.9)	98 (9.5)	0.259

Sagittal Vertebral Body Width

L1	28.7 (2.8)	26.9 (3.1)	<0.001*
L2	30.3 (3.1)	28 (3.5)	<0.001*
L3	32 (3.3)	29.6 (3.6)	<0.001*
L4	32 (3)	30.3 (2.9)	<0.001*
L5	31.2 (3.5)	29.8 (2.9)	0.003*
S1	23.5 (4)	22.2 (3)	0.010*

Sagittal Vertebral Body Height
--

L1	24.4 (2.1)	22.3 (2.2)	<0.001*
L2	25.1 (1.7)	23 (1.9)	<0.001*
L3	25 (1.8)	22.7 (1.8)	<0.001*
L4	24.4 (1.9)	22 (2.2)	<0.001*
L5	23.9 (1.8)	21.5 (1.9)	<0.001*
S1	25.8 (2.7)	24.3 (2.4)	<0.001*

Sagittal Spinal Canal Width			
L1	15.5 (1.5)	15.3 (1.7)	0.338
L2	14.5 (1.4)	14.7 (1.8)	0.468
L3	13.7 (1.6)	13.8 (2.1)	0.888
L4	13.8 (2)	13.7 (2)	0.578
L5	14.1 (2.1)	14.2 (2.9)	0.727
S1	12.5 (3.2)	12 (2.5)	0.204

* Asterisk denoted statistical significance.

†: Anteroposterior.

#: Lamina angle was measured with an angle from the base of the spinous process to the pedicles.

Table 4: Receiver operating characteristic (ROC) analysis for anteroposterior bony spinal canal diameter

	Area Under the Curve (AUC)	p-value	95% CI[†]
L1	0.66	0.028*	0.518-0.803
L2	0.66	0.030*	0.523-0.794
L3	0.81	<0.001*	0.712-0.916
L4	0.84	<0.001*	0.725-0.946
L5	0.82	<0.001*	0.715-0.933
S1	0.55	0.523	0.399-0.694

[†]: A 95% confidence interval (CI) value below the value 1 indicates statistical significance.

* Asterisk denotes statistical significance.

Table 5: Receiver operating characteristic (ROC) analysis of critical stenosis and developmental stenosis for anteroposterior bony spinal canal diameter

	Critical Stenosis⁺	Sensitivity	Specificity
L4	14mm	100%	80%
L5	14mm	98.7%	85%
S1	12mm	97.3%	90%
	Developmental Stenosis*	Sensitivity	Specificity
L1	20mm	50%	76%
L2	19mm	30%	93.3%
L3	19mm	55%	93.3%
L4	17mm	65%	92%
L5	16mm	45%	92%
S1	16mm	50%	68%

⁺: Critical (absolute) stenosis acts as the cut-off value for the axial bony spinal canal anteroposterior diameter; thereby, any subject with a narrow canal diameter regarded as having critical stenosis would most likely require surgery for spinal stenosis.

*: Developmental (relative) stenosis was based on the cut-off value of the anteroposterior bony spinal canal diameter for patients that would include approximately 50% of the controls, with best sensitivity and specificity for identifying this subject group. These values indicate which subjects are likely to develop spinal stenosis symptoms requiring surgery.

Figure Legends

Figure 1: Sagittal radiograph of a patient with spinal stenosis showing generalized short pedicles, which are decreasing in trend from cranially to caudally.

Figure 2: Axial MRI measurements: (A) midline AP vertebral body diameter; (B) mid-vertebral body width; (C): midline AP spinal canal diameter; (D): AP dural sac diameter; (E) spinal canal width/interpedicular distance; and (G): pedicle width (right and left).

Figure 3: Axial MRI measurement of the lamina angle (angle made from two lines crossing from the base of the spinous process along the lamina to the base of the pedicles).

Figure 4: Sagittal MRI measurements: (H) midline AP body diameter; (I) mid-vertebral body height; and (J) AP spinal canal diameter (from the most prominent tip of the spinous process, taking a perpendicular line to the vertebral body).

Figure 5: Bar graph showing patients (red bar) have narrower AP spinal canal diameters than controls (blue bar) at all levels (L1-S1), which was statistically significant.

Figure 2
[Click here to download high resolution image](#)

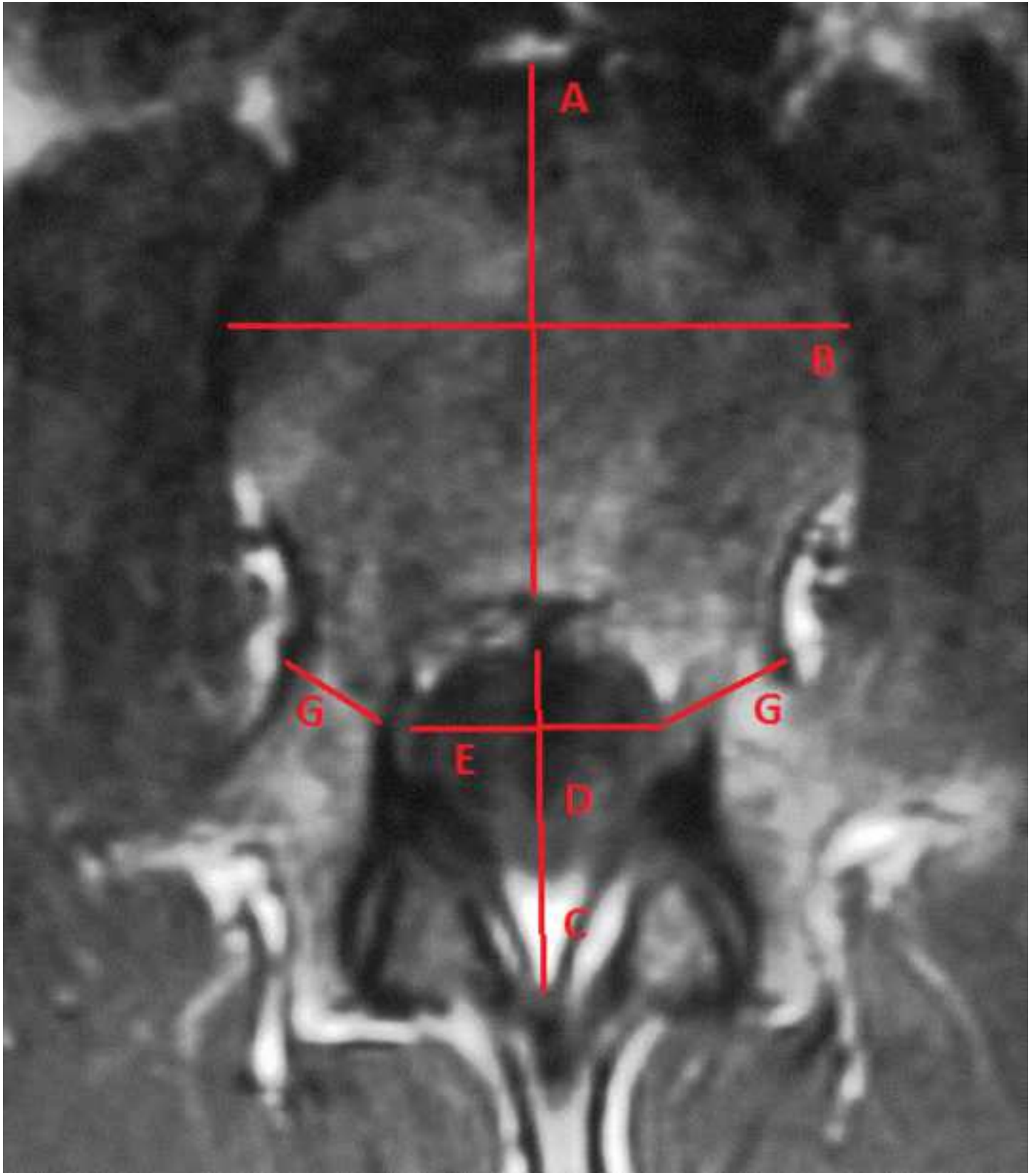

Figure 3
[Click here to download high resolution image](#)

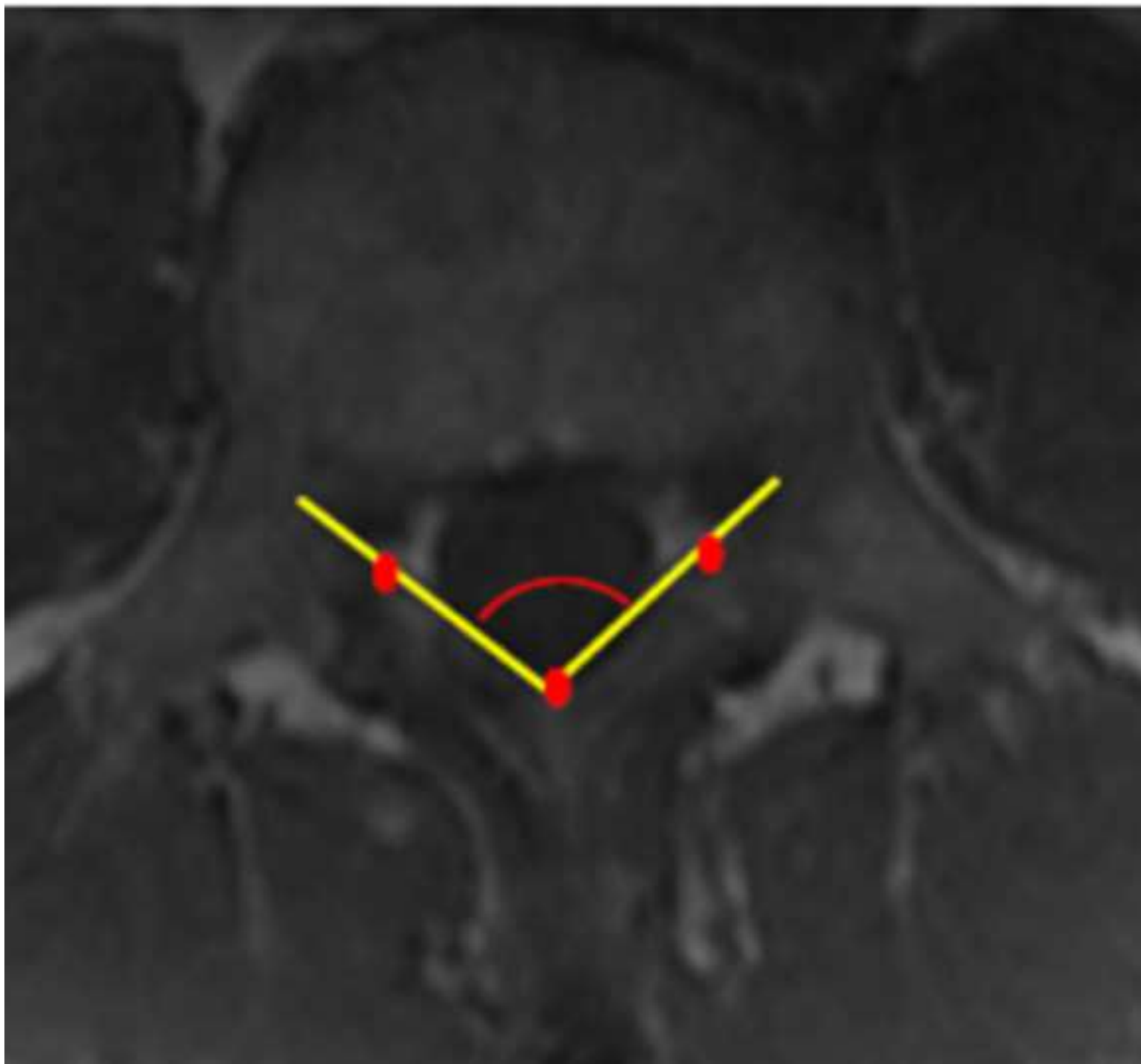


Figure 4
[Click here to download high resolution image](#)




Figure 1

[Click here to download high resolution image](#)

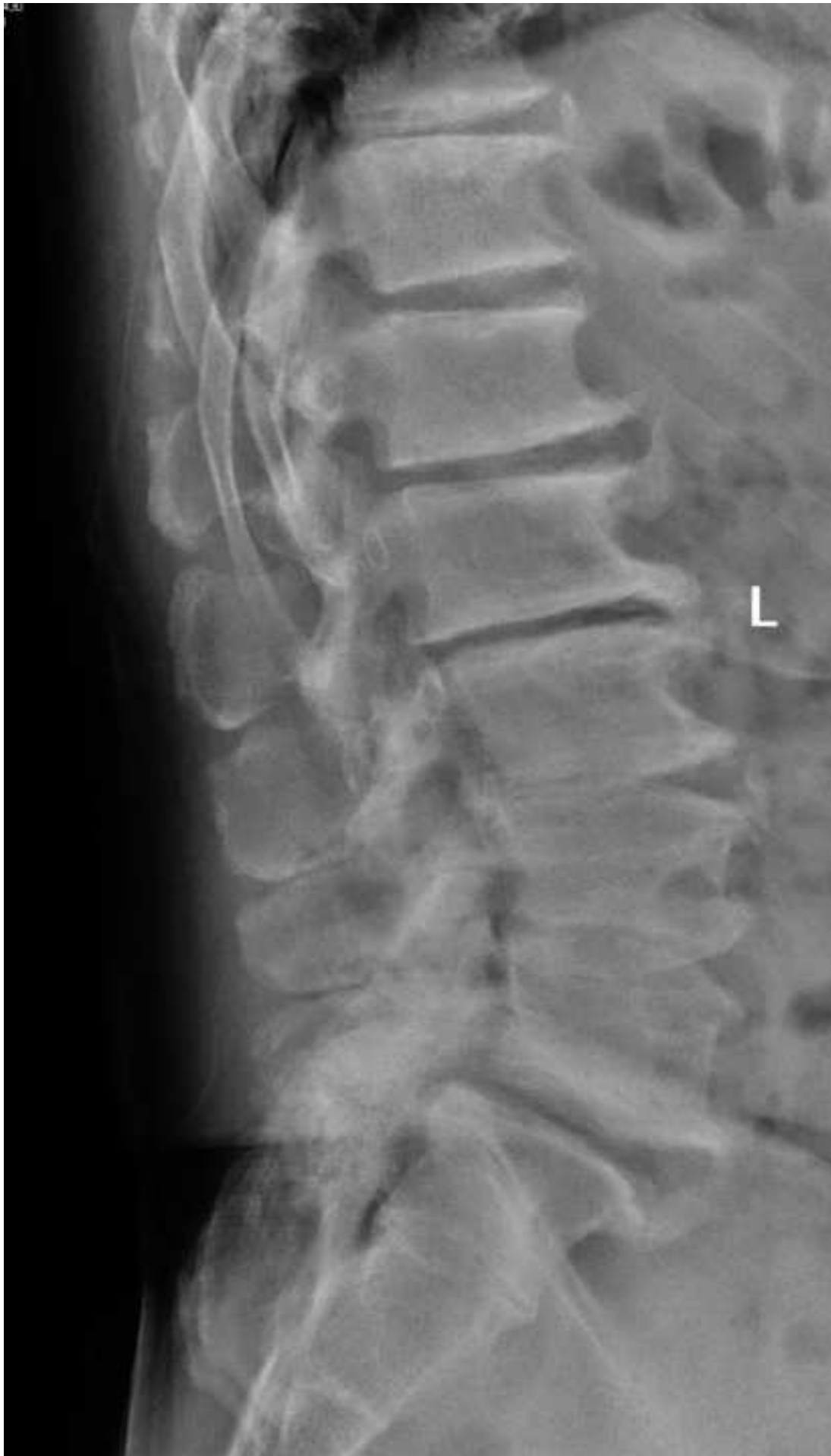

Figure 5
[Click here to download high resolution image](#)

AP Spinal Canal Diameter

* $p < 0.001$

