



<b>Title</b>	<b>Primary endovascular treatment of post-irradiated carotid pseudoaneurysm at the skull base with the Pipeline embolization device</b>
<b>Author(s)</b>	<b>Tsang, ACO; Lui, WM; Leung, GKK</b>
<b>Citation</b>	<b>Journal of NeuroInterventional Surgery, 2015, v. 7 n. 8, p. 603-607</b>
<b>Issued Date</b>	<b>2015</b>
<b>URL</b>	<b><a href="http://hdl.handle.net/10722/198113">http://hdl.handle.net/10722/198113</a></b>
<b>Rights</b>	<b>Journal of NeuroInterventional Surgery. Copyright © BMJ Group.</b>

**Primary Endovascular Treatment of Post-irradiated Carotid Pseudoaneurysm at the skull base with Pipeline embolization device**

Journal:	<i>Journal of NeuroInterventional Surgery</i>
Manuscript ID:	neurintsurg-2014-011154.R1
Article Type:	Original research
Keywords:	Aneurysm, Complication, Flow Diverter, Hemorrhage, Vessel Wall

SCHOLARONE™  
Manuscripts

1  
2  
3 **Primary Endovascular Treatment of Post-irradiated Carotid Pseudoaneurysm at**  
4 **the skull base with Pipeline embolization device**  
5  
6  
7  
8  
9

10 **ABSTRACT**  
11  
12

13  
14 **BACKGROUND:** Post-irradiated carotid pseudoaneurysm at the skull base can cause life-  
15 threatening blowout syndrome. Conventional treatments include parent vessel occlusion,  
16 endovascular coiling or covered stenting. Use of the Pipeline Embolization Device (PED) for  
17 pseudoaneurysm exclusion at the skull base is not well described. We report the clinical and  
18 angiographic outcome using multiple PED to treat recently ruptured radiation-induced carotid  
19 pseudoaneurysms at the skull base.  
20  
21  
22  
23  
24  
25

26  
27 **METHODS:** Retrospective review of the clinical and angiographic records of patients who  
28 received PED as primary treatment for skull base carotid pseudoaneurysm from 1<sup>st</sup> April 2011 to  
29 31<sup>st</sup> March 2013.  
30  
31  
32  
33

34 **RESULTS:** 7 patients were treated in the study period including five men and two women, with  
35 a mean age of 58 years (range: 47 to 65). Primary treatment with the PED alone, with adjunct coil  
36 embolization in 2 patients, achieved immediate hemostasis in all patients, with no  
37 pseudoaneurysm rebleeding after a mean follow-up of 15.3 months (range 4-24 months). One  
38 patient suffered from peri-procedural cerebral infarction. Delayed ICA occlusion secondary to in-  
39 stent thrombosis occurred in 3 patients, 1 of which had lacunar infarct and 2 remained  
40 asymptomatic.  
41  
42  
43  
44  
45  
46  
47

48 **CONCLUSION:** Endovascular treatment with the PED was effective in excluding skull base  
49 post-irradiated carotid pseudoaneurysms and preventing recurrent blowout. However the risk of  
50 ischemic complications in this group of patients was high and our experience did not support the  
51 use of flow diverters as a first line treatment for this condition.  
52  
53  
54  
55  
56  
57  
58  
59  
60

1  
2  
3 **RUNNING TITLE:** Flow diverter for radiation-induced ICA aneurysms at the skull base  
4  
5

6  
7 **KEYWORDS:** Carotid pseudoaneurysm, Radiotherapy, Endovascular procedures  
8  
9

10  
11 **ABBREVIATIONS:**  
12

13  
14  
15 CBS, carotid blowout syndrome  
16  
17

18  
19 CT, computer tomography  
20  
21

22  
23 DSA, digital subtraction angiography  
24  
25

26  
27 ICA, internal carotid artery  
28  
29

30  
31 PVO, parent artery occlusion (PVO)  
32  
33

34  
35 PED, pipeline embolization device  
36  
37  
38  
39  
40  
41  
42  
43  
44  
45  
46  
47  
48  
49  
50  
51  
52  
53  
54  
55  
56  
57  
58  
59  
60



## INTRODUCTION

Radiotherapy is an effective treatment for head and neck cancers but it may also cause long-term damages to the carotid arteries, resulting in arterial stenosis, occlusion or the formation of pseudoaneurysms.(1) Post-irradiated carotid pseudoaneurysms after radiotherapy for nasopharyngeal cancer typically occur at the petrous and laceral carotid artery, and may present with life-threatening epistaxis due to carotid blowout syndrome (CBS).(2) Recognized treatments for these lesions include parent artery occlusion (PVO) with or without revascularization, endovascular coil embolization, and covered stenting.(3, 4) The introduction of endovascular flow-diverters provides another potential treatment option. The pipeline embolization device (PED) is one of these flow-diverters with 30-35% surface coverage, designed to achieve curative reconstruction of intracranial arteries that harbor aneurysms with challenging morphologies.(5, 6) Outcome in the treatment of non-ruptured intracranial aneurysms was satisfactory.(7-10) However, its efficacy for ruptured pseudoaneurysm, in particular that with an extradural location at the skull base is unclear. We present our experience with the PED in the treatment of patients with ruptured post-irradiated ICA pseudoaneurysms at the skull base.

## PATIENTS AND METHODS

### Patients

This is a retrospective study of prospectively collected data of all-inclusive patients treated with the PED for radiation-induced extracranial ICA pseudoaneurysms at our institution from April 2011 to March 2013. All patients had history of nasopharyngeal carcinoma primarily treated with prior external radiotherapy involving the skull base, and had developed ICA pseudoaneurysms within the irradiated fields at the skull base. All presented with severe epistaxis due to aneurysm rupture. Initial hemostasis was achieved by means of nasal packing, followed by diagnostic digital subtraction angiography (DSA) and PED reconstruction on an emergency basis within 24 hours.

## Procedure and Follow-up

Immediately before PED placement, patients were given 300mg of clopidogrel and 300 mg of aspirin. Clopidogrel (75mg daily) was maintained for at least one week and aspirin (80mg daily) was given for six months after surgery. Low molecular weight heparin was given at 1mg/kg every 12 hours and was maintained for 24 hours after surgery. Intravenous prophylactic antibiotics (amoxicillin-clavulanate 1.2g and metronidazole 500mg) were given on induction of general anesthesia, and maintained for one week post-operatively.

The PED (ev3 Inc, Plymouth, MN, USA) was deployed in the standard manner using transfemoral arterial approach. Additional PEDs were placed telescopically with the overlapping segment covering the entire aneurysm neck for double coverage if there was inadequate contrast stasis in the aneurysm sac. (Figure 3b) Coils were deployed prior to placement of PED when there was ongoing contrast extravasation or the aneurysm sac was large to facilitate hemostasis and thrombosis of pseudoaneurysm. (Figure 2b) A check DSA was performed to ensure that the entire aneurysm neck was covered, and to exclude acute in-stent thrombosis, distal embolism and contrast extravasation through the aneurysm.

## Outcome assessment

We assessed the efficacy of immediate and mid-term hemostasis, and the occurrence of periprocedural complications including ischemic and hemorrhagic neurological events. Follow-up DSA or computer tomography (CT) angiograms were performed to assess aneurysm obliteration, delayed in-stent stenosis and device migration. Patients' neurologic outcomes were assessed using the modified Rankin's Score.

## RESULTS

### Patient characteristics

1  
2  
3  
4  
5 There were seven patients, including five men and two women, with a mean age of 58 years  
6 (range: 47-65). Their clinical features, aneurysm characteristics, and treatment outcomes were  
7 summarized in Table 1. Four patients' primary malignant diseases were in remission; three  
8 suffered from recurrent cancers at the time of presentation. The pseudoaneurysms occurred in the  
9 petrous and laceral portions of the ICA in five and two patients, respectively. The median  
10 aneurysm size was 2.3mm (range: 1.2-12.2mm) All except two patients presented without a prior  
11 diagnosis of ICA pseudoaneurysm. *Patient 1* had reconstitution of pseudoaneurysm one year  
12 after covered stent placement. *Patient 2* had undergone treatment for a left-sided pseudoaneurysm  
13 at another center 3 months prior to presenting to us with a ruptured right-sided lesion.  
14  
15  
16  
17  
18  
19  
20  
21  
22  
23  
24  
25  
26  
27  
28  
29  
30  
31  
32  
33  
34  
35  
36  
37  
38  
39  
40  
41  
42  
43  
44  
45  
46  
47  
48  
49  
50  
51  
52  
53  
54  
55  
56  
57  
58  
59  
60

**Table 1. Demographic data, pseudoaneurysm characteristics, treatment and outcome in the patient series.**

Patient	Age	Aneurysm location	No. of PED (size)	Aneurysm size (max. diameter x dome height)	Adjuvant coils	Complications	Angiogram findings(months post-operation)	Follow up (months)	Outcome at last follow up
1	40s	Right petrous ICA	1 (4.5x20mm)	1.2x0.9mm	-	-	CTA (7): Patent ICA, obliterated aneurysm	18	Died of brainstem hemorrhage
2	50s	Right petrous ICA	2 (4x20, 3.75x20mm)	2.2 x 1.3mm	-	Multiple cerebral infarctions	Not done	11	Died of tumor progression
3	50s	Left laceral ICA	2 (5x20mm)	2.5x1.6mm	-	-	CTA (1): Patent ICA, obliterated aneurysm CTA (8): occluded ICA	24	mRS 1
4	60s	Right petrous ICA	2 (4.25x20,4x20mm)	1.8x6.0mm	GDC coils	-	Not done	4	Died of metastatic breast cancer
5	60s	Left petrous ICA	2 (4.5x30, 3.75x20mm)	12.2x6.6mm	Matrix coils	-	DSA (8): Patent ICA obliterated aneurysm	14	Died of pneumonia
6	60s	Right petrous ICA	2 (5x35,4.5x20mm)	3.3x1.7mm	-	Delayed ICA thrombosis and lacunar infarct at 10 months	CTA (3): Patent ICA, obliterated aneurysm DSA (10): occluded ICA	14	Died of tumor progression
7	40s	Right laceral ICA	3 (4x20, 3.75x20, 4x30mm)	2.3x1.8mm	-	-	DSA (5): Right ICA occlusion	22	mRS 1

Abbreviations: CTA, CT angiogram; DSA, digital subtraction angiogram; GDC, Guglielmi detachable coil; ICA, internal carotid artery; mRS, modified Rankin scale; NPC, nasopharyngeal carcinoma;

### Procedural and clinical outcomes

Five patients received two PEDs each, one patient received one device, and another had three devices. Adjuvant coil embolization was used in two patients. The median operation time was 85 minutes (range: 50-236). The median hospital stay was 21 days (range: 4-90). (Table 1) There was no procedure-related mortality. Immediate hemostasis was achieved with DSA confirmed no filling of the pseudoaneurysm in all patients. None experienced recurrent pseudoaneurysm bleeding after a mean clinical follow-up period of 15.3 months (range 4-24 months).

The patient who had a contralateral pseudoaneurysm treated previously (*Patient 2*) suffered from ischemic cerebral infarctions after PED placement at our center. There was left ICA occlusion, presumably due to previous treatment at another center, as well as 70% right common carotid artery and 50% right proximal ICA stenosis. We performed right ICA angioplasty and stenting for the stenosis prior to PED placement. This patient developed multiple ischemic infarctions afterwards which were likely secondary to endovascular manipulations within a precarious circulation. (Figure 1) There was no other peri-procedural complication.

Follow-up angiographic studies were performed in five patients. *Patient 2* as described above declined further investigation, and died of progression of nasopharyngeal cancer 11 months after PED treatment. Another patient (*Patient 4*) developed pleural effusion secondary to lymphangitis carcinomatosa and carcinoma of the breast and died four months after PED placement. Of the remaining five patients with angiographic follow up, there were no reconstitutions of aneurysm. Two patients (*Patients 2 and 7*) had asymptomatic in-construct thrombosis at 5 and 7 months respectively. *Patient 6* had obliterated aneurysm and patent ICA on CT angiogram at 3 months and remained asymptomatic until at 10 months when a new lacunar infarction at ipsilateral internal capsule developed. There was good neurological recovery. Subsequent DSA showed occluded ipsilateral Right ICA. Their neurologic outcomes were listed in Table 1. Figure 2 and 3 illustrate two patients (*Patient 5 and 6*) who had complete aneurysm obliterations on initial follow up angiogram.

## DISCUSSION

The primary goal of treatment for radiation-induced ICA pseudoaneurysm is the prevention of life-threatening CBS. Since these aneurysms commonly occur at the extradural segments of the ICA located at the skull base, they are rarely amenable to surgical clipping. Endovascular intervention is currently the treatment of choice. PVO in patients with adequate collateral supplies, confirmed on balloon occlusion test (BTO), has been used by many authorities with satisfactory outcome.(11) However, a subgroup of these patients may still develop severe ischemic complications after PVO which indicates the advantage of preserving the native circulation.(12) PVO with extracranial-intracranial arterial bypass is another option but the procedure is technically demanding, and sometimes challenging for this group of often debilitated patients.(13) This cohort of patients typically received repeated radiotherapy for nasopharyngeal cancer and frequently there were bilateral radiation-induced carotid stenosis putting the cerebral circulation at risk. We did not perform routine BTO as we aim to preserve of parent artery with endovascular treatments whenever possible.

Established endovascular therapies for pseudoaneurysm while preserving parent artery include coil embolization and covered-stent exclusion. Coil embolization, for example, can achieve hemostasis effectively.(4) However, the morphology of some of these lesions (e.g., wide-based or blister-like pseudoaneurysm) may not be suitable for coiling, as were the case in five of our patients. Moreover, these pseudoaneurysms lack a true wall histologically and are commonly surrounded by radionecrotic bone, coil extrusion and rebleeding may occur.(14, 15) Our center had previously reported the use of self-expandable covered stent-graft in such patients, which has the advantage of achieving immediate reconstruction of the vessel wall.(15) The initial angiographic outcomes were satisfactory but the presence of tumorous or infected tissues may result in delayed complications such as in-stent thrombosis and infections.(15-17) Chang et al treated 11 patients with CBS using stent-grafts. Immediate hemostasis was achieved in all patients but five subsequently suffered from rebleeding.(2) Since 2011, we elect to use flow diverter because of its high metal surface coverage, better maneuverability compared with covered-stents, and because self-expanding covered-stents are no longer available at our locality.

1  
2  
3 Flow diverters had proven to be an effective treatment for unruptured intracranial aneurysms.(5-  
4 9, 18-21) A recent meta-analysis including 1654 intracranial aneurysms found a complete  
5 occlusion rate of 76% at 6-months. (22) The PED is known to reduce blood flow within an  
6 aneurysm sac to the point of stagnation and thrombosis, and can facilitate neointimal remodeling  
7 of the parent artery. Use of the PED for carotid pseudoaneurysm intracranially as well as at the  
8 skull base had been reported with mixed results. (23-28) Amenta et al. reported a successful PED  
9 treatment for traumatic carotid pseudoaneurysm with a follow up of 4 months.(26) Nerva et al.  
10 reported 2 patients with iatrogenic carotid pseudoaneurysm at the cavernous segment after  
11 endoscopic transsphenoidal surgery treated with PED and achieved complete aneurysm occlusion.  
12 (27) However, early rebleeding after PED treatment in pseudoaneurysms could occur.(24, 28)  
13 Our results provide further information on applying PED for post-irradiated carotid  
14 pseudoaneurysms located at the skull base. For the 7 patients we treated, all achieved the primary  
15 goal of hemostasis and pseudoaneurysm exclusion.  
16  
17  
18  
19  
20  
21  
22  
23  
24  
25  
26  
27

28 A single PED has 30 to 35% surface area coverage. To secure the pseudoaneurysm and prevent  
29 re-rupture, we deliberately used multiple PEDs in 6 of the patients with telescopic placement in  
30 an attempt to increase coverage over the aneurysm neck. We also used adjuvant coiling when  
31 there was ongoing contrast extravasation or when the aneurysm sac was large. This was  
32 necessary in two of our seven patients. This approach was similar to the successful experience by  
33 Amenta et al., and Nerva et al., which may suggest the efficacy of multiple flow-diverters in  
34 achieving a covered-stent effect to exclude the pseudoaneurysm.(26, 27) Although none of our  
35 patients suffered from recurrent hemorrhages after a mean follow-up of over 15 months, the  
36 importance of long-term follow-up cannot be over-emphasized. It is also important to emphasize  
37 the need for obtaining temporary control of the epistaxis by means of surgical packing prior to  
38 PED placement; the latter performed in the presence of active CBS is neither safe nor feasible.  
39  
40  
41  
42  
43  
44  
45  
46  
47  
48

49 Use of the PED in the context of a recently ruptured intracranial aneurysm causing subarachnoid  
50 haemorrhage has also been reported but remains controversial.(29-34) The PED does not always  
51 result in an immediate and complete cessation of intrasaccular blood flow. This may lead to  
52 rebleeding especially where there is no coil to protect the aneurysm dome. MaAulliffé et al  
53 treated 11 patients with recently ruptured intracranial aneurysms. Two patients suffered from  
54  
55  
56  
57  
58  
59  
60



1  
2  
3 rebleeding and the author cautioned against this application.(33) Another concern is the need for  
4 dual antiplatelet agents after PED placement, complicating the risk of rebleeding and  
5 hydrocephalus management.  
6  
7

8  
9  
10 Despite the reasonable results for preventing rebleeding, our patients demonstrated a higher rate  
11 of ischemic complications than generally reported for the PED. *Patient 2* had an occluded left  
12 carotid artery and multifocal stenosis of the right carotid artery due to previous radiation. In order  
13 to secure the pseudoaneurysm, we had to perform angioplasty and negotiate through the proximal  
14 stenosed carotid artery before deploying the PED. He suffered from peri-procedural infarct. In  
15 addition, 3 patients developed delayed stent thrombosis, of which 1 was symptomatic.  
16 Symptomatic infarctions secondary to delayed in-stent thrombosis similar to *Patient 6* have been  
17 reported.(6, 35). *Patient 6* was put on double anti-platelet agents since PED placement,  
18 clopidogrel was stopped 2 weeks later and aspirin maintained for 6 months. This patient  
19 remained asymptomatic for 4 months after cessation of all anti-platelet therapy, and only  
20 developed lacunar infarct with in-construct thrombosis at 10 months after initial PED placement.  
21  
22  
23  
24  
25  
26  
27  
28  
29  
30

31 We surmise this worrisome rate of ischemic complications may be due to the inadequate  
32 antiplatelet regimen we used in this particular group of patients, compounded with delayed  
33 endothelialization of irradiated parent arteries as well as use of multiple PEDs. The optimal  
34 duration for antiplatelet treatment after flow diverters is unclear. For elective treatment of  
35 unruptured aneurysms, we routinely prescribe double antiplatelet agents for at least 3 months  
36 followed by aspirin for 6 months in total. However, in the present study, the patients were  
37 constantly at risk of life-threatening bleeding from the pseudoaneurysm, the osteonecrotic  
38 nasopharynx or recurrent nasopharyngeal tumor. We therefore were much more prudent with  
39 antiplatelet agents and only used double antiplatelet agents for the initial 1-4 weeks followed by  
40 aspirin alone subsequently. Although we did not encounter hemorrhagic complications, this over-  
41 cautious antiplatelet regimen led to a high ischemic risk. The high delayed in-stent thrombosis  
42 rate demonstrated in our series highlighted the importance of adequate antiplatelet treatment. In  
43 light of the significant ischemic risk, long term or even life-long antiplatelet agents may be  
44 indicated after PED placement, in particular in irradiated arteries, although the hemorrhagic risk  
45 remains a concern.  
46  
47  
48  
49  
50  
51  
52  
53  
54  
55  
56  
57  
58  
59  
60



## CONCLUSION

Radiation-induced ICA pseudoaneurysms at the skull base are challenging conditions for which endovascular intervention is currently the treatment of choice. The present study indicates that the PED as a primary emergency treatment was effective in excluding recently ruptured pseudoaneurysm and preventing rebleeding. However, there was a significant risk of ischemic complications in this group of patients with irradiated arteries. Adequate antiplatelet agents were mandatory although hemorrhagic risk remain a concern. Our results did not support the use of flow diverters as a first line treatment for this condition over coil embolization or covered stent, and it should be used with discretion.

## REFERENCES

1. Murros KE, Toole JF. The effect of radiation on carotid arteries. A review article. *Arch Neurol.* 1989;46(4):449-55. Epub 1989/04/01.
2. Chang FC, Lirng JF, Luo CB, Wang SJ, Wu HM, Guo WY, et al. Patients with head and neck cancers and associated postirradiated carotid blowout syndrome: endovascular therapeutic methods and outcomes. *J Vasc Surg.* 2008;47(5):936-45. Epub 2008/03/11.
3. Ellens DJ, Hurley MC, Surdel D, Shaibani A, Pelzer H, Bendok BR. Radiotherapy-induced common carotid pseudoaneurysm presenting with initially occult upper airway hemorrhage and successfully treated by endovascular stent graft. *Am J Otolaryngol.* 2010;31(3):195-8. Epub 2009/12/18.
4. Cheng KM, Chan CM, Cheung YL, Chiu HM, Tang KW, Law CK. Endovascular treatment of radiation-induced petrous internal carotid artery aneurysm presenting with acute haemorrhage. A report of two cases. *Acta Neurochir (Wien).* 2001;143(4):351-5; discussion 5-6. Epub 2001/07/05.
5. Lylyk P, Miranda C, Ceratto R, Ferrario A, Scivano E, Luna HR, et al. Curative endovascular reconstruction of cerebral aneurysms with the pipeline embolization device: the Buenos Aires experience. *Neurosurgery.* 2009;64(4):632-42; discussion 42-3; quiz N6. Epub 2009/04/08.
6. Szikora I, Berentei Z, Kulesar Z, Marosfoi M, Vajda ZS, Lee W, et al. Treatment of intracranial aneurysms by functional reconstruction of the parent artery: the Budapest experience with the pipeline embolization device. *AJNR Am J Neuroradiol.* 2010;31(6):1139-47. Epub 2010/02/13.

- 1  
2  
3 7. Deutschmann HA, Wehrsuetz M, Augustin M, Niederkorn K, Klein GE. Long-term  
4 follow-up after treatment of intracranial aneurysms with the Pipeline embolization device: results  
5 from a single center. *AJNR Am J Neuroradiol.* 2012;33(3):481-6. Epub 2011/12/14.
- 6  
7 8. de Barros Faria M, Castro RN, Lundquist J, Scrivano E, Ceratto R, Ferrario A, et al. The  
8 role of the pipeline embolization device for the treatment of dissecting intracranial aneurysms.  
9 *AJNR Am J Neuroradiol.* 2011;32(11):2192-5. Epub 2011/09/03.
- 10  
11 9. Becske T KD, Saatci I, McDougall CG, Szikora I, Lanzino G, Moran CJ, Woo HH, Lopes  
12 DK, Berez AL, Cher DJ, Siddiqui AH, Levy EI, Albuquerque FC, Fiorella DJ, Berentei Z,  
13 Marosfoi M, Cekirge SH, Nelson PK. Pipeline for uncoilable or failed aneurysms: results from a  
14 multicenter clinical trial. *Radiology.* 2013;267(3):858-68. doi: 10.1148/radiol.13120099. Epub  
15 2013 Feb 15.
- 16  
17 10. Yu SC, Kwok CK, Cheng PW, Chan KY, Lau SS, Lui WM, et al. Intracranial aneurysms:  
18 midterm outcome of pipeline embolization device--a prospective study in 143 patients with 178  
19 aneurysms. *Radiology.* 2012;265(3):893-901. Epub 2012/09/22.
- 20  
21 11. Wong GK, Poon WS, Chun Ho Yu S. Balloon test occlusion with hypotensive challenge  
22 for main trunk occlusion of internal carotid artery aneurysms and pseudoaneurysms. *Br J*  
23 *Neurosurg.* 2010;24(6):648-52. Epub 2010/07/17.
- 24  
25 12. Dare AO, Chaloupka JC, Putman CM, Fayad PB, Awad IA. Failure of the hypotensive  
26 provocative test during temporary balloon test occlusion of the internal carotid artery to predict  
27 delayed hemodynamic ischemia after therapeutic carotid occlusion. *Surg Neurol.* 1998;50(2):147-  
28 55; discussion 55-6. Epub 1998/08/13.
- 29  
30 13. Yasuda H, Kuroda S, Ushikoshi S, Kato T, Houkin K, Iwasaki Y, et al. Combined  
31 surgical and endovascular treatment of infected pseudoaneurysm after carotid endarterectomy.  
32 Case report. *Neurol Med Chir (Tokyo).* 2005;45(1):37-40. Epub 2005/02/09.
- 33  
34 14. Lin HW, Tierney HT, Richmon JD, Mark EJ, Deschler DG. Extrusion of embolization  
35 coils through the carotid artery in a radiated neck. *Auris Nasus Larynx.* 2010;37(3):390-3. Epub  
36 2009/08/28.
- 37  
38 15. Auyeung KM, Lui WM, Chow LC, Chan FL. Massive epistaxis related to petrous carotid  
39 artery pseudoaneurysm after radiation therapy: emergency treatment with covered stent in two  
40 cases. *AJNR Am J Neuroradiol.* 2003;24(7):1449-52. Epub 2003/08/15.
- 41  
42 16. Pyun HW, Lee DH, Yoo HM, Lee JH, Choi CG, Kim SJ, et al. Placement of covered  
43 stents for carotid blowout in patients with head and neck cancer: follow-up results after rescue  
44 treatments. *AJNR Am J Neuroradiol.* 2007;28(8):1594-8. Epub 2007/09/12.
- 45  
46 17. Simental A, Johnson JT, Horowitz M. Delayed complications of endovascular stenting for  
47 carotid blowout. *Am J Otolaryngol.* 2003;24(6):417-9. Epub 2003/11/11.
- 48  
49 18. Wong GK, Kwan MC, Ng RY, Yu SC, Poon WS. Flow diverters for treatment of  
50 intracranial aneurysms: current status and ongoing clinical trials. *J Clin Neurosci.*  
51 2011;18(6):737-40. Epub 2011/04/26.
- 52  
53 19. Lubicz B, Collignon L, Raphaeli G, De Witte O. Pipeline flow-diverter stent for  
54 endovascular treatment of intracranial aneurysms: preliminary experience in 20 patients with 27  
55 aneurysms. *World Neurosurg.* 2011;76(1-2):114-9. Epub 2011/08/16.
- 56  
57 20. Puffer RC, Kallmes DF, Cloft HJ, Lanzino G. Patency of the ophthalmic artery after flow  
58 diversion treatment of paraclinoid aneurysms. *J Neurosurg.* 2012;116(4):892-6. Epub  
59 2012/01/10.
- 60  
61 21. Colby GP, Lin LM, Gomez JF, Paul A, Huang J, Tamargo RJ, et al. 100 Immediate  
62 procedural outcomes in 35 consecutive pipeline embolization cases: a single-center, single-user  
63 experience. *Neurosurgery.* 2012;71(2):E543. Epub 2012/07/20.

- 1  
2  
3 22. Brinjikji W, Murad MH, Lanzino G, Cloft HJ, Kallmes DF. Endovascular treatment of  
4 intracranial aneurysms with flow diverters: a meta-analysis. *Stroke*. 2013;44(2):442-7. Epub  
5 2013/01/17.  
6  
7 23. Rahal JP, Dandamudi VS, Heller RS, Safain MG, Malek AM. Use of concentric Solitaire  
8 stent to anchor Pipeline flow diverter constructs in treatment of shallow cervical carotid  
9 dissecting pseudoaneurysms. *J Clin Neurosci*. 2013. Epub 2014/01/15.  
10 24. Kadkhodayan Y, Shetty VS, Blackburn SL, Reynolds MR, Cross DT, 3rd, Moran CJ.  
11 Pipeline embolization device and subsequent vessel sacrifice for treatment of a bleeding carotid  
12 pseudoaneurysm at the skull base: a case report. *J Neurointerv Surg*. 2013;5(5):e31. Epub  
13 2012/07/31.  
14  
15 25. Kim JD, Barber SM, Diaz OM, Li HK, Jackson RE, Hall D, et al. Post-traumatic  
16 amaurosis secondary to paraophthalmic internal carotid artery pseudoaneurysm treated with  
17 pipeline embolization device. *Journal of neuro-ophthalmology : the official journal of the North*  
18 *American Neuro-Ophthalmology Society*. 2013;33(4):359-62. Epub 2013/10/31.  
19 26. Amenta PS, Starke RM, Jabbour PM, Tjoumakaris SI, Gonzalez LF, Rosenwasser RH, et  
20 al. Successful treatment of a traumatic carotid pseudoaneurysm with the Pipeline stent: Case  
21 report and review of the literature. *Surgical neurology international*. 2012;3:160. Epub  
22 2013/02/02.  
23  
24 27. Nerva JD, Morton RP, Levitt MR, Osburn JW, Ferreira MJ, Ghodke BV, et al. Pipeline  
25 Embolization Device as primary treatment for blister aneurysms and iatrogenic pseudoaneurysms  
26 of the internal carotid artery. *J Neurointerv Surg*. 2014. Epub 2014/03/01.  
27 28. Wan WS, Lai V, Lau HY, Wong YC, Poon WL, Tan CB. Endovascular treatment  
28 paradigm of carotid blowout syndrome: Review of 8-years experience. *Eur J Radiol*. 2011. Epub  
29 2011/02/12.  
30  
31 29. Martin AR, Cruz JP, Matouk CC, Spears J, Marotta TR. The pipeline flow-diverting stent  
32 for exclusion of ruptured intracranial aneurysms with difficult morphologies. *Neurosurgery*.  
33 2012;70(1 Suppl Operative):21-8; discussion 8. Epub 2011/08/16.  
34 30. Narata AP, Yilmaz H, Schaller K, Lovblad KO, Pereira VM. Flow-diverting stent for  
35 ruptured intracranial dissecting aneurysm of vertebral artery. *Neurosurgery*. 2012;70(4):982-8;  
36 discussion 8-9. Epub 2011/09/23.  
37 31. McAuliffe W, Wycoco V, Rice H, Phatouros C, Singh TJ, Wenderoth J. Immediate and  
38 midterm results following treatment of unruptured intracranial aneurysms with the pipeline  
39 embolization device. *AJNR Am J Neuroradiol*. 2012;33(1):164-70. Epub 2011/10/08.  
40 32. Ducruet AF, Crowley RW, Albuquerque FC, McDougall CG. Reconstructive  
41 endovascular treatment of a ruptured vertebral artery dissecting aneurysm using the Pipeline  
42 embolization device. *J Neurointerv Surg*. 2013;5(4):e20. Epub 2012/06/22.  
43 33. McAuliffe W, Wenderoth JD. Immediate and Midterm Results Following Treatment of  
44 Recently Ruptured Intracranial Aneurysms with the Pipeline Embolization Device. *AJNR Am J*  
45 *Neuroradiol*. 2011. Epub 2011/12/03.  
46 34. Wong GK, Poon WS. Why current evidence is against flow diverters for treatment of  
47 carotid blowout syndrome. *Eur J Radiol*. 2013;82(1):191. Epub 2012/02/03.  
48 35. Fiorella D, Hsu D, Woo HH, Tarr RW, Nelson PK. Very late thrombosis of a pipeline  
49 embolization device construct: case report. *Neurosurgery*. 2010;67(3 Suppl Operative):onsE313-  
50 4; discussion onsE4. Epub 2010/08/04.  
51  
52  
53  
54  
55  
56  
57  
58  
59  
60

**FIGURE LEGENDS**

Fig. 1: *Patient 2.*

- (a) DSA shows a petrosal ICA pseudoaneurysm (white arrow) with stenosis in the proximal segment (black arrow);
- (b) After angioplasty with stenting of the stenotic segment and PED placement;
- (c) CT brain at day 1 post-operation shows multiple ischemic infarctions.

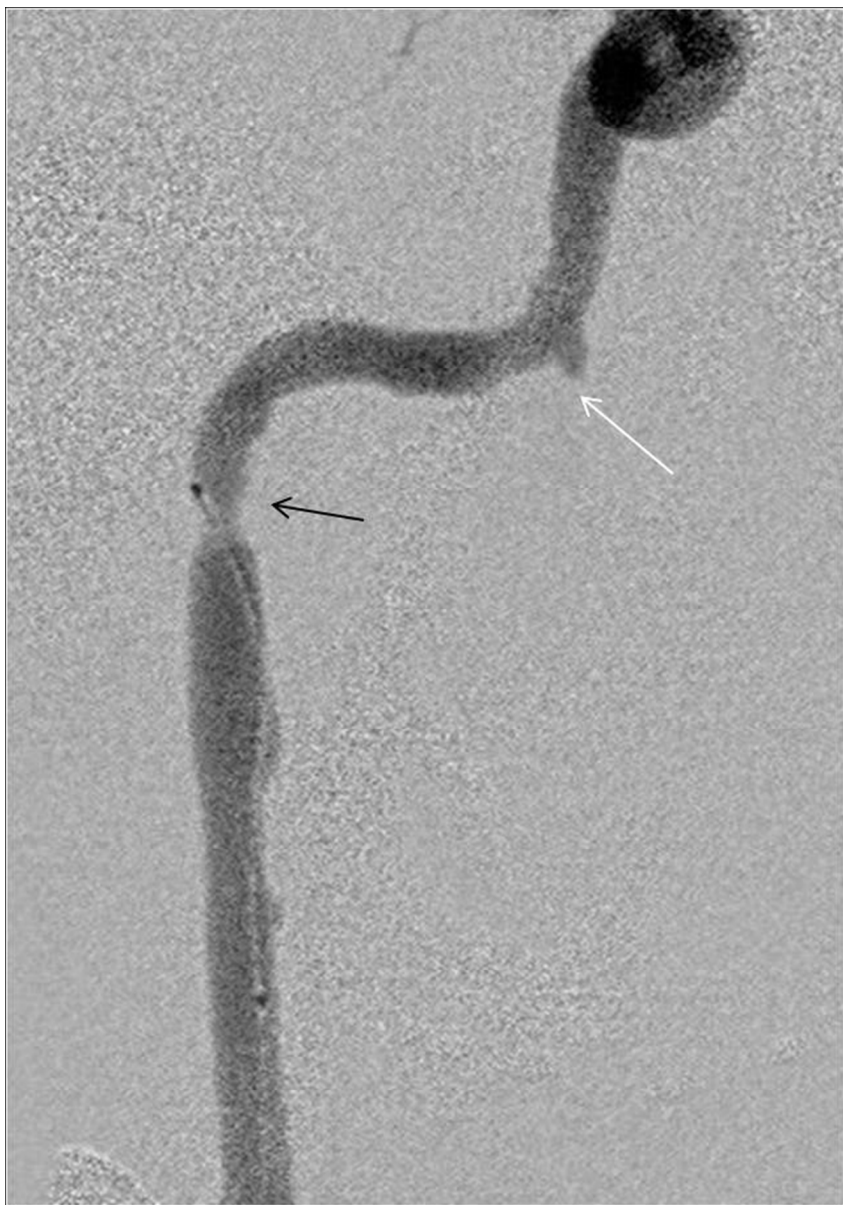
Fig. 2: *Patient 5 treated with the PED with adjuvant coiling.*

- (a) Diagnostic DSA shows an 8 x 14mm left petrous ICA pseudoaneurysm;
- (b) Obliteration of the pseudoaneurysm sac after placement of 2 PEDs and coil;
- (c) Follow-up DSA at 8-month shows the obliteration of the pseudoaneurysm and a patent parent artery.

Fig.3: *Patient 6*

- (a) DSA shows a pseudoaneurysm at the right petrous ICA;
- (b) Follow-up CTA at 3-month demonstrates telescoping of the PED and the obliteration of the pseudoaneurysm with a patent parent artery.

1  
2  
3  
4  
5  
6  
7  
8  
9  
10  
11  
12  
13  
14  
15  
16  
17  
18  
19  
20  
21  
22  
23  
24  
25  
26  
27  
28  
29  
30  
31  
32  
33  
34  
35  
36  
37  
38  
39  
40  
41  
42  
43  
44  
45  
46  
47  
48  
49  
50  
51  
52  
53  
54  
55  
56  
57  
58  
59  
60



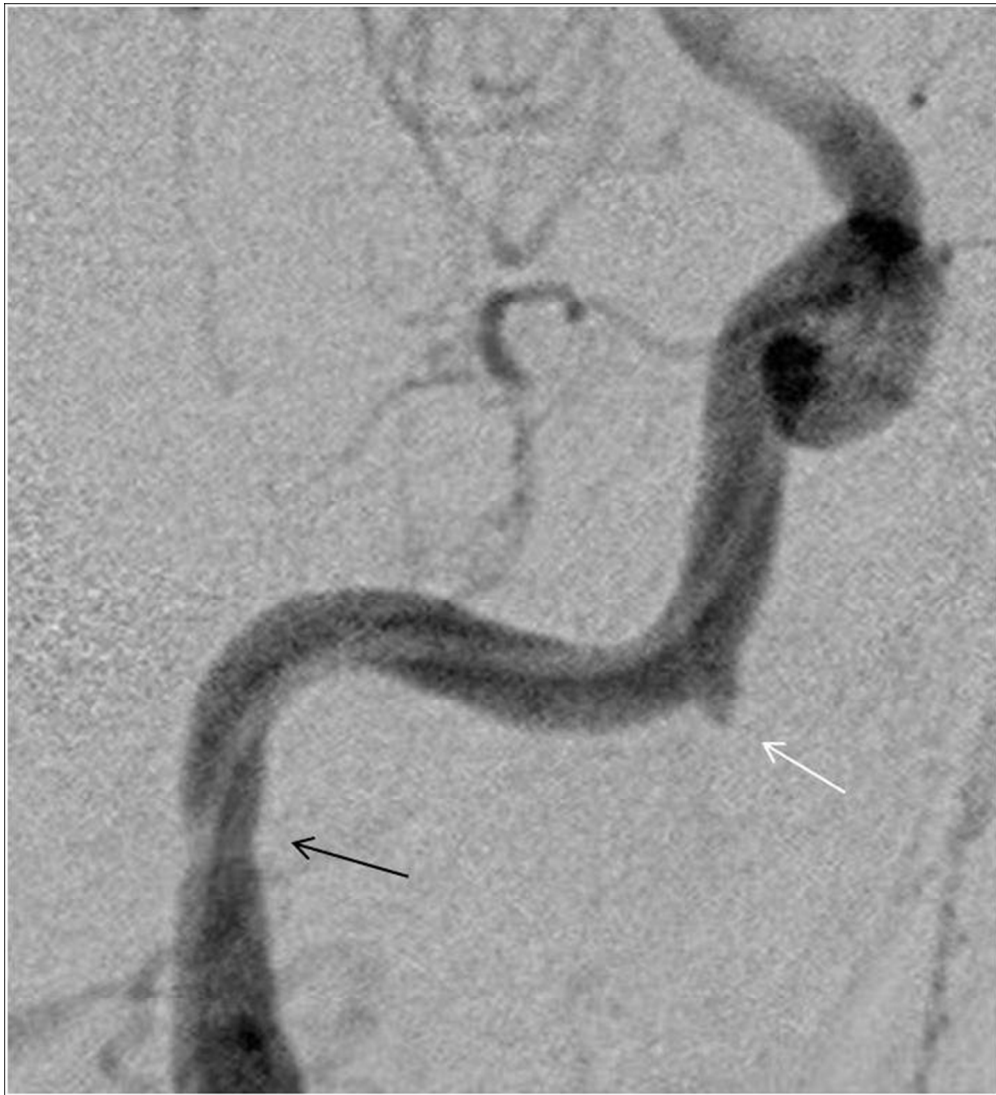Patient 2. DSA shows a petrosal ICA pseudoaneurysm (white arrow) with stenosis in the proximal segment (black arrow);

108x155mm (150 x 150 DPI)





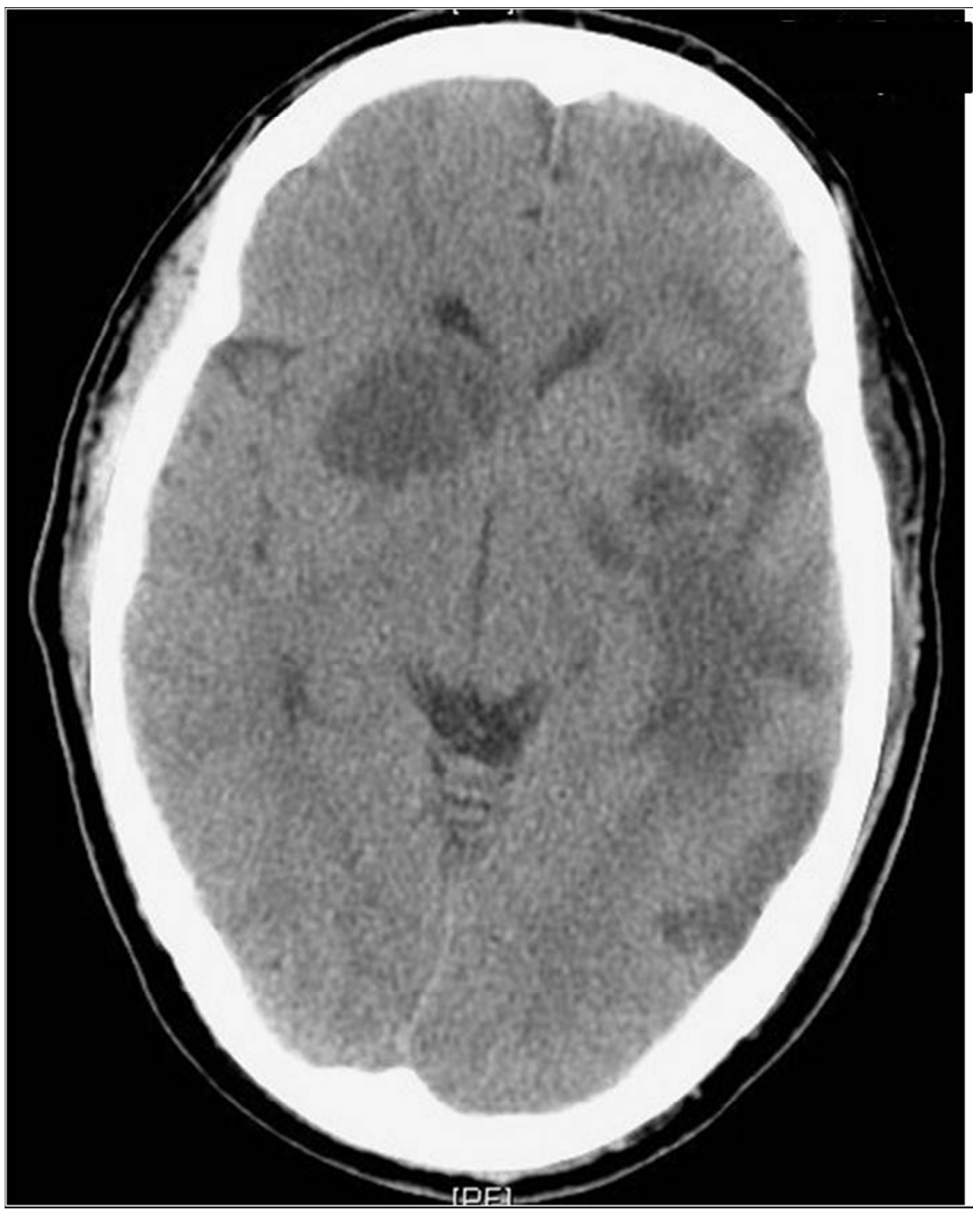1  
2  
3  
4  
5  
6  
7  
8  
9  
10  
11  
12  
13  
14  
15  
16  
17  
18  
19  
20  
21  
22  
23  
24  
25  
26  
27  
28  
29  
30  
31  
32  
33  
34  
35  
36  
37  
38  
39  
40  
41  
42  
43  
44  
45  
46  
47  
48  
49  
50  
51  
52  
53  
54  
55  
56  
57  
58  
59  
60



After angioplasty with stenting of the stenotic segment and PED placement  
119x130mm (150 x 150 DPI)

Only

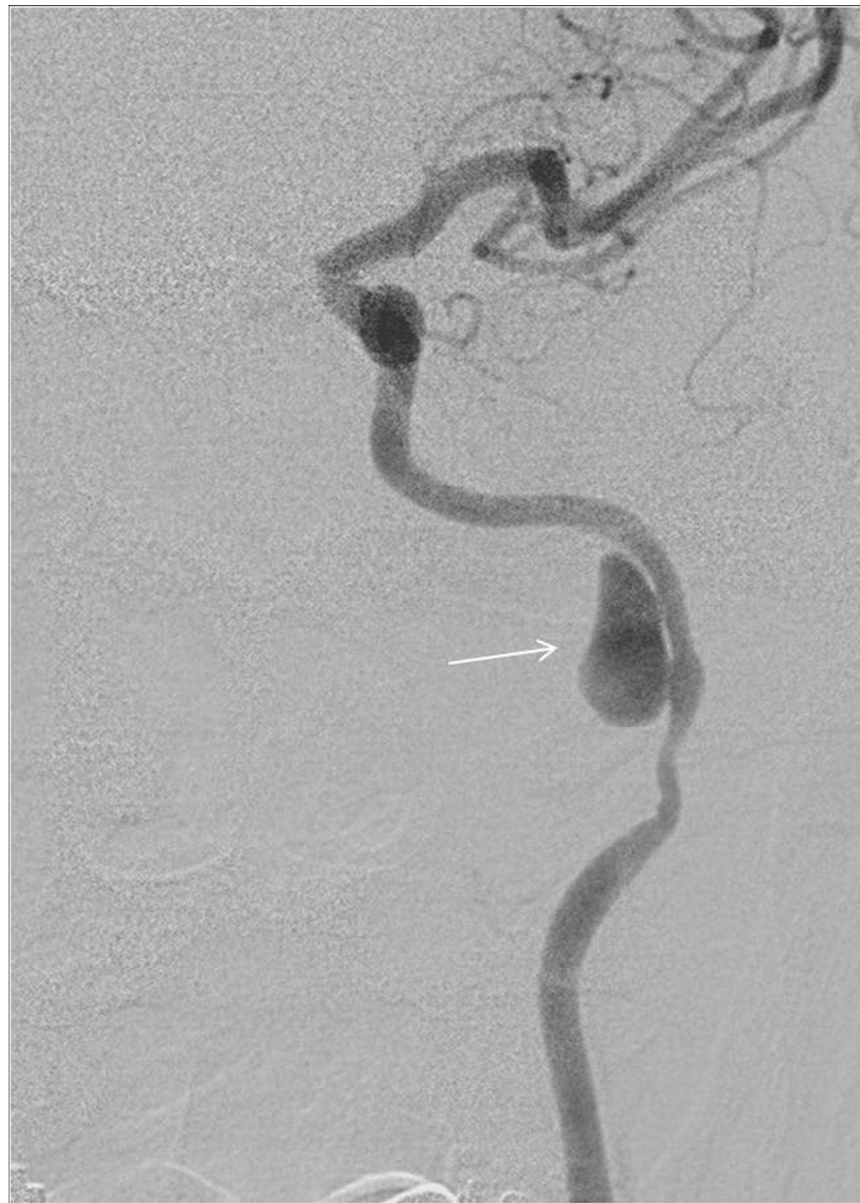1  
2  
3  
4  
5  
6  
7  
8  
9  
10  
11  
12  
13  
14  
15  
16  
17  
18  
19  
20  
21  
22  
23  
24  
25  
26  
27  
28  
29  
30  
31  
32  
33  
34  
35  
36  
37  
38  
39  
40  
41  
42  
43  
44  
45  
46  
47  
48  
49  
50  
51  
52  
53  
54  
55  
56  
57  
58  
59  
60



CT brain at day 1 post-operation shows multiple ischemic infarctions.  
121x149mm (150 x 150 DPI)

only

1  
2  
3  
4  
5  
6  
7  
8  
9  
10  
11  
12  
13  
14  
15  
16  
17  
18  
19  
20  
21  
22  
23  
24  
25  
26  
27  
28  
29  
30  
31  
32  
33  
34  
35  
36  
37  
38  
39  
40  
41  
42  
43  
44  
45  
46  
47  
48  
49  
50  
51  
52  
53  
54  
55  
56  
57  
58  
59  
60



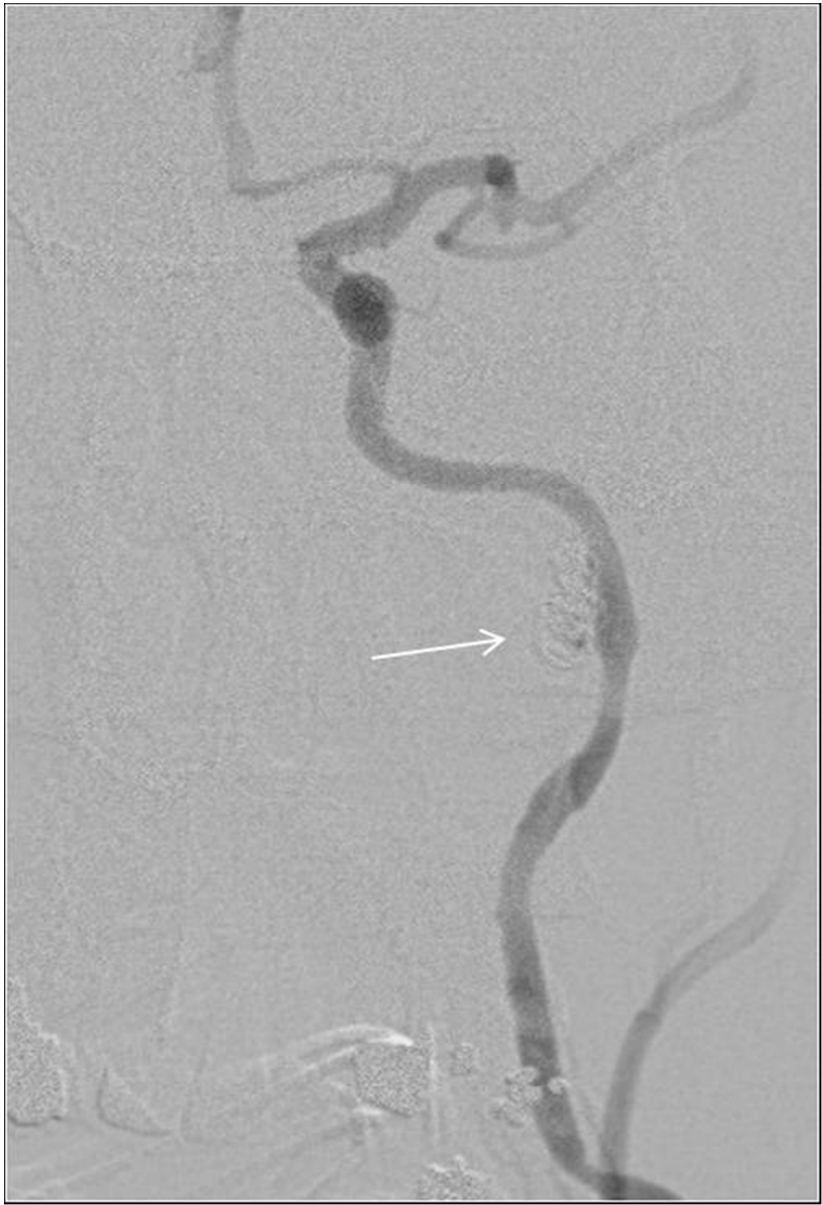Patient 5 treated with the PED with adjuvant coiling. Diagnostic DSA shows an 8 x 14mm left petrous ICA pseudoaneurysm;

110x153mm (150 x 150 DPI)





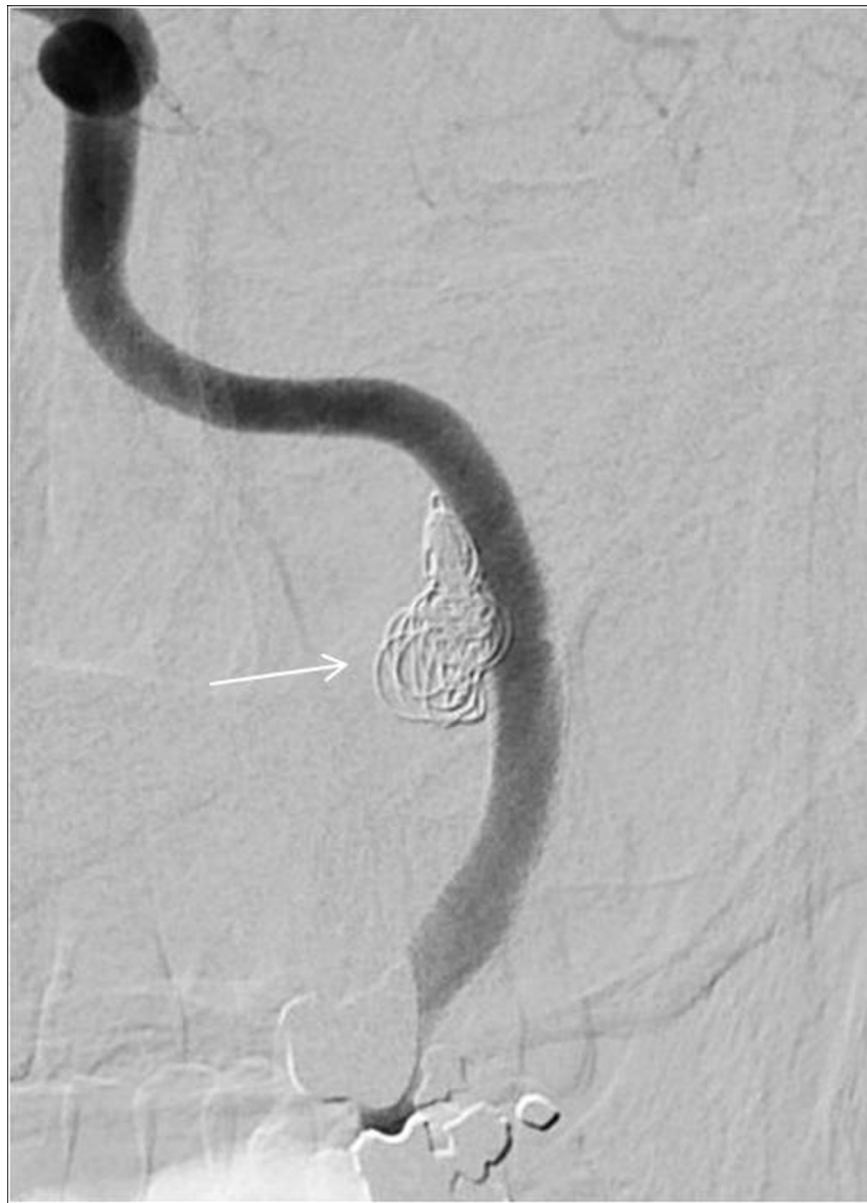1  
2  
3  
4  
5  
6  
7  
8  
9  
10  
11  
12  
13  
14  
15  
16  
17  
18  
19  
20  
21  
22  
23  
24  
25  
26  
27  
28  
29  
30  
31  
32  
33  
34  
35  
36  
37  
38  
39  
40  
41  
42  
43  
44  
45  
46  
47  
48  
49  
50  
51  
52  
53  
54  
55  
56  
57  
58  
59  
60



Obliteration of the pseudoaneurysm sac after placement of 2 PEDs and coil  
85x125mm (150 x 150 DPI)

only

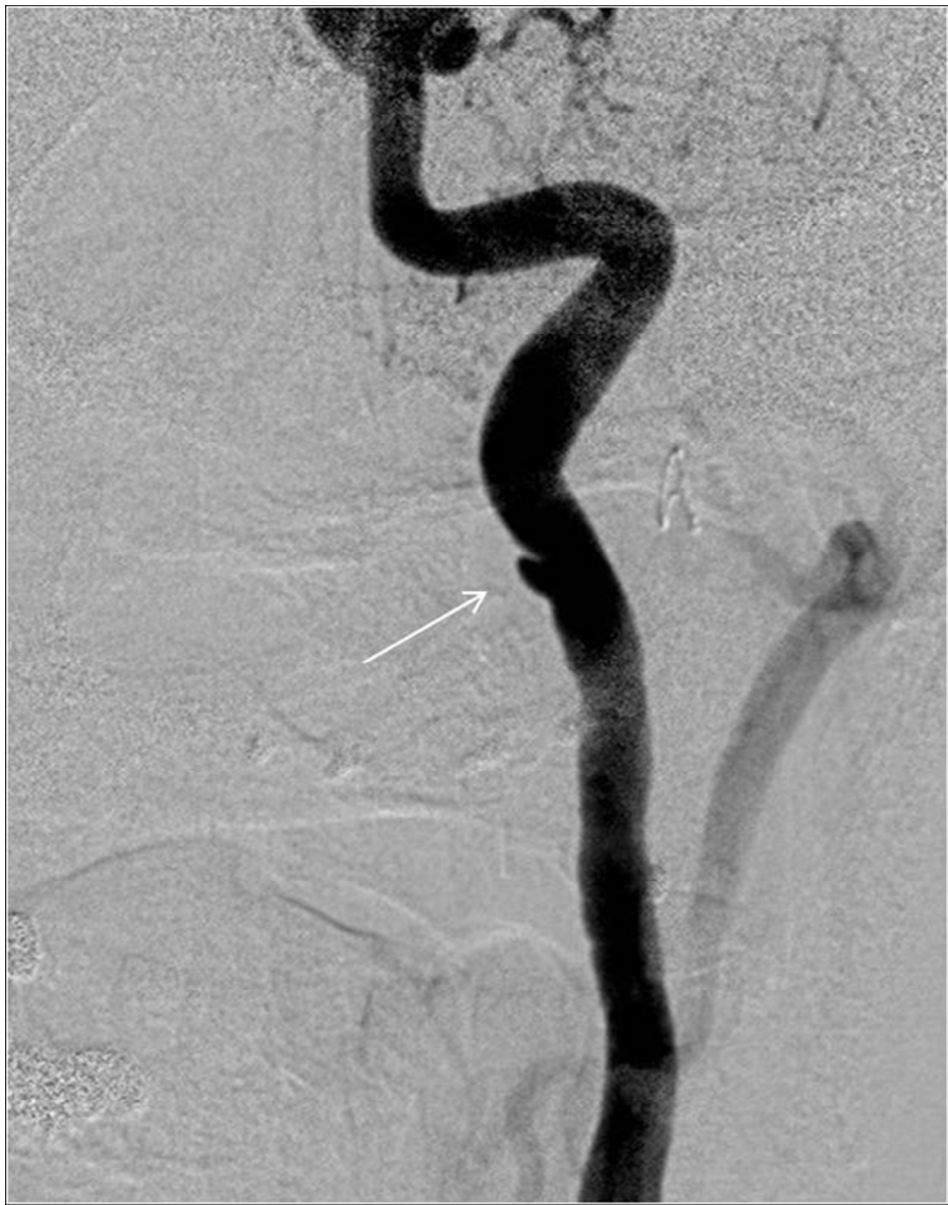1  
2  
3  
4  
5  
6  
7  
8  
9  
10  
11  
12  
13  
14  
15  
16  
17  
18  
19  
20  
21  
22  
23  
24  
25  
26  
27  
28  
29  
30  
31  
32  
33  
34  
35  
36  
37  
38  
39  
40  
41  
42  
43  
44  
45  
46  
47  
48  
49  
50  
51  
52  
53  
54  
55  
56  
57  
58  
59  
60



Follow-up DSA at 8-month shows the obliteration of the pseudoaneurysm and a patent parent artery.  
87x120mm (150 x 150 DPI)

only

1  
2  
3  
4  
5  
6  
7  
8  
9  
10  
11  
12  
13  
14  
15  
16  
17  
18  
19  
20  
21  
22  
23  
24  
25  
26  
27  
28  
29  
30  
31  
32  
33  
34  
35  
36  
37  
38  
39  
40  
41  
42  
43  
44  
45  
46  
47  
48  
49  
50  
51  
52  
53  
54  
55  
56  
57  
58  
59  
60

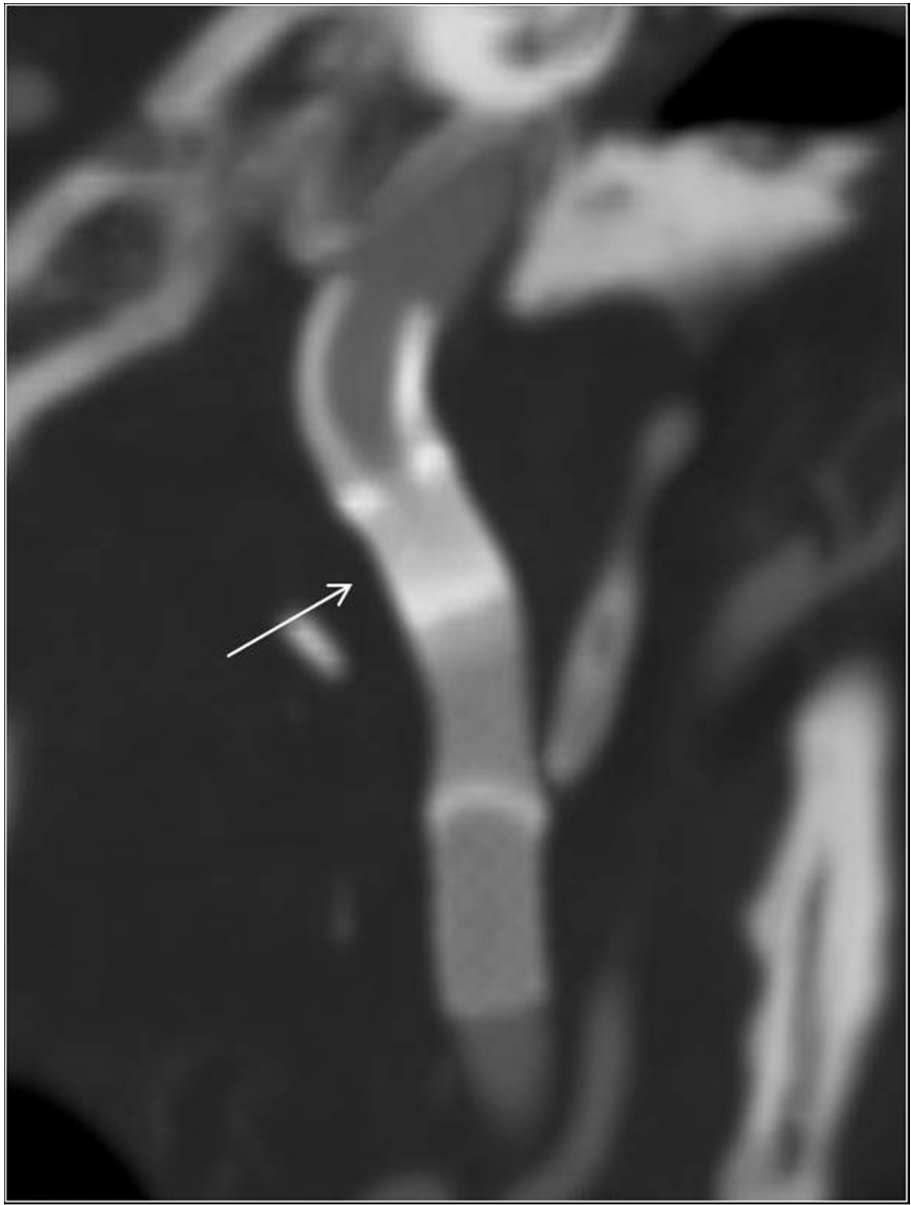


Patient 6. DSA shows a pseudoaneurysm at the right petrous ICA;

106x135mm (150 x 150 DPI)

AM

1  
2  
3  
4  
5  
6  
7  
8  
9  
10  
11  
12  
13  
14  
15  
16  
17  
18  
19  
20  
21  
22  
23  
24  
25  
26  
27  
28  
29  
30  
31  
32  
33  
34  
35  
36  
37  
38  
39  
40  
41  
42  
43  
44  
45  
46  
47  
48  
49  
50  
51  
52  
53  
54  
55  
56  
57  
58  
59  
60



Follow-up CTA at 3-month demonstrates telescoping of the PED and the obliteration of the pseudoaneurysm with a patent parent artery.  
101x134mm (150 x 150 DPI)

AM