



Title	Brunner's gland adenoma: unusual cause of duodenal haemorrhage and obstruction
Author(s)	Cheung, TT; Ip, EWK; Poon, RTP; Trendell-Smith, N
Citation	Hong Kong Medical Journal, 2013, v. 19 n. 5, p. 460.e1-460.e2
Issued Date	2013
URL	http://hdl.handle.net/10722/193242
Rights	Hong Kong Medical Journal. Copyright © Hong Kong Academy of Medicine Press.

Brunner's gland adenoma: unusual cause of duodenal haemorrhage and obstruction

A 70-year-old man was admitted to hospital for repeated vomiting and passing tarry stool for 1 week in October 2011. On physical examination, the patient was pale. The abdomen was not distended but there was a succussion splash in the epigastric area. Laboratory tests revealed microcytic anaemia with a haemoglobin level of 60 g/L. His creatinine level was 140 µmol/L, and his bilirubin level was 30 µmol/L. Liver enzyme and amylase levels were within normal limits. Upper endoscopy showed a deformed pylorus with duodenal obstruction where a very limited view showed an ulcerative tumour at the duodenal bulb.

Computed tomography (CT) with intravenous contrast revealed a large tumour occupying the first and second parts of the duodenum (Fig 1). Local resection of the lesion was planned and

pancreaticoduodenectomy was offered in case the ampulla of Vater was involved. During the operation, full Kocherisation of the duodenum was performed, and upon enterotomy of the first part of the duodenum, a well-encapsulated submucosal tumour measuring 10 cm x 6 cm x 8 cm was revealed (Fig 2). After identification of the ampulla of Vater, distal gastrectomy with local resection of the first and second parts of the duodenum was performed. The duodenal stump was closed with 4/0 Prolene suture. Gastrojejunostomy was constructed as a Billroth operation. The patient resumed diet on day 3 and was discharged on day 4. Histopathology of the resected specimen showed features of Brunner's gland adenoma (BGA) of the duodenum (Fig 3).

Discussion

The commonest tumour of the duodenum is a gastro-intestinal stromal tumour, which may have malignant potential. Other possibilities include adenocarcinoma of the duodenum, paraganglioma, and BGA.¹

In theory, endoscopic ultrasound (EUS) can provide adequate information on the depth of involvement of the lesion within the duodenum. The origin of the lesion and whether there is full thickness involvement with a breach of the serosal layer may provide more information for management.² Fine-

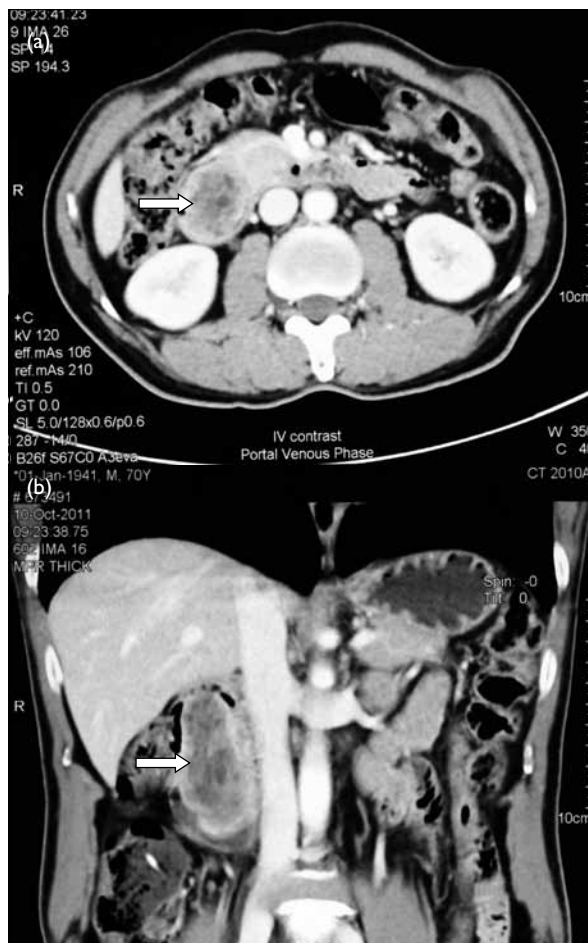


FIG 1. Contrast computed tomography of the abdomen shows a heterogeneous mass occupying the first and second parts of the duodenum: (a) transverse cut and (b) coronal cut

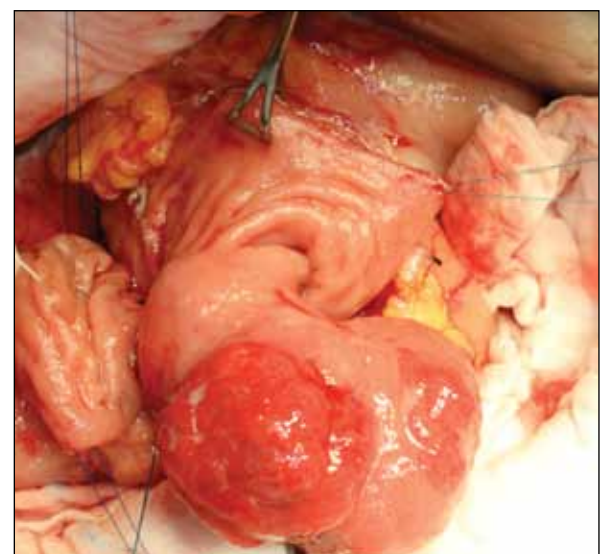


FIG 2. Operative view of the duodenum being transected revealing a pedunculated mass without involvement of the ampulla of Vater

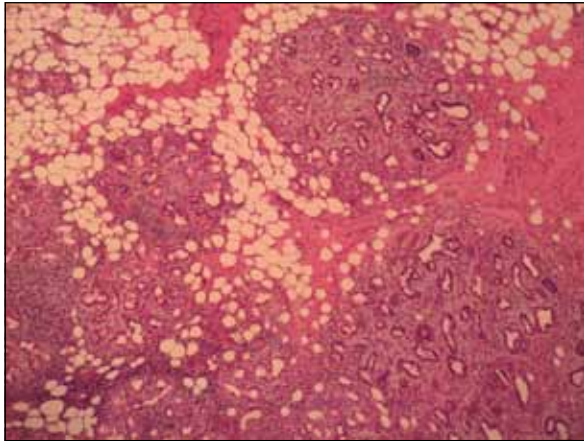


FIG 3. A photomicrograph of the tumour shows well-formed but abnormal Brunner's glands arranged within a fibrofatty stroma. The features are most in keeping with those of a Brunner's gland adenoma (H&E, x 100)

needle aspiration or tru-cut biopsy of the lesion guided by EUS could establish a tissue diagnosis and in turn facilitate better preoperative planning.³

Brunner's gland adenoma is a rare disease entity with approximately 150 cases reported in the literature since its first description in 1835 by Cruveilhier.⁴ It was encountered in 0.0013% out of

a series of 215 000 autopsies.^{1,5} Brunner's glands are branched acinotubular structures which secrete mucus that empties into the crypts of Lieberkühn. These glands also produce urogastrone and pepsinogen upon food passage into the stomach. The adenomas develop from Brunner glands deep within the mucosa and submucosa of the duodenum.⁶

In conclusion, a BGA generally carries a very good prognosis even when it has grown to a very large size. Preoperative planning including endoscopic and CT features, and the intra-operative finding of its duodenal tumour location largely determine the extent of the operation. If in doubt, endoscopy can be repeated to delineate the degree of tissue involvement, as the surgical approach and postoperative outcome vary greatly between malignant lesions and benign pathology.

TT Cheung, MB, BS

Email: tantocheung@hotmail.com

EWK Ip, MB, BS

RTP Poon, MS, PhD

Department of Surgery, The University of Hong Kong, Queen Mary Hospital, Pokfulam, Hong Kong

N Trendell-Smith, MB, BS

Department of Pathology, Queen Mary Hospital, Pokfulam, Hong Kong

References

1. Osborne R, Toffler R, Lowman RM. Brunner's gland adenoma of the duodenum. *Am J Dig Dis* 1973;18:689-94. [cross ref](#)
2. Xu GQ, Wu YQ, Wang LJ, Chen HT. Values of endoscopic ultrasonography for diagnosis and treatment of duodenal protruding lesions. *J Zhejiang Univ Sci B* 2008;9:329-34. [cross ref](#)
3. Stoos-Veic T, Tadic M, Aralica G. EUS-FNA of Brunner's gland hamartoma: a case report. *Cytopathology* 2013;24:194-6. [cross ref](#)
4. Cruveilhier J. *Anatomie pathologique du corps humain*. Paris: JB Balliere; 1835.
5. Hol JW, Stuijbergen WN, Teepeen JL, van Laarhoven CJ. Giant Brunner's hamartomas of the duodenum and obstructive jaundice. An overview of the literature and suspicion of malignancy in a case. *Dig Surg* 2007;24:452-5. [cross ref](#)
6. Lang IM, Tansy MF. Neural and hormonal control of Brunner's gland secretion. *Life Sci* 1982;30:409-17. [cross ref](#)