



<b>Title</b>	<b>Choroidal effusion following post-trabeculectomy bleb massage- Case report</b>
<b>Author(s)</b>	<b>Lai, JSM; Choy, NKB; Gangwani, RA</b>
<b>Citation</b>	<b>Hong Kong Journal of Ophthalmology, 2011, v. 15 n. 2, p. 71-72</b>
<b>Issued Date</b>	<b>2011</b>
<b>URL</b>	<b><a href="http://hdl.handle.net/10722/191113">http://hdl.handle.net/10722/191113</a></b>
<b>Rights</b>	<b>Hong Kong Journal of Ophthalmology. Copyright © Hong Kong Academy of Medicine Press.</b>

# Choroidal effusion following post-trabeculectomy bleb massage

Jimmy S. M. Lai,<sup>1</sup> FRCS, Bonnie N. K. Choy,<sup>2</sup> MB, BS, Rita Gangwani,<sup>1</sup> FRCSEd

<sup>1</sup>Eye Institute, The University of Hong Kong, Hong Kong SAR, China

<sup>2</sup>Department of Ophthalmology, United Christian Hospital, Kowloon, Hong Kong SAR, China

## Correspondence and reprint requests:

Prof. Jimmy S. M. Lai, Eye Institute, The University of Hong Kong, Room 301, Level 3, Block B, Cyberport 4, 100 Cyberport Road, Cyberport, Hong Kong SAR, China. Email: laism@hku.hk

## Abstract

We report a case of choroidal effusion after ocular massage following uncomplicated phacotrabeculectomy for chronic angle-closure glaucoma. Flap suturelysis and ocular massage are frequently used to manage underfiltration in the early post-trabeculectomy period. They are not without risk however. Malignant glaucoma has been reported following suturelysis.

shallow anterior chamber with an IOP of 3 mm Hg. Seidel's test was negative. There was choroidal detachment in the nasal quadrant (**Figure**). Ocular massage was discontinued. The IOP returned to 8 mm Hg on the next day with a decrease in the size of the choroidal effusion.

## Discussion

Ocular massage and laser suturelysis play an important role in the post-trabeculectomy period. Ocular massage increases the aqueous flow through the ostium and prevents any obstruction to the filtration from being permanent. Several complications such as wound dehiscence, hypotony, bleb rupture, and choroidal hemorrhage have been reported.<sup>1</sup>

Suturelysis is most effective when performed from day 4 to week 3 after trabeculectomy.<sup>2</sup> Although hypotony is a possible complication,<sup>3</sup> it has been recommended not to massage the eye too vigorously after suturelysis, or that massage should initially be performed by the surgeon under direct vision.<sup>2</sup>

In our patient, although ocular massage before suturelysis had no significant effect on drainage, the same maneuver after suturelysis resulted in a drastic increase in drainage complicated by choroidal detachment. We therefore recommend that massage should be performed cautiously by the patient who has undergone suturelysis, even if it was performed successfully before. Moreover, the patient should be educated regarding possible complications, so that he or she can consult an ophthalmologist at the earliest if the need arises.

**Key words:** Glaucoma, open-angle; Retinal artery occlusion; Trabeculectomy

## Case report

A 71-year-old man with left-eye chronic angle-closure glaucoma underwent uneventful phacotrabeculectomy with mitomycin-C in August 2010. The intraocular pressure (IOP) was 12 mm Hg on the first postoperative day. Five days later, the IOP increased to 50 mm Hg and the patient was taught to perform bleb massage using index fingers through the upper eyelid 3 times a day. The massage did not lower the IOP and laser suturelysis was performed. The IOP decreased to 7 mm Hg after suturelysis but 2 days later, the bleb became low again. There was no conjunctival leak and IOP was 20 mm Hg. The patient was instructed to continue ocular massage 3 times daily. Three days later, the patient complained of blurred left-eye vision for 1 day. Examination showed a

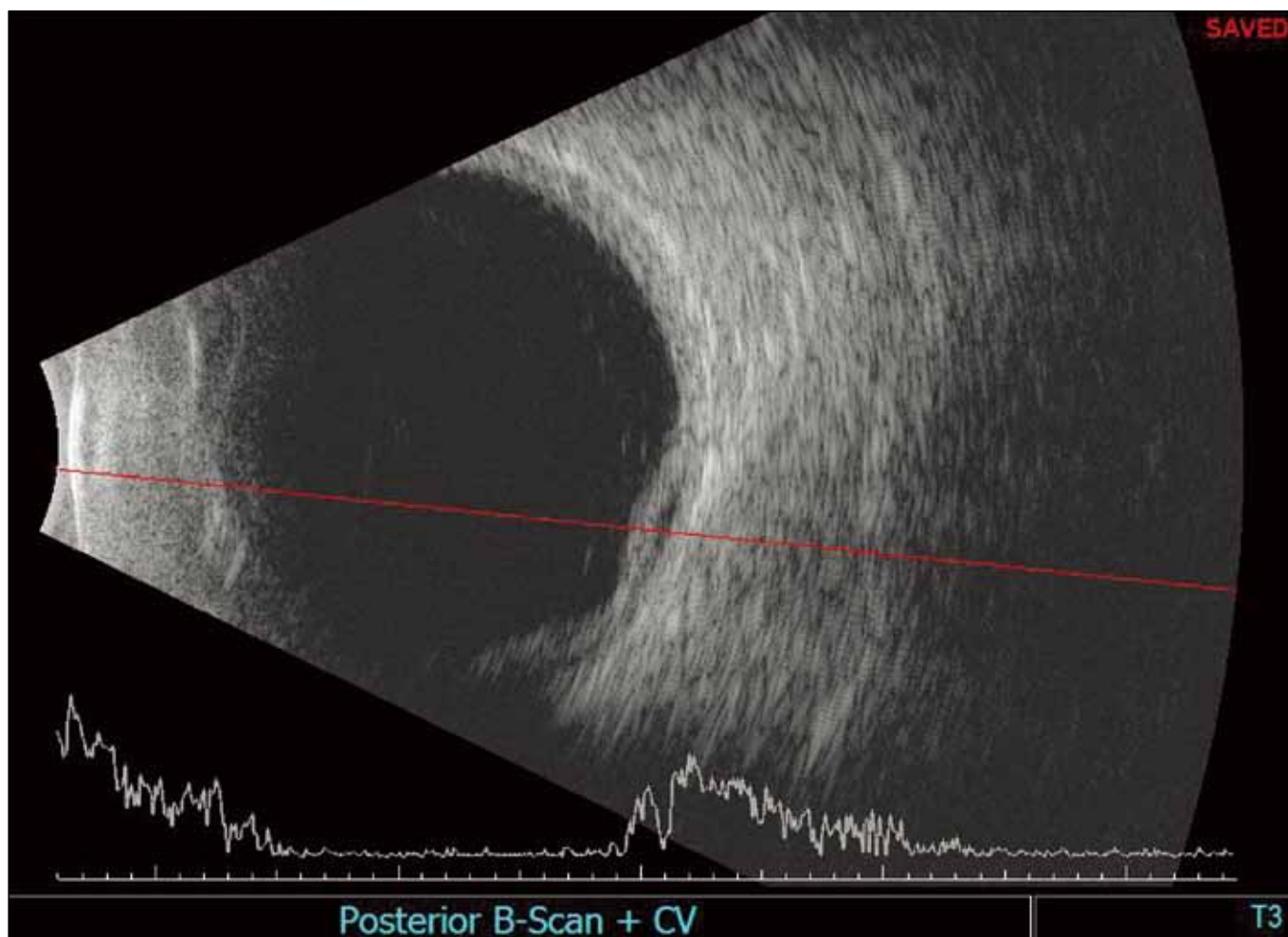


Figure. B-scan ultrasound showing choroidal effusion.

## References

1. Buys Y, Trope G. *Massage: techniques and complications*. In: Trope GE, editor. *Glaucoma surgery*. Boca Raton: Taylor & Francis Group, 2005:139-44.
2. Trope G. *Glaucoma suture lysis*. In: Trope GE, editor. *Glaucoma surgery*. Boca Raton: Taylor & Francis Group, 2005:145-9.
3. Macken P, Buys Y, Trope GE. *Glaucoma laser suture lysis*. *Br J Ophthalmol*. 1996;80:398-401.