




<b>Title</b>	<b>Second trimester termination of pregnancy after previous classical caesarean section for uterine fibroid</b>
<b>Author(s)</b>	<b>Pun, TC; Ngu, SF; Seto, MTY; Cheung, VYT</b>
<b>Citation</b>	<b>The 2013 RCOG World Congress, Liverpool, UK., 24-26 June 2013. In BJOG, 2013, v. 120 suppl. s1, p. 519, abstract no. EP13.05</b>
<b>Issued Date</b>	<b>2013</b>
<b>URL</b>	<b><a href="http://hdl.handle.net/10722/187175">http://hdl.handle.net/10722/187175</a></b>
<b>Rights</b>	<b>Creative Commons: Attribution 3.0 Hong Kong License</b>



## Second trimester termination of pregnancy after previous classical caesarean section for uterine fibroid

TC Pun, SF Ngu, MT Seto, VY Cheung, Department of Obstetrics & Gynaecology, the University of Hong Kong, Hong Kong, SAR, China



**Objectives:** To report the successful termination of pregnancy in a patient with history of previous classical caesarean section performed because of uterine fibroid obstructing the lower segment.

**Methods:** The patient had classical caesarean section performed for transverse lie, uterine fibroid 14 months prior to presentation requesting termination of pregnancy at 14 weeks maturity. During the operation, a 16 cm broad ligament fibroid was found posteriorly in the left side.

The patient was treated with the following regimen

1. Insertion of hygroscopic cervical dilator the night before
2. Misoprostol 50 microgram vaginally, then 100 microgram vaginally 4 hours after initial dose, then 150 microgram vaginally 8 hours after initial dose, then 200 microgram vaginally 12 hours after initial dose

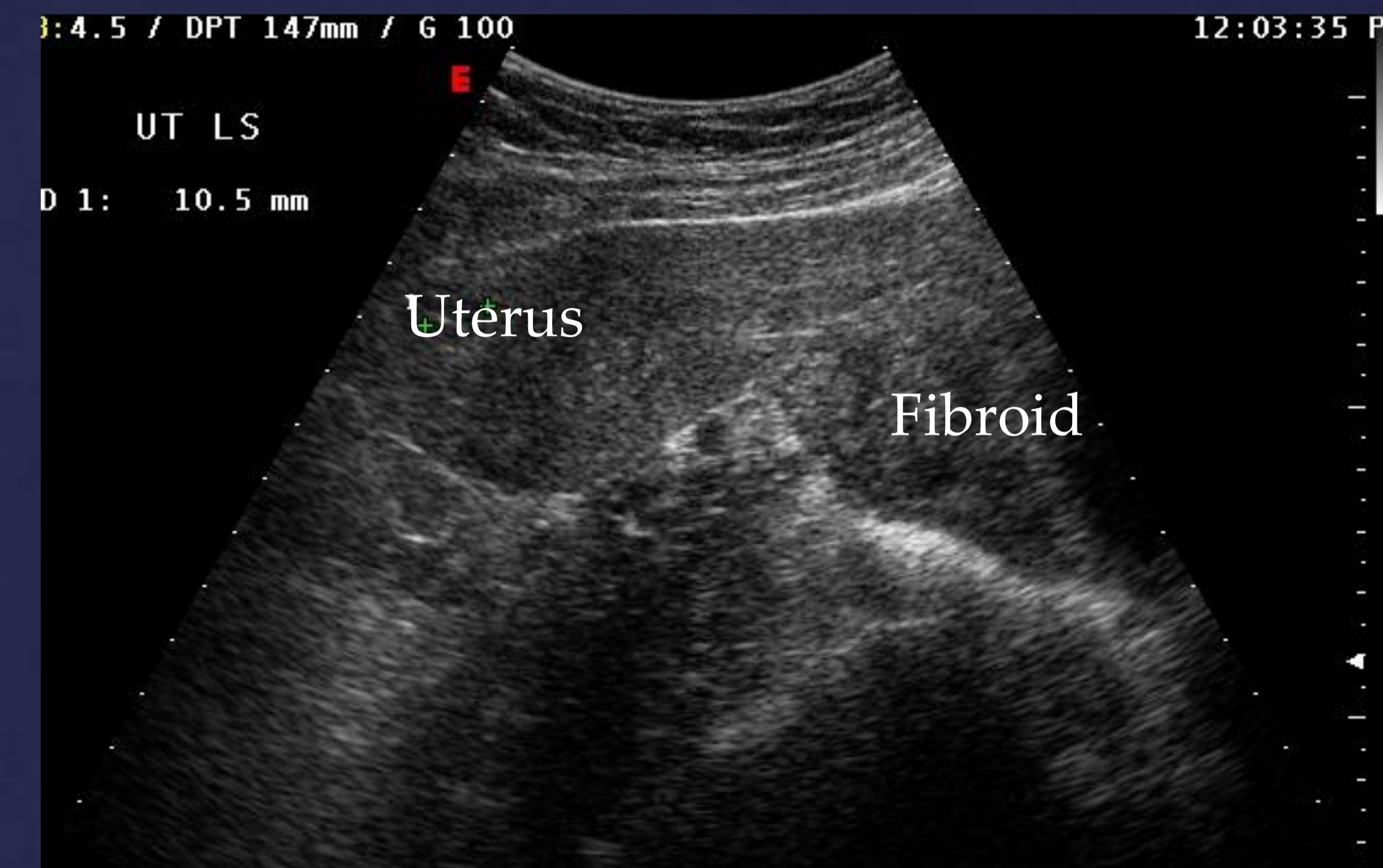
**Results:** Physical examination at presentation revealed an enlarged uterus with bulge over right lower quadrant. The cervix was displaced anteriorly and the same bulge was also felt at the posterior fornix. Ultrasound examination revealed the fetus near the fundus of the uterus.

The patient developed bleeding and abdominal pain 8 hours after the first dose of misoprostol. A total of 3 doses of misoprostol were given. The fetus aborted 9 1/2 hours after the first dose of misoprostol. The patient made an uneventful recovery and was discharged the next day.

**Discussion:** The safety of using misoprostol to terminate second trimester pregnancy in patients with previous classical caesarean section was not established. In a systematic review, two cases were identified and one had a rupture.(Berghella, Airolidi & O'Neill et al 2009) In a case report of 3 cases, two patients had inevitable miscarriages.(Malapati R, Villaluna G, Nguyen TM 2011) The authors proposed to use misoprostol in a stepwise fashion. The termination of pregnancy was further complicated by the presence of a uterine fibroid at the lower part of the uterus.

To further facilitate the operation, we insert hygroscopic cervical dilator to ripen the cervix before misoprostol was started. Misoprostol was then given in a stepwise fashion after assessment and the patient aborted uneventfully.

**Conclusions:** Misoprostol in a lower dose can be used after previous classical caesarean section.



Ultrasound examination performed 45 days after the termination of pregnancy to show the relationship of the fibroid with the uterus.

**Acknowledgement:**

The authors thank the Department of Radiology, Queen Mary Hospital for providing the ultrasound picture.

**Reference:**

Berghella V, Airolidi J, O'Neill AM et al. Misoprostol for second trimester pregnancy termination in women with prior caesarean: a systematic review. BJOG; Int J Obstet Gynaecol 2009;116:1151-1157.

Malapati R, Villaluna G, Nguyen TM. Use of misoprostol for pregnancy termination in women with prior classical caesarean delivery. A report of 3 cases. J Reprod Med 2011;56:85-86.