



<b>Title</b>	<b>Fibromatosis of the neck causing airway obstruction managed effectively with weekly low-dose methotrexate and vinblastine</b>
<b>Author(s)</b>	<b>Sze, H; Yeung, MW</b>
<b>Citation</b>	<b>Hong Kong Medical Journal, 2009, v. 15 n. 3, p. 221-223</b>
<b>Issued Date</b>	<b>2009</b>
<b>URL</b>	<b><a href="http://hdl.handle.net/10722/180450">http://hdl.handle.net/10722/180450</a></b>
<b>Rights</b>	<b>Hong Kong Medical Journal. Copyright © Hong Kong Academy of Medicine Press</b>

# Fibromatosis of the neck causing airway obstruction managed effectively with weekly low-dose methotrexate and vinblastine

Henry Sze 施俊健  
MW Yeung 楊美雲

Fibromatosis is a rare disease with benign histology. Its infiltrative growth pattern may prevent complete resection. We report a case of a 40-year-old woman with fibromatosis of the neck requiring an emergency operation for acute upper airway obstruction. Gross residual tumour was left behind but excellent tumour shrinkage was achieved by using weekly low-dose methotrexate and vinblastine. Despite the use of newer agents such as imatinib, cytotoxic chemotherapy remains an efficacious treatment for inoperable fibromatosis.

## Introduction

Fibromatosis, also known as desmoid tumour, is a slow-growing and locally infiltrative disease caused by uncontrolled proliferation of fibrous tissue arising from deep musculoaponeurotic structures. It differs from fibrosarcoma by having low cellularity, infrequent mitoses, absence of necrosis, and not metastasising. Despite having benign histology, its aggressive local growth pattern can cause significant morbidity.<sup>1</sup>

Fibromatosis is a rare entity, representing only 0.03% of all neoplasms.<sup>2</sup> It is classified according to its anatomical position into abdominal, intra-abdominal, and extra-abdominal subtypes.<sup>1</sup> Fibromatosis of the head and neck region comprises about 10 to 25% of all cases of extra-abdominal fibromatosis.<sup>3</sup> Attempts have been made to separate it from that arising from other parts of the body because of the unique clinical problems it can cause in relation to its critical anatomical position.<sup>3-5</sup>

The belief that cytotoxic chemotherapy is ineffective against slow-growing tumours with benign histology and is associated with significant morbidity has led to it being considered a last resort for patients who have run out of treatment options. We report a case where a woman whose fibromatosis of the neck obstructed her upper airway had a dramatic response to traditional chemotherapy.

## Case report

A 40-year-old woman with a history of good past health first presented with a right neck swelling in May 2003. The neck mass was surgically excised and it was found to be a neurofibroma after examination by the pathologist. One year later, the neck swelling recurred and an incisional biopsy confirmed that it was caused by extra-abdominal fibromatosis. A computed tomographic (CT) scan showed a large soft tissue mass over her right lower neck, posterior to the right common carotid artery and jugular vein. She was given tamoxifen for 8 months. A later CT scan showed an enlarging tumour mass extending to the superior mediastinum and causing anterior displacement of the trachea. Her treatment was changed, tamoxifen was ceased and sulindac commenced but she developed an allergic reaction to sulindac. Debulking surgery was finally performed in 2005, during which her right external carotid artery was ligated. She also developed right vocal cord palsy postoperatively.

One year after the debulking surgery, the patient developed acute upper airway obstruction requiring an emergency procedure for airway relief. Intra-operatively, a huge right neck tumour was found tightly adherent to the prevertebral muscle. It closely surrounded the right common carotid artery and spread behind the trachea and oesophagus to the contralateral side. Inferiorly, the tumour reached the superior mediastinum. Exploratory sternotomy, debulking of the tumour, and a tracheostomy were performed. The right common carotid artery was ruptured during its dissection from the tumour and was ligated. A feeding jejunostomy was performed later to manage extrinsic oesophageal compression. A baseline CT scan of the neck was done after the operation (Fig 1).

To manage her gross inoperable residual tumour, the patient was referred to the Department of Clinical Oncology, Pamela Youde Nethersole Eastern Hospital, Hong

### Key words

Airway obstruction; Chemotherapy, adjuvant; Fibromatosis, aggressive; Head and neck neoplasms

*Hong Kong Med J* 2009;15:221-3

Department of Clinical Oncology,  
Pamela Youde Nethersole Eastern  
Hospital, Chai Wan, Hong Kong  
H Sze, MB, BS  
MW Yeung, FRCR

Correspondence to: Dr H Sze  
E-mail: henrysze@graduate.hku.hk

## 每週使用低劑量的methotrexate及vinblastine有效醫治引致呼吸道阻塞的頸部纖維瘤

纖維瘤是一種罕見的良性疾病。其浸潤性成長模式可避免病人完全切除腫瘤。本文報告一名患有頸部纖維瘤的40歲女子，因急性上呼吸道阻塞須接受急診手術。術後有明顯的腫瘤殘留，每週使用低劑量的methotrexate及vinblastine後，腫瘤縮小。對於不能施行手術的纖維瘤，雖然可使用如imatinib的新藥，可是細胞毒性化療仍是有效的療法。

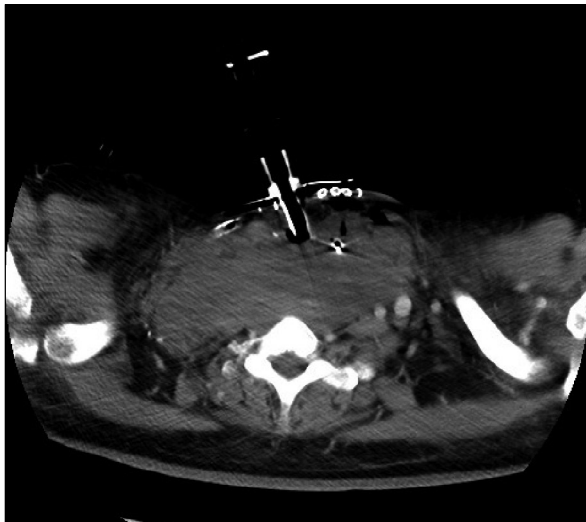


FIG 1. Computed tomographic scan before chemotherapy showing a huge tumour compressing the airway, vessels, and oesophagus after debulking surgery and tracheostomy

Kong, for possible radiotherapy, which has a documented role in the management of fibromatosis. Radiotherapy could not be justified, however, due to the exceptionally large radiotherapy portal required, making the risks of radiotherapy likely to outweigh any potential benefits. Thus, instead of stepping up local treatment, we managed her with low-dose chemotherapy using weekly methotrexate 50 mg and vinblastine 10 mg, both intravenously.

After a few weeks of chemotherapy, the patient had a subjective improvement in neck tightness. Her obstructive symptoms improved gradually and she was able to resume oral feeding. The jejunostomy and tracheostomy tubes were removed after 6 months and 11 months, respectively. Her general condition and quality of life improved greatly.

This response was also confirmed radiologically. Though the first CT scan performed after 2 months of chemotherapy showed minimal change, serial CT scans from 6 months onwards showed progressive improvement. Her most recent CT scan, performed after 16 months of chemotherapy, showed excellent tumour shrinkage amounting to a partial response according to the RECIST (Response Evaluation Criteria

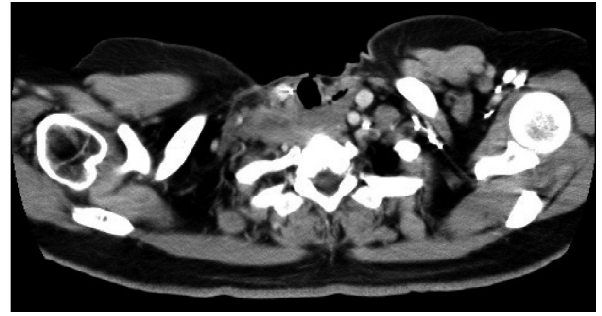


FIG 2. Computed tomographic scan after 16 months of chemotherapy showing excellent tumour shrinkage and removal of the tracheostomy tube

in Solid Tumours) scale (Fig 2).

The patient did suffer side-effects, developing myelotoxicity with grade 3 neutropaenia after 6 weeks of chemotherapy. Her dose was halved and was well tolerated afterwards.

It was planned that the total length of treatment be 12 months, but it was extended due to her continuing excellent response. Chemotherapy will be continued until a plateau of response is reached. The need for radiotherapy will be reviewed after maximal tumour shrinkage has been achieved.

## Discussion

Fibromatosis of the head and neck is a rare disease. Patients usually present with a painless mass or less commonly, pain or neurological symptoms.<sup>4</sup> Upper airway obstruction is a potentially fatal clinical presentation that requires urgent attention. As with fibromatosis arising from other parts of the body, surgical resection is the mainstay of treatment.<sup>1-6</sup> The primary goal is to achieve a clear resection with wide margins, but preservation of function is of equal importance. Due to the complex anatomy and frequent entrapment of neurovascular structures in the head and neck region, these aims are often difficult to achieve. Resection often leads to injury of important surrounding tissues, for example the brachial plexus, and is associated with recurrence requiring repeated excisions.<sup>5</sup> The reported recurrence rate ranges between 46 and 62%.<sup>5,6</sup> The role of adjuvant therapy has not been established because of the occasional observation of spontaneous regression and arrested growth after incomplete excision, and the finding that the resection margin correlates poorly with the likelihood of local recurrence.<sup>4</sup>

For patients with inoperable tumours, or those where surgery may result in major functional loss, radiotherapy is a reasonable option. Improved disease control has been reported in both adjuvant and primary settings.<sup>2,7,8</sup> Primary radiotherapy has achieved a local control rate of up to 93%.<sup>8</sup> The

optimal margin around the tumour, radiation dose, fractionation and technique remain undefined, with wide variations reported.<sup>7</sup> Margins of 2 to 3 cm in transverse and 5 cm in longitudinal directions are commonly used, as in soft tissue sarcoma. Total doses ranging from 36.0 to 76.2 Gy have been reported.<sup>7</sup> A dose-response relationship had been suggested with doses higher than 50 Gy being associated with better local control.<sup>2</sup> Most authors propose a dose between 50 and 60 Gy using conventional fractionation.

Sulindac<sup>9</sup> or other non-steroidal anti-inflammatory drugs including celecoxib and hormonal therapy using tamoxifen<sup>10</sup> or toremifene have shown promising disease control while causing fewer side-effects.

Cytotoxic chemotherapy is usually reserved for patients in whom other treatment options have been exhausted. Many clinicians consider chemotherapy toxic and ineffective for low-grade tumours with a benign histology and no invasive component. While there are limited data on the use of single-agent chemotherapy in fibromatosis, the overall response rate to combination chemotherapy ranges between 17 and 100% with a median response rate of 50%.<sup>11</sup> Such an impressive level of responsiveness to chemotherapy is not demonstrated by other low-grade tumours or even some malignant neoplasms. Commonly used regimens include doxorubicin-based chemotherapy (doxorubicin with dacarbazine or doxorubicin with cyclophosphamide and vincristine), actinomycin D-based chemotherapy, or a combination of methotrexate with a vinca alkaloid

(vinblastine or vinorelbine). These are all traditional agents that are cheap and easily available. The major concern about doxorubicin-based chemotherapy is cardiotoxicity while those related to actinomycin D-based regimens include sterility and carcinogenesis. The combination of methotrexate with vinblastine, administered weekly, is associated with fewer side-effects.<sup>12,13</sup> This is a less toxic alternative, especially when the treatment has to be administered for prolonged periods. Fibromatosis usually responds slowly to chemotherapy; it may take months for the tumour to show a reduction in size. This may be due to the presence of mostly connective tissues with abundant collagen fibres, the low cellularity, and infrequent mitoses of this low-grade tumour. Current data support the use of chemotherapy for at least 1 year unless there is evidence of disease progression or significant toxicity. Most patients can tolerate weekly low-dose methotrexate and vinblastine, although it was demonstrated that myelotoxicity and hepatotoxicity can lead to a prolonged interval between cycles.<sup>14</sup> In our patient, myelotoxicity was managed effectively with a dose reduction, without compromising the treatment efficacy.

Other alternatives to systemic treatment include biological agents such as interferon and more recently, imatinib, a tyrosine kinase inhibitor.<sup>15</sup> While the most effective therapeutic agent is yet to be defined, our patients should not be left without the option of cytotoxic chemotherapy just because of concerns about its toxicity or the misconception that it is not effective against low-grade tumours.

## References

1. Enzinger FM, Weiss SW. Soft tissue tumors: fibromatoses. 4th ed. St Louis, MO: Mosby; 2001.
2. Nuyttens JJ, Rust PF, Thomas CR Jr, Turrisi AT 3rd. Surgery versus radiation therapy for patients with aggressive fibromatosis or desmoid tumors: a comparative review of 22 articles. *Cancer* 2000;88:1517-23.
3. Wang CP, Chang YL, Ko JY, Cheng CH, Yeh CF, Lou PJ. Desmoid tumor of the head and neck. *Head Neck* 2006;28:1008-13.
4. Hoos A, Lewis JJ, Urist MJ, et al. Desmoid tumors of the head and neck—a clinical study of a rare entity. *Head Neck* 2000;22:814-21.
5. Fasching MC, Saleh J, Woods JE. Desmoid tumors of the head and neck. *Am J Surg* 1988;156:327-31.
6. Kulaylat MN, Karakousis CP, Keaney CM, McCorvey D, Bem J, Ambrus Sr JL. Desmoid tumour: a pleomorphic lesion. *Eur J Surg Oncol* 1999;25:487-97.
7. Tolan S, Shanks JH, Loh MY, Taylor B, Wylie JP. Fibromatosis: benign by name but not necessarily by nature. *Clin Oncol (R Coll Radiol)* 2007;19:319-26.
8. Spear MA, Jennings LC, Mankin HJ, et al. Individualizing management of aggressive fibromatoses. *Int J Radiat Oncol Biol Phys* 1998;40:637-45.
9. Tsukada K, Church JM, Jagelman DG, et al. Noncytotoxic drug therapy for intra-abdominal desmoid tumor in patients with familial adenomatous polyposis. *Dis Colon Rectum* 1992;35:29-33.
10. Chao AS, Lai CH, Hsueh S, Chen CS, Yang YC, Soong YK. Successful treatment of recurrent pelvic desmoid tumour with tamoxifen: case report. *Hum Reprod* 2000;15:311-3.
11. Janinis J, Patriki M, Vini L, Aravantinos G, Whelan JS. The pharmacological treatment of aggressive fibromatosis: a systematic review. *Ann Oncol* 2003;14:181-90.
12. Weiss AJ, Lackman RD. Low-dose chemotherapy of desmoid tumors. *Cancer* 1989;64:1192-4.
13. Skapek SX, Hawk BJ, Hoffer FA, et al. Combination chemotherapy using vinblastine and methotrexate for the treatment of progressive desmoid tumor in children. *J Clin Oncol* 1998;16:3021-7.
14. Azzarelli A, Gronchi AP, Bertulli R, et al. Low-dose chemotherapy with methotrexate and vinblastine for patients with advanced aggressive fibromatosis. *Cancer* 2001;92:1259-64.
15. Chugh R, Maki RG, Thomas DG, et al. A SARC phase II multicenter trial of imatinib mesylate (IM) in patients with aggressive fibromatosis [abstract 9515]. *J Clin Oncol* 2006;24(18 Suppl):523S.