



<b>Title</b>	<b>Enophthalmos caused by an orbital venous malformation</b>
<b>Author(s)</b>	<b>Chung, CF; Lai, JSM</b>
<b>Citation</b>	<b>Hong Kong Medical Journal, 2009, v. 15 n. 4, p. 299-300</b>
<b>Issued Date</b>	<b>2009</b>
<b>URL</b>	<b><a href="http://hdl.handle.net/10722/176477">http://hdl.handle.net/10722/176477</a></b>
<b>Rights</b>	<b>Hong Kong Medical Journal. Copyright © Hong Kong Medical Association.</b>

# Enophthalmos caused by an orbital venous malformation

CF Chung 鍾創輝  
Jimmy SM Lai 黎少明

Orbital vascular malformations usually present with proptosis. We report a case where a patient with an orbital venous malformation presented with enophthalmos. Since many underlying orbital pathologies, including orbital metastases, can cause enophthalmos, it is important to investigate patients properly. Computed tomographic imaging of the orbit remains the most useful tool in the management of patients with enophthalmos.

## Introduction

Enophthalmos is recession of the eyeball into the bony orbit. It is due to a change in the volumetric relationship between the rigid bony orbital cavity and its contents, predominantly the orbital fat and the eyeball. Expansion of the orbital cavity with no change in the volume of the orbital contents leads to enophthalmos. Alternatively, scar contracture of the orbital fat and extraocular muscles may decrease the soft tissue volume, making the orbital cavity less full, thus causing enophthalmos. Conditions that can lead to orbital cavity expansion include fractures of the orbital bones, surgical expansion of the orbit in thyroid orbitopathy, and orbital varices with bone erosion. Conditions that cause loss of orbital contents include orbital fat atrophy following trauma, severe inflammation or infection, external beam irradiation, orbital metastases, maxillary mucocoeles and surgical resection of an orbital mass.<sup>1</sup>

## Case report

In January 2007, a 55-year-old woman with no history of trauma presented with a 5-year history of progressive drooping of her left eyelid and a sunken left eye. A physical examination revealed a 4-mm enophthalmos with a 5.5-mm pseudoptosis obscuring the visual axis of the left eye (Fig 1). A soft tissue mass with an indistinct border was palpable below the superonasal orbital rim. The size of the mass and the degree of enophthalmos did not change during the Valsalva manoeuvre. The left eye had limited lower and lateral movement. The visual acuity was 0.2. Both pupils had a normal light reaction. The intraocular pressure was 16 mm Hg. A plain computed tomographic (CT) scan of the orbit revealed a 5.6-mm lobulated soft tissue mass with multiple calcified densities, mainly in the superomedial orbital region, displacing the optic nerve medially. The left orbit showed expansion (Fig 2a). An orbital CT scan with contrast showed a homogeneously enhancing mass involving the superior and medial recti muscles, the posteromedial part of the inferior rectus muscle, and the optic nerve, around their attachments to the globe (Fig 2b). Phleboliths were visualised (Fig 2c). Fourteen months later, the enophthalmos had increased to 6.5 mm while the pseudoptosis remained unchanged. Her visual acuity was unchanged at 0.2. Because of the diffuse nature of the lesion, conservative management

### Key words

Enophthalmos; Orbit; Vascular malformations

*Hong Kong Med J* 2009;15:299-300

Department of Ophthalmology, United Christian Hospital, Kwun Tong, Hong Kong

CF Chung, FRCS (Edin), FHKAM (Ophthalmology)  
Eye Institute, The University of Hong Kong, Cyberport, Hong Kong  
JSM Lai, MD, FHKAM (Ophthalmology)

Correspondence to: Prof JSM Lai  
E-mail: laism@hku.hk

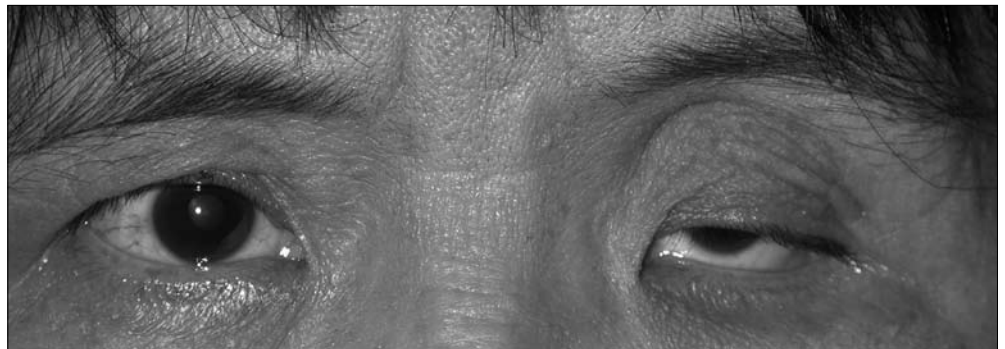

FIG 1. Left eye enophthalmos and pseudoptosis

## 眶內靜脈畸形造成的眼球內陷

眶內靜脈畸形往往會引致病人眼球突出。本文報告一名有眶內靜脈畸形的病人出現眼球內陷的情況。由於有很多眼疾，包括癌細胞擴散至眼窩，都會導致眼球內陷，所以必須要為病人徹底檢查。替病人眼窩進行斷層照相術仍然是眼球內陷一種有效的診斷方法。

was adopted. The pseudoptosis was corrected with levator aponeurosis plication.

## Discussion

Venous malformations of the orbit usually cause proptosis.<sup>2-5</sup> The proptosis is caused by the mass effect of the lesion or haemorrhage inside the orbit. We report a case where an orbital venous malformation caused enophthalmos instead of proptosis. The enophthalmos was probably due to expansion of the orbital volume and pressure-induced orbital fat atrophy. Some venous malformations are non-distensible and in this instance the Valsalva manoeuvre has no effect on their size.<sup>3</sup> For this reason, a negative Valsalva manoeuvre test cannot be used to exclude an orbital venous malformation as a possible diagnosis. In contrast to most venous malformations, which are well defined,<sup>4,5</sup> our patient's lesion was poorly defined, so its shape was variable.

General practitioners may occasionally encounter patients with enophthalmos. It is important to search for the underlying aetiology because of the diversity of mechanisms causing this. A CT scan of the orbits is a very useful tool for investigating underlying causes as this can reveal orbital fractures, orbital fat atrophy, orbital varices, and orbital changes associated with pathology in the maxillary sinus. The presence of phleboliths in CT orbit imaging is highly suggestive of venous malformation. On the other hand, magnetic resonance imaging is best for visualising neoplastic infiltrations. Bone scans are occasionally needed to identify areas of bone inflammation in osteomyelitis or inflammatory wasting disorders. Where an orbital tumour is suspected, a systemic evaluation for a primary malignancy or metastatic disease should be performed. An open biopsy may be indicated, but a needle biopsy is rarely used for the investigation of enophthalmos.

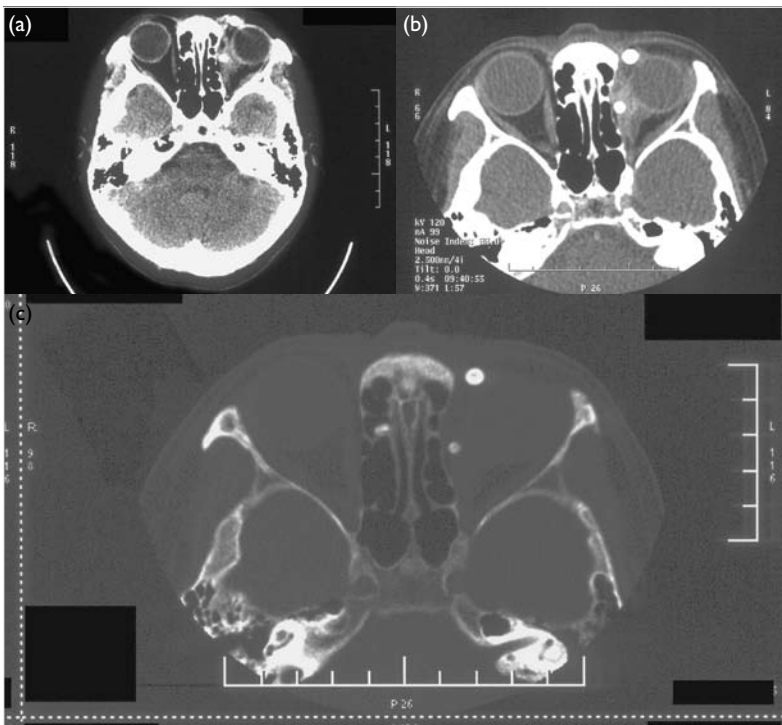


FIG 2. (a) Plain computed tomographic (CT) scan of the orbits showing a soft tissue mass in the left medial orbit with a calcified focus; (b) CT scan of the orbits with contrast showing homogenous enhancement of the soft tissue mass with medial deviation of the optic nerve. Two foci of calcification were present; (c) CT scan of the orbits showing foci of calcification with lucent centres

## References

1. Cline RA, Rootman J. Enophthalmos: a clinical review. *Ophthalmology* 1984;91:229-37.
2. Tan ST, Bialostocki A, Brasch H, Fitzjohn T. Venous malformation of the orbit. *J Oral Maxillofac Surg* 2004;62:1308-11.
3. Lacey B, Rootman J, Marotta TR. Distensible venous malformations of the orbit: clinical and hemodynamic features and a new technique of management. *Ophthalmology* 1999;106:1197-209.
4. Kim JW, Stewart WB, Spencer WH, Ellis DS. Acute expansion of an orbital vascular malformation. *Arch Ophthalmol* 1999;117:844-5.
5. Rubin PA, Remulla HD. Orbital venous anomalies demonstrated by spiral computed tomography. *Ophthalmology* 1997;104:1463-70.