



www.fmshk.org

THE HONG KONG 香港醫訊
MEDICAL DIARY

VOL.16 NO.11 NOVEMBER 2011

*Oral &
Maxillofacial Surgery*

Helping hands *around the world*

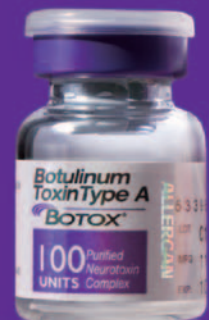

Turning heads *with a* *wealth of publications*

BOTOX®: one of the world's most widely researched medicines¹

BOTOX®: a wealth of experience

- ▶ Treating serious and/or debilitating conditions for 20 years worldwide²
- ▶ Over 4000 clinical publications³
- ▶ More licensed indications than any other botulinum toxin:⁴⁻⁶
 - Strabismus and blepharospasm
 - Hemifacial spasm
 - Cervical dystonia
 - Dynamic equinus foot deformity due to spasticity in juvenile cerebral palsy
 - Wrist and hand disability due to upper limb spasticity associated with stroke
 - Severe axillary hyperhidrosis
 - Upper facial rhytides



References:

1. Allergan, data on file.
2. Mejia N et al. Long-term botulinum toxin efficacy, safety, and immunogenicity. *Mov Disord* 2005;20(5):592-597.
3. Search strategies are identical across all products. Searches are conducted on STN International® in the following databases: Medline®, Embase®, Embal®, Hcoplus®, Pascal®, Biosis®, Scisearch®, Data are reported separately from either peer-reviewed articles, letters, reports, or from congress abstracts, meeting posters. Results include clinical studies, case reports, reviews, and exclude trade magazines, news, book chapters.
4. BOTOX® Product Insert, Allergan HK, September 2009.
5. Dysport® Product Insert, Ipsen, June 2007.
6. Xeomin® Product Insert, Merz Pharma, January 2008.



Contents

Editorial

- **Editorial** 2
Dr. Philip LEE

Dental Bulletin

- **Current Concepts in Mandibular Reconstruction** 3
Dr. Winnie WS CHOI
Dr. John LO CME
- **MCHK CME Programme Self-assessment Questions** 6
- **Do You Think They Know about Us? Oral and Maxillofacial Surgery in Hong Kong** 8
Dr. Alfred SL LAU
- **Mandible Repositioning in the Management of Obstructive Sleep Apnoea** 12
Dr. Philip LEE
- **The Use of Recombinant Human Bone Morphogenetic Protein-2 in Vertical Ridge Augmentation for Dental Implants – A Case Report** 19
Dr. James CHOW
- **Reconstruction of Maxillary Defects** 23
Dr. Sai-kwing CHAN

Life Style

- **Besides Maxillofacial Surgery** 27
Dr. Kiang-cheong CHOW

Dermatological Quiz

- **Dermatological Quiz** 31
Dr. Ka-ho LAU

Medical Diary of November

- Calendar of Events** 30


Disclaimer

All materials published in the Hong Kong Medical Diary represent the opinions of the authors responsible for the articles and do not reflect the official views or policy of the Federation of Medical Societies of Hong Kong, member societies or the publisher.

Publication of an advertisement in the Hong Kong Medical Diary does not constitute endorsement or approval of the product or service promoted or of any claims made by the advertisers with respect to such products or services.

The Federation of Medical Societies of Hong Kong and the Hong Kong Medical Diary assume no responsibility for any injury and/or damage to persons or property arising from any use of execution of any methods, treatments, therapy, operations, instructions, ideas contained in the printed articles. Because of rapid advances in medicine, independent verification of diagnoses, treatment method and drug dosage should be made.

The Cover Shot



A snap shot in the sky at a flight back from Europe. I was attracted by the pattern of cloud and the outstanding part that was red-colored by the setting sun. With a bit of imagination, that reminded me of Dore's illustration to Dante's 'Divine Comedy'.

H3D-31 HC-80mm, Program (f/3.2, 1/80 sec)



Dr. Edward HUI
MBBS(HK), BDS(HK),
MDS(HK), FDSRCS(Eng),
FRCD(C), FCDSHK(OMS),
FHKAM(DS)
*Specialist in Oral &
Maxillofacial Surgery*



Published by
The Federation of Medical Societies of Hong Kong

EDITOR-IN-CHIEF

Dr. MOK Chun-on
莫鎮安醫生

EDITORS

Prof. CHAN Chi-fung, Godfrey
陳志峰教授 (Paediatrics)
Dr. CHAN Chun-hon, Edmond
陳振漢醫生 (General Practice)
Dr. KING Wing-keung, Walter
金永強醫生 (Plastic Surgery)

EDITORIAL BOARD

Dr. CHAN Chi-kuen
陳志權醫生 (Gastroenterology & Hepatology)
Dr. CHAN Chi-wai, Angus
陳志偉醫生 (General Surgery)
Dr. CHAN Chun-kwong, Jane
陳真光醫生 (Respiratory Medicine)
Dr. CHAN Hau-ngai, Kingsley
陳厚毅醫生 (Dermatology & Venereology)
Dr. CHAN, Norman
陳諾醫生 (Diabetes, Endocrinology & Metabolism)
Dr. CHIANG Chung-seung
蔣忠想醫生 (Cardiology)
Prof. CHIM Chor-sang, James
詹楚生教授 (Haematology)
Dr. CHONG Lai-yin
莊禮賢醫生 (Dermatology & Venereology)
Dr. FAN Yiu-wah
范耀華醫生 (Neurosurgery)
Dr. FONG To-sang, Dawson
方道生醫生 (Neurosurgery)
Prof. HO Pak-leung
何栢良教授 (Microbiology)
Dr. KWOK Po-yin, Samuel
郭寶賢醫生 (General Surgery)
Dr. LAI Sik-to, Thomas
黎錫滔醫生 (Gastroenterology & Hepatology)
Dr. LAI Yuk-yau, Timothy
賴旭佑醫生 (Ophthalmology)
Dr. LAM Tat-chung, Paul
林達聰醫生 (Psychiatry)
Dr. LAM Wai-man, Wendy
林慧文醫生 (Radiology)
Dr. LEE Kin-man, Philip
李健民醫生 (Oral & Maxillofacial Surgery)
Dr. LEE Man-piu, Albert
李文彪醫生 (Dentistry)
Dr. LEUNG Kwok-yin
梁國賢醫生 (Obstetrics & Gynaecology)
Dr. LO See-kit, Raymond
勞思傑醫生 (Geriatric Medicine)
Dr. MAN Chi-wai
文志衛醫生 (Urology)
Dr. MOK, Mo-yin
莫慕賢醫生 (Rheumatology)
Dr. SIU Wing-tai
蕭永泰醫生 (General Surgery)
Dr. TSANG Wai-kay
曾偉基醫生 (Nephrology)
Prof. WEI I, William
韋霖教授 (Otorhinolaryngology)
Dr. WONG Bun-lap, Bernard
黃品立醫生 (Cardiology)
Dr. YU Chau-leung, Edwin
余秋良醫生 (Paediatrics)

Design and Production

A-PRO MULTIMEDIA LTD www.apro.com.hk

Editorial

Dr. Philip LEE

BDS(HK), MDS(HK), FRACDS, FFDRCSI,
FDSHK(Oral Maxillofacial Surgery),
FHKAM(Dental Surgery)

Director, Dental Implant and Maxillofacial Centre, Hong Kong

Editor



Dr. Philip LEE

In the aesthetic point of view, our chin projection, symmetry and balance of our jaw line are important landmarks affecting our outlooks. The mandible or the lower jaw can be considered the corner stone of our facial profile.

Functionally, underdevelopment of this piece of bone whether congenital or developmental not only can affect our speech and masticatory function, it also constitutes an important aetiological factor for obstructive sleep apnoea which is now found related to different systemic disorders.

Reconstruction of jaw defects as a result of resection of benign or malignant lesions of the jaw is still a challenge to surgeons who want to restore the patients' aesthetic appearance and functions.

In this issue, there are different articles related to this important piece of bone of our body, the mandible. I will discuss the treatment of a moderate case of obstructive sleep apnoea by repositioning of the jaws, (MaxilloMandibular Advancement). Dr. Winnie Choi will give us an update and latest advances in mandibular reconstruction. Dr. SK Chan will report on a case of maxillary reconstruction. Dr. James Chow will report a case of alveolar bone reconstruction with genetic recombinant bone morphogenic protein, to facilitate rehabilitation of a patient after traumatic injury.

Dr. Alfred Lau will report his interesting findings on public awareness of the speciality of Oral and Maxillofacial Surgery and it seems that our speciality needs to work harder for more public awareness.

I hope our readers will enjoy reading these academic articles and also share the joy of Marathon running with Dr. Ben Chow.



Current Concepts in Mandibular Reconstruction

Dr. Winnie WS CHOI¹

BDS (HK), MDS (OMS) (HK), MOS RCSEd, AdvDipOMS (HK), FCSDHK (OMS), FHKAM (Dental Surgery)

Dr. John LO¹

BDS (HK), MDS (OMS) (HK), MOS RCSEd, FCSDHK (OMS), FHKAM (Dental Surgery)

¹Clinical Assistant Professor in Oral & Maxillofacial Surgery
Faculty of Dentistry, the University of Hong Kong



Dr. Winnie WS CHOI

Dr. John LO

This article has been selected by the Editorial Board of the Hong Kong Medical Diary for participants in the CME programme of the Medical Council of Hong Kong (MCHK) to complete the following self-assessment questions in order to be awarded 1 CME credit under the programme upon returning the completed answer sheet to the Federation Secretariat on or before 30 November 2011.

Introduction

Mandibular reconstruction has been a challenge for surgeons over the past 50 years. The concepts and techniques have evolved significantly in order to achieve the best aesthetic and functional result individualised for the patients so that the quality of life is improved. The reconstruction may involve bone with or without soft tissue reconstruction. The objectives are (1) to restore mandibular continuity, (2) to achieve a symmetrical facial contour and (3) to allow prosthetic rehabilitation for mastication. There are two well established classifications of mandibular defects. The one described by Daniel R.¹ classified mandibular defects into (1) isolated bone (2) Compound (bone and oral lining or skin) (3) Composite (bone, oral lining and skin) and (4) extensive composite (bone, oral lining, skin and soft tissues). Jewer et al² classified mandibular defects according to the location: hemimandibular defect (H), central defect (C) and lateral defect (L). Different reconstructive options are available for different types of mandibular defects secondary to trauma, post ablative surgery for benign and malignant tumours, osteoradionecrosis, bisphosphonates related osteonecrosis of the jaws and congenital deformity.

Alloplastic Material

Reconstruction with alloplastic materials is often an option for selected patients who suffer from advanced malignant disease unfit for extended operation as a temporary treatment to provide contour and mechanical stability. It may be used in combination of a pedicled myocutaneous flap as coverage, such as pectoralis major, trapezius and latissimus dorsi flaps. Maurer and colleagues³ reported in a long term follow up that the success rate of mandibular reconstruction using reconstruction plate only to bridge the segmental defect was 58%. The failures were related to extraoral and / or intraoral exposure, loosened osteosynthesis screws and fractures of reconstruction plates. Postoperative radiotherapy and smoking habit were found to be related to the reduced success rate.

Non Vascularised Bone Graft

In the past decades, nonvascularised autogenous

bone grafting was commonly used in mandibular reconstruction. The common donor sites include anterior and posterior iliac crests, cranium, rib and tibia. The bone graft can be harvested as a bone block or as corticocancellous chips contained in a mesh or tray to be fixed to the mandible by titanium screws. However, some of these reconstructions especially large block grafts are suboptimal due to the inherent limitation on revascularisation and bone regeneration which are best at the resection margin and taper towards the centre of the graft⁴. This may lead to resorption with residual defect and compromises future implant rehabilitation. The bone healing is further compromised by perioperative radiation therapy and early graft exposure with saliva contamination. It has been suggested that this technique should be used in defect lengths less than 6cm⁵ and truly lateral defects using an extraoral approach only⁶.

Vascularised Free Flap

In the recent 30 years, vascularised free flap has become more popular in mandibular reconstruction and is often regarded as the most reliable, efficient and cost-effective technique for oromandibular reconstruction⁷. The most commonly used osteocutaneous free flaps are: fibular flap, deep circumflex iliac artery flap and scapular flap.

Fibular Flap

The fibular flap is probably the most popular free flap used in mandibular reconstruction because it has adequate pedicle calibre and length for anastomosis and bone length (~ 25cm) for total mandible reconstruction. The fibula bone can be segmentalised⁸, typically into 3 pieces, to resemble the contour of the mandible from angle to angle. The high flap survival rate, availability of skin paddle and minimal donor site morbidity also favour its use by reconstructive surgeons. However, there are two limitations: (1) The short bone height may influence the lower lip position and it also poses challenge in future implant rehabilitation especially if the remaining mandible is dentate. A double barrel technique has been advocated to solve this problem⁹⁻¹³. Other options such as using shorter implants to support long prosthesis, or performing distraction osteogenesis of the fibula bone to lengthen the height to reach the level of the remaining alveolus¹⁴⁻¹⁹. (2) Although the fibula can be harvested as an osteocutaneous flap²⁰, the

amount of soft tissues that can be transferred is limited and may contribute to donor site morbidity such as wound dehiscence and poor appearance of skin graft. Other common donor site morbidities include weakness of extension and flexion of the great toe²¹.

The Deep Circumflex Iliac Artery (DCIA) Flap

The DCIA flap is particularly useful in reconstruction of hemimandibular defects. The angle of the mandible can be created by the anterior superior iliac spine of the ipsilateral iliac bone. The iliac bone provides adequate bone height comparable to the alveolar height of a dentate mandible making future implant rehabilitation more favourable. If soft tissue reconstruction is needed, the internal oblique muscle can be harvested based on the ascending branch of DCIA. The disadvantages of DCIA flap are relatively short pedicle length compared to fibular flap and bulky skin paddle. Donor site morbidities are also more common such as postoperative pain, gait disturbance, injury to the lateral femoral cutaneous nerve and hernia formation when the internal oblique muscle is harvested²¹.

The Scapular Flap

The scapular flap allows great flexibility in three-dimensional reconstruction due to independent vascular pedicles of the skin paddle, muscle and bone flap based on the branches of the subscapular artery. Although the bone length, quality and shape may be inferior to the fibular and DCIA flaps, the scapular flap has the potential for mass tissue transfers. With proper selection of the donor tissue, the flap thickness can be easily controlled. The skin is predominantly hairless and has a better colour match to the face compared to fibular and DCIA flaps. The drawback of the scapular flap, apart from the limited bone volume, is the inconvenience during the harvest which requires prone or lateral decubitus position and thus does not allow two team operation.

Computer Assisted Surgery

Mandibular reconstruction remains to be a great challenge to reconstructive surgeons. Owing to the anatomical difference, precise reconstruction usually demands segmentalisation of the free vascularised bone graft. Accurate 3-dimensional placement of the graft is always essential to restore the pre-disease contour, and functions in terms of speech and chewing. Traditionally this procedure is time-consuming even for experienced surgeons. With the increased popularity in computer tomography and the improved computer technology, clinicians are allowed to (i) visualise the disease using multi-planar reformat CT images, and (ii) perform pre-surgical planning on three-dimensional model (3D model) using CT data. The simulation can be performed either in the laboratory or with a computer.

1.Laboratory-based treatment planning

Stereolithographic model has been a useful tool in mandibular reconstructive surgeries to achieve good facial contour and occlusal relationship after surgery²². It is first fabricated from CT data using rapid prototyping machine. The surgical planning, from the bone resection, bone graft harvest and segmentalisation, till the final graft placement, can all be simulated on this model. The final reconstructed model serves a good platform for (i) pre-bending the fixation plate, and (ii) the fabrication of

the surgical templates.

2.Virtual computer planning

Nowadays, there are some user-friendly computer softwares which allow surgical planning in a virtual environment. Compared to the laboratory based planning, the planning is usually simpler as the position of the reconstructed bone can be easily adjusted based on mirroring of the non-disease side of the mandible. The surgical plan will usually be exported for fabrication of (i) surgical templates and (ii) stereolithographic model for pre-bending of the fixation plates. This further saves laboratory time and manpower.

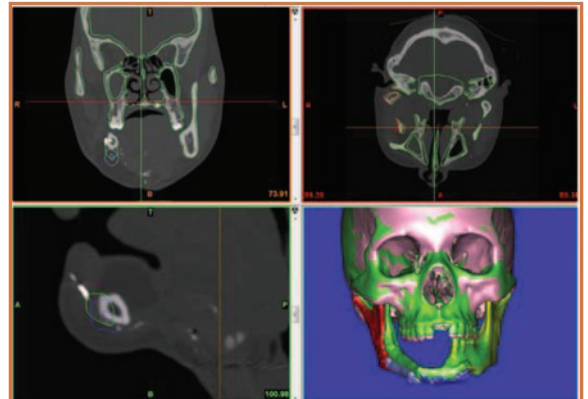


Figure 1. Discrepancy between the laboratory model (green colour) and the computer model (in red, blue, pink and yellow colours) planning using mirroring in a patient for secondary reconstruction using the fibula graft. Laboratory planning was made on a stereomodel by an experienced technician while the computer planning was made based mainly on mirroring the unaffected side of the mandible. After the plan was accepted by the surgeon, the stereomodel would be sent for CT scan. The CT data would be used to fuse with the computer planning data.

Surgical Navigation

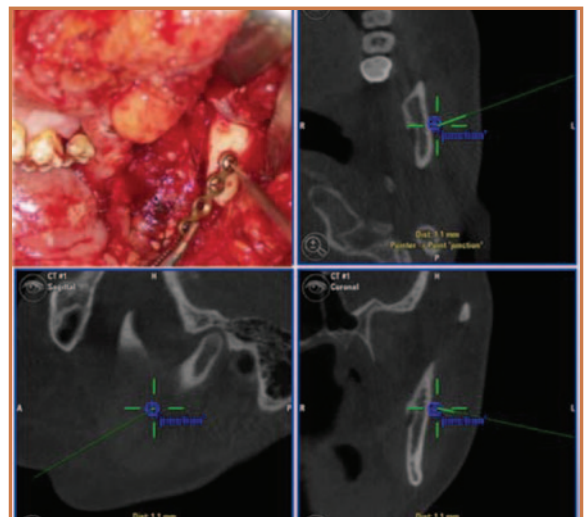


Figure 2. Use of surgical navigation to check the condyle position with reference to the surgical plan using the pre-determined reference point.

Apart from using surgical templates, execution of the surgical plan can be assisted by surgical navigation,



which is similar to a global positioning system (GPS). With the attachments of sensors on the patient's skull, the spatial position of the patient and the calibrated surgical instruments can be tracked by the navigation system. Following mapping of the virtual patient (surgical plan based on CT data) to the actual patient, surgical navigation allows the surgeon to check and control the position of the reconstructed bone with reference to the surgical plan, which was shown on the screen as "the map in GPS" (Figure 2).

Future Development

Tissue Engineering

Although vascularised free flap transfer has become the standard of care in mandibular reconstruction, the major disadvantage of this approach is the donor site morbidity. The use of alloplastic materials is also associated with complications such as exposure and infection. The field of tissue engineering may become one of the solutions in mandibular reconstruction. There are techniques developed to culture cell substrates and transfer them, with or without scaffolds, to regenerate part of the mandible. The use of recombinant bone morphogenetic protein (rhBM-2) and stem cells are being explored in bone regeneration. These techniques are currently undergoing further investigation and evaluation.

Medical Imaging

With the good success rate in vascularised flap reconstructions, our next milestone will be on good soft tissue planning. Current worldwide computer-aided mandibular reconstruction techniques are mainly based on CT hard tissue imaging only. Despite an improved speed in scanning, radiation exposure is considered as a potential hazard. MRI can be considered as a non-invasive alternative for both bone and soft tissue imaging nowadays. The feasibility of using MRI in 3D bone reconstruction had been reported since 2003 using special algorithm²³. Compared with CT scan and ultrasound, MRI can offer a better resolution in head and neck soft tissue imaging. Combination with angiogram could aid us in identification of vascularised flap donor site and recipient sites' vascular network. In situation of secondary reconstruction in patients with previous radiation therapy, this could allow a better pre-surgical estimation.

Computer Planning

While there are numerous commercial software available for surgical planning, the majority of them are considered as closed systems in which the planning file format is locked and can only be opened by their own software providers' rapid prototyping machine. As a result, a surgical template can only be fabricated by those commercial companies. It is not uncommon for those surgical templates' manufacturers located far away from local city; hence a period of time (ranged from 1-3 weeks) is required for the splint to be ready in the surgeon's hands. With the recent increase in popularity in computer design and manufacturing technology, it is generally recommended that those software also allow export of the surgical plan as an open file format which can be used by general rapid prototyping software for local preparation of surgical template with better customisation. In complex situations when combination of surgical template and

navigation could offer a better accuracy, direct linkage of virtual planning with the navigation system via an open export file format could further lessen the workload during the pre-surgical planning.

Virtual Bone Library

While current virtual computer planning is generally based on mirroring of the non-disease side as reference, reconstruction planning in situations with significant tissue loss involving both sides of the face is always challenging due to lack of references. Thanks to the relative long history of CT imaging, there should have a huge number of CT scans available comprising a wide range of hard tissue skull models of different gender and age. The concept of "virtual bone library" had appeared in a few centres in which virtual jaw bone data from one patient database will be exported for aiding the planning in another patient with no good skeletal reference for mirroring. It is generally believed that our virtual bone library could be collected and organised following simple skeletal anthropometry analysis. This virtual database can serve as a good source for local surgeons during planning in patients suffering from advanced tissue loss due to tumour or trauma.

References

- David, D.J., et al., Mandibular reconstruction with vascularized iliac crest: a 10-year experience. *Plast Reconstr Surg*, 1988. 82(5): p. 792-803.
- Jewer, D.D., et al., Orofacial and mandibular reconstruction with the iliac crest free flap: a review of 60 cases and a new method of classification. *Plast Reconstr Surg*, 1989. 84(3): p. 391-403; discussion 404-5.
- Maurer, P., et al., Scope and limitations of methods of mandibular reconstruction: a long-term follow-up. *The British journal of oral & maxillofacial surgery*, 2010. 48(2): p. 100-4.
- Marx, R.E., Bone and bone graft healing. *Oral and maxillofacial surgery clinics of North America*, 2007. 19(4): p. 455-66, v.
- Pogrel, M.A., et al., A comparison of vascularized and nonvascularized bone grafts for reconstruction of mandibular continuity defects. *Journal of oral and maxillofacial surgery : official journal of the American Association of Oral and Maxillofacial Surgeons*, 1997. 55(11): p. 1200-6.
- van Gemert, J.T., et al., Nonvascularized bone grafts for segmental reconstruction of the mandible—a reappraisal. *Journal of oral and maxillofacial surgery : official journal of the American Association of Oral and Maxillofacial Surgeons*, 2009. 67(7): p. 1446-52.
- Wang, K.H., J.C. Inman, and R.E. Hayden, Modern concepts in mandibular reconstruction in oral and oropharyngeal cancer. *Curr Opin Otolaryngol Head Neck Surg*, 2011. 19(2): p. 119-24.
- Hidalgo, D.A., Fibula free flap: a new method of mandible reconstruction. *Plast Reconstr Surg*, 1989. 84(1): p. 71-9.
- Shen, Y., et al., Long-Term Results of Partial Double-Barrel Vascularized Fibula Graft in Symphysis for Extensive Mandibular Reconstruction. *Journal of oral and maxillofacial surgery : official journal of the American Association of Oral and Maxillofacial Surgeons*, 2011.
- He, Y., et al., Double-Barrel Fibula Vascularized Free Flap With Dental Rehabilitation for Mandibular Reconstruction. *Journal of oral and maxillofacial surgery : official journal of the American Association of Oral and Maxillofacial Surgeons*, 2011.
- Chang, Y.M., C.Y. Tsai, and F.C. Wei, One-stage, double-barrel fibula osteoseptocutaneous flap and immediate dental implants for functional and aesthetic reconstruction of segmental mandibular defects. *Plast Reconstr Surg*, 2008. 122(1): p. 143-5.
- Bahr, W., P. Stoll, and R. Wächter, Use of the "double barrel" free vascularized fibula in mandibular reconstruction. *Journal of oral and maxillofacial surgery : official journal of the American Association of Oral and Maxillofacial Surgeons*, 1998. 56(1): p. 38-44.
- Horiuchi, K., et al., Mandibular reconstruction using the double barrel fibular graft. *Microsurgery*, 1995. 16(7): p. 450-4.
- Siciliano, S., B. Lengele, and H. Revchler, Distraction osteogenesis of a fibula free flap used for mandibular reconstruction: preliminary report. *Journal of cranio-maxillo-facial surgery : official publication of the European Association for Cranio-Maxillo-Facial Surgery*, 1998. 26(6): p. 386-90.
- Nocini, P.F., et al., Vertical distraction of a free vascularized fibula flap in a reconstructed hemimandible: case report. *Journal of cranio-maxillo-facial surgery : official publication of the European Association for Cranio-Maxillo-Facial Surgery*, 2000. 28(1): p. 20-4.
- Levin, L., et al., Enhancement of the fibula free flap by alveolar distraction for dental implant restoration: report of a case. *Facial Plast Surg*, 2003. 19(1): p. 87-94.
- Ortakoglu, K., et al., Vertical distraction osteogenesis of fibula transplant for mandibular reconstruction: a case report. *Oral Surg Oral Med Oral Pathol Oral Radiol Endod*, 2006. 102(4): p. e8-11.



18. Schleier, P, et al., Vertical distraction of fibula transplant in a case of mandibular defect caused by shotgun injury. *Int J Oral Maxillofac Surg*, 2006. 35(9): p. 861-4.

19. Cho-Lee, C.Y., et al., Vertical distraction osteogenesis of a free vascularized fibula flap in a reconstructed hemimandible for mandibular reconstruction and optimization of the implant prosthetic rehabilitation. Report of a case. *Med Oral Patol Oral Cir Bucal*, 2011. 16(1): p. e74-8.

20. Wei, F.C., et al., Fibular osteoseptocutaneous flap: anatomic study and clinical application. *Plast Reconstr Surg*, 1986. 78(2): p. 191-200.

21. Mahoney, J., Complications of free flap donor sites. *Microsurgery*, 1995. 16(7): p. 437-44.

22. Yeung, R.W., et al., Stereomodel-assisted fibula flap harvest and mandibular reconstruction. *Journal of oral and maxillofacial surgery : official journal of the American Association of Oral and Maxillofacial Surgeons*, 2007. 65(6): p. 1128-34.

23. Dullin, C et al. 3D-Reconstruction of Bone Structures From Multi-Spectral MRI Data Sets. *Proc. Intl. Soc. Mag. Reson. Med.* 2003. 11: p. 935

MCHK CME Programme Self-assessment Questions

Please read the article entitled "Current Concepts in Mandibular Reconstruction" by Dr. Winnie WS CHOI and Dr. John LO and complete the following self-assessment questions. Participants in the MCHK CME Programme will be awarded CME credit under the Programme for returning completed answer sheets via fax (2865 0345) or by mail to the Federation Secretariat on or before 30 November 2011. Answers to questions will be provided in the next issue of The Hong Kong Medical Diary.

Questions 1-10: Please answer T (true) or F (false)

- The success rate of mandibular reconstruction using alloplastic materials is over 70%.
- Non vascularised graft is the best option for hemimandibular reconstruction in young fit patients.
- Vascularised free flaps are considered to be the most reliable, efficient and cost-effective technique for oromandibular reconstruction.
- Fibular flaps can be used for total mandibular reconstruction.
- The advantage of using the fibular flap over the DCIA flap in mandibular reconstruction is the adequate bone height for future implant rehabilitation especially in dentate patients.
- The scapular flap has the potential for three dimensional reconstruction because it has independent vascular pedicles of the skin paddle, muscle and bone flap.
- Clinicians can visualise the disease using multi-planar reformat CT images, and perform pre-surgical planning on three-dimensional model (3D model) using CT data.
- Preoperative surgical planning using stereolithographic model allows prebending of fixation plates and fabrication of surgical templates in the laboratory which can save some surgical time.
- During the surgical planning using computer software, the graft position is determined by the surgeon based on experience.
- Surgical navigation in mandibular reconstruction allows real time adjustment of the graft position with reference to the computer plan and patient's CT image.

ANSWER SHEET FOR NOVEMBER 2011

Please return the completed answer sheet to the Federation Secretariat on or before 30 November 2011 for documentation. 1 CME point will be awarded for answering the MCHK CME programme (for non-specialists) self-assessment questions.

Current Concepts in Mandibular Reconstruction

Dr. Winnie WS CHOI¹

BDS (HK), MDS (OMS) (HK), MOS RCSEd, AdvDipOMS (HK), FCSDHK (OMS), FHKAM (Dental Surgery)

Dr. John LO¹

BDS (HK), MDS (OMS) (HK), MOS RCSEd, FCSDHK (OMS), FHKAM (Dental Surgery)

¹Clinical Assistant Professor in Oral & Maxillofacial Surgery
Faculty of Dentistry, the University of Hong Kong

1 2 3 4 5 6 7 8 9 10

Name (block letters): _____ HKMA No.: _____ CDSHK No.: _____

HKID No.: __ - __ - __ - __ X X (X) HKDU No.: _____ HKAM No.: _____

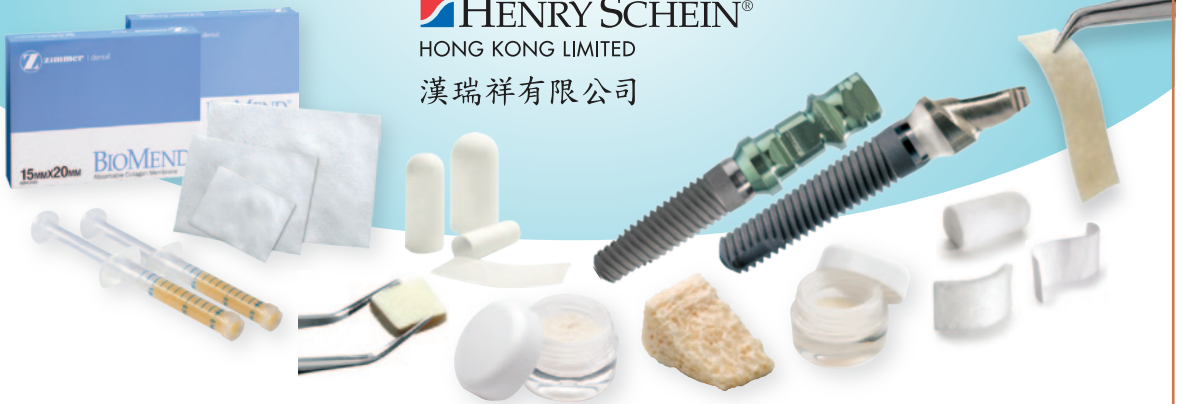Contact Tel No.: _____

Answers to October 2011 Issue

An Update on HPV Vaccine

1. **F** 2. **T** 3. **T** 4. **F** 5. **T** 6. **F** 7. **F** 8. **F** 9. **F** 10. **T**

HENRY SCHEIN®
 HONG KONG LIMITED
 漢瑞祥有限公司



Everything Dental.™

HENRY SCHEIN®

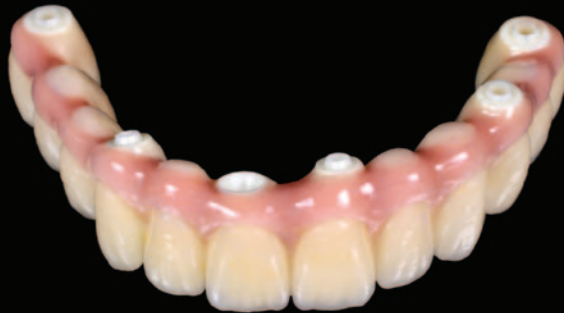Authorized distributor for



MODERN
 Dental Laboratory

www.moderndentallab.com

+852 2305 2084



.....creating beautiful smiles around the world


Hong Kong · Shenzhen · Chicago · Seattle · Los Angeles · Boston

Do You Think They Know about Us? Oral and Maxillofacial Surgery in Hong Kong

Dr. Alfred SL LAU

BDS(HK), MDS(HK)(OMS), AdvDipOMS(HK), MOSRCS(Edin), FHKAM, FCDSHK(OMS)

Consultant, Branemark Osseointegration Centre, Hong Kong



Dr. Alfred SL LAU

Introduction

People nowadays are more conscious about healthcare related issues as reflected by the blooming of a lot of commercials on televisions, signboards and magazines. More and more doctors were being interviewed through these media, as there is a great demand for the public to know more about their health. Dentistry is a little bit slow in this area, due to their relative conservativeness over publicity and advertisements. Despite the tremendous increase in public awareness regarding personal health, the specialty of oral and maxillofacial surgery (OMFS) is still unknown to many. OMFS receives referrals from both dental and medical specialties as well as emergency department. It acts as a bridge to a lot of different fields across the dental and medical borders. However, it has been reported that there was a low awareness of this field to both the general public and professionals in other countries¹⁻⁴. Hong Kong Chinese are thought to be unexceptional. The reasons may be due to the traditional thinking that oral health is not as important, and people will not seek help until symptoms affect their daily life to an unbearable extent.

This is the first survey to analyse the public awareness regarding the specialty of OMFS in Hong Kong. It aims to point out the situation and arouse the responsible bodies' action accordingly. Their objectives should be aimed at promoting the specialty to the public, to help fully unitising the services available, and to encourage more people to take the opportunity to be trained, in turn more people can become part of our team.

Methodology

Questionnaires were sent out through personal network by helpers recruited. These questionnaires were distributed to Hong Kong citizens aged 18 years or above. The subjects, who should not be any dental or medical related personnel, were interview individually by helpers.

The questionnaires were made up of three parts, including 12 simple questions. Personal demographic data were recorded in the first part. Second part included general questions about OMFS including the scope of services and training particulars. The final part was designed to test the knowledge of the interviewees, whether they could correlate some specific diseases or conditions that could be treated by oral and maxillofacial (OMF) surgeons.

Results

There were 150 questionnaires distributed to 20 helpers in June 2011, where 104 were completed through personal interviews to non-dentally and non-medically related Hong Kong citizens. There were 59 (57%) females and 45 males (43%). The mean age was 32 year-old, ranging from 18 to 65 year-old.

Among the 104 interviewees, there were 78 who (75%) claimed they had never heard of the specialty of OMFS, while the other 26 (25%) reported that they had heard of it. Within the 26 people who heard of OMFS, 14 (54%) said that they did not actually know what OMFS was about, while the other 12 (46%) claimed that they had knowledge about OMFS to a certain extent (fig. 1). They were asked on how they had known about OMFS. There were five ways reported, including from friends/ family members (65%), newspaper/ magazine (15%), television (12%), radio (4%) and medical/ healthcare related magazine (4%) respectively.

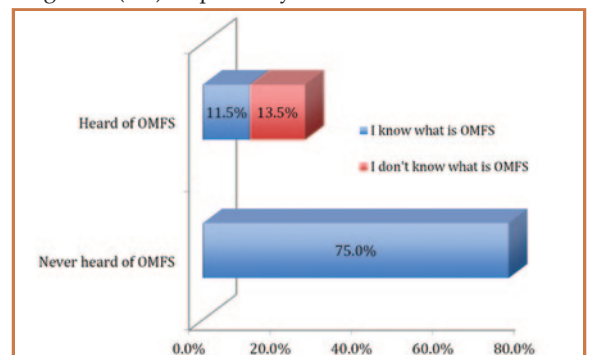


Figure 1: Have you ever heard of OMFS?

Five questions were asked regarding the training and services of OMFS available in Hong Kong. There were different thoughts regarding the stream of field that OMFS belonged to (fig. 2). A majority (44%) knew that OMFS belonged to the field of dentistry while 39% thought that it belonged to medicine. There were 33 interviewees (32%) who had a correct idea of the fact that there were around 50 OMFS specialists in Hong Kong. The rest had overestimated the amount of OMFS specialists in which 34 (33%) thought that there were around 150, 21 (20%) said that there were around 250 and 16(15%) thought that there were around 350 (fig. 3). Regarding the training pathway, only 8 (7.8%) had correctly pointed out that there was a minimum of six years training after the primary degree. Most of



the people had underestimated the training period, in which 83.6 % thought it required less than six years of training. Only 3.8% thought that it required more than six years, where the rest of the people (4.8%) claimed that they did not know. The University of Hong Kong is the only tertiary institute which provides the training of OMFS specialists. There were 69% of interviewees who were correct about this, where 16 % thought that other universities provide it and 18% said they did not know. Regarding service provision in the field of OMFS by the government sector, 38 (37%) knew that was available, while 21 (20%) did not. A majority (43%) was uncertain about this.

surgeries (15.5%), followed by intra-oral surgeries (15%). The results are summarised in figure 4. Multiple choices are given to interviewees on where they would refer themselves to if they were diagnosed to have a certain disease or condition. Choices included OMF surgeons; ear, throat and nose (ENT) surgeons; general surgeons; head and neck surgeons and plastic surgeons. The answers are summarised in table 1.

Table 1. Public perception of some disease / condition which should be treated by different specialties

	Oral and Maxillofacial Surgeons		ENT Surgeons		General Surgeons		Head and Neck Surgeons		Plastic Surgeons		Don't Know	
	N	%	N	%	N	%	N	%	N	%	N	%
Oral Ulceration	62	59.6%	13	12.5%	29	27.9%	0	0.0%	0	0.0%	0	0.0%
Oral Malignancy	65	62.5%	17	16.3%	18	17.3%	3	2.9%	1	1.0%	0	0.0%
Tongue Tumour	50	48.1%	28	26.9%	17	16.3%	5	4.8%	3	2.9%	1	1.0%
TMJ Disorder	48	46.2%	4	3.8%	16	15.4%	28	26.9%	8	7.7%	0	0.0%
Jaw Fracture	31	29.8%	0	0.0%	15	14.4%	35	33.7%	29	27.9%	4	3.8%
Salivary Gland Pathology	48	46.2%	26	25.0%	18	17.3%	8	7.7%	4	3.8%	0	0.0%
Dental Implant	78	75.0%	2	1.9%	9	8.7%	3	2.9%	10	9.6%	2	1.9%
Cleft Lip and Palate Repair	30	28.8%	1	1.0%	3	2.9%	13	12.5%	57	54.8%	0	0.0%
Jaw Tumour	27	26.0%	8	7.7%	14	13.5%	44	42.3%	10	9.6%	1	1.0%
Facial Swelling	23	22.1%	4	3.8%	40	38.5%	12	11.5%	15	14.4%	10	9.6%
Dentofacial Deformity	11	10.6%	0	0.0%	1	1.0%	4	3.8%	87	83.7%	1	1.0%

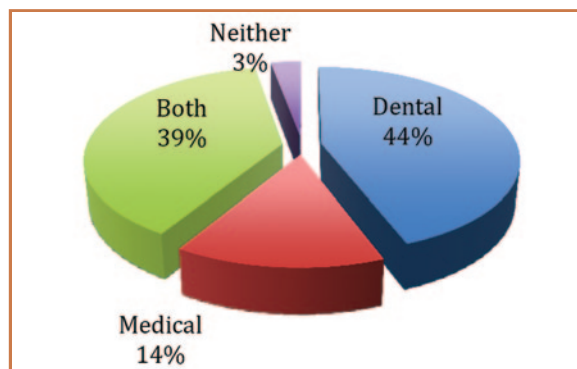


Figure 2: Which stream do you think OMFS belongs to?

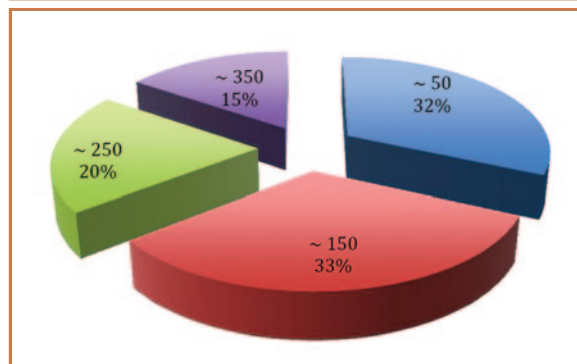


Figure 3: How many Specialists in OMFS do you think there are in Hong Kong?

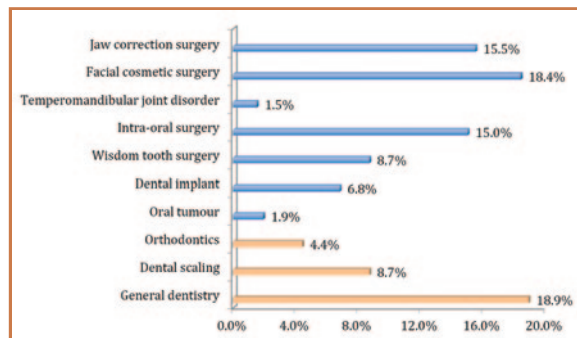


Figure 4: Can you name what the OMF surgeons do?

There were about one third (32%) of answers wrongly named the scope of services within OMFS. These included general dentistry (18.9%), dental scaling (8.7%) and orthodontics (4.4%). Among the correct answers, most of the people knew that OMFS specialists did facial cosmetic surgeries (18.4%) and jaw correction

Discussions

Although OMFS is a branch of dentistry, it is the only specialty that bridges to the medical community so closely. It is not compulsory in Hong Kong for OMFS specialists to obtain a medical degree, but in some other countries it is a must. Current trend shows that a full medical degree is not that necessary for OMFS specialists to practise with competency. Some of the European countries are trying to trim down the training pathway especially in the medical course, trying to incorporate the essential medical part into an integrated OMFS training curriculum, so that one should no longer take another full medical training. OMFS specialists are qualified to treat not only dento-alveolar surgeries, but also a full scope of jaws and facial surgeries including facial fractures, congenital facial deformities, temporomandibular joint (TMJ) disorders, pathologies related to the jaws, salivary gland diseases, facial reconstructions with extra-oral bone or soft tissue harvesting. With adequate training or, in some situations, collaborating with other specialties, the scope could be expanded to cranio-facial reconstructions, oncology and reconstructions using local or distant microvascular free flaps. Although the specialty is involved in the treatment of a lot of important conditions or diseases, it is disappointing to see the lack of awareness from the general public. It was reported that there were only 11.5 % who had heard of and knew what OMFS was.

OMFS was introduced to a majority of people (65%) by a friend or a family member. This indicates that most of the knowledge was by personal experiences of people around. There was almost no public image about this specialty. The government or tertiary institute could publicise this field by media like TV, radios or newspapers through interviews or in terms of case study. The local association should also take a



leading role to arouse the public's awareness regarding our specialty, either by organising public talks or distributing leaflets / booklets / magazines regularly.

There are 83% of interviewees who had answered correctly that OMFS belongs to the field dentistry or both dentistry and medicine. It is not surprising as the name OMFS itself indicated that is something about the oral cavity, thus dentistry. There are 51 registered OMFS specialists currently in Hong Kong⁵. When compared to other medical specialties, we have relatively few colleagues. Only 32% of the interviewees had the correct impression about the amount of specialists available in Hong Kong while the rest had overestimated the amount with 15% said that there were around 350. The small amount of registered specialists may explain in part the relative low public awareness.

Regarding the scope of services in OMFS, around one third of people misunderstood what we did (fig. 4). Although the others could name some of the treatments that we provided, a lot were unknown to them. Most of the people had stated we provided facial cosmetic surgeries (18.4%), jaw correction surgeries (15.5%) and intra-oral surgeries (15%). This may not truly reflect the knowledge about the scope in OMFS. Oral and maxillofacial surgery itself is self-explanatory. May be the interviewees were just guessing the answer.

Table 1 summarised some conditions / diseases which could be treated by different specialties. In fact OMFS surgeons could treat all of the listed conditions. Although there are overlapping responsibilities over some specialties, there are never absolute right or wrong on who should do what. It all depends on the training they have received and the culture in different places. The results indicate only on how the general public thought when they came across these diseases. A majority (59.6%) thought that OMF surgeons should treat oral ulceration over other specialties. Moreover, it was reported similarly that, most of the people thought an OMF surgeon should treat oral malignancy (62.5%) and tongue tumour (48.1%). In my personal experience, most of these cases would go to either ENT surgeons or head and neck surgeons. In real life, it depends a lot on who was referring the cases. A dental practitioner would mostly refer these cases to OMF surgeons, while a medical practitioner would do it differently. This may be the explanation on the reported high percentage of seeking OMF surgeons over these cases while in the real life it is not the truth. The reason lies on the amount of medical practitioners are far more than dental practitioners in Hong Kong.

TMJ disorder is rather a vague area for both practitioners and patients. The reason of this is the fact that these joints involve a lot of different structures and usually the symptom is indistinct in terms of location and soreness. Most of the patients came in with a history of seeking different doctors already without treating the problems, however most of the patients (46.2%) would prefer an OMF surgeon. Jaw fractures are a unique condition for OMF surgeons, as it involves most of the time teeth and occlusion. However head and neck surgeons ranked first (33.7%) in patients' minds, followed by OMF surgeons (29.8%) and plastic surgeons (27.9%). Jaw tumour is a similar entity, as

it involves surgery and reconstruction of the jaw. As such, the pattern was reported similarly that head and neck surgeons ranked first (42.3%), followed by OMF surgeon (26%).

Dental implant is absolutely a scope of OMF surgeons within the list. Very interestingly, around 10 % of people felt that plastic surgeons would do that. Probably, most of the time, it involves a cosmetic concern, especially at the anterior esthetic zone of the dentition. Cleft lip and palate repair surgeries involve mostly plastic surgeons as well as OMF surgeons. The results showed that 54.8% thought the plastic surgeons should be responsible for this while 28.8% thought of OMF surgeons. Dentofacial deformity involves the facial cosmetic as well as functional problem of patients. Treatment includes orthodontics before the jaw could be moved surgically to a better position. To achieve an ideal occlusion is one of the most important objectives in the treatment of these situations. Although not as obvious as dental implant, orthognathic surgery is again one of the most unique surgeries that OMF surgeons do. Results showed that over 80% of people would seek plastic surgeons for this kind of treatment, while only around 10% would seek OMF surgeons. Although some plastic surgeons would do this kind of surgery, still this is a main area in OMFS. This again reflects the poor awareness of OMFS among the general public. Lastly, facial swellings may indicate a lot of different problems, as it can originate from anywhere around the face, jaws, teeth, ears, sinus, eyes, etc. Around 10 % of people did not know who to seek help from, and this was the condition that confused patients the most. These results indicated a lot of people were actually unaware of what OMFS specialists could help them if they got a relevant disease. Even it was within the scope of OMFS, they would prefer other specialties more.

The training pathway of OMFS specialists include a minimum of six years supervised training in recognised training centres. It comprises of three years of basic training after the dental degree, followed by another three years of advanced training. There is an intermediate examination in between and an exit examination on finishing all the training. The College of Dental Surgeons of Hong Kong is the responsible body of specialist training in Hong Kong, and it is under the umbrella of the Hong Kong Academy of Medicine. The specialist training pathway is in a sense similar to other medical specialties. The results indicate most of the general public (83.6%) has underestimated the training requirement in terms of time. This reflects either they have a general lack of knowledge on how specialists are being trained in Hong Kong or they have underestimated on the scope of services we can provide, as reflected in the latter part of the results. The University of Hong Kong is the only tertiary institute which provides such training, as there is only one dental school in Hong Kong. 69% were correct about this. There are also recognised training centres from the government sector, but it is of a minority. The government sector does provide public service in OMFS. Either it could be a referral from private practitioners or the public can go to queue up in a government outpatient unit before they are being referred. Only 37% reported they had knowledge about this.



This shows the lack of knowledge from the general public, regarding the training opportunity and the provision of service by government sector. Lack of awareness will in turn reduce the amount of people who can enjoy the service, or reduce the chance of being trained. The government and the university should think over again in how to fully unite the resources being input, or else it will be a waste of effort. This lack of awareness affects the dynamic of the whole system, not only to the patients or to the public, but also to the doctors who provide the treatment, the trainers who train residents and all the personnel who are being involved.

In summary, there is a very low awareness in OMFS to the general public in terms of its scope of services, the provision of service and training by the government and institutes. It is very discouraging to learn that most people do not really know us as they may miss the chance to be treated or to be trained. There is no doubt that the specialty deserves a better public awareness. The stress should be put on three areas, namely the public image of who we are, awareness of the treatment we could provide, the awareness of the details of training pathways and opportunities. The objectives are to let more people know who they should seek help from and provide open opportunities for people to be trained.

References

1. Ameerally P, Fordyce AM, Martin IC: SO you think they know what we do? The public and professional perception of oral and maxillofacial surgery. Br J Oral Maxillofac Surg 32:142, 1994
2. Hunter MJ, Rubeiz T, Rose L: Recognition of the scope or oral and maxillofacial surgery by the public and health care professionals. J Oral Maxillofac Surg 54:1227, 1996
3. Sonna N, Ifeacho G, Malhi K, James G: Perception by the public and medical profession or oral and maxillofacial surgery – Has it changed after 10 years? Br J Oral Maxillofac Surg 43:289, 2005
4. Subhashraj K, Subramaniam B. Awareness of the specialty of oral and maxillofacial surgery among health care professional in Pondicherry, India. J Oral Maxillofac Surg. 11:66, 2008
5. Hong Kong Dental Council Webpage. http://www.dchk.org.hk/docs/SB_Oral_and_Maxillofacial_Surgery.pdf

made in Germany

CAD/CAM SYSTEMS INSTRUMENTS HYGIENE SYSTEMS TREATMENT CENTERS IMAGING SYSTEMS

Sirona Hong Kong, now here to serve you!

Sirona Dental System (HK) Ltd.
Office Address: 6/F, Luk Kwok Centre, 72 Gloucester Road, Wan Chai, Hong Kong
Contact: Pei Hsu
Mobile: +852 9260-2511
Office: +852 3127-5659
E-mail: pei.hsu@sirona.hk

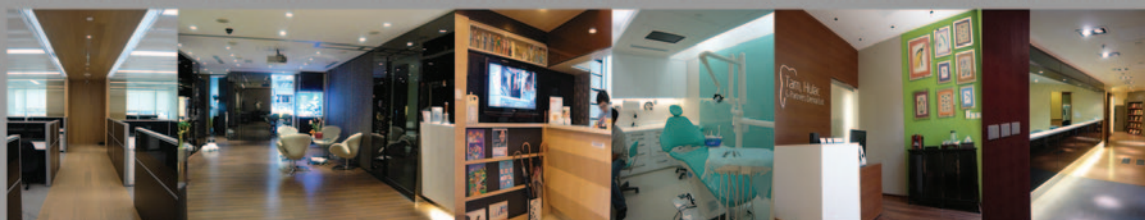High quality products imported from Germany with after sales guarantee by Sirona.

The Dental Company **sirona**

INTERIOR DESIGN - PROJECT MANAGEMENT - CONTRACTING - CONSULTATION



DENTAL CLINIC - RESIDENTIAL - RETAILS - COMMERCIAL OFFICE - BEAUTY CENTRE - MEDICAL CENTRE



HALLWICKS CONSULTANTS LIMITED
康偉顧問有限公司

BEIJING - SHANGHAI - SHENZHEN - NINGBO - XIAMEN - HONG KONG
T 3102 0821 F 3186 2376 E HALLWICKS@GMAIL.COM
WWW.HALLWICKS.COM

Mandible Repositioning in the Management of Obstructive Sleep Apnoea

Dr. Philip LEE

BDS(HK), MDS(HK), FRACDS, FFDRCSI, FDSHK(Oral Maxillofacial Surgery), FHKAM(Dental Surgery)
Director, Dental Implant and Maxillofacial Centre, Hong Kong



Dr. Philip LEE

Obstructive sleep apnoea (OSA) is the most common type of sleep apnoea and is caused by obstruction of the upper airway during sleep. It is believed that over 20% of the population may be suffering from the disorder.¹ Obstructive sleep apnoea is characterised by repetitive episodes of cessation of breathing during sleep despite there is an effort for breathing. There are associated episodes of decrease in blood oxygen saturation.²

OSA is now recognised to be associated with different medical conditions,^{3,4} which include:

1. coronary artery disease
2. hypertension
3. stroke
4. cardiac arrhythmia
5. glaucoma

The symptoms of OSA include loud snoring, excessive daytime sleepiness, headache in the morning, loss of concentration and focus during work.

The dimension of our airway decreases with age due to sagging of soft tissue around the airway and the chance of developing OSA increases with age. Risk factors in OSA include overweighted males with increased body mass in torso and neck typically middle age or older; a receded lower jaw; and alcohol consumption and medications like sedatives and muscle relaxants.

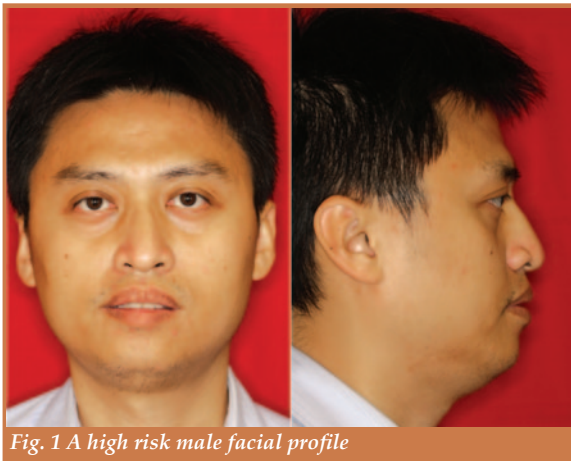

Fig. 1 A high risk male facial profile

Fig. 1 shows a typical facial profile of a middle age man with receded chin and sagging of soft tissue around the neck.

The patient presented with symptoms is investigated with a sleep study or polysomnography in which a comprehensive recording of the biophysiological changes that occur during sleep. These parameters include EEG, EOG, EMG, ECG, and oxygen saturation. The diagnosis of OSA is established with the use of AHI (apnoea and hypopnoea index) and RDI (Respiratory Disturbance Index).

The obstruction of the upper airway can happen at different levels. Commonly seen is a deviated nasal septum, a hypertrophic turbinate, a long and floppy uvula; and obstruction at the base of tongue and the glossohyaryngeal level.

Treatment of OSA

There are non-surgical means and surgical means in the management of OSA patients. Treatment should be customised and combination of surgery and non-surgical means might be necessary for individual patients.

CPAP or Continuous Positive Airway Pressure therapy is the most common treatment prescribed for patients with moderate to severe OSA. The patient wears a mask and the machine continuously ventilates the patient with positive air pressure to open up the airway. The therapy is effective but depends very much on patient compliance and tolerance of the machine during sleep.^{5,6}

Dental appliance is another commonly used non-surgical means to treat OSA patients with obstruction at the base of the tongue level. The appliance repositions the mandibular teeth in a protruded position and pulls the hyoid attachment forward to prevent collapse of the tongue during sleep. It seems to be effective and less sleep disturbing to patients with mild to moderate OSA compared with CPAP machines. It is contraindicated in patients with periodontal disease, loose teeth and temporomandibular joint disorder.⁷

Role of Maxillofacial Surgery in the Management of OSA

Forward repositioning of the mandible is an effective way of opening up the collapsed airway at the base of the tongue.



There are two main orthognathic procedures that are used to achieve this goal, namely genioplasty advancement and Maxillo-Mandibular Advancement (MMA).^{8,9}

Genioplasty Advancement¹⁰

The aim of the surgery is to pull the base of the tongue and the hyoid attachment forward by forward positioning of the osteotomised chin segment.

Location of the genio-tubercle is checked with Cone Beam CT. Simulated osteotomy is performed on stereo-model (Fig. 2). Mini-plate can be pre-bended with model surgery.

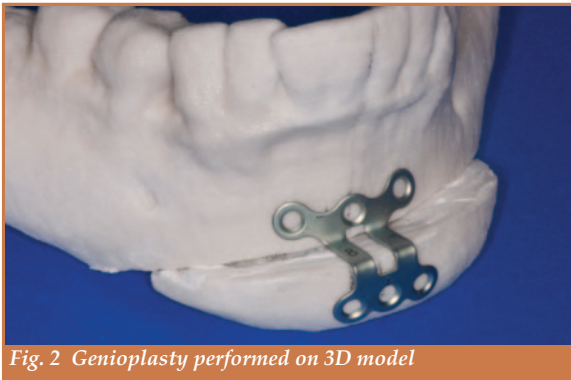


Fig. 2 Genioplasty performed on 3D model

Surgical Technique

A circum-vestibular incision is made intraorally from the lower premolar to premolar. The mentalis muscle is transected and the periosteum incised. The chin is degloved. An osteotomy cut is made horizontally inferior to both the mentle foramens and away from the roots of the lower anterior teeth. The genial tubercle, attachment of the genioglossus muscle must be included in the mobilised segment (Fig. 3). The chin segment is fixed in the planned position with the pre-bended titanium plate. Facial profile improved after the chin advancement.

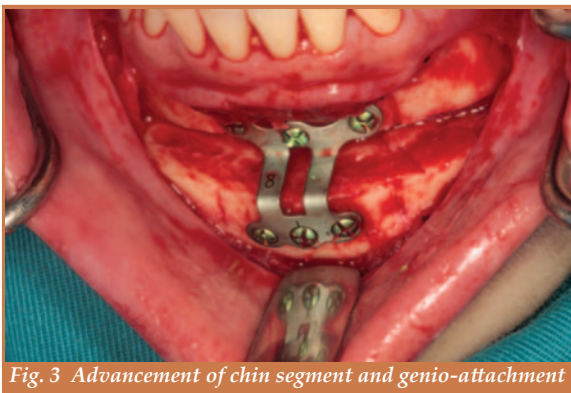


Fig. 3 Advancement of chin segment and genio-attachment

Maxillo-Mandibular Advancement (MMA)¹¹⁻¹⁴

MMA is often regarded as the final solution for moderate to severe OSA patients who had gone through conservative means eg. weight control, dental appliance and CPAP. Forward positioning of the tongue base attachment is an effective means of opening the airway. Empirically rule of ten applied to the amount of repositioning of the jaw bone: advancement of the mandible for 10mm with concomitant advancement of the maxilla and genio-advancement for 10mm.

Case Report

A 36 years old Chinese male patient (Fig.4) was referred to the Oral and Maxillofacial Surgery Clinic for surgical management of his OSA. The patient was diagnosed to have a moderate OSA for three years with symptoms of loud snoring, witnessed apnoea, daytime sleepiness, poor concentration and memory. RDI was 19 from a sleep study. He had been treated with CPAP and dental appliance but has become intolerable to the noise of the CPAP machine and the discomfort from the facemask.

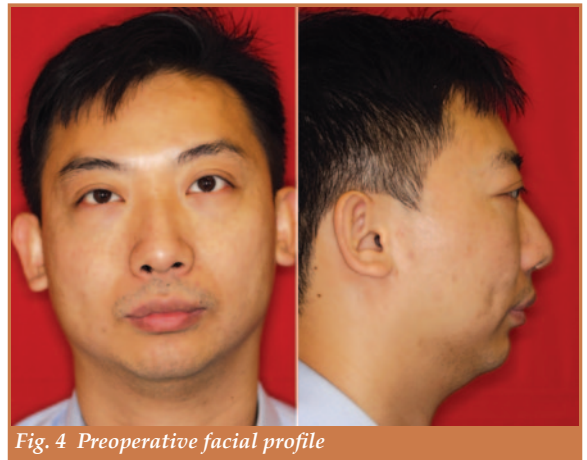


Fig. 4 Preoperative facial profile

On presentation, he is slightly overweight with a retrognathic mandible and a short neck. The overbite was deep and the dental health was reasonable. (Fig. 5)

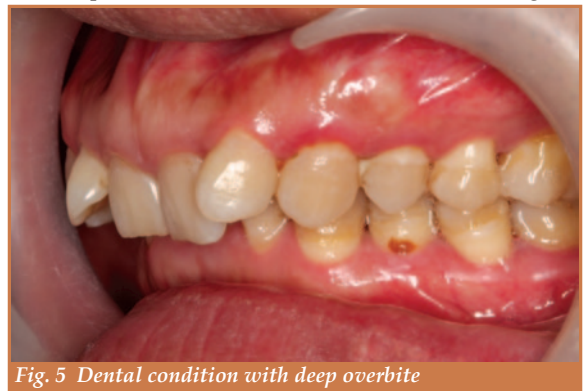

Fig. 5 Dental condition with deep overbite

The airway was assessed with CT scan and airway assessment computer software (3DMd Vultus).^{15,16} The obstruction was confirmed to be located at the base of the tongue level. (Fig. 6 & Fig. 7)

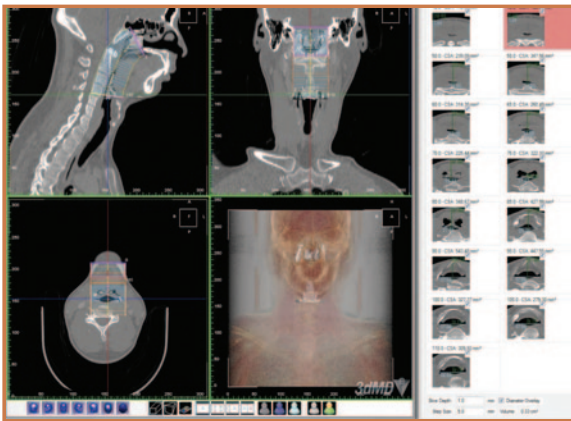


Fig. 6 Measurement of airway dimension with Vultus software

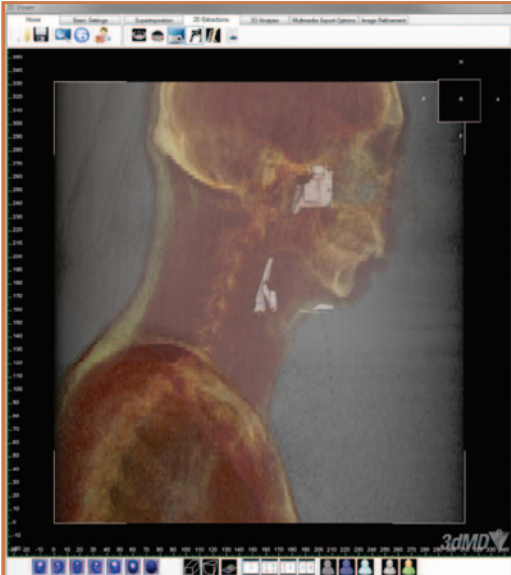


Fig. 7 Narrowing of airway at base of the tongue level

Surgical Plan

In order to open up the airway, the aim of the surgery is to advance the mandible and genio-attachment. Theoretically the maxilla needs no surgery. However, a pure mandibular advancement will create a non-functional malocclusion. Usually the problem is solved by orthodontic therapy presurgically to harmonise the dental arches and preserve overjet for the mandibular surgery. In this case, the patient declined orthodontic treatment; a Maxillo-Mandibular Advancement is offered to the patient, the maxilla and mandible are advanced together to preserve the existing dental occlusion.

To minimise the change in mid face profile, the maxilla is planned for an anti-clockwise rotation with an impaction of 6mm and advanced with the mandible. The mandible is advanced 10mm and the chin segment is advanced 10mm.

Maxillary Le Fort I osteotomy, Bilateral Sagittal Split mandibular osteotomy and genioplasty were performed

simultaneously to achieve the surgical movements via an intra-oral approach. The new jaw positions were fixed with mini-titanium plates. (Fig. 8)

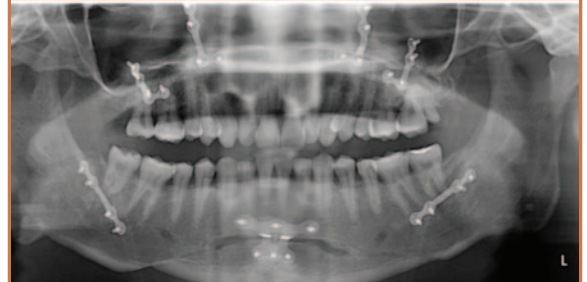
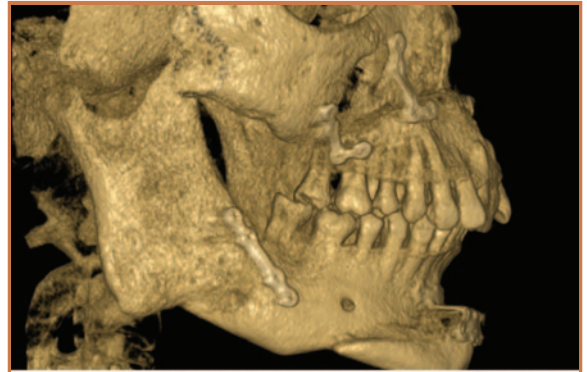

Fig. 8 MMA osteotomy

Surgical Results

The facial profile changes and dental occlusion were as planned. No neurosensory disturbance noted from the osteotomy. (Fig. 9)

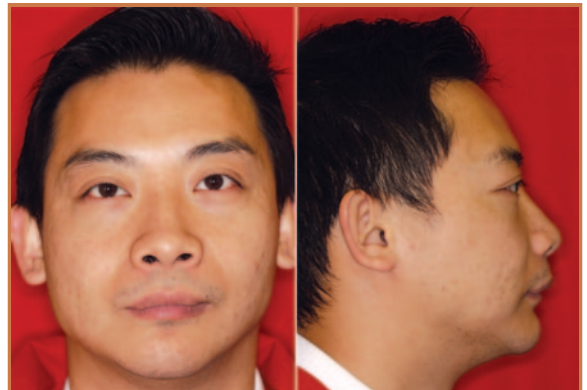

Fig. 9 Postoperative facial profile changes

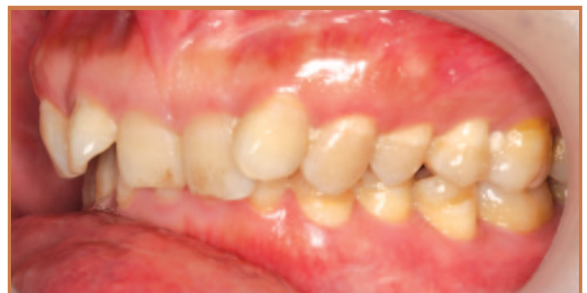

Fig. 10 Postoperative dentition



The airway was reassessed with postoperative CT scan and 3DMD Vultus again and compared (Fig. 11 & Fig. 12). Considerable increase in airway dimension was noted from the measurement.¹⁷

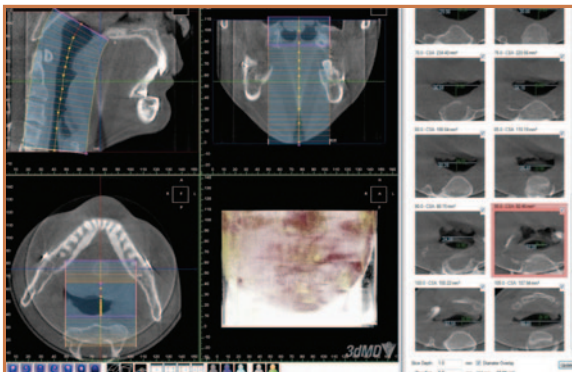


Fig. 11 Postoperative airway measurements

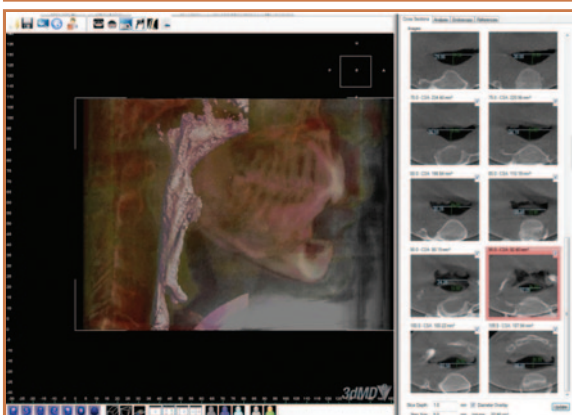


Fig. 12 Postoperative airway dimension

Subjectively the patient reported good quality sleep without daytime sleepiness and loss of concentration to work. Unfortunately, the patient refused postoperative polysomnography study for documentation of postoperative AHI and RDI.

Conclusion

It is shown in this case that MMA is an effective way to eliminate obstructive sleep apnoea at glossopharyngeal level obstruction.

Genioplasty and Maxillo-Mandibular Advancement procedures offer an option for patients with moderate to severe OSA to completely eliminate the CPAP machine. However, consideration should be taken for facial profile changes and possibility of adjuvant orthodontic treatment.

References

1. Punjabi NM, The epidemiology of adult obstructive sleep apnoea, Proc Am Thorac Soc. 2008 Feb 15;5(2):136-43
2. Lam JC, Sharma SK, Lam B, Obstructive sleep apnoea, definitions, epidemiology and natural history, Indian J Med Res. 2010 Feb; 131:165-70
3. Bounhoure JP, Galinier M, Didier A, Leophonte P; Sleep apnoea syndromes and cardiovascular disease, Bull Acad Natl Med. 2005 Mar;189(3):445-59; discussion 460-4
4. Parish JM, Somers VK, Obstructive sleep apnoea and cardiovascular disease, Mayo Clin Proc. 2004 Aug;79(8):1036-46

5. Rosenberg R, Doghramji P, Optimal treatment of Obstructive sleep apnoea and excessive sleepiness, Adv Ther. 2009 Mar;26(3):295-312.
6. Chai CL, Pathinathan A, Smith B, Continuous positive airway pressure delivery interfaces for obstructive sleep apnoea, Cochrane Database Syst Rev. 2006 Oct 18;(4):CD005308
7. Ahrens A, McGrath C, Hagg U, A systematic review of the efficacy of oral appliance design in the management of obstructive sleep apnoea, Eur J Orthod. 2011 Jun;33 (3):318-24
8. Holty JE, Guilleminault C, Surgical options for the treatment of obstructive sleep apnoea, Med Clin North Am. 2010 May;94(3):479-515.
9. Meslemani D, Jones LR., Skeletal surgery in sleep apnea., Curr Opin Otolaryngol Head Neck Surg. 2011 Jun 8.
10. Joao F Junior, Marcio A, Luiz CG, Adriane IZ, Emne HG, Genioplasty for genioglossus muscle advancement in patients with obstructive sleep apnoea, Rev Bras Otorrinolaringol 2007;73(4):480-6
11. Boyd SB., Management of obstructive sleep apnea by maxillomandibular advancement. Oral Maxillofac Surg Clin North Am. 2009 Nov;21(4):447-57.
12. Pirklbauer K, Russmueller G, Stiebellehner L, Nell C, Sinko K, Millesi G, Klug C Maxillomandibular advancement for treatment of obstructive sleep apnea syndrome: a systematic review., J Oral Maxillofac Surg. 2011 Jun;69(6):e165-76.
13. Prinsell JR., Primary and Secondary Telegnathic Maxillomandibular Advancement, With or Without Adjunctive Procedures, for Obstructive Sleep Apnea in Adults: A Literature Review and Treatment Recommendations, Oral Maxillofac Surg. 2011 Aug
14. Mattos CT, Vilani GN, Sant'anna EF, Ruellas AC, Maia LC., Effects of orthognathic surgery on oropharyngeal airway: a meta-analysis, Int J Oral Maxillofac Surg. 2011 Jul 20.
15. Hernández-Alfaro F, Guizarro-Martínez R, Mareque-Bueno J., Effect of Mono- and Bimaxillary Advancement on Pharyngeal Airway Volume: Cone-Beam Computed Tomography Evaluation, J Oral Maxillofac Surg. 2011 Jul 26.
16. El AS, El H, Palomo JM, Baur DA., A 3-dimensional airway analysis of an obstructive sleep apnea surgical correction with cone beam computed tomography, J Oral Maxillofac Surg. 2011 Sep;69(9):2424-36.
17. Goodday R, Bourque S., Subjective Outcomes of Maxillomandibular Advancement Surgery for Treatment of Obstructive Sleep Apnea Syndrome. J Oral Maxillofac Surg. 2011 Jul 12.

Customer Education
Centre address :
10X, Valiant Ind. Ctr.,
2-12 Au Pui Wan St.,
Fotan, N. T.,
Hong Kong

64 | Power Procedure Chair

40" max
Height
19" mini

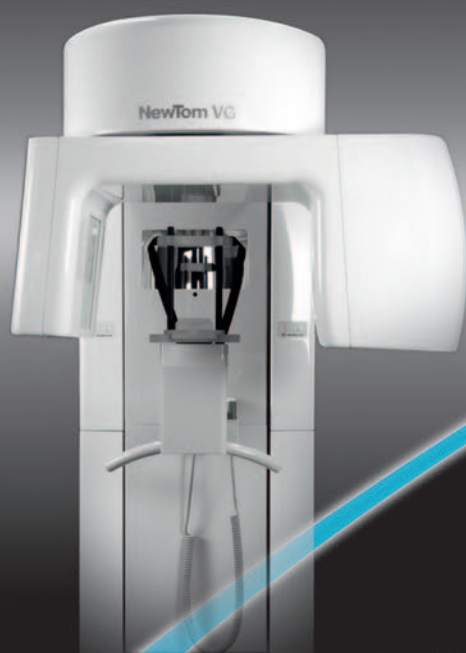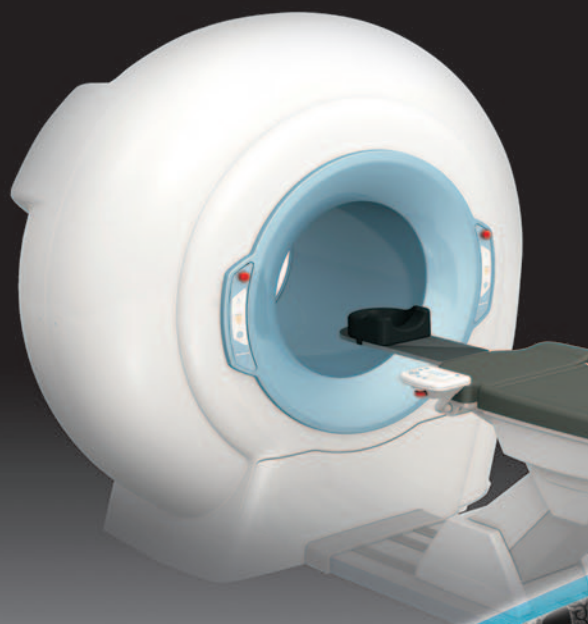
350°
Rotation

Associated Medical Supplies Co., Ltd.
Email : general@amscl.com Tel : 2604 9389

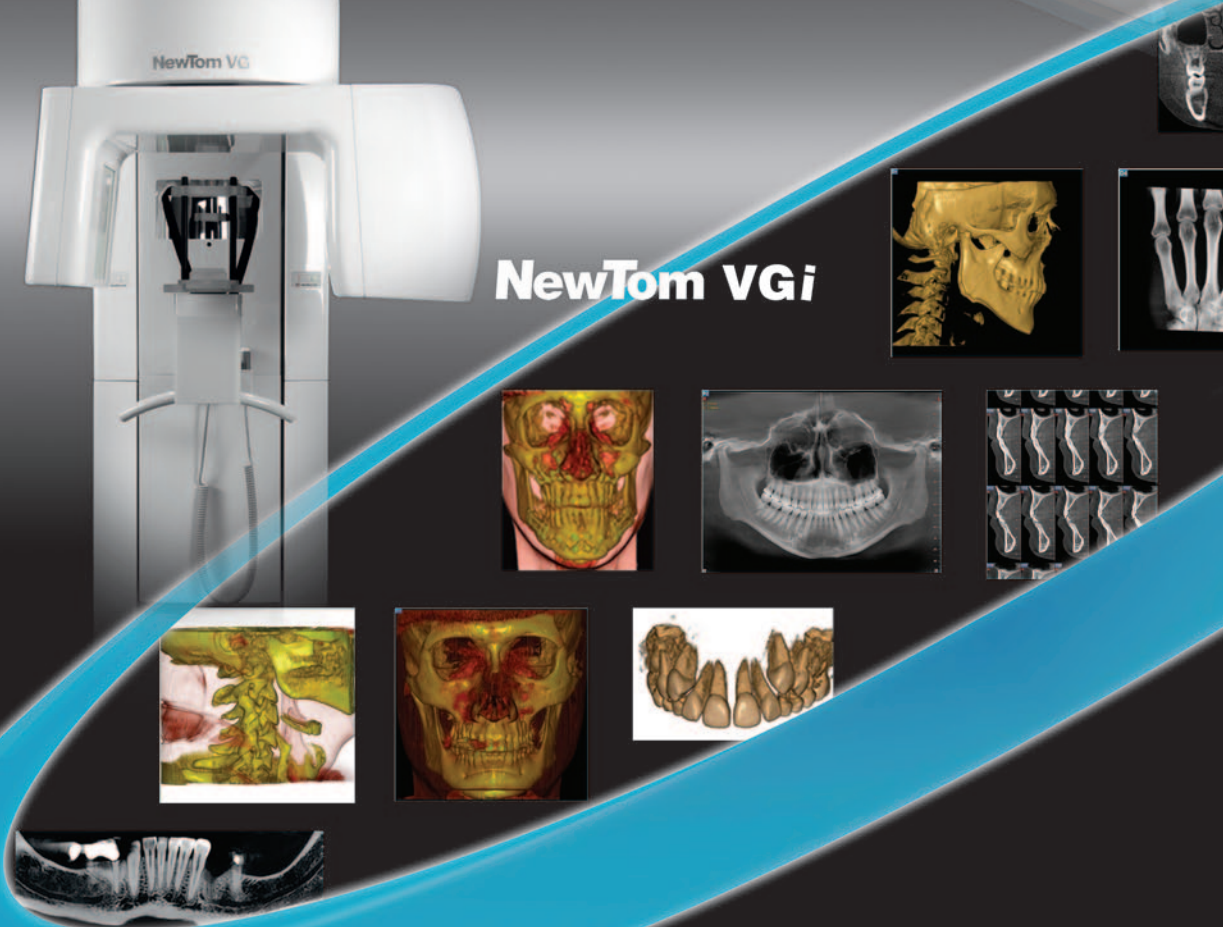Come to our showroom!

NewTom

Prime Cone Beam CT



NewTom VGi



NewTom - Market Leader of CBCT

Smallest Possible Focal Spot
for the Clearest Images

360 Degree Imaging and Rotating
Anode Means No Scatter of Artifacts

Greater Patient Comfort
and Treatment Acceptance

Easier Image Sharing

Precise 1:1 Scale Imaging

SafeBeam Technology for Patient Safety

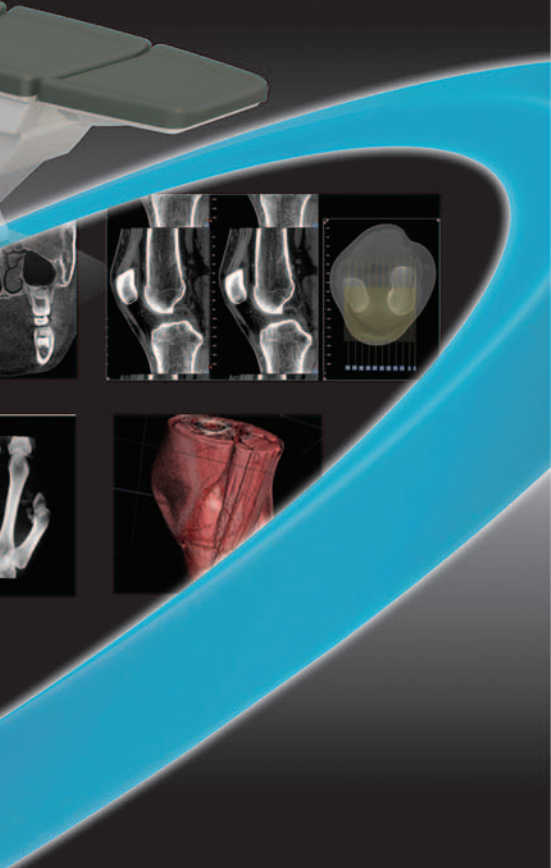
Consistent Images Regardless
of Patient Size

Sino-Ita International Trading CO., LTD

Add. : Room1702,Tower C,Weiboshidai Center
No.17,South Street,Zhongguancun,Beijing China

Tel. : 86+(10)8857-9042/43 Fax: 86+(10)8857-9044

NewTom 5G

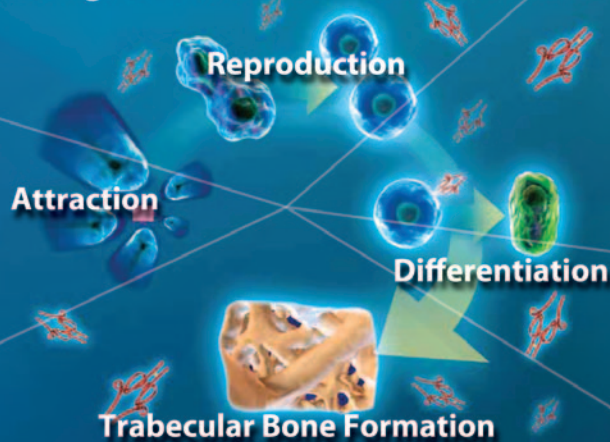


eriverona.it

ny3ddental.net (Chinese)



INFUSE® Bone Graft induces new bone formation for dental implant placement Understanding the Mechanism of Action of rhBMP-2/ACS*



To learn more about INFUSE® Bone Graft (rhBMP-2/ACS) and the Total Biologics Solution go to www.infusebonegraft.com or contact your local sales representative.

* Summary of Safety and Effectiveness (SSE&E) Data, INFUSE® Bone Graft/IT-GAGE® Lumbar Tapered Fusion Device, PMA Number P000058, July 2, 2002, and INFUSE® Bone Graft, PMA P000054, April 30, 2004. These preclinical results may not necessarily be indicative of human clinical performance.

DCH (Diploma in Child Health Examination) Written Examination (MRCPCCH Part IA) 2012

The Hong Kong College of Paediatricians (HKCPaed) and the Royal College of Paediatrics and Child Health (RCPCH) will hold a Joint Diploma in Child Health Examination in Hong Kong in 2012 awarding DCH (HK) and DCH (International) to successful candidates.

The Examination is divided into two parts, Written (MRCPCCH Pt IA) and Clinical. The DCH Written Examination is a common paper shared with the MRCPCCH Part IA. The MRCPCCH Part IA Examination is held three times a year in Hong Kong. The next MRCPCCH Part IA Examination will be held on **Tuesday, 14 February 2012**. The examination fee is **HK\$4,250** for Part IA. Candidates who wish to enter the examination must hold a recognized medical qualification in Hong Kong.

Application: Candidates who wish to sit the examination in Hong Kong **MUST** apply through the Hong Kong College of Paediatricians (HKCPaed). For application details, please visit the HKCPaed website at www.paediatrician.org.hk/entcnews.htm or call the College Secretariat at 28718871.

Deadline for Application: Friday, 20 November 2011

Important Notice **New Clinical Examination for DCH from April 2011**

A new format of the DCH clinical examination has been adopted since April 2011. Details of the new format and other relevant information can be viewed on the RCPCH website at: www.rcpch.ac.uk



The Use of Recombinant Human Bone Morphogenetic Protein-2 in Vertical Ridge Augmentation for Dental Implants – A Case Report

Dr. James CHOW

Specialist in Oral Maxillofacial Surgery



Dr. James CHOW

Introduction

Ridge resorption is the consequence of tooth loss. When the residual bone volume is so diminished that direct replacement of the missing tooth with a dental implant is unsuitable, it may be necessary to augment the deficient ridge prior to dental implant placement.

Depending on the size and the morphology of the defect, different techniques such as guided bone regeneration and onlay bone grafting are employed to reconstruct the deficient ridge.

In a systematic review, Donos et al.¹ found that there was adequate evidence in the literature to support that staged guided bone regeneration was effective in horizontal ridge augmentation and the clinical outcomes of dental implants in the augmented ridge were predictable with a high survival rate of 99% to 100% with up to 5 years follow-up after loading. However, the same authors reported less favourable outcomes of onlay bone grafting in horizontal ridge augmentation with implant survival rates varied from 84.1% to 100%.

Rocchietta et al.² conducted a systematic review on vertical ridge augmentation. Despite that there were clinical and histological data supporting the potential use of vertical ridge augmentation for dental implants, there was limited evidence in the literature to conclude that guided bone regeneration, distraction osteogenesis, and onlay bone grafting were predictable in vertical ridge augmentation.

Aghaloo and Moy³ published a consensus report to investigate on the effectiveness of various ridge augmentation techniques for dental implants and concluded that guided bone regeneration was predictable for alveolar ridge augmentation. However, there was insufficient documentation on the other augmentation techniques such as onlay bone grafting, split-crest, and distraction osteogenesis. The authors stated that these techniques were more operator-sensitive and more technique-sensitive procedures and they were associated with more complications such as wound dehiscence, infection, graft resorption, and graft failure.

In order to improve the clinical outcomes of horizontal and vertical ridge augmentation and avoid complications, new techniques have been introduced. These new techniques include the use of growth factors such as the bone morphogenetic proteins to increase the bone volume of the deficient ridges.

Feasibility studies of rhBMP-2/ACS applications in oral and maxillofacial surgeries have been conducted on sinus lift grafting and socket preservation⁴⁻⁵. These studies have confirmed that rhBMP-2/ACS has unparalleled osteoinductive potential and rhBMP-2/ACS is effective in forming bone de novo in sinus lift grafting and socket grafting situations.

To demonstrate the effectiveness of rhBMP-2 in vertical ridge augmentation, a case with deficient anterior maxillary ridge reconstructed with rhBMP-2 and dental implants is reported here.

Case report

A 25 years old lady presenting with missing upper central incisors due to traumatic injury when she fell from her bicycle.

Clinical examination revealed that there were vertical and horizontal defects of the residual alveolar ridge possibly due to the loss of labial bone plate during the avulsion injury (Figure 1).

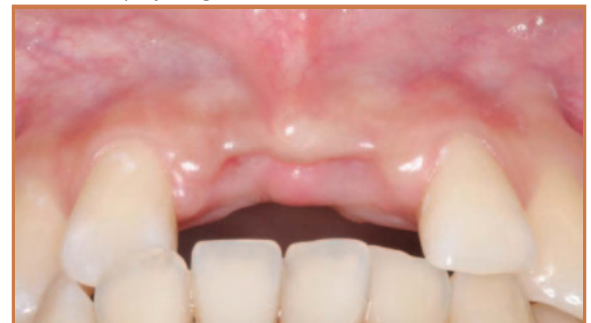

Figure 1. Deficient alveolar ridge in a 25 years old lady after traumatic injury.

Cone Beam CT (NewTom™, Italy) examination was performed to study the morphology of the deficient ridge. The DICOM3 file of the CBCT was segmented and converted to the STL format. Subsequently the maxilla model of this patient was produced by rapid prototyping (Objet™, Israel).

Treatment options of various augmentation techniques were discussed in detail with the patient and her mother. The benefits and disadvantages of using rhBMP-2/ACS (Infuse®, Medtronic) were explained. Eventually the patient decided to undergo ridge augmentation with rhBMP-2/ACS.

The deficient ridge on the maxilla model was built up using self-curing acrylic resin (Figure 2). A Titanium-mesh tray was fabricated to follow the contour of the reconstructed ridge (Figure 3). A teeth-supported acrylic surgical stent was made in the laboratory. This surgical stent was necessary for correct positioning of the Ti-mesh tray during surgery in order to obtain the desired height of the vertical ridge augmentation.

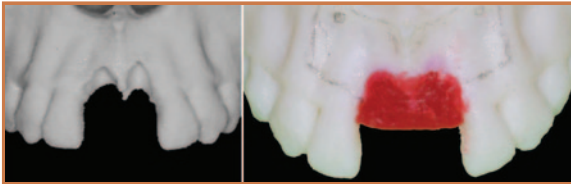

Figure 2a. The jaw model produced by rapid prototyping revealing the bone defect.

Figure 2b. The bone defect is built up with self-cured acrylic.



Figure 3. The customized Titanium-mesh tray is sterilized and ready for use.

The patient underwent the vertical ridge augmentation under monitored anaesthetic care. Local anaesthesia (2% Xylestaine™ 1.7 mL, ESPE) was given by infiltration technique. A 3-side full thickness muco-periosteal flap was raised from canine to canine. Periosteal releasing incision was made to mobilize the flap sufficiently. Ti-mesh tray was positioned using the surgical stent.

An XXS package of rhBMP-2/ACS (0.7 cc) was opened and prepared according to the written instructions. The rhBMP-2 was reconstituted with sterile water and loaded in a syringe. The reconstituted rhBMP-2 solution was delivered to the Absorbable Collagen Sponge (ACS) carrier (Figure 4). It was necessary to wait for a minimum 15 minutes to allow the complete adsorption of rhBMP-2 by the ACS carrier. The ACS carrier retained the rhBMP-2 and controlled the release of the rhBMP-2.



Figure 4. The rhBMP-2/ACS ready for use.

The ACS carrier was cut into smaller pieces and applied to the residual ridge by layers. Finally the Ti-mesh

was seated with the surgical stent and stabilized with titanium screws of 1.5mm diameter and 8 mm length (Figure 5). The Ti-mesh tray provided stable support to the underneath rhBMP-2/ACS preventing it from collapse during the healing period. A tension-free primary closure was carried out with 4/0 and 5/0 vicryl sutures.

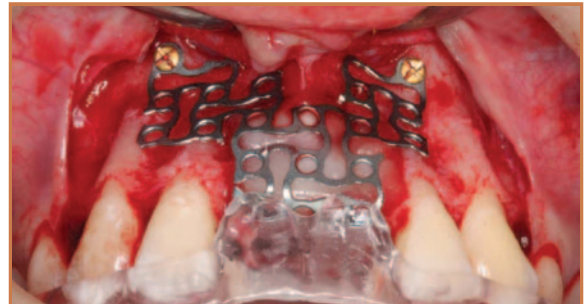

Figure 5. The rhBMP-2/ACS is supported by the Ti-mesh tray.

Patient recovered from the surgery unremarkably except that she developed gross facial swelling postoperatively. The swelling gradually subsided and disappeared after 2 weeks.

Cone Beam CT examinations taken immediately after surgery and six months later were compared. From the CT images, there was new bone formation in the space previously occupied by rhBMP-2/ACS (Figure 6a and 6b).

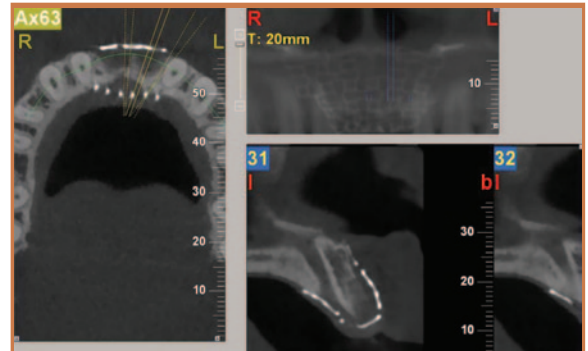


Figure 6a. Immediate post-operative Cone Beam CT examination.

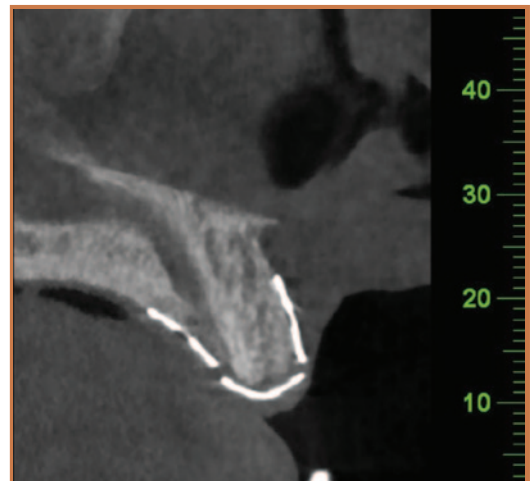


Figure 6b. Cone Beam CT examination taken six months later.



Patient underwent dental implant placement under local anesthesia. A 3-side flap was raised following the previous surgical incisions. The Ti-mesh tray was exposed and removed. There was good bone volume in the reconstructed site. Two dental implants (NobelActive™ 3.3mm x 13mm, Nobel Biocare AG) were inserted with good primary stability (50 Ncm). After the healing abutments were connected, the mucosa was closed with 5/0 vicryl sutures. Postoperative CT showed that these two implants were well supported by the regenerated bone (Figure 7).

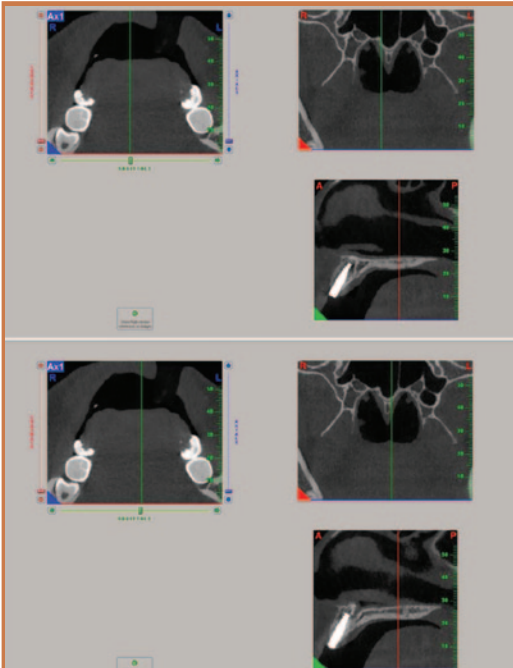


Figure 7. Cone Beam CT examination after placement of implants.

Three months later these implants were restored with ceramic abutments and ceramic crowns produced by CAD/CAM process (ProCera® Nobel Biocare AG).

Discussion

In 1965, Marshall R Urist⁶ induced ectopic bone formation in rabbits by implanting demineralized bone matrix into intramuscular pouch of them. This phenomenon of autoinduction of bone formation led to subsequent discovery of the bone morphogenetic proteins (BMPs). Bone morphogenetic proteins (BMPs) are members of the family of transforming growth factors. Two recombinant proteins are available: recombinant human bone morphogenetic protein rhBMP-2 and rhBMP-7. These recombinant products have been investigated as alternatives to autogenous bone grafts in a variety of clinical situations, including spinal fusions, fracture repair, and reconstruction of acquired and congenital maxillofacial conditions.

Currently, rhBMP-2 is FDA-approved for sinus lift grafting and socket preservation. Boyne et al.⁷ conducted randomized controlled clinical study of rhBMP-2 in sinus lift grafting to establish the efficacy and safety of the rhBMP-2/ACS combination. The authors concluded that a concentration of 1.50mg/mL rhBMP-2/ACS induced

faster bone formation compared to a concentration of 0.75mg/mL rhBMP-2/ACS. In a randomized prospective study, Triplett et al⁸ compared the clinical outcomes of 1.50mg/mL rhBMP-2/ACS with autogenous bone graft in 160 patients undergoing sinus lift grafting. They reported that the clinical and histological results in terms of bone formation and implant survival rates were comparable.

Jovanovic et al.⁹ conducted an animal study to compare the effectiveness of bone reconstruction using either rhBMP-2 or guided bone regeneration (GBR). The authors concluded that rhBMP-2/ACS with or without GBR induced significantly more bone formation than GBR alone. In addition, the authors found that the combined use of rhBMP-2/ACS and GBR may impair the osteoinduction potential of rhBMP-2.

Despite that there were animal studies⁹⁻¹⁰ demonstrating promising results of using rhBMP-2 in bone reconstruction, the efficacy of rhBMP-2 in alveolar ridge augmentation was equivocal. Fiorellini et al.¹¹ reported favorable results of rhBMP-2/ACS in socket preservation in 80 patients. The authors showed that in sockets with/without intact buccal wall, 1.5mg/mL rhBMP-2/ACS induced bone formation of sufficient quantity and good quality for implant placement. Cochran et al¹². evaluated the efficacy of rhBMP-2/ACS in 12 patients requiring either socket preservation or localized ridge augmentation. The authors reported satisfactory bone formation with socket preservation but they failed to obtain increased bone volume in cases with ridge augmentation.

There are definite advantages of using rhBMP-2/ACS for ridge augmentation compared with conventional bone grafting and guide bone regeneration. The advantages include autoinduction for bone formation, less technique-sensitive procedure, elimination of donor site morbidities and transmission of human diseases. However, rhBMP-2/ACS is expensive and evidence of its effectiveness in alveolar ridge augmentation is still limited.

References

1. Donos N, Mardas N, Chadha V. Clinical outcomes of implants following lateral bone augmentation: systematic assessment of available options (barrier membranes, bone grafts, split osteotomy). *J Clin Periodontol* 2008; 35 (Suppl. 8): 173-202.
2. Rocchietta I, Fontana F, Simion M. Clinical outcomes of vertical bone augmentation to enable dental implant placement: a systematic review. *J Clin Periodontol* 2008; 35 (Suppl. 8): 203-215.
3. Aghaloo TL, Moy PK. Which Hard Tissue Augmentation Techniques Are the Most Successful in Furnishing Bony Support for Implant Placement? *Int J Oral Maxillofac Implants* 2007; 22 (Suppl):49-70.
4. Boyne PJ, Marx RE, Nevins M, et al: A feasibility study evaluating rhBMP-2/ absorbable collagen sponge for maxillary sinus floor augmentation. *Int J Periodontics Restorative Dent.* 1997; 17:11.
5. Howell TH, Fiorellini J, Jones A, et al. A feasibility study evaluating rhBMP-2/ absorbable collagen sponge device for local alveolar ridge preservation or augmentation. *Int J Periodontics Restorative Dent* 1997;17: 125-140.
6. Urist MR. Bone: formation by autoinduction. *Science* 1965: 150: 893-899.
7. Boyne PJ, Lilly LC, Marx RE, et al: De novo bone induction by recombinant human bone morphogenetic protein-2 (rhBMP-2) in maxillary sinus floor augmentation. 2005; *J Oral Maxillofac Surg* 63:1693.
8. Triplett RG, Nevins M, Marx RE, Spagnoli DB, Oates TW, Moy PK, Boyne PJ. Pivotal, Randomized, Parallel Evaluation of Recombinant Human Bone Morphogenetic Protein-2/Absorbable Collagen Sponge and Autogenous Bone Graft for Maxillary Sinus Floor Augmentation. *J Oral Maxillofac Surg* 2009; 67:1947-1960.
9. Jovanovic SA, Hunt DR, Bernard GW, Spiekermann H, Wozney JM, Wikesjö UME. Bone reconstruction following implantation of rhBMP-2 and guided bone regeneration in canine alveolar ridge defects. *Clin. Oral Impl. Res.* 18, 2007; 224-230.
10. Jovanovic SA, Hunt DR, Bernard GW, Spiekermann H, Nishimura R, Wozney JM, Wikesjö UME. Long-term functional loading of dental implants in rhBMP-2 induced bone. A histologic study in the canine ridge augmentation model. *Clin. Oral Impl. Res.* 14, 2003; 793-803.
11. Fiorellini JP, Howell H, Cochran DL, Malmquist J, Lilly LC, Spagnoli D, Toljanic J, Jones A, Nevins M. Randomized Study Evaluating Recombinant Human Morphogenetic Protein-2 for Extraction Socket Augmentation. *J Periodontol* 2005; 76:605-613.
12. Cochran DL, Jones AA, Lilly LC, Fiorellini JP, Howell H. Evaluation of Recombinant Human Bone Morphogenetic Protein-2 in Oral Applications Including the Use of Endosseous Implants: 3-Year Results of a Pilot Study in Humans. *J Periodontol* 2000; 71:1241-1257.

TESCO

MAKING YOUR PRACTICE
PERFECT



What do we offer?

..... is what you deserve.

Biocompatible



Esthetics

VITA




Strength



Technology

AICHI STEEL





Reconstruction of Maxillary Defects

Dr. Sai-king CHAN

BDS(HK), FRACDS, FCDShK(Oral & Maxillofacial Surgery), FHKAM(Dental Surgery)

Consultant Oral & Maxillofacial Surgeon, Queen Elizabeth Hospital



Dr. Sai-king CHAN

Introduction

The maxilla is formed by strong bony buttresses and thin paper-thin cortical bones. As the keystone of the midface, it supports the orbits, the zygomatic complex, the nasal unit and the dento-alveolar complex of the upper jaw - holding the entire midface into one functional and aesthetic complex.

Causes of Maxillary Defects

In a broad sense, the physiological alveolar bone resorption after loss of teeth, for one reason or another, is the most common maxillary defect that requires reconstruction - simple removable dentures or complicated osseointegrated dental implants, with or without bone grafting procedures.

Congenital defects affecting the maxilla include cleft lip and palate, hemifacial microsomia, facial cleft and various dento-facial deformities.

Trauma to the maxilla can be caused by road traffic accidents, gun-shots, falls, inter-personal violence etc.

Defects resulting from ablative surgeries depend on the nature, size and site of the pathological lesions concerned. The commonest malignancy is squamous cell carcinoma of the hard palate and maxillary alveolus. Benign lesions include ameloblastoma, keratocystic odontogenic tumour, benign fibro-osseous lesions.

Osteoradionecrosis presenting as a complication after radiation therapy for the head and neck cancers can lead to extensive bone loss. Bisphosphonate related osteonecrosis of the jaws is now a known complication of taking bisphosphonate medications.

Bone destructions related to infections, such as tuberculosis and syphilis, are rare. In immune deficiency diseases e.g. AIDS, bone loss might be caused by fungal or viral infections.

Consequences of Maxillary Defects

Functional consequences are problems in mastication and swallowing, loss of teeth and supporting tissue, leakage and regurgitation, phonation and even eye problems if the orbit is involved.

Structural problems may result if any part the maxillary

buttresses (zygomaticomaxillary, pterygomaxillary, nasomaxillary) system is involved¹.

Socio-psychological problems after maxillectomy have been assessed by evaluating the health-related quality of life². The defect itself or a large prosthesis disrupts emotional, cognitive and social functioning.

Sigmund Freud, the father of modern psychoanalysis, tragically died of cancer of the soft palate in 1939 at the age of 83. Cigar smoking had a large part to play as a causative agent. For the last sixteen years of his life, he was subjected to 30 or so surgical procedures and had to endure the daily wearing of unsatisfactory prostheses to replace his resected maxilla³. Eating and speaking were severely affected. He was reported to be most upset by the inability to indulge in his 'sin' of cigar smoking. A brilliant life and a painful agony finally ended with 2 centigrams of morphine⁴.

Objectives for Reconstruction of Maxilla

The mechanical replacement of the missing parts with extended dental prostheses was once the only reconstructive means available after surgical resections. A whole array of local flaps, free microvascular flaps, distraction osteogenesis and osseointegrated dental implants are nowadays standard reconstructive techniques.

The goals for the reconstruction of maxillary defects are⁵:

1. Obliteration of the defect;
2. Restoration of functions e.g. mastication and speech;
3. Provision of adequate structural support to the midface; and
4. Aesthetic reconstruction of the external structures.

Since most maxillary defects are composite in nature, skin coverage, bony support, and mucosal lining are usually required to meet the reconstructive objectives

Classification of Defects

Although maxillary defects involve both soft and hard tissues, the classifications are usually based on the size and location of the bony defects. A good classification system should allow for a thorough planning of the resection and the reconstructive surgery, to fulfil the practical needs in the reconstruction of prostheses and

to provide a basis for comparison of results obtained by different techniques.

A classification of maxillary defects was published by Aramany in 1978 for prosthetic rehabilitation⁶. Since then, many other methods of classifications have been published as surgical techniques and rehabilitation advance.

Spiro et al⁷ classified three different categories of maxillectomy defects:

1. "Limited maxillectomy" was applied to any maxillectomy which primarily removed one wall of the antrum.
2. "Subtotal maxillectomy" was any procedure which removed at least two walls, including the palate.
3. "Total maxillectomy" was those procedures that resulted in a complete resection of the maxilla, which could include the exenteration of orbital contents.

Cordeiro et al⁸ described a four-part classification system that conceptualised the maxilla as a hexahedrium.

1. Type I defect (limited maxillectomy) included resection of one or two walls of the maxilla.
2. Type II defect (subtotal maxillectomy) included resection of the maxillary arch, palate, anterior and lateral walls (lower five walls), with preservation of the orbital floor.
3. Type III defects (total maxillectomy) included resection of all six walls of the maxilla. This was further subdivided into type IIIa, where the orbital contents were preserved, and type IIIb, where the orbital contents were exenterated.
4. Type IV defects (orbitomaxillectomy) included resection of the upper five walls of the maxilla, with preservation of the palate.

Brown et al⁹ developed a classification system classifying maxillectomy defects according to the vertical and horizontal components:

Vertical component:

- I: maxillectomy not causing an oronasal fistula
- II: not involving the orbit
- III: involving the orbital adnexae with orbital retention
- IV: with orbital enucleation or exenteration
- V: orbitomaxillary defect
- VI: nasomaxillary defect

Horizontal component:

- a: palatal defect only
- b: less than or equal to 1/2 unilateral
- c: less than or equal to 1/2 bilateral or transverse anterior
- d: greater than 1/2 maxillectomy.

With a view to facilitate further studies combining surgical reconstruction and prosthodontic rehabilitation of maxillectomy defects, Okay et al¹⁰ presented the palatomaxillary classification system:

- Class 1a defects involved any portion of the hard palate but not the tooth-bearing maxillary alveolus.

Class Ib defects involved premaxilla or any portion of the maxillary alveolus and dentition posterior to the canines.

- Class II defects involved any portion of the hard palate and tooth-bearing maxillary alveolus and only one canine. The anterior margin of the defects lies within the premaxilla. This class included transverse defects that involved less than 50% of the hard palate.
- Class III defects involved any portion of the hard palate and tooth-bearing maxillary alveolus, including both canines. This class included total and transverse palatotomy defects that involved more than 50% of the hard palate.

Development of Maxillary Reconstruction

Various reconstructive methods to augment the alveolar bone ridge for osseointegrated dental implants are widely used. Non-vascularised bone, e.g. harvested from the chin or ramus of the mandible, calvaria, anterior iliac crest, is used in procedures such as sinus lift to augment the sinus floor. Secondary bone graft for cleft lip and palate cases involving the alveolus is another commonly performed maxillary reconstruction procedure with non-vascularised cancellous bone.

A prosthetic appliance was the only reconstructive option following resection of the maxilla. An extended upper removable denture with a bulb obliterates the surgical defect, immediately restores the aesthetic, provides the patients with a set of teeth and gives support to the remaining soft tissues. It allows periodic direct inspections of the oncologic defect. However, there might be leakage between the oral and nasal cavities, discomfort, difficulty in manipulating bulky prostheses and problems with oral hygiene in an already debilitated mouth. An adequate number of remaining teeth must be required for satisfactory functions.

With the advent of osseointegrated dental implants, prosthetic replacements have been given a new meaning. A removable obturator was considered a temporary treatment before further extensive reconstruction surgery. Sophisticated rehabilitation with osseointegrated dental implants is now the final definitive step to fulfil the ultimate reconstructive functional standard – the restoration of occlusion.

A multitude of local flaps have been used for small defects. Traditionally, congenital defects of the maxilla, as in the case of cleft palates, are repaired by various local sliding palatal mucoperiosteal flaps. Alternative methods for repairing small oro-antral communications include island mucoperiosteal flaps, buccal fat pads¹¹, and nasolabial flaps¹².

For larger defects, pedicled myocutaneous flaps were developed in the 1960s and 1970s. The flaps are bulky and limited in their ability to reproduce the function and form of the maxillectomy defects. Historically, the deltopectoral flap¹³, pectoralis major¹⁴, latissimus dorsi¹⁵, temporalis¹⁶, sternomastoid¹⁷, trapezius¹⁸ flaps have been described. Restoration of function is difficult, or



impossible at all. These are now reserved back-up flaps to the micro-vascular free flaps.

Free tissue transfer with microvascular surgery developed in the 1980s had brought about the use of less bulky fascial, fasciocutaneous and osseous flaps. Reconstructive options utilising free bone grafts and free tissue transfer include the radial forearm free flap (the "Chinese flap")¹⁹, rectus abdominis free flap²⁰, scapula free flap²¹, deep circumflex iliac artery free flap²², fibula free flap²³ and anterolateral thigh flap²⁴. At present, the use of microvascular flaps is the most versatile treatment option. However, comorbidity and a permanent deficit at the donor sites remain a problem.

Functional rehabilitation has been further enhanced with the development of osseointegration of dental implants and distraction osteogenesis to create new alveolar bone and, more importantly, soft tissue coverage. Distraction osteogenesis, however, is limited by the difficulty in controlling the vector of distraction in three-dimensional maxillary defects.

Advances in Diagnostic Techniques

Magnetic resonance imaging (MRI) provides a good image of the soft tissues and allows a good knowledge of the depth of extension of the tumour processes. CT scan remains the most useful modality to study the bony skeleton. Thinner slices, two-dimensional and three-dimensional reconstructions can now be easily done. In parallel to the advances in CT scan technology, stereolithography provides very accurate models for planning²⁵. Navigation not only facilitates the removal of deep tumours, but also provides better positioning and fixation of dental implants.

Future Development

With an attempt to reduce donor-site defects, tissue engineering for new bone formation using human tissues has been experimented clinical trials. It is now possible to create a prefabricated bone flap, using an alloplastic framework impregnated with bone morphogenetic protein (BMP) inserted into muscular tissue²⁶.

In 2005, the first facial transplantation ever was undertaken in France²⁷. The second case was done in China²⁸. Since then, a dozen or so more facial allograft transplantations have been reported worldwide with various degrees of success. Exciting as the procedure may be, the long-term results are unknown.

Conclusion

Since level 1 or 2 evidence for the method of maxillary reconstruction does not exist, the approaches used in different centres are largely subjective, very often depending on the expertise available and inevitably influenced by personal preferences.

There is no doubt that dental prostheses have an important place in maxillary reconstruction, especially

with the use of osseointegrated dental implants. Adequate bony support with good soft tissue coverage would be a prerequisite. These should be taken into account in the planning of the surgical approach – to preserve, transfer or even create the hard and soft tissues required are now possible.

Maxillary reconstruction hence requires both surgical and prosthodontic approaches for the optimal functional and aesthetic restoration.

References

1. Yamamoto Y, Kawashima K, Sugiharat T, et al. Surgical management of maxillectomy defects based on the concept of buttress reconstruction. *Head Neck* 2004;26:247-256.
2. Rogers SN, Lowe D, McNally D, et al. Health-related quality of life after maxillectomy: a comparison between prosthetic obturation and free flap. *J Oral Maxillofac Surg* 2003;61:174-181.
3. Romm S. The oral cancer of Sigmund Freud. *Clin Plast Surg* 1983;10(4):709-14.
4. Aziz SR. Sigmund Freud; psychoanalysis, cigars, and oral cancer. *J Oral Maxillofac Surg* 2000;58:320-23.
5. Muzaffar AR, Adams WP Jr, Hartog JM, et al. Maxillary reconstruction: functional and aesthetic considerations. *Plast Reconstr Surg* 1999;104(7):2127-84.
6. Aramany MA. Basic principles of obturator design for partially edentulous patients. Part I: classification. *J Prosthet Dent* 1978;40:554-7.
7. Spiro RH, Strong EW, Shah JP. Maxillectomy and its classification. *Head Neck* 1997;19:309-14.
8. Cordeiro PG, Santamaria E. A classification system and algorithm for reconstruction of maxillectomy and midfacial defects. *Plast Reconstr Surg* 2000;105:2331-46.
9. Brown J, Shaw RJ. Reconstruction of the maxilla and midface: introducing a new classification. *Lancet Oncol* 2010;11:1001-08.
10. Okay DJ, Genden E, Buchbinder D, et al. Prosthodontic guidelines for surgical reconstruction of the maxilla: a classification system of defects. *J Prosthet Dent* 2001;86:352-63.
11. Samman N, Cheung LK, Tideman H. The buccal fat pad in oral reconstruction. *Int J Oral Maxillofac Surg* 1993;22:2-6.
12. Varghese BT, Sebastian P, Koshy CM, et al. Nasolabial flaps in oral reconstruction: an analysis of 224 cases. *Br J Plast Surg* 2001;54(6):499-503.
13. Sako K, Razack MS, Kalnins I. Reconstruction of massive orbito-maxillary-cheek defects. *Head Neck Surg* 1981;3:251.
14. Ariyan S, Cuono B. Use of the pectoralis major myocutaneous flaps for reconstruction of large cervical, facial or cranial defects. *Am J Surg* 1980;140:503.
15. Barton FE Jr, Spicer TE, Byrd HS. Head and neck reconstruction with the latissimus dorsi myocutaneous flap: Anatomic observations and a report of 60 cases. *Plast Reconstr Surg* 1983;71:199.
16. Bradley P, Brockband J. The temporalis muscle flap in oral reconstruction: A cadaveric, animal and clinical study. *J Maxillofac Surg* 1981;9:139.
17. Larson DL, Goepfert H. Limitations of the sternomastoid musculocutaneous flap in head and neck cancer reconstruction. *Plast Reconstr Surg* 1982;70:328.
18. Shapiro MJ. Use of the trapezius myocutaneous flaps in the reconstruction of head and neck defects. *Arch Otolaryngol* 1981;107:333.
19. Yang GF, Chen PJ, Gao YZ, et al. Forearm free skin flap transplantation: a report of 56 cases. *Chinese Med J* 1981;61:139-41.
20. Taylor GI, Corlett RJ, Boyd JB. The versatile deep inferior epigastric (inferior rectus abdominus) flap. *Br J Plast Surg* 1984;10:24.
21. Swartz WM, Banis JC, Newton ED, et al. The osteocutaneous scapular free flap for mandibular and maxillary reconstruction. *Plast Reconstr Surg* 1986;77:530-45.
22. Urken ML, Vickery C, Weinberg H, et al. The internal oblique-iliac crest osseomyocutaneous free flap in oromandibular reconstruction. Report of 20 cases. *Arch Otolaryngol Head Neck Surg* 1989;115:339-40.
23. Hidalgo D. Fibular free flap: a new method of mandibular reconstruction. *Plast Reconstr Surg* 1989;84:71-79.
24. Song YG, Chen GZ, Song YL. The free thigh flap: a new free flap concept based on the septocutaneous artery. *Br J Plast Surg* 1984;37:149-59.
25. Chang PS, Parker TH, Patrick Jr CW, et al. The accuracy of stereolithography in planning craniofacial bone replacement. *J Craniofac Surg* 2003;14:164-70.
26. Warnke PH, Springer ING, Wiltfang J, et al. Growth and transplantation of a custom vascularized bone graft in man. *Lancet* 2004;364:766-70.
27. Devauchelle B, Badet L, Lengele B, et al. First human face allograft: early report. *Lancet* 2006;368:203-9.
28. Guo S, Han Y, Zhang X, et al. Human facial allotransplantation: a 2-year follow-up study. *Lancet* 2008;372:631-8.

Difflam-C™

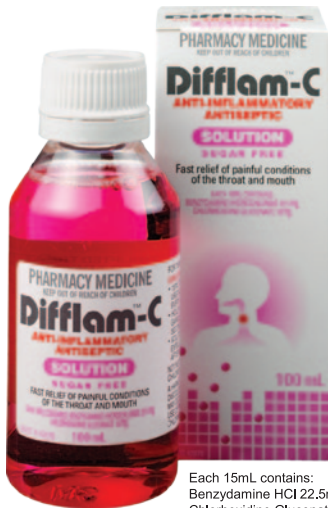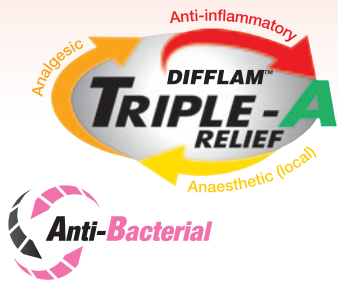
**ANTI-INFLAMMATORY
ANTISEPTIC**

SOLUTION

SUGAR FREE

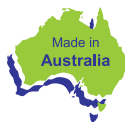Delivers Fast Pain Relief

For painful and inflamed
mouth-throat conditions



Each 15mL contains:
Benzylamine HCl 22.5mg,
Chlorhexidine Gluconate 18mg

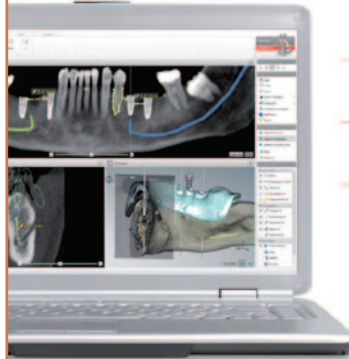Further information is available on request from:
iNova Pharmaceuticals (Hong Kong) Limited
Unit 01, 20/F, Millennium City 3
370 Kwun Tong Road, Kln, HK
Tel (+852) 2155 0668
Fax (+852) 3107 0668
www.inovapharma.com



inova
pharmaceuticals

HK2011/10

Take diagnostics and planning to the next level.



Maximize treatment safety
and predictability.

Enhance quality and
efficiency through digital
diagnostics.

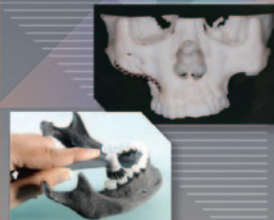Enjoy planning flexibility
for optimized function
and esthetics.

For more information, contact a Nobel Biocare
representative or visit nobelbiocare.com/digital



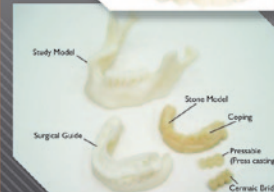OBJET

Desktop 3D Printer



Objet 3-Dimensional Printing Systems brings high-resolution, fine-detailed models into the hands of dental specialists and fits in any office environment.

Objet's biocompatible materials allow it to serve the dental segment well. Tests such as cytotoxicity irritation, sensitization, USP Class VI, and more provide medical experts with the ability to undertake advanced experiments using Objet-printed models.



"Objet's 3D modeling solution helps us show presentable and professional models to patients, resulting in both good patient-doctor communication and a planning tool for surgery."

Dr. Ben Chow,
Specialist in Oral & Maxillofacial Surgery

For detail, please contact:

ICT 智誠科技有限公司
Intelligent CAD/CAM Technology Ltd.

Tel: 852 2425 8136 Email: ictinfo@ict.com.hk Website: <http://www.ict.com.hk>



Besides Maxillofacial Surgery

Dr. Kiang-cheong CHOW

BDS, FRACDS, FHKAM (Dental Surgery), FCDSHK (OMS)
Specialist in Oral & Maxillofacial Surgery



Dr. Kiang-cheong CHOW

Life was dominated by work and sports very early in my dental career. Dr. Eric Carter was enthusiastic enough to teach the first batch of dental students in Hong Kong to row in 1980. A few of them including me became really involved. We formed part of the first ever rowing team to represent Hong Kong in the Asian Games in 1982 in New Delhi. We got special permission from the Dean to leave early from our clinical session everyday for the rowing practice. It was then we started learning how to work more efficiently. These training sessions at a competition level continued throughout my undergraduate and early career as a dental officer until the Asian Games in 1986 in Seoul.



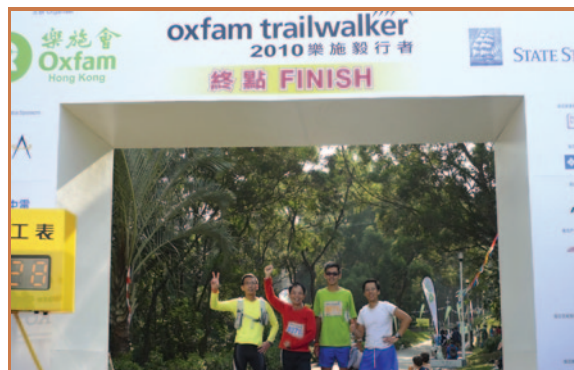So much so for the serious rowing. I maintained my connection with rowing as an international umpire. I still managed to keep a level of physical fitness, but nothing compared as before, especially when I was doing my specialist training.

My first Trailwalker dated back to 1994. I was a member of a medical team comprising of maxillofacial surgeons and anaesthetists. We just finished a charity medical

mission in Nepal and did some hiking in the countryside near the hospital overlooking the Himalayan range in the distance. The combination of charity work and nature really struck us deep in our souls. We wanted to keep the spirit going on after returning to Hong Kong and the Trailwalker seemed to be a good substitute. Covering one hundred kilometres over the MacLehose Trail was a real challenge. Our team had a mixed range of physical fitness. But that was where teamwork came in. We accommodated and supported each other very well and managed to finish in 28 hours, not a very fast record, but definitely a tremendous achievement in our own eyes. The direct consequence was that I slept for two days and my legs were sore for almost a week.

This unique experience kept driving me back onto the Trail although every time I insisted that it would be my last one. I have joined the event over 10 times since then. So every year it involved running and long hikes over the summer, gradually building up the fitness and endurance reaching the peak at the event. Different members added different chemistry and my fastest record was under 17 hours. I think it is a very respectable time and it took a lot of sweat to achieve this. It seemed a bit of waste to go through such a harsh training just for one event. So my team members started thinking to join other road running races as well for the fun of it. Marathon was again an obvious choice.

Having finished running a marathon was not as emotional as I would imagine. It was just an anti-climax. I could not resist going through the whole thing again and again in my mind. Perhaps I could shave a few minutes off if I had trained better, or ate more before the run, or did the warm-up ten minutes earlier and so on. So the natural conclusion was that I would be able to do it better the following year, always forgetting that I would also be one year older.





It was like an addiction. But after a while it seemed quite boring running on highways away from the crowd. Then the Tokyo Marathon brought in new perspectives and excitement. It was my first full marathon overseas. We were able to run in downtown Tokyo passing all the famous landmarks, temples, palace and department stores. The busy streets once packed with motor-vehicles were now dominated by runners. The pavements on both sides were packed with crowds of different age, all cheering and encouraging the runners passing-by just like their long-time friends or family members.

Running is like meditation to me. It brings peace of mind. I have to concentrate on the pace, the breathing and the form. It releases me from the stress of daily clinical work and refreshes my mind. But nothing is comparable to an experience of summiting a peak 6,000 m above sea level in a remote area in Tibet in 2002. Life was so basic but people there were also very religious and happy. People learn to be humble and respect the nature. Wealth and fame mean nothing while high altitude sickness can easily take your breath away. I also remembered the most enjoyable bath in a hot spring outside Lhasa after a week in the mountains without taking a bath.

Life became really busy outside maxillofacial surgery. There were the Trailwalker, local and overseas marathons, not to mention the training involved in between. Luckily self-discipline was part of our clinical training. You can always find time for training as long as you are motivated. Earlier this year I was crazy or

stupid enough to do two marathons in a row with just one week in between. The price was a torn calf muscle making me limping for several weeks.




By this time of the year, I should have finished the first ever Osaka Marathon, giving support to the post-earthquake Japanese community. Hopefully I could also run in the Kyoto Marathon on 11 March 2012 one year after the earthquake and Tsunami. This would be a wonderful opportunity to show that we care and support them, just the way they used to give encouraging words to foreign runners. We want to witness how they recover from the devastation. So let's go for it!


CME/CNE Course	CERTIFICATE COURSE FOR DENTAL NURSE	Course No. C188
-----------------------	--	------------------------

Certificate Course on
Dental Nursing in
Oral Surgery
2012


Jointly organised by



The Federation of
Medical Societies of
Hong Kong



The Hong Kong Association
of Oral and Maxillofacial
Surgeons Limited



Objectives:
 Modern dentistry has been continuously evolving. Oral surgical procedures are commonly performed nowadays in the dental office. Good dental nursing is a key component to success in this setting. Our course aims at introducing contemporary concept on dental nursing in oral and maxillofacial surgery.

Date : 6 Jan - 10 Feb 2012
Time : 7:00 p.m. – 8:30 p.m.
Venue : Lecture Hall, 4/F., Duke of Windsor Social Service Building, 15 Hennessy Road, Wanchai, Hong Kong
Language Media : Cantonese (Supplemented with English)
Course Fee : HK\$750 (6 sessions)
Certificate : Awarded to participants with a minimum attendance of 70%
Enquiry : The Secretariat of The Federation of Medical Societies of Hong Kong
Tel.: 2527 8898 Fax: 2865 0345 Email: info@fmshk.org



Sunday	Monday	Tuesday	Wednesday	Thursday	Friday	Saturday																	
<ul style="list-style-type: none"> * 3rd Guangdong, Hong Kong and Macau Sports Meet * HKMA Certificate Course on Family Medicine 2011 * HKMA MPS CME – Mastering Difficult Interactions with Patients * Beat Drugs Public Education Day <p style="text-align: right;">6</p>	<ul style="list-style-type: none"> * HKMA Eye Course – Latest Advances in Oculoplastic Surgery * FMSHK Officers' Meeting * Council Meeting <p style="text-align: right;">1</p>	<ul style="list-style-type: none"> * HKMA MPS CME – Mastering Your Risk * HKMA Trailwalker Final Briefing Session <p style="text-align: right;">2</p>	<ul style="list-style-type: none"> * HKMA MPS CME – Mastering Difficult Interactions with Patients * Kin East Community Network – Certificate Course on Allergic Rhinitis & Asthma (Session 3) * HKMA NTW Community Network – Certificate Course on Management and the role of Bisphosphonates * HKMA Structured CME Programme with Hong Kong Sanatorium & Hospital Year 2011 – New Frontiers in Therapeutic Endoscopy <p style="text-align: right;">3</p>	<ul style="list-style-type: none"> * HKMA MPS CME – Mastering Your Risk * HKMA MPS CME – Mastering Professional Interactions * Refresher Course for Health Care Providers 2011/2012 <p style="text-align: right;">4</p>	<ul style="list-style-type: none"> * Joint Surgical Symposium – Minimal Invasive Access for Head and Neck Surgery * HKMA Shatin Doctors Network - Treatment Strategies in Major Depressive Disorder <p style="text-align: right;">5</p>	<ul style="list-style-type: none"> * HKMA MPS CME – Mastering Adverse Outcome <p style="text-align: right;">13</p>	<ul style="list-style-type: none"> * HKMA MPS CME – Mastering Adverse Outcome * HKMA Family Sports Day * HKMA Tennis Tournament <p style="text-align: right;">14</p>	<ul style="list-style-type: none"> * HKMA Kin West Community Network - Treatment of Major Depressive Disorder <p style="text-align: right;">15</p>	<ul style="list-style-type: none"> * HKMA MPS CME – Mastering Professional Interactions <p style="text-align: right;">16</p>	<ul style="list-style-type: none"> * HKMA MPS CME – Mastering Difficult Interactions with Patients * FMSHK Executive Committee and Council Meeting * FMSHK and HKFMS Foundation Annual General Meeting <p style="text-align: right;">17</p>	<ul style="list-style-type: none"> * HKMA MPS CME – Mastering Difficult Interactions with Patients * Kin East Community Network – Certificate Course on Allergic Rhinitis & Asthma (Session 3) * HKMA NTW Community Network – Certificate Course on Management and the role of Bisphosphonates * HKMA Structured CME Programme with Hong Kong Sanatorium & Hospital Year 2011 – New Frontiers in Therapeutic Endoscopy <p style="text-align: right;">18</p>	<ul style="list-style-type: none"> * HKMA MPS CME – Mastering Adverse Outcome * HKMA MPS CME – Mastering Professional Interactions * Oxfam Trailwalker 2011 <p style="text-align: right;">19</p>	<ul style="list-style-type: none"> * HKMA MPS CME – Mastering Adverse Outcome * HKMA HKE Community Network – Current Management on Sleep Disorder/Breathing * HKMA Kin East Community Network - The Latest Development of Female Contraception * HKMA NTW Community Network – Androgenetic Alopecia (Hair Loss) in Men – Current Treatment Trend <p style="text-align: right;">20</p>	<ul style="list-style-type: none"> * HKMA MPS CME – Mastering Adverse Outcome * HKMA YTMCN and Kowloon Central Cluster – Certificate Course on Bringing Better Health to Our Community (Lecture 6) * HKMA Trailwalker Reunion Party <p style="text-align: right;">21</p>	<ul style="list-style-type: none"> * HKMA MPS CME – Mastering Adverse Outcome * HKMA YTMCN and Kowloon Central Cluster – Certificate Course on Bringing Better Health to Our Community (Lecture 6) * HKMA Trailwalker Reunion Party <p style="text-align: right;">22</p>	<ul style="list-style-type: none"> * HKMA MPS CME – Mastering Professional Interactions * Kin East Community Network – Certificate Course on Allergic Rhinitis & Asthma (Session 3) * HKMA NTW Community Network – Certificate Course on Management and the role of Bisphosphonates * HKMA Structured CME Programme with Hong Kong Sanatorium & Hospital Year 2011 – New Frontiers in Therapeutic Endoscopy <p style="text-align: right;">23</p>	<ul style="list-style-type: none"> * HKMA MPS CME – Mastering Adverse Outcome * HKMA MPS CME – Mastering Professional Interactions * Oxfam Trailwalker 2011 <p style="text-align: right;">24</p>	<ul style="list-style-type: none"> * HKMA MPS CME – Mastering Adverse Outcome * HKMA YTMCN and Kowloon Central Cluster – Certificate Course on Bringing Better Health to Our Community (Lecture 6) * HKMA Trailwalker Reunion Party <p style="text-align: right;">25</p>	<ul style="list-style-type: none"> * HKMA MPS CME – Mastering Adverse Outcome * HKMA MPS CME – Mastering Professional Interactions * Oxfam Trailwalker 2011 <p style="text-align: right;">26</p>	<ul style="list-style-type: none"> * HKMA MPS CME – Mastering Adverse Outcome * HKMA MPS CME – Mastering Professional Interactions * Oxfam Trailwalker 2011 <p style="text-align: right;">27</p>	<ul style="list-style-type: none"> * HKMA MPS CME – Mastering Adverse Outcome * HKMA MPS CME – Mastering Professional Interactions * Oxfam Trailwalker 2011 <p style="text-align: right;">28</p>	<ul style="list-style-type: none"> * HKMA MPS CME – Mastering Adverse Outcome * HKMA MPS CME – Mastering Professional Interactions * Oxfam Trailwalker 2011 <p style="text-align: right;">29</p>	<ul style="list-style-type: none"> * HKMA MPS CME – Mastering Adverse Outcome * HKMA MPS CME – Mastering Professional Interactions * Oxfam Trailwalker 2011 <p style="text-align: right;">30</p>



Date / Time	Function	Enquiry / Remarks
1 TUE 1:15 pm 8:00 pm – 10:00 pm 8:00 pm	HKMA Eye Course – Latest Advances in Oculoplastic Surgery Organiser: The Hong Kong Medical Association, Chairman: Dr. Victor Chi-pang WOO, Speaker: Dr. Carol Shan YU, Venue: The Hong Kong Medical Association Central Premises, Dr. Li Shu Pui Professional Education Centre, 2/F., Chinese Club Building, 21-22 Connaught Road Central, Hong Kong	HKMA CME Department Tel: 2527 8452 1 CME Point
	FMSHK Officers' Meeting Organiser: The Federation of Medical Societies of Hong Kong, Venue: Gallop, 2/F., Hong Kong Jockey Club Club House, Shan Kwong Road, Happy Valley, Hong Kong	Ms. Sonia CHEUNG Tel: 2527 8898 Fax: 2865 0345
	Council Meeting Organiser: The Hong Kong Medical Association, Chairman: Dr. Kin CHOI, Venue: HKMA Head Office, 5/F., Duke of Windsor Social Service Building, 15 Hennessy Road, Hong Kong	Ms. Christine WONG Tel: 2527 8285
2 WED 2:30 pm / 6:30 pm (12) 8:00 pm	HKMA MPS CME – Mastering Your Risk Organiser: The Hong Kong Medical Association, Speakers: Dr. Andy CHEUNG & Dr. Danny LEE, Venue: Eaton Hotel or The Hong Kong Medical Association Central Premises, Dr. Li Shu Pui Professional Education Centre, 2/F., Chinese Club Building, 21-22 Connaught Road Central, Hong Kong	HKMA CME Department Tel: 2527 8452 2.5 CME Points
	HKMA Trailwalker Final Briefing Session Organiser: HKMA Trailwalker Final Briefing Session, Venue: The Hong Kong Medical Association Central Premises, Dr. Li Shu Pui Professional Education Centre, 2/F., Chinese Club Building, 21-22 Connaught Road Central, Hong Kong	Miss Alice TANG & Miss Sharon HUNG Tel: 2527 8285
3 THU 2:30 pm / 6:30 pm (13, 16, 20, 26)	HKMA MPS CME – Mastering Adverse Outcome Organiser: The Hong Kong Medical Association, Speakers: Dr. Emily HUNG, Dr. Danny LEE & Dr. Anthony FUNG, Venue: The Hong Kong Medical Association Central Premises, Dr. Li Shu Pui Professional Education Centre, 2/F., Chinese Club Building, 21-22 Connaught Road Central, or Holiday Inn	HKMA CME Department Tel: 2527 8452 2.5 CME Points
4 FRI 8:00 am – 9:00 am 1:00 pm	Joint Surgical Symposium – Minimal Invasive Access for Head and Neck Surgery Organiser: Department of Surgery, The University of Hong Kong & Hong Kong Sanatorium & Hospital, Chairman: Dr. Victor TO, Speakers: Dr. Wai-Kuen HO & Dr. Jonathan LAU, Venue: Hong Kong Sanatorium Hospital	Department of Surgery, Hong Kong Sanatorium & Hospital Tel: 2835 8698 Fax: 2892 7511 1 CME Point (Active)
	HKMA Shatin Doctors Network - Treatment Strategies in Major Depressive Disorder Organiser: HKMA Shatin Doctors Network, Speaker: Dr. Cindy Pui-yu CHIU, Venue: The Royal Park Hotel	Miss Candice TONG Tel: 2527 8285
5 SAT (9, 12, 16, 19) (6)	HKMA MPS CME – Mastering Professional Interactions Organiser: The Hong Kong Medical Association, Speakers: Dr. Ka-lam HAU & Dr. Andy CHEUNG, Venue: Various 3rd Guangdong, Hong Kong and Macau Sports Meet Organiser: The Hong Kong Medical Association	HKMA CME Department Tel: 2527 8452 2.5 CME Points Miss Alice TANG & Miss Sharon HUNG Tel: 2527 8285
6 SUN 2:00 pm 2:00 pm / 6:30 pm (10, 17, 23, 24)	HKMA Certificate Course on Family Medicine 2011 Organiser: The Hong Kong Medical Association, Speakers: Prof. Martin Chi-sang WONG & Dr. Kelvin KF TSOI, Venue: Queen Elizabeth Hospital	HKMA CME Department Tel: 2527 8452 2.5 CME Points Miss Nadia HO Tel: 2527 8285
	HKMA MPS CME – Mastering Difficult Interactions with Patients Organiser: The Hong Kong Medical Association, Speaker: Dr. Justin CHENG, Venue: Holiday Inn, or The Hong Kong Medical Association Central Premises, Dr. Li Shu Pui Professional Education Centre, 2/F., Chinese Club Building, 21-22 Connaught Road Central, Hong Kong	
	Beat Drugs Public Education Day Organiser: The Hong Kong Medical Association, Venue: Tai Po	Miss Nadia HO Tel: 2527 8285
8 TUE 1:00 pm	HKMA Kln West Community Network -Treatment of Major Depressive Disorder Organiser: HKMA Kln West Community Network, Chairman: Dr. Raymond Ngam LAM, Speaker: Dr. Ka-lik KWAN, Venue: Crystal Room I-III, 30/F., Panda Hotel, Tsuen Wan, NT	Miss Candice TONG Tel: 2527 8285
9 WED 7:30 am 1:00 pm	Hong Kong Neurosurgical Society Monthly Academic Meeting – War against Glioma: from Molecules to Patients Organiser: Hong Kong Neurosurgical Society, Chairman: Dr. Danny CHAN, Speaker: Dr. Jane LAU, Venue: Seminar Room, G/F, Block A, Queen Elizabeth Hospital, Kowloon	Dr. Gilberto LEUNG Tel: 2255 3368 Fax: 2818 4350
	HKMA CW&S Community Network - Alternative Management of Vaginal Infection and Recurrent Vaginitis Organiser: HKMA CW&S Community Network, Speaker: Dr. Claire LAU, Venue: Central Premises	Mr. Alan LAW Tel: 2527 8285
10 THU 12:45 pm 1:00 pm 2:00 pm	Kln East Community Network –Certificate Course on Allergic Rhinitis & Asthma (Session 3) Organiser: Kln East Community Network, Chairman: Dr. Gary Ka-kui AU, Speaker: Dr. Anthony Chung-yan CHAN, Venue: Lei Garden, Kwun Tong, Kowloon	Mr. Alan LAW Tel: 2527 8285 1.5 CME Points
	HKMA NTW Community Network –Update in Osteoporosis Management and the role of Bisphosphonates Organiser: HKMA NTW Community Network, Venue: Plentiful Delight Banquet, Yuen Long, NT	Mr. Alan LAW Tel: 2527 8285
	HKMA Structured CME Programme with Hong Kong Sanatorium & Hospital Year 2011 – New Frontiers in Therapeutic Endoscopy Organiser: The Hong Kong Medical Association, Chairman: Dr. Grace Sau-wai WONG, Speaker: Angus CW CHAN, Venue: The Hong Kong Medical Association Central Premises, Dr. Li Shu Pui Professional Education Centre, 2/F., Chinese Club Building, 21-22 Connaught Road Central, Hong Kong	HKMA CME Department Tel: 2527 8452 1 CME Point
12 SAT 2:30 pm	Refresher Course for Health Care Providers 2011/2012 Organiser: The Hong Kong Medical Association, Speaker: Cecilia WONG, Venue: OLMH	HKMA CME Department Tel: 2527 8452 2 CME Points
13 SUN 1:00 pm (20, 27)	HKMA Family Sports Day Organiser: The Hong Kong Medical Association, Venue: Stanley Ho Sports Centre	Miss Alice TANG & Miss Sharon HUNG Tel: 2527 8285
	HKMA Tennis Tournament Organiser: The Hong Kong Medical Association, Venue: Kowloon Tong Club	Miss Alice TANG & Miss Sharon HUNG Tel: 2527 8285
15 TUE 1:00 pm (22, 29)	HKMA Kln West Community Network - Certificate Course on Eye Diseases (Session I – Session 3) Organiser: HKMA Kln West Community Network, Chairmen: Dr. Pak-chin CHOW, Dr. Bernard Siu-man CHAN & Dr. Kai-sing TONG, Venue: Lecture Theatre, LG2, Nurses Quarter, Princess Margaret Hospital, 232 Lai King Hill Road, Lai Chi Kok, Kowloon	Miss Candice TONG Tel: 2527 8285



Date / Time	Function	Enquiry / Remarks
15 TUE 1:15 pm	HKMA Eye Course – Advances in Ocular Imaging for Retina, Anterior Segment and Glaucoma Organiser: The Hong Kong Medical Association, Chairman: Dr. William Kin-ying LEUNG, Speakers: Dr. Jonathan Moon-kwong TSANG & Dr. Nancy Shi-yin YUEN, Venue: The Hong Kong Medical Association Central Premises, Dr. Li Shu Pui Professional Education Centre, 2/F., Chinese Club Building, 21-22 Connaught Road Central, Hong Kong	HKMA CME Department Tel: 2527 8452 1 CME Point
17 THU 7:00 pm – 8:00 pm 8:30 pm – 10:00 pm	FMSHK Executive Committee and Council Meeting Organiser: The Federation of Medical Societies of Hong Kong, Venue: Council Chambers, 4/F., Duke of Windsor Social Service Building, 15 Hennessy Road, Wanchai, Hong Kong FMSHK and HKFMS Foundation Annual General Meeting Organiser: The Federation of Medical Societies of Hong Kong and HKFMS Foundation Limited, Venue: Lecture Hall, 4/F., Duke of Windsor Social Service Building, 15 Hennessy Road, Wanchai, Hong Kong	Ms. Sonia CHEUNG Tel: 2527 8898 Fax: 2865 0345 Ms. Sonia CHEUNG Tel: 2527 8898 Fax: 2865 0345
18 FRI (19, 20)	Oxfam Trailwalker 2011 Organiser: The Hong Kong Medical Association, Venue: MacLehose Trail	Miss Alice TANG & Miss Sharon HUNG Tel: 2527 8285
19 SAT 1:30 pm	HKMA – KLN East Community Network; HA – UCH; HKCFP - CME Course for Health Personnel 2011 Organiser: HKMA – KLN East Community Network, Chairman: Dr. Man-wo TSANG, Speaker: Dr. Chiu-sun YUE, Venue: United Christian Hospital	Mr. Alan LAW Tel: 2527 8285 1.5 CME Point
22 TUE 1:00 pm	HKMA Yau Tsim Mong Community Network - Practical Management of Parkinson's Diseases Organiser: HKMA - Yau Tsim Mong Community Network, Chairman: Dr. Chung-ping HO, MH, JP, Speaker: Dr. Lawrence Man-wai LO, Venue: Pearl Ballroom, Level 2, Eaton Smart, Hong Kong, 380 Nathan Road, Kowloon	Miss Candice TONG Tel: 2527 8285
24 THU 1:00 pm	HKMA HKE Community Network – Current Management on Sleep Disorder Breathing Organiser: HKMA HKE Community Network, Chairman: Dr. Dominic Ying-nam YOUNG, Speaker: Dr. Chun-kuen CHOW, Venue: HKMA Head Office, 5/F., Duke of Windsor Social Service Building, 15 Hennessy Road, Hong Kong	Miss Candice TONG Tel: 2527 8285 1 CME Point
1:00 pm	HKMA Kln East Community Network - The Latest Development of Female Contraception Organiser: HKMA Kln East Community Network, Chairman: Dr. Gary Ka-kui AU, Speaker: Dr. Pansy Wai-ye LAM, Venue: Lei Garden, Kwun Tong, Kowloon	Mr. Alan LAW Tel: 2527 8285 1 CME Point
1:00 pm	HKMA NTW Community Network –“Androgenetic Alopecia (Hair Loss) in Men –Current Treatment Trend” Organiser: HKMA NTW Community Network, Speaker: Dr. Bertram Man-fai NG, Venue: Plentiful Delight Banquet, Yuen Long, NT	Mr. Alan LAW Tel: 25278285 1 CME Point
26 SAT 1:00 pm	HKMA YTMCN and Kowloon Central Cluster – Certificate Course on Bringing Better Health to Our Community (Lecture 6) Organiser: HKMA YTMCN and Kowloon Central Cluster, Speakers: Dr. Man-po LEE & Dr. Ying-fai MAK, Venue: Block M, Lecture Theatre, Queen Elizabeth Hospital, 30 Gascoigne Road, Kowloon, Hong Kong	Miss Candice TONG Tel: 2527 8285
3:00 pm	HKMA Trailwalker Reunion Party Organiser: The Hong Kong Medical Association, Venue: The Hong Kong Medical Association Central Premises, Dr. Li Shu Pui Professional Education Centre, 2/F., Chinese Club Building, 21-22 Connaught Road Central, Hong Kong	Miss Alice TANG & Miss Sharon HUNG Tel: 2527 8285
29 TUE 1:45 pm	HKMA Tai Po Community Network – “Who Am I” Organiser: HKMA Tai Po Community Network, Dr. Joseph Wan-ye LAU, Venue: Tai Po	Ms. Joyce Tel: 2664 3808 1 CME Point

Dermatological Quiz



Dermatological Quiz

Dr. Ka-ho LAU

MBBS(HK), FRCP(Edin, Glasg), FHKCP, FHKAM(Med)
Yaumatei Dermatology Clinic, Social Hygiene Service



Dr. Ka-ho LAU

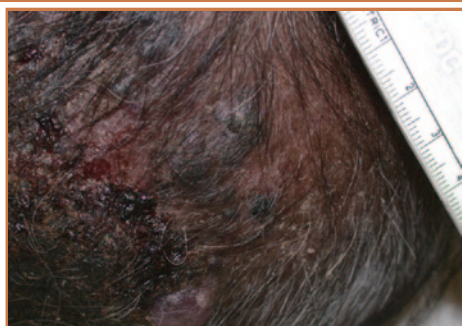


Fig 1: Multiple lesions on scalp (close up)

This 85 year-old man noticed a red lump developed over his scalp for 6 months which rapidly increased in size. Similar new lesions occurred around the old ones with bleeding and ulceration (Fig 1). His past health was unremarkable and there was no history of trauma at the scalp. He has been seen by various doctors and tried various topical treatments with no improvement.

Questions:

1. What is your clinical diagnosis or differential diagnoses?
2. How will you confirm the diagnosis?
3. How will you manage this man?

(See P.32 for answers)



Answer to Dermatological Quiz

- This elderly man developed these erythematous violaceous vascular haemangiomatic nodules and plaques over his scalp, which rapidly increased in size despite various treatments, together with new surrounding lesions arose while the old lesions ulcerated. The presentation was very suggestive of a malignant skin disease. The clinical diagnosis of angiosarcoma must be excluded. Other differential diagnoses would include Kaposi's sarcoma and other borderline/low-grade malignant vascular neoplasms such as Kaposiform haemangioendothelioma. Benign vascular lesions such as pyogenic granuloma was less likely.
- An urgent skin biopsy is needed to confirm or exclude the diagnosis of angiosarcoma. Histology of the scalp biopsy of this patient showed well to moderately-differentiated areas displaying an anastomosing network of sinusoidal vessels, most of them were bloodless, lined by a single layer of endothelial cells of slight to moderate nuclear atypia. These exhibited a highly infiltrative pattern, splitting apart collagen bundles and groups of adipose cells. Most angiosarcomas immunoreact positively for CD31 and CD34, with CD31 being the more sensitive and endothelium-specific of the two.

Angiosarcoma is an uncommon malignant neoplasm of the endothelium, accounting for less than 1% of all sarcomas. It has a predilection for the skin and superficial soft tissues and most commonly affects the scalp and face of elderly patients and areas of chronic lymphoedema or radiodermatitis.
- Wide local excision of clinically evident tumours with or without skin graft to achieve a negative surgical margin and then followed by wide field irradiation is recommended if the patient's condition allows. The prognosis is relatively poor, with fewer than 15% of patients surviving 5 years. Most long term survivors received early radical ablative surgery. For those fragile elderly patients who cannot tolerate extensive surgical excision, radiotherapy alone can offer some local disease control. Metastatic disease is not uncommon and treatment is mainly palliative as all metastatic patients will eventually die of the disease.

Dr. Ka-ho LAU

MBBS(HK), FRCP(Edin, Glasg), FHKCP, FHKAM(Med)
Yaumatei Dermatology Clinic, Social Hygiene Service

The Federation of Medical Societies of Hong Kong
4/F Duke of Windsor Social Service Building, 15 Hennessy Road, Wanchai, HK
Tel: 2527 8898 Fax: 2865 0345

Patron	The Honourable Donald TSANG, GBM	曾蔭權先生
President	Dr. LO See-kit, Raymond	勞思傑醫生
1st Vice-President	Prof. CHAN Chi-fung, Godfrey	陳志峰教授
2nd Vice-President	Dr. LO Sze-ching, Susanna	盧時楨醫生
Hon. Treasurer	Mr. LEE Cheung-mei, Benjamin	李祥美先生
Hon. Secretary	Dr. CHAN Sai-kwing	陳世炯醫生
Executive Committee Members	Dr. CHAN Chi-wing, Timmy Dr. CHAN Chun-kwong, Jane Dr. CHAN Hau-ngai, Kingsley Prof. CHIM Chor-sang, James Dr. HUNG Che-wai, Terry Ms. KU Wai-yin, Ellen Dr. LEUNG Ka-kit, Gilberto Dr. MAN Chi-wai Dr. MOK Chun-on Dr. NG Yin-kwok Dr. WONG Mo-lin, Maureen Ms. YAP Woan-tyng, Tina Dr. YU Chau-leung, Edwin Dr. YUEN Shi-yin, Nancy	陳智榮醫生 陳光醫生 陳厚毅醫生 詹楚生教授 洪致偉醫生 梁嘉傑醫生 文志倫醫生 吳嘉敏醫生 黃慕蓮醫生 葉婉婷女士 余秋良醫生 袁淑賢醫生

Founder Members

British Medical Association (Hong Kong Branch)
英國醫學會 (香港分會)

President	Dr. LO See-kit, Raymond	勞思傑醫生
Vice-President	Dr. WU, Adrian	鄒揚源醫生
Hon. Secretary	Dr. HUNG Che-wai, Terry	洪致偉醫生
Hon. Treasurer	Dr. LEUNG, Clarence	梁顯信醫生
Council Representatives	Dr. LO See-kit, Raymond Dr. CHEUNG Tse-ming Tel: 2527 8898 Fax: 2865 0345	勞思傑醫生 張子明醫生

The Hong Kong Medical Association
香港醫學會

President	Dr. CHOI Kin	蔡堅醫生
Vice-Presidents	Dr. CHAN Yee-shing, Alvin Dr. CHOW Pak-chin	陳以誠醫生 周伯展醫生
Hon. Secretary	Dr. LEE Fook-kay	李福基醫生
Hon. Treasurer	Dr. LEUNG Chi-chiu	梁子超醫生
Council Representatives	Dr. CHAN Yee-shing Dr. CHOW Pak-chin	陳以誠醫生 周伯展醫生
Chief Executive	Mrs. LEUNG, Yvonne Tel: 2527 8285 (General Office) 2527 8324 / 2536 9388 (Club House in Wanchai / Central) Fax: 2865 0943 (Wanchai), 2536 9398 (Central) Email: hkma@hkma.org Website: http://www.hkma.org	梁周月美女士

The HKFMS Foundation Limited 香港醫學組織聯合會基金

Board of Directors		
President	Dr. LO See-kit, Raymond	勞思傑醫生
1st Vice-President	Prof. CHAN Chi-fung, Godfrey	陳志峰教授
2nd Vice-President	Dr. LO Sze-ching, Susanna	盧時楨醫生
Hon. Treasurer	Mr. LEE Cheung-mei, Benjamin	李祥美先生
Hon. Secretary	Dr. CHAN Sai-kwing	陳世炯醫生
Directors	Mr. CHAN Yan-chi, Samuel Prof. CHIM Chor-sang, James Ms. KU Wai-yin, Ellen Dr. WONG Mo-lin, Maureen Dr. YU Chak-man, Aaron	陳恩賜先生 詹楚生教授 顧慧賢女士 黃慕蓮醫生 余則文醫生

stryker®

Craniomaxillofacial



Leibinger

The Federation Annual Dinner 2011

31st December, 2011 (Sat)

Run Run Shaw Hall

The Hong Kong Academy of Medicine Jockey Club Building

Performers of the evening: Ms. Suzan Guterres & Mr. Howard McCrary

Casablanca

Howard McCrary

Suzan Guterres 蘇珊小姐

Enjoy an Elegant & Chic New Year's Eve Celebration with our Federation's Friends!

Book your tickets now (\$1,000 HKD per person)

- ★ **Free Raffle Tickets for Early Bird before Oct 31**
- ★ **Top Raffle Prizes include Cathay Pacific air tickets & Swire Travel travel coupons**
- ★ **Gaming tables for charity**

Call the Federation Secretariat on 2527-8898 to reserve your tables!

Ms. Suzan Guterres 蘇珊小姐 - one of the most glamorous and gorgeous stars of our very own Hong Kong's entertainment industry, and has recently released her fabulous audiophile "Colors of Suzan".

Mr. Howard McCrary - The renowned, award winning singer, songwriter, producer, and also a Grammy Award nominee, who has worked with some of the US's most prestigious Artists such as Quincy Jones, Michael Jackson, Chaka Khan, Edwin Hawkins to name a few.



THE FEDERATION OF MEDICAL SOCIETIES OF HONG KONG

香 港 醫 學 組 織 聯 會