



Title	Hong Kong dollar in the Oesophagus
Author(s)	Yam, PPC; Tong, DKH; Law, S
Citation	Hong Kong Medical Journal, 2012, v. 18 n. 2, p. 166
Issued Date	2012
URL	http://hdl.handle.net/10722/148751
Rights	Hong Kong Medical Journal. Copyright © Hong Kong Academy of Medicine Press.

A 72-year-old woman with hypertension, old stroke, hyperlipidaemia, and Alzheimer's disease presented to the emergency department with a 2-day history of dysphagia and chest discomfort after taking her usual medicine. Physical examination showed no surgical emphysema; chest radiographs revealed there was a Hong Kong two dollar coin at the neck level (Fig 1). Oesophagoscopy identified the coin at 18 cm from the incisor (Fig 2). The coin was removed with rat-toothed forceps without difficulty. The coin measured 2.8 cm in its maximal diameter. The patient was discharged on the same day.

Coins are the most frequent non-food oesophageal foreign bodies in both children and adults.^{1,2} The main determinants whether a coin will lodge in the oesophagus are patient age, coin size, and the presence of oesophageal abnormalities.¹ For asymptomatic children without any underlying oesophageal or tracheal abnormality, an 8- to 16-hour period of observation is suggested, because there is a spontaneous passage rate of 25 to 30% and the risks of delayed retrieval are low.³ Adult coin ingestion

is usually associated with alcohol or drug use, psychiatric or mental disease, and being in prison.^{4,5} For this patient, her mental incapability probably attributed to the event. Impaction in the oesophagus requires a diameter of 22 mm or greater, unless there is some structural abnormality.² The oesophagus has four regions of anatomic narrowing: the level of the cricopharyngeus, the aortic arch, the left main stem bronchus, and the lower oesophageal sphincter. In multiple series, the cervical portion has the highest reported rate of involvement.¹ Smaller coins usually pass through the oesophagus without incident, but may become lodged if there is a pre-existing abnormality, such as a stricture or diverticulum.

Patricia PC Yam, MB, ChB

Daniel KH Tong, MS, FRACS

Simon Law, MS, FRCS (Edin)

Email: slaw@hku.hk

Department of Surgery

The University of Hong Kong

Queen Mary Hospital, Pokfulam, Hong Kong

References

1. Yoshida CM, Peura DA. Foreign bodies. In: Castell DO, Richter JE, editors. The esophagus. 3rd ed. Philadelphia, Pa: Lippincott Williams & Wilkins; 1999: 335-48.
2. Taylor RB. Esophageal foreign bodies. *Emerg Med Clin North Am* 1987;5:301-11.
3. Waltzman ML, Baskin M, Wypij D, Mooney D, Jones D, Fleisher G. A randomized clinical trial of the management of esophageal coins in children. *Pediatrics* 2005;116:614-9.
4. Webb WA. Management of foreign bodies of the upper gastrointestinal tract: update. *Gastrointest Endosc* 1995;41:39-51.
5. Carp L. Foreign bodies in the gastrointestinal tracts of psychotic patients. *Arch Surg* 1950;60:1055-75.

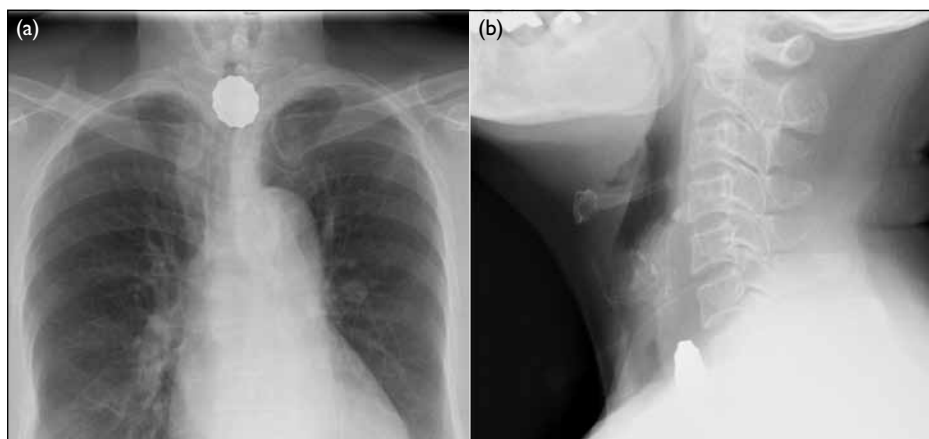


FIG 1. (a) Chest X-ray: anterolateral, and (b) lateral X-ray of neck

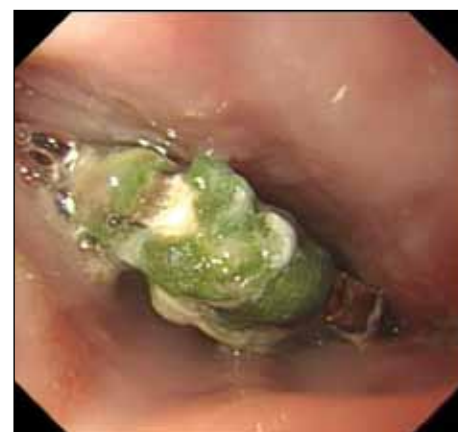

FIG 2. Endoscopic view of the coin, 18 cm from the incisor