



Title	Transhepatic placement of haemodialysis catheter: A solution for vascular access exhaustion
Author(s)	Yap, DYH; Tso, WK; Chu, FSK; Chan, TM; Lai, KN; Tang, SCW
Citation	Nephrology, 2010, v. 15 n. 6, p. 661-662
Issued Date	2010
URL	http://hdl.handle.net/10722/143272
Rights	The definitive version is available at www.blackwell-synergy.com

Transhepatic placement of hemodialysis catheter: a solution for vascular access exhaustion

Desmond Yat Hin YAP¹, Wai Kuen TSO², Ferdinand Siu Kay CHU², Tak Mao CHAN¹, Kar Neng LAI¹, Sydney Chi Wai TANG¹

¹Division of Nephrology, Department of Medicine, Queen Mary Hospital, University of Hong Kong, Hong Kong SAR

²Department of Radiology, Queen Mary Hospital, Hong Kong, Hong Kong SAR

Running title: Portal venous access for HD

Keywords: interventional radiology, hemodialysis, vascular access

Disclosures: No conflict of interest to declare

Word Count: 393

Correspondence:

Dr. Sydney Chi Wai Tang

Associate Professor

Division of Nephrology

Department of Medicine

Queen Mary Hospital

University of Hong Kong

Hong Kong SAR

Tel: (852)-2855 3879

Fax: (852) 2872 5828

Email: scwtang@hkucc.hku.hk

We report the successful hemodialysis via access to the portal vein in a patient whose jugular, subclavian and femoral veins were all exhausted.

A fifty-year-old woman suffered from end stage renal failure due to lupus nephritis. She was switched to hemodialysis after ten years of peritoneal dialysis. Creation of arterio-venous fistulae or grafts in both upper limbs was unsuccessful and catheter thrombosis occurred in the jugular, subclavian and femoral regions bilaterally. The anterior branch of the right portal vein was cannulated using a 21-G needle under fluoroscopic guidance. A Retrocath[®] (45 cm long; 16 Fr) was then lodged into the portal venous system [Figure 1] and this catheter remained functional for 3 months.

In localities where peritoneal dialysis is the predominant mode of renal replacement therapy, the initial creation of AV fistulae or grafts is often problematic when patients require hemodialysis. This may be due to extensive calcifications aggravating vasculopathic changes with increased dialysis vintage. Placement of tunneled catheter in the traditional sites became increasingly difficult. In this context, the transhepatic approach is a promising solution to the problem. This approach was first described by Po *et al.* in 1994.¹ Later, Stavropoulos *et al.*² reported a series with a high technical success rate of catheter insertion but a low mean primary and secondary patency duration. Complications associated with the transhepatic approach, though infrequent, include line sepsis, catheter migration, thrombosis and bleeding.^{2,3} Hemorrhagic pleural effusion and intra-peritoneal hemorrhage, though rare, can be life-threatening.^{2,3} These complications can be minimized when the procedure is performed by an interventional radiologist who is familiar with portal venous cholangiography as in our case. Alternative approaches such as percutaneous trans-renal or trans-lumbar IVC cannulation have also been described.^{4,5} Expertise to cannulating these venous systems is a prerequisite.

REFERENCES

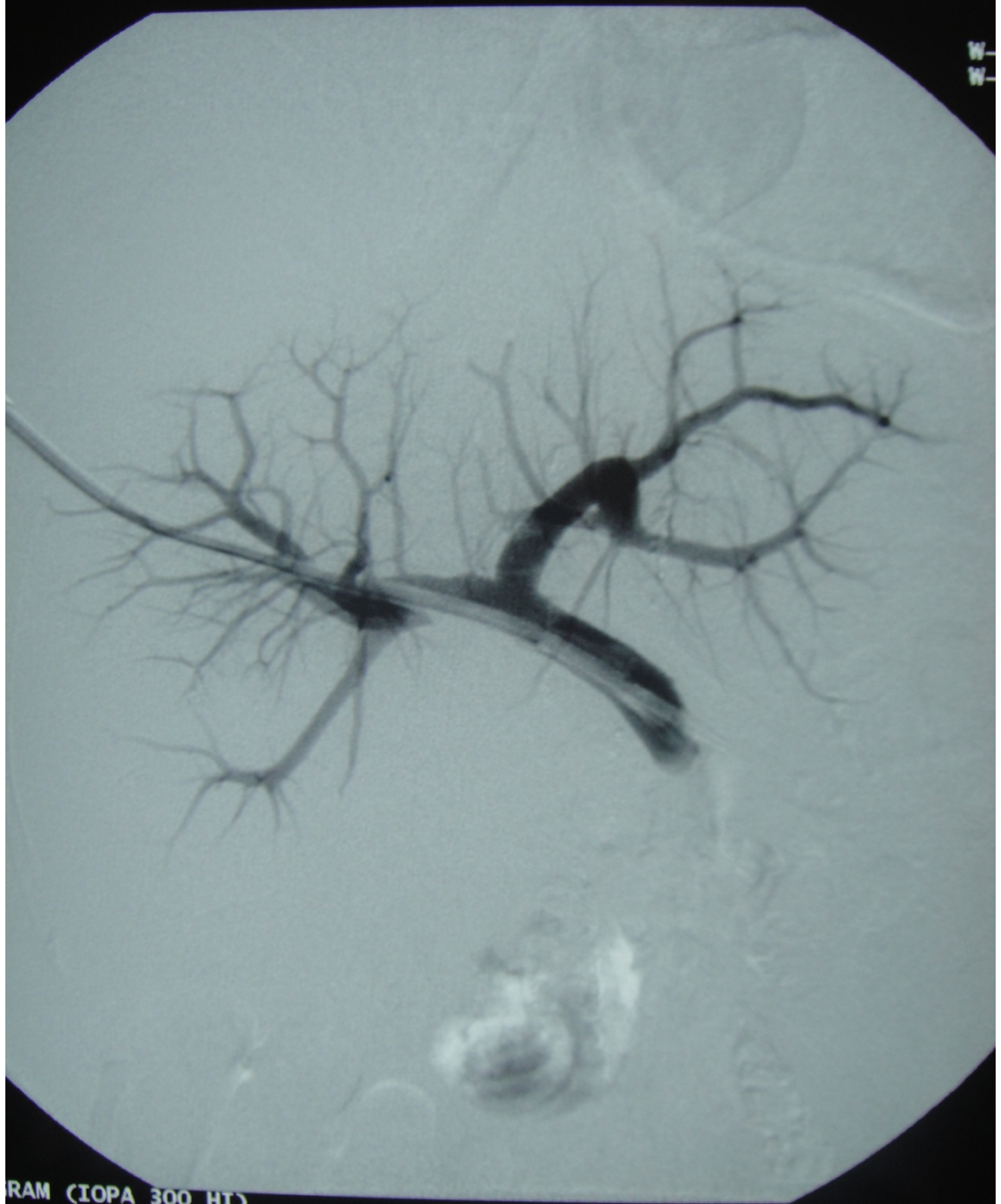
1. Po CL, Koolpe HA, Allen S *et al.* Transhepatic PermCath for hemodialysis. *Am. J. Kidney Dis.* 1994; **24**: 590-1.
2. Stavropoulos SW, Pan JJ, Clark TW *et al.* Percutaneous transhepatic venous access for hemodialysis. *J. Vasc. Interv. Radiol.* 2003; **14**:1187-90.
3. Smith TP, Ryan JM, Reddan DN. Transhepatic catheter access for hemodialysis. *Radiology* 2004; **232**: 246-51.
4. Rajan DK, Crotau DL, Sturza SG *et al.* Translumbar placement of inferior vena cava catheters: a solution for challenging hemodialysis Access. *Radiographics* 1998; **18**:1155-67.
5. Murthy R, Arbazadeh M, Lund G *et al.* Percutaneous transrenal hemodialysis catheter insertion. *J. Vasc. Interv. Radiol.* 2002; **13**:1043-6.

Figure Legend

Fig. 1 Transhepatic placement of a Retrocath[®] (45cm long; 16 Fr) into the portal vein. Contrast was injected to confirm the successful cannulation of the portal venous system.

26.05.20

W-
W-



RAM (IOPA 300 HI)

26.05.2009