



Title	A man with hypophosphataemia
Author(s)	Lam, JK; Lam, CW; Kung, AW; Tan, KC; Lau, KS; Lam, KS
Citation	Bmj (Clinical Research Ed.), 2011, v. 342, p. d773
Issued Date	2011
URL	http://hdl.handle.net/10722/139923
Rights	Creative Commons: Attribution 3.0 Hong Kong License

ENDGAMES

We welcome contributions that would help doctors with postgraduate examinations
See bmj.com/endgames for details

FOR SHORT ANSWERS

See p 707

FOR LONG ANSWERS

Go to the Education channel on bmj.com

CASE REPORT

A man with hypophosphataemia

A 76 year old man was referred with hypophosphataemia. He had a history of hypertension and gout. He presented with a six month history of generalised bone pain and lower limb weakness. Examination showed weak hip flexion and extension (power 4/5). Complete blood count, serum glucose, and kidney function tests were normal. Serum calcium was 2.33 mmol/L (normal 2.10-2.60), serum phosphate was 0.49 mmol/L (0.8-1.4), and alkaline phosphatase was 204 U/L (47-124). He had no family history of hypophosphataemia or bone disorders.

Parathyroid hormone (PTH) was within the normal range (53 ng/L; normal 11-54). Serum calcidiol was low at 38 nmol/L (50-250), and serum calcitriol was also low at 26.8 pmol/L (65.3-171.9). Maximal tubular reabsorption of phosphate was 0.44-0.49 mmol/L (0.9-1.35). A skeletal survey (radiographs including posteroanterior view of the chest; anteroposterior and lateral views of the whole spine, humeruses, and femora; anteroposterior and lateral views of the skull; and anteroposterior view of the pelvis) showed no evidence of fracture or lytic lesion. Technetium-99m-methylene diphosphonate bone scintigraphy showed multiple hot spots over rib cage, involving the costochondral and costovertebral junctions. He was treated with phosphate 500 mg twice daily and calcitriol 0.25 µg daily.

- 1 What is the most likely diagnosis?
- 2 How would you investigate and confirm your diagnosis?
- 3 What is the pathophysiological basis of this condition?
- 4 What is the treatment of choice?

Submitted by J Lam, C W Lam, Annie W C Kung, Kathryn C B Tan, K S Lau, and Karen S L Lam
Cite this as: *BMJ* 2011;342:d773

STATISTICAL QUESTION

Observational study design I

Researchers investigated violence by intimate partners and associated factors among married women living in Tirana, the capital city of Albania. A national survey undertaken in April 2001 was used to compile a list of all married women aged 25 to 65 years living in Tirana. A representative sample of 1039 women was randomly selected from the list. In summer 2003 all women in the sample were sent a questionnaire asking for social and demographic characteristics of themselves and their husbands together with details of any intimate partner violence over the previous year. Thirty seven per cent of the women reported that they had experienced spousal violence.

Which of the following best describes the study design used above?

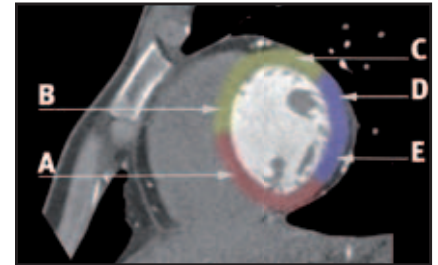
- a) Census
- b) Prospective cohort study
- c) Cross sectional study
- d) Retrospective cohort study

Submitted by Philip Sedgwick
Cite this as: *BMJ* 2011;342:d1742

ANATOMY QUIZ

Heart segments on short axis computed tomography section

Name the indicated segments (A-E) of the heart and their coronary arterial supply (colours) on this mid-cavity short axis computed tomography view.



Submitted by Jonathan Colledge and Shaun Quigley
Cite this as: *BMJ* 2011;342:d1834

CASE REPORT

A 42 year old man with bilateral exophthalmos and weight loss

A 42 year old white man who was concerned about a recent change in the appearance of his eyes was referred to the outpatient clinic for evaluation and treatment. He reported weight loss of more than 15 kg during the preceding six months, even though his appetite had been good. He was a smoker. Apart from alopecia universalis since childhood, he did not report any other significant medical history, and he was not taking any medication.

On examination he appeared restless. His body weight was 98 kg and height 168 cm. He was afebrile, with a resting tachycardia of 100 beats/min, and his blood pressure was 140/80 mm Hg. His skin was moist and warm, and there was fine tremor of the outstretched hands. He had marked bilateral exophthalmos associated with swelling and erythema of the eyelids and redness of the conjunctivae, as well as punctate keratopathy (corneal epithelial erosions). His eye movements were restricted, particularly upward gaze. His thyroid gland was diffusely enlarged with no tenderness on palpation.

- 1 What is the diagnosis on the basis of the clinical information provided?
- 2 What further investigations would you request?
- 3 What is the appropriate initial management of this condition?
- 4 How should the patient's eye disease be managed?

Submitted by Stelios Tigas and Agathocles Tsatsoulis
Cite this as: *BMJ* 2011;342:d1105

ON EXAMINATION QUIZ Risk factors for stroke

This week's question is on risk factors for stroke and is taken from the onExamination revision questions for the MRCGP exam.

A 78 year old male patient mentions to you, in passing, that he is worried he might have a stroke.

Which of the following is the single, strongest risk factor for developing a stroke?

- A Diabetes mellitus
- B Hypertension
- C Hypercholesterolaemia
- D Rheumatoid arthritis
- E Smoking