



Title	Intra-orbital distance as a record of social brain dysmorphology in autism
Author(s)	Cheung, C; Yu, GKK; Yam, A; Myint, V; Yee, YF; Chua, SE; McAlonan, GM
Citation	The 19th Annual Meeting of the International Society for Magnetic Resonance in Medicine (ISMRM 2011), Montreal, Canada, 7-13 May 2011. In Proceedings of the 19th ISMRM, 2011, p. 2522
Issued Date	2011
URL	http://hdl.handle.net/10722/135418
Rights	Creative Commons: Attribution 3.0 Hong Kong License

Intra-orbital distance as a record of social brain dysmorphology in autism.

C. Cheung¹, K. Yu¹, A. Yam², V. Myint³, Y. Yee⁴, S. Chua^{5,6}, and G. M. McAlonan^{5,7}

¹Psychiatry, University of Hong Kong, Pokfulam, Hong Kong, ²Neuroscience, University of Bristol, United Kingdom, ³Psychology, University of Cardiff, United Kingdom, ⁴University of Harvard, United States, ⁵Psychiatry, University of Hong Kong, Hong Kong, Hong Kong, ⁶State Key Laboratory for Brain and Cognitive Sciences, ⁷Key State Laboratory for Brain and Cognitive Sciences

Introduction

MPAs (minor physical anomalies) occur more frequently in neurodevelopmental disorders because face and brain are derived from neuroectoderm in the first trimester [1]. Conventionally, MPAs are measured by direct evaluation of external appearance but it is possible to quantify MPA using MRI. MRI circumvents potential observer bias; facilitates multi-centre data analysis and allows for simultaneous comparisons between intracranial (brain) anatomy and MPAs. Optical indices have a tightly synchronized developmental trajectory. For example, as head size increases with age, inter-orbital distance increases. This expansion is generally complete before 3 years and remains relatively fixed throughout the remainder of life [2]. Thus optical MPAs might provide a retrospective 'window' to early neurodevelopment. In autism, head size has been reported to expand dramatically up to the age of 2 years [3]. Thereafter growth is at a much slower rate than typically developing children and by mid childhood there is generally no discernible difference in overall brain size. We hypothesized that there would be increased inter-orbital distance in children with autism spectrum disorders. We also predicted that intra-orbital distance would be related to intra-regional brain anatomy in autism.

Methods

The groups comprised $n = 36$ children with autism spectrum and $n = 55$ age (6-16 years) and gender matched typically developing controls. All children had a normal IQ. Inter-orbital distance was measured on T1-weighted images acquired on a GE Signa 1.5 Tesla system (General Electric, Milwaukee, WI, USA). Images were aligned along the ac-pc line, and the axial slice that displayed the largest diameter for both eyes was used for measurement. The inter-orbital distance was defined as the most medial point of the orbits located at the point of intersection between nasal bone and eyeball [4]. All measurements were 'blind' to diagnosis and inter and intra-rater reliability was measured on 10 scans at 1 week interval, inter class coefficient = 0.95. Following methods previously described [5], we also acquired a T2/PD dataset from each child to conduct a voxel-wise linear regression of grey matter volume and inter-orbital distance in each group separately. We used Cambridge Brain Activation software (CAMBA) to assess the significance of three-dimensional cluster statistics by non-parametric permutation testing [6]. The statistical thresholds were corrected for multiple comparisons by controlling the 'family wise error rate' and results accepted when the number of false positive clusters expected under the null-hypothesis was < 1 , $p < 0.01$. Total brain volume and age were entered as covariates.

Results

Intra-orbital distance in the autism group was significantly greater than typically developing controls ($t = 2.16$, $p = 0.03$; Figure A). In the autism group only, there was a significant positive correlation between inter-orbital distance and the grey matter volume of the bilateral amygdala, extending to unci and inferio-medial poles of the temporal lobes bilaterally (with peak co-ordinates $x -26$, $y -7$, $z -30$; $r > 0.7$ and $x 28$, $y -23$, $z -32$; $r > 0.7$). There was no significant group difference in total grey matter or volume of the amygdala based region-of-interest highlighted in red in Figure B.

Figure A Intra-orbital distance in autism and controls

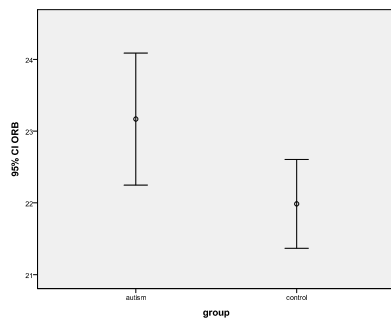
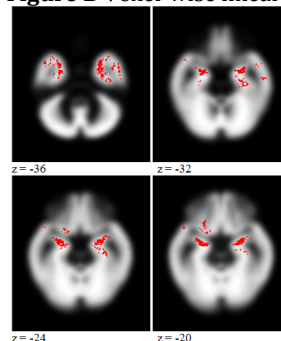


Figure B Voxel-wise linear regression



In Figure B regions with significant positive volumetric correlation with intra-orbital distance were concentrated in bilateral medial temporal lobe regions including the bilateral amygdala.

Discussion

Greater inter-orbital distance in the autism group relative to typically developing control children fits with a history of head size expansion during infancy in the autism group only. Inter-orbital distance was positively correlated with volumes in the interio-medial temporal lobe, including the amygdalae. This perhaps indicates that MPAs in autism may go hand-in-hand with "social brain" dysmorphology. Thus optical MPAs may provide a "fossil record" of early brain dysmaturation in autism.

References: 1. Tripi et al. 2008 *Early Hum Dev*, 84, 217-23; 2. Cohen 2002 *Am J Med Genet*, 115, 245-68; 3. Courchesne et al. 2001 *Neurology*, 57, 245-54. 4. Boyes et al. 2001 *Schizophr Res*, 50, 1-2; 5. McAlonan et al. 2009 *Br J Psychiatry*, 194, 123-9; Bullmore et al. 1999 *IEEE Transactions on medical imaging* 18.