



Title	Cadaveric Study of Zone 2 Flexor Hallucis Longus Tendon Sheath
Author(s)	Lui, TH; Chan, KB; Chan, LK
Citation	Arthroscopy - Journal Of Arthroscopic And Related Surgery, 2010, v. 26 n. 6, p. 808-812
Issued Date	2010
URL	http://hdl.handle.net/10722/127713
Rights	Creative Commons: Attribution 3.0 Hong Kong License

Manuscript Number: ARTH-09-283R2

Title: Cadaveric Study of Zone 2 Flexor Hallucis Longus Tendon Sheath

Article Type: Original Article

Keywords: flexor hallucis longus; tendon; sheath; tendoscopy; Arthroscopy; endoscopy

Corresponding Author: Dr. Tun Hing Lui, F.R.C.S.(Edin)

Corresponding Author's Institution: North District Hospital

First Author: Tun Hing Lui, F.R.C.S.(Edin)

Order of Authors: Tun Hing Lui, F.R.C.S.(Edin); Kwok Bill Chan, MBBS (HK), FRCS (Edin), FHKAM, FHKCOS; Lap Ki Chan, BSc (Biomed), MBBS (HK), PhD (Duke), FHKCOS, FHKAM

Abstract: Purpose: The purpose of this study is to study the anatomy of the zone 2 flexor hallucis longus (FHL) tendon sheath

Methods: Dissection of the zone 2 FHL tendon sheath was performed in 12 feet of 6 cadaveric bodies. The tendon sheath was subdivided into proximal fibrous (zone 2A) and distal fascial (zone 2B) parts. The lengths of the zone 2A and 2B FHL tendon were measured and represented the length of the corresponding tendon sheaths and the relationship of the medial plantar nerve to each part of the zone 2 FHL tendon sheath was studied.

Result: In all specimens, there were fibrous and fascial components of the zone 2 FHL tendon sheath. The medial plantar nerve crossed the zone 2 B tendon sheaths and then became plantar lateral to the sheath in 7 specimens. The distance between the medial plantar nerve and the orifice of the zone 2A tendon sheath averaged 7.6mm. The distance between the medial plantar nerve and the junction between zones 2A and 2B averaged 3.2mm. The distance between the medial plantar nerve and the distal end of the zone 2B tendon sheath averaged 4.2mm. The average length of the zone 2A tendon sheath was 35.9mm and the average length of the zone 2B tendon sheath was 30.5mm.

Conclusions: Zone 2 flexor hallucis longus tendon sheath can be subdivided into proximal fibrous (zone 2A) and distal fascial (zone 2B) one. Because of the close approximation of the medial plantar nerve to the tendon sheath, there is a significant risk of iatrogenic nerve injury when surgical procedures are performed in zone 2B.

Clinical Relevance: The understanding of the anatomy of the zone 2 flexor hallucis longus tendon sheath is useful for safe practice of zone 2 flexor hallucis longus tendoscopy.

Cadeveric Study of Zone 2 Flexor Hallucis Longus Tendon Sheath

Tun Hing Lui, M.B.B.S.(HK), F.R.C.S.(Edin), F.H.K.A.M., F.H.K.C.O.S.,
Kwok Bill Chan, M.B.B.S.(HK), F.R.C.S.(Edin), F.H.K.A.M., F.H.K.C.O.S.,
and Lap Ki Chan, B.Sc.(Biomed), M.B.B.S.(HK), Ph.D., F.H.K.C.O.S.,
F.H.K.A.M.(Orth), F.R.C.S.(Edin)

Lui, Tun Hing, MBBS (HK), FRCS (Edin), FHKAM, FHKCOS
Consultant

Department of Orthopaedics and Traumatology, North District Hospital, 9 Po Kin
Road, Sheung Shui, NT, Hong Kong SAR, China.

Telephone: (852) 26837588

Email: luithderek@yahoo.co.uk

Chan, Kwok Bill, MBBS (HK), FRCS (Edin), FHKAM, FHKCOS
Associate Consultant

Department of Orthopaedics and Traumatology, North District Hospital, 9 Po Kin
Road, Sheung Shui, NT, Hong Kong SAR, China

Chan, Lap Ki, BSc (Biomed), MBBS (HK), PhD (Duke), FHKCOS, FHKAM (Ortho),
FRCS (Edin)

Associate Professor

Institute of Medical and Health Sciences Education and Department of Anatomy, The
University of Hong Kong Li Ka Shing Faculty of Medicine

Proofs and reprint requests should be addressed to Dr TH Lui

Supported by outside funding or grant(s) from

N/A.

One or more of the researchers or an affiliated institute

N/A ******(supply specific name(s)/initials or enter
"N/A") ****** has received (or agreed to receive) from a commercial entity something of
value (exceeding the equivalent of US\$500) related in any way to this manuscript or
research. *******Enter "N/A" or supply the name(s) of the commercial
entity(ies) ******* N/A.

Research was performed at Hong Kong (if
different from affiliation of any of the authors).

Cadaveric Study of Zone 2 Flexor Hallucis Longus Tendon Sheath

Abstract

Purpose: The purpose of this study was to investigate the anatomy of the zone 2 flexor hallucis longus (FHL) tendon sheath.

Methods: Dissection of the zone 2 FHL tendon sheath was performed in 12 feet of 6 cadaveric bodies. The tendon sheath was subdivided into proximal fibrous (zone 2A) and distal fascial (zone 2B) parts. The lengths of the zone 2A and 2B FHL tendon were measured and represented the length of the corresponding tendon sheaths and the relationship of the medial plantar nerve to each part of the zone 2 FHL tendon sheath was studied.

Result: In all specimens, there were fibrous and fascial components of the zone 2 FHL tendon sheath. The medial plantar nerve crossed the zone 2 B tendon sheaths and then became plantar lateral to the sheath in 7 specimens. The distance between the medial plantar nerve and the orifice of the zone 2A tendon sheath averaged 7.6mm. The distance between the medial plantar nerve and the junction between zones 2A and 2B averaged 3.2mm. The distance between the medial plantar nerve and the distal end of the zone 2B tendon sheath averaged 4.2mm. The average length of the zone 2A tendon sheath was 35.9mm and the average length of the zone 2B tendon sheath was 30.5mm.

Conclusions: The zone 2 flexor hallucis longus tendon sheath can be subdivided into a proximal fibrous zone (2A) and a distal fascial zone (2B). Because of the close approximation of the medial plantar nerve to the tendon sheath, there is a significant risk of iatrogenic nerve injury when surgical procedures are performed in zone 2B.

Clinical Relevance: The understanding of the anatomy of the zone 2 flexor hallucis	1
longus tendon sheath is useful for the safe practice of zone 2 flexor hallucis longus	2
tendoscopy.	3
Key Words: flexor hallucis longus; tendon; sheath; tendoscopy; arthroscopy;	4
endoscopy	5
	6

Introduction

1
2
3 The indications for arthroscopy and endoscopy of the foot and ankle have expanded in
4 recent years. Tendoscopy is an endoscopy of the tendon sheath and has been
5 described in various tendons of foot and ankle, including posterior tibial tendon
6 (1,2,3), peroneal tendons (4,5), long toe flexor tendons (6) and anterior tibial tendon
7 (7). Recently, Lui et al described the technique of flexor hallucis longus (FHL)
8 tendoscopy (8,9,10). Flexor hallucis longus tendon is a deep seated tendon in most of
9 its course. It can be divided into 3 zones (10). Zone 1 tendon is behind the ankle and
10 can be examined through the posterior ankle endoscopy (12). Zone 3 tendon is from
11 the knot of Henry to its phalangeal insertion and can be examined by toe flexor
12 tendoscopy (7). Zone 2 tendon includes the part underneath the sustentaculum tali to
13 the knot of Henry. It is the deep part of the tendon and close to the medial plantar
14 nerve. This minimally invasive approach has been utilized for synovectomy of zone 2
15 FHL tenosynovitis (10) and endoscopic FHL transfer for chronic Achilles tendon
16 rupture (9). Lui et al have performed a cadaveric study to confirm the efficacy of the
17 zone 2 FHL tendoscopy (11). From the study, a fascia deep to the flexor digitorum
18 brevis muscle is identified and stated to be the landmark for the medial plantar nerve.
19 The purpose of this cadaveric study was to study the anatomy of the zone 2 FHL and
20 the relationship with the medial plantar nerve. We hypothesized that tendoscopy of
21 the FHL in Zone 2 is risky given the close proximity of the medial plantar nerve.

Methods

Twelve fresh-frozen cadaver specimens in 6 cadaver bodies were used for this study. The average age was 66.8 years old (51-74 years). None of the cadavers had deformity or scars of their foot and ankle regions on gross inspection. A longitudinal incision was made on the lateral margin of the Achilles tendon and just above the insertion of the Achilles tendon. The FHL tendon at the posterior ankle was identified and a 4mm metal rod was inserted into the tendon sheath and advanced until it penetrated the plantar aponeurosis and reach the plantar skin. A stab wound was made at the tip of the metal rod and the plantar portal of the original zone 2 FHL tendoscopy was then made (**Fig 1**). The incisions were connected and the medial plantar nerve (**Fig 2**) and zone 2 FHL tendon sheath were identified. The tendon sheath of the zone 2 FHL was subdivided into proximal fibrous one (zone 2A) and the distal fascial one (zone 2B) (**Fig 3**). The transition from the fibrous sheath to the fascial sheath was quite a sudden in all specimens and was easily identified by direct vision. The relationship between the nerve and each part of the FHL tendon sheath was studied. The distance between the nerve and the tendon sheath was measured at three sites that can be located arthroscopically: at the orifice of the zone 2A tendon sheath, the junction between the zones 2A and 2B, the distal end of the zone 2B tendon sheath. The orifice of the fibrous tendon sheath was defined by the posterior talar tubercles and the ligament in between and it is a consistent anatomic landmark that can be identified during posterior ankle endoscopy. The distal end of the zone 2B tendon sheath is the point where the rod pierced the fascial sheath. It is the point where the arthroscopic view transit from muscle of the flexor digitorum brevis to the fascial sheath when the arthroscope is withdrawn from the plantar portal at clinical setting.

The nerve was then reflected and FHL tendon was pinned at the orifice of the fibrous tendon sheath, the junction between the fibrous and fascial tendon sheath and the exit point of the metal rod. The tendon sheath was cut open and the FHL tendon was cut at the pinned sites. The lengths of the zone 2A and 2B FHL tendon were then measured (Fig 4). The lengths of the tendon segments represented the lengths of the corresponding length of the zone A and B tendon sheaths.

1
2
3
4
5
6
7

Results

In all specimens, there were fibrous and fascial components of the zone 2 FHL tendon sheath. The medial plantar nerve was at the plantar medial side of the zone 2A (fibrous) tendon sheath in all specimens. The nerve was either medial or plantar medial to the zone 2B (fascial) tendon sheath in 5 specimens. It crossed the zone 2 B tendon sheaths and then became plantar lateral to the sheath in 7 specimens. All of them were within the proximal 6mm of the zone 2B tendon sheath (0mm-6mm). The distance between the medial plantar nerve and the orifice of the zone 2A tendon sheath averaged 7.6mm (3mm to 12mm). The distance between the medial plantar nerve and the junction between zones 2A and 2B averaged 3.2mm (0mm to 7mm). The distance between the medial plantar nerve and the distal end of the zone 2B tendon sheath averaged 4.2mm (2mm to 6mm) (**Table 1**).

The average length of the zone 2A tendon sheath was 35.9mm (26-41) and the average length of the zone 2B tendon sheath was 30.5mm (22-37). In all specimens, the length of the zone 2A tendon sheath was longer than the zone 2B tendon sheath. The average ratio of the length of the zone 2A to that of the zone 2B tendon sheath was 1.18 (1.07-1.29).

Discussion

1

2

Lui et al have confirmed the efficacy of the zone 2 FHL tendoscopy (11). In his study, the fascia deep to the extensor digitorum brevis (EDB) muscle is the anatomic landmark of the location of the medial plantar nerve. From our study, we believe that it should represent the discrete fascial tendon sheath (zone 2B) rather than a loose deep fascia of the EDB muscle. The zone 2B tendon sheath was a well defined and thin structure.

9

In our study, the zone 2A and 2B tendon lengths which represented the lengths of the corresponding tendon sheath were similar although the length of the zone 2A tendon was a bit longer. The lengths of the zones 2A and 2B provided clinical guideline of the location of the transition between zone 2A and 2B. During clinical practice, if the posteromedial portal is the visualization portal (which is the usual practice), the arthroscope will exit the plantar portal and then withdrawn. When it is withdrawn, it passes through the EDB muscle and then the zone 2B tendon sheath. When it is withdrawn for 30.5mm (the average length of zone 2B tendon sheath, the transition between zone 2A and 2B will be encountered and the arthroscope will then be in zone 2A. On the other hand, if the plantar portal is the visualization portal, the arthroscope will exit the dorsomedial portal and then withdrawn. The orifice of the 2A tendon sheath (which is defined by the posterior talar processes and the ligament in between) will be encountered and the arthroscope enters the zone 2A tendon sheath. After withdrawal of 35.9mm (the average length of zone 2A tendon sheath), the transition between zone 2A and 2B can be identified and the arthroscope start to be in zone 2B tendon sheath. These data provide guideline to the location of the transition between

25

the zone 2A and 2B tendon sheaths during FHL tendoscopy. Actually, the transition
can also be seen easily during arthroscopy.

In this study, the medial plantar nerve was at plantar medial side of the zone 2A
tendon sheath in all specimens. Its relationship to the zone 2B tendon sheath was
variable. It crossed the sheath in half of the cases and at the proximal fifth of the zone
2B tendon sheath. The medial plantar nerve is close to the zone 2 tendon sheath
especially at the junction between the zone 2A and 2B sheaths.

During the zone 2A FHL tendoscopy, arthroscopic synovectomy is a relatively safe
procedure since the tough fibrous tendon sheath is difficult to be perforated by the
shaver and the medial plantar nerve relationship to the zone 2A tendon sheath is
constant. During the zone 2B FHL tendoscopy, procedure focused on the FHL tendon
including harvest of the tendon for FHL transfer or synovectomy of the inflamed
synovium at the surface of the tendon should be safe because the opening of the
arthroscopic shaver or scissors would be facing the tendon rather than the thin tendon
sheath. However, procedures focused on the surface of zone 2B tendon sheath e.g.
synovectomy of the tendon sheath were risky because the zone 2B tendon sheath is a
thin fibrous structure which can be easily perforated by the shaver and the relationship
of the medial plantar nerve to the zone 2B tendon sheath is variable and can be
directly opposed to the sheath. Surgeons should pay particular attention during zone
2B synovectomy, the shaver opening should be kept towards the FHL tendon and
suction should be kept to minimum in order to avoid damage of the medial plantar
nerve.

Conclusions

1

The zone 2 flexor hallucis longus tendon sheath can be subdivided into a proximal

2

fibrous zone (2A) and a distal fascial zone (2B). Because of the close approximation

3

of the medial plantar nerve to the tendon sheath, there is a significant risk of

4

iatrogenic nerve injury when surgical procedures are performed in zone 2B.

5

6

7

References:

- 1) C. Niek van Dijk, Kort N, Scholten PE. Tendoscopy of the posterior tibial tendon
Arthroscopy 13(6),1997:692-8
- 2) Chow HT, Chan KB, Lui TH. Tendoscopic Debridement for Stage I Posterior Tibial Tendon Dysfunction
Knee Surgery, Sports Traumatology, Arthroscopy, Vol. 13: pp. 695-698, 2005
- 3) Lui TH. Endoscopic Assisted Posterior Tibial Tendon Reconstruction for Stage 2 Posterior Tibial Tendon Insufficiency
Knee Surgery, Sports Traumatology, Arthroscopy : Official Journal of the ESSKA 2000
15(10):1228-1234, 2007 October
- 4) van Dijk C, Kort N. Tendoscopy of the peroneal tendons.
Arthroscopy Vol 14 No 5 pp 471-478, 1998.
- 5) Lui TH. Endoscopic Peroneal Retinaculum Reconstruction
Knee Surgery, Sports Traumatology, Arthroscopy, Vol. 14: pp. 478-481, 2006
- 6) Maquirriain J, Sammartino M, Ghisi JP, Mazzuco J. Tibialis anterior tenosynovitis: avoiding extensor retinaculum damage during endoscopic debridement.
Arthroscopy: Vol 19 No 2 pp 9e, 2003
- 7) Lui TH, Chow HT. Role of toe Flexor Tendoscopy in the Management of an Unusual Cause of Metatarsalgia
Knee Surgery, Sports Traumatology, Arthroscopy, Vol. 14: pp. 654-658, 2006.
- 8) Lui TH. Current Concepts: Foot and ankle arthroscopy and endoscopy: indications of new technique
Arthroscopy : The Journal of Arthroscopic and Related Surgery 23(8):889-902, 2007

- 9) Lui TH. Endoscopic assisted flexor hallucis longus tendon transfer in management of chronic Achilles tendon rupture
Knee Surgery, Sports Traumatology, Arthroscopy 15(9):1163-1166, September 2007
- 10) Lui TH. Flexor hallucis longus tendoscopy : a technical note
Knee Surgery, Sports Traumatology, Arthroscopy 2009 17:107-110
- 11) Lui TH, Chan KB, Chan LK. Zone 2 flexor hallucis longus tendoscopy : a cadaveric study
Foot Ankle Int 30(5), May 2009
- 12) C Niek van Dijk, Peter E. Scholten and Rover Krips. A 2-portal endoscopic approach for diagnosis and treatment of posterior ankle pathology
Arthroscopy: The journal of arthroscopy and related surgery, Vol 16, No 8 (November-December), 2000:pp871-876.

Legend

Fig. 1 The FHL tendon at the posterior ankle was identified and a 4mm metal rod was inserted into the tendon sheath and penetrated the plantar aponeurosis.

The plantar portal of the original zone 2 FHL tendoscopy was then made

Fig. 2 The posteromedial ankle wound was extended towards the plantar wound and the medial plantar nerve (a) was identified. The flexor hallucis tendon was deep to the medial plantar nerve in this specimen (b, flexor digitorum longus tendon).

Fig. 3 The medial plantar nerve was reflected to expose the zone 2 FHL tendon sheath from the orifice at the posterior ankle (a) to the Knot of Henry (b) which is the interconnection between flexor digitorum longus tendon (c) and the flexor hallucis longus tendon (d). It was subdivided into fibrous zone 2A (e) and fascial zone 2B (f) sheaths.

Fig. 4 (A) The FHL tendon was pinned at the orifice of the fibrous tendon sheath, the junction between the fibrous and fascial tendon sheath and the exit point of the metal rod. (B) The tendon sheath was cut open to expose the tendon. (C) The tendon was cut at the pinned sites. The lengths of the zone 2A and 2B FHL tendon were then measured.

Table 1 Orientation of medial plantar nerve to zone 2A and Zone 2B flexor hallucis longus (FHL) tendon.

Orientation of medial plantar nerve to zone 2A and Zone 2B flexor hallucis longus (FHL) tendon

Specimen number	Orientation of medial plantar nerve to zone 2A FHL tendon	Distance between the medial plantar nerve and the orifice of the zone 2A tendon sheath (mm)	Location of the medial plantar nerve crossed the tendon sheath	Distance between the medial plantar nerve and the tendon sheath at the junction between zone 2A and zone 2B (mm)	Orientation of medial plantar nerve to zone 2B FHL tendon	Distance between the medial plantar nerve and the distal end of the zone 2B tendon sheath (mm)
1	Plantar medial	3	5mm distal to the junction between zone A and zone B tendon sheaths	2	Cross the tendon and then lie plantar lateral to the zone 2B tendon	5

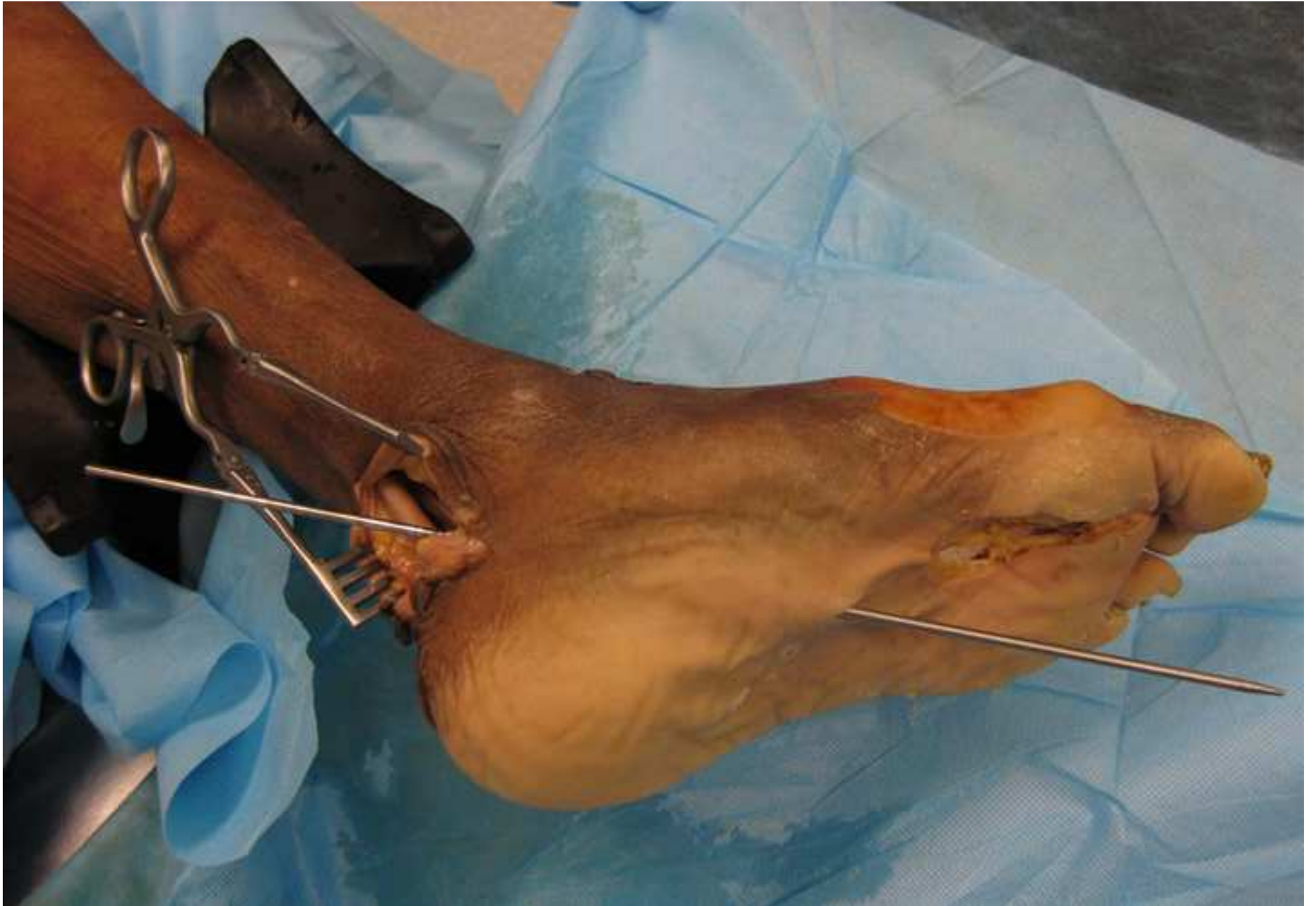2	Plantar medial	7	3mm distal to the junction between zone A and zone B tendon sheaths	2	Cross the tendon and then lie plantar lateral to the zone 2B tendon	4
3	Plantar medial	12	The nerve did not cross the tendon sheath	7	Medial	5
4	Plantar medial	9	The nerve did not cross the tendon sheath	5	Plantar medial but converged onto the tendon at the distal part	2
5	Plantar medial	9	The nerve did not cross the tendon sheath	6	Plantar medial	5

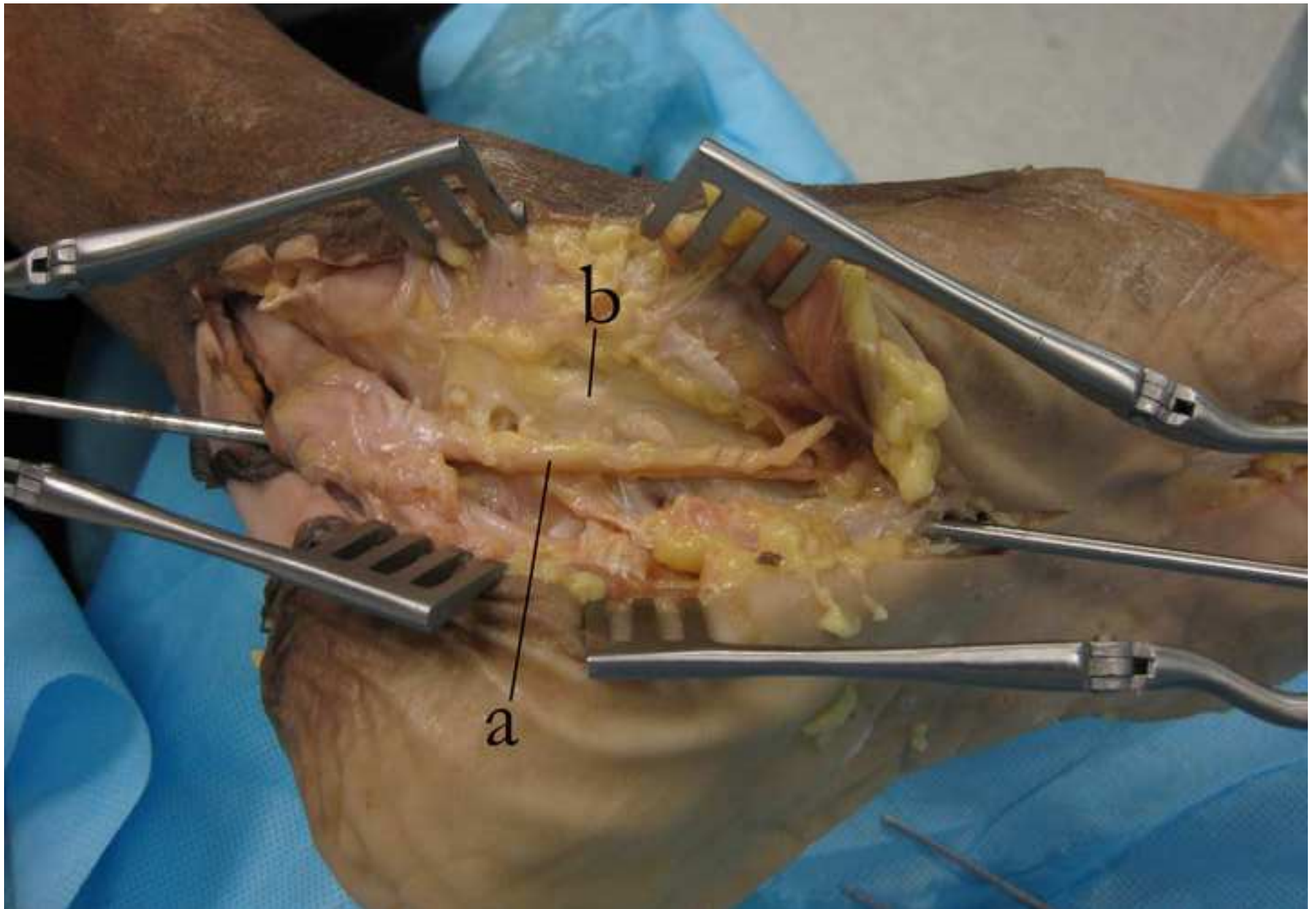
6	Plantar medial	7	The nerve did not cross the tendon sheath	4	Plantar medial	3
7	Plantar medial	6	At the junction between zone A and zone B tendon sheaths	0	Cross the tendon and then lie plantar lateral to the zone 2B tendon	6
8	Plantar medial	8	At the junction between zone A and zone B tendon sheaths	0	Cross the tendon and then lie plantar lateral to the zone 2B tendon	5
9	Plantar medial	5	6mm distal to the junction between zone A and zone B	1	Cross the tendon and then lie plantar lateral to the zone	4

			tendon sheaths		2B tendon	
10	Plantar medial	9	The nerve did not cross the tendon sheath	6	Plantar medial but converged onto the tendon at the distal part	2
11	Plantar medial	8	2mm distal to the junction between zone A and zone B	2	Cross the tendon and then lie plantar lateral to the zone 2B tendon	5
12	Plantar medial	8	5mm distal to the junction between zone A and zone B	3	Cross the tendon and then lie plantar lateral to the zone 2B tendon	4
Mean distance		7.6		3.2		4.2

(mm)						
------	--	--	--	--	--	--

Figure(s) in separate file(s)
[Click here to download high resolution image](#)





Figure(s) in separate file(s)
[Click here to download high resolution image](#)

