



Title	Use of functional MRI to evaluate correlation between acupoints and the somatic sensory cortex activities
Author(s)	Li, G; Wong, KK; Huang, L; Liu, SR; Cao, G; Shen, GG; Yang, ES; Ma, Q
Citation	International Society for Magnetic Resonance in Medicine 9th Scientific Meeting & Exhibition, Glasgow, UK, 23-27 April 2001, p. 1326
Issued Date	2001
URL	http://hdl.handle.net/10722/98938
Rights	This work is licensed under a Creative Commons Attribution-NonCommercial-NoDerivatives 4.0 International License.

Use of Functional MRI to Evaluate correlation Between Acupoints and the Somatic Sensory Cortex Activities

G LI¹, KK Wong¹, L Huang², SR Liu², G Cao³, GG Shen¹, ES Yang¹, QY Ma¹

¹The Jockey Club MRI Engineering Centre, The University of Hong Kong, Hong Kong, HKSAR; ²Medical Imaging Centre of The First Affiliated Hospital of Medical College, Jinan University, ; ³GE Medical Systems Asia, ;

Introduction

As a therapy for functional diseases, acupuncture is being increasingly accepted even though the mechanism of this therapy is yet to be fully explained. Recently, using functional MRI (fMRI) to evaluate the correlation between acupoints and some of the brain cortices has been reported [1-4]. But so far there has been no report on the correlation between acupoints and motor cortex. This work uses fMRI to study somatic sensory cortex activation produced by acupuncture stimulation, which is related to the somatic sensory cortex, and the related mechanism of acupuncture.

Materials and Methods

Eighty-eight right-handed healthy volunteers aged 18-45 were examined using a quadrature head coil on 1.5 T system. After sagittal spin-echo localiser images were acquired, 16 coronal slices placed parallel to the commisura anterior-commisura posterior (AC-CP) line of the fMRI was performed using single-shot gradient-echo (GE-EPI) pulse sequence with TR, 3000 ms; TE, 60 ms; 64 X 128; FOV, 24 X 24cm; slice thickness, 4.0 mm without inter-slice gap; multi-phase and single excitation. The 36-second activation period was alternated with a 36-second rest period. First, fMRI was performed with no meridian and no acupoint as control groups in Fig.1(a).

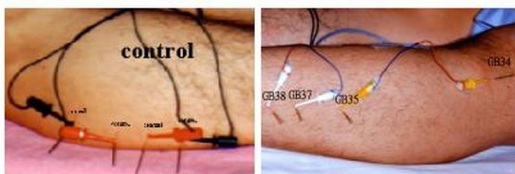


Fig 1(a) No Meridian and No Acupoints as Control Groups

Fig 1(b) Points of Gallbladder Meridian of Foot-Shaoyang

The functional MRI was then repeated with electro-acupuncture with 2Hz separately at the following acupoint groups as shown in table 1. Finally, T1-weighted 3D images of the whole brain were acquired for the anatomical image of the major interest regions. All data were analyzed on the software package of SPM99b (Institute of Neurology Wellcome Dept of Cognitive Neurology).

Results

Electro-acupuncture stimulation of groups of acupoints – ST 36, GB34, GB35 and GB39; and GB34, GB35, GB37 and GB38 (Fig.1b) – elicited signal increases in the somatic sensory cortices of the toe and foot in Fig. 2. Signal increases in the somatic sensory cortices of the hand and arm were elicited by electro-acupuncture stimulation of groups of acupoints – (LI4 and LI9), (LI9 and LI14), (LI10 and LI15) and (LI10 and LI13) in Fig. 3. No signal increases in the somatic sensory cortex can be found in the control groups.

Group of Acupoints	Subjects	Group of Acupoints	Subjects
LI4 LI11	10	SJ5 SJ9 / SJ5 SJ3	2
LI9 LI14	10	SJ3 SJ5	3
LI10 LI15	10	GB34 GB35 GB37 GB38	10
LI10 LI13	10	GB34 GB35 GB39 ST36	31

Table 1. The group of acupoints and No. of volunteers

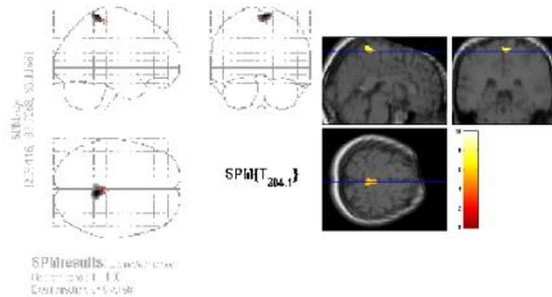


Fig.2 Combined fMRI signal increases in Somatosensory cortices (11 volunteers) created by electro-acupuncture stimulation at GB34, GB35 GB39 and ST36.

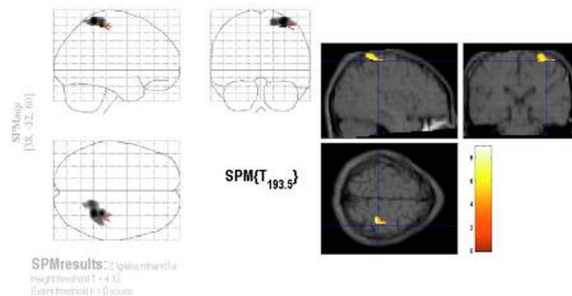


Fig.3 Combined fMRI signal increases in somatosensory cortices (7 volunteers) created by electro-acupuncture stimulation at LI4 and LI11.

Discussion and Conclusion

This present study demonstrates the correlation between disease related acupoints and the brain function. The results demonstrated that somatic sensory cortex and dysfunction of motor cortex are related to acupoints. Acupuncture has a potential to treat some functional disorder of motor cortex.

Acknowledgement: Financial support was provided by The Hong Kong Jockey Club Charities Trust and Hong Kong University Foundation. We thank GE Medical Systems Asia for the technical support.

References

1. Cho ZH et al., Proc. Natl. Acad. Sci. USA 1998;95:2670-2673.
2. Hui KKS et al., Human Brain Mapping 2000;9:13-25.
3. Wu MT et al., Radiology 1999;212:133-141.
4. Wu MT et al., Neuroimage 1997;5(4), part 2 of 4 parts.
5. Talairach J et al., A Coplanar Stereotaxic Atlas of the Human Brain, Thieme, New York 1988.