



Title	Automated adaptive analysis of tagged magnetic resonance images of the mouse heart
Author(s)	Azeloglu, EU; Tang, H; Chen, RK; Chaudhry, HW; Wu, EX; Gaudette, GR; Costa, KD
Citation	The International Society for Magnetic Resonance in Medicine 14th Scientific Meeting & Exhibition (ISMRM2006). Seattle, WA, 6-12 May 2006, p. 1217
Issued Date	2006
URL	http://hdl.handle.net/10722/98769
Rights	This work is licensed under a Creative Commons Attribution-NonCommercial-NoDerivatives 4.0 International License.

Automated Adaptive Analysis of Tagged Magnetic Resonance Images of the Mouse Heart

E. U. Azeloglu¹, H. Tang^{2,3}, R. K. Chen⁴, H. W. Chaudhry⁴, E. X. Wu⁵, G. R. Gaudette⁶, K. D. Costa¹

¹Biomedical Engineering, Columbia University, New York, NY, United States, ²Imaging, Merck Research Laboratories, Rahway, NJ, United States, ³Radiology, Columbia University College of Physicians & Surgeons, New York, NY, United States, ⁴Medicine, Columbia University College of Physicians & Surgeons, New York, NY, United States, ⁵Electrical & Electronic Engineering, The University of Hong Kong, Hong Kong SAR, China, People's Republic of, ⁶Surgery, UMass Medical School, Worcester, MA, United States

Introduction Magnetic resonance (MR) tagging of the mouse heart is an emerging technology for non-invasive evaluation of cardiac mechanics in transgenic animals for the study of heart disease and evaluation of cell transplantation therapies [1]. Utility of tagged MR has been limited due to high SNR requirements and labor-intensive image processing. Therefore, we have developed a rapid, high-resolution adaptive boundary technique for analysis of tagged MR images that does not entail tracking of individual tags and involves minimal user involvement. This new tagging analysis method provides an automated and efficient way to analyze regional cardiac mechanics from tagged MR images in mice as well as other species.

Methods

High resolution MR image tagging High resolution MR tagged images were obtained via methods previously described [2]. Anesthetized wild-type mice (C57BL/6; 25g) were either scanned at baseline (*Control*) or 2 weeks following a left anterior descending (LAD) coronary artery occlusion (*Infarct*). Heart rate during scan was about 450 bpm. Image acquisition was performed in a 9.4T microimaging system (Bruker Avance 400WB) using 30mm ID RF probe. Bright blood, short axis images of ventricles were obtained using ECG-gated, fast-gradient echo Cine sequences. Tagging images were acquired using a Sinc modulated RF pulse trains with 10ms duration and a 3-lobe Sinc function, yielding 8 frames per cardiac cycle, 25.6mm FOV, in-plane resolution 100um, and 1.25mm slice thickness. The modulated RF pulse trains provided tags with rectangular intensity profile (sharp-edges) and flexible tag width-to-separation ratio. Non-tagged images at the same cardiac phases were also acquired for ventricular myocardium wall tracing.

Displacement field determination The displacement fields from end-diastole to end-systole between individual frames were determined using a custom developed phase correlation algorithm, named *High Density Mapping* (HDM; Figure 1), in which a rectangular region of interest was selected and segmented into 16 ×16-pixel subregions with 1-pixel separation. Correlation of each subimage, before and after deformation, was performed in the frequency domain by using the following cross power spectrum: $\hat{f}_2(u,v)\hat{f}_1(u,v)^* / |\hat{f}_1(u,v)\hat{f}_1(u,v)^*| = \exp(-i(ux_0 + vy_0))$. Subpixel deformation (± 0.05 pxl) was quantified using Sinc interpolation [3]. Myocardial displacement vectors were identified using ventricular tracings from non-tagged images and an automated dynamic border detection algorithm. Radial wall motion and the 2-D strain components were computed from the fitted displacement fields and individual frames were summed to yield systolic deformation.

Results High resolution tagged MR cine images were acquired with tag width 0.1mm and tag separation (center-to-center) 0.5mm. Regional variations in mechanics and mechanical dysfunction caused by LAD occlusion were detected and quantified in the infarcted mouse (Figure 2). The spatial resolution for HDM was equivalent to that of MR pixel resolution (100um). This analysis generated approximately 2000 displacement vectors per ventricle. Computation of systolic displacement maps with HDM took about 30 seconds, and post-processing of displacement values, calculation of strains and correlation with geometry within Matlab took about 90 seconds (3.2GHz P4m PC). HDM calculated strains compared favorably with manual tag tracking (Figure 3). The analysis of infarcted mouse hearts clearly showed areas of poor function, with substantial reduction in circumferential shortening, radial thinning and abnormal wall motion in the infarct zone.

Conclusions and discussions This new automatic and rapid tagging analysis approach will provide an objective way to process tagged MR images. It can further help promote MR tagging technique and the use of transgenic mice in study of cardiac mechanics, which will aid in evaluation of novel cardiac therapies (e.g. cell transplantation), and may be practical for clinical diagnostic applications.

Acknowledgements This study was supported by NIH Grant (HL067048; HWC).

References 1. Epstein FH, Yang Z, *et al.* Magn. Reson. Med. 48(2):399–403, 2002. 2. Wu EX, Towe CW, Tang H. Magn. Reson. Med. 48(2):389-393, 2002. 3. Azeloglu EU, Yun YH, *et al.* J. Biomech. Eng., 2005, AiP.

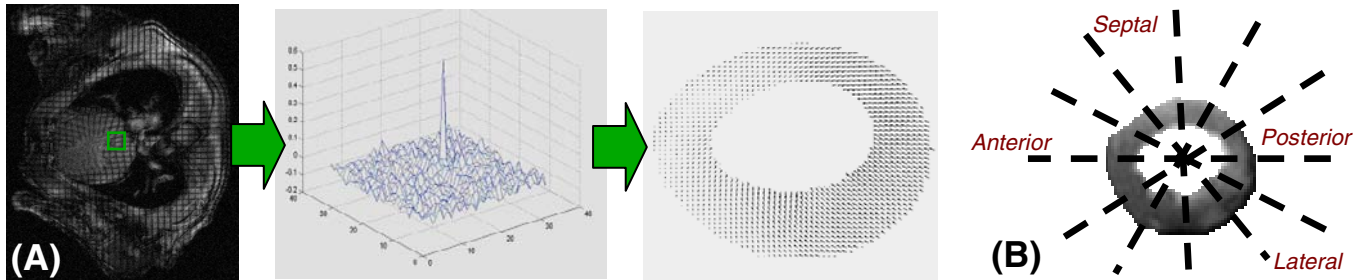


Figure 1. Schematic of the MR tagging analysis technique. (A) 16x16 pixel subregions in consecutive images were cross-correlated in the Fourier domain yielding subpixel accuracy. (B) The myocardium is divided into 8-16 circumferential sections for subsequent biquadratic fitting of individual displacement fields.

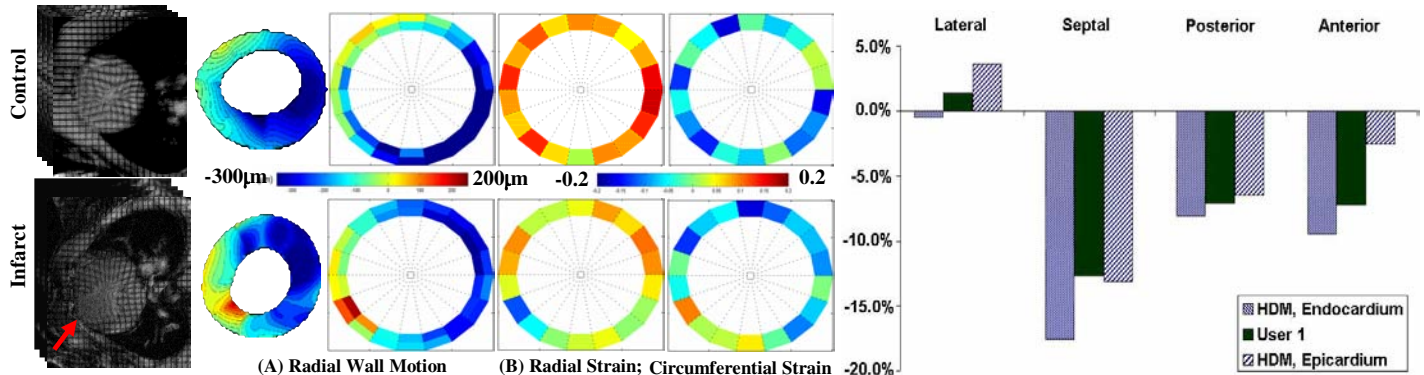


Figure 2. Comparison of functional parameters from short-axis sections of representative control and infarct mice. Contour plots of (A) radial displacement and (B) 2-D strain components reveal abnormal mechanics in the infarcted region of the LV (red arrow).

Figure 3. Regional circumferential strain values from an infarcted heart as measured by manual tag tracking and HDM.