



<b>Title</b>	<b>MRI and image quantitation for assessment of the growth effects of anabolic steroid precursors in a guinea pig model</b>
<b>Author(s)</b>	<b>Tang, H; Wu, EX; Vasseli, JR</b>
<b>Citation</b>	<b>The International Society for Magnetic Resonance in Medicine 14th Scientific Meeting &amp; Exhibition (ISMRM2006). Seattle, WA, 6-12 May 2006, p. 1257</b>
<b>Issued Date</b>	<b>2006</b>
<b>URL</b>	<b><a href="http://hdl.handle.net/10722/98717">http://hdl.handle.net/10722/98717</a></b>
<b>Rights</b>	<b>This work is licensed under a Creative Commons Attribution-NonCommercial-NoDerivatives 4.0 International License.</b>

# MRI and Image Quantitation for Assessment of the Growth Effects of Anabolic Steroid Precursors in a Guinea Pig Model

H. Tang<sup>1,2</sup>, E. X. Wu<sup>3</sup>, J. R. Vasselli<sup>4</sup>

<sup>1</sup>Imaging, Merck Research Laboratories, Rahway, NJ, United States, <sup>2</sup>Radiology, Columbia University College of Physicians & Surgeons, New York, NY, United States, <sup>3</sup>Electrical & Electronic Engineering, The University of Hong Kong, Hong Kong SAR, China, People's Republic of, <sup>4</sup>Obesity Research Center, St. Luke's Roosevelt Hospital, Columbia University, New York, NY, United States

## Introduction

MRI and image quantitation play an expanding role in modern drug research, because MRI provides high resolution, non-invasive, and quantitative imaging of various soft tissues with sufficient contrast. With effective image segmentation and analysis methods, *in vivo* and longitudinal measurement of tissue growth can be assessed [1]. Anabolic steroids are observed increase muscle mass and are widely used for muscle growth. The effects of the steroids of nandrolone and testosterone on muscle growth and body composition have been investigated in a previous study [2], in which MRI acquisition and analysis protocol were established and validated, and excellent correlations were found between MRI measurement and dissection analyzes. In the study [2], customized image segmentation tools were developed to label the tissues of interest for volume estimation, a tissue area outlining method was used to study tissue geometric features in relation to tissue growth, and an automatic data retrieval and analysis procedure was implemented to facilitate the overall image quantitation, growth evaluation, statistical analysis, and across group comparisons. Concurrent with the use of classical anabolic steroids, is the use of steroid precursors. In the current study, the MRI and analysis protocol were further used to evaluate the anabolic potential of the selected steroid precursors: 4-Androstene-3-17-dione (Androstenedione), and 4-Androstene-3 $\beta$  17 $\beta$ -diol (4-Andros), which are precursors for testosterone; 19-Nor-4-Androstene-3 $\beta$ -17 $\beta$ -diol (Bolandiol), and 19-Nor-4-Androstene-3 17-dione (19-Nor), which are precursors for nandrolone. The effects on muscle growth in groups of castrated male guinea pigs over a 10-week period, in comparison with the growth in respective positive control groups were determined.

## Methods

**Animal Model** Certified virus free male Hartley guinea pigs weighing 450–500g, at 8–9 weeks of age (post-pubertal stage) were used in the study. Silastic capsules containing the steroid precursors Androstenedione, 4-Andros, Bolandiol, and 19-Nor, in amounts sufficient to achieve target levels of the steroid products, were implanted in intact and castrated experimental groups. The guinea pigs were grouped for each of the four steroid precursors (Intact Androstenedione, n = 14; Castrated Androstenedione, n = 15; Intact 4-Andros, n=14; Castrated 4-Andros, n=15; Intact Bolandiol, n = 16; Castrated Bolandiol, n = 16; Intact 19-Nor, n=14; Castrated 19-Nor, n=15), their positive control steroids (Intact Testosterone, n = 9; Castrated Testosterone, n = 10; Intact Nandrolone, n = 10; Castrated Nandrolone, n = 8), and the empty capsule groups (Intact, n = 16; Castrated, n = 17). Images were taken at baseline and 10-week treatment period. The protocol was approved by the Institutional Animal Care and Use Committees.

**MRI Image Acquisition** 3D high-resolution images of a coronal view were acquired covering the entire body of guinea pig using a multi-slice T1W sequence (0.5mm  $\times$  0.5mm  $\times$  1.5mm voxel size, slice gap 0.3mm) on a whole-body 1.5T Philips Intera scanner equipped with a 10cm I.D. quadrature coil. Such images provide adequate soft tissue contrast for delineation of tissues of interest. Animals were anesthetized with IP injection of 30 mg/Kg sodium pentobarbital during imaging.

**MRI Image Analysis** Images were analyzed using an IDL based customized software package. It features fast semi-automatic and interactive segmentation using a combination of intensity and histogram-based, region growing, and active contouring algorithms for effective tissue separation and labeling. Nine tissue compartments were labeled and quantified, which included the five skeletal muscles in specific segments (temporalis, masseter, neck complex, shoulder complex, and the remaining skeletal muscle), three sexual organs (prostate and seminal vesicles, testis), and whole-body adipose tissue. The growth effects were statistically analyzed and compared between and within groups. Meanwhile, a longitudinal "area profile" was produced reflecting tissue distribution from rostral to caudal, with which the geometric parameters such as tissue volume, tissue length, and tissue center could be derived, to reflect the total volume and shape changes as a function of treatment time. Finally, since hundreds of guinea pigs were scanned at multiple time points for the study, an Excel-based data retrieval and analysis procedure was developed to facilitate the huge amount of data analysis for sufficient group comparisons and graphical generation, to better understand the growth effects of the steroids/precursors.

## Results

Steroid and the respective precursor replacement in the castrated groups resulted in significant muscle growth to or towards normal for all muscles and organs at wk-10. Significant differences were observed for all of the comparisons made between the Castrated steroid/precursor treatment groups and Castrated Empty capsule group, which suggest that the selected steroid precursors stimulated normal or near-normal muscle growth in castrated guinea pigs over a 10-week interval. Figure 1 shows the example of total body and temporalis muscle growth in castrated groups treated with androstenedione and testosterone, comparing their growth to that of empty capsule groups. Figure 2 shows total muscle distribution profiles of Intact Empty, Castrated Empty, Castrated Androstenedione, and Castrated Testosterone capsule groups over 10-week treatment. Very similar growth effects were observed in the selected tissue compartments between the Androstenedione and Testosterone groups, as well as other steroid and positive control groups, with no significant differences in percent growth between the groups in either surgical condition (intact or castrated). Moreover, Androstenedione and 4-Andros resulted in highly elevated circulating testosterone levels in both intact and castrated guinea pigs. Maintenance of testosterone at these levels augmented the growth of specific muscles to levels above normal in intact animals over the 10-week treatment period.

## Conclusions and discussions

An MRI acquisition and analysis protocol was employed to evaluate the steroid precursor effects on muscle growth and body composition changes in a castration guinea pig test model, demonstrating the practical and experimental utility of MR imaging and image analysis technology for biomedical applications. The study showed that the MRI imaging technique is extremely sensitive in detecting differences in individual muscle compartments in the growing guinea pigs, and confirmed the growth effects of the selected steroid precursors. The established imaging and analysis protocol are applicable to future human studies.

## Acknowledgment

This study was in part supported by the Drug Enforcement Administration, US Dept. of Interior.

## Reference

1. Tang H, Vasselli JR, Wu EX, et al. Am. J. Physiol, 282: R890-R899, 2002.
2. Wu EX, Tang H, Vasselli JR. ISMRM 2004.

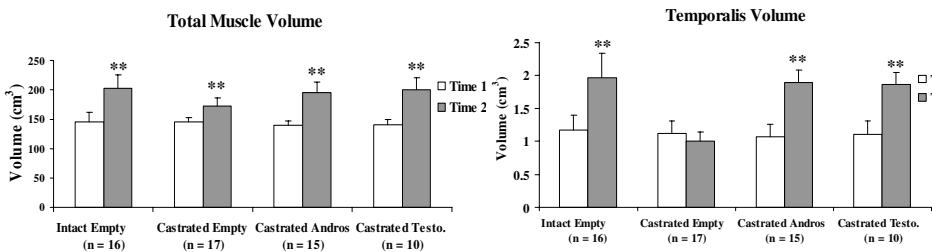


Fig. 1. Total and temporalis muscle growth in Empty Capsule, Castrated Androstenedione, and Castrated Testosterone groups over 10-week interval

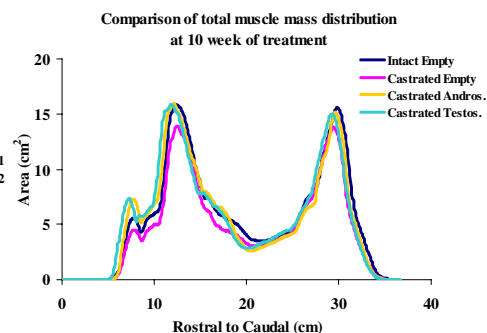


Fig. 2. Total muscle distribution profiles of Empty Capsule, Castrated Androstenedione, and Castrated Testosterone at 10 week treatment