



<b>Title</b>	<b>Multimodality minimally invasive autopsy-A feasible and accurate approach to post-mortem examination</b>
<b>Author(s)</b>	<b>Fan, JKM; Tong, DKH; Poon, JTC; Lo, OSH; Beh, PSL; Patil, NG; Law, WL</b>
<b>Citation</b>	<b>Forensic Science International, 2010, v. 195 n. 1-3, p. 93-98</b>
<b>Issued Date</b>	<b>2010</b>
<b>URL</b>	<b><a href="http://hdl.handle.net/10722/88285">http://hdl.handle.net/10722/88285</a></b>
<b>Rights</b>	<b>Creative Commons: Attribution 3.0 Hong Kong License</b>

# **Minimally Invasive Autopsy – Multimodality to Post-Mortem Examinations**

*Joe KM FAN	MBBS (HK), FRCS Ed
*Daniel KH TONG,	MBBS (HK), FRACS
*Jensen TC POON	MBBS (HK), FRCS Ed
*Siu Hung LO	MBBS (HK), FRCS Ed
+Philip BEH	MBBS(HK), DMJ(Lond), FHKCPath, FHKAM(Pathology), FFFLM (UK)
*NG PATIL	MBBS (Bombay), MS, FRCS Ed
*Wai Lun LAW	MS (HK), FRCS Ed, FACS

\*Department of Surgery and +Department of Pathology, University of Hong Kong Medical Centre, Queen Mary Hospital

Correspondence:

Wai Lun LAW  
Department of Surgery  
University of Hong Kong Medical Centre  
Queen Mary Hospital  
Pokfulam Road, Hong Kong

Tel: (852) 28554763  
Fax: (852) 28728425  
E-mail: lawwl@hkucc.hku.hk

Running title: minimally invasive autopsy

## **Abstract**

### **Background**

Autopsy examination has been the bedrock of western medicine. With the decline in the autopsy rate secondary to the negative psychological impact to the deceased's relatives, the benefits of autopsy have been undermined. Minimally invasive autopsy has been introduced but has not been widely adopted as an alternative to the 'traditional' open approach. This technique not only provides information on the cause of death but also minimizes the disfigurement induced to the deceased. Our study aims to explore the feasibility and evaluate the accuracy of this technique.

### **Methods**

A series of coroner cases ordered for autopsy were examined by a group including an experienced forensic pathologist and two experienced laparoscopic surgeons using thoracoscopic, laparoscopic, endoluminal or endovascular approaches. The procedure was video-recorded and the provisional diagnoses and causes of death were made based on the findings. These findings were subsequently correlated with the full autopsy examination. A few limited clinical post-mortem examinations were also performed with consent from relatives.

### **Results**

A total of 22 cases of minimally invasive autopsies were performed from Nov, 2007 to Mar, 2008. The median duration of the procedures was 78.3 +/- 20.7 min. Thoracoscopies and laparoscopies were performed in 18 patients while additional arterioscopic

examination with endoscope was performed in two patients with suspected aortic diseases. Four consented limited clinical autopsies were also performed: two of them involved thoracoscopic biopsies of lung tissues, one was a para-mortem upper endoscopy for the investigation of pathology of the stomach and the other one was laparoscopy for a patient, who died of unexplained acidosis. Comparison with full autopsies showed that the accuracy of the diagnosis was 94.4%, the sensitivity was 90%, the specificity was 100%, the positive predictive value was 100% and the negative predictive value was 88.9%.

### **Conclusion**

Minimally invasive autopsy is a feasible approach, yielding accurate findings when compared with conventional autopsies. The former can be a valuable tool for obtaining more valuable information in situations when the next-of-kin of the deceased does not consent to a conventional autopsy.

## **Introduction:**

There is a global decline in the autopsy rate<sup>1-5</sup> and the low acceptance of post-mortem examination by the general public is mainly due to the fact that autopsy is considered a disfiguring procedure and causes “unnecessary sufferings” to the deceased. This does not only occur in consented post-mortem examination, but in many coroner cases, the autopsy is waived in the absence of “foul play” or medico-legal issues. However, autopsy examination has an important role in advancing medical knowledge, solving clinical problems, promoting public health, and enhancing medical research<sup>6</sup>. The concept of “minimally invasive autopsy” was first reported in the modern medical literature by Avrahami et al<sup>7,8</sup>. They reported a series of 25 cases of post-mortem examination with laparoscopy and thoracoscopy. The objective of minimally invasive autopsy is to achieve scientific, educational, and public health benefits without the need for the conventional autopsy, which is perceived by the family to be a ‘disfiguring’ procedure. A literature search revealed that there were only a few case-reports on the feasibility of this approach<sup>8-12</sup>. With the objective to evaluate the accuracy of minimally invasive autopsy, we embarked on this to compare the results of minimally autopsy with conventional post-mortem examination.

**Method:**

The Coroner Ordinance in Hong Kong Special Administrative Region (HKSAR), China, requires mandatory reporting of death in twenty situations listed under Part 2 Schedule 1 of the Ordinance. (Laws of Hong Kong Cap 504). This list covers all the situations of unnatural deaths and also many situations when the death is more a question for accuracy of medical causation. Following a reported death (Appendix 1), a full autopsy examination may be ordered subject to the decision of the Coroner Court based on the available clinical information and the expressed views of the family of the deceased. Waiver of an autopsy by the Coroner is on an individual basis but the number of waiver has been rising steadily in the last few years and in 2008 over 50% of all the reported cases to the Coroner were waived (Figure 1). This study was conducted at the hospital mortuary of a university hospital. Cases reported to the Coroner and ordered for autopsy examinations were selected for initial minimally invasive autopsy followed by a full autopsy, which allowed the authors to validate the findings from the minimally invasive autopsy. The cases were selected by investigators in order to maximize the benefit of minimally invasive autopsy. The bodies were stored at 4°C before autopsy examination. Minimally invasive autopsy was performed by surgeons with skills in laparoscopy and thoracoscopy together with the presence of forensic pathologist. The hospital mortuary was equipped with laminated air flow system. Laparoscopy and thoracoscopy were performed using standard 5-mm and 10-mm laparoscopic instruments. Endoscopic visualization of great vessels in the two cases with vascular diseases was performed using the single-channel endoscope (GIF-Q240X, Olympus Optical Co, Ltd, Tokyo, Japan).

After laparoscopic and thoracoscopic examination, full autopsy was performed to validate the findings of the minimally invasive approach.

*Laparoscopy:*

Laparoscopy was performed in the same manner as in living patients. A subumbilical incision was made and camera port was inserted by open method. Carbon dioxide pneumoperitoneum was created at 12mmHg. A 12mm balloon trocar (BTT™ Autosuture™) was used for the camera port to minimize gas leakage during the procedure. Another four 5-12mm trocars (Autosuture™ Woodford Spike™ Trocar and Cannula; Applied Medical™, Convertible® Trocar Access System) were inserted under direct vision. Laparoscopy was performed to look for obvious intra-abdominal pathology and individual organs were examined in detail. Biopsy of the abdominal organs was performed if indicated (Figure 2-6). The mucosal surface hollow viscera would be examined by incising the bowel wall at the end of the procedure to look for gastrointestinal bleeding and other mucosal pathologies which may be suggested by the clinical history.

*Thoracoscopy:*

Thoracoscopic examination was performed firstly through the left chest. The body was positioned in a right lateral position and a 10mm trocar was inserted at the 7th rib space at the posterior axillary line. Another two to three 5 mm trocars were inserted at the 5<sup>th</sup> anterior intercostal space, 3<sup>rd</sup> and 7<sup>th</sup> intercostal spaces at mid axillary line, respectively. The left lung was retracted caudally and the inferior pulmonary ligament was incised.

Any pleural fluid would be collected and the parenchyma of lung was examined. Any bleeding at anterior mediastinum could also be detected (Figure 7). The pericardial window would be opened along the left phrenic nerve longitudinally and any pericardial effusion or pathology would be noted. The myocardium would be opened from the left ventricle to look for evidence of myocardial infarction. The left anterior descending coronary artery would be transected and the cut surface of the artery examined to assess the degree of stenosis present. The right side of pericardium would then be opened and the right thoracic cavity would be examined.

#### *Endoscopic Examination of major vessels*

Minimally invasive examinations of aorta were performed in two patients who died of suspected pathologies of the aorta. A single channel endoscope (GIF-Q240X, Olympus Optical Co, Ltd, Tokyo, Japan) was used for the assessment of intra-luminal condition of the aorta. An incision was made over the right neck and the external carotid artery was isolated (Figure 8), a 1.5cm arteriotomy was created and a cannula was inserted. Another incision was made at the right groin to create an arteriotomy of the right femoral artery. Normal saline was irrigated through the carotid artery to flush out all the blood clots in the arterial system. The endoscope was then inserted through the carotid artery to examine the main arterial system (Figure 9). In the presence of aortic dissection, the false lumen was cannulated as well. Narrow Band Imaging (NBI) mode was used to enhance the contrast of the dissection flap once it was identified (Figure 10).

#### *Endoscopic Examination of stomach*



Endoscopic examination of the upper gastrointestinal tract was performed in one patient with a past history of a 3-phase esophagectomy performed 4 years ago for carcinoma of esophagus and died of a bleeding duodenal ulcer, which required plication of bleeder. A single channel endoscope (GIF-Q240X, Olympus Optical Co, Ltd, Tokyo, Japan) was used for the assessment to rule out gastric remnant ischemia (Figure 11). The procedure was performed over bedside in the Intensive Care Unit 1 hour after her death. The endoscope was inserted via oral cavity down to the duodenum and the mucosa of esophagus, around anastomosis, stomach and duodenum was assessed.

Definition of positive or negative exploration:

The whole procedure was recorded by digital video cassettes and the apparent cause of death was attributed by gross anatomy of organs examined. It was reviewed if there is any inconsistent conclusion from surgeons and pathologist after initial exploration by minimally invasive approach. Exploration was defined possible if the cause of death could be ascertained by laparoscopic / thoracoscopic and autopsy findings, e.g. gangrenous bowel or ruptured aneurysm. If the findings could not explain the death of the patient or if histological examination was needed to delineate the exact pathology e.g. myocardial infarction, pneumonia, or when the major pathology was outside the explored region, e.g. inside cranium, the exploration was defined as negative. False negative is defined as the presence of fatal pathology at subsequent macroscopic autopsy examination, which was not found during minimally invasive autopsy.

## **Results:**

From November 2007 to March 2008, 22 minimally invasive autopsies were performed. Thoracoscopies and laparoscopies were performed in 18 patients while an additional arterioscopic examination was performed in two patients with suspected major aortic diseases. Four consented limited clinical autopsies were also performed. Two of them involved thoracoscopic biopsies of lung tissues and, one was a para-mortem upper endoscopy for the investigation of pathology of the stomach and one was a laparoscopy for a patient who died of unexplained metabolic acidosis. Comparison with full autopsies showed that the accuracy of the diagnosis was 94.4%. The sensitivity was 90%, the specificity was 100%, the positive predictive value was 100% and the negative predictive value was 88.9% in patients with abdominal and thoracic exploration. The mean age of all patients was 74.01 (range: 32 to 96) years with 11 males and 11 females. 12 patients were referred from surgical unit whereas 9 were from medical unit, and 1 from the orthopaedic unit. The mean examination time was 78.3 +/- 20.7 mins. The details of autopsy result are shown in Table 1.

Gastro-intestinal bleeding was missed in one of patient who died of ischemic heart disease. It is not sure whether the bleeding exacerbated the ischemic heart disease or vice versa. But during laparoscopy, it was thought to be a negative exploration until full post-mortem examination when 600ml of blood and old clot was found in stomach and small bowel. Since then, endoscopic examination of the upper gastrointestinal tract was performed routinely to look for evidence of gastrointestinal bleeding.

## **Discussion:**

Autopsy remains the ultimate audit of clinical practice and a valuable source of medical knowledge despite the increasing availability of advanced imaging techniques and diagnostic procedures. The “feedback” information from autopsies to clinicians can help determine the cause and circumstance of death, enhance clinical knowledge, improve the care of similar patients, and reduce clinical diagnostic errors. It provides education for practitioners and trainees, identification and elucidation of emerging and re-emerging diseases, and post-marketing surveillance of drugs, devices and procedures<sup>13</sup>. The rate of autopsies is, however, rapidly declining in Hong Kong as well as in other parts of the world<sup>1-5</sup>, leaving uncertain the causes of many deaths. This decline in Hong Kong has affected not only the “clinically consented autopsies” but also the Coroners’ autopsies ([http://www.judiciary.gov.hk/en/publications/publications.htm#con\\_report](http://www.judiciary.gov.hk/en/publications/publications.htm#con_report)). The autopsy rate dropped from 14.6% of all deaths in HKSAR to only 10.2% in 2008 (Figure 1). Many family members refuse autopsies or apply for waivers of autopsy because autopsies are perceived to be “disruptive” and involve an extensive incision on the body of the deceased. Laparoscopic and thoracoscopic approach for autopsy was first reported by Avrahami, R. et al in Israel<sup>7,8</sup> in 1995 followed by some case reports from the United States<sup>9,10</sup>. It has the advantage of allowing a visual inspection of the peritoneal and thoracic cavity as well as removal of tissues or fluid samples for further examinations without creating a big incision.

Currently, the largest series was reported in 1995 by Avrahami, R. et al<sup>7,8</sup> whom they performed minimally invasive autopsy mainly on patients died of trauma and gunshot injuries. They achieved a high correlation in patients died of trauma. However for in-patient category, there was a significant discrepancy between laparoscopic findings and full post-mortem examination. It was due to small number of patients in the in-hospital group (only 5 patients). Compared with their findings, only 2 of the 22 patients in this series died of trauma. We were able to achieve an overall accuracy of 94.4% with a positive predictive value of 100%. We experienced similar technical difficulties in the exploration of the retroperitonem by the laparoscopic approach. Avrahami also found many of the injuries of the retroperitoneal region were not identified. We were able to identify some pathologies in this difficult area, but the exact site of pathology was often not easily visualized e.g. the site of rupture of an abdominal aortic aneurysm.

In additional to the laparoscopic and thoracoscopic approaches, we also performed endoscopic examination of great vessels and we were successful to demonstrate arterial pathologies. In cases of aortic dissection, the beginning and the extent of the dissection were clearly identified. The extension of the false lumen together with the re-entry point could also be visualized in endoscopic examination.

One of the hindering factors for the wide application of minimally invasive approach is the cost. Besides the cost of the laparoscopic equipment, the cost of manpower is also an important consideration. In this study, a forensic pathologist and two surgeons specialized in minimally invasive surgery were involved in each autopsy examination.

Training of the pathologists the skills in minimally invasive procedure may be an alternative. The application of minimally invasive autopsy may provide an opportunity for the training of surgical residents.

There are also technical issues in this approach. Gas leak during laparoscopy is a common problem. Gas leak can lead to the potential spread of infectious disease and the leakage of unpleasant odor. We tried to limit the gas leak by using balloon camera ports (BTT™ Autosuture™), decreasing the intra-abdominal pressure, and creating accurately sized skin incisions for port insertion. The use of N95 grade mask and universal precaution can help to minimize the risk of infection to staff, surgeons and pathologists.

From the legal perspectives, minimally invasive autopsy cannot replace a full autopsy. However, in cases when the medical cause of death is not clear, this approach can lead to less resistance from the family members. With the development of para-mortem imaging, ‘autopsy’ can now be performed without an extensive incision and trauma to the deceased.

### **Conclusion:**

Minimally invasive autopsy is a feasible approach, yielding accurate findings when compared with conventional autopsies. The former can be a valuable tool for obtaining more valuable information in situations when the next-of-kin of the deceased does not consent to a conventional autopsy.

Table 1:

	Sex/Age	Minimally Invasive Autopsy finding	Additional findings in full post-mortem examination	Cause of death	Correlation with full post-mortem
1	F/79	Retroperitoneal haematoma over right iliac region with small amount of intraperitoneal blood	Ruptured right iliac aneurysm	Rupture Iliac Aneurysm	YES
2	M/56	Negative findings	Fracture skull and severe brain injuries	Severe Head Injuries, Road Traffic Accident	YES*
3	F/81	Adhesion over lower abdominal wound and adhesion band causing ischaemic small bowel	Similar to laparoscopic and thoracoscopic findings	Ischaemic bowel due to Adhesion Band	YES
4	M/59	Blood stained peritoneal fluid, Fat necrosis of omentum and necrotic looking pancreaa	Similar to laparoscopic and thoracoscopic findings	Liver Failure, Pancreatitis	YES
5	M/82	Cardiomegaly and mild stenotic coronary vessels	Blood in stomach and small bowel	Gastro-Intestinal Bleeding, Ischaemic Heart Disease	False –ve**
6	M/87	Cardiomegaly and stenotic coronary vessels	Similar to laparoscopic and thoracoscopic findings	Ischaemic Heart Disease	YES*
7	F/96	Carcinoma of gallbladder with invasion to liver and omentum, multiple liver metastases	Similar to laparoscopic and thoracoscopic findings	Carcinoma of Gallbladder	YES
8	M/32	Type B aortic dissection, dissection involving SMA and celiac trunk with ischaemic bowel	Similar to endoscopic findings	Aortic dissection – type B	YES#
9	M/75	Type A aortic dissection with dissection started at arch of aorta, blood in mediastinum in thoracoscopy	Similar to endoscopic findings	Aortic dissection – type A	YES#
10	F/91	Negative exploration	Similar to laparoscopic and thoracoscopic findings	Acute Myocardial infarction	YES*
11	M/80	No bowel ischaemia seen over abdominal cavity, prolene mesh used for abdominal closure after emergency rupture	Intact abdominal aneurysm repair, rupture thoracic aneurysm	Rupture Thoracic Aneurysm	YES

		abdominal aneurysm and fascia defect was identified, no intra or retroperitoneal haematoma seen. Blood in right pleural cavity, and haematoma over posterior mediastinum at costophrenic region			
12	M/56	Negative exploration	Cerebral hemorrhage caused by cerebrovascular accident	Cerebral Hemorrhage	YES*
13	F/87	Stenotic coronary artery, cardiomegaly	Similar to laparoscopic and thoracoscopic findings	Ischemic Heart Disease	YES*
14	M/80	Negative exploration	Fracture skull, severe brain injuries	Severe Head Injuries, Fell from Height	YES*
15	M/59	Congested lung parenchyma	-	Pulmonary hemorrhage	Clinical@
16	F/86	Congested lung parenchyma	-	Idiopathic fibrosing alveolitis	Clinical@
17	F/73	No ischemia of gastric remnant after open plication of bleeder for severe bleeding from duodenal ulcer in patient with previous history of 3-phase esophagectomy	-	Post-esophagectomy, GIB, Multi-organ failure	Clinical^
18	F/84	Ischacmic looking distal transverse colon in patient died of unexplained acidosis, necrotic mucosa of large bowel seen	-	Ischemic Colitis	Clinical^^
19	F/75	Blood over R peritoneal cavity with large liver tumor at segment 4	Ruptured HCC	Ruptured HCC	YES
20	M/75	Retroperitoneal haematoma over R iliac vessels	Ruptured aorto-iliac aneurysm	Ruptured aorto-iliac aneurysm	YES
21	F/44	Congested left lung, otherwise negative exploration	Similar to laparoscopic and thoracoscopic findings	Pneumonia	YES*
22	F/92	Negative exploration	Similar to laparoscopic and thoracoscopic findings	Ischemic Heart Disease	YES*

\* Negative exploration of thoracic and abdominal cavity

\*\* Blood in stomach was missed during laparoscopy



# Endoscopic examination of aorta

@ Clinical post-mortem examination with thoracoscopic biopsy of lung tissue performed

^ Clinical post-mortem examination with endoscopic examination of stomach performed

^^ Clinical post-mortem examination with laparoscopy performed

Figure 1: Number of deaths in HKSAR from 1999 to 2008

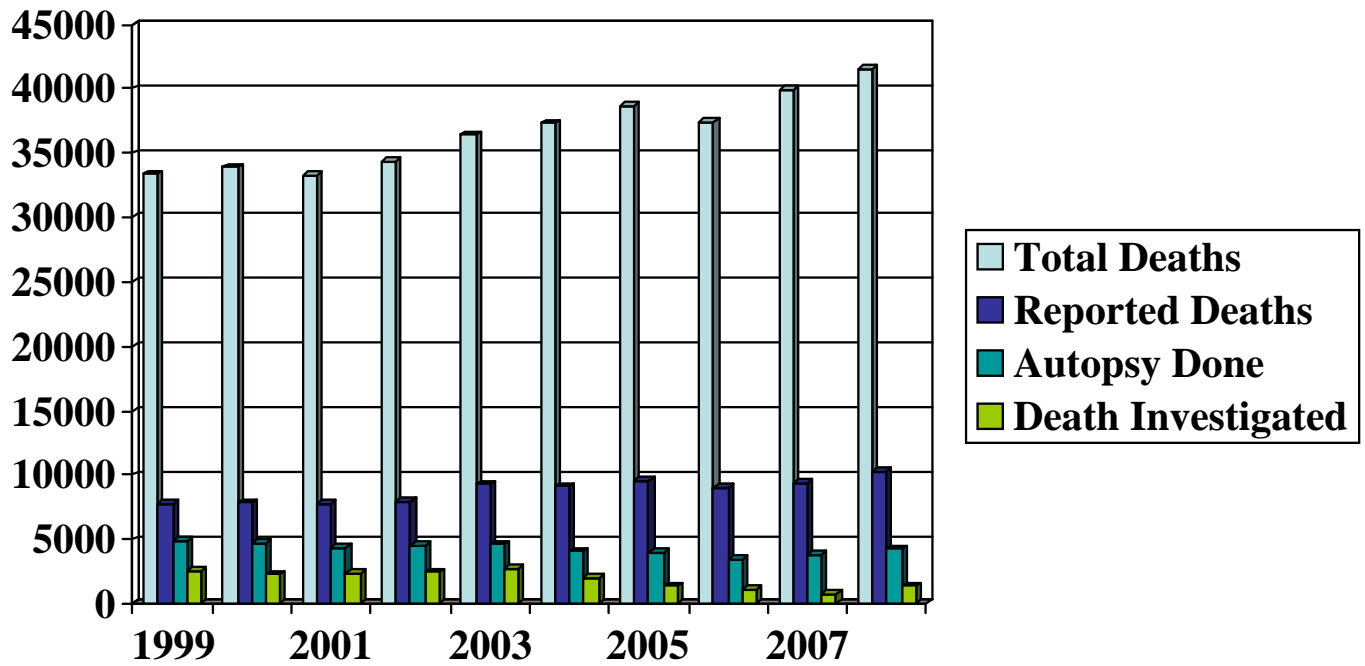


Figure 2: Biopsy of necrotic pancreas

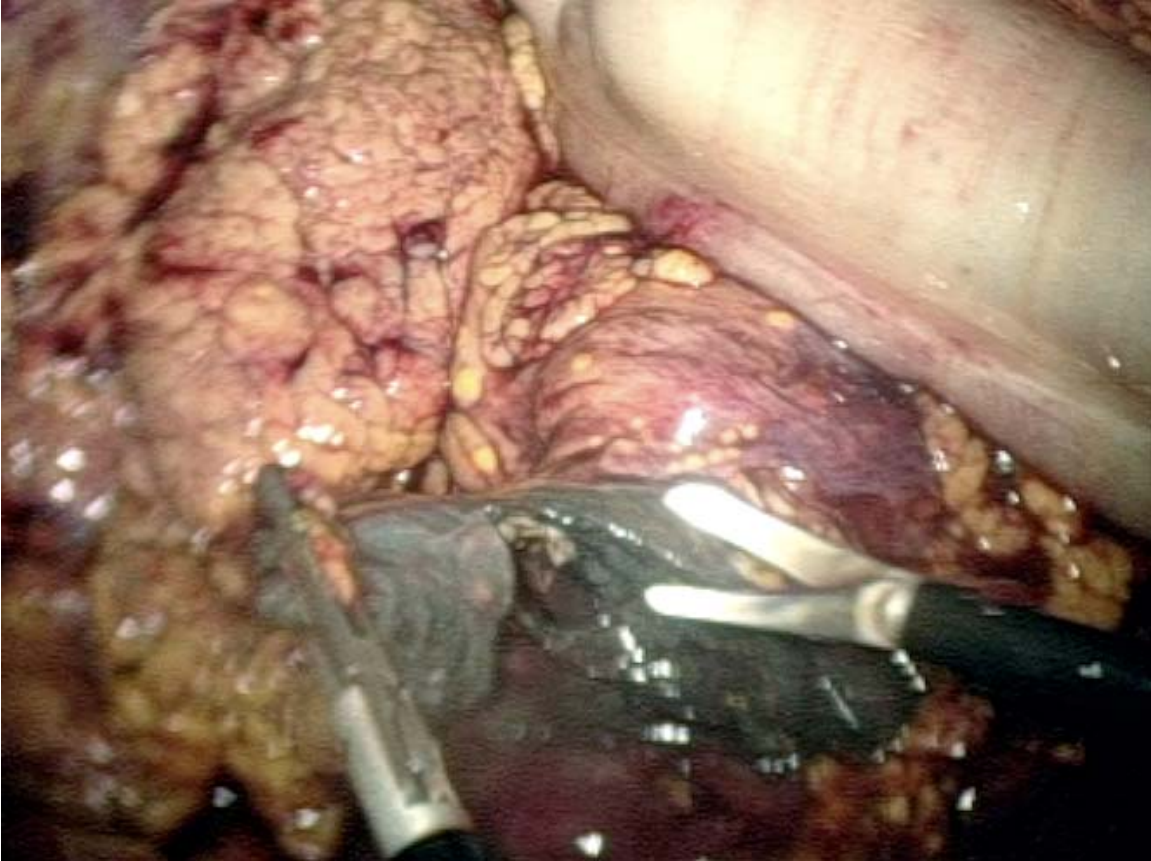

Figure 3: Carcinoma of gallbladder

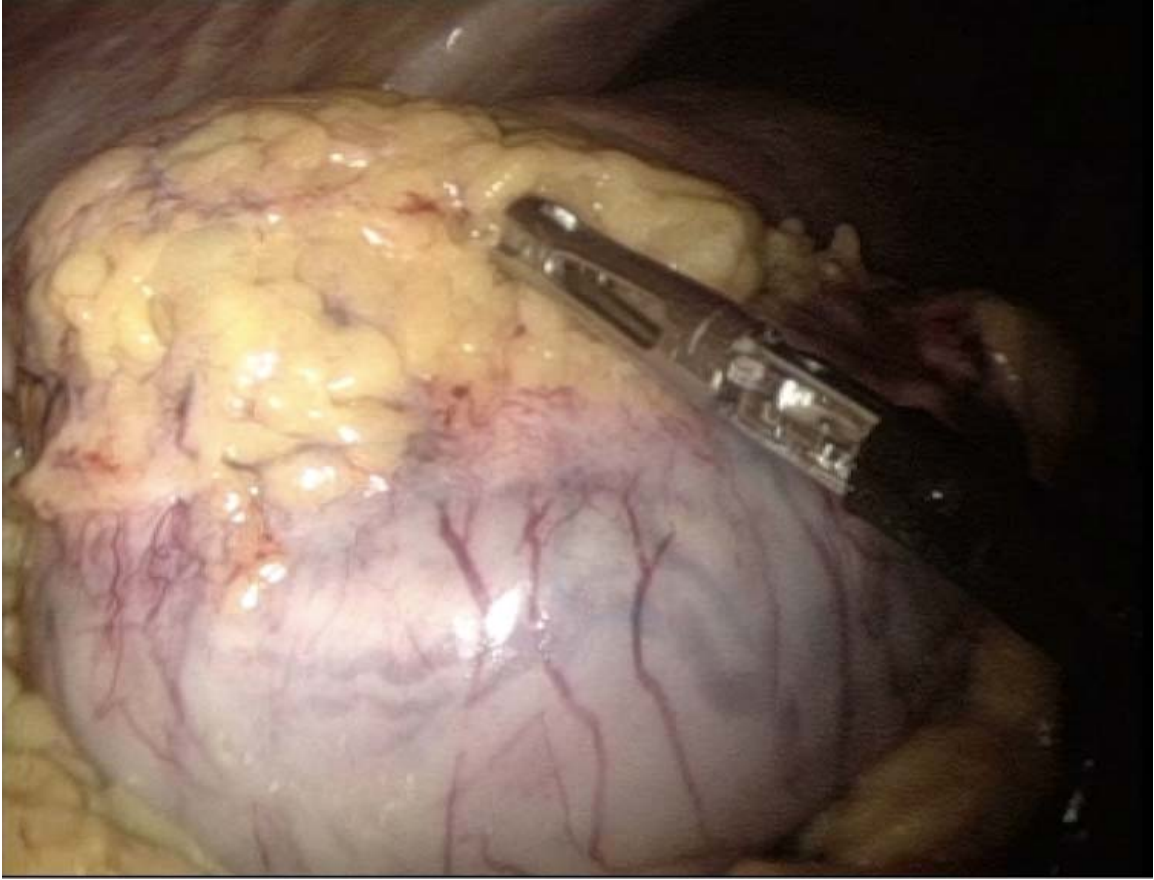

Figure 4: Adhesion banding causing gangrenous small bowel

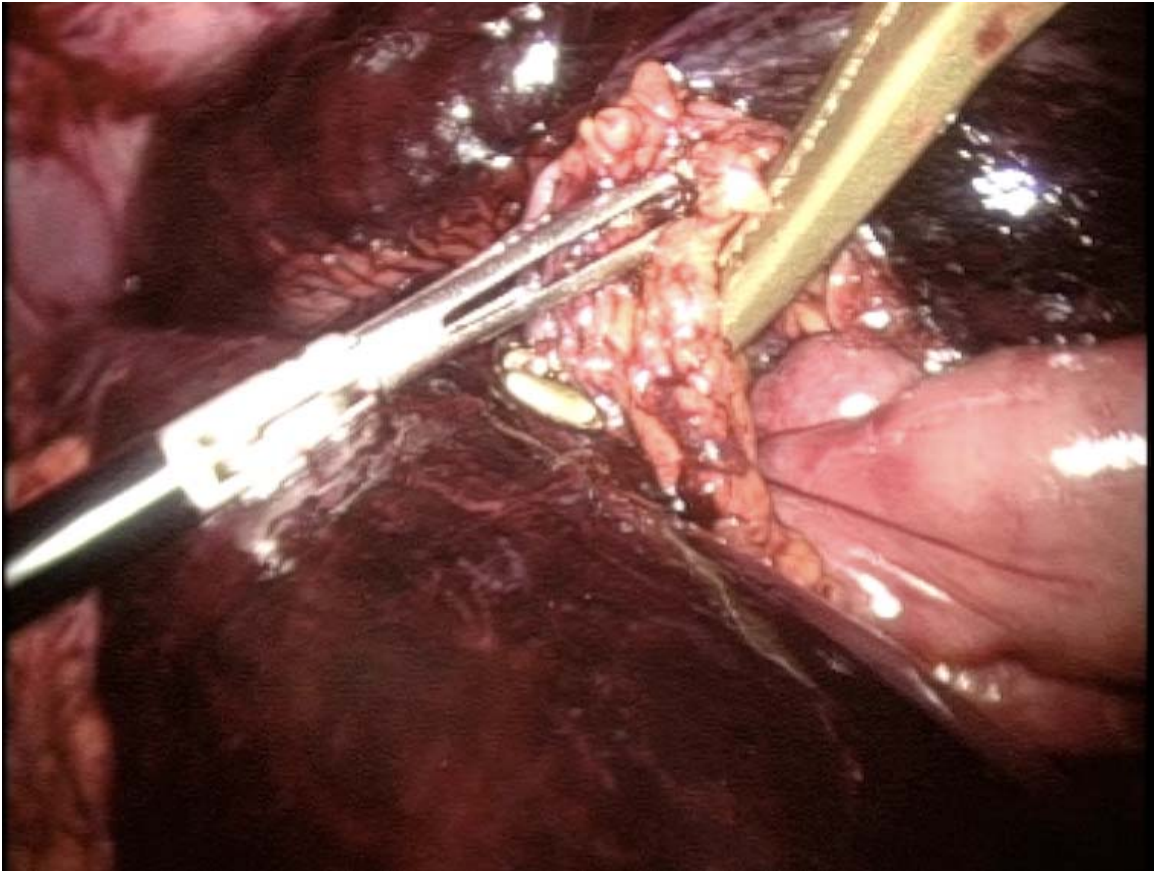


Figure 5: Laparoscopic view of prolene mesh used for abdominal closure after compartment syndrome

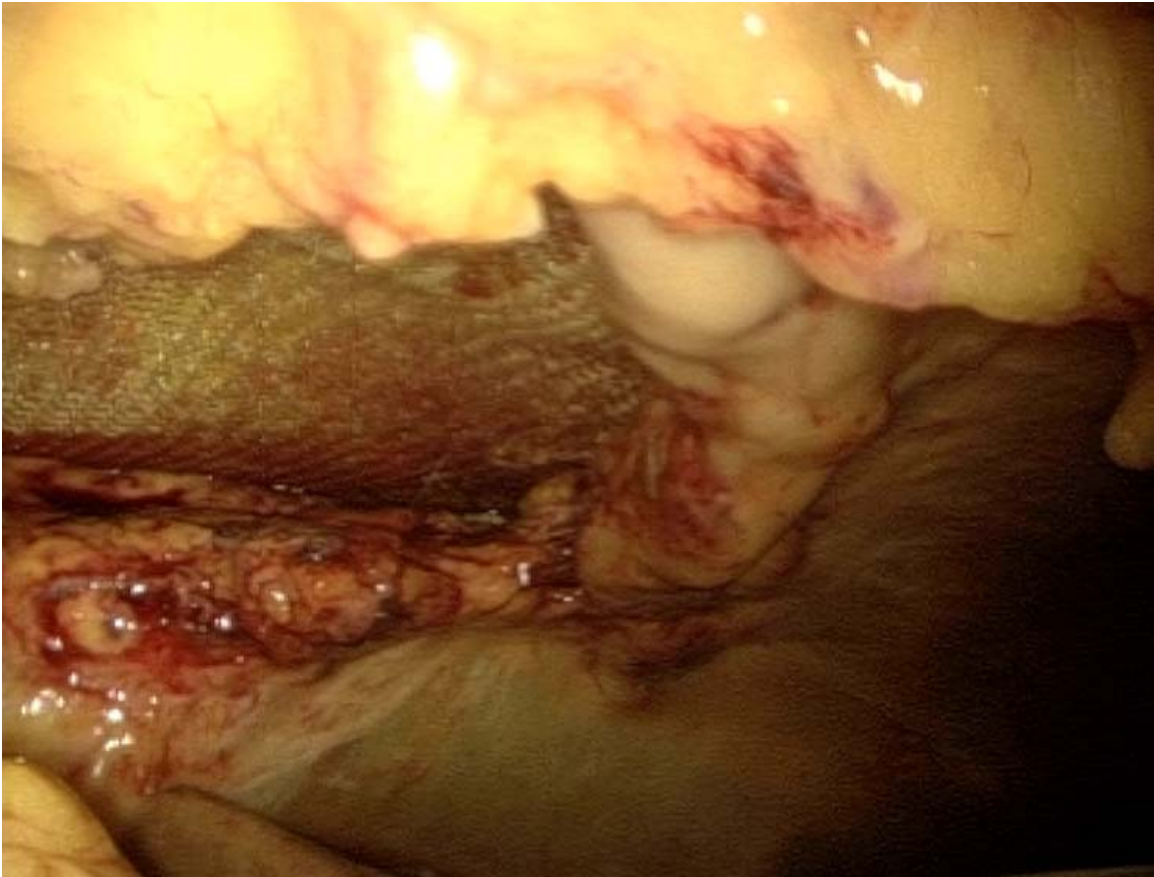

Figure 6: Ruptured hepatocellular carcinoma over segment 4

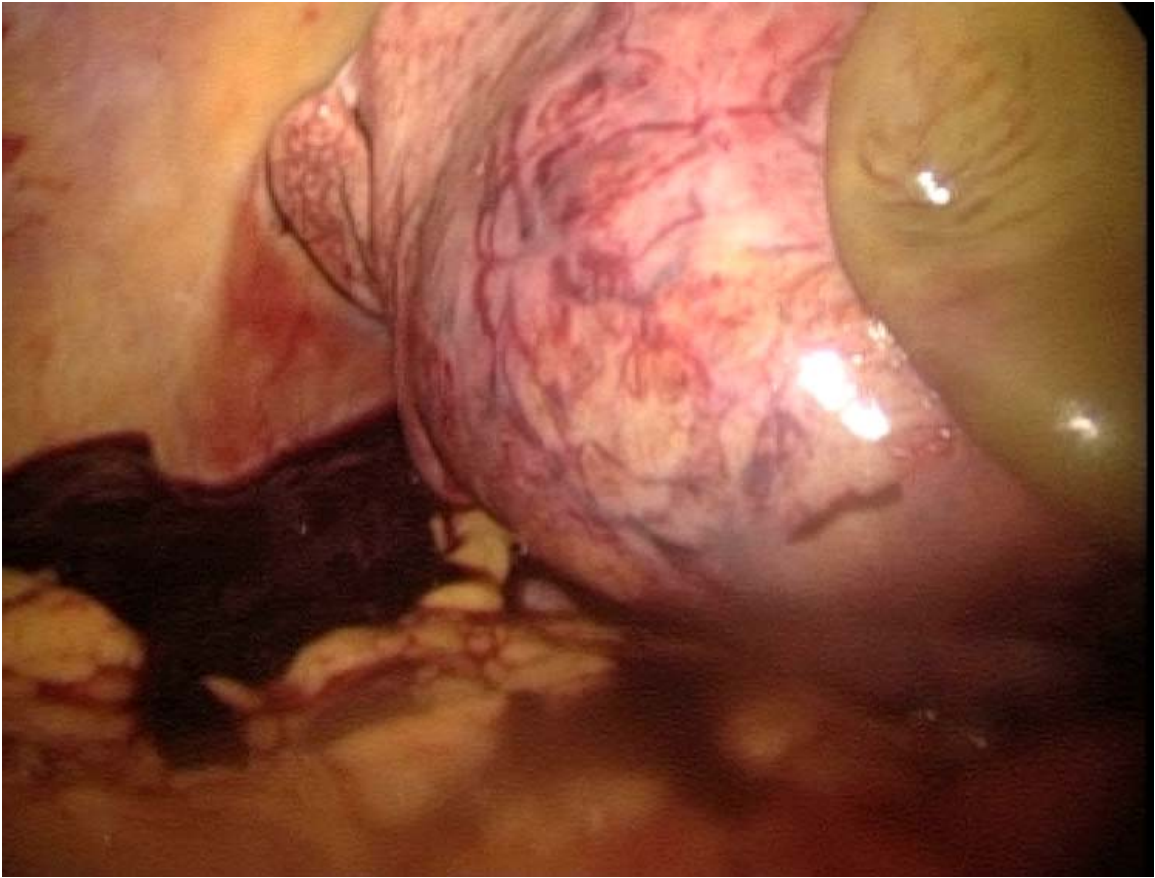

Figure 7: Thoracic aortic arch aneurysm

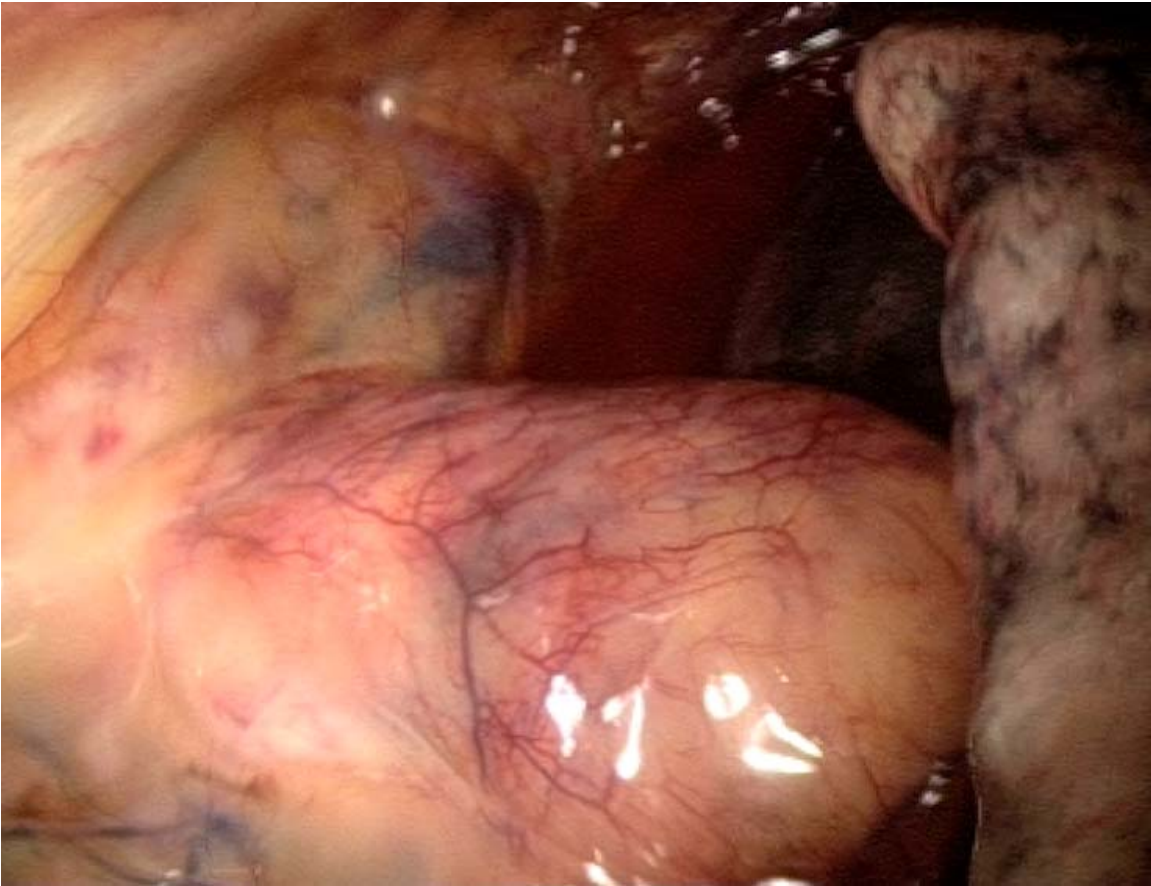




Figure 8: Isolation of external carotid artery

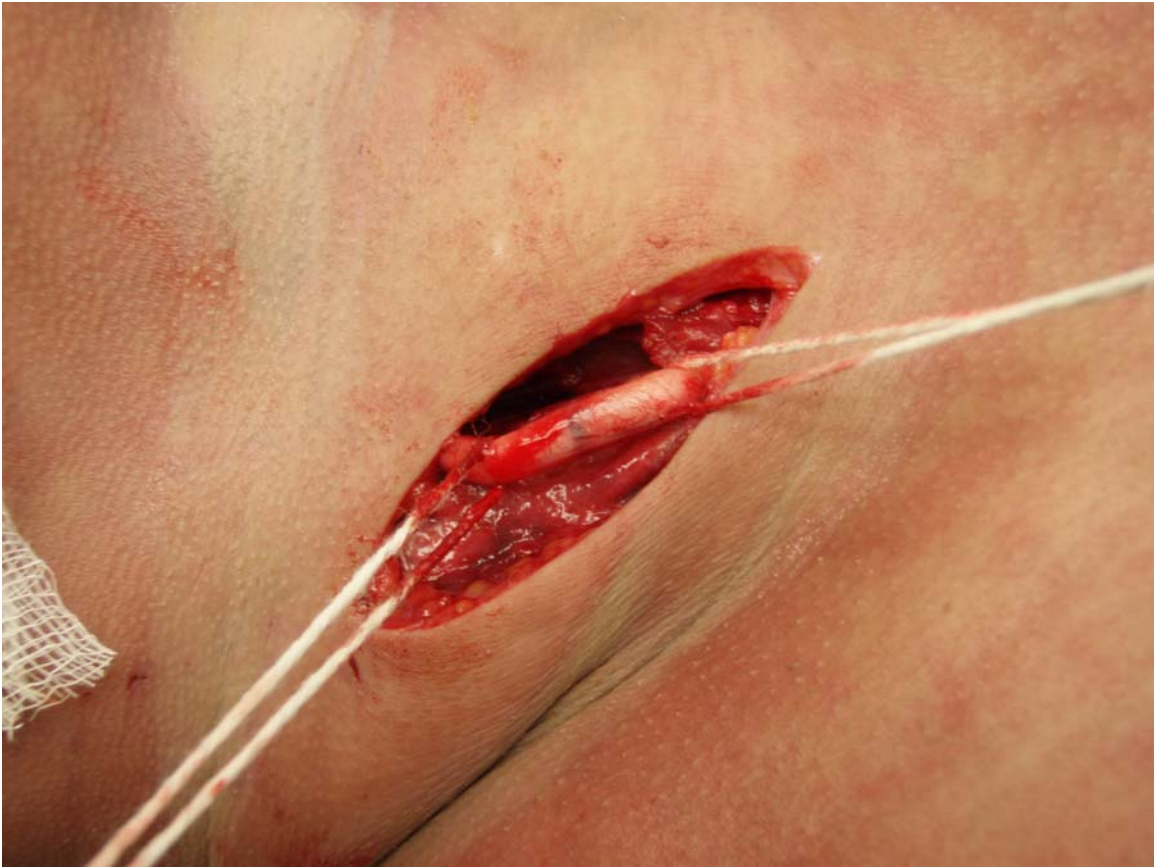


Figure 9: Endoscopic examination of aortic dissection with false lumen visualized

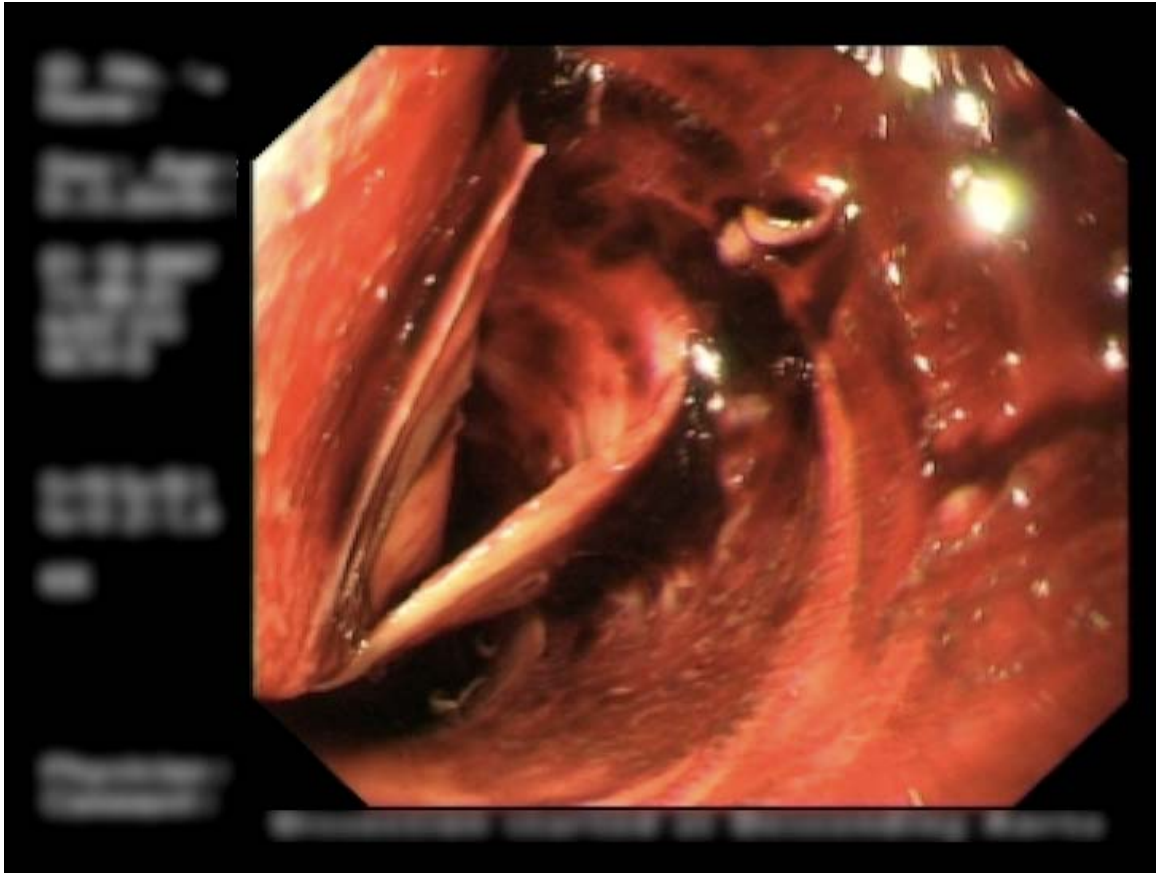


Figure 10: Use of Narrow Band Imaging to enhance visualization of false lumen

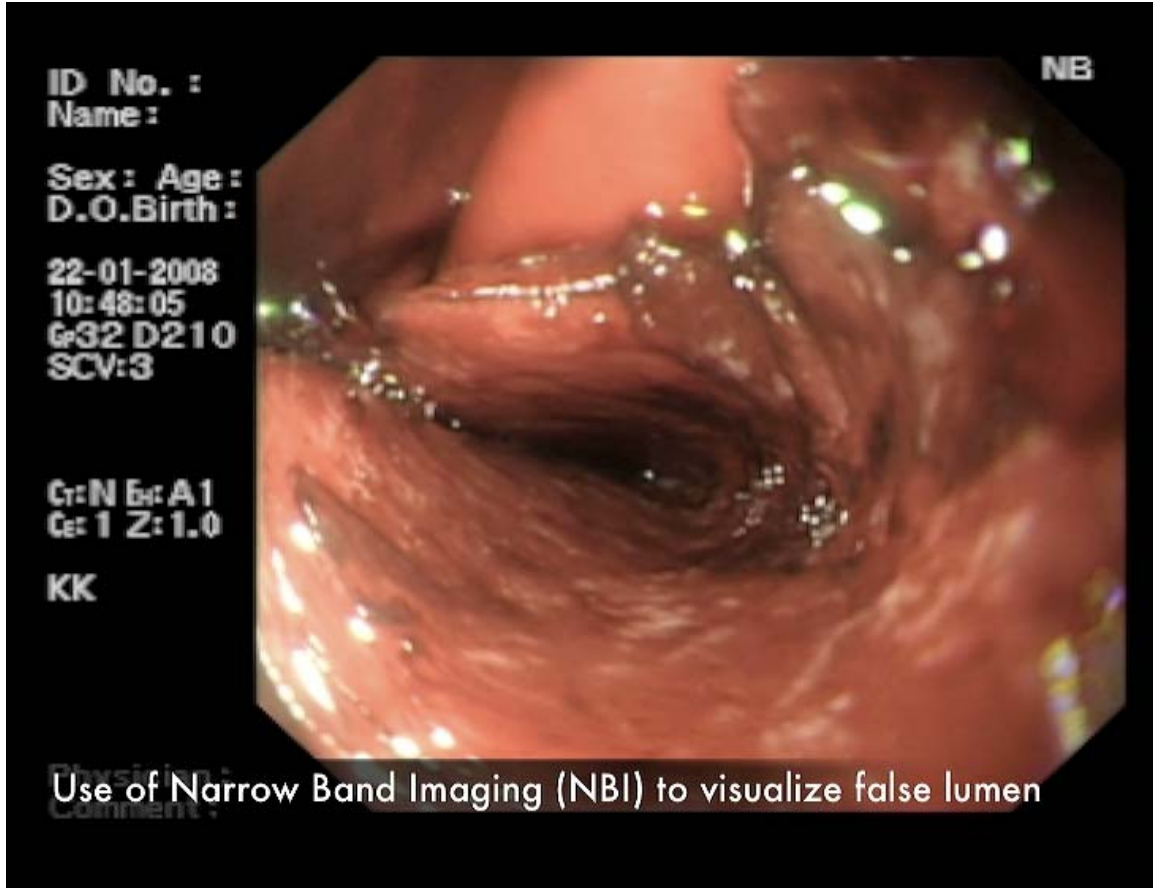
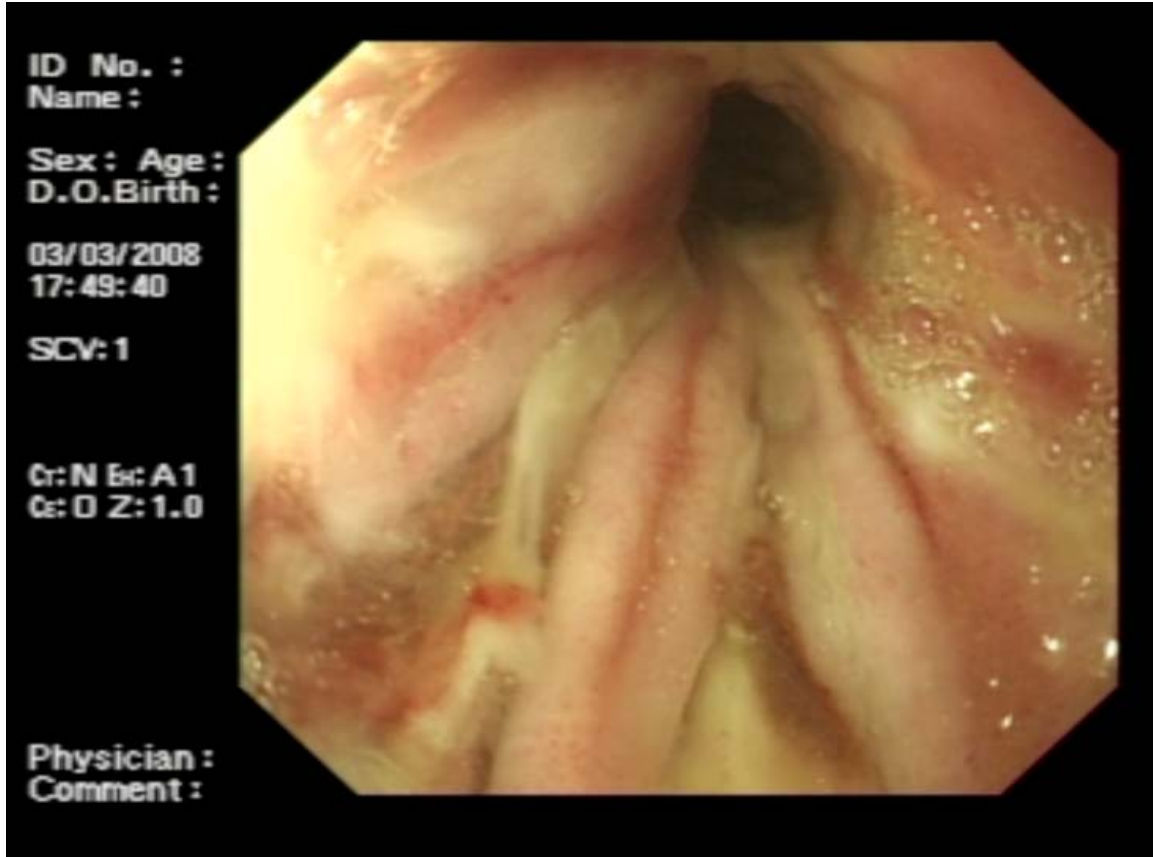


Figure 11: Endoscopic view of stomach remnant – no evidence of ischemia



## Appendix 1: Reportable Death in Hong Kong

1. Death the medical cause of which is uncertain
2. Sudden / unattended death, except where a person has been diagnosed before death with a terminal illness
3. Death caused by an accident or injury
4. Death caused by crime
5. Death caused by an anaesthetic or under the influence of a general anaesthetic or which occurred within 24 hours of the administering of anaesthetic
6. Death caused by a surgical operation or within 48 hours after a surgical operation
7. Death caused by an occupational disease or directly / indirectly connected with present or previous occupation
8. Still birth
9. Maternal death
10. Deaths caused by septicaemia with unknown primary cause
11. Suicide
12. Death in official custody
13. Where death occurred during discharge of duty of an officer having statutory powers of arrest or detention
14. Death in the premises of a Government Department any public officer of which has statutory powers of arrest or detention
15. Death of certain mental patients (as defined by law) in a hospital or in a mental hospital

16. Death in a private care home
17. Death caused by homicide
18. Death caused by a drug or poison
19. Death caused by ill-treatment, starvation or neglect
20. Death which occurred outside Hong Kong where the body of the person is brought into Hong Kong.

## References

1. Duband S, Raoux D, Dumollard JM et al. [Values of the autopsy in the university hospitals illustrated by the casuistry.]. *Rev Med Interne* 2008; 29:94-99.
2. The decline of the hospital autopsy: a safety and quality issue for healthcare in Australia. *Med J Aust* 2004; 180:281-285.
3. Sperhake J, Puschel K. [The autopsy law of Hamburg from February 9, 2000--changing autopsy rates in departments of pathology in Hamburg]. *Pathologe* 2003; 24:204-206.
4. Bombi JA, Ramirez J, Sole M et al. Clinical and autopsy correlation evaluated in a university hospital in Spain (1991-2000). *Pathol Res Pract* 2003; 199:9-14.
5. Brinkmann B, Du CA, Vennemann B. [Recent data for frequency of autopsy in Germany]. *Dtsch Med Wochenschr* 2002; 127:791-795.
6. Hull MJ, Nazarian RM, Wheeler AE et al. Resident physician opinions on autopsy importance and procurement. *Hum Pathol* 2007; 38:342-350.
7. Avrahami R, Watemberg S, Hiss Y et al. Laparoscopic vs conventional autopsy. A promising perspective. *Arch Surg* 1995; 130:407-409.
8. Avrahami R, Watemberg S, Hiss Y. Thoracoscopy vs conventional autopsy of the thorax. A promising perspective. *Arch Surg* 1995; 130:956-958.
9. Cacchione RN, Sayad P, Pecoraro AM et al. Laparoscopic autopsies. *Surg Endosc* 2001; 15:619-622.

10. Catheline JM, Turner R, Guettier C et al. Autopsy can be performed laparoscopically. *Surg Endosc* 1999; 13:1163-1164.
11. Catheline JM, Biaggi A, Barrat C et al. [Post mortem diagnostic laparoscopy]. *Chirurgie* 1999; 124:66-68.
12. Damore LJ, Barth RF, Morrison CD et al. Laparoscopic postmortem examination: a minimally invasive approach to the autopsy. *Ann Diagn Pathol* 2000; 4:95-98.
13. Shojania KG, Burton EC. The vanishing nonforensic autopsy. *N Engl J Med* 2008; 358:873-875.