



Title	A simple and secure method to fix laparoscopic trocars in children
Author(s)	Yip, PKF; Tam, PKH; Li, MKW
Citation	Journal of Laparoendoscopic & Advanced Surgical Techniques, 2006, v. 16 n. 2, p. 188-189
Issued Date	2006
URL	http://hdl.handle.net/10722/84296
Rights	Creative Commons: Attribution 3.0 Hong Kong License

Short Communication

A Simple and Secure Method to Fix Laparoscopic Trocars in Children

K.F. YIP, FHKAM,¹ P.K.H. TAM, ChM, FHKAM,² and M.K.W. LI, FHKAM¹

ABSTRACT

We introduce a simple method of fixing trocars to the abdominal wall in children. Before anchoring the trocar, a piece of Tegaderm™ polyurethane adhesive (3M Healthcare, St. Paul, Minnesota) is attached to the trocar. A silk stitch is anchored to neighboring skin, and then transfixed over the shaft of the trocar through the adhesive. Both inward and outward movement of the trocar can be restrained. This method is simple, fast, secure, and can be applied to trocars of any size.

INTRODUCTION

COMMON METHODS OF FIXING TROCARS onto the abdominal wall in children during a laparoscopic procedure are either insecure or clumsy. We present a method of trocar fixation during laparoscopic procedures in pediatric patients that is fast, simple, secure, and applicable to trocars of all sizes.

MATERIALS AND METHODS

After a trocar penetrates the abdominal wall of the patient, its shaft is dried and then sandwiched by a piece of Tegaderm™ polyurethane dressing (3M Healthcare, St. Paul, Minnesota). The two adhesive-free edges of the dressing stick together. The trocar is then transfixed obliquely with a 2-0 silk suture which pierces through the adhesive-free edge a few millimeters above skin level, and is then anchored to the neighboring skin (Figs. 1, 2).

DISCUSSION

Fixation of trocars in laparoscopic procedures is of utmost importance. A dislodged trocar can lead to air leakage, and inwardly displaced trocars jam the jaws of instruments. Therefore any movement of trocars must be restricted. This is more important in pediatric patients, given their thin abdominal walls and the limited peritoneal space.

Different methods of trocar fixation, including tying, intracorporeal button, and adhesive tape have been reported.¹⁻³ However, tying can only limit the outward dislodgement of trocars; the intracorporeal button needs specially prepared devices; and handling adhesive tape with a gloved hand can be clumsy. The adhesive also leaves glue on the surface of the trocar which is difficult to clean.

Our method of trocar fixation carries several advantages. It is simple and fast, and suitable for trocars of all sizes. It saves time, especially when several trocars need to be fixed in a procedure. It only requires simple and readily available materials, and can be applied as an adjunct to supplement anchorage whenever necessary. Al-

¹Department of Surgery, Pamela Youde Nethersole Eastern Hospital, Hong Kong, China.

²Division of Paediatric Surgery, University of Hong Kong Medical Centre, Queen Mary Hospital, Hong Kong, China.
Presented at the 14th Annual Congress for Endosurgery in Children, Venice, Italy, June 2005.

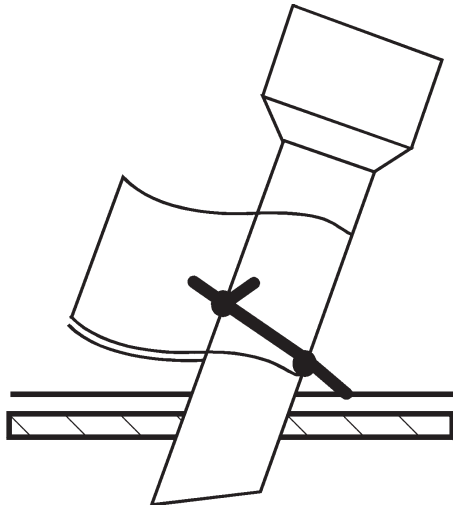


FIG. 1.

though it is simple, it is effective in avoiding both the inward and outward movement of trocars.

Tegaderm is especially suitable for this. It is a thin polyurethane film with an acrylic adhesive surface that sticks to both metal and plastic surfaces, and a non-slippery surface allowing suture tying securely and with ease. Tying with suture pierced through the adhesive gives extra strength. The dressing does not leave any glue on the instrument surface so cleansing is easy.

This is an easy and secure method for fixing the laparoscopic trocar in children.

REFERENCES

1. Asao T, Kuwano T, Shimura T, et al. An easy and certain method to prevent dislodging of laparoscopic ports. *Surg Laparosc Endosc Percutan Tech* 2003;13:125–127.
2. Bax NM, Can der Zee DC. Trocar fixation during endoscopic surgery in infants and children. *Surg Endosc* 1998;12:181–182.
3. Horvath KD, Whelan RL, Bessler M, et al. A new method to prevent port dislodgement during laparoscopic surgery. *Surg Endosc* 1995;9:526–527.

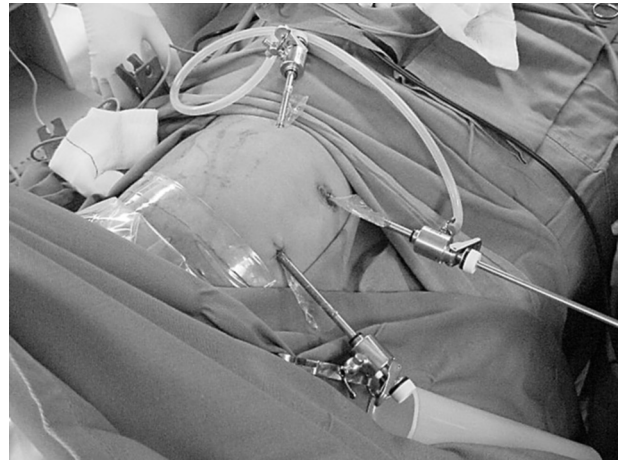

FIG. 2. Metallic trocars anchored during a laparoscopic nephrectomy in a 9-month-old girl.

Address reprint requests to:

K.F. Yip, MD

Department of Surgery

Pamela Youde Nethersole Eastern Hospital

3 Lok Man Road, Chai Wan

Hong Kong, SAR

China

E-mail: surgeryip@yahoo.com

