



Title	Dynamic treatment for proximal phalangeal fracture of the hand
Author(s)	Rajesh, G; Ip, WY; Chow, SP; Fung, BK
Citation	Journal Of Orthopaedic Surgery (Hong Kong), 2007, v. 15 n. 2, p. 211-215
Issued Date	2007
URL	http://hdl.handle.net/10722/79544
Rights	Journal of Orthopaedic Surgery. Copyright © Hong Kong Academy of Medicine Press.

Dynamic treatment for proximal phalangeal fracture of the hand

G Rajesh, WY Ip, SP Chow, BKK Fung

Department of Orthopaedics and Traumatology, University of Hong Kong, Queen Mary Hospital, Pokfulam, Hong Kong

ABSTRACT

Purpose. To assess a protected mobilisation programme (dynamic treatment) for proximal phalangeal fracture of the hand, irrespective of the geometry.

Methods. Clinical and radiological results of 32 consecutive patients with proximal phalangeal fracture of the hand treated from January 2001 to February 2007 were evaluated. Our supervised rehabilitation programme was strictly followed to gain full range of movement of the proximal interphalangeal joint and to prevent the development of an extension lag contracture. Patients were followed up for a mean period of 15 (range, 13–16) months. Results were evaluated using the Belsky classification.

Results. The results were excellent in 72% of the patients, good in 22%, and poor in 6%. Some patients defaulted follow-up, which made long-term assessment difficult. The poor results may have been related to patient non-compliance or default from rehabilitation. Many good results upgraded to

excellent following further rehabilitation.

Conclusion. Skeletal stability, not rigidity, is necessary for functional movements of the hand. Proximal phalangeal fractures can be effectively treated by closed methods, using the stabilising effect of soft tissues (zancolli complex–metacarpophalangeal retention apparatus) and external devices (metacarpophalangeal block splint), thus enabling bone healing and movement recovery at the same time.

Key words: *finger phalanges; fracture healing; hand injuries*

INTRODUCTION

Fractures of proximal phalanges of the hand, also known as 'no man's land',¹ irrespective of geometry, are difficult to treat, either conservatively or surgically. After surgery, tendinous phalangeal structures are prone to adhere and lose proximal interphalangeal (PIP) movement. Osteosynthesis does not guarantee stability and requires postoperative immobilisation. Four weeks of immobilisation was reported to

result in a 66% decrease of normal total active range of movement (ROM), and physiotherapy was required.²

Displaced proximal phalangeal fractures usually present with an apical palmar angulation where the interossei insert into the base of the proximal phalanx and flex the proximal fragment. At the same time, the distal fragment is hyperextended by the central slip acting on the base of the middle phalanx.³ The anterior surface of the proximal phalangeal shaft forms the floor of the flexor tendon sheath, so an anatomic reduction is very important for the phalangeal tendon to glide normally.³

Skeletal stability, not rigidity, is necessary for functional movement. Proximal phalangeal fractures can be treated by closed methods, using the stabilising effect of soft tissues (zancolli complex–metacarpophalangeal [MCP] retention apparatus) and external devices (thermoplastic MCP block splint).^{4,5}

Bleeding associated with fracture compromises the space between the tendon and dorsal cortex.¹ When the PIP joint is flexed, the tightened extensor acts as a tension band on the dorsal phalanx, tightening and moving the extensor aponeurosis distally in the splint. When the MCP joint flexes, the extensor tendon shifts distally, so that two thirds of the proximal phalanx is embraced and the fracture is stabilised in terms of axis, length, and rotation. Bone healing and movement recovery are therefore enabled at the same time.

MATERIALS AND METHODS

We evaluated clinical and radiological results of protected mobilisation (dynamic treatment) using a thermoplastic MCP block splint for proximal phalangeal fractures (irrespective of geometry), among 20 men and 12 women presenting between January 2001 and February 2007. Inclusion criteria were: (1) single-digit, closed, proximal phalangeal fracture; (2) displaced, extra-articular involvement; (3) non-pathological, fresh (<1 week) injury; (4) no associated injuries (e.g. tendon rupture or collateral tear) and with an intact capsule or Zancolli complex; and (5) absence of infection.

There were 24 patients aged ≤50 years and 8 patients aged >50 years; 10 had dominant hand and 22 had non-dominant hand injuries. Three injured the index finger, 4 the middle, 6 the ring, and 19 the little finger.

Treatment was modified, if required, depending on radiological and clinical observations (Fig. 1), e.g.

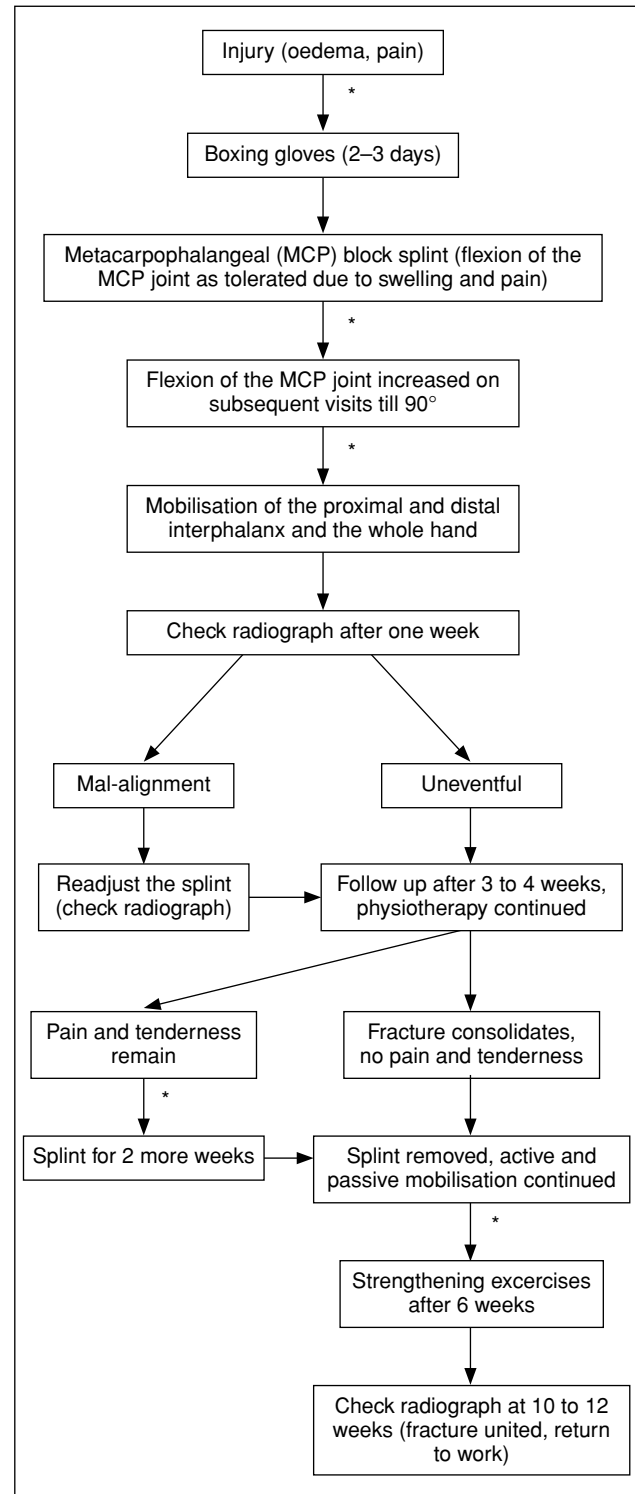


Figure 1 Treatment algorithm.

* Radiological and clinical examination

(1) extension lag—vigorous passive mobilisation, followed by dynamic extension splinting, if the lag

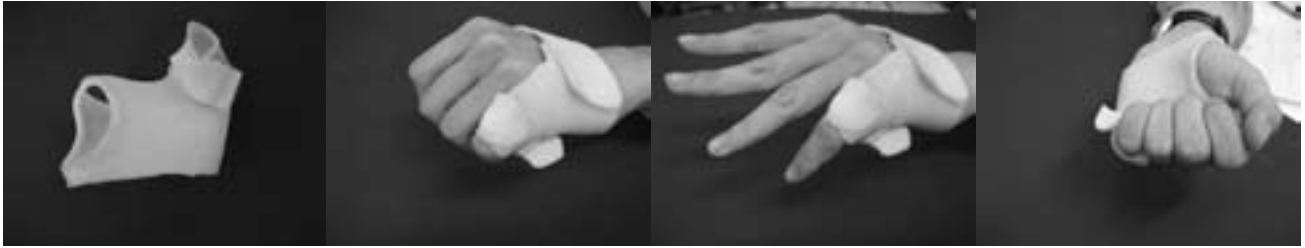

Figure 2 Active mobilisation of the hand with the thermoplastic metacarpophalangeal block splint.

remained after stabilisation; (2) improper splintage—modified splintage to achieve proper angulation for fracture alignment; (3) improper rehabilitation—re-education of the patient regarding treatment and physiotherapy; and (4) unacceptable reduction—fracture re-reduction under radiographic control and additional double splintage, if required.

Reductions were considered acceptable when (1) $<10^\circ$ axial angulation was evident on anteroposterior radiographs, (2) $<15^\circ$ axial angulation on lateral radiographs, (3) no rotation, and (4) no collapse affecting functional outcome.

The rehabilitation protocol was based on principles of external positioning and active mobilisation. Fracture mal-alignment was caused by intrinsic muscle forces, not external forces. Proper external positioning controlled the deforming muscle forces. Active ROM exercises were started as soon as patients were capable; all fingers were closed simultaneously to negate any rotational mal-alignment problem. When all fingers were flexed simultaneously in the presence of fully flexed MCP joints, rotational deformity could be treated at the same time. All fingers had to close at the same time to avoid overlapping (Fig. 2). Thermoplastic MCP block splints could be removed for fracture re-alignment and taking radiographs. Proximal phalangeal fractures tended to have extensor lag at the PIP joint. Flexion contracture could be avoided with passive extension exercises. Favourable results were expected if early radiographs showed proximal phalanx alignment, without rotational deformity and satisfactory flexion of the PIP joint with only a mild degree of extensor lag. Formation of callous could be seen on radiographs at 3 to 4 weeks (Fig. 3), at which time the finger was clinically stable, and the external immobilisation was removed. If the phalanx or metacarpal remained tender on palpation, immobilisation was continued for further 2 to 3 weeks.

Functional and radiological assessments were made at each follow-up, and included ROM of

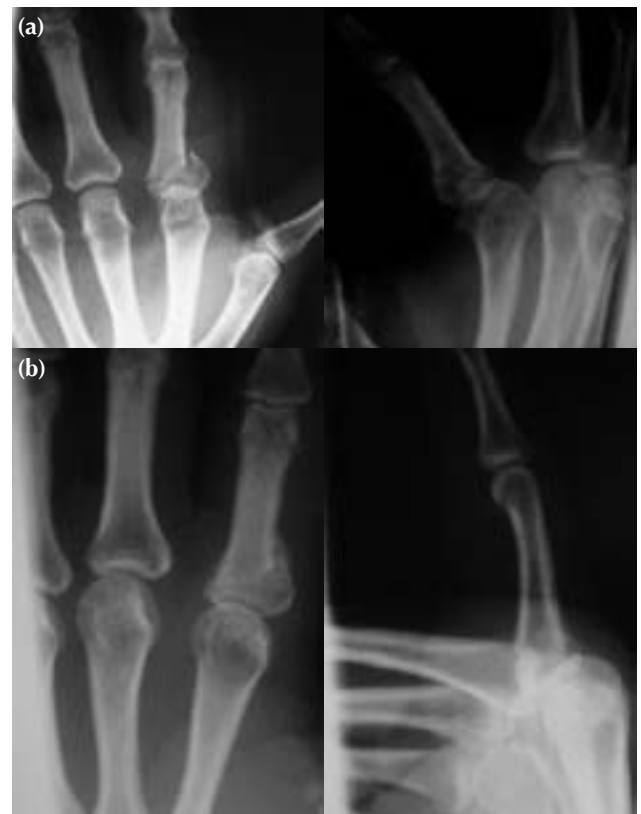

Figure 3 (a) Preoperative radiographs showing a comminuted proximal phalangeal fracture of the ring finger. (b) Postoperative 7-week radiographs showing bone union after dynamic treatment.

the MCP, PIP, and distal interphalangeal (DIP) joints, and total active ROM of the injured finger was measured. Vigorous physiotherapy was performed to overcome flexion and extension lags, so as to prevent future contracture. Grip and pinch strengths were evaluated after fracture stabilisation (at week 8).

Table 1
Outcomes according to gender, age, and hand dominance

Outcome	Gender		Age		Hand	
	Male, n=20	Female, n=12	≤50 years, n=24	>50 years, n=8	Dominant, n=10	Non-dominant, n=22
Excellent	15 (75%)	8 (67%)	21 (88%)	2 (25%)	7 (70%)	16 (73%)
Good	4 (20%)	3 (25%)	2 (8%)	5 (63%)	2 (20%)	5 (23%)
Fair to poor	1 (5%)	1 (8%)	1 (4%)	1 (13%)	1 (10%)	1 (5%)

Table 2
Descriptive features of 32 patients with proximal phalangeal fractures

Patient No.	Age (years)/sex	Injured finger	Range of movement (degrees)*				Grip/pinch strength (%)	Extension/flexion lag (degrees)	Anteroposterior/lateral angulation (degrees)	Return to work (weeks)
			MCP	PIP	DIP	Total active				
1	52/M	Middle	0-95	5-95	0-80	265	100/100	5/0	-	13
2	71/M	Little	0-95	7-90	0-80	258	100/95	7/0	5/5	9
3	15/M	Little	0-95	0-90	0-75	260	100/100	0/0	-	9
4	47/F	Little [†]	0-85	0-95	0-85	265	100/100	0/0	-	11
5	48/F	Index	0-86	0-94	0-80	260	90/95	0/0	-	9
6	44/M	Little [†]	0-80	0-100	0-60	240	100/95	0/0	-	15
7	57/F	Little	0-80	0-80	0-70	230	90/90	0/10	0/5	10
8	16/M	Little	0-90	0-90	0-80	260	100/100	0/0	-	9
9	27/F	Ring	0-95	0-100	0-80	275	95/90	0/0	-	9
10	29/F	Little [†]	0-90	0-100	5-70	255	90/80	0/0	-	8
11	15/M	Ring	0-100	10-100	0-80	270	80/70	10/0	-	12
12	46/M	Little	0-75	5-90	0-65	225	100/83	5/0	5/5	14
13	52/M	Middle [†]	0-80	0-98	5-60	233	80/85	0/0	-	14
14	26/M	Little	0-90	5-95	0-90	270	80/75	5/0	-	10
15	45/M	Little [†]	0-90	5-90	0-90	265	85/100	5/0	5/5	13
16	19/M	Ring [†]	0-90	0-95	5-85	265	75/90	0/0	-	13
17	43/F	Little	0-90	0-90	0-90	270	95/100	0/0	0/5	12
18	73/M	Little	0-75	5-90	0-70	230	80/100	5/0	5/10	15
19	53/F	Little	0-80	6-86	0-75	235	90/85	6/4	0/5	13
20	49/M	Little	0-90	0-90	0-80	260	100/100	0/0	-	9
21	22/M	Index	0-90	0-108	0-82	280	100/100	0/0	-	10
22	46/F	Little	0-90	5-90	0-85	260	90/90	5/0	10/0	15
23	46/M	Ring	0-85	0-100	0-82	267	93/70	0/0	-	12
24	21/M	Little [†]	0-85	0-100	0-75	260	90/80	0/0	-	10
25	32/M	Index	0-95	0-100	0-85	280	96/73	0/0	-	10
26	35/M	Middle	0-92	0-100	0-72	264	100/89	0/0	-	12
27	49/F	Little [†]	0-60	10-75	0-45	170	70/55	10/15	10/15	15
28	13/F	Ring	0-85	0-95	0-80	260	95/90	0/0	-	12
29	12/F	Ring [†]	0-80	0-100	0-80	260	-	0/0	-	10
30	74/M	Little	0-70	15-70	10-55	170	100/100	15/20	10/10	14
31	53/F	Little	0-80	5-90	0-75	240	90/90	5/0	-	13
32	12/M	Middle [†]	0-90	0-100	0-80	270	90/100	0/0	-	10

* MCP denotes metacarpophalangeal, PIP proximal interphalangeal, and DIP distal interphalangeal

[†] Dominant hand

Results were classified according to Belsky et al.⁶ into: excellent (no symptoms, pain-free union, no angular/rotational deformity, PIP movement of >100°, total active ROM of >250°); good (minimal angular/rotational deformity, PIP movement of >80°, total active ROM of >180°); fair; and poor (remaining unchanged).

RESULTS

The mean follow-up period was 15 (range, 13–16) months. According to the Belsky classification,⁶ 23 (72%) patients attained excellent, 7 (22%) attained good, and 2 (6%) attained fair to poor results (Table 1). As per Reyes and Latta criteria,⁷ all of our patients

attained excellent results. Those aged ≤ 50 years had significantly better functional results than older patients. Hand dominance was evenly distributed between groups and showed no significant difference in terms of functional outcomes. Males attained better results than females (Table 2).

No tendon adhesion, intrinsic contracture, infection, non-union, or malunion was noted. Two patients attained poor results: a 74-year-old man with the non-dominant hand little finger injured and a 49-year-old woman with the dominant hand little finger injured. Both patients had bone union. They returned to work and had minimal deformities and pain at the extremes of movement. The poor result may have been related to patient non-compliance or default from rehabilitation. Many good results upgraded to excellent after further rehabilitation.

DISCUSSION

The anatomical attachment of the proximal phalanx and the stability provided by the surrounding soft tissue envelope are the mainstay for dynamic conservative treatment of proximal phalangeal fractures.⁵ Proximal phalangeal fractures are better

treated conservatively with less complications; bone healing and recovery of ROM should occur simultaneously, not consequently.⁷ After closed treatment using plaster of Paris, supervised rehabilitation can facilitate attainment of full flexion at the PIP joint and prevent development of extension lag contractures.^{1,3} A mixed series of intra- and extra-articular proximal phalangeal fractures treated by forearm thermoplastic splints has been reported to give good results, following acute reduction of the fracture under digital anaesthesia.⁴ Our treatment modality involved gradual reduction and increase in flexion at MCP joint, without anaesthesia.

CONCLUSION

Despite a small sample size, the early functional results of our patients with dynamic treatment were better than those with other treatment modalities, but late results were approximately the same.^{1,3,4,7-10} Surgical procedures have disadvantages such as: prolonged rehabilitation periods, requiring a minimum of 2 interventions (for fixation and removal), economic and social losses, and the stress of undergoing surgery coupled with the risks of anaesthesia.

REFERENCES

1. Burkhalter WE. Closed treatment of hand fractures. *J Hand Surg Am* 1989;14:390-3.
2. Strickland JW, Steichen JB, Klienman WB, Hastings H II, Flynn N. Phalangeal fractures. Factors influencing digital performance. *Orthop Rev* 1982;11:39-50.
3. Widgerow AD, Edinburgh M, Biddulph SL. An analysis of proximal phalangeal fractures. *J Hand Surg Am* 1987;12:134-9.
4. Ebinger T, Erhard N, Kinzl L, Mentzel M. Dynamic treatment of displaced proximal phalangeal fractures. *J Hand Surg Am* 1999;24:1254-62.
5. Widgerow AD, Ladas CS. Anatomical attachments to the proximal phalangeal base—a case for stability. *Scand J Plast Reconstr Surg Hand Surg* 2001;35:85-90.
6. Belsky MR, Eaton RG, Lane LB. Closed reduction and internal fixation of proximal phalangeal fractures. *J Hand Surg Am* 1984;9:725-9.
7. Reyes FA, Latta LL. Conservative management of difficult phalangeal fractures. *Clin Orthop Relat Res* 1987;214:23-30.
8. Hurov JR, Concannon MJ. Management of metacarpophalangeal joint fracture using a dynamic traction splint and early motion. *J Hand Ther* 1999;12:219-27.
9. Elmaraghy MW, Elmaraghy AW, Richards RS, Chinchalkar SJ, Turner R, Roth JH. Transmetacarpal intramedullary K-wire fixation of proximal phalangeal fractures. *Ann Plast Surg* 1998;41:125-30.
10. Liew KH, Chan BK, Low CO. Metacarpal and proximal phalangeal fractures—fixation with multiple intramedullary Kirschner wires. *Hand Surg* 2000;5:125-30.