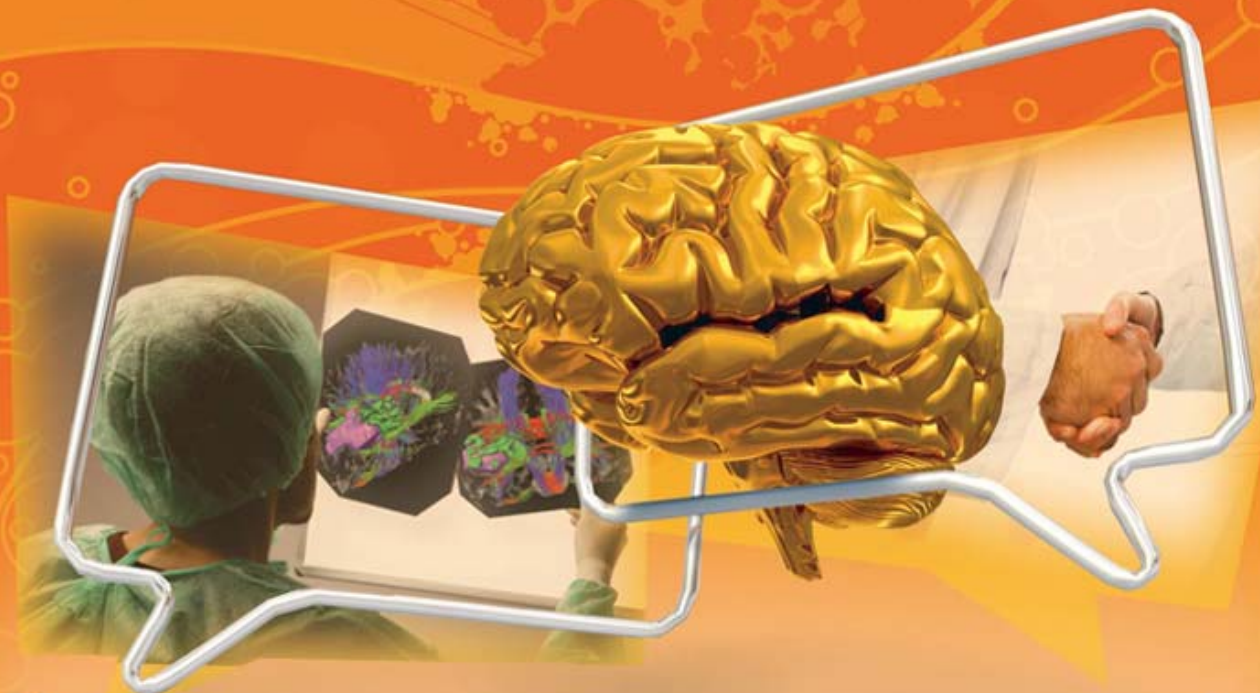



Title	Incidence of subjective anosmia after interhemispheric approach to anterior skull pathology
Author(s)	Li, LF; Leung, GKK
Citation	The 15th Annual Scientific Meeting of the Hong Kong Neurosurgical Society (HKNS), Hong Kong, 21-22 November 2008. In Programme Book, 2008, p. 47
Issued Date	2008
URL	http://hdl.handle.net/10722/62862
Rights	Creative Commons: Attribution 3.0 Hong Kong License



15th Annual Scientific Meeting The Hong Kong Neurosurgical Society



Controversies in Neurosurgery

Date

21 November 2008 (Fri) &
22 November 2008 (Sat)



Welcome Message	2
Council Of The Hong Kong Neurosurgical Society	4
Guest Faculty	5
Venue Floor Plan	10
Programme at a Glance	12
Programme for Free Paper	14
Programme for Oral Poster	15
Programme for Nursing Session	16
Abstracts:	
Free Paper I	18
Free Paper II	24
Free Paper III	28
Free Paper IV	31
Free Paper V	33
Oral Paper I	38
Oral Paper II	43
Nursing Session	50
Acknowledgement	56



Welcome Message

Dear invited guests, members and colleagues,

It is my pleasure to welcome you to the 15th Annual Scientific Meeting of our Hong Kong Neurosurgical Society on behalf of the organizing committee. This year, we are very honored to have very salient figures in our specialty as well as medical profession of Hong Kong as a whole to be our speakers. First of all, we have Prof. Shigeaki Kobayashi of Shinshu University to be our overseas invited speaker. Secondly, Dr. York Chow, the Secretary for Food and Health of the Hong Kong Special Administrative Region, will deliver a keynote lecture. Thirdly, we have Prof. David Fang, past president of the Hong Kong Academy of Medicine. He is currently the Chairman of the Ethics Committee of the Medical Council of Hong Kong. However, our meeting will not sparkle without the participation of local speakers. Dr. CF Fung, Dr. TH Aung, Prof. WS Poon and Dr. Samuel Leung are also our local keynote speakers. I think this company of distinguished scholars with different background will shine up the whole meeting and inspire all participants.



Lastly, I have to express my deepest thanks to the hard work of the organizing committee, the council particularly Dr. YC Po, Dr. KY Yam and Dr. KN Hung for making our meeting successful.

Looking forward to seeing you in the meeting.



Wong Chi Keung
President
The Hong Kong Neurosurgical Society

Welcome Message



Dear invited guests, members and colleagues,

It is my great pleasure to welcome you to the 15th Annual Scientific Meeting of the Hong Kong Neurosurgical Society.

The Hong Kong Neurosurgical Society has always been keen on organizing activities for the local fellow neurosurgeons, our younger generations of trainees and our nurses. We have been trying our best to invite renowned speakers from Hong Kong and all over the world to share with us with their brilliant knowledge.

This year, we are delighted to have Professor Kobayashi as our guest speaker. Professor Kobayashi is a renowned neurosurgeon and he has been the Professor Emeritus of the Shinshu University of Japan. He has a vast interest on various topics on cerebrovascular surgery, brain tumour and skull base surgery, microsurgical anatomy and cerebral circulation research; as well as the development of neurosurgical instruments, image analysis and surgical simulation and surgical robotics. It would be fascinating to learn his views on the various controversies in Neurosurgery.



On our regional side, Dr. York Y.N. Chow, SBS, JP, the Secretary for Food and Health of the Government of the Hong Kong Special Administrative Region would give us his vision in the future of Neurosurgery in Hong Kong. Drs. T.H. Aung and C.F. Fung would also share with us their precious experience on their successful neurosurgical career.

The Annual Scientific Meeting serves as the platform for neurosurgical research. This year, we are going to have our fellow neurosurgeons and surgical trainees and our neurosurgical nursing colleagues to share their brilliant work on oral presentation and poster sections.

On behalf of the organizing committee, I would like to thank Dr. C.K. Wong, our President, and all the council members, core members of the Nurse Chapter, the conference managers for their vast support on this meeting. I would also like to thank our commercial partners for their generous support and sponsors.

Finally, I would like to thank all the participants for the time and effort. I hope it would be a memorable meeting that all of us would treasure in the year 2008.

Dr. Yin-chung Po
Honorary Secretary



Council Of The Hong Kong Neurosurgical Society

Council

President	:	Dr. Chi-keung Wong
Vice President	:	Dr. Kwan-ngai Hung
Honorary Secretary	:	Dr. Yin-chung Po
Honorary Treasurer	:	Dr. Kwong-yui Yam
Council Members	:	Dr. Hok-ming Chiu
		Dr. Gilberto Leung
		Dr. George Wong
		Dr. Xian-lun Zhu

Organising Committee

Dr. Chi-keung Wong
Dr. Kwan-ngai Hung
Dr. Yin-chung Po
Dr. Kwong-yui Yam

Audio-visual Support

Dr. Marco Kwan
Dr. Hing-yuen Law
Dr. Yat-hang Tse
Mr. Kai-chi Cheng



The Organising Committee would like to thank
the guest faculties for their invaluable participation in and contribution to the

15th Annual Scientific Meeting

Professor Shigeaki Kobayashi, M.D.

Professor Emeritus, Shinshu University
Director, Medical Research and Education Center
Director, Stroke and Brain Center
Aizawa Hospital
Japan

Dr. York, Y N Chow, SBS, JP

Secretary for Food and Health
Government of the Hong Kong Special Administrative Region

Dr. David Fang

Chairman, Ethics Committee
The Medical Council of Hong Kong

Dr. Ching-fai Fung

Specialist in Neurosurgery



Guest Faculty



Professor Shigeaki Kobayashi, MD

Academic Appointments

Professor Emeritus, Shinshu University
Director, Medical Research and Education Center
Director, Stroke and Brain Center, Aizawa Hospital

Education

Shinshu University School of Medicine	1957-1963
Rotating internship at U.S. Naval Hospital, Yokosuka, Japan	1963-1964
Residency in Surgery at Shinshu University Hospital	1964-1965
Residency in Neurosurgery at Mayo Clinic (Mayo Graduate School of Medicine, The University of Minnesota)	1965-1971

Degrees

M.D. from Shinshu University	1963
Master of Science in Neurological Surgery, Mayo Graduate School of Medicine (The University of Minnesota)	1971
PhD, Neurosurgery, Shinshu University Graduate School of Medicine	1977

Certificate

National Board for Medical Practice in Japan	1964
American Board of Neurological Surgery	1971
Japanese Board of Neurological Surgery	1971
Board of the Japan Stroke Society	2003

Professional Experience

Professor and Chairman, Department of Neurosurgery, Shinshu University School of Medicine	1988-2003
Professor Emeritus, Shinshu University	2003.4
Director, Komoro Kosei General Hospital	2003.4- 2006.3
Director, Stroke and Brain Center & Director, Medical Education and Research Center, Aizawa Hospital	2006.4

Dr York Chow, SBS, JP

*Secretary for Food and Health
Government of the Hong Kong Special Administrative Region*




Dr Chow is an orthopaedic surgeon by profession. He was appointed Hospital Chief Executive of Queen Elizabeth Hospital in 1992 and Hospital Chief Executive of Queen Mary Hospital in 2001. He was subsequently appointed Cluster Chief Executive of the Hong Kong West Cluster of the Hong Kong Hospital Authority in 2002. He took up the post of Secretary for Health, Welfare and Food in October 2004 and the post of Secretary for Food and Health in July 2007.

Professionally, he served as President of the Hong Kong Orthopaedic Association, Vice-President of the College of Orthopaedic Surgeons, and was elected Council Member of the Hong Kong Academy of Medicine. He is currently an Honorary Professor in Rehabilitation Science at the Hong Kong Polytechnic University, and an Honorary Professor of the Medical Faculty of the University of Hong Kong.

Dr Chow participates actively in voluntary and community work. He served as Vice-Chairman of the Hong Kong Sports Development Board and the Sports Institute, and as a member of the Rehabilitation Task Force.

He was elected Vice-President of the International Paralympic Committee in 1997-2005 and was Chairman of the Hong Kong Sports Association for the Physically Disabled between 1986 and 2004.




Guest Faculty

Dr. David Fang

*Chairman, Ethics Committee
The Medical Council of Hong Kong*

Education and professional Qualifications:

M.B.,B.S., University of Hong Kong	- 1972
M.Ch. Orth., University of Liverpool	- 1979
F.R.C.S.(Edin.)	- 1978
F.R.A.C.S.	- 1985
FHKCOS	- 1987
F.H.K.A.M. (Orthopaedic Surgery)	- 1993
FRCP RCPS (Glasg)	- 1999



Present Appointments :

Medical Superintendent, St. Paul's Hospital since June 2002
Consultant Orthopaedic Surgeon, St. Paul's Hospital since Oct 1994
Honorary Professor, Faculty of Medicine, University of Hong Kong since 1997
Honorary Clinical Professor, Department of Orthopaedic Surgery, University of Hong Kong since 2005
Member, Hong Kong Medical Council since 1989
Chairman, Ethics Committee, Hong Kong Medical Council since Feb 2003
Chairman, Hong Kong Academy of Medicine Foundation Fund since 1991
Chairman, Hospital Governing Committee,
MacLehose Medical Rehabilitation Centre (MMRC), Hospital Authority since 1991
President, The Hong Kong Society for Rehabilitation since Oct 2003
Director, WHO Collaborating Centre for Rehabilitation since 2005
Editor-in-Chief, Journal of Orthopaedic Surgery since Nov 1992
Member, Health and Medical Development Advisory Committee, Hong Kong Special Administrative Region since 1994
Member, Sports Commission since Jan 2005
Honorary President, Arts with the Disabled Association Hong Kong since 2006

Past Appointments :

President, Hong Kong Academy of Medicine (1996-2000)
President, Hong Kong Medical Association (1992-94)
President, Hong Kong Orthopaedic Association (1987, 88)
Chairman, Health and Medical Development Advisory Committee, Hong Kong Special Administrative Region (1994-2005)

Decorations and honours :

Silver Bauhinia Star, The Government of the Hong Kong Special Administrative Region, awarded for contribution to medical services, 1998
Non official Justice of the Peace, since July 1992
Hon. Fellow, Hong Kong Academy of Medicine 2005
Hong Kong Academy of Medicine Medal, 2001
Honorary Fellow, Royal Australasian College of Physicians, 1997
Fellowship by election, Royal College of Surgeons of England 1997
Ninth Dr. Sun Yat Sen Orator and Gold Medal, Hong Kong College of Family Physicians, 1998
Fellow, Academy of Medicine of Malaysia, 1997
Fellow, Academy of Medicine, Singapore, 1998
Fellow, Hong Kong College of Otorhinolaryngologists 2002

Dr. Ching - fai Fung

Specialist in Neurosurgery

Honorary Appointments

Honorary Clinical Associate Professor
Department of Surgery, University of Hong Kong

Honorary Consultant Neurosurgeon
Queen Mary Hospital

Qualifications

Specialist in Neurosurgery
M.B.B.S. (HKU) 1978
F.R.C.S. (Edinburgh) 1983
F.R.C.S. (Glasgow) 1983
F.H.K.A.M. (Surgery)
F.C.S.H.K.

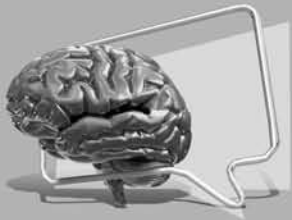

Professional Societies

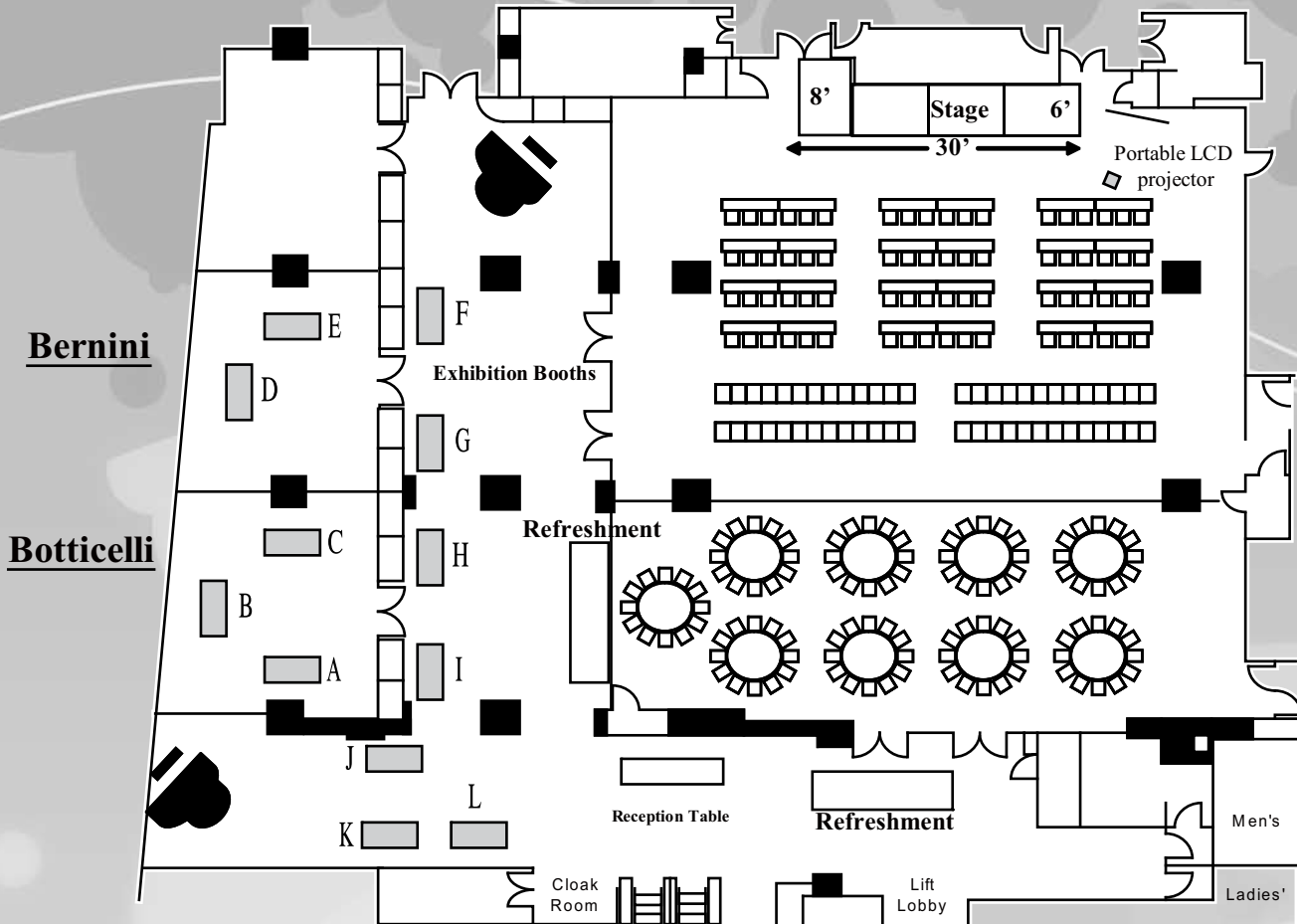
The Hong Kong Neurosurgical Society	
Honorary Secretary	1986-1990
Council Member	1990-1994
Vice-Chairman	1994-1998
The Hong Kong Brain Foundation	
Chairman	1993-2002
Congress of Neurological Surgeons, U.S.A	
International Member	1994

Previous Appointments

Medical Officer, Neurosurgical Unit, Queen Elizabeth Hospital	79-80
Medical Officer, Surgical Unit, United Christian Hospital	80-83
Medical Officer, Neurosurgical Unit, Queen Elizabeth Hospital	83-86
Hon Clinical Fellow, Department of Neurosurgery University of Birmingham, UK	86-87
Senior Medical Officer, Division of Neurosurgery, Department of Surgery, University of Hong Kong, Queen Mary Hospital	87-89
Lecturer and Chief of Neurosurgery, Division of Neurosurgery, Dept of Surgery, University of Hong Kong, Queen Mary Hospital	89-92
Consultant and Chief of Neurosurgery, Division of Neurosurgery, Dept of Surgery, University of Hong Kong, Queen Mary Hospital	92-96



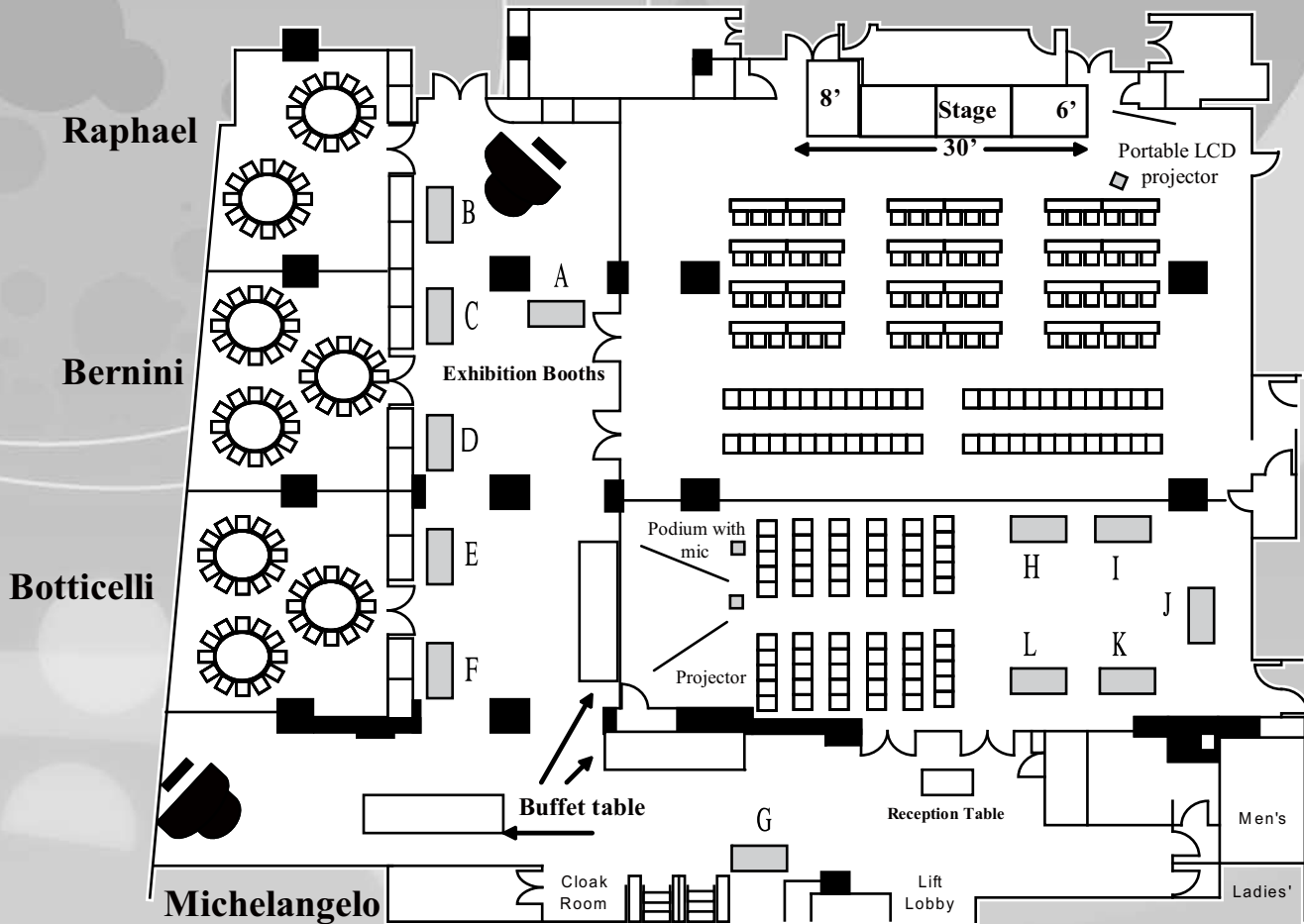
Venue Floor Plan



21st November, 2008

Booth No.	Company
A	Stryker China Ltd.
B	SOL Limited (Schering-Plough)
C	Boston Scientific HK Ltd.
D	Baxter Healthcare Ltd.
E	Esaote China Ltd.
F	Newtech International Trading Ltd.
G	Johnson & Johnson (HK) Ltd.
H	B. Braun Medical (HK) Ltd.
I	Medtronic International Ltd.
J	Carl Zeiss Far East Co. Ltd.
K	The Industrial Promoting Co. Ltd.
L	BrainLAB Ltd.

Venue Floor Plan



22nd November, 2008

Booth No.	Company
A	Carl Zeiss Far East Co. Ltd.
B	Stryker China Ltd.
C	Medtronic International Ltd.
D	B. Braun Medical (HK) Ltd.
E	Johnson & Johnson (HK) Ltd.
F	BrainLAB Ltd.
G	Newtech International Trading Ltd.
H	Baxter Healthcare Ltd.
I	The Industrial Promoting Co. Ltd.
J	SOL Limited (Schering-Plough)
K	Esaote China Ltd.
L	Boston Scientific HK Ltd.



Programme at a Glance

Venue: Ballroom A, 2/F Langham Hotel, Peking Road, Tsimshatsui, Kowloon

Time	Date	21 November 2008 (Friday)		
9:00 a.m. – 9:15 a.m.		Registration		
9:15 a.m. – 10:15 a.m.	EXHIBITION AND POSTERS	<u>Keynote Lecture I</u> Surgical treatment of paraclinoid aneurysm Prof. Shigeaki Kobayashi <i>Chairpersons: Dr. ST Chan & Dr. HM Chiu</i>		
10:15 a.m. – 10:50 a.m.		Tea Break		
10:50 a.m. – 12:14 p.m.		<u>Free Paper I</u> <i>Chairpersons: Dr. ST Chan & Dr. HM Chiu</i>		
12:14 p.m. – 13:40 p.m.		Lunch	13:15 p.m. – 13:40 p.m.	<u>Oral/Poster I</u> <i>Chairpersons: Dr. KY Pang & Dr. Gilberto Leung</i>
13:40 p.m. – 13:45 p.m.		Society project presentation		
13:45 p.m. – 14:45 p.m.		<u>Seminar on Poor Grade SAH</u> <i>Moderators: Dr. WM Lui, Dr. George Wong, Dr. SC Yuen</i>		
14:45 p.m. – 15:21 p.m.		<u>Free Paper II</u> <i>Chairpersons: Dr. CF Fung & Dr. KN Hung</i>		
15:21 p.m. – 15:50 p.m.		Tea Break		
15:50 p.m. – 16:20 p.m.		<u>Keynote Lecture II</u> Intramedullary spinal tumour Dr. Fung Ching Fai <i>Chairpersons: Dr. MK Lam & Dr. YW Fan</i>		
16:20 p.m. – 16:56 p.m.		<u>Free Paper III</u> <i>Chairpersons: Dr. MK Lam & Dr. YW Fan</i>		
16:56 p.m. – 17:00 p.m.		Concluding Remarks		
Venue for ASM Dinner: The Garden Suite, 7th Floor, Peninsula Hotel, Kowloon				
18:30 p.m. – 19:00 p.m.	Welcome Cocktail			
19:00 p.m. – 20:00 p.m.	<u>Guest Lecture</u> Medical Professional Liability Dr. David Fang <i>Chairpersons: Dr. CK Wong</i>			
20:00 p.m. – 21:30 p.m.	Annual Scientific Meeting Dinner			

Programme at a Glance



Time	Date	22 November 2008 (Saturday)		
9:00 a.m. – 9:15 a.m.		Registration		
9:15 a.m. – 10:15 a.m.	EXHIBITION AND POSTERS	<u>Keynote Lecture III</u> Experience with tPA treatment for acute cerebral infarct Prof. Shigeaki Kobayashi <i>Chairpersons: Dr. YT Kan & Dr. SC So</i>		
10:15 a.m. – 10:45 a.m.		Tea Break		
10:45 a.m. – 11:45 a.m.		<u>Seminar on Pituitary Tumour</u> <i>Moderators: Prof. W Poon</i> <i>Dr. Samuel Leung & Dr. CK Wong</i>	<u>Nursing Session</u> <i>Chairpersons:</i> <i>Ms Shum Chor Wai, Rita &</i> <i>Mr. Poon Wai Leung</i>	
11:45 a.m. – 12:21 p.m.		<u>Free Paper IV</u> <i>Chairpersons: Dr. TH Aung</i> <i>& Dr. FC Cheung</i>		
12:21 p.m. – 14:00 p.m.		Lunch	13:35 p.m. – 14:00 p.m.	<u>Oral/Poster II</u> <i>Chairpersons: Dr. XL Zhu & Dr. WM Lui</i>
14:00 p.m. – 15:00 p.m.		<u>Keynote Lecture IV</u> Sustaining Quality of Healthcare <i>York YN Chow, SBS, JP</i> <i>Chairpersons: Dr. Dawson Fong & Dr. CK Wong</i>		
15:00 p.m. – 15:48 p.m.		<u>Free Paper V</u> <i>Chairpersons: Dr. KH Chan & Prof. W Poon</i>		
15:48 p.m. – 16:20 p.m.		Tea Break		
16:20 p.m. – 16:50 p.m.		<u>Keynote Lecture V</u> Reflections of my life – Village doctor to a Neurosurgeon Dr. Aung Tin Htun <i>Chairpersons: Dr. KH Chan & Prof. W Poon</i>		
16:50 p.m. – 17:00 p.m.		Concluding Remarks		



Programme for Free Paper

Programme for Free Paper Sessions on 21 November 2008

Free Paper I <i>Chairpersons: Dr. ST Chan & Dr. HM Chiu</i>	
10:50 a.m. – 11:02 a.m.	Challenges in the Endovascular Management of Cerebral Aneurysm Remnants after Surgical Clipping: An illustrative case <i>CT Pun / PYM Woo / CY Law / KS Wong / WS Ho / KY Pang / CK Wong</i>
11:02 a.m. – 11:14 a.m.	The making of an aneurysm model by neurosurgical trainees <i>Law Hing Yuen / Leung Kar Ming / Lui Wai Man / Hung Kwan Ngai</i>
11:14 a.m. – 11:26 a.m.	Measurement of the exposure of clinoidal ICA after anterior clinoidectomy and proximal and distal dural ring cut <i>YH Tse / PH Wong / WM Lui</i>
11:26 a.m. – 11:38 a.m.	Outcome of Epilepsy Surgery at the Tuen Mun Hospital <i>BBT Taw / DTS Fong / KY Yam / WK Chak / TTS Lai</i>
11:38 a.m. – 11:50 a.m.	Decompressive craniectomy for hemispheric infarction: value of early surgery and predictive factors for outcome <i>Mak WK / Wong GK / Poon WS</i>
11:50 a.m. – 12:02 p.m.	Management outcome of cerebral arteriovenous malformation: Multimodality treatment in a neurosurgical center in Hong Kong <i>Ng YT / Wong GK / Kam KM / Yu SC / Poon WS</i>
12:02 p.m. – 12:14 p.m.	Management of atypical meningioma – The experience from Princess Margaret Hospital <i>CP Tsang / TH Aung</i>
Free Paper II <i>Chairpersons: Dr. CF Fung & Dr. KN Hung</i>	
14:45 p.m. – 14:57 p.m.	The effect of concomitant and adjuvant chemotherapy on the survival of Chinese patients with primary Glioblastoma Multiforme (GBM) <i>Danny TM Chan / Benedict Ng / Stephanie Ng / Brigette Ma / KM Kam / XL Zhu / WS Poon</i>
14:57 p.m. – 15:09 p.m.	Diffusion Tensor Tractography of the Facial Nerve in Cerebellopontine Angle Tumors <i>PHD Wong / R Lee / WM Lui</i>
15:09 p.m. – 15:21 p.m.	Can Magnetic resonance arteriography replace digital subtraction angiography in patients having intracranial aneurysm treated with endovascular coiling? <i>Yu Chi Hung / Cheng Kin Ming / Cheung Yuk Ling / Tang Kwok Wing / Chan Chi Ming / Siu Chi Wai, Jimmy</i>
Free Paper III <i>Chairpersons: Dr. MK Lam & Dr. YW Fan</i>	
16:20 p.m. – 16:32 p.m.	Extended-Subtemporal Transcavernous Transpetrosal Transtentorial Approach for petroclival tumours – Review of surgical results <i>WM Lui / Jenny Pu / YW Fan</i>
16:32 p.m. – 16:44 p.m.	Accuracy of Percutaneous Placed Lumbar Pedicle Screws in Hong Kong Chinese patients <i>Sun TF David / Ng Wing Kit / Poon WS</i>
16:44 p.m. – 16:56 p.m.	Temporal lobe radionecrosis in patients with nasopharyngeal carcinoma: Should early surgery be advocated? <i>ST Wong / KY Yam / D Fong</i>

Programme for Free Paper



Free Paper IV

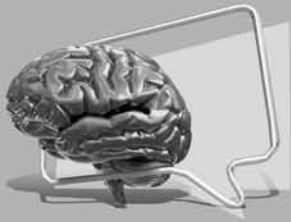Chairpersons: Dr. TH Aung & Dr. FC Cheung

11:45 a.m. – 11:57 a.m.	Endoscopic third ventriculostomy (EVT) and biopsy for pineal region tumour: single or two burr holes? <i>Gao R / Zhu XL / Wong HT / Wong KC / Ng YT / Wong Rosanna / Poon WS</i>
11:57 a.m. – 12:09 p.m.	Management outcome of NPC-related and non-NPC-related brain abscess in Hong Kong <i>Tam MH / Wong GK / Zhu XL / Ip M / Poon WS</i>
12:09 p.m. – 12:21 p.m.	A Cluster of CNS Infections <i>Cheng KF / Lee WY / Lee RA / Yip Ida / Wong CK</i>

Free Paper V

Chairpersons: Dr. KH Chan & Prof. W Poon

15:00 p.m. – 15:12 p.m.	A regional hospital experience in Onyx the liquid embolic agent <i>Calvin HK Mak / JCK Kwok / KY Chan / KH Pang</i>
15:12 p.m. – 15:24 p.m.	A review of treatment outcome in adult cerebral AVM in terms of AVM control, obliteration rate and clinical outcome <i>MY Chan / ST Wong / KY Yam / D Fong</i>
15:24 p.m. – 15:36 p.m.	Onyx embolization of cerebral arteriovenous malformation in Hong Kong: a single institute experience over 14 months <i>Wong GK / Yu SC / Poon WS</i>
15:36 p.m. – 15:48 p.m.	APOE Influences Vasospasm and Outcome of patients with aneurysmal subarachnoid hemorrhage in Chinese Population <i>Tai WH / Poon WS</i>



Programme for Oral Poster

Programme for Oral Poster Paper I

13:15 p.m. – 13:40 p.m. 21 November 2008 (Friday)

Oral Poster Paper I

Chairpersons: Dr. KY Pang & Dr. Gilberto Leung

Ventriculoperitoneal Shunt Failure and Infection: a retrospective review at Queen Mary Hospital
PHD Wong / G Leung

Radiation-induced meningioma and cavernous hemangioma in a patient with Gorlin syndrome
– A case report
Co Michael / Cheng Kin Ming / Chiu Hok Ming

Dissecting extracranial vertebral artery
Kenneth Law

Review of ruptured cerebral aneurysm management in Tuen Mun Hospital
Samuel SK Lam / WM Hung / KY Yam / Dawson Fong

Thyroid-stimulating hormone secreting pituitary adenoma – Case report
Samuel SK Lam / KY Yam / Dawson Fong

Computer-assisted Spinal Navigation for Multi-level Thoraco-lumbar Transpedicular screw insertion: An illustrative case
CY Law / PYM Woo / KS Wong / WY Lee / WS Ho / KY Pang / CK Wong

Lumbar Spine Intradural Epidermoid Cyst: Case Report and Review of the Literature
CT Pun / PYM Woo / KS Wong / WY Lee / WS Ho / KY Pang / CK Wong

Role of Computed Tomography Angiography in the Diagnosis of Arteriovenous Malformations in an Emergency setting: a local hospital experience
CY law / PYM Woo / KS Wong / WY Lee / WS Ho / KY Pang / CK Wong

Programme for Oral Poster Paper II

13:20 p.m. – 14:00 p.m. 22 November 2008 (Saturday)

Oral Poster Paper II

Chairpersons: Dr. XL Zhu & Dr. WM Lui

Visual field defect after anterior temporal lobectomy
HK Mak / TM Chan / XL Zhu / D Liu / WS Poon / MK Lam / H Leung / P Kwan

Prognostic factors and clinical outcome of non-traumatic cerebellar haemorrhage
Tang CW / Luk WY / Sun TFD / Poon WS

The PYNEH experience of Dissecting aneurysm of Vertebral artery
Pun CT / Vincent KY Pang / Alain KS Wong / CK Wong / KF Fung

Case report of Spontaneous intracranial hypotension
Yeung Yuk Nam / Hung Wai Man / Yuen Shing Chau / Yam Kwong Yui / Dawson Fong

Mycotic pseudoaneurysm of internal carotid artery: case report and review of the literature
LY Ho / KM Leung / KN Hung

Incidence of subjective anosmia after interhemispheric approach to anterior skull pathology
Li Lai Fung / Leung GKK

Case of spinal arteriovenous malformation with multiple arteriovenous fistulas
HP Lai / SW Liu / KT Chan / KM Cheng

Extracranial metastasis from medulloblastoma
KT Chan / Y Chan

Programme for Nursing Session



10:45 a.m. – 12:21 p.m. 22 November 2008

Nursing Session

Chairpersons: Ms Shum Chor Wai, Rita & Mr. Poon Wai Leung

Team work in awake craniotomy and brain mapping procedure
CK Ng / SC Yuen

Programming of Subthalamic nucleus (STN) Deep Brain Stimulation (DBS)
for Parkinson's disease
Edith Wong / Anne Chan / TM Chan / Xi Zhu / V Mok / J Yeung / W Poon / Sam Ng / Christine Lau / R Wong

Exploring the Education needs of Newly-diagnosed Brain Tumour Patients and Their Family Caregivers
Cheung MY Miranda / Wong WL Marian

Responses to thermal stimulation in persons with central poststroke pain:
Sensory decision theory analysis
Lo Shuk Man / Chung WY Joanne

NTWC Care Management in Department of Neurosurgery at TMH, NTWC
Chan Chi Ho / Fok Ka Man

Enhancement training program for nurses in safety of intra hospital transportation
for critical ill patients in neurosurgical department
HW Cheng

Discussion



Abstracts : Free Paper I

Title:

Challenges in the Endovascular Management of Cerebral Aneurysm Remnants after Surgical Clipping: An illustrative case

Authors and Institution :

CT Pun, PYM Woo, CY Law, KS Wong, WY Lee, WS Ho, KY Pang, CK Wong
Department of Neurosurgery, Pamela Youde Nethersole Eastern Hospital

Abstract :

The presence of residual cerebral aneurysm remnants after surgical clipping range from 4-19% on follow-up angiography and the risk of hemorrhage warrants further treatment. Repeat surgery for partially clipped aneurysms is fraught with risk and is associated with increased morbidity and mortality. Unfortunately, there is a dearth of literature studying endovascular coiling of aneurysm remnants after surgery.

A 58 year-old male was treated in our department after experiencing a sudden onset of headache. He was subsequently diagnosed to have subarachnoid hemorrhage secondary to a right middle cerebral artery aneurysm (M1 segment). Craniotomy for surgical clipping was done and he recovered satisfactorily. Two years afterwards, digital subtraction angiography revealed a recurrent fusiform aneurysm beneath the site of the clip incorporating the parent artery. Stent-assisted coil embolisation was successfully achieved with complete obliteration and no neurological complications occurred.

The management options for partially clipped residual aneurysms and the difficulties encountered during endovascular treatment will be discussed.

Title :

The making of an aneurysm model by neurosurgical trainees

Authors and Institution :

Law Hing Yuen, Leung Kar Ming, Lui Wai Man, Hung Kwan Ngai
Department of Neurosurgery, Queen Mary Hospital

Abstract :

A proposal of making aneurysm models by higher neurosurgical trainee using rats/rabbits. Aim to provide reliable and reproducible aneurysm models suitable for endovascular training and further research. The morphology and patency rate of the aneurysm models will be studied.

Background – different methods has been adopted to create aneurysm models with varying degree of success. Rabbits were commonly used in experiments for their easy access, low maintenance cost and comparable coagulation system to humans.

Method – Arteriovenous fistulae will be created between inferior vena cava and abdominal aorta of rats, while in rabbits, the internal jugular veins and the internal carotid arteries will be connected by side to side anastomosis. The draining vein will be ligated after 60 minutes to create side wall aneurysms. Aneurysms will be harvested after 2-4 weeks.

Conclusion – reliable and reproducible aneurysm models can be made by creating AVF in rats/rabbits by neurosurgical trainees. Basic microsurgical techniques can also be improved.



Title:

Measurement of the exposure of clinoidal ICA after anterior clinoidectomy and proximal and distal dural ring cut

Authors and Institution:

YH Tse; PH Wong; WM Lui
Department of Neurosurgery, Queen Mary Hospital

Abstract:

Anterior clinoidectomy has long been one of the most widely applied surgical technique in neurosurgery. It has been used for the exposure of the clinoidal segment of internal carotid artery (ICA) as well as its mobilization. Papers have been describing about the intradural approach and the extradural approach to achieve similar goals. However, the extend of how much length of ICA one can have after various approach has not been fully studied. In the current study, 2 specimen head (i.e. 4 sides) were used for dissection. We will measure the exact length of clinoidal ICA exposure after i) intradural anterior clinoidectomy, ii) extradural anterior clinoidectomy and iii) cutting of both proximal and distal ring of the ICA. Difference in the exposure and the clinical use of these approaches will be compared.



Abstracts : Free Paper I

Title :

Outcome of Epilepsy Surgery at the Tuen Mun Hospital

Authors and Institution :

B.B.T. Taw¹, D.T.S. Fong¹, K.Y. Yam¹, W.K. Chak², T.T.S. Lai³

Department of Neurosurgery¹, Department of Paediatrics and Adolescent Medicine², Tuen Mun Hospital, Child and Adolescent Psychiatry, Castle Peak Hospital³

Abstract :

For patients with intractable seizures, surgery may offer a chance of improved seizure control and consequently better quality of life.

We present a retrospective review of the experience and results of epilepsy surgery carried out at the Tuen Mun Hospital. A more in-depth psychiatric assessment was carried out in four of the child and adolescent patients by the psychiatric team.

Over a ten-year period (1998 - 2008), there were a total of 32 patients who underwent epilepsy surgery at the Tuen Mun hospital.

The patients included 25 children and 7 adults. There has been an increasing trend in the number of paediatric cases over the last 4 years. The adult program was started in 2005. Four children were screened for any mood and behavioural symptoms before and after surgery. The Engel's classification was used to measure the outcome. The etiology of these cases included: Hippocampal sclerosis (22%), benign temporal tumour (17%), multifocal epilepsy having callosotomy (26%), benign extra-temporal tumour (13%), cortical malformation (4%), post-encephalitic epilepsy (9%), and porencephalic cyst (4%). Mean follow up was 26 months (from 4 months to 10 years).

Almost half of the patients achieved Engel's class 1 outcome, with about 30% achieving Engel's class 2 or 3 outcome. About 20% scored class 4 outcomes. 78% of temporal lobe pathology achieved class 1 outcome compare with only 22% of extra-temporal lobe pathology.

In terms of psychiatric outcomes, all four patients recorded an improvement of self-esteem and quality of life. There were no significant psychiatric symptoms detected as a result of surgery.

There was 1 case of transient III palsy, no quadrantic field defect was observed, but there was one suspected limited field. There was no mortality.

In conclusion, epilepsy surgery can be carried out safely and with a favourable outcome. Early results in psychiatric assessment suggests that there is improvement in patients' self-esteem and quality of life with no added psychiatric symptoms. Larger scale studies and perhaps a better classification of outcomes including patients' social and psychological aspects should be included in the future.



Title :

Decompressive craniectomy for hemispheric infarction: value of early surgery and predictive factors for outcome

Authors and Institution :

Mak WK, Wong GK, Poon WS
Division of Neurosurgery, Department of Surgery, Prince of Wales Hospital, The Chinese University of Hong Kong

Abstract :

Background: Malignant infarction of middle cerebral artery (MCA) carries a mortality rate of up to 80% for pure medical treatment. Recent pool-analysis of data from three European randomized controlled trials (DECIMAL, DESTINY and HAMLET) showed significant improvement in terms of survival and functional outcome at 1 year. The findings are highly consistent across the three trials. Randomisation was done within 48 hours after stroke onset. The aims of this study were to determine the factors associated with survival rates and functional outcome in patients with MCA infarction especially the timing of surgery.

Methods: From 01/2003 to 06/2008, 27 patients with MCA infarction were included in the study from New Territories East Cluster Hospitals. All the patients underwent decompressive craniectomy and duroplasty. Neurological presentation was evaluated by Glasgow coma scale (GCS). Functional outcome was evaluated with the Glasgow outcome scale (GOS) during the follow-up period at 1 month, 3 month and 6 months after operation.

Results: Mean age was 54 and male to female ratio was 1:3. 5 patients (18.5%) achieved independent activity of daily living at six months after rehabilitation. There was no significant improvement in terms of outcome for those with early surgery (within 48 hours). Mean time from admission to surgery was 47 hours. Other specific factor like side of infarct was not correlated with 6-month outcome. Only admission GCS showed significant correlation.

Conclusion: Early decompression is not predictive of neurological outcome in terms of Glasgow outcome score at 6 months in our local experience. Poor GCS on admission predicted poor outcome.



Abstracts : Free Paper I

Title:

Management outcome of cerebral arteriovenous malformations: Multimodality treatment in a neurosurgical center in Hong Kong

Authors and Institution :

Ng RY¹, Wong GK¹, Kam KM², Yu SC³, Poon WS¹

Division of Neurosurgery¹, Department of Clinical Oncology², Department of Diagnostic Radiology and Organ Imaging³, Prince of Wales Hospital, The Chinese University of Hong Kong, HKSAR, China

Abstract

Objective: To analyze the management outcome of cerebral arteriovenous malformations (AVMs), with treatment selection based on eloquence in AVM location, in a regional neurosurgical center in Hong Kong.

Methods: We performed a retrospective analysis of 47 consecutive patients with cerebral arteriovenous malformations (AVMs) treated in our center between January 2002 and September 2007. The management guideline during the period was microsurgical for AVM located in non-eloquent areas and radiosurgery for AVM located in eloquent areas, in addition to patient preference. Glue embolization was performed in selected patients.

Results: Male to female ratio was 3:2. Age (mean \pm SD) was 29.6 \pm 13.2 years. Twenty-nine (61.7%) were ruptured AVM. The presenting symptoms of unruptured AVM included seizure (9, 50%), headache (6, 33%) and incidental finding (3, 17%). There were 17 (36.2%) grade I; 15 (31.9%) grade II; 14 (29.8%) grade III and 1 (2.1%) grade IV AVMs. Complete excisions were confirmed angiographically in 23(88.4%) patients. Two (7.7%) patients underwent RS for the residual nidus. Twenty-one patients underwent radiosurgery. Out of the 15 patients with angiographic follow-up, angiographic cure was confirmed in 10 (67%) patients. Two (9.5%) patients bled after radiosurgery. Overall, forty-three (91.5%) patients attained favorable neurological outcome on last follow up. In the 14 patients with grade 3 AVM, thirteen (91.5%) patients attained favorable neurological outcome on last follow up.

Conclusion: Management strategy of cerebral arteriovenous malformation based on eloquence in location was feasible and effective.



Title :

Management of atypical meningioma – The experiences from Princess Margaret Hospital

Authors and Institution :

CP Tsang, TH Aung
Department of Neurosurgery, Princess Margaret Hospital

Abstract :

Background

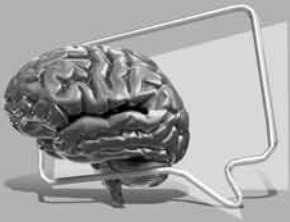Atypical meningioma is an uncommon subtype of intracranial tumours. World Health Organization (WHO) revised the grading of meningioma subtype in 2000. The prognosis of this subtype was poor.

Objective

The recurrence rate of atypical meningioma and WHO grade II meningioma were studied.

Materials and Method

All the patients with atypical meningioma and WHO grade II meningioma managed in Princess Margaret Hospital (PMH) were included. The medical records from the Clinical Management System (CMS) were reviewed retrospectively. The demographic data, tumour characteristic, management plan and recurrence rate were studied.



Abstracts : Free Paper II

Title :

The effect of concomitant and adjuvant chemotherapy on the survival of Chinese patients with primary Glioblastoma Multiforme (GBM)

Authors and Institution :

Danny TM Chan, Benedict Ng, Stephanie Ng, Brigette Ma*, KM Kam*, XL Zhu, Wai S Poon
Prince of Wales Hospital

Abstract :

Objective

Concomitant and Adjuvant chemotherapy has become the standard of care in treatment of glioblastoma since early 2005. We have tried to comply with this standard with a major financial obstacle in many of the patients. The generality of this regime might or might not cover Asians of Chinese descent. Hence we carried out a retrospective study to determine if there is any survival difference between radiotherapy alone and radiotherapy with concomitant chemotherapy.

Method & Patients

Histologically proven glioblastoma patients who received radiotherapy in Prince of Wales hospital in the period from March 2005 to December 2007 were recruited. Prognostic factors, including age, performance score, degree of surgical resection and use of chemotherapy, were recorded. Their progression-free survival (PFS) and overall survival (OS) were analysed by Kaplan Meier's Survival Test.

Results

During the study period, there were 35 newly diagnosed histologically proved glioblastoma. There were 27 male and 8 female. Their mean age was 50.4(+/-17.1) years old. They had a median Progression-free survival (PFS) of 11.8 (6.7-17.0) months and a median Overall Survival (OS) of 29.3 (16.8-41.9) months.

Seventeen patients received concomitant radiotherapy and chemotherapy. Their PFS was 15.3(5.1-25.4) months and OS was 33.4(21.4-45.5) months. 18 patients received radiotherapy alone and their median PFS was 10.6(7.9-13.3) months and median OS was 14.7(4.6-24.7) months. There was a trend of difference in overall survival between concomitant chemoradiation followed by adjuvant chemotherapy and radiotherapy alone ($p=0.066$).

Conclusion

Our single-centre results indicated Chinese glioblastoma might have a better survival (Progress-free and Overall survival). Those received concomitant radiotherapy and chemotherapy showed a trend of longer overall survival when compared with those received radiotherapy alone.



Title :

Diffusion Tensor Tractography of the Facial Nerve in Cerebellopontine Angle Tumors

Authors and Institution :

PHD Wong¹, R Lee², WM Lui¹

¹ Division of Neurosurgery, Department of Surgery, LKS Faculty of Medicine, The University of Hong Kong

² Department of Radiology, Queen Mary Hospital

Abstract :

Background:

Damage to facial nerve is a known risk for excision of cerebellopontine angle tumors. Advance in imaging technologies allow better illustration of the anatomy. Yet the facial nerve is still difficult to be visualized in ordinary magnetic resonance imaging. In this study, diffusion tensor tractography is employed to locate the facial nerve in patients diagnosed to be suffering from cerebellopontine angle tumors. The information is compared with intra-operative findings to determine whether such an imaging technique can be adopted to provide more information in the planning of the operation.

Method:

Three patients diagnosed to be suffering from cerebellopontine angle tumors undergoing surgical excision were included. Magnetic resonance imaging for diffusion tensor tractography were performed within two weeks before the operation. Location of the facial nerve in relation to the tumor found intra-operatively was compared with the tractography images, and the reliability of the tractography was evaluated.

Results:

Diffusion tensor tractography is successfully performed in two of the patients. Among them the location of the facial nerve shown on the images matched that observed during surgery. One of the patient underwent the magnetic resonance imaging, but failed to reconstruct the facial nerve tract. During the operation, facial nerve could not be identified.

Conclusion:

Diffusion tensor tractography is an imaging technique that can be employed to provide preoperative evaluation of the facial nerve position in patients undergoing surgical excision of cerebellopontine angle tumors. Further study is needed to evaluate the accuracy of this imaging technique.



Abstracts : Free Paper II

Title :

Can Magnetic resonance arteriography replace digital subtraction angiography in patients having intracranial aneurysm treated with endovascular coiling?

Authors and Institution :

Yu Chi Hung, Cheng Kin Ming, Cheung Yuk Ling, Tang Kwok Wing, Chan Chi Ming, Siu Chi Wai, Jimmy Queen Elizabeth Hospital

Abstract :

Patients having intracranial aneurysm treated with endovascular coiling are usually followed up regularly by digital subtraction angiography. However, digital subtraction angiography carries significant risks. It has complications of allergic reactions to contrast, groin haematoma, strokes or even sepsis. It causes significant morbidity and even mortality to patients once complications occur.

Magnetic resonance arteriography is another way to assess intracranial vessels. We currently have 3 Tesla magnetic resonance machine and it is sensitive enough to detect very small lesion. It is a non- invasive investigation and the contrast allergic rate is much lower.

However, it is a static investigation compared with digital subtraction angiography, which is a dynamic investigation.

We want to investigate whether new generation of 3 Tesla magnetic resonance arteriography is sensitive and specific enough to replace conventional digital subtraction angiography.

We perform both digital subtraction angiography and magnetic resonance arteriography on the patient had intracranial aneurysm treated with endovascular coiling. The films are reviewed by two separate radiologists. Then we stratify the patient into three groups (complete occlusion, residual neck, regrowth of aneurysm) and compare the report of digital subtraction angiography and magnetic resonance arteriography.

We hope to gather enough evidence that magnetic resonance arteriography can replace digital subtraction angiogram as follow up investigation for patients having intracranial aneurysm treated with endovascular coiling.



A large white rectangular area containing 20 horizontal dotted lines for writing notes.



Abstracts : Free Paper III

Title :

Extended-Subtemporal Transcavernous Transpetrosal Transtentorial Approach for petroclival tumours – Review of surgical results

Authors and Institution :

WM Lui, Department of Neurosurgery, Queen Mary Hospital

Abstract :

A new approach, Extended-Subtemporal Transcavernous Transpetrosal Transtentorial (ESTTT) Approach, was being adopted in Queen Mary Hospital for treating petroclival tumours. This is a modification of Kawase Approach with Dolenic approach to the petroclival and neighbouring regions. Additional transtentorial dissection was carried out to enhance the posterior exposure. It involves extensive subtemporal dissection, from the anterior clinoid process to the transverse sinus tentorial attachment. Tentorium was splitted till the free tentorial edge. This permits a wider exposure of petroclival region, with early devascularization of tumour blood supplies from internal carotid artery. Fourteen patients, 12 meningiomas, 1 chordoma and 1 haemangioma, ranging from 3-8cm in diameter, were operated by this approach. Mean age was 51-year, ranges from 36-74. All presented with signs of cranial nerve palsy and/or brainstem compression. Nine patients achieved Simpson 2 and five patients had Simpson 3 removal. There was no mortality. The reasons for incomplete removal were tumour invasion to brainstem or cavernous ICA. Residues were left deliberately. There was three CSF leak and two required surgical repair. Three patients suffered from additional CN deficit after the surgery. Concerning the long-term outcome, all except four patients still under rehabilitation care had GOS 5. Seven patients had K-score 100/100 and three patients had 90/100. In summary, the ESTTT Approach is an effective and safe approach to excise petroclival tumour. The main reason for in-complete removal is due to tumour invasion of the vital neurovascular structures.



Title :

Accuracy of Percutaneous Placed Lumbar Pedicle Screws in Hong Kong Chinese patients

Authors and Institution :

SUN TF David, NG Wing Kit, POON WS
Division of Neurosurgery, Department of Surgery, Prince of Wales Hospital, The Chinese University of Hong Kong

Abstract :

AIM

This study is designed to evaluate the safety of percutaneous pedicle screw placement following minimally invasive Transforaminal Lumbar Interbody Fusion (TLIF) in Hong Kong Chinese population.

METHODS

Positions of pedicle screws placement following minimally invasive TLIF were assessed using post-operative computerized tomography examination. Sizes of pedicles and angle of insertion were measured. Factors affecting the accuracy and clinical outcome were evaluated.

RESULTS

25 patients with 104 pedicle screws were examined. The mean diameters of the pedicles of L4, L5 and S1 are 8.6, 11.2 and 15.8 mm respectively. Five screws (5/104; 4.8%) in three patients were found to have breached the cortex of the pedicles, 4 breached medially and 1 laterally. Three (3/27; 11%) were at S1 and two (2/46; 4.3%) were at L5. All the medially breached screws were at the side of where the facetomy were performed. It is thought to be due to the more medial angle of insertion compared with the contralateral side (29.3o vs 23.2o). One patient developed radicular pain after the surgery and required repositioning of the screw, which was also done percutaneously. The other two patients had good response to surgery and remained well in subsequent follow-ups.

CONCLUSION

The placement of percutaneous placed pedicle screws in Hong Kong Chinese patients is safe and the accuracy of our technique is comparable with literature.



Abstracts : Free Paper III

Title :

**Temporal lobe radionecrosis in patients with nasopharyngeal carcinoma:
Should early surgery be advocated?**

Authors and Institution :

ST Wong, KY Yam, D Fong, Department of Neurosurgery, Tuen Mun Hospital

Abstract :

Temporal lobe radionecrosis occurs in 0-18.6% of patients with nasopharyngeal carcinoma within 10 years after irradiation. Cognitive dysfunction is common in patients with temporal lobe radionecrosis. The treatment options include observation, pulse steroid therapy and surgical excision. However, surgical excision is presently offered only to those with severe mass occupying effect such as large cyst and acute hemorrhage, or when associated abscess formation occurs. We carried out a study to evaluate the role of early surgery in temporal lobe radionecrosis.

We retrospectively analyzed patients with temporal lobe radionecrosis treated at Tuen Mun Hospital from January 1998 to July 2008. All patients with documented temporal lobe radionecrosis were included for analysis. 23 patients received operations.

We analyzed their radiological findings and also the histological features of the resection specimens. Radiologically, the progression of radionecrosis and the post-operative resolution of edema, re-accumulation of cyst and appearance of new lesions were studied. Re-operation rate and indications were discussed. The pathogenesis of radionecrotic lesions and the role of surgery to alter the course of the formation of these lesions were discussed.



Title :

Endoscopic third ventriculostomy (EVT) and biopsy for pineal region tumour: single or two burr holes?

Authors and Institution :

Gao R*, Zhu XL, Wong HT, Wong KC, Ng YT, Wong Rosanna**, Poon WS
Department of Neurosurgery, the 1st People's Hospital, Zhang Jia Gang, Jiang Su Province, China*; Division of Neurosurgery, Department of Surgery; Department of Occupational Therapy**, Prince of Wales Hospital, Chinese University of Hong Kong, HKSR, China

Abstract :

Introduction: For pineal region tumours presented with obstructive hydrocephalus, endoscopic 3rd ventriculostomy (ETV) and tumour biopsy in one operation provide a definitive treatment of hydrocephalus and histological diagnosis for further treatment. However, there is a concern of injuring important adjacent structures during the endoscopic maneuver (Bonanni 2004). A two-burr-hole method has been proposed to minimize the displacement of the foramen of Monro (FERENCE 1997). There is no systemic study on the endoscope trajectories through single burr hole for EVT and tumour biopsy. We analysed the trajectory angle and displacement of the foramen of Monro with outcome correlation in a case series undergone single burr hole for ETV and pineal region tumour biopsy. The objective is to see if a single-burr-hole method is adequate and safe.

Patient and methods: This is a retrospective study. All cases in both institutes of the authors from 2001 to 2008 received endoscopic ETV and tumour biopsy in the pineal region were included. Clinical data were reviewed. Images were analysed in neuronavigation computer (BrainLab). Location of the burr hole, angle of the EVT and biopsy trajectories and theoretical displacement of the foramen of Monro were measured. Cognitive and memory function were assessed.

Results: There were ten cases (8 male, 2 female, age 11-74), including 5 germcell tumour, 2 pilocytic astrocytoma, 1 atypical teratoid / rhabdoid tumour and 1 pineocytoma. In one case the biopsy result is fibrous tissue only. She was followed up for 7 years without significant change of the tumour. All had hydrocephalus. No CSF shunting required for all the cases after ETV. After the biopsy, four cases received craniotomy for tumour excision, seven cases receive chemotherapy and / or radiotherapy. One case died one year after due to haemorrhagic stroke. There was no peri-operative amnesia complication. Nine patients received instrumental cognitive assessment post-operatively (Minimetal Status Examination, Neurobehavioral Cognitive Status Examination & Rivermead Behavioural Memory Test). 2 had overall cognitive impairment not specific to memory (one was an 81 year old patient with dementia; the other had global cognitive impairment after tumour excision and radiotherapy). The remaining 7 patients were normal. One case had intraventricular haemorrhage on post-op day 2. In this case, the massa intermedia was injured during the biopsy procedure. The mean distance for burr hole-coronal suture was 16mm (SD* 8, range 5-29); burr hole-midline was 30mm (SD 7, range 18-37) The mean angle between ETV trajectory and orbitomeatal (OM) line was 57 degree (SD 5, range 50-63), between biopsy trajectory and OM line was 46 degree (SD 4, range 39-53). The mean displacement of foramen of Monro was 1.6mm (SD2, range 0-4.8) for ETV, 2.8mm (SD2.2, range 0-5.5) for biopsy.

Discussion: The fornix is most vulnerable to the anterior movement of the endoscope during EVT. Our result showed that the displacement is minimal during EVT. No peri-operative amnesic complication occurred in our series. No memory specific impairment in post-operative assessment. During biopsy, there is posterior movement and the range of displacement is larger than that of EVT. It may cause injury to the massa intermedia as in one of our case. Although no neurological deficit, it may relate to the postoperative intra-ventricular haemorrhage. Shortages of the study are retrospective study, small number of cases and no pre- and post-op memory assessment comparison.

Conclusion: The concern of forniceal damage to justify the two-burr-hole strategy is exaggerated. For the majority, single burr hole approach is safe in achieving the purposes of both ETV and pineal region tumour biopsy. Pre-operative trajectory planning is useful in optimize the burr hole location.



Abstracts : Free Paper IV

Title:

Management outcome of NPC-related and non-NPC-related brain abscess in Hong Kong

Authors and Institution :

Tam MH¹, Wong GK¹, Zhu XL¹, Ip M², Poon WS¹
Division of Neurosurgery¹, Department of Microbiology², Prince of Wales Hospital, The Chinese University of Hong Kong, HKSAR, China

Abstract

Objectives: (1) To review the management outcome of brain abscess in a regional neurosurgical center in Hong Kong; (2) To identify if patients with NPC-related brain abscess had worse outcome with brain abscess than non-NPC patients.

Method: Retrospective review of consecutive patients diagnosed (radiologically and/or microbiologically) with brain abscess in Prince of Wales Hospital between 1/1999 and 3/2008.

Results: A total of 54 patients were recruited into this study. There were 37 male and 17 female patients. 18 (33%) patients had previous radiotherapy for nasopharyngeal carcinoma. Only 31 (57%) patients had fever on presentation. Other common clinical presentations included decreased general condition (31, 57%), focal neurological deficits (22, 41%), headache (21, 39%). White cell count and/or C-reactive protein, was raised in 41 (76%) patients on admission. Abscess was located in the frontal lobe in 33%, in the temporal lobe in 30%, and in the parietal lobe in 20%. Operation was performed on 49 (91%) patients, either aspiration through a craniotomy or excision of the abscess. Recurrence of abscess after aspiration was observed in 11 (20%), all of which required further surgical treatment. Culture was positive in 45 (83%) patients. Common organisms isolated included *Streptococcus* species (33%) and *Peptostreptococcus* species (17%). The mean follow-up time was 18 months. At the 6 month interval, 24 (44%) patients had good recovery. Favorable outcome was achieved in 30 (55%). In-patient mortality was 6 (11%). Patients with NPC-related brain abscess was associated with unfavorable six month neurological outcome (33%, $p=0.020$). There was a trend towards higher in-patient mortality in patients with NPC-related brain abscess (22%, $p=0.066$).

Conclusion: Brain abscess carried a substantial morbidity and mortality despite aggressive surgical and medical treatment. Patients with NPC-related brain abscess had a higher in-patient mortality and unfavorable six month neurological outcome.

Title :

A CLUSTER OF CNS INFECTIONS

Authors and Institution :

CHENG KF¹, LEE WY¹, LEE RA², YIP Ida³, WONG CK¹
Pamela Youde Nethersole Eastern Hospital
¹ Department of Neurosurgery
² Microbiologist
³ Infection Control SNO

Abstract :

From September to November 2007, we detected four cases of symptomatic central nervous system infection. In all cases, there was multiple isolates of bacillus growth in the cerebrospinal fluid during postoperative period. A thorough investigation was carried out to pinpoint the source of the outbreak. Control measures were implemented and our infection rate had returned to near zero as usual. We would like to share our experience at the anniversary of the outbreak.

Title :

A regional hospital experience in Onyx the liquid embolic agent

Authors and Institution :

Dr Calvin HK Mak, Dr JCK Kwok, Dr KY Chan, Dr KH Pang
Department of Neurosurgery, Kwong Wah Hospital

Abstract :

Objectives:

The aim of this case series was to report the initial experience of utilizing a novel liquid embolic agent Onyx in various aspects in endovascular treatment in a regional neurosurgical centre.

Background:

Onyx is a liquid embolic agent mainly used in treating arteriovenous malformations (AVMs). It can also achieve penetration of feeding vessels in tumours and thus create tumour necrosis and shrinkage. This case series gives the initial experience in Onyx and assesses its safety and efficacy in various neurosurgical disease entities.

Methods and Patients:

Between May 2008 and September 2008, 6 embolization procedures using Onyx in 6 patients were performed. 5 patients with cerebral AVMs were embolized with Onyx, in which 4 patients were nidus types and 1 patient with dural arteriovenous fistula previously partially embolized with glue. 1 patient with a large hypervascular meningioma was treated by preoperative embolization with Onyx using superselective catheterization of the feeding arteries. They were 4 (66.6%) men and 2 (33.3%) women with a mean age of 42 years.

Results:

Onyx was the sole embolic agent used in all 6 embolization procedures. The mean estimated size of the 4 nidus AVMs was 3.9 cm (range 3 – 5cm). Average estimated size reduction was 88% (range 40% - 80%). In the patient with dural arteriovenous fistula, it was completely obliterated with Onyx. There were no symptoms of postembolization tumour swelling or hemorrhage in the patient with meningioma before complete resection 5 days later. Penetration of Onyx into the tumour arteries was observed in specimens for histopathology. Technical difficulties including difficulties in catheter retrieval were experienced in some cases. Procedure-related permanent morbidities and mortalities in all 6 patients were not detected.

Conclusions:

Our initial experience shows that Onyx is useful and safe in treating AVMs and arteriovenous fistulas. It is also promising in preoperative devascularization of meningiomas.

References:

- [1] Katsaridis V, Papagiannaki C, Aimar E. **Curative embolization of cerebral arteriovenous malformations (AVMs) with Onyx in 101 patients.** *Neuroradiology.* 2008 Jul;50(7):589-97. Epub 2008 Apr 12.
- [2] Weber W, Kis B, Siekmann R, Jans P, Laumer R, Kühne D. **Preoperative embolization of intracranial arteriovenous malformations with Onyx.** *Neurosurgery.* 2007 Aug;61(2):244-52; discussion 252-4.
- [3] Shi ZS, Feng L, Jiang XB, Huang Q, Yang Z, Huang ZS. **Therapeutic embolization of meningiomas with Onyx for delayed surgical resection.** *Surg Neurol.* 2008 Feb 8.
- [4] Weber W, Kis B, Siekmann R, Kuehne D. **Endovascular treatment of intracranial arteriovenous malformations with onyx: technical aspects.** *AJNR Am J Neuroradiol.* 2007 Feb;28(2):371-7.
- [5] Carlson AP, Taylor CL, Yonas H. **Treatment of dural arteriovenous fistula using ethylene vinyl alcohol (Onyx) arterial embolization as the primary modality: short-term results.** *J Neurosurg.* 2007 Dec;107(6):1120-5.
- [6] van Rooij WJ, Sluzewski M, Beute GN. **Brain AVM Embolization with Onyx.** *AJNR Am J Neuroradiol.* 2007 Jan;28(1):172-7
- [7] Mounayer C, Hammami N, Piotin M, Spelle L, Benndorf G, Kessler I, Moret J. **Nidal Embolization of Brain Arteriovenous Malformations Using Onyx in 94 Patients.** *AJNR Am J Neuroradiol.* 2007 Mar;28(3):518-23.



Abstracts : Free Paper V

Title :

A review of treatment outcome in adult cerebral AVM in terms of AVM control, obliteration rate and clinical outcome

Authors and Institution :

Dr M.Y. Chan, Dr S.T. Wong, Dr K.Y. Yam, Dr D. Fong, Department of Neurosurgery, Tuen Mun Hospital

Abstract :

Background : This is a retrospective study. We reviewed cases with cerebral AVM treated in our unit between January 1998 and December 2007. Paediatric cases, cases with dural AVM or AVF, and cases treated in other unit or before the study period were excluded. Treatment modalities include microsurgery, embolization as well as radiosurgery. In general, AVM with lower Spetzler Martin grade was treated with microsurgery while higher grade AVM was treated with a combination of different treatment modalities. We look at the obliteration rate, rebleeding rate, treatment related mortality, Glasgow Coma Scale and modified Rakin Scale at different time from treatment. Results were compared among different treatment groups and with results from other studies.

Results : A total of 98 cases were identified. 47 (48.0%) were treated with surgical excision, 5 (5.1%) with embolization, 23 (23.5%) with radiosurgery and 23 (23.5%) with a combination of above. 47 cases (48.0%) received microsurgery, the mean outcome GCS and MRS was 15 and 1.08 respectively. Treatment related mortality was 4.26%. AVM control was good and there was no rebleeding. 5 patient (5.1%) had AVM embolisation as the sole treatment. Though there was no documented rebleeding and treatment related mortality, 33.3% of the patient showed residual lesion and the mean GCS and MRS was not as good. Among the 23 cases (23.5%) receiving only radiosurgery, 63.6% achieved AVM obliteration and there was no documented rebleed or treatment related mortality. Mean GCS and MRS was 15.0 and 0.62 respectively. In the group of 23 patients (23.5%) receiving a combination of treatment modalities, rebleeding was documented in 9.1% although 82.8% was proven to have complete AVM excision / obliteration. There was no treatment related mortality and mean GCS and MRS of the group was 15.0 and 0.90 respectively.

The above difference can be explained by the choice of treatment at presentation. As embolization was usually done in patient with poorer grade AVM, a lower outcome GCS, outcome MRS and obliteration rate was expected. This can also explained the higher rebleeding rate in the combination group.



Title:

Onyx embolization of cerebral arteriovenous malformation in Hong Kong: a single institute experience over 14 months

Authors and Institution :

Wong GK¹, Yu SC², Poon WS¹

Division of Neurosurgery¹, Department of Diagnostic Radiology and Organ Imaging Department², Prince of Wales Hospital, The Chinese University of Hong Kong, HKSAR, China

Abstract

Background: Onyx appeared in recently years as a new embolic agent for endovascular neuro-intervention. Its non-adherent nature allowed more prolonged and controlled injection, a perceived advantage for cerebral arteriovenous malformation embolization.

Objective: To review the experience in Onyx embolization of cerebral arteriovenous malformation in a regional neurosurgical center in Hong Kong.

Study design: Data of patients with cerebral arteriovenous malformation underwent Onyx embolization in Prince of Wales Hospital, The Chinese University of Hong Kong, over a 14 month period, were prospectively collected.

Results: Eleven sessions of Onyx embolization were done in 9 patients with cerebral arteriovenous malformation. Seven were ruptured cerebral arteriovenous malformation. Overall, total occlusion was achieved in 3(33%) patients. In 4 patients with cerebral arteriovenous malformation larger than 3.5cm in diameter, near-total occlusion (over 90% occlusion) was achieved in 3(75%) patients. Two patients developed new neurological deficits, which recovered on follow-up assessments at one month.

Conclusion: Onyx embolization of cerebral arteriovenous malformation is feasible in Hong Kong. Careful patient and target selections are important.



Abstracts : Free Paper V

Title :

APOE Influences Vasospasm and Outcome of patients with aneurysmal subarachnoid hemorrhage in Chinese Population

Authors and Institution :

Tai WH, Poon WS*
Department of Neurosurgery, St Januario Central Hospital, Macau
Division of Neurosurgery, Prince of Wales Hospital*

Abstract :

Objective

To determine the influence of the APOE genotype on outcome and on the incidence of clinical vasospasm in patients with aneurysmal subarachnoid hemorrhage (aSAH) in Chinese population.

Method & Patients

A prospective clinical study was performed on 204 patients admitted to the Prince of Wales Hospital, Hong Kong (from July 1998 to June 2004) and the 1st affiliated hospital of Sun Yat-sen University, Guangzhou (from January 2003 to December 2004), and St Januario Central Hospital, Macau (from January 2003 to December 2004). The patients' characteristics, World Federation of Neurological Surgeons (WFNS) clinical grading score, and Fisher's grading score (quantifying the severity of SAH on CT) were recorded. Blood samples for apolipoprotein E genotyping were obtained via venipuncture for other routine blood tests. All patients were managed under a standard protocol. The diagnosis of symptomatic cerebral vasospasm was confirmed by in-charged neurosurgeon. Outcome assessment was based on the Glasgow Outcome Scale (GOS). A follow-up interview was arranged for 6 months after the patients were discharged to determine the clinical outcome according to the GOS. After determining of apolipoprotein E genotype, Chi square, T test and univariate analysis were performed to determine the effect of age, sex, Fisher's grade, WFNS grade, and APOE4 on the outcome at 6 months (defined by GOS score). Logistic regression analysis was used to analyzed the relationship among APOE genotype, vasospasm and outcome.

Results

Results from the Chi square and T test suggested that older patients, poor WFNS grade, poor Fisher's grade, and $\epsilon 4$ carriers were more likely to attain an unfavorable outcome ($P < 0.05$), $\epsilon 3$ carriers is not related to unfavorable outcome, $\epsilon 2$ carrier is related to favorable outcome ($P = 0.048$). Added the clinical outcome predictors (age, WFNS grade, Fisher's grade) into $\epsilon 4$ model, the difference is more significant ($OR = 3.68$, $P < 0.01$). Results from the Chi square and Logistic regression analysis suggested $\epsilon 4$ carriers were more likely to have vasospasm ($P < 0.05$), $\epsilon 2$ carriers is not related to vasospasm, and $\epsilon 3$ carriers were NOT likely to have vasospasm ($P < 0.05$).

Conclusion

In Chinese population, APOE4 is a risk factor for outcome of aneurysmal subarachnoid hemorrhage and related to unfavorable outcome; APOE2 is a protective factor for outcome of aneurysmal subarachnoid hemorrhage and related to favorable outcome. APOE4 is also a risk factor for cerebral vasospasm after aneurysmal subarachnoid hemorrhage, and $\epsilon 4$ carriers is more likely to have vasospasm.

Notes



A large white rectangular area containing 20 horizontal dotted lines for writing notes.



Abstracts : Oral Poster I

Title :

Ventriculoperitoneal Shunt Failure and Infection: a retrospective review at Queen Mary Hospital

Authors and Institution :

PHD Wong, G Leung

Division of Neurosurgery, Department of Surgery, LKS Faculty of Medicine, The University of Hong Kong

Abstract:

Background:

Ventriculoperitoneal shunting is a commonly performed procedure for diversion of cerebrospinal fluid. However shunt failure and infection results in significant morbidity and repeated operations. In this retrospective review study, ventriculoperitoneal shunting procedures performed at Queen Mary Hospital from January 2006 to December 2007 were reviewed.

Method:

All ventriculoperitoneal shunts performed within the period of January 2006 and December 2007 were included. Demographic data was obtained from medical record and department database. Shunt infection was defined as positive bacterial culture from cerebrospinal fluid.

Results:

Totally 122 ventriculoperitoneal shunts were performed among 92 patients. Blockage was noted in 12 shunts. Shunt infection was documented in 12 cases, yielding an infection rate of 9.8%. No causal relationship was identified between shunt infection and systemic infection. Seven shunts were ligated or revised due to over-shunting.

Conclusion:

Many factors were postulated to be related to ventriculoperitoneal shunt infection or failure. However it is likely to be multifactorial. Upon performing a ventriculoperitoneal shunt, caution should be taken to prevent infection. Valve pressure should be carefully selected to prevent need of further revision due to over-shunting.



Title :

RADIATION-INDUCED MENINGIOMA AND CAVERNOUS HEMANGIOMA IN A PATIENT WITH GORLIN SYNDROME – A CASE REPORT

Authors and Institution :

CO, MICHAEL (QUEEN MARY HOSPITAL)
CHENG, KIN MING (QUEEN ELIZABETH HOSPITAL)
CHIU, HOK MING (QUEEN ELIZABETH HOSPITAL)

Abstract :

Radiation therapy is the mainstay of treatment of cancers in modern medicine. On the contrary, radiation-induced complication is also recognized as an important burden to our health care system. Radiation causes a wide variety of intracranial pathologies including both benign and malignant neoplasms. Here we describe a case of right frontal meningioma and cavernous hemangioma formation 14 years after cranial irradiation for cerebellar medulloblastoma in a child with Gorlin syndrome.

Title :

Dissecting extracranial vertebral artery

Authors and Institution :

Dr Kenneth Law
Department of Neurosurgery, Kwong Wah Hospital

Abstract :

A 34-year-old lady enjoying good past health presented to casualty for sudden onset of loss of consciousness and generalized tonic clonic seizure. A day before admission, she was seen by general practitioner and was noted to have right homonymous hemianopia. CT brain showed massive left temporal, occipital and cerebellar infarct. Urgent DSA reviewed dissecting left extracranial vertebral artery at C1 level with complete occlusion of basilar artery. Mechanical embolectomy was performed over basilar artery and restoration of blood flow was demonstrated afterwards. MRI brain showed persistent left massive temporal, occipital and cerebellar infarct. Her conscious level regained full afterwards but was left with persistent left hemiparesis and right homonymous hemianopia.



Abstracts : Oral Poster I

Title :

Review of ruptured cerebral aneurysm management in Tuen Mun Hospital

Authors and Institution:

Samuel SK Lam, W M Hung, K Y Yam, Dawson Fong
Department of Neurosurgery, Tuen Mun Hospital

Abstract:

Objectives

To review the outcomes of surgical clipping and endovascular treatment in aneurysmal subarachnoid hemorrhage (SAH).

Method

All patients presented with SAH with "clipping" or endovascular coiling done within 2003 to 2007 were recruited using the CDARS in the EPR. AED records, OT records, angiogram report, discharge summary, and latest follow up record were retrieved and analyzed. Clinical outcomes (GOS) were assessed at 6 months after the procedure.

Results and Discussion

There were 100 and 28 patients with clipping and endovascular coiling done respectively from 1st Jan 2003 to 31st Dec 2007.

For those who underwent clipping, there were 33 males and 67 females. Age was ranged from 27 to 82. The median age was 52. The WFNS grading was used. Mortality in grade I/II patients was 6.7 % (4/59); whereas in grade IV/V was 20.5 % (7/34). Overall mortality in the same admission was 11%. Significant morbidity leading to dependency (GOS 2-3) was 18%. Major complication, namely vasospasm, hydrocephalus and rebleeding was encountered in 42 patients. The median length of stay was 28 days.

For those who underwent coiling, there were 14 males and 14 females. Age was ranged from 20 to 79. Mortality in grade I/II patients was 6.3% (1/15); whereas in grade IV/V was 10% (1/10). Significant morbidity leading to dependency (GOS 2-3) was 11% (3/28). Several additional complications such as residual neck, coil compaction were also encountered. The median length of stay was 16 days.

Clinical outcomes seem comparable in both arms in terms of mortality and dependency. Surgical clipping is a well established therapeutic option in our department; there was a raising trend of endovascular treatment performed in recent years; results and clinical outcomes are comparable to international standard.

Title :

Thyroid-stimulating hormone secreting pituitary adenoma - Case report

Authors and Institution :

Samuel Lam, K Y Yam, Dawson Fong
Department of Neurosurgery, Tuen Mun Hospital

Abstract :

Thyroid-stimulating hormone pituitary adenomas are rare tumors (0.5% of all pituitary tumors) classically causing secondary hyperthyroidism. Up to a third of cases reported in the literature have undergone prior ablative thyroid procedures before the pituitary is thoroughly investigated. We report a 51-year-old lady with secondary hyperthyroidism, presented to general practitioner for goiter. Magnetic resonance imaging revealed a pituitary macroadenoma with mild extension into left cavernous sinus. Transphenoidal excision of pituitary adenoma was performed. Immunostains for pituitary hormones confirmed TSH and prolactin reactivity. Normalization of thyroid function achieved and pituitary function maintained.

Title:

Computer-assisted Spinal Navigation for Multi-level Thoraco-lumbar Transpedicular screw insertion: An illustrative case

Authors and Institution :

CY Law, PYM Woo, KS Wong, WY Lee, WS Ho, KY Pang, CK Wong
Department of Neurosurgery, Pamela Youde Nethersole Eastern Hospital

Abstract :

Conventional intraoperative spinal navigation using plain radiographs or C-arm fluoroscopy has significant limitations. Various clinical and laboratory studies have shown that thoraco-lumbar pedicle screw insertion using standard techniques may lead to misplacement in 20-30% of cases. In contrast, misplacement rates using computer-assisted image guidance range from 0-4%.

In January 2008 a 15 year-old female was treated in our department after jumping from a height of 10 feet. She landed on her buttock resulting in paraparesis. Computed tomography and magnetic resonance imaging revealed a burst fracture of the L1 vertebral body with retropulsion causing spinal cord compression. Computer-assisted spinal navigation for open reduction and internal fixation by transpedicular screw insertion was done. Post-operatively the patient regained full power of her lower limbs and had no other neurological complications. Computed tomography scans showed satisfactorily reduced fracture fragments and screw placement.

Details on planning, operative technique and clinical-radiological outcomes will be discussed.



Abstracts : Oral Poster I

Title:

Lumbar Spine Intradural Epidermoid Cyst: Case Report and Review of the Literature

Authors and Institution :

CT Pun, PYM Woo, KS Wong, WY Lee, WS Ho, KY Pang, CK Wong
Department of Neurosurgery, Pamela Youde Nethersole Eastern Hospital

Abstract :

Intradural extramedullary spinal epidermoid cysts are exceedingly rare and account for less than 1% of all intraspinal tumors. Most arise in the lumbosacral region. They are thought to be congenital and thus often present in adolescents.

In April 2008 a 43 year-old male was treated in our department after experiencing a four-month history of progressive back pain associated with bilateral lower limb weakness, numbness and retention of urine. He was diagnosed to have cauda equina syndrome and magnetic resonance imaging revealed a L4 to L5 level intradural extramedullary lesion with contrast enhancement. Corresponding level laminectomies for tumor excision was done and the final histopathology confirmed it to be an epidermoid cyst.

The peculiar intra-operative findings, as well as the patient's clinical- radiological outcomes will be discussed.

Title:

Role of Computed Tomography Angiography in the Diagnosis of Arteriovenous Malformations in an Emergency setting: a local hospital experience

Authors and Institution :

CY Law, PYM Woo, KS Wong, WY Lee, WS Ho, KY Pang, CK Wong
Department of Neurosurgery, Pamela Youde Nethersole Eastern Hospital

Abstract :

Almost half of cerebral arteriovenous malformations (AVM) presents as intracerebral hemorrhage with associated significant morbidity and mortality. Digital subtraction angiography (DSA) still remains as the gold standard investigation. However, in the emergency situation, when a deteriorating patient presents with intracerebral hemorrhage, there is a need for a faster and less invasive investigative technique. Few studies examined the use of 3-dimensional computed tomography angiography (CTA) as a diagnostic tool for AVMs.

During the period from September 2003 to September 2008, a total of seventeen patients aged younger than 65-years-old presented with intracerebral hemorrhage secondary to arteriovenous malformation. Twelve patients underwent urgent CTA of which ten patients were found to have AVM. The remaining five patients had no CTA performed and were diagnosed either by DSA, contrast CT brain or intraoperatively.

This case series illustrates the feasibility of urgent CTA as a quick, reliable and relatively simple screening investigation in an emergency setting. Larger trials are required to establish the detection rate of AVM by pre-operative CTA and its effect on patient's outcome.

Title :

Visual field defect after anterior temporal lobectomy

Authors and Institution :

Dr HK Mak, Dr TM Chan, Dr XL Zhu, Dr D Liu*, Prof WS Poon, Dr MK Lam, Dr H Leung, Dr P Kwan
Department of Neurosurgery, Department of Surgery, Prince of Wales Hospital
*Department of Ophthalmology & Visual Sciences, Prince of Wales Hospital

Abstract :

Objectives:

To assess the visual field defect postoperatively after anterior temporal lobectomy for epilepsy surgery in Prince of Wales Hospital

Background:

Anterior temporal lobectomy is one of the most frequently used surgical methods in treating refractory epilepsy with fairly satisfactory outcome. However, estimates of visual field defect complicating anterior temporal lobectomy range from 50–70% to 90–100% in different case series. The aim of this study is to assess the visual field defect postoperatively in our unit over the past 10 years.

Methods:

Each patient was examined on the best-corrected visual acuity for distance and near. Visual field of each eye was tested using Humphrey perimetry. Questionnaires were employed to assess the subjective visual ability after operation in relations to daily life. Seizure outcome was assessed by modified Engel's scale

Patients:

35 patients were recruited into the study, with the criteria as below:

Inclusion criteria:

Standard anterior temporal lobectomy and hippocampectomy was done for epilepsy surgery in Prince of Wales Hospital from May 1998 to April 2008. Visual acuity and visual field analysis was performed at least 6 months after surgery.

Exclusion criteria:

- Age <6 or >70
- Temporal lobectomy for head injury, malignant tumours, or lesions not localized at hippocampus, amygdale, uncus or temporal lobe

Results:

Among the 17 patients whom visual field studies have been performed so far, 12 (70.6%) developed visual field defects. 9 (52.9%) had partial homonymous quadrantanopia, 1 (5.9%) had complete homonymous quadrantanopia and 2 (11.8%) had concentric visual field defects.

Conclusions:

We conclude that visual field defect is a significant complication after anterior temporal lobectomy. The interpersonal variation in visual field loss may be due to variation of the Meyer's loop among different individuals. This can serve as the basis for the next stage of study which includes magnetic resonance imaging with diffuse tensor tractography, to demonstrate the correlation between postoperative visual field defect and anterior limit of Meyer's loop on tractography.



Abstracts : Oral Poster II

Title :

Prognostic factors and clinical outcome of non-traumatic cerebellar haemorrhage

Authors and Institution :

TANG CW, LUK WY, SUN TFD, POON WS

Division of Neurosurgery, Department of Surgery, Prince of Wales Hospital, The Chinese University of Hong Kong

Abstract :

Background : Spontaneous cerebellar haemorrhage is a less common form of intracranial haemorrhage. Literature regarding the management strategy remains scarce. Treatment options include conservative management and various types of surgical intervention.

Aim: To identify the predictive factors for clinical outcome in spontaneous cerebellar haemorrhage.

Methods : Patients with spontaneous cerebellar hemorrhage from 2002 to 2007 were recruited. They were divided into group A, initial conservative, Group B, early surgery. Clinical features and clinical outcome were compared.

Results : 76 patients were diagnosed to have spontaneous hemorrhage, 58 and 18 in group A and B respectively. 13 patients in Group A had EVD (external ventricular drainage) inserted. With univariate analysis, age less than 60 ($p=0.03$) and Glasgow coma scale (GCS) on admission greater than 8 ($p=0.001$) were found to correlate significantly with good neurological outcome at 6 months. Haematoma size of less than 3cm, although more likely to result in good neurological outcome, is not a significant factor. ($p=0.37$). The overall neurological outcome for patients who have been operated was not as good as those treated conservatively, which could be explained by the fact that patients in the conservative group generally have better prognosis. But for patients who have GCS < 15 on admission and the size of haematoma greater than 3cm, favorable neurological outcome at 6 months was seen in 44% of the patients in the surgically treated group, compared to only 31% of the patients treated conservatively. This, however, was not statistically significant ($p=0.51$).

Conclusion : Age and Glasgow coma scale serve as important predictors of neurological outcome. Neurosurgical intervention has shown to confer modest neurological benefit in certain patients. In order to define the selection criteria for neurosurgical intervention, larger clinical trial is needed.



Title :

The PYNEH experience of Dissecting aneurysm of Vertebral artery

Authors and Institution :

Vincent KY Pang, Alain KS Wong, CK Wong, KF Fung
Department of Neurosurgery, PYNEH

Abstract :

There are several cases of dissecting aneurysms of VA treated in the past 1 year in PYNEH. The presentation, clinical course and treatment strategy are discussed. The difficulty and inadequacy of current treatment tool for this condition is exemplified by cases discussion.

Title :

Case report of Spontaneous intracranial hypotension

Authors and Institution :

Dr Yeung Yuk Nam, Dr Hung Wai Man, Dr Yuen Shing Chau, Dr Yam Kwong Yui, Dr Dawson Fong
Department of Neurosurgery, Tuen Mun Hospital, Hong Kong

Abstract:

Spontaneous intracranial hypotension is an increasingly recognized syndrome. A 40 years old woman presented with positional headache and meningeal irritation was admitted to our unit. MRI showed diffuse dural enhancement compatible with intracranial hypotension. She have persistent headache despite conservative management. MR myelogram showed CSF leakage along right C2 nerve root. CT brain showed bilateral frontal subdural effusion, prominent pituitary gland and inferior sagging of brain. Epidural blood patch was done on C2/3 region. However, the headache was only relieved for 1 day. 2 more epidural blood patches were done on L3/4, L4/5 region. The patient has complete resolution of headache after the procedures.

We also outline the diagnostic challenges of spontaneous intracranial hypotension as well as the management options.



Abstracts : Oral Poster II

Title :

Mycotic pseudoaneurysm of internal carotid artery: case report and review of the literature

Authors and Institution :

LY Ho, KM Leung, KN Hung; Department of Neurosurgery, Queen Mary Hospital

Abstract :

OBJECTIVE AND IMPORTANCE : Mycotic aneurysms of the carotid artery are rare and difficult to diagnose. We present a case of mycotic pseudoaneurysm of the cavernous segment of internal carotid artery due to *Propionibacterium* septicemia and discuss the pathogenesis as well as various aspects of the diagnosis and surgical management.

CLINICAL PRESENTATION : A 63-year-old man presented with 1 week history of severe left sided headache; initial laboratory and radiographic investigation unremarkable. 3 days later, he developed fever and left conjunctival injection, complete ophthalmoplegia and ptosis. An angiogram and a contrast magnetic resonance imaging study revealed a pseudoaneurysm over the left cavernous internal carotid artery (ICA) and thrombosed left cavernous sinus. Blood culture yielded *Propionibacterium* species. Intravascular infection, endocarditis or contagious infective foci could not be identified.

MANAGEMENT : The patient was given intravenous broad spectrum antibiotics for 4 weeks. Subsequently, the patient complained of increased severity and frequency of left ocular pain. Repeated imaging showed reconstitution and increased in size of the left ICA pseudoaneurysm.

INTERVENTION : Pterional craniotomy, left Extracranial-Intracranial vascular bypass, trapping of left ICA and exploration of left cavernous sinus was performed. Subsequently, the headache completely resolved; however, remained. Pathological examination of the cavernous sinus biopsy revealed thrombus only.

CONCLUSION : The postoperative course was satisfactory except for the persisted left ptosis and ophthalmoplegia. Three months later, a magnetic resonance imaging study showed patent bypass with postoperative changes only



Title :

Incidence of subjective anosmia after interhemispheric approach to anterior skull pathology

Authors and Institution :

LI Lai Fung, LEUNG GKK
Department of Neurosurgery, Queen Mary Hospital

Abstract :

Introduction : Interhemispheric approach to anterior skull base pathology may cause damage to the olfactory nerve by traction with subsequent anosmia. This deficit may affect patient's daily activities and work. We aim to find out the incidence of subjective anosmia after interhemispheric approach and possible influence to patient.

Method : Patients with interhemispheric approach since 1999 were selected. Those who had impaired conscious status and had impaired olfactory function before operation were excluded. Subjective evaluation of anosmia and effect on daily living were assessed by telephone interview.

Result : In progress

Title :

Case of spinal arteriovenous malformation with multiple arteriovenous fistulas

Authors and Institution :

HP Lai, SW Liu, KT Chan, KM Cheng
Department of Neurosurgery, Queen Elizabeth Hospital

Abstract :

Vascular malformations of the spinal cord are one of the causes of spinal cord myelopathy. Endovascular interventions have become an important adjunct and often the primary treatment of these spinal cord malformations.

We reported a case of thoracic spinal AVM and multiple levels of AVFs which was managed with both microsurgical and endovascular approaches. This patient with thoracic spinal AVM presented with bilateral lower limb weakness for years when she was 14 year-old in 1980s. She has received laminectomy with partial excision of thoracic AVM in 1988. Patient was all along asymptomatic after the operation. However, she noticed bilateral thigh weakness with instability on stairs walking in 2007. A follow up MRI spine showed residual AVM. A diagnostic angiogram done later confirmed a thoracic intramedullary AVM with multiple levels of thoracic extramedullary dural AVFs. 3 sessions of embolization were performed to obliterate the thoracic spinal AVM and multiple AVFs.



Abstracts : Oral Poster II

Title :

Extracranial metastasis from medulloblastoma

Authors and Institution :

KT Chan, Y Chan,
Department of Neurosurgery, Kwong Wah Hospital

Abstract :

Extraneural relapse of medulloblastoma is an uncommon event and has typically been associated with a fatal outcome. We present a case of 35 year old woman who developed extensive bone and bone marrow metastasis 11 months after diagnosis and treatment of medulloblastoma. She refused palliative chemotherapy or radiotherapy and died within 1 month after diagnosis of metastatic disease.



A large white rectangular area containing 20 horizontal dotted lines for writing notes.



Abstracts : Nursing Session

Title :

Team work in awake craniotomy and brain mapping procedure

Authors and Institution :

CK Ng, SC Yuen, Department of Neurosurgery, Tuen Mun Hospital

Abstract :

Introduction

The identification of eloquent areas is of utmost importance in the surgery of tumors located near motor and speech cortex. Because of the inter-individual variability, the sensitivity and specificity of fMRI for accurately planning neurosurgical interventions in these eloquent areas is not sufficient when used alone. As recommended by many neurosurgical pioneers (e.g. Ojemann, Berge), awake craniotomy and brain mapping (direct cortical and subcortical electrical stimulations) provide the most precise and reliable method allowing optimal resection of brain tumors in close apposition to eloquent cortex.

Method

We report our preliminary experience in awake craniotomy and brain mapping of intracerebral infiltrative tumors in 7 patients (6 males, 1 females, mean age 46 years) operated from May 2007 through July 2008 in our institution. Presenting symptoms were epileptic seizures in 6 cases and neurological deficit (confusion & slurring of speech) in 1 case. Location of the tumours detected in pre-operative MRI including right pre-central - 1 case, left inferior frontal - 2 cases, right frontal - 2 cases, right fronto-temporal & insular - 1 case, left fronto-temporal & insular - 1 case. Histology examination demonstrated recurrent low grade astrocytoma - 1 case, recurrent oligodendroglioma - 3 cases, oligodendroglioma - 1 case, ganglioglioma - 1 case, and metastatic adenocarcinoma - 1 case.

Pre-operative preparation especially focused on assessment of patient's concentration as well as patient education in terms of intra-operative communication and pain management, so as to facilitate patient's psychological readiness and compliance to the procedure.

During the tumour resection, all patients were under conscious sedation. The primary motor cortex was identified by the somatosensory evoked phase reversal and then direct cortical stimulation mappings were applied to define the areas representing sensorimotor, language and speech functions. Continuous neurological, motor and speech examinations were performed by anaethetists and nurse specialist.

Result

All patients were fully co-operative at the entire surgical procedure. No brain swelling and intra-operative epileptic seizure occurred during brain mappings. 5 gross-total, 1 subtotal and 1 partial removal of tumour were achieved. Post-operative radiological studies (MRI & CT) revealed that no tumour recurrence in 6 cases and residue tumour in 1 case.

Immediately after surgery, 5 patients had no postoperative deficit, 1 patient sustained motor deficit due to intra-operative interruption of lenticulostriate arteries which were buried inside the tumour and 1 had slight expressive dysphasia. The patient with motor deficit recovered from 54 to 84 at Barthel index and grade 4 to 3 at modified Rankin scale respectively at 3 months postoperatively. Meanwhile the expressive dysphasic patient achieved full score in Barthel index and only grade 1 at modified Rankin scale upon her hospital discharge. In brief postoperative patient interview, all 7 patients commented that the awake procedure was within their tolerance level.

Conclusion

Awake craniotomy and direct cortical and subcortical electrical stimulations offer a reliable, precise and safe method, allowing functional mapping especially useful in case of infiltrative cerebral tumors in eloquent areas. This technique facilitates improvement in the quality of tumour resection and a minimization of the risk of postoperative neurological deficit. We believe the pre-requisites of success rely not only on the special technique, but also teamwork, pre-operative patient education and preparation.

Title:

Programming of Subthalamic nucleus(STN) Deep Brain Stimulation (DBS) for Parkinson's disease

Authors and Institution:

Edith Wong, Anne Chan, T.M. Chan, X.L. Zhu, V. Mok, J. Yeung, Prof .W. Poon, Sam Ng, Christine Lau, R. Wong
Combine Movement Disorder group, Prince of Wales Hospital, NTEC

Abstract:

Deep brain stimulation (DBS) of the subthalamic nuclei (STN) has shown to be an effective treatment for advanced Parkinson's disease with motor fluctuation. Post-operative programming can be tedious but is of paramount importance to the overall outcome. We would like to summarize our experience of STN DBS for Parkinson's patients over these 10 years.

Preparatory work for programming was started intra-operatively. Data of microelectrode recording (MER) and effect of macrostimulation is crucial to the choice of stimulation electrodes (Contact 0-4 / Contact 5-7). Post-operative imaging (CT) with image-fusion with pre-operative MRI scan is used to confirm the anatomical position of the leads. After insertion of DBS, medication regime can be simplified. L-DOPA dosage is reduced by 30-50% compared to pre-op dosage and is kept unchanged during programming. Programming usually starts on Day 3 to Day 5 after DBS when the microlesioning effect worn off. Patients are tested during medication-off with setting: monopolar current with frequency of 130Hz, pulse width of 60. Each contact is tested to see the effects and side-effects. The starting current is 0.5V with increments of 0.2V titrating with the effects and side-effects. Results of intra-operative MER information is an important reference to the choice of optimal stimulation contact. Contact 1 (left) & 5 (right) are the commonest optimal contact in monopolar setting. The response to stimulation was best tested with rigidity and tremor. Bradykinesia was difficult for testing due to the delay of stimulation effect. Programming and adjustment were performed at the same time everyday or twice per day. Initial setting was usually achieved in 3 to 5 days. Patients could be discharged on Day 10 to 14. They could return every 2 weeks for fine adjustments until optimization and stabilization of the effect, which was usually achieved by 2 months.

We have operated on 50 Parkinson's patient with STN DBS. Most of them went through uneventful programming. Difficult programming was, though, not rare.

Stimulation side-effects can be divided into target (STN) specific side-effects and side-effects related to stimulation of neighboring structures (electrode malposition or current diffusion).

Target specific side effects include dyskinesia, eyelid opening apraxia, weight gain and psychological effect. Side-effects related to stimulation of neighboring structures are due to electrode malposition or current diffusion. We would like to share our experience in dealing with these problems.



Abstracts : Nursing Session

Title:

Exploring the Education Needs of Newly-diagnosed Brain Tumour Patients and Their Family Caregivers

Authors and Institution:

Cheung Mei Yee Miranda, Neurosurgical ICU, Queen Mary Hospital
Wong Wai Lin Marian, School of Nursing, The Hong Kong Polytechnic University

Abstract:

Purpose : The aim of this study is to investigate the education needs of newly diagnosed brain tumour patients and their family caregivers, as the disease bring them tremendous impacts.

Method : A qualitative study design was employed.

Result : Eight patients and eleven caregivers were invited to participate semi-structured interviews. Six education needs were identified from the data analysis. They include brain tumour, treatment, impacts on daily activities & coping, recovery, social concerns, and home care. Besides, emotion turmoil was revealed in association with the disease. These emotional reactions hindered the education needs, as the participants employed two different approaches to cope with their emotional turbulence. One was actively seeking information. Another was avoiding further information about their disease. Therefore, there are differences in education needs in different stage of treatment process and individual. Furthermore, the participants reflected that the attitude of the health care professional would affect their coping with the disease. The findings enhance planning of patient education strategies.



Title:

Responses to thermal stimulation in persons with central poststroke pain: Sensory decision theory analysis

Authors and Institution:

LO, Shuk Man, Neurosurgical ICU, Queen Mary Hospital
CHUNG, Joanne Wai Yee, School of Nursing, The Hong Kong Polytechnic University

Abstract:

Purpose : The purpose of this study is to determine characteristics of pain responses in persons with central poststroke pain (CPSP) using the sensory decision theory (SDT) and measures of heart rate variability (HRV).

Method : A single interval forced-choice SDT procedure was administered to test seven subjects with CPSP and 15 normal subjects for responses to thermal stimulation. Forty-eight stimuli of 6 thermal intensities of 36°C, 39°C, 42°C, 45°C, 47°C and 49°C were delivered. Neurosensory functioning was measured by discriminability [P(A)], and affective component of pain was evaluated by report criterion (B); whereas, autonomic response to thermal stimuli was evaluated by using time domain and frequency domain parameters of HRV.

Results : The results showed that there were no significance difference between the two groups in discriminability and report criterion. However, higher report criterion in high intensity block was found in the CPSP group. Subjects with CPSP were relatively more stoical. Alternatively, baseline measures of HRV did not show significant difference between the 2 groups. A continuous decrease in LF/HF ratio existed in both groups throughout the procedure. In the post-procedure phase, there was a significant difference in SDNN as indicated by spectral analysis.

Conclusion : The insignificant results from the SDT measures yielding inadequate scientific evidence and inconsistent directional change in the time domain and frequency domain parameters appearing in each group in each experimental phase bringing controversy matters made findings impossible to link the sensory, affective and autonomic responses for characterization of pain pattern in CPSP. Further study into these matters is needed.



Abstracts : Nursing Session

Title :

NTWC care Management in Department of Neurosurgery at TMH, NTWC

Authors and Institution :

Chan Chi-ho, Fok Ka-man, Department of Neurosurgery, Tuen Mun Hospital

Abstract :

To maintain a safety and high quality of service is our priorities to meet the different needs of patient in our Department, but the shortage of manpower may cause great challenges and difficulties to our workplace.

We can now apply the new NTWC care management, introduced by our CCE Dr. Albert Lo, in different practices in our department such as pre-admission service of cerebral angiogram, CSSD sharps management, visual management for the commonly use O2 therapy device, standard stations for easy-reaching disinfectant. By mean of Value Stream Mapping, 6S, Visual Management, Problem solving: Fishbone diagram, Standard work, Kaizen and etc., non-value works (waste) are eliminated and treasurable time is saved for patient care and staff training.

The change in our culture of management is just a beginning and there are rooms for us to improve through the LEAN thinking.

Title:

Enhancement training program for nurses in safety of intra hospital transportation for critical ill patients in neurosurgical department

Authors and Institution:

Mr. H W CHENG, Department of Neurosurgery, Kwong Wah Hospital

Abstract:

Since 1996, the only CT scanner was installed inside our neurosurgical centre which also composed of one HDU & OT in the 7th floor of our hospital. The CT scanner also provided services for all clinical departments meanwhile it also provided excellent access convenience to our frequent users – critical neurosurgical patients of HDU. However, in the recent years, frequent breakdown of CT scanner due to aging has been interrupting our emergency diagnostic service.

With approval from HA for replacement, our hospital has installed one latest model but bigger sized CT scanner in Radiology department in 1st floor of the hospital. As the result, the transfer of our HDU patients for longer distance for CT service, enhancement training is necessary for all nurses in the safe transportation of critical patients. Our training comprised 6 components such as briefing, practice, audit etc. The outcome was also measured and all nurses have followed hospital established guidelines. However, it is necessary that we need to further elaborate the real time documentation during transportation.



A large white rectangular area containing 20 horizontal dotted lines for writing notes.



Acknowledgement



The Organising Committee would like to
extend their heartfelt thanks

to

Accuray Asia Ltd.
Allergan Asia Limited
B. Braun Medical (HK) Ltd.
Baxter Healthcare Ltd.
Boston Scientific HK Ltd.
BrainLAB Ltd.
Carl Zeiss Far East Co. Ltd.
Ebewe Pharma (Asia) Ltd.
Esaote China Limited
The Industrial Promoting Co. Ltd.
Johnson & Johnson (HK) Ltd.
Medtronic International Ltd.
Newtech International Trading Ltd.
Sanofi-aventis Group
SOL Limited (Schering-Plough)
Stryker China Ltd.

for the generous support and contribution to

15th Annual Scientific Meeting
The Hong Kong Neurosurgical Society