



Title	Spinal cord compression secondary to brown tumour in a patient on long-term haemodialysis: a case report.
Author(s)	Mak, KC; Wong, YW; Luk, KD
Citation	Journal Of Orthopaedic Surgery (Hong Kong), 2009, v. 17 n. 1, p. 90-95
Issued Date	2009
URL	http://hdl.handle.net/10722/59485
Rights	Journal of Orthopaedic Surgery. Copyright © Hong Kong Academy of Medicine Press.

Spinal cord compression secondary to brown tumour in a patient on long-term haemodialysis: a case report

KC Mak, YW Wong, KDK Luk

Department of Orthopaedics and Traumatology, Queen Mary Hospital, University of Hong Kong, Hong Kong

ABSTRACT

Brown tumours may occur secondary to hyperparathyroidism in patients with chronic renal failure (CRF). Diagnosing a spinal brown tumour causing cord compression requires a high index of suspicion. We report a 65-year-old woman, who had been on haemodialysis for CRF for over 10 years, who presented with leg weakness and back pain over the thoracolumbar junction. She had a brown tumour at T8 causing subacute spinal cord compression. Ambulation was regained after surgical decompression and stabilisation. Adherence to the National Kidney Foundation guidelines in the management of patients with CRF may prevent renal osteodystrophy. Treatment of spinal brown tumour depends on the severity of the neurological deficit. Remineralisation is expected after correction of the parathyroid level, thus negating the need for total excision of the parathyroid glands.

Key words: hyperparathyroidism, secondary; kidney failure,

chronic; osteitis fibrosa cystica; renal dialysis; spinal cord compression; vitamin D

INTRODUCTION

Patients with chronic renal failure (CRF) on long-term haemodialysis are at risk of secondary hyperparathyroidism due to phosphate retention and lowered calcitriol levels. Brown tumours are uncommon sequelae in hyperparathyroidism.¹ They are not neoplasms, but can grow considerably in size and compress vital structures,² particularly in the mandible, maxilla, ribs, and pelvis. Incidence rates of 1.5 to 13% have been reported in patients with CRF.³ Vertebral brown tumours are rare and a high index of suspicion is required for early diagnosis and treatment. We report a case of brown tumour at T8 causing subacute spinal cord compression in a patient with CRF.

CASE REPORT

In 2006, a 65-year-old woman who had been on

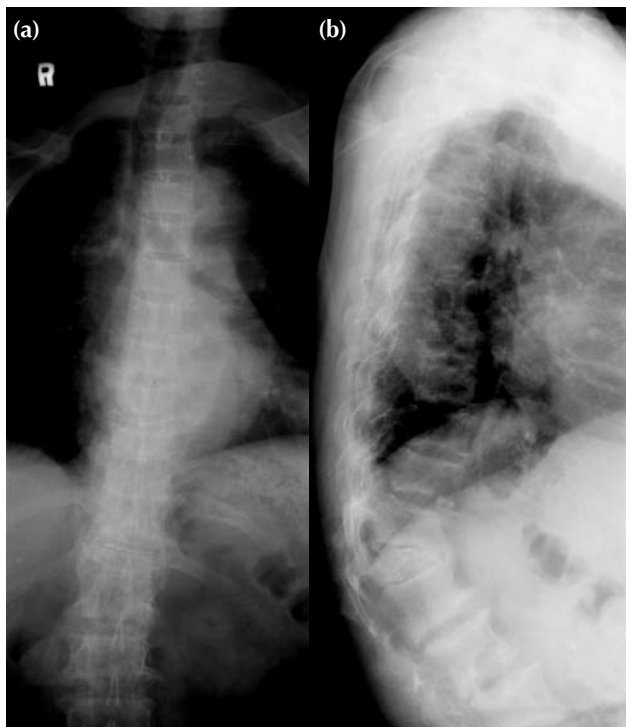


Figure 1 (a) Anteroposterior and (b) lateral radiographs of the thoracic spine showing collapse of T11 and T12.

haemodialysis for CRF for over 10 years presented with a 6-month history of back pain over the thoracolumbar junction. Her leg power had deteriorated considerably a week before presentation and she was unable to walk. She had sustained a wedge fracture of T12 about 20 years earlier and developed a kyphosis at the thoracolumbar junction. Physical examination revealed local tenderness over the gibbus. Her leg power was 3 out of 5 based on the Medical Research Council grading⁴ and the deep tendon reflexes were diminished. The plantar reflex was equivocal on the right and upgoing on the left. Sharp/blunt discrimination was intact, but vibration sense was reduced in the right leg. A rectal examination revealed lax anal tone and absent anal grip despite no complaint of bowel or urinary symptoms. Upper limb functions were normal.

Radiographs showed marked wedging of T12, with mild collapse of T11, resulting in an acute kyphosis over the thoracolumbar junction (Fig. 1). No abnormalities were visible at T8 because this was obscured by lung shadows. A bone scan revealed no increased uptake over T8. Magnetic resonance imaging (MRI) showed cord compression at T8 but not at T12. A sagittal T2-short tau inversion recovery

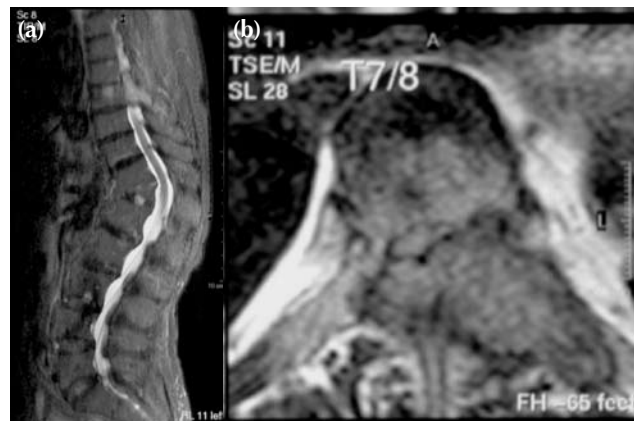

Figure 2 (a) Sagittal T2-weighted image showing a hyperintense lesion at T8 and hypertrophic ligamentum flavum at T9/T10 and T10/T11. (b) Transverse T1-weighted image showing an isointense lesion involving posterior elements of T8, causing spinal cord compression and displacing the cord to the right.

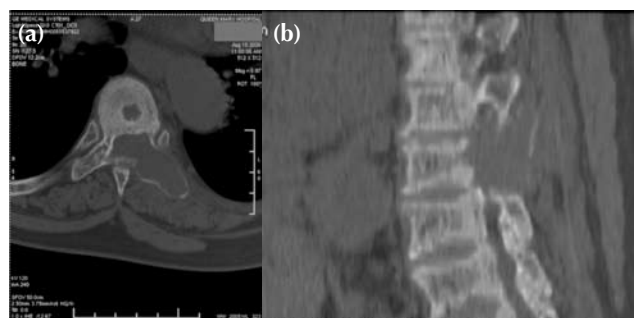


Figure 3 (a) Axial and (b) sagittal sections of computed tomographic scans showing an expansile, lytic lesion in the left T8 lamina extending to about T7.

(STIR) image showed a hyperintense lesion at T8 (Fig. 2a), whereas a transverse T1-weighted image showed an isointense lesion involving posterior elements of T8, causing spinal cord compression and displacing the cord to the right (Fig. 2b). There were folds of ligamentum flavum between the T9/T10 and T10/T11 junctions. Computed tomographic (CT) scanning confirmed a lytic, expansile lesion at T8 arising from the left lamina and extending cephalad to abut the posterior element of T7, with no obvious intra-lesional calcification (Fig. 3).

Her creatinine level was 382 (normal range, 45–82) $\mu\text{mol/l}$, calcium level adjusted for serum albumin was 2.27 (normal range, 2.24–2.63) mmol/l , phosphate

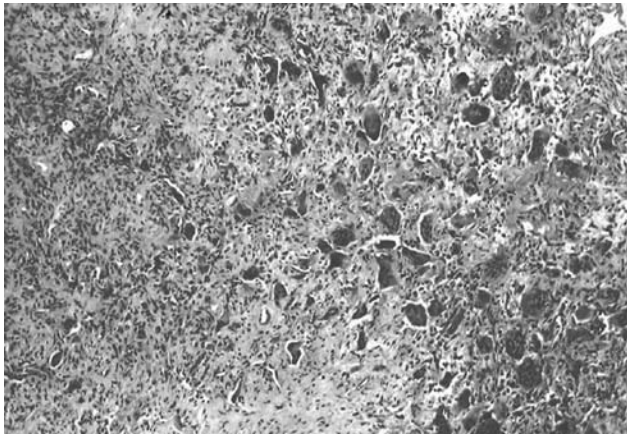


Figure 4 Photomicrograph of the T8 lesion showing a cluster of multinucleated giant cells in fibroblastic stroma (H&E, x10).

level was 1.57 (normal range, 0.88–1.45) mmol/l, and alkaline phosphatase level was 378 (normal range, 54–140) u/l. Treatment for her CRF included haemodialysis 3 times a week, erythropoietin β , and alfacalcidol. Her white cell count was normal.

A percutaneous CT-guided Tru-Cut needle biopsy of the posterior T8 vertebra revealed no malignancy but the presence of multinucleated giant cells on a background of hypervascular fibroblastic stroma (Fig. 4). The serum parathyroid hormone (PTH) level was markedly elevated (intact PTH immunoassay, 93.2 pmol/l; normal range, 1.2–5.7 pmol/l). This confirmed the diagnosis of a brown tumour at T8.

Surgical decompression was performed in view of pending paralysis. Severe cord compression secondary to the epidural tumour mass was noted from T7 to T8/9 disc level, with erosion of the left T7/8 facet joint and transverse processes. Decompression was achieved through a T7 and T8 laminectomy until the dura was seen and the left T7/8 facet joint was taken down, using a standard posterior midline approach. The tumour was debulked using an ultrasonic suction aspirator.⁵ The spine was fused with instrumentation from T6 to T10 using autogenous cancellous bone graft from the left ilium.

The patient was prescribed a thoracolumbar orthosis for 4 months. Her motor power improved gradually to grade 4 after rehabilitation. Radiographs at 3 months showed no major collapse of T8 (Fig. 5). At the one-year follow-up, she could walk unaided for over 15 minutes. Her hyperparathyroidism was treated medically as she had undergone thyroidectomy 20 years earlier, and the parathyroid scintigraphy was negative.

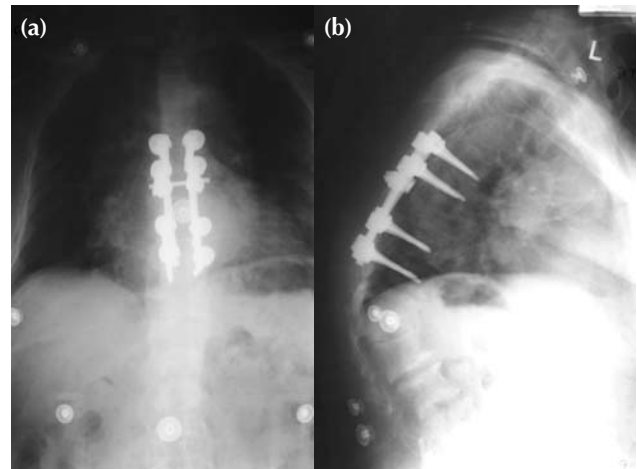


Figure 5 Postoperative (a) anteroposterior and (b) lateral radiographs showing pedicle screw instrumentation from T6 to T10, with no significant collapse of T8.

DISCUSSION

The overall incidence of brown tumours is greater in patients with primary than with secondary hyperparathyroidism.⁶ Nonetheless, more spinal brown tumours result from secondary than from primary hyperparathyroidism. Secondary hyperparathyroidism is due to compensatory hypersecretion of PTH and can thus be caused by any condition that chronically suppresses calcium levels.⁷ The most common cause is chronic renal failure, followed by inadequate dietary intake of calcium and vitamin-D deficiency.⁷ In the later stages of secondary hyperparathyroidism, some patients develop tertiary hyperparathyroidism, with autonomous and excessive PTH secretion, despite hypercalcaemia.⁷

Hyperparathyroidism causes loss of cortical bone and predisposes to microfractures and secondary haemorrhage, which leads to an influx of multinucleated macrophages and the ingrowth of reparative fibrous tissue, a reactive tissue mass known as a brown tumour forms and they may encroach upon other structures.⁸ The vascularity, haemorrhage, and haemosiderin deposition gives rise to the characteristic colour. Cystic degeneration is not uncommon.⁸ The pathophysiology of renal osteodystrophy and brown tumour is complex. The histopathology lacks a pathognomonic feature and the predominant pattern (whether osteomalacic or osteosclerotic, high- or low-turnover, or mixed) may be affected by a number of variables. The PTH level is almost always elevated; a greater level of elevation is

Table
Cases of spinal brown tumour caused by secondary hyperparathyroidism in patients with chronic kidney disease

Studies	Sex/age (years)	Haemodialysis	Spine segment involved	Surgical decompression
Ericsson et al., ¹¹ 1978	F/47	Pending	Cervico-thoracic junction	Yes
Bohlman et al., ¹² 1986	F/69	No	Thoracic	No (patient died)
Pumar et al., ¹³ 1990	F/24	Yes	Thoracic	Yes
Barlow and Archer, ¹⁴ 1993	F/31	Yes	Cervical	No (patient had radiculopathy)
Fineman et al., ¹⁵ 1999	F/37	Yes	Thoracic	Yes
Azria et al., ¹⁶ 2000	F/40	Yes	Thoracic	No (patient only had neck pain)
Masutani et al., ¹⁷ 2001	F/39	Yes	Thoracic	Yes
Vandenbussche et al., ³ 2004	F/34	Yes	Thoracic	Yes
Tarass et al., ⁷ 2005	M/42	Yes	Sacral	Yes
Current case	F/65	Yes	Thoracic	Yes

required to cause dynamic bone disease owing to PTH resistance.⁹ Several factors are known to contribute to adynamic bone diseases, including the use of high dialysate calcium concentration, large doses of calcium-containing phosphate binders, inappropriate use of active vitamin D sterols, peritoneal dialysis, and aluminium toxicity (owing to the use of aluminium-based phosphate binders).⁹

Symptomatic hyperparathyroidism usually presents with complaints described as painful bones, renal stones, abdominal groans, and psychic moans.¹ Most densitometry studies support the view that hyperparathyroidism leads to cortical bone catabolism and relative cancellous bone preservation.¹⁰

Bone abnormalities and other changes associated with PTH excess are less severe in secondary than primary hyperparathyroidism.¹ There have been 8 cases of spinal brown tumour due to secondary hyperparathyroidism reported in patients with CRF on haemodialysis (Table).^{3,11-17} In one other case the patient had CRF but was not on haemodialysis, and there was a case in a patient with chronic pyelonephritis for over 20 years who was awaiting haemodialysis or transplantation. All but one of the patients were women, and the thoracic spine was most commonly involved. Only 2 patients were over 60 years of age, possibly reflecting decreased bone remodelling with ageing.

Findings on imaging vary according to the modality used. On radiographs, it is difficult to define the margin of a brown tumour in the spine because of overlapping shadows, but in the peripheral skeleton these tumours are well defined, expansile with internal septations or with sclerosis in the later stages.¹⁸ On bone scans, they are often hypervascular, with increased uptake in the immediate-blood-flow phase. In 3-phase bone scans, enhancement in all 3 phases

indicates regional perfusion, osteoid formation, and mineralisation.¹⁹ In contrast, extremely aggressive tumours disrupting local blood supply or displacing bone marrow may produce cold lesions. The amount of tracer uptake in the delayed-blood-flow phase depends on the extent of the mineralisation front and intensity of osteitis fibrosa.²⁰ In our patient, the negative bone scan suggests a lesion with limited osteoblastic activity. On MRI, our patient's lesion was hyperintense on T2-weighted imaging, which is consistent with other reports.¹⁵

A fast field echo would show the haemosiderin deposits of a brown tumour better, and gadolinium contrast would show enhancement of the lesion.²¹

The differential diagnosis of a brown tumour includes a giant cell tumour and an aneurysmal bone cyst. In giant cell tumours, the stromal spindle cells are more swollen, and the osteoclastic multinucleated giant cells are more regularly distributed and tend not to appear in aggregates, without interstitial haemorrhage.⁶ Aneurysmal bone cysts have a slight preponderance in females and tend to affect patients aged 10 to 20 years, with multiloculated cysts with fluid levels seen on MRI.²² Cytological tests help differentiate malignant from benign lesions, but cannot confirm the diagnosis. Serum PTH levels are therefore paramount in both the diagnosis and monitoring of treatment for brown tumours.

In patients with CRF, PTH levels are often elevated because of PTH resistance, and this may worsen with progression of renal failure. In patients with mild-to-moderate renal failure, PTH levels have been reported to range from 1.8 to 40.3 pmol/l.²³ Patients with CRF and spinal brown tumour have markedly elevated PTH levels, often more than 10 times normal.^{6,9,23} Calcium and phosphate levels may be normal in secondary hyperparathyroidism.¹⁸

Therefore, biochemical screening of electrolytes and alkaline phosphatase may not be conclusive in terms of secondary hyperparathyroidism or brown tumour.

The management of brown tumours in patients with CRF should begin with monitoring for secondary hyperparathyroidism and prevention of the development of renal osteodystrophy. In 2003, the National Kidney Foundation proposed the Kidney Disease Outcomes Quality Initiative (K/DOQI) guidelines.²⁴ Target levels were established for PTH, calcium, phosphate, and calcium-phosphate products, but the 'cocktail' of medication required to attain those targets remains a matter of active research. Current treatment guidelines include judicious use of calcium supplements, phosphate binders, and vitamin-D sterols.²⁴ Aluminium toxicity and the adverse effects of hypercalcaemia have led to the use of non-calcium, non-aluminium phosphate binders and active vitamin-D sterols with wider therapeutic windows (i.e. greater PTH suppression but fewer hypercalcaemic effects).^{25,26} Nonetheless, most patients on haemodialysis do not meet the stringent K/DOQI guidelines because of the complex interactions of the above minerals.

When medical prevention of renal osteodystrophy and its consequent formation of brown tumour fails, imminent or frank cord compression may result. Some cases may be due to the mass itself whereas others may be due to the associated pathological fractures.¹³ Urgent decompression is indicated to prevent paraplegia. Complete resection may not be necessary, because regression and remineralisation may take place once the PTH level is corrected. When the spine is unstable, reconstructive surgery involving bone grafting and instrumentation may be necessary.¹⁵ The surgical approach is dictated by the site of the lesion and whether instrumentation is needed. Although brown tumours are often described as vascular, there was no undue bleeding intra-operatively in our patient. Only one of the 9 reported cases underwent preoperative embolisation.³

Correction of the PTH level is mandatory and can be achieved by the use of medications or by parathyroidectomy. Recent controlled studies on calcimimetics have provided new impetus for the former option.²⁷ These new drugs act by increasing calcium receptor sensitivity, causing a rapid decrease in PTH levels within hours. Compared to

the use of calcium and vitamin-D sterols alone, the addition of calcimimetics reduces the side effects of calcium-phosphate product elevation.²⁸ Nonetheless, parathyroidectomy remains the standard treatment approach. It does not require a difficult hormonal 'balancing act'; the tumour regresses within weeks (compared to months with medication alone); and the gain in bone mineral density (BMD) is more rapid and complete. Surgical removal of the gland may also be necessary when the PTH, calcium, and/or phosphate levels are resistant to medical therapy. Rapid increase in the BMD of osteitis fibrosa cystica lesions due to primary hyperparathyroidism after parathyroidectomy has been reported in a study on BMD in the radius, hip, and lumbar spine.²⁹ The increase occurred as early as one week after surgery and at a rate of greater than 100% per year. Although 20% of the cases did not experience complete regression of the tumour, BMD were notably improved in cancellous structures (e.g. the lumbar spine and the distal end of the radius).²⁹ Parathyroidectomy may be total, total with parathyroid tissue transplantation, or subtotal. Transplantation should avoid nodular areas of the gland and total parathyroidectomy should be avoided to prevent adynamic bone disease. The main postoperative complication is the 'hungry bone syndrome', which may cause significant hypocalcaemia.³⁰

CONCLUSION

Regular monitoring of PTH levels and treatment according to K/DOQI guidelines helps prevent brown tumours in patients with CRF. The diagnosis of brown tumour hinges on the finding of a giant cell lesion on biopsy and a markedly elevated serum PTH level. Treatment should include normalisation of the PTH level, either via medication or more rapidly through parathyroidectomy. Surgical decompression of the spinal cord is necessary in the presence of spinal brown tumour and a severe neurological deficit.

ACKNOWLEDGEMENTS

We thank WY Cheung for helping in the surgery and P Ip from the Department of Pathology for providing the histological findings.

REFERENCES

1. Maitra A, Abbas AK. The endocrine system. In: Kumar V, Abbas AK, Fausto N, editors. Robbins & Cotran pathologic basis of

- disease, 7th ed. Philadelphia: Elsevier Saunders; 2005:1155–226.
2. Lessa MM, Sakae FA, Tsuji RK, Filho BC, Voegels RL, Butugan O. Brown tumor of the facial bones: case report and literature review. *Ear Nose Throat J* 2005;84:432–4.
 3. Vandenbussche E, Schmider L, Mutschler C, Man M, Jacquot C, Augereau B. Brown tumor of the spine and progressive paraplegia in a hemodialysis patient. *Spine* 2004;29:E251–5.
 4. John J. Grading of muscle power: comparison of MRC and analogue scales by physiotherapists. Medical Research Council. *Int J Rehabil Res* 1984;7:173–81.
 5. Suetsuna F, Harata S, Yoshimura N. Influence of the ultrasonic surgical aspirator on the dura and spinal cord. An electrohistologic study. *Spine* 1991;16:503–9.
 6. Pecovnik Balon B, Kavalar R. Brown tumor in association with secondary hyperparathyroidism. A case report and review of the literature. *Am J Nephrol* 1998;18:460–3.
 7. Tarrass F, Ayad A, Benjelloun M, Anabi A, Ramdani B, Benghanem MG, et al. Cauda equina compression revealing brown tumor of the spine in a long-term hemodialysis patient. *Joint Bone Spine* 2006;73:748–50.
 8. Rosenber AE. Bones, joints, and soft tissue tumors. In: Kumar V, Abbas AK, Fausto N, editors. *Robbins & Cotran pathologic basis of disease*, 7th ed. Philadelphia: Elsevier Saunders; 2004:1273–324.
 9. Hernandez JD, Wesseling K, Salusky IB. Role of parathyroid hormone and therapy with active vitamin D sterols in renal osteodystrophy. *Semin Dial* 2005;18:290–5.
 10. Khan A, Bilezikian J. Primary hyperparathyroidism: pathophysiology and impact on bone. *CMAJ* 2000;163:184–7.
 11. Ericsson M, Holm E, Ingemansson S, Lindholm T, Svendgaard NA. Secondary hyperparathyroidism combined with uremia and giant cell containing tumor of the cervical spine. A case report. *Scand J Urol Nephrol* 1978;12:185–7.
 12. Bohlman ME, Kim YC, Eagan J, Spees EK. Brown tumor in secondary hyperparathyroidism causing acute paraplegia. *Am J Med* 1986;81:545–7.
 13. Pumar JM, Alvarez M, Perez-Batallon A, Vidal J, Lado J, Bollar A. Brown tumor in secondary hyperparathyroidism, causing progressive paraplegia. *Neuroradiology* 1990;32:343.
 14. Barlow IW, Archer IA. Brown tumor of the cervical spine. *Spine* 1993;18:936–7.
 15. Fineman I, Johnson JP, Di-Patre PL, Sandhu H. Chronic renal failure causing brown tumors and myelopathy. Case report and review of pathophysiology and treatment. *J Neurosurg* 1999;90(2 Suppl):S242–6.
 16. Azria A, Beaudreuil J, Juquel JP, Quillard A, Bardin T. Brown tumor of the spine revealing secondary hyperparathyroidism. Report of a case. *Joint Bone Spine* 2000;67:230–3.
 17. Masutani K, Katafuchi R, Uenoyama K, Saito S, Fujimi S, Hirakata H. Brown tumor of the thoracic spine in a patient on long-term hemodialysis. *Clin Nephrol* 2001;55:419–23.
 18. Potts JT Jr. Diseases of the parathyroid gland and other hyper- and hypocalcemic disorders. In: Kasper DL, Braunwald E, Fauci AS, Hauser SL, Longo DL, Jameson JL, editors. *Harrison's principles of internal medicine*. 16th ed. New York: McGraw Hill; 2005:2249–68.
 19. Jordan KG, Telepak RJ, Spaeth J. Detection of hypervascular brown tumors on three-phase bone scan. *J Nucl Med* 1993;34:2188–90.
 20. Karsenty G, Vigneron N, Jorgetti V, Fauchet M, Zingraff J, Druke T, et al. Value of the ^{99m}Tc-methylene diphosphonate bone scan in renal osteodystrophy. *Kidney Int* 1986;29:1058–65.
 21. McKie S, Brittenden J. Basic science: magnetic resonance imaging. *Curr Orthop* 2005;19:13–9.
 22. Liu JK, Brockmeyer DL, Dailey AT, Schmidt MH. Surgical management of aneurysmal bone cysts of the spine. *Neurosurg Focus* 2003;15:1–7.
 23. Arabi A, Khoury N, Zahed L, Birbari A, El-Hajj Fuleihan G. Regression of skeletal manifestations of hyperparathyroidism with oral vitamin D. *J Clin Endocrinol Metab* 2006;91:2480–3.
 24. National Kidney Foundation. K/DOQI clinical practice guidelines for bone metabolism and disease in chronic kidney disease. *Am J Kidney Dis* 2003;42(4 Suppl 3):S1–201.
 25. Brown AJ, Slatopolsky E. Drug insight: vitamin D analogs in the treatment of secondary hyperparathyroidism in patients with chronic kidney disease. *Nat Clin Pract Endocrinol Metab* 2007;3:134–44.
 26. Ogata H, Koiwa F, Ito H, Kinugasa E. Therapeutic strategies for secondary hyperparathyroidism in dialysis patients. *Ther Apher Dial* 2006;10:355–63.
 27. Weigel RJ. Nonoperative management of hyperparathyroidism: present and future. *Curr Opin Oncol* 2001;13:33–8.
 28. Block GA, Martin KJ, de Francisco AL, Turner SA, Avram MM, Suranyi MG, et al. Cinacalcet for secondary hyperparathyroidism in patients receiving hemodialysis. *N Engl J Med* 2004;350:1516–25.
 29. Agarwal G, Mishra SK, Kar DK, Singh AK, Arya V, Gupta SK, et al. Recovery pattern of patients with osteitis fibrosa cystica in primary hyperparathyroidism after successful parathyroidectomy. *Surgery* 2002;132:1075–85.
 30. Slatopolsky E, Gonzalez E, Martin K. Pathogenesis and treatment of renal osteodystrophy. *Blood Purif* 2003;21:318–26.