



| | |
|--------------------|--|
| Title | Bone regeneration goal in sight |
| Author(s) | Rabie, ABM |
| Citation | Asian Medical News, 1994, v. 16 n. 6, p. 5 |
| Issued Date | 1994 |
| URL | http://hdl.handle.net/10722/57502 |
| Rights | Creative Commons: Attribution 3.0 Hong Kong License |

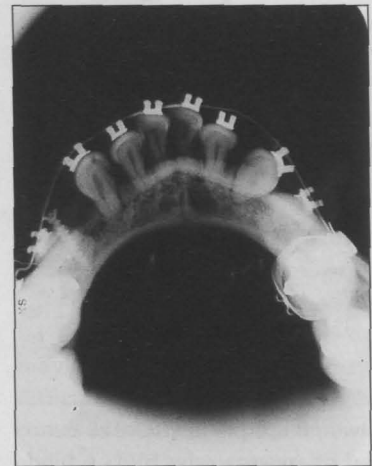
Bone regeneration goal in sight

by Susan Mulley

HONG KONG - Engendering natural bone regeneration to plug small bony defects in the oral cavity instead of using onlay bone grafts is the ultimate goal of Dr A-Bakr M Rabie.

He also hopes to be able to enhance the integration of bone grafts, as well as pinpoint the underlying mechanisms involved in bone integration.

Dr Rabie is a lecturer in the Department of Children's Dentistry and Orthodontics at the University of Hong Kong, Prince Philip Dental Hospital. "While the routine replacement of some damaged or diseased tissues appears to be nearing realization, the replacement of lost bone by autogenous grafting is seldom practiced in orthodontics," he told *Asian Medical News*.



Three months post-surgery, the graft cannot be distinguished from bone on the X-ray.

"Frequently, clinicians face the horror of losing the buccal plate of bone to extraction or collapse of the cortical plates. This leads to failure of moving teeth into the extraction site."

Dr Rabie has shown that non regenerative bony defects in adults can be repaired with the use of a membranous onlay bone graft, demineralized cortical bone matrix, and fixation of the onlay graft.

Once the bone graft, taken from the membranous bone of the chin or cranium, has been fixed, bone morphogenetic protein (BMP) is packed around it.

After 24 hours, the bone graft releases angiogenic factors which "are crucial for the growth of capillaries and the introduction of blood supply to the region. The BMP, (genetically cloned demineralized bone) precipitates the conversion of the "mother" cells, circulating in the blood, into bone-building osteoblasts.

Finally, the area is closed with sutures. No gortex covering is necessary.

X-rays indicate that three weeks after bone grafting, integration is taking place, and just a "shadow" exists between the graft and host bone.

Six weeks later the shadow has faded, and three months post-surgery, the graft cannot be

distinguished on the X-ray (This patient had lost bone with a tooth extraction). Teeth can then be moved successfully into the graft site.

Fixation of the graft is essential, Dr Rabie said, explaining that without fixation, "micro-

wriggling" occurs, leading to the rupture of blood vessels and bone resorption.

Dr Rabie is trying to identify the specific factors released by the membranous bone which encourage blood vessel induction, and believes this is the key to

eliminating the need for a bone graft.

"If we know exactly what factors are being released (from the bone graft), we can extract them and mix them with the BMP and the tissue trimmings from the patient," and the bone should regenerate naturally, Dr Rabie said.

Dr Rabie came to Hong Kong six months ago, from Northwestern University's Department of Orthodontics and Oral Biology in Chicago, USA, attracted by the greater opportunity of securing research grants. ♦

UROTRACTIN

Recurrent CYSTITIS and women at repeated risk



urotractin[®]
pipemidic acid 400 mg

The Urinary Quinolone for Effective Prophylaxis of Recurrent Cystitis in Females

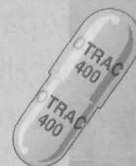PROPOSED DOSAGE

GENERAL PROPHYLAXIS OF RECURRENT CYSTITIS

- 1 CAPSULE AT BEDTIME FOR 6 MONTHS

PROPHYLAXIS OF RECURRENT CYSTITIS TRIGGERED BY SEXUAL INTERCOURSE

- 1 CAPSULE IN THE MORNING AND 1 CAPSULE IN THE EVENING AFTER INTERCOURSE



eurodrug
laboratories

EURODRUG LABORATORIES LTD.
1501, Java Commercial Centre, 124-134, Java Road, North Point, Hong Kong.
UROTRACTIN is a registered Trademark. Further information is available on request.