

Title	Focal fatty change: a rare hepatic manifestation of diabetes mellitus
Author(s)	Ng, WK; Ng, IOL
Citation	Hong Kong Medical Journal, 1996, v. 2 n. 1, p. 99-101
Issued Date	1996
URL	http://hdl.handle.net/10722/54180
Rights	Creative Commons: Attribution 3.0 Hong Kong License

Focal fatty change: a rare hepatic manifestation of diabetes mellitus

WK Ng, IOL Ng

Focal fatty change of the liver is a rare and poorly recognised entity. Most of the previously reported cases occurred in patients suffering from the usual steatogenic conditions, such as diabetes mellitus and obesity. The focality of the lesion, however, remains unexplained. The authors report a rare case of subcapsular focal fatty change of the liver occurring in a 60-year-old Chinese woman suffering from poorly controlled adult-onset diabetes mellitus. The underlying pathogenesis for the focal fatty change is thought to be related to local ischaemic effect secondary to diabetic angiopathy, which may further enhance the steatogenicity of diabetes mellitus. The recognition of focal fatty change of the liver is important in order to avoid misdiagnosis of other space-occupying lesions radiologically and macroscopically.

HKMJ 1996;2:99-101

Key words: Fatty liver; Liver; Diabetes mellitus

Introduction

Fatty change of the liver is a common surgical biopsy and autopsy finding associated with steatogenic conditions including alcoholism, diabetes mellitus, obesity, malnutrition, drug effect and—more rarely—inherited metabolic disorders. It is a diffuse process involving all parts of the liver more or less equally, although it may have a zonal distribution within individual hepatic acini. However, focal fatty change of the liver is a poorly recognised and rarely described entity. To date, approximately 40 cases have been reported in the literature.¹⁻¹² Most of these cases occurred in patients who also suffered from steatogenic conditions for diffuse fatty change. The underlying pathogenesis for the focality remains controversial. The authors report a rare case of focal fatty change of the liver associated with poorly controlled adult-onset diabetes mellitus.

Case report

The patient was a 60-year-old Chinese woman with a 20-year history of hypertension which required regu-

lar medication (frusemide, 20 mg, once daily). Otherwise, her prior medical history was said to be unremarkable. She presented on this occasion with shortness of breath of one day's duration. Serum creatine kinase level on admission measured 386 U/L (normal range, 0-130 U/L), and there was no definite electrocardiographic evidence of acute myocardial infarction (AMI). The echocardiogram showed globally impaired left ventricular systolic function. The spot blood glucose level was also found to be markedly elevated (50 mmol/L (normal range, 3.9-6.1 mmol/L)). Liver function was within normal limits. A provisional diagnosis of left ventricular failure and diabetes mellitus was made. The blood glucose level was subsequently controlled by administering an oral hypoglycaemic (gliclazide, 80 mg, twice daily). However, on day 4 of her hospital stay, she suddenly developed cardiac arrest and could not be resuscitated. A clinical postmortem was performed.

Pathological findings

The most important autopsy finding was in the cardiovascular system, where there was an old AMI in the posteroseptal region complicating severe atherosclerosis of the right coronary artery. On sectioning of the liver, an incidental finding of a well-demarcated nonexpansile solitary yellow lesion was identified in the subcapsular region of the anteroinferior part of the right lobe of the liver around the porta hepatis. This measured 4 x 3 x 2

Department of Pathology, The University of Hong Kong, Queen Mary Hospital, Pokfulam, Hong Kong
WK Ng, MB, BS
IOL Ng, MD, MRCPath
Correspondence to: Dr WK Ng

cm in size and had a homogeneous greasy cut surface and 'geographic' border. Other diabetes-related complications, namely, old pulmonary tuberculosis, mild diabetic nephropathy, and cholelithiasis were also found.

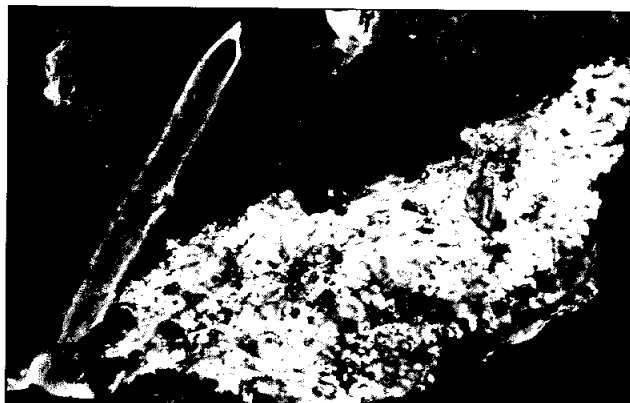

Fig 1. Cut surface of the liver showing focal fatty change with well-demarcated geographic border

Representative samples were taken from the focal liver lesion, promptly fixed in 10% neutral buffered formalin, and processed as paraffin blocks. Three-micron-thick paraffin sections were cut and stained with haematoxylin and eosin. Histological examination of the subcapsular lesion showed diffuse and marked macrovesicular steatosis of the hepatocytes. The acinar zone 3 was most severely affected. However, the acinar architecture was preserved.

Many of the hepatic arterioles within and adjacent to the lesion showed intimal thickening and hyalinisation which stained positively with periodic acid-Schiff reagent. Sections taken from other parts of the liver showed mild fatty change in acinar zone 3 only. There was no evidence of hepatocytic necrosis, Mallory-hyaline body or bridging necrosis. The small hepatic arterial branches and arterioles in other parts of the liver were unremarkable.

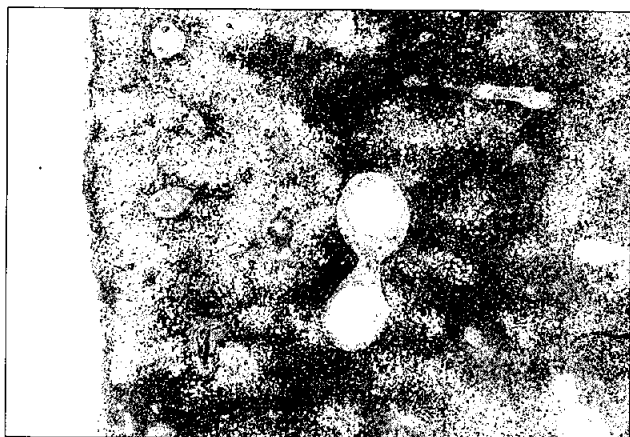


Fig 2. Low-power view showing focal fatty change in the subcapsular region of the liver (H & E, x 25)

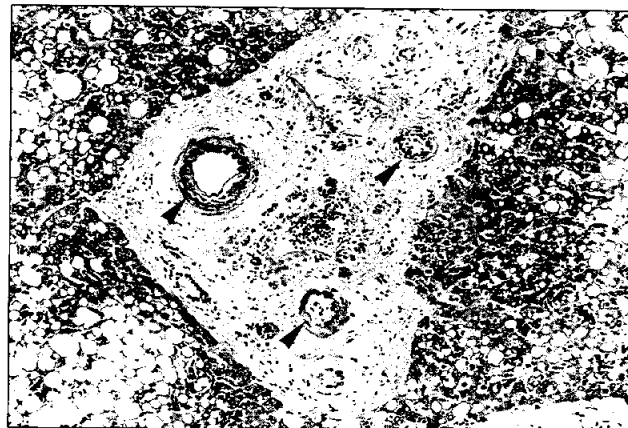

Fig 3. High-power examination of one of the portal tracts within the lesion showing hyalinized and narrowed hepatic arterioles (arrows) (H & E, x 150)

Discussion

Focal fatty change of the liver is rare and probably underdiagnosed. Most of the reported cases in the literature are associated with conditions such as diabetes mellitus,^{1-6,8,10,12} continuous ambulatory peritoneal dialysis (CAPD),^{2,5,10} and disseminated malignancies.^{1,9} Some of these conditions are known to be steatogenic and may also cause diffuse fatty change of the liver. Gross focal fatty change may be solitary or multifocal and is characterised by well-demarcated nodule(s) having a yellow greasy cut surface. There is often a subcapsular location. The remaining liver parenchymal tissue may show a different degree of steatosis. The focality of the lesion in most of the reported cases remains unexplained, although local hypoxia¹ and a relationship with the hyperosmotic dialysis solution^{2,5,10} (in those patients undergoing CAPD) have been postulated as possible causes.

Regarding the associated clinical conditions, 18 of the 41 reported cases of liver focal fatty change were associated with diabetes mellitus under varying degrees of control.^{1-6,8,10,12} This patient also had poorly controlled adult-onset diabetes mellitus with multiple complications. The frequent association of overt diabetes with focal fatty change of the liver may provide some clue to the pathogenetic link.

Generally, fatty change of the liver results from an imbalance between triacylglycerol synthesis and secretion. This can be due to enhanced mobilisation and transport of lipids from peripheral adipose tissue, increased endogenous fatty acid synthesis, or decreased mitochondrial oxidation of fatty change. The steatogenicity of diabetes mellitus is

mainly related to enhanced lipid mobilisation and transport, and, less importantly, to increased endogenous fatty acid production.¹³

In focal fatty change of the liver, focal ischaemia related to angiopathic changes exaggerated by poorly controlled diabetes may play an important role. This was evident in the frequent finding of narrowed and hyalinised hepatic arterioles in the portal tracts near and within the lesion in this case. The predominantly subcapsular location of fat deposits is probably related to the fact that the distal hepatic arterial branches supplying these areas are most severely affected.

Focal hypoxia may enhance steatogenesis owing to a decrease in the mitochondrial oxidation of fatty acids.¹⁴ The ischaemia is further perpetuated by swelling of the lipid-laden hepatocytes which may compress the hepatic sinusoids. This postulation is analogous to the frequent presence of steatosis in focal nodular hyperplasia¹⁵ which also typically contains abnormal vasculature within the lesion. Nevertheless, focal hypoxia may not be the sole explanation, as morphological evidence of microcirculation disturbance was not identified in most of the previously reported cases.

The recognition of focal fatty change of the liver may have some clinical significance. Radiologically and macroscopically, it has a superficial resemblance to other space-occupying lesions of the liver, including cholangiocarcinoma and metastatic tumour.^{1,11} Histologically, it must be distinguished from other intrahepatic lipid-containing lesions such as lipoma, coelomic fat ectopia, angiomyolipoma, and myelolipoma. With a trucut needle biopsy of focal liver lesions, if marked steatosis is found in the absence of other morphological or biochemical abnormalities, focal fatty change has to be considered.

References

1. Brawer MK, Austin GE, Lewin KJ. Focal fatty change of the liver, a hitherto poorly recognized entity. *Gastroenterology* 1980;78:247-52.
2. Burrows CJ, Jones AW. Hepatic subcapsular steatosis in a patient with insulin dependent diabetes receiving dialysis. *J Clin Pathol* 1994;47:274-5.
3. Clain JE, Stephens DH, Charboneau JW. Ultrasonography and computed tomography in focal fatty liver: report of two cases with special emphasis on changing appearances over time. *Gastroenterology* 1984;87:948-52.
4. Floymoy JG, Potter JL, Sullivan BM, Gerza CB, Ramzy I. Case report: CT appearance of multifocal hepatic steatosis. *J Comput Assisted Tomogr* 1984;8:1192-4.
5. Grove A, Vyberg B, Vyberg M. Focal fatty change of the liver: a review and a case associated with continuous ambulatory peritoneal dialysis. *Virchows Arch A Pathol Anat Histopathol* 1991;419:69-75.
6. Hartshorne MF, Crooks LA, Bennett W, et al. A false-negative xenon-133 study in focal fatty infiltration of the liver. *Clin Nucl Med* 1985;10:336-40.
7. Pardes JG, Haaga JR, Borkowski G. Focal hepatic fatty metamorphosis secondary to trauma. *J Comput Assisted Tomogr* 1982;6:769-71.
8. Sawada S, Kawa S, Murata T, Tanaka Y, Koishi T, Fukagae N. Localized fatty infiltration of the liver: CT demonstration of its disappearance on treatment. *Acta Radiol Diagn Stockh* 1983;24:359-61.
9. Simon MA. Focal fat infiltration in the liver. *Am J Pathol* 1934;10:799-803.
10. Wanless IR, Bargman JM, Oreopoulos DG, Vas SI. Subcapsular steatonecrosis in response to peritoneal insulin delivery: a clue to the pathogenesis of steatonecrosis in obesity. *Mod Pathol* 1989;2:69-74.
11. Yates CK, Streight RA. Focal fatty infiltration of the liver simulating metastatic disease. *Radiology* 1986;159:83-4.
12. Yoshikawa J, Matsui O, Takashima T, et al. Focal fatty change of the liver adjacent to the falciform ligament: CT and sonographic findings in five surgically confirmed cases. *Am J Roentgenol* 1987;149:491-4.
13. Creutzfeldt W, Frerichs H, Sickinger K. Liver diseases and diabetes mellitus. In: Popper H, Schaffner F, editors. *Progress in liver diseases*. New York: Grune & Stratton, 1970:371-407.
14. McGarry JD, Foster DW. Regulation of hepatic fatty acid oxidation and ketone body production. *Annu Rev Biochem* 1980;49:395-420.
15. Shojania NG, Hoog GR. Isolated liver nodules. *Gastroenterology* 1975;69:28-34.