



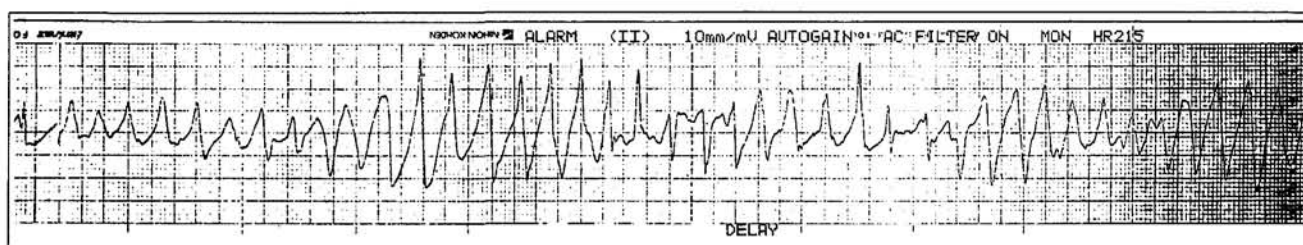
<b>Title</b>	<b>ECG Round</b>
<b>Author(s)</b>	<b>Wan, SH; Lau, CP</b>
<b>Citation</b>	<b>Hong Kong Practitioner, 1997, v. 19 n. 4, p. 203-206</b>
<b>Issued Date</b>	<b>1997</b>
<b>URL</b>	<b><a href="http://hdl.handle.net/10722/53409">http://hdl.handle.net/10722/53409</a></b>
<b>Rights</b>	<b>Creative Commons: Attribution 3.0 Hong Kong License</b>

# ECG ROUNDS

## Clinical History:

A 45-year-old hypertensive woman presented with syncope, diarrhoea and palpitations in the Accident and Emergency Department. The following ECG strip was obtained.

Figure 1



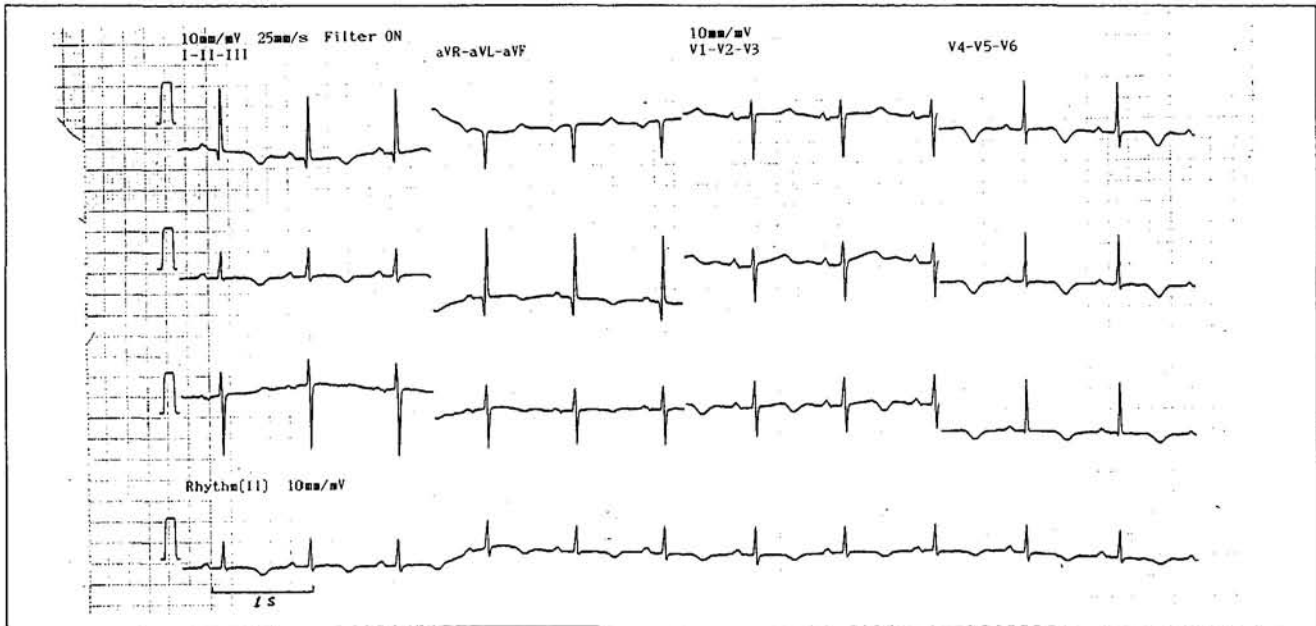
## Question 1: What was the diagnosis?

- A. Ventricular fibrillation
- B. Torsade de pointes (polymorphic ventricular tachycardia)
- C. Supraventricular tachycardia
- D. Monomorphic ventricular tachycardia

This ECG case was prepared by: **Dr. S. H. Wan**  
**Prof. C. P. Lau**

# ECG ROUNDS

**Figure 2**



**Answer : B. Torsade de pointes (polymorphic ventricular tachycardia)**

The ECG strip showed broad polymorphic QRS complexes compatible with ventricular tachycardia with the so called twisting of the axis appearance (torsade de pointes). The ventricular rate was around 200 per minute. This form of tachycardia usually tends to be rapid and produces symptoms of hypotension and may even degenerate into ventricular fibrillation. As the patient developed hypotension soon after the onset of this polymorphic ventricular tachycardia, external DC cardioversion was given. After the cardioversion, the above ECG strip was obtained (Figure 2).

**Question 2: What was the underlying rhythm?**

- A. Sinus bradycardia
- B. Prolonged QT interval
- C. Normal sinus rhythm
- D. Idioventricular rhythm

**Answer : B. Prolonged QT interval**

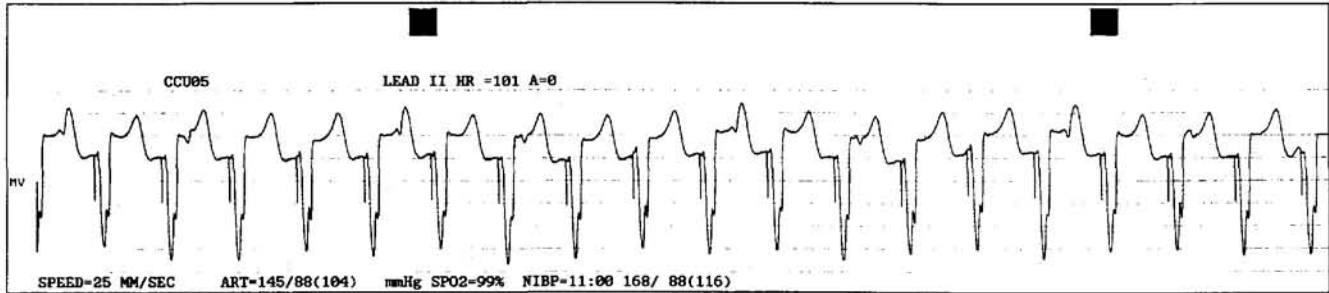
The ECG strip showed sinus rhythm of 70 per minute with a corrected QTc interval of 544 ms. There were also T wave inversions over leads I, II, aVL, aVF and lateral chest leads. As the patient had recurrent torsade de pointes, a temporary pacemaker was inserted and the ventricle was paced at a rate of 100 per minute. The ECG strip after the temporary pacing (VVI) was shown in Figure 3. Subsequent history taking reviewed that the patient was on diuretic treatment for her hypertension and blood investigation showed hypokalaemia of 2.4 mmol/l. Intravenous potassium replacement was commenced and the serum potassium level normalised after 2 days. The ECG showed gradual normalisation of the QTc interval and the temporary pacing was removed subsequently.

There are various causes of the acquired prolonged QT syndrome including antiarrhythmic agents, tricyclic antidepressants, electrolyte disturbances (see Table 1).<sup>1,2</sup> Terfenadine, a commonly used antihistamine for upper respiratory tract infection, has been described to cause torsade de pointes in conjunction with antimicrobials such as erythromycin and antifungal agents.<sup>3,4</sup> The main

(Continued on page 206)

# ECG ROUNDS

**Figure 3: ECG strip showing pacing artefacts followed by ventricular complexes of a VVI temporary entricular pacemaker at a pacing rate of 100 per minute**



**Table 1: Causes of acquired prolonged QT syndrome and torsade de pointes**

### Electrolyte disturbances

Hypokalaemia  
Hypomagnesaemia  
Hypocalcaemia

### Drugs

Antiarrhythmics: quinidine, procainamide,  
disopyramide, sotalol,  
amiodarone  
Tricyclic antidepressants: amitriptyline  
Phenothiazine  
Terfenadine, astemizole especially taken with  
erythromycin

### Poisons

Organophosphorous insecticide poisons

### Miscellaneous

Bradycardia  
Acute myocardial infarction  
Central nervous system diseases e.g. intracerebral  
haemorrhage

ECG findings are the prolonged QTc interval associated with pauses. Post-pause or post-ectopic T wave changes or U wave accentuation and ventricular bigeminy may also be seen.<sup>5</sup> The underlying mechanism for the occurrence of this polymorphic ventricular tachycardia appears to be due to early afterdepolarization (a form of triggered activity).

Treatment of this acquired long QT syndrome (LQTS) includes prompt withdrawal of the offending agent, replacement of electrolytes (e.g. potassium, calcium or magnesium) and intravenous infusion of isoprenaline or ventricular pacing to maintain a ventricular rate of >90 per minute. Interestingly, intravenous magnesium has been shown to be effective in suppressing drug induced torsade de pointes even in patients with a normal magnesium level.<sup>6</sup> ■

### References

1. Chan EMC, Lau CP. The Long QT Syndrome. *J HK Coll Cardiol*. 1995; 3: 5-12.
2. Roden DM. Torsade de pointes. *Clin Cardiol* 1993; 16: 683-686.
3. Honig PK, Woosley RL, Zamani K, et al. Changes in the pharmacokinetics and electrocardiographic pharmacodynamics of terfenadine with concomitant administration of erythromycin. *Clin Pharm Ther*. 1992; 52: 231-238.
4. Hanrahan JP, Choo PW, Carlson W, et al. Terfenadine-associated ventricular arrhythmias and QTc interval prolongation. A prospective cohort study comparison with other antihistamines among members of a health maintenance organization. *Ann Epidemiol*. 1995; 5: 201-209.
5. Jackman WM, Friday KJ, Anderson JL, et al. The long QT syndrome: a critical review, new clinical observations and a unifying hypothesis. *Prog Cardiovasc Dis* 1988; 31: 115-172.
6. Zivoni D, Keren A, Cohen AM, et al. Magnesium therapy for torsade de pointes. *Am J Cardiol* 1984; 53: 528-530.