



Title	Differential cytokine expression in EBV positive peripheral T cell lymphomas
Author(s)	Ho, JWY; Liang, RHS; Srivastava, G
Citation	Journal Of Clinical Pathology - Molecular Pathology, 1999, v. 52 n. 5, p. 269-274
Issued Date	1999
URL	http://hdl.handle.net/10722/53405
Rights	Journal of Clinical Pathology. Copyright © B M J Publishing Group.

Differential cytokine expression in EBV positive peripheral T cell lymphomas

J W Y Ho, R H S Liang, G Srivastava

Abstract

Aim—To investigate whether specific cytokines are secreted locally at the tumour site in Epstein-Barr virus (EBV) positive peripheral T cell lymphoma (PTCL).

Methods—An RNase protection assay system was used to study the differential expression of 21 cytokines in parallel in eight cases of EBV positive non-nasal PTCL, and compared with 11 EBV negative non-nasal PTCLs and three EBV positive nasal natural killer (NK) cell lymphomas.

Results—Among the eight EBV positive cases, interferon γ (IFN- γ), lymphotoxin β (LT β), interleukin 10 (IL-10), tumour necrosis factor α (TNF- α), transforming growth factor β 1 (TGF- β 1), and IL-1 receptor α (IL-1Ra) were frequently detectable. IL-15, IL-6, IL-4, IL-1 β , TNF- β , and IL-9 were sporadically detectable. Of the frequently detectable cytokines, IFN- γ and LT β were commonly detected in the EBV negative cases. For cases with > 50% EBV encoded small non-polyadenylated RNA (EBER) positive cells, IL-10, TNF- α , and TGF- β 1 were detected in three of three cases, and IL-1Ra in two of three cases. For cases with < 20% EBER positive cells, IL-10 was detected in three of five cases, TNF- α in two of four cases, but TGF- β 1 and IL-1Ra were not detected. Interestingly, IL-6 was detected in two of three cases with > 50% EBER positive cells, but only in one of five cases with < 20% EBER positive cells. For compari-

son, in NK cell lymphomas, IL-10, TNF- α , IL-1Ra, and IL-6 were all detectable, but TGF- β 1 was not detected at all. Immunohistochemical staining revealed IL-10 in many cells; in contrast, EBV latent membrane protein 1 (LMP1) was only found to be positive in isolated cells.

Conclusions—Certain cytokines, such as IL-10 and TNF- α , might be expressed preferentially in EBV positive peripheral T cell lymphomas. It is likely that such a cytokine environment enhances EBV infection and contributes towards tumorigenesis.

(J Clin Pathol: Mol Pathol 1999;52:269-274)

Keywords: cytokines; Epstein-Barr virus; peripheral T cell lymphomas

In primary nasal T/natural killer (NK) cell lymphomas, Epstein-Barr virus (EBV) is associated with 100% of cases,^{1,2} the virus exists as a single clonal episome, and is found in almost all tumour cells.² In non-nasal peripheral T cell lymphoma (PTCL), EBV is detected in only 52% of cases,³ the virus might be monoclonal or biclonal, and is found only in a proportion of atypical cells. EBV infection and cytokine expression are closely associated in B cells,⁴ and we speculate that specific cytokines are secreted locally in the tumour environment of EBV positive PTCLs.

In vitro studies on EBV infection suggest that viral survival in lymphoblastoid cells can be maintained largely by cytokine mediated autocrine loops.⁴ In vivo studies have shown that various cytokine genes can be upregulated in a number of EBV associated malignancies.⁵⁻⁸ Many cytokines are suspected to contribute towards the histological characteristics and clinical behaviour of tumours.⁹⁻¹⁴ Moreover, large numbers and variable amounts of cytokines are found in various malignant lymphomas.¹⁰⁻¹⁴

From the literature, it is clear that the expression of many cytokines is altered in peripheral T cell lymphomas. To date, however, the differential expression of a panel of cytokines in EBV positive peripheral T cell lymphomas has not been reported. Therefore, it is not clear whether EBV infection is associated with upregulation of cytokines in the microenvironment of PTCLs. We have examined cytokine expression in EBV positive non-nasal peripheral T cell lymphomas, compared with EBV negative non-nasal PTCLs, as well as with nasal NK cell lymphoma. The results obtained should give an insight into the factors influencing viral survival in the tumour environment of peripheral T cell lymphomas.

Department of Pathology, The University of Hong Kong, Hong Kong, The People's Republic of China

J W Y Ho
G Srivastava

Department of Medicine, The University of Hong Kong, Hong Kong, The People's Republic of China

R H S Liang

Correspondence to: Dr G Srivastava, Department of Pathology, University Pathology Building, Queen Mary Hospital Compound, Pokfulam Road, Hong Kong, The People's Republic of China.

email: sgopesh@hkucc.hku.hk

Accepted for publication 22 June 1999

Table 1 Peripheral T cell lymphoma (PTCL) and natural killer cell lymphoma (NL)

	PTCL		NL EBV positive
	EBV positive	EBV negative	
Frequently detectable cytokines			
IFN- γ	8/8	10/11	3/3
LT β	7/7	9/10	2/2
IL-10	6/8	5/11	3/3
TNF- α	5/7	5/10	2/2
TGF- β 1	4/7	9/10	0/2
IL-1Ra	4/8	9/11	2/2
Sporadically detectable cytokines			
IL-15	3/7	3/10	3/3
IL-6	3/8	5/10	3/3
IL-4	3/8	1/11	0/3
IL-1 β	2/8	4/10	0/2
TNF- β	0/7	4/10	0/2
IL-9	0/7	2/10	0/3

Frequently detectable cytokines are detected in 50% or more cases of Epstein-Barr virus (EBV) positive PTCLs.

Sporadically detectable cytokines are detected in less than 50% of cases of EBV positive PTCLs.

IFN- γ , interferon γ ; IL, interleukin; IL-1Ra, IL-1 receptor α ; LT β , lymphotoxin β ; TGF- β 1, transforming growth factor β 1; TNF, tumour necrosis factor.

Table 2 Summary of mRNA expression of EBER by ISH; LMP1 and EBNA2 by RT-PCR; and the detectable cytokines by RNase protection assay in Epstein-Barr virus (EBV) positive peripheral T cell lymphomas (PTCLs) of different subtypes

	1	2	3	4	5	6	7	8
Subtype	AIL	PL	MF	AIL	AIL	AIL	LEL	PL
EBER	>50%#	>50%	>50%	<20%*	<20%	<20%	<20%	<20%
LMP1	+	+	+	+	+	+	+	+
EBNA2	-	-	-	+	-	-	-	+
IFN- γ	+	+	+	+	+	+	+	+
LT β	+	+	+	+	+	+	+	ND
IL-10	+	+	+	+	+	+	-	-
TNF- α	+	+	+	-	-	+	+	ND
TGF- β 1	+	+	+	-	-	-	+	ND
IL-1Ra	-	+	+	+	-	-	-	+
IL-15	-	-	-	+	+	+	ND	-
IL-6	+	+	-	+	-	-	-	-
IL-4	-	-	-	-	+	+	+	-
IL-1 β	-	+	-	-	-	-	-	+

#EBER was positive in >50% of the atypical cells; *EBER was positive in <20% of the atypical cells.

AIL, angioimmunoblastic T cell lymphoma; EBER, EBV encoded small non-polyadenylated RNAs; EBNA2, EBV nuclear antigen 2; IFN- γ , interferon γ ; IL, interleukin; IL-1Ra, IL-1 receptor 1; ISH, in situ hybridisation; LEL, lymphoepithelioid lymphoma; LT β , lymphotoxin β ; MF, mycosis fungoides; ND, not determined; PL, pleomorphic medium size and large T cell lymphoma; RT-PCR, reverse transcription-polymerase chain reaction; TGF- β 1, transforming growth factor β 1; TNF- α , tumour necrosis factor α .

Materials and methods

The RNase protection assay (RPA) requires a large amount of snap frozen material from each case, but the biopsy samples were often very small, particularly those from the nasal cases. Sufficient frozen biopsy samples were available from eight cases of EBV positive non-nasal PTCL, 11 cases of EBV negative non-nasal PTCL, and three cases of EBV positive primary nasal NK cell lymphoma. Essentially, the 19 cases included five cases of angioimmunoblastic T cell lymphoma (AIL), two of Ki-1 large cell anaplastic T cell lymphoma (LCAL), two of lymphoepithelioid lymphoma (LEL), one of mycosis fungoides (MF), eight of pleomorphic medium size and large T cell lymphoma (PL), and one of T zone lymphoma (TZ). All biopsies were from the lymph node

except for one PL case from the intestine and two cases from skin (one MF and one PL). The eight EBV positive cases included four cases of AIL, two of PL, one of LEL, and one of MF. The 11 EBV negative cases consisted of one case of AIL, six of PL, two of LCAL, one of LEL, and one of TZ. All cases were selected from the files in the department of pathology, Queen Mary Hospital, Hong Kong. They were all diagnosed according to the updated Kiel classification.^{15 16} All patients were Chinese and had no apparent immunodeficiency.

The phenotypic profile for each case was established at the time of diagnosis.^{3 17} The tumour cells in all cases expressed at least one T cell or NK cell antigen and no B cell antigens. Genotyping¹⁸ to confirm T cell lineage was performed for the eight cases of EBV positive PTCL.³ Immunostaining for EBV latent membrane protein 1 (LMP1) and EBV nuclear antigen 2 (EBNA2) using monoclonal antibodies CS.1-4 and PE2, respectively, was performed on 6 μ m frozen sections, as described previously.¹⁹ Immunostaining for interleukin 10 (IL-10) using goat polyclonal antibody (R&D, Minneapolis, MN, USA) was performed on 6 μ m frozen sections using the LSAB+ kit (Dako, Glostrup, Denmark), according to the manufacturer's instructions.

In situ hybridisation (ISH) for EBV encoded small non-polyadenylated RNA (EBER) was performed using the EBV-ISH kit from Dako, as reported previously.³

Total RNA was extracted from frozen tissues of each case and the control cell lines by the acid guanidinium thiocyanate/phenol/chloroform method.²⁰ For the detection of LMP1 and EBNA2 mRNA expression, reverse transcription-polymerase chain reaction (RT-PCR) followed by Southern blot hybridisation

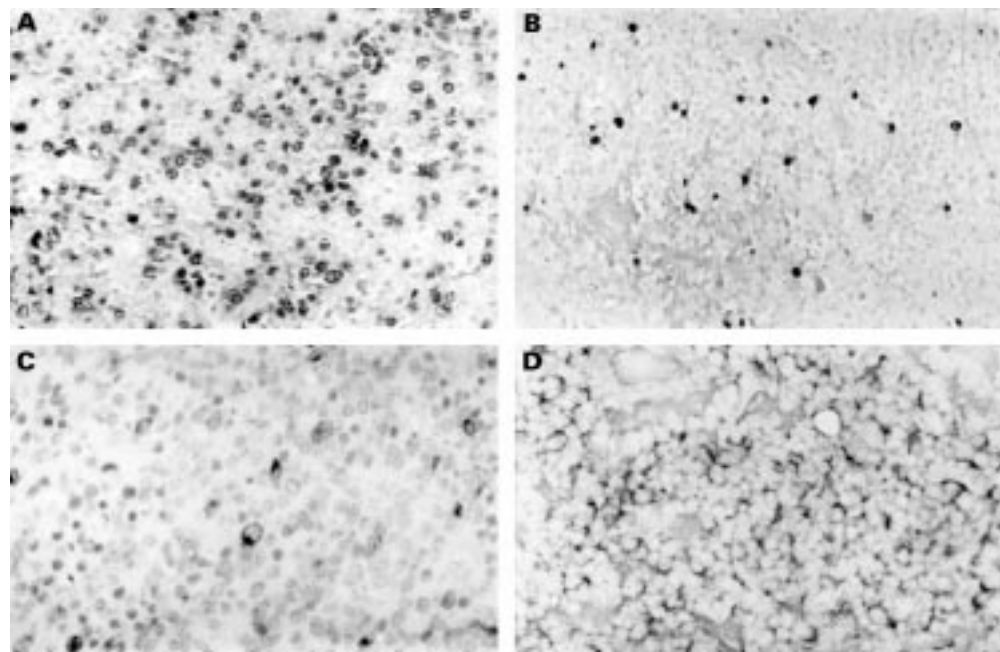


Figure 1 Detection of Epstein-Barr virus (EBV) encoded small non-polyadenylated RNA (EBER) 1 and 2 by in situ hybridisation (ISH) using a fluorescein isothiocyanate (FITC) labelled probe. (A) EBER was positive in ~ 50% of atypical cells including blast like cells. (B) EBER was only positive in a subpopulation (up to 20%) of atypical cells including blast like cells. (C) LMP1 protein was positive in isolated cells. (D) Interleukin 10 (IL-10) protein was positive in many cells showing cytoplasmic staining.

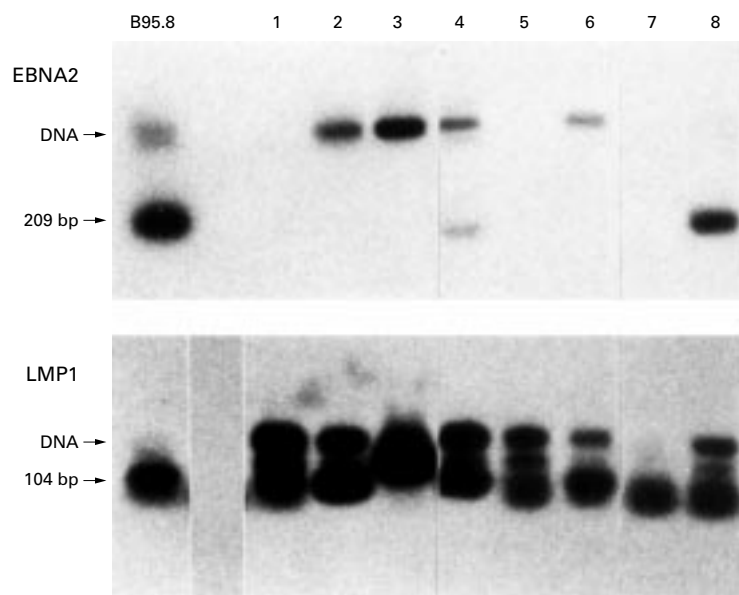


Figure 2 Epstein-Barr virus (EBV) nuclear antigen 2 (EBNA2) and EBV latent membrane protein 1 (LMP1) mRNA expression analysis for the eight EBV positive peripheral T cell lymphomas (PTCLs) by reverse transcription-polymerase chain reaction (RT-PCR) followed by Southern blot hybridisation. Whereas EBNA2 mRNA was detected in cases 3 and 8 only, LMP1 mRNA was detected in all eight cases. The B95.8 cell line was used as a positive control.

was carried out as described previously.¹⁹ The primers and probes used have also been described previously.¹⁹

Three template sets were used for RPA (PharMingen, San Diego, USA). Each set contains DNA templates that can be used for the T7 polymerase directed synthesis of ³²P labelled antisense RNA probes that can in turn hybridise with target human mRNA encoding IL-5, IL-4, IL-10, IL-14, IL-15, IL-9, IL-2, IL-13, and interferon γ (IFN- γ) (hCK-1); IL-12p35, IL-12p40, IL-10, IL-1 α , IL-1 β , IL-1 receptor a (IL-1Ra), IL-6, and IFN- γ (hCK-2); TNF- β , lymphotoxin β (LT β), tumour necrosis factor α (TNF- α), IFN- γ , IFN- β , transforming growth factor β 3 (TGF- β 3), TGF- β 2, and TGF- β 1 (hCK-3). These assays were carried out essentially according to the manufacturer's instructions.

Results

Table 1 summarises the expression of the cytokines. Table 2 summarises the histological subtypes, expression of EBV, and cytokine gene transcripts for the eight EBV positive cases. Among the eight EBV positive cases, three cases showed > 50% EBER positive cells (fig

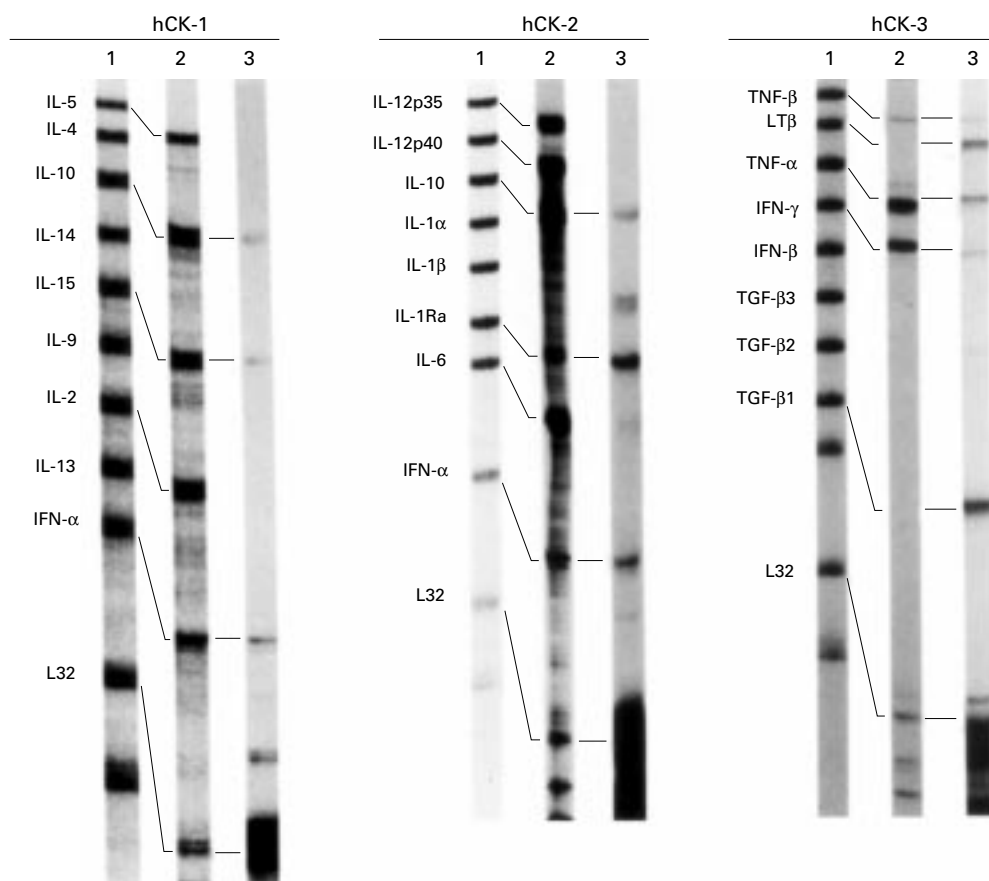


Figure 3 Multiprobe RNase protection assay for the detection of cytokines using hCK-1, hCK-2, and hCK-3 probe sets. Lane 1 shows the unprotected probe sets. Lane 2 shows the corresponding RNase protected probes after hybridisation with the total RNA (2 μ g; provided by PharMingen) as positive control. Lane 3 shows the corresponding RNase protected probes after hybridisation with total RNA (5 μ g) from a case of Epstein-Barr virus (EBV) positive angioimmunoblastic T cell lymphoma (AIL). The negative control using yeast tRNA (2 μ g) is not shown. Note that each probe band (lane 1) migrates more slowly than its protected bands (lanes 2 and 3); this is the result of flanking sequences in the probe that are not protected by mRNA. Because of the differences in the expression of different cytokines, the exposure time for each lane varied, resulting also in variations in the intensity of the housekeeping gene L32. The undigested probe sets were also loaded (typically 1000–2000 counts/minute/lane) as markers. IFN, interferon; IL, interleukin; IL-1Ra, IL-1 receptor; LT β , lymphotoxin β ; TGF, transforming growth factor; TNF; tumour necrosis factor.

Table 3 Expression of LMP1, EBNA2, and IL-10 (as measured by immunohistochemistry) in Epstein-Barr virus (EBV) positive peripheral T cell lymphomas

	1	2	3	4	5	6	7	8
Subtype	AIL	PL	MF	AIL	AIL	AIL	LEL	PL
LMP1	+	+	+	+	+	+	-	+
EBNA2	-	-	-	-	-	-	-	-
IL-10	+	+	+	+	-	+	-	-

AIL, angioimmunoblastic T cell lymphoma; EBNA2, EBV nuclear antigen 2; IL-10, interleukin 10; LEL, lymphoepithelioid lymphoma; MF, mycosis fungoides; PL, pleomorphic medium size and large T cell lymphoma.

1A) and five cases showed < 20% EBER positive cells (fig 1B). The three nasal cases showed EBER positive cells in more than 70% of the atypical cells. All eight cases showed LMP1 mRNA expression, and two cases showed EBNA2 mRNA expression (fig 2). However, using immunohistochemical staining, LMP1 was detected only in isolated cells (fig 1C), and EBNA2 was not detected at all.

Figure 3 illustrates the results obtained from the RPA system. Each set of RPA analysis requires a minimum of 5 µg of total RNA, so that each analysis could only be repeated once because of the limited amounts of tissue available for our study. The x ray film was given maximum exposure to avoid underdetection. Our aim was to identify the presence or absence of the cytokines in the tumour environment. Overall, 12 of 21 cytokines showed detectable levels of expression. Nine of 21 cytokines, namely IL-5, IL-14, IL-2, IL-12p35, IL-12p40, IL-1α, IFN-β, TGF-β3, and TGF-β2 were not detected by RPA; either their expression level was below the detection limit or they were not expressed.

NON-NASAL PTCL

Frequently detectable cytokines

As shown in Tables 1 and 2, irrespective of the presence of EBV, IFN-γ and LTβ were detectable in almost all cases. In cases with > 50% EBER positive cells, IL-10, TNF-α, and TGF-β1 were uniformly detectable (three of three cases), and IL-1Ra was frequently detectable (two of three cases). In cases with < 20% EBER positive cells, only IL-10 was preferentially detectable (three of five cases). Overall, IL-10 and TNF-α were marginally more frequently detected in EBV positive cases compared with EBV negative cases. At the cellular level, the IL-10 protein was detected by immunohistochemistry in the cytoplasm of many cells (fig 1D). Table 3 compares the production of the IL-10 protein with the EBV proteins, namely LMP1 and EBNA2.

Sparadically detectable cytokines

These cytokines are listed in table 1. However, in cases with > 50% EBER positive cells, IL-6 was frequently detectable (two of three cases). In contrast, in cases with < 20% EBER positive cells, IL-6 was rarely detectable (table 2). In EBV negative cases, most of these cytokines were detected sporadically (table 1).

NK CELL LYMPHOMA

IFN-γ, LTβ, IL-10, TNF-α, IL-1Ra, IL-15, and IL-6 were detectable in every tested case of EBV positive NK cell lymphoma. In PTCL

cases with > 50% EBER positive cells, TGF-β1 was not detected at all, whereas IL-6 and IL-1Ra were detected in all cases.

Discussion

The study of cytokine expression by means of RPA indicated that cytokines can be differentiated into two sets: those cytokines that are associated directly with the presence of EBV and those that are not.

Irrespective of EBV infection, IFN-γ and LTβ were commonly detectable in all cases. Together with most of the sporadically detectable cytokines, namely IL-15, IL-4, IL-1β, TNF-β, and IL-9 (table 1), these cytokines do not correlate specifically with EBV infection. Instead, the expression of many of these cytokines correlated well with the tumour entities.^{12 21-23}

TGF-β1 was detectable in all three cases with > 50% EBER positive cells. This potent immunosuppressive agent has been detected before in the tumour cells of PTCLs,²⁴ but no reference was made to the presence of EBV. Its absence in other EBV positive PTCLs and all three cases of EBV positive NK cell lymphoma suggest that this cytokine might not play a direct and primary role in EBV infection. However, it might have a cooperative role in PTCLs that harbour high numbers of EBV.^{25 26} Similarly, IL-1Ra and IL-6 were detectable in two of three cases with > 50% EBER positive cells. Unlike TGF-β1, they were detectable in every cases of EBV positive NK cell lymphoma tested. Such a correlation suggests that these two cytokines are associated only indirectly with both T and NK cell tumours that harbour high numbers of EBV.²⁷

Others have reported IL-10 expression in PTCLs to be subtype specific rather than associated with EBV²⁸; our result did not show the same trend. Among the six frequently detectable cytokines, IL-10 and TNF-α showed marginal preferential expression in the eight EBV positive PTCLs. They were also detected in all cases of EBV positive NK cell lymphoma. These two cytokines did not appear to be lymphoma subtype specific.

IL-10 is a pleiotropic cytokine. It is a potent immunosuppressor of cytotoxic T cells and a costimulator of B cell growth. Presented to NK cells, IL-10 is found to mediate IL-2 induced NK production of IFN-γ.²⁹ IL-10 has been associated with many EBV associated malignancies, such as Hodgkin's disease and Burkitt's lymphoma, in which it is thought to mediate immunosuppression in the microenvironment.^{7 8}

EBV gene transcript studies of the eight cases revealed that only isolated cells were LMP1 positive, irrespective of the percentage of EBER infected cells, indicating mixed latency I and II EBV positive cells. The detection of EBNA2 at the mRNA level, but not at the protein level, suggests that there might be rare latency III cells in the tumour cell population of the two cases. Therefore, the latency pattern appears to be similar to that of EBV positive NK cell lymphoma, the EBV gene expression pattern of which has been studied

previously.¹⁹ In contrast to the isolated detection of LMP1 positive cells, immunostaining revealed, at the cellular level, that many cells stained positive for IL-10, irrespective of the percentage of EBV positive cells. The percentage of IL-10 positive cells did not appear to correlate with the percentage of EBV positive cells. In vitro studies on B cell lines suggest that IL-10 expression might be transactivated by LMP1,³⁰ but this has not been studied in T cell lines or T cell tumours; therefore, the effect of EBV proteins and IL-10 on each other in T cells is not clear. We suspect that IL-10 was already present in the tumour environment upon viral infection, but further studies are needed to clarify whether or not EBV had a sustaining or enhancing effect on IL-10 expression. Moreover, our results indicate that there is no correlation between IL-10 and EBNA2 expression. However, this also needs to be clarified further in future in vitro studies.

Comparing the two immunosuppressive agents, TGF- β 1 was detected more frequently in EBV negative cases, whereas IL-10 was detected more often in EBV positive cases. Interestingly, in cases with > 50% EBV positive cells, both IL-10 and TGF- β 1 were expressed. In contrast, in the highly EBV associated NK cell lymphoma, IL-10 was detectable, but TGF- β 1 was not (table 1). Thus, EBV infection correlates with IL-10 expression both in non-nasal PTCL and NK cell lymphoma, and local immunosuppression in EBV positive cases might be the result of IL-10 rather than TGF- β 1 expression. The coexpression of TGF- β 1 and IL-10 is unique in cases with > 50% EBV positive cells, so their effect on immunosuppression in those cases will require further study.

TNF- α is also a pleiotropic cytokine, and it can be produced by B and T cells, as well as NK cells. EBV infection of B cells promotes its expression,⁸ and it has been detected in EBV positive B immunoblasts in ALLD cases.³¹ Recent studies have shown that EBV positive T cells also upregulate TNF- α expression.⁶ Furthermore, EBV selectively upregulated TNF- α expression over IFN- γ and IL-1 α .⁶ TNF- α and TNF- β are known to be functionally redundant cytokines in many aspects. Interestingly, our study shows that in the EBV negative cases, the frequency of detection of TNF- α and TNF- β was similar. In EBV positive cases, however, there was a preferential upregulation of TNF- α and downregulation of TNF- β (table 1). In comparison, TNF- α is also detected selectively in EBV positive NK cell lymphoma. This is interesting because in normal NK cells, upregulation of TNF- α induced apoptosis.³²

In summary, among the 21 cytokines studied, we noted a trend for the preferential expression of IL-10 and TNF- α in EBV positive non-nasal PTCL. This finding correlates strongly with a similar survey on EBV immortalized B cell lines.⁴ Thus, in EBV positive non-nasal PTCL, the strongest candidates associated directly with EBV infection are IL-10 and TNF- α . Furthermore, at the cellular level, as shown by protein staining, the detection of more IL-10 positive cells com-

pared with EBER and LMP1 suggests that such cytokine environments might enhance EBV infection and contribute towards tumorigenesis.

Presented in part at the 8th International EBV Symposium, July 1998, Stockholm, Sweden. Supported by the Research Grants Council of the Hong Kong Special Administrative Region, The People's Republic of China; Contract grant number: HKU 7299/98M. We thank Professor FCS Ho and Dr ACL Chan for their evaluation of the cases used for this study, and Mr KS Lau for his photographic assistance.

- 1 Ho FCS, Srivastava G, Loke SL, *et al.* Presence of Epstein-Barr virus DNA in nasal lymphomas of B and "T" cell type. *Hematol Oncol* 1990;8:271-81.
- 2 Tao Q, Ho FCS, Loke SL, *et al.* Epstein-Barr virus is localised in the tumour cells of nasal lymphomas of NK, T or B cell type. *Int J Cancer* 1995;60:315-20.
- 3 Ho JWY, Ho FCS, Chan ACL, *et al.* Frequent detection of Epstein-Barr virus infected B cells in peripheral T-cell lymphomas. *J Pathol* 1998;185:79-85.
- 4 Rochford R, Cannon MJ, Sabbe RE, *et al.* Common and idiosyncratic patterns of cytokine gene expression by Epstein-Barr virus transformed human B cell lines. *Viral Immunol* 1997;10:183-95.
- 5 Foss HD, Herbst H, Hummel M, *et al.* Patterns of cytokine gene expression in infectious mononucleosis. *Blood* 1994;83:707-12.
- 6 Lay JD, Tsao CJ, Chen JY, *et al.* Upregulation of tumor necrosis factor-alpha gene by Epstein-Barr virus and activation of macrophages in Epstein-Barr virus-infected T cells in the pathogenesis of hemophagocytic syndrome. *J Clin Invest* 1997;100:1969-79.
- 7 Herbst H, Foss HD, Samol J, *et al.* Frequent expression of interleukin-10 by Epstein-Barr virus-harboring tumor cells of Hodgkin's disease. *Blood* 1996;87:2918-29.
- 8 Klein SC, Kube D, Abts H, *et al.* Promotion of IL8, IL10, TNF alpha and TNF beta production by EBV infection. *Leuk Res* 1996;20:633-6.
- 9 Hsu S-M, Waldron JA, Fink L, *et al.* Pathogenic significance of interleukin-6 in angioimmunoblastic lymphadenopathy-type T-cell lymphoma. *Hum Pathol* 1993;24:125-31.
- 10 Hsu S-M, Waldron JW, Jr, Hsu P-L, *et al.* Cytokines in malignant lymphomas: review and prospective evaluation. *Hum Pathol* 1993;24:1040-57.
- 11 Sappino A-P, Seelentag W, Pelte M-F, *et al.* Tumor necrosis factor/cachectin and lymphotoxin gene expression in lymph nodes from lymphoma patients. *Blood* 1990;75:958-62.
- 12 Kato H, Nagasaka T, Ichikawa A, *et al.* Tumor necrosis factor- β gene expression and its relationship to the clinical features and its histopathogenesis of peripheral T-cell lymphomas. *Leuk Lymphoma* 1994;16:125-33.
- 13 Shin SS, Traweck ST, Ulich TR. Expression of interleukin-1 receptor antagonist protein in malignant lymphomas: an immunohistochemical study. *Arch Pathol Lab Med* 1995;119:247-51.
- 14 Merz H, Filedner A, Orscheschek K, *et al.* Cytokine expression in T-cell lymphomas and Hodgkin's disease: its possible implication in autocrine or paracrine production as a potential basis for neoplastic growth. *Am J Pathol* 1991;139:1173-80.
- 15 Suchi T, Lennert K, Tu L-Y, *et al.* Histopathology and immunohistochemistry of peripheral T cell lymphomas: a proposal for their classification. *J Clin Pathol* 1987;40:995-1015.
- 16 Lennert K, Feller AC. *Histopathology of non-Hodgkin's lymphomas (based on the updated Kiel classification)*, 2nd ed. Berlin: Springer, 1992.
- 17 Chan ACL, Ho JWY, Chiang AKS, *et al.* Phenotypic and cytotoxic characteristics of peripheral T-cell and NK-cell lymphomas in relation to Epstein-Barr virus association. *Histopathology* 1999;34:16-24.
- 18 Cossman J, Uppenkamp M, Sundeen J, *et al.* Molecular genetics and the diagnosis of lymphoma. *Arch Pathol Lab Med* 1988;112:117-27.
- 19 Chiang AK, Tao Q, Srivastava G, *et al.* Nasal NK- and T-cell lymphomas share the same type of Epstein-Barr virus latency as nasopharyngeal carcinoma and Hodgkin's disease. *Int J Cancer* 1996;68:285-90.
- 20 Chomczynski P, Sacchi N. Single-step method of RNA isolation by acid guanidinium thiocyanate-phenol-chloroform extraction. *Anal Biochem* 1987;162:156-9.
- 21 Raziuddin S, Abu-Eshy S, Sheikha A. Peripheral T-cell lymphomas: immunoregulatory cytokine (interleukin-2, interleukin-4, and interferon-gamma) abnormalities and autologous mixed lymphocyte reaction. *Cancer* 1994;74:2843-9.
- 22 Saed G, Fivenson DP, Naidu Y, *et al.* Mycosis fungoides exhibits a Th1-type cell-mediated cytokine profile whereas Sezary syndrome expresses a Th2-type profile. *J Invest Dermatol* 1994;103:29-33.
- 23 Merz H, Houssiau FA, Orscheschek K, *et al.* Interleukin-9 expression in human malignant lymphomas: unique association with Hodgkin's disease and large cell anaplastic lymphoma. *Blood* 1991;78:1311-17.
- 24 Su I-J, Kadin ME. Expression of growth factor/receptor genes in postthymic T cell malignancies. *Am J Pathol* 1989;135:439-45.

- 25 Ahmad A, Menezes J. Binding of the Epstein-Barr virus to human platelets causes the release of transforming growth factor-beta. *J Immunol* 1997;159:3984-8.
- 26 Altiok A, Jadersten M, Magyarlaki T, *et al*. Biphasic effect of transforming growth factor-beta on Epstein-Barr virus-induced activation of human tonsillar B cells. *Immunol Lett* 1994;40:111-15.
- 27 Herbst H, Samol J, Foss HD, *et al*. Modulation of interleukin-6 expression on Hodgkin and Reed-Sternberg cells by Epstein-Barr virus. *J Pathol* 1997;182:299-306.
- 28 Boulland ML, Meignin V, Leroy-Viard K, *et al*. Human interleukin-10 expression in T/natural killer-cell lymphomas: association with anaplastic large cell lymphomas and nasal natural killer-cell lymphomas. *Am J Pathol* 1998;153:1229-37.
- 29 Carson WE, Lindemann MJ, Baiocchi R, *et al*. The function characterization of interleukin-10 receptor expression on human natural killer cells. *Blood* 1995;85:3577-85.
- 30 Nakagomi H, Dolcetti R, Bejarano MT, *et al*. The Epstein-Barr virus latent membrane protein-1 (LMP1) induces interleukin-10 production in Burkitt lymphoma lines. *Int J Cancer* 1994;57:240-4.
- 31 Foss HD, Anagnostopoulos I, Herbst H, *et al*. Patterns of cytokine gene expression in peripheral T-cell lymphoma of angioimmunoblastic lymphadenopathy type. *Blood* 1995;85:2862-9.
- 32 Ross ME, Caligiuri MA. Cytokine-induced apoptosis of human natural killer cells identifies a novel mechanism to regulate the innate immune response. *Blood* 1997;89:910-18.

Journal of Clinical Pathology - <http://www.molpath.com>

Visitors to the world wide web can now access the *Journal of Clinical Pathology* either through the BMJ Publishing Group's home page (<http://www.bmjpg.com>) or directly by using its individual URL (<http://www.molpath.com>). There they will find the following:

- Current contents list for the journal
- Contents lists of previous issues
- Members of the editorial board
- Information for subscribers
- Instructions for authors
- Details of reprint services.

A hotlink gives access to:

- BMJ Publishing Group home page
- British Medical Association web site
- Online books catalogue
- BMJ Publishing Group books.

The web site is at a preliminary stage and there are plans to develop it into a more sophisticated site. Suggestions from visitors about features they would like to see are welcomed. They can be left via the opening page of the BMJ Publishing Group site or, alternatively, via the journal page, through "about this site".