



Title	Outcome for Hong Kong residents undergoing cadaveric liver transplantation in mainland China
Author(s)	Wong, ACC; Lo, CM; Liu, CL
Citation	Hong Kong Medical Journal, 2003, v. 9 n. 3, p. 165-170
Issued Date	2003
URL	http://hdl.handle.net/10722/45422
Rights	Creative Commons: Attribution 3.0 Hong Kong License

ACC Wong 黃昭灼
CM Lo 盧寵茂
CL Liu 廖子良

Outcome for Hong Kong residents undergoing cadaveric liver transplantation in mainland China

香港病人在內地接受屍肝移植的結果

Objective. To review the outcome for Hong Kong residents undergoing cadaveric liver transplantation in mainland China.

Design. Retrospective study.

Setting. Liver Transplant Centre, university teaching hospital, Hong Kong.

Subjects and methods. A retrospective review of medical records was undertaken for patients at Queen Mary Hospital who underwent cadaveric liver transplantation in China between 1 January 1997 and 31 December 2001.

Results. Fifteen patients from Queen Mary Hospital underwent cadaveric liver transplantation in China during the study period. Eleven were men and four were women. Their mean age was 51 years. Disease indications included hepatitis B-related liver cirrhosis (n=7), hepatitis B-related liver cirrhosis with hepatocellular carcinoma (n=5), hepatitis C-related liver cirrhosis (n=1), hepatitis C-related liver cirrhosis with hepatocellular carcinoma (n=1), and polycystic liver and kidney disease (n=1). Nine patients were already waiting for liver transplantation at Queen Mary Hospital, and two of the nine patients were on the 'urgent' list. The overall survival rate was 80.0% at 6 months and 73.3% at 12 months. There were four (27%) deaths, two of which occurred in China. Of the 11 surviving patients, nine (82%) developed complications. Nineteen complications were seen in the 13 patients who were managed in Hong Kong following their return from China. Infective and biliary complications accounted for 58% and 26% of complications, respectively. Major complications necessitated prolonged hospitalisation for four patients and two required further laparotomy.

Conclusion. Although cadaveric liver transplantation in China is an option for Hong Kong residents, patients and clinicians should be aware of the possible outcomes and resource implications.

目的：總結香港病人在內地接受屍肝移植的結果。

設計：回顧性研究。

安排：大學教學醫院的肝移植中心，香港。

患者與方法：回顧瑪麗醫院的病人在1997年1月1日至2001年12月31日期間，返內地接受屍肝移植的紀錄。

結果：研究期間，瑪麗醫院共有15名病人返內地接受屍肝移植；其中11名為男性，4名為女性；平均年齡為51歲。病因包括乙型肝炎肝硬化(n=7)，乙型肝炎肝硬化合併肝癌(n=5)，丙型肝炎肝硬化(n=1)，丙型肝炎肝硬化合併肝癌(n=1)，和多囊肝及多囊腎(n=1)。9名病人原已被安排於瑪麗醫院輪候肝移植，其中2名高危病人獲優先輪候。病人的六個月及十二個月的總存活率分別為80.0%及73.3%。15名病人中有4人(27%)死亡，當中2人在內地醫院死亡。其餘的11名病人中，9人(82%)出現併發症。13名回港的病人共出現19宗併發症。當中58%為感染性併發症，26%為膽道併發症。4名病人患上嚴重併發症而需要延長住院治療，其中2人更需再次接受手術。

結論：儘管內地的屍肝移植能為香港病人提供另一種治療選擇，病人和醫護人員應注意其術後結果及病人返港接受跟進時的資源運用。

Introduction

Liver transplantation is the most effective treatment for end-stage liver diseases and selected primary hepatic malignancies. Due to the prevalence of hepatitis B

Key words:

China;
Liver transplantation;
Postoperative complications

關鍵詞：

中國；
肝移植；
術後併發症

Hong Kong Med J 2003;9:165-70

Liver Transplant Centre, Department of Surgery and Centre for the Study of Liver Disease, University of Hong Kong Medical Centre, Queen Mary Hospital, Pokfulam Road, Hong Kong

ACC Wong, MB, BS, FRCS (Edin)
CM Lo, MS, FHKAM (Surgery)
CL Liu, MS, FHKAM (Surgery)

Correspondence to: Prof CM Lo

and Chinese religious and cultural traditions, however, the availability of cadaveric donor organs is seriously restricted, thus limiting its wide application in Hong Kong and other Asian countries. At Queen Mary Hospital (QMH), the average waiting time for a cadaveric graft is between 18 and 24 months. For those patients who are on the 'urgent' waiting list, only 10% receive a cadaveric liver transplant within 7 days of listing.¹ There is significant mortality during the waiting period. Living donor liver transplantation has been developed to relieve the organ shortage, both for elective and urgent cases.² With the use of living donors as an alternate source of organs, the number of liver transplantations at QMH has significantly increased in recent years. Living donor liver transplantation accounts for more than 70% of liver transplants to date. More than 50% of transplant candidates do not have a living donor, however.³ The number of cadaveric liver transplantations undertaken in mainland China has been increasing in recent years,⁴⁻⁶ and this treatment is also available to patients from Hong Kong, with a much shorter waiting time but at a cost. Thus, the option of going to China for cadaveric liver transplantation has become attractive for a number of patients. Despite the cost of the operation, the main concern with this choice is the uncertainty regarding the results. The purpose of this study was to evaluate the operative outcome for patients from Hong Kong who undergo cadaveric liver transplantation in mainland China.

Subjects and methods

The hospital records of 15 QMH patients who had liver transplantation in hospitals in China between 1 January 1997 and 31 December 2001 were retrospectively reviewed. Nine (60%) of the 15 patients were waiting for liver transplantation at QMH before receiving liver transplantation in China. During the same period, 144 adult liver transplants were performed at QMH using 63 cadaveric and 81 living donor grafts.

Of the nine patients who had been waiting at QMH, eight were men and one was a woman, with a mean age of 52 years (range, 41-65 years). All patients were evaluated and accepted for liver transplantation according to a standard protocol. The indications for liver transplantation were hepatitis B-related liver cirrhosis (n=4), hepatitis B-related liver cirrhosis with hepatocellular carcinoma (n=3), and acute-on-chronic hepatitis B (n=2). Two patients had been in the Intensive Care Unit and on the 'urgent' waiting list at QMH prior to travelling to China for transplantation. The duration from joining the waiting list at QMH to transplantation in China ranged from 2 weeks to 6 months (median, 1 month). The two patients on the 'urgent' waiting list had family members who had volunteered to be living donors but both were considered unsuitable—one was considered psychologically unfit, and the other was a chronic carrier of the hepatitis B surface antigen. All nine patients who went to China for liver transplantation did so on a voluntary basis. It is hospital policy not to refer patients to China for consideration of liver transplantation.

Of the six patients who were not waiting for liver transplantation at QMH, three were men and three were women. The mean age was 51 years (range, 41-63 years). Two patients had hepatitis B-related liver cirrhosis with hepatocellular carcinoma, one had hepatitis C-related liver cirrhosis with hepatocellular carcinoma, one had hepatitis B-related liver cirrhosis, one had hepatitis C-related liver cirrhosis, and one had polycystic disease of the liver and kidneys. Five of the six patients had been evaluated but were not accepted for future liver transplantation at QMH due to contra-indications (three patients had advanced hepatocellular carcinoma), lack of an appropriate indication (one patient with polycystic disease), and patient refusal (one patient with hepatitis C-related liver cirrhosis). The remaining patient with hepatitis B-related liver cirrhosis had not been seen at QMH before undergoing liver transplantation in China.

All patients were admitted to QMH when they returned to Hong Kong after cadaveric liver transplantation in China, and available information provided by the hospitals in China was reviewed. Full assessments were performed, including history, physical examination, blood tests (complete blood count, clotting profile, liver and renal function tests, blood glucose level, hepatitis status, and blood level of immunosuppressants), chest X-ray, and cholangiography if a T-tube was in situ. The type and dosage of immunosuppressants were reviewed and adjusted according to the current immunosuppression protocol, consisting of a double regimen of a steroid and tacrolimus. The steroid was rapidly tapered off with the aim of tacrolimus monotherapy 6 months after transplantation. Lamivudine 100 mg daily prophylaxis was used to prevent recurrent hepatitis B.

Results

The details of patient demographics, disease indications, relevant dates (including time on the waiting list and date of transplantation), duration of follow-up, mortality and morbidity, and current status are reported in Tables 1 and 2.

The mean duration of follow-up was 9 months (range, <1 month to 21 months). The survival rates were 80.0% at 6 months and 73.3% at 12 months. Two (13.3%) patients (patients 1 and 2) who were on the list for urgent transplantation died soon after transplantation during hospital stay in China. The cause of death was unknown. One patient (patient 10) who had hepatitis C-related liver cirrhosis and hepatocellular carcinoma developed recurrent disease with bilateral pulmonary metastases and died in Hong Kong 8 months after liver transplantation. Another patient (patient 3) who had hepatitis B-related liver cirrhosis and hepatocellular carcinoma had re-activation of hepatitis B and died of liver failure and sepsis 4 months after transplantation.

The hospital stay at QMH for the 13 patients who returned from mainland China ranged from 4 to 103 days (mean, 41.6 days; median, 24 days). Four patients

Table 1. Summary patient data for 15 Hong Kong residents who underwent cadaveric liver transplantation in mainland China

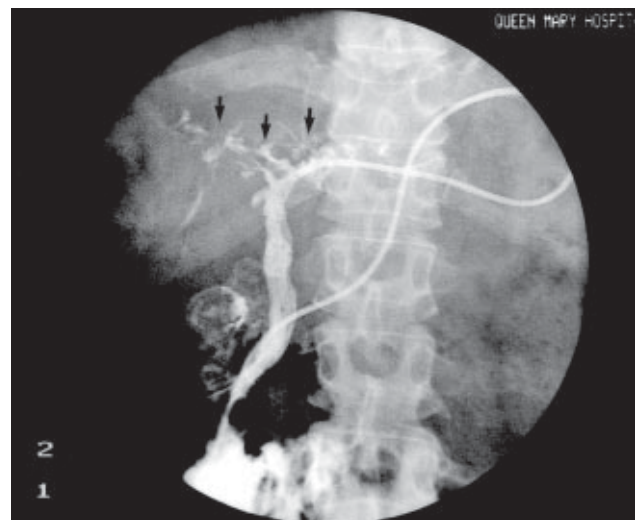
Patient No.	Sex/age (years)	Disease indication	Date of initial placement on the waiting list at Queen Mary Hospital	Date of cadaveric liver transplantation in China	Hospital stay in Hong Kong (days)	Duration of follow-up (months)	Current patient status
1	M/51	Hepatitis B cirrhosis with acute decompensation	Mar 99	Apr 99	-	<1	Died (in hospital, China)
2	M/41	Hepatitis B cirrhosis with acute decompensation	Mar 99	Apr 99	-	<1	Died (in hospital, China)
3	M/63	Hepatitis B cirrhosis, hepatocellular carcinoma	Sep 00	Sep 00	4	4	Died (recurrent hepatitis B)
4	F/53	Hepatitis B cirrhosis, hepatocellular carcinoma	Jun 00	Dec 00	13	12	Alive
5	M/65	Hepatitis B cirrhosis	Jan 01	Feb 01	103	11	Alive, pending re-transplantation
6	M/47	Hepatitis B cirrhosis	Apr 01	Jun 01	27	8	Alive
7	M/44	Hepatitis B cirrhosis	Nov 00	Aug 01	17	8	Alive
8	M/46	Hepatitis B cirrhosis	Jul 01	Sep 01	18	5	Alive
9	M/54	Hepatitis B cirrhosis, hepatocellular carcinoma	Sep 01	Oct 01	103	3	Alive
10	F/57	Hepatitis C cirrhosis, hepatocellular carcinoma	Not applicable	Jun 98	96	8	Died (recurrent hepatocellular carcinoma)
11	F/47	Polycystic disease of the liver and kidneys	Not applicable	Jun 00 (combined liver and kidney)	11	19	Alive
12	M/49	Hepatitis B cirrhosis, hepatocellular carcinoma	Not applicable	Sep 00	72	18	Alive
13	M/41	Hepatitis B cirrhosis, hepatocellular carcinoma	Not applicable	Mar 01	24	9	Alive
14	F/63	Hepatitis C cirrhosis	Not applicable	Sep 01	23	5	Alive
15	M/43	Hepatitis B cirrhosis	Not applicable	Apr 00	30	21	Alive

Table 2. Morbidity in 15 Hong Kong residents following cadaveric liver transplantation in mainland China

Type of morbidity	No. of patients
Diffuse biliary stricture	3
Biliary leakage	2
Ruptured hepatic artery pseudoaneurysm	1
Segmental portal vein thrombosis	1
Duodenal perforation	1
Recurrent hepatitis B	3
De novo hepatitis B	1
De novo hepatitis C	2
Nosocomial pneumonia	2
Intra-abdominal abscess	1
Aspergillus paracolic abscess with enterocutaneous fistula	1
Yeast abscess of the palm	1

developed major complications that necessitated prolonged hospital stay (patients 5, 9, 10, and 12), and two required repeat laparotomy. Patient 9, who had hepatitis B cirrhosis with hepatocellular carcinoma, developed methicillin-resistant *Staphylococcus aureus* and enterococcus peritonitis 2 weeks after transplantation, and laparotomy and peritoneal lavage were performed in China. The patient was subsequently transferred to Hong Kong approximately 6 weeks after transplantation, and had a further complication of a ruptured hepatic artery pseudoaneurysm. Laparotomy was performed, which showed multiple intra-abdominal abscesses eroding the hepatic artery and duodenum, leading to duodenal perforation and bile leakage. This patient also developed nosocomial pneumonia after surgery, requiring temporary tracheostomy and mechanical ventilation, with 28 days respiratory support in the Intensive Care Unit. Patient 12, who had hepatitis B cirrhosis with hepatocellular

carcinoma, developed massive gastrointestinal bleeding from liver and paracolic abscesses caused by aspergillus. These necessitated laparotomy, colectomy, ileostomy, and drainage of the abscesses. Patient 5, who had hepatitis B-related liver cirrhosis, developed diffuse ischaemic biliary stricture and biloma formation after transplantation, which required percutaneous transhepatic biliary drainage (PTBD) [Fig]. The patient was repeatedly admitted to QMH due to PTBD blockage requiring flushing and revision under radiological guidance. The patient is currently waiting for repeat transplantation. Patient 10, who had hepatitis C cirrhosis with hepatocellular carcinoma, developed methicillin-resistant *S*

**Fig. Percutaneous transhepatic cholangiogram of patient 5 shows features of diffuse ischaemic biliary stricture (arrows)**

aureus pneumonia requiring mechanical ventilation. This patient subsequently developed recurrent hepatocellular carcinoma with persistent left pleural effusion and a right lung hilar mass, and died 8 months after transplantation.

Of the 11 patients alive 3 to 21 months after liver transplantation, nine (82%) developed complications. There were 19 complications among 13 patients who returned to Hong Kong. Two of these patients died from complications (patients 3 and 10). Infective complications accounted for 58%, and the remaining 42% were surgical complications. For infective complications, 55% were viral, 27% were bacterial, and 18% were fungal. Patient 11, who had polycystic disease and was hepatitis B surface antigen-negative before transplantation, had de novo hepatitis B after transplantation. Patient 15, who had hepatitis B cirrhosis, developed recurrent hepatitis B as well as de novo hepatitis C after cadaveric liver transplantation. There were two cases of nosocomial pneumonia requiring mechanical ventilation (patients 9 and 10), and one instance of intra-abdominal, pyogenic abscess requiring laparotomy for drainage (patient 9). Patient 12, who had aspergillus liver and paracolic abscesses, developed adhesions and an enterocutaneous fistula after initial laparotomy. This patient subsequently underwent two further operations. Patient 5 developed an invasive yeast infection over the palm, requiring surgical excision and a 9-month course of oral fluconazole. This patient can only undergo re-transplantation once the fungal infection is completely eradicated. Of the surgical complications, biliary causes accounted for 63%, while 37% were vascular complications. Three patients had ischaemic bile duct strictures. This was defined as a non-anastomotic intrahepatic biliary lesion with either two or more sites of stricture formation and/or biliary dilatation, or multiple intrahepatic fluid collections or abscesses.⁷ Hepatic artery patency was confirmed by percutaneous Doppler ultrasound. Biliary leakage was demonstrated on T-tube cholangiography. Hepatic artery pseudoaneurysm with rupture was diagnosed during laparotomy for patient 9, who had intra-abdominal pyogenic abscess. Segmental portal vein thrombosis was demonstrated on computed tomographic scan of the liver and confirmed with liver biopsy for patient 4.

Discussion

Although liver transplantation is the most effective treatment for end-stage liver diseases, it is a highly sophisticated procedure, and is associated with significant morbidity and mortality. Complications that occur after liver transplantation also have a significant impact on resource utilisation and costs.⁸

This study has reported the outcome for 15 patients who received cadaveric liver transplantation in mainland China. There were two hospital deaths, and a further two patients died 4 and 10 months after transplantation. The patient survival rate was 80% at 6 months and 73.3% at 12 months, while 82% had complications. Patients electing to travel to

mainland China for liver transplantation may represent a selected group of high-risk patients. Two of the patients were urgent candidates for liver transplantation and required intensive care before they were transferred to China for liver transplantation. Hence, it is not appropriate to view the outcomes for these 15 patients as representative of the results achieved with liver transplantation in China overall. Unfortunately, publications in China are not well-indexed in the international literature and, until recently, few papers concerning liver transplantation in China had been published.⁴⁻⁶ It is therefore difficult to access data on a large case series of liver transplantation as a comparative standard.

Advanced hepatocellular carcinoma is a contraindication for liver transplantation because of the high risk of recurrence. For selected patients with a small hepatocellular carcinoma that is not resectable because of location or underlying cirrhosis, a 5-year survival rate of approximately 70% can be achieved after liver transplantation, however. At QMH, liver transplantation for hepatocellular carcinoma is restricted to patients with no more than three tumour nodules of 5 cm or less, in the absence of macroscopic vascular permeation.⁹⁻¹¹ The two patients (patients 10 and 12) with hepatocellular carcinoma and liver cirrhosis were not selected for liver transplantation due to the large size of the primary tumour. For benign liver disease, liver transplantation is considered at QMH only if the disease has progressed to its terminal stage and there is no alternative treatment available. The patient with polycystic disease of the liver and kidney was not listed for transplantation, as the liver and renal function were satisfactory, and she was not debilitated by the hepatomegaly. These patients highlight differences in selection criteria for transplantation between QMH and hospitals in China.

After transplantation in mainland China, the recipients returned to Hong Kong for follow-up care. The information accompanying them was not always comprehensive. Information regarding the status of the donor and the pathology of the explanted liver, which are crucial for subsequent management and follow-up, and for indicating possible complications, were often missing. This added to difficulties in the clinical management of this group of patients.

In this series, infection accounted for 58% of all complications. Most infections occurring in the first month were bacterial or fungal and were related to the surgical procedure. These included intra-abdominal infections, cholangitis, pneumonia, urinary tract infection, wound infection, and catheter-related sepsis. Both recurrent and de novo hepatitis were common in this group of patients. Recurrence of hepatitis B virus is associated with reduced patient and graft survival rates. The major risk factor for graft hepatitis B infection is pre-transplantation of hepatitis B, with the risk of recurrence greatest in patients whose hepatitis B-DNA was positive at the time of transplantation.¹² Current strategies for prophylaxis against graft hepatitis B include using hepatitis B immunoglobulin to

bind and clear hepatitis B surface antigen-positive viral particles,¹³ and using nucleoside analogues to inhibit hepatitis B viral replication. Lamivudine monotherapy is highly effective for preventing recurrent hepatitis B.¹⁴

With regard to the two patients who developed de novo hepatitis B and C, we suspect that the donor liver grafts might have carried the virus, or that the patients were given excess immunosuppressive therapy in the early post-operative period. The assessment of the cadaveric liver graft preoperatively is of the utmost importance to ensure transmission of hepatitis does not occur. Transmission of hepatitis through the transfusion of blood products is a further possibility in the absence of rigorous blood screening.

Surgical complications accounted for 42% of the remaining complications, with biliary complications comprising the majority. Biliary complications are a continuing concern in liver transplantation, occurring in 8% to 15% of cases, with a mortality rate of 10%.¹⁵ Diffuse biliary stricture—occurring in three of the patients in this series (patients 5, 8, and 13)—can be due to ischaemia from hepatic artery thrombosis, extended graft preservation time and warm ischaemic time, and ABO incompatibility and rejection.¹⁶ It is likely that the occurrence of diffuse ischaemic bile duct stricture in these cases was due to warm ischaemic injury to the donor liver during harvesting, as all hepatic arteries in these three patients were patent on Doppler ultrasound. Information on the process of donor liver graft preservation, and cold and warm ischaemic time during these patients' procedures was not available. Diffuse ischaemic bile duct stricture triggers the need for re-transplantation. Bile leakage around the T-tube or after its removal is related to inadequate development of the fibrous tract along the course of the T-tube tract, probably caused by impairment of fibrogenesis under steroid immunosuppression.¹⁷

Hepatic artery pseudoaneurysms are rare (0.2%-0.9%) complications of liver transplantation. They usually occur at sites of anastomosis and are often infected, causing rupture and fatal haemorrhage, making early diagnosis and treatment imperative.¹⁸ In the absence of infection, resection and primary anastomosis or reconstruction with an interposition graft can be performed. However, if there is evidence of infection, as for patient 9, resection and ligation are mandatory even though re-transplantation may ultimately be required.¹⁹

Patients from Hong Kong travel to mainland China for liver transplantation to bypass the long waiting time for a cadaveric graft and the lack of voluntary living liver donors in Hong Kong. Despite the increase in cadaveric liver donors as a result of public education and maximal use of marginal donors during the past decade,³ the donor rate has remained low overall at less than three per million population per year. Although innovative techniques for living donor liver transplantation have also expanded the donor pool, more than 50% of transplant candidates do not have

a living donor.¹ There are other measures to recruit more donor livers but only limited success has been achieved to date. Regional sharing of organs²⁰ has a limited role in Asia as most transplant centres are short of organs and do not have any surplus for sharing. Although split-liver transplantation offers an attractive concept of transplanting two patients with one donor liver,²¹ the logistical difficulties of mounting two simultaneous transplants and the associated resource constraints seriously limit its wide application in Hong Kong at this time.

A substantial amount of hospital resources and manpower were utilised in the treatment of Hong Kong residents who returned from China after cadaveric liver transplantation seeking management of complications and subsequent follow-up. It is inappropriate to make generalisations based only on the outcome for the 15 patients reviewed. Patients who decide to seek treatment in China should be aware of the potential risks they may encounter, however. Clinicians considering referral of patients to China for consideration of cadaveric liver transplantation should also be aware of the potential risks, as well as the resource implications of appropriate patient follow-up on their return to Hong Kong.

Conclusion

Liver transplantation is a complex procedure, with significant morbidity and mortality. The scarcity of cadaveric liver grafts in Hong Kong currently limits its wide application. Cadaveric liver transplantation in mainland China is an option for some patients, affording a shorter waiting time for treatment. This review suggests the outcome may not be favourable for a variety of reasons, including patient status prior to surgery. Furthermore, it should be noted that patients may utilise substantial hospital resources and manpower on returning to Hong Kong for further management of complications.

References

1. Lo CM, Fan ST, Liu CL, et al. Applicability of living donor liver transplantation to high-urgency patients. *Transplantation* 1999;67:73-7.
2. Lo CM, Fan ST, Liu CL, et al. Adult-to-adult living donor liver transplantation using extended right lobe grafts. *Ann Surg* 1997;226:261-70.
3. Lo CM, Fan ST, Liu CL, et al. Ten-year experience with liver transplantation at Queen Mary Hospital: retrospective study. *Hong Kong Med J* 2002;8:240-4.
4. Peng S. Improving the level of liver transplantation in China [in Chinese]. *Zhonghua Yi Xue Za Zhi* 2001;81:1089-90.
5. Chen S, Qiu F. Progress in the study of organ transplantation in China [in Chinese]. *Zhonghua Yi Xue Za Zhi* 1998;78:912-3.
6. Xia SS. Organ transplantation in China: retrospect and prospect. *Chin Med J (Engl)* 1992;105:430-2.
7. Li S, Stratta RJ, Langnas AN, Wood RP, Marujo W, Shaw BW Jr. Diffuse biliary tract injury after orthotopic liver transplantation. *Am J Surg* 1992;164:536-40.
8. Brown RS Jr, Ascher NL, Lake JR, et al. The impact of surgical complications after liver transplantation on resource utilization. *Arch Surg* 1997;132:1098-103.

9. Mazzaferro V, Regalia E, Doci R, et al. Liver transplantation for the treatment of small hepatocellular carcinomas in patients with cirrhosis. *N Engl J Med* 1996;334:693-9.
10. Figueras J, Ibanez L, Ramos E, et al. Selection criteria for liver transplantation in early-stage hepatocellular carcinoma with cirrhosis: results of a multicenter study. *Liver Transpl* 2001;7:877-83.
11. Llovet JM, Bruix J, Fuster J, et al. Liver transplantation for small hepatocellular carcinoma: the tumor-node-metastasis classification does not have prognostic power. *Hepatology* 1998;27:1572-7.
12. Samuel D, Muller R, Alexander G, et al. Liver transplantation in European patients with the hepatitis B surface antigen. *N Engl J Med* 1993;329:1842-7.
13. McGory RW, Ishitani MB, Oliveira WM, et al. Improved outcome of orthotopic liver transplantation for chronic hepatitis B cirrhosis with aggressive passive immunization. *Transplantation* 1996;61:1358-64.
14. Lo CM, Cheung ST, Lai CL, et al. Liver transplantation in Asian patients with chronic hepatitis B using lamivudine prophylaxis. *Ann Surg* 2001;233:276-81.
15. O'Connor TP, Lewis WD, Jenkins RL. Biliary tract complications after liver transplantation. *Arch Surg* 1995;130:312-7.
16. Sanchez-Urdazpal L, Gores GJ, Ward EM, et al. Diagnostic features and clinical outcome of ischemic-type biliary complications after liver transplantation. *Hepatology* 1993;17:605-9.
17. Shuhart MC, Kowdley KV, McVicar JP, et al. Predictors of bile leaks after T-tube removal in orthotopic liver transplant recipients. *Liver Transpl Surg* 1998;4:62-70.
18. Madariaga J, Tzakis A, Zajko AB, et al. Hepatic artery pseudoaneurysm ligation after orthotopic liver transplantation—a report of 7 cases. *Transplantation* 1992;54:824-8.
19. Tobben PJ, Zajko AB, Sumkin JH, et al. Pseudoaneurysms complicating organ transplantation: roles of CT, duplex sonography, and angiography. *Radiology* 1988;169:65-70.
20. de Villa VH, Chen CL, Chen YS, et al. Internal sharing of split liver grafts in Asia: initial experience. *Clin Transplant* 2000;14:355-9.
21. Bismuth H, Morino M, Castaing D, et al. Emergency orthotopic liver transplantation in two patients using one donor liver. *Br J Surg* 1989;76:722-4.