



<b>Title</b>	<b>Laparoscopic incisional hernioplasty utilising on-lay expanded polytetrafluoroethylene DualMesh: Prospective study</b>
<b>Author(s)</b>	<b>Lau, H; Patil, NG; Yuen, WK; Lee, F</b>
<b>Citation</b>	<b>Hong Kong Medical Journal, 2002, v. 8 n. 6, p. 413-417</b>
<b>Issued Date</b>	<b>2002</b>
<b>URL</b>	<b><a href="http://hdl.handle.net/10722/45416">http://hdl.handle.net/10722/45416</a></b>
<b>Rights</b>	<b>Creative Commons: Attribution 3.0 Hong Kong License</b>

H Lau 劉 雄  
 NG Patil 彭 達  
 WK Yuen 袁維基  
 F Lee 李燦榮

# Laparoscopic incisional hernioplasty utilising on-lay expanded polytetrafluoroethylene DualMesh: prospective study

## 應用高嵌體伸展聚四氟乙烯二元網的腹腔鏡切口疝根治術：預期研究

**Objective.** To evaluate the early outcomes of laparoscopic incisional hernioplasties using on-lay GORE-TEX DualMesh.

**Design.** Prospective study.

**Setting.** Medical centre of a regional hospital, Hong Kong.

**Subjects and methods.** Between June 2000 and October 2001, 11 consecutive patients underwent attempted laparoscopic incisional hernioplasties at the University of Hong Kong Medical Centre. A prospective collection of peri-operative data and assessment of postoperative outcomes was performed.

**Results.** Laparoscopic incisional hernioplasty was successfully performed for 10 (91%) patients. One patient was converted to open repair because of extensive adhesions within the peritoneal cavity. The overall mean operative time was 107 minutes. Five (45%) patients were found to have more than one hernial defect after reduction of the hernial contents. Eight (73%) patients were discharged within 2 days after operation. Postoperative morbidities included wound bruising (n=4), seroma (n=2), and prolonged suture site pain (n=1). All postoperative morbidities resolved spontaneously without intervention. With a mean follow-up of 3 months, no early recurrence was detected.

**Conclusion.** Early outcomes of laparoscopic incisional hernioplasty utilising GORE-TEX DualMesh were promising. This technique confers the advantages of minimal access surgery and allows clear identification of multiple hernial defects. Extensive adhesion, which does not allow the establishment of pneumoperitoneum, is a condition that precludes the safe performance of laparoscopic repair.

### Key words:

Hernia, ventral;  
 Laparoscopy;  
 Polytetrafluoroethylene;  
 Surgical mesh

### 關鍵詞：

腹部疝氣；  
 腹腔鏡檢查；  
 聚四氟乙烯；  
 外科手術網

Hong Kong Med J 2002;8:413-7

Department of Surgery, University of Hong Kong Medical Centre, Tung Wah Hospital, 12 Po Yan Street, Sheung Wan, Hong Kong

H Lau, FRACS, FHKAM (Surgery)  
 NG Patil, FRCS (Edin), FHKAM (Surgery)  
 WK Yuen, FRACS, FHKAM (Surgery)  
 F Lee, FRACS, FHKAM (Surgery)

Correspondence to: Dr H Lau

**目的：**評估應用高嵌體 GORE-TEX 二元網腹腔鏡切口疝根治術的早期結果。

**設計：**預期研究。

**安排：**香港地區醫院的外科中心。

**患者與方法：**2000年6月至2001年10月期間，在香港大學外科中心嘗試進行腹腔鏡切口疝根治術的連續11名患者。進行了手術前後數據的預期收集和術後結果的評估。

**結果：**10名患者(91%)成功進行腹腔鏡切口疝根治術，另1名患者因腹腔廣泛粘連而轉為進行開放式修補。手術平均時間為107分鐘。5名(45%)患者在腹腔鏡檢查時發現有一個以上的疝缺口。8名患者(73%)在手術後2天內出院。術後的併發症包括傷口瘀傷(n=4)、血清腫(n=2)、及長期縫合點疼痛(n=1)。所有術後併發症都自然消失。在平均3個月的跟進期內，並未發現早期復發的病例。

**結論：**從早期結果看，應用高嵌體 GORE-TEX 二元網的腹腔鏡切口疝根治術的結果十分理想。它的優點包括手術切口小，以及可清楚辨認多重的疝氣缺口。但腹腔廣泛粘連的情況會妨礙建立氣腹，因而影響使用腹腔鏡檢查修補的安全性。

## Introduction

The incidence of incisional hernia after abdominal operations varies from 5% to 11%.<sup>1-3</sup> Repair of incisional hernia has been a challenging surgical problem for many years. The operative technique of open repair has evolved from simple approximation of the defect, which is associated with a high incidence of recurrence, to prosthetic repair.<sup>4,5</sup> Mesh hernioplasty of incisional hernia has been shown to achieve a superior long-term outcome.<sup>5</sup> The placement of prosthetic mesh, however, requires extensive dissection of the hernia and thus increases the risk of wound complications.

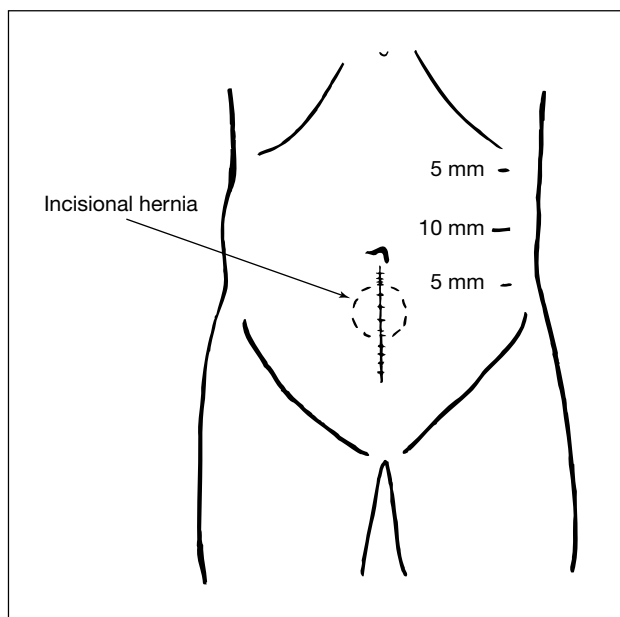
LeBlanc and Booth<sup>6</sup> first described the laparoscopic repair of incisional hernia with an on-lay patch in 1993. Laparoscopic incisional hernioplasty has been gaining popularity in recent years.<sup>7</sup> With the laparoscopic approach, long incisions and wide dissections can be avoided. The placement of a large mesh with adequate overlap of the defect is also facilitated. This study reports the early outcomes of laparoscopic incisional hernioplasties utilising on-lay GORE-TEX DualMesh Biomaterial (W.L. Gore and Associates, Flagstaff, US) performed at Tung Wah Hospital, Hong Kong.

## Subjects and methods

Between June 2000 and October 2001, 11 consecutive patients underwent attempted laparoscopic incisional hernia repairs with an on-lay GORE-TEX DualMesh at the University of Hong Kong Medical Centre, Tung Wah Hospital. Selection criteria for laparoscopic incisional hernioplasty included medical fitness for general anaesthesia and absence of coagulopathy. A prospective collection of data on demographic features, co-morbidities, and anatomical positions of hernial defects was performed. Operative details, including operative duration, intra-operative complications, and number of conversions of the procedure, were documented. Postoperative outcomes, including complications, pain scores, and length of hospital stay, were prospectively evaluated.

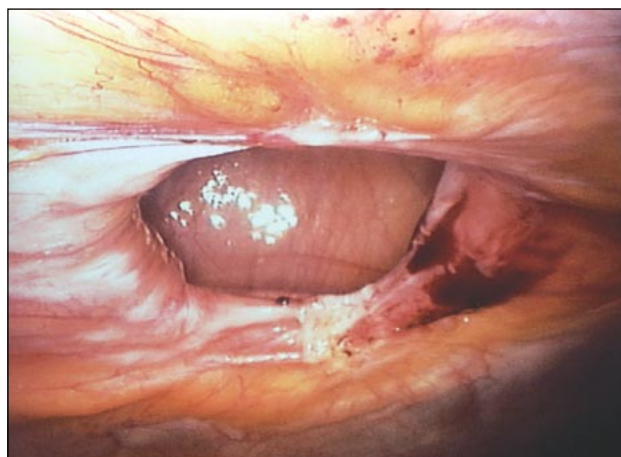
### Operative techniques

The patient was operated in a supine position using general anaesthesia. For patients with midline incisional hernias, the first 10-mm trocar was placed over the left anterior axillary line midway between the costal margin and the anterior superior iliac spine via an open cut-down technique (Fig 1). Pneumoperitoneum was created by insufflation with carbon dioxide until a pressure of 12 mm Hg was reached. A 30° telescope was introduced for diagnostic laparoscopy. Two additional 5-mm trocars were placed over the left upper and left lower quadrants of the abdomen. The number and position of the trocars were individualised, depending on the anatomical position of the hernial defect and the location of adhesions. Lysis of adhesions was performed using endo-scissors with diathermy. The contents of the hernia were then reduced into the peritoneal cavity. The



**Fig 1. Position of the three trocar ports in a patient with lower midline incisional hernia**

edges of the hernia defect were ascertained by direct vision and palpation (Fig 2). The location of the hernia was marked on the abdomen and the dimensions of the hernial defect were measured (Fig 3). A GORE-TEX DualMesh was cut to a size that would overlap the defect by at least 3 cm in all directions. Non-absorbable sutures were placed and tied at 5-cm intervals along the edge of the mesh. The sutures were cut to leave two tails, each at least 10 cm long. The mesh was then inserted into the peritoneal cavity. Multiple stab skin incisions of 2 mm in length were made with a scalpel along the circumference of the mesh, which had been marked on the abdominal wall. A Gore Suture Passer Instrument (W.L. Gore and Associates, Flagstaff, US) was inserted through the abdominal wall into the peritoneal cavity. This was used to grasp the sutures of the mesh under direct vision and pull them through the abdominal wall. The sutures were then tied extra-corporeally and buried subcutaneously. The gaps between the sutures were closed by helical tackers at 1-cm intervals along the circumference of the mesh to avoid bowel obstruction (Fig 4).



**Fig 2. Incisional hernial defect after reduction of contents**

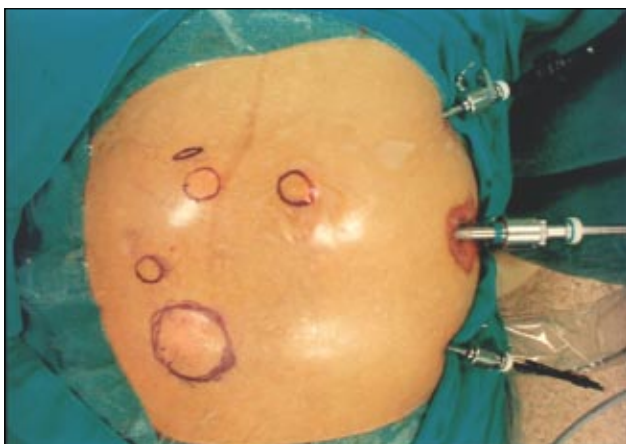

Fig 3. A patient with five hernial defects marked on the abdomen

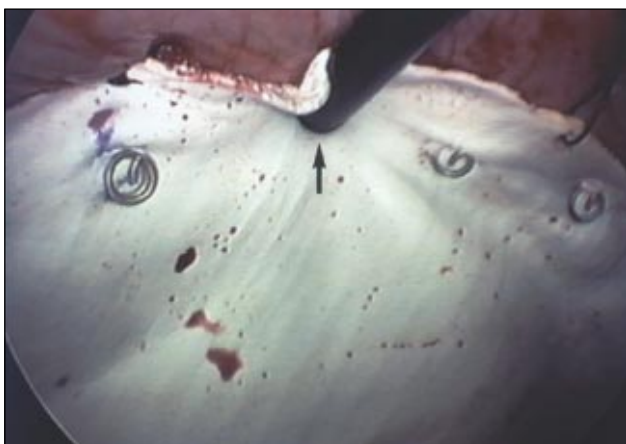


Fig 4. A GORE-TEX DualMesh being anchored in place by a spiral tacker (arrow)

### Postoperative management

All patients were allowed to resume normal diet and ambulate after operation. The analgesic regimen included oral diclofenac 100 mg daily and compound analgesic, propoxyphene 50 mg and paracetamol 325 mg, four times daily upon request. Severity of pain at rest and on coughing was assessed by a linear analogue pain score on a scale from 0 to 10 daily after operation. Patients were discharged once they could walk comfortably. Length of hospital stay referred to the total number of nights spent in hospital after operation. All patients had regular follow-up visits at the Hernia Clinic. All complications were recorded and any clinical recurrence was documented during follow-up visits.

## Results

### Patient characteristics

The ages of the study population ranged from 32 to 81 years with a mean age of 66 years (standard deviation [SD], 12.8 years). There were four males and seven females. The patients had one or more of the following co-morbidities: hypertension (n=7), ischaemic heart disease (n=3), diabetes mellitus (n=1), hypothyroidism (n=1), and asthma (n=1). Previous operations leading to the development of incisional hernia included hysterectomy (n=3), caesarean section (n=2), splenectomy (n=1), cholecystectomy with drainage of liver

abscess (n=1), resection of gastric stromal tumour (n=1), appendectomy (n=1), abdominal aortic aneurysmorrhaphy (n=1), and repair of para-umbilical hernia (n=1). The anatomical positions of the incisional hernias were along the lower midline incision (n=5), central midline incision (n=3), grid-iron incision (n=1), rooftop incision (n=1), and transverse infra-umbilical incision (n=1).

### Operative results

Laparoscopic incisional hernioplasty was successfully performed for 10 patients, giving an overall success rate of 91%. One patient was converted to open repair because of extensive adhesions within the peritoneal cavity. Operative time ranged from 68 to 190 minutes, with a mean of 107 minutes (SD, 42 minutes). The number of hernial defects found during operation ranged from one to five, with an average of two defects per patient. The diameters of the hernial defects varied from 1 to 10 cm, with a mean diameter of 3.2 cm. There were no visceral or other intra-operative complications.

### Postoperative outcomes

Postoperative morbidities included wound bruising (n=4), seroma (n=2), and prolonged suture site pain (n=1). One patient, who underwent laparoscopic repair of a 10-cm incisional hernia, complained of severe abdominal pain on postoperative day 1. Contrast computed tomography scan of the abdomen revealed a seroma. The patient recovered uneventfully. Prolonged suture site pain, which occurred in one patient, gradually resolved after 6 weeks.

The length of hospital stay ranged from 1 to 12 days, with a mean of 3 days. Eight (73%) patients were discharged within 2 days after operation. Figure 5 shows the mean postoperative pain scores at rest and on coughing. All postoperative morbidities resolved spontaneously without intervention. The follow-up period was calculated from the date of operation and ranged from 1 to 15 months with a mean of 3 months. No recurrence had been detected up to the day of review.

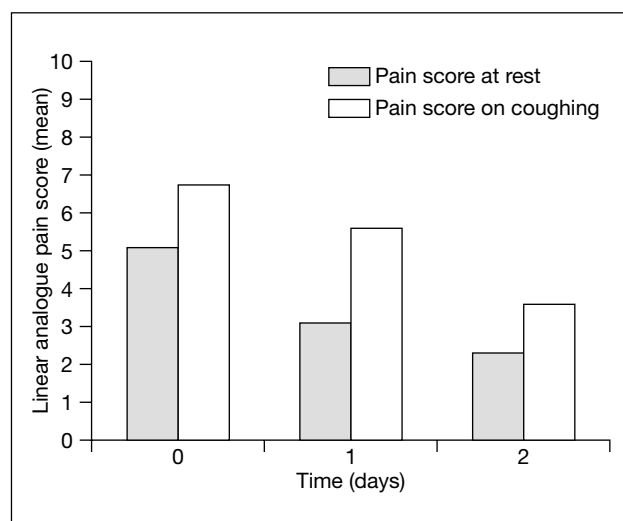


Fig 5. Daily postoperative pain scores at rest and on coughing

## Discussion

Leber et al<sup>8</sup> demonstrated that the nature of prosthetic material had significant implications on the long-term complications after prosthetic repair of incisional hernias. Biomaterials such as polypropylene and mersilene elicit intense inflammatory reaction and cause adhesive bowel obstruction when exposed to abdominal viscera. These materials also predispose patients to future development of enterocutaneous fistulae.<sup>9</sup> The utilisation of expanded polytetrafluoroethylene (PTFE) mesh has significantly reduced the risk of these complications as expanded PTFE evokes a limited inflammatory and foreign body response.<sup>10,11</sup> GORE-TEX DualMesh has a visceral surface with a pore size of less than 3 µm that minimises adhesion formation. The opposite parietal surface has an average pore size of 22 µm, which allows host tissue to incorporate into the mesh. In a number of animal studies in which different prosthetic materials were placed intra-abdominally, far greater adhesions were associated with polypropylene mesh than with expanded PTFE mesh.<sup>12,13</sup> Placement of expanded PTFE mesh in the intraperitoneal position has been proven to be safe.<sup>14</sup>

To date, no prospective randomised trial has been conducted to compare the outcomes of laparoscopic hernioplasty and open mesh repair of incisional hernia. A few retrospective studies demonstrated superior outcomes of laparoscopic hernioplasty to open repair of incisional hernia.<sup>15-17</sup> The reported advantages of the laparoscopic approach included shorter hospital stay, reduced wound pain, early return of bowel function, and faster resumption of normal activities.<sup>18-21</sup> As laparoscopic hernioplasty involves smaller skin incisions and less extensive dissection, the wound complication rate is lower than that with open repairs. The laparoscopic approach also allows clear identification of bowel contents, thereby reducing the risk of bowel injury.

The recurrence rate after laparoscopic repair was universally lower than those of open repairs.<sup>19</sup> The improved recurrence rate for patients undergoing laparoscopy has been attributed to the tension-free repair and the wide coverage beyond the border of the hernia defect by the sizeable mesh. Since the mesh is placed in the intraperitoneal position, it acts as an additional buttress to the repair. Above all, the laparoscopic technique allows clear identification of multiple hernial defects from the intra-abdominal perspective. Half of the patients (n=5) in this study were found to have more than one fascial defect during operation. Multiple defects, particularly the small ones far away from the main hernia, can be easily overlooked during open surgery. This may account for the higher recurrence rate following open repairs.

Our single incidence of conversion to open repair occurred in a patient with extensive adhesions within the peritoneal space. This patient underwent an exploratory laparotomy for abdominal pain 4 years previously. Extensive adhesion, which does not allow the establishment of pneumoperitoneum, has been reported to be a condition that

does not allow the safe performance of laparoscopic incisional hernioplasty.<sup>20</sup> Lysis of adhesions is the most hazardous step of the laparoscopic incisional hernia repair.<sup>15</sup> Inadvertent enterotomy with resultant contamination of the peritoneal cavity will necessitate abandonment of the hernia repair. Fatal sepsis secondary to delayed treatment of unrecognised enterotomy has been reported.<sup>22</sup> Adhesiolysis therefore needs to be performed with extreme caution and minimal use of diathermy.

Postoperative pain after laparoscopic incisional hernioplasty was greater than that reported for endoscopic inguinal hernioplasties.<sup>23</sup> LeBlanc<sup>24</sup> and Costanza et al<sup>20</sup> also reported similar findings. In general, patients who undergo laparoscopic incisional hernioplasty experience more discomfort than with laparoscopic cholecystectomy. The increased pain is probably due to the placement of transabdominal sutures and the helical tackers. Prolonged suture site pain occurred in up to 2% of patients after laparoscopic ventral hernia repair. Possible causes include nerve or tissue entrapment, deep-seated haematoma, and nerve injury during placement of helical tackers or transabdominal sutures. The pain can usually be controlled by oral analgesics and resolves with time.<sup>18</sup>

Seroma was the most frequently reported morbidity following laparoscopic incisional hernioplasty. Toy et al<sup>25</sup> reported an incidence of 16%, which was consistent with our experience (20%). The risk of seroma formation, however, remained lower than that after open mesh repair of incisional hernia (21%).<sup>26</sup> For most patients, seroma was self-limiting and resolved without intervention. Heniford et al<sup>18</sup> recommended aspiration of seroma for patients who were symptomatic whilst allowing others to resolve on their own. Patients should be warned of this complication prior to operation since seroma mimics early recurrence.

## Conclusion

Early outcomes of laparoscopic incisional hernioplasty utilising GORE-TEX DualMesh were promising. The laparoscopic approach confers the advantages of minimal access surgery and appears to be a safe technique for the repair of incisional hernia. Extensive adhesion, which does not allow the establishment of pneumoperitoneum, is a condition that precludes the safe performance of laparoscopic repair.

## Acknowledgement

The authors wish to acknowledge the kind assistance of Dr TC Tan, Department of Neurosurgery, Queen Elizabeth Hospital, Hong Kong, in editing the manuscript.

## References

1. Israelsson LA, Jonsson T. Incisional hernia after midline laparotomy: a prospective study. *Eur J Surg* 1996;162:125-9.
2. Mudge M, Hughes LE. Incisional hernia: a 10-year prospective study

- of incidence and attitudes. *Br J Surg* 1985;72:70-1.
3. George CD, Ellis H. The results of incisional hernia repair: a twelve year review. *Ann R Coll Surg Engl* 1986;68:185-7.
  4. Read RC, Yoder G. Recent trends in the management of incisional herniation. *Arch Surg* 1989;124:485-8.
  5. Stoppa RE. The treatment of complicated groin and incisional hernias. *World J Surg* 1989;13:545-54.
  6. LeBlanc KA, Booth WV. Laparoscopic repair of incisional abdominal hernias using expanded polytetrafluoroethylene: preliminary findings. *Surg Laparosc Endosc* 1993;3:39-41.
  7. Lau H, Lee F, Patil NG. Laparoscopic repair of incisional hernia. *Hong Kong Med J* 2001;7:319-21.
  8. Leber GE, Garb JL, Alexander AI, Reed WP. Long-term complications associated with prosthetic repair of incisional hernias. *Arch Surg* 1998;133:378-82.
  9. Chew DK, Choi LH, Rogers AM. Enterocutaneous fistula 14 years after prosthetic mesh repair of a ventral incisional hernia: a life-long risk? *Surgery* 2000;127:352-3.
  10. Bauer JJ, Salky BA, Gelernt IM, KreeI I. Repair of large abdominal wall defects with expanded polytetrafluoroethylene (PTFE). *Ann Surg* 1987;206:765-9.
  11. Utrera Gonzalez A, de la Portilla de Juan F, Carranza Albarran G. Large incisional hernia repair using intraperitoneal placement of expanded polytetrafluoroethylene. *Am J Surg* 1999;177:291-3.
  12. Christoforoni PM, Kim YB, Preys Z, Lay RY, Montz FJ. Adhesion formation after incisional hernia repair: a randomized porcine trial. *Am Surg* 1996;62:935-8.
  13. LeBlanc KA, Booth WV, Whitaker JM, Baker D. In vivo study of meshes implanted over the inguinal ring and external iliac vessels in uncastrated pigs. *Surg Endosc* 1998;12:247-51.
  14. Gillion JF, Begin GF, Marecos C, Fourtanier G. Expanded polytetrafluoroethylene patches used in the intraperitoneal or extra-peritoneal position for repair of incisional hernias of the anterolateral abdominal wall. *Am J Surg* 1997;174:16-9.
  15. Ramshaw BJ, Esartia P, Schwab J, et al. Comparison of laparoscopic and open ventral herniorrhaphy. *Am Surg* 1999;65:827-32.
  16. Park A, Birch DW, Lovrics P. Laparoscopic and open incisional hernia repair: a comparison study. *Surgery* 1998;124:816-22.
  17. Holzman MD, Purut CM, Reintgen K, Eubanks S, Pappas TN. Laparoscopic ventral and incisional hernioplasty. *Surg Endosc* 1997;11:32-5.
  18. Heniford BT, Park A, Ramshaw BJ, Voeller G. Laparoscopic ventral and incisional hernia repair in 407 patients. *J Am Coll Surg* 2000;190:645-50.
  19. Koehler RH, Voeller G. Recurrences in laparoscopic incisional hernia repairs: a personal series and review of the literature. *JLS* 1999;3:293-304.
  20. Costanza MJ, Heniford BT, Arca MJ, Mayes JT, Gagner M. Laparoscopic repair of recurrent ventral hernias. *Am Surg* 1998;64:1121-7.
  21. Park A, Gagner M, Pomp A. Laparoscopic repair of large incisional hernias. *Surg Laparosc Endosc* 1996;6:123-8.
  22. Voeller GR. Repair of incisional hernias and midline defects. In: Bendavid R, Abrahamson J, Arregui ME, Flament JB, Phillips EH, editors. *Abdominal wall hernias: principles and management*. New York: Springer-Verlag; 2001:519-24.
  23. Lau H, Lee F, Patil NG, Yuen WK. Laparoscopic totally extraperitoneal inguinal hernioplasty: an audit of the early postoperative results of 100 consecutive repairs. *Ann Acad Med Singapore* 2000;29:640-3.
  24. LeBlanc KA. Current considerations in laparoscopic incisional and ventral herniorrhaphy. *JLS* 2000;4:131-9.
  25. Toy FK, Bailey RW, Carey S, et al. Prospective, multicenter study of laparoscopic ventral hernioplasty. Preliminary results. *Surg Endosc* 1998;12:955-9.
  26. White TJ, Santos MC, Thompson JS. Factors affecting wound complications in repair of ventral hernias. *Am Surg* 1998; 64:276-80.

## Announcement

Academy Fellows and Association Members are invited to submit original articles, case reports, pictorial medicine and medical practice papers for publication in the Journal.

The current acceptance rate is approximately 55 percent.

For further information, please refer to our website <<http://www.hkmj.org.hk>>.

Page charges will be abolished from 2003.