



Title	Treatment of a ruptured iliac aneurysm with an endoluminal stent graft.
Author(s)	Ting, AC; Cheng, SW; Kwok, KF
Citation	Hong Kong Medical Journal = Xianggang Yi Xue Za Zhi / Hong Kong Academy Of Medicine, 2002, v. 8 n. 2, p. 145-148
Issued Date	2002
URL	http://hdl.handle.net/10722/45412
Rights	Creative Commons: Attribution 3.0 Hong Kong License

ACW Ting 丁志偉
 SWK Cheng 鄭永強
 KF Kwok 郭家輝

Treatment of a ruptured iliac aneurysm with an endoluminal stent graft

使用腔內支架治療破裂的髂動脈瘤

The management of a 79-year-old man presenting with a ruptured common iliac aneurysm is described. The patient had multiple medical problems including hypertension, ischaemic heart disease, and atrial fibrillation, as well as a left hemispheric stroke 5 years previously. Traditional open surgery was judged unsuitable in this case because of the predicted poor outcome. The patient was subsequently treated successfully with endoluminal stent grafting.

本文描述了對一位出現破裂的髂總動脈瘤的79歲老人的治療處理。該患者有多種疾病，包括高血壓、心臟病、前心室纖維顫動、以及五年前的左半腦中風。由於傳統的腹腔手術的預計效果差，因此斷定不適合用於這病例。後來，我們使用腔內支架對患者成功地進行了治療。

Introduction

Despite improvements in perioperative care, ruptured abdominal aortic aneurysm is still associated with a very high risk of mortality and morbidity, especially in elderly patients with multiple co-morbidities. The reported in-hospital mortality rate ranges from 40% to 60%.^{1,2} Similar mortality rates have been reported for patients with a ruptured iliac aneurysm.³ High-risk patients with multiple co-morbidities, who have a low probability of a successful outcome, are often not considered for surgery.⁴ However, with the advent of endoluminal repair of aortoiliac aneurysm, indications for intervention may need redefinition. Given the efficacy of endoluminal repair in high-risk patients, it should be considered as an option for this patient group.⁵ We report on a high-risk patient with a contained rupture of a left common iliac aneurysm, who was not considered a candidate for open aneurysm repair, but was subsequently treated successfully with an endoluminal stent graft.

Case report

A 79-year-old man was referred to the Vascular unit at Queen Mary Hospital with contained rupture of a left common iliac aneurysm. He presented with abdominal pain and decreased consciousness associated with hypotension. The patient had multiple medical problems, including hypertension, ischaemic heart disease, and atrial fibrillation. In addition, a left hemispheric stroke 5 years previously had resulted in a right hemiplegia and dysphasia, and the patient had subsequently resided in a nursing home as he required ongoing assistance with some activities of daily living. Traditional open surgery had been considered by the referring hospital and judged unsuitable because of the high risk and predicted poor outcome. The patient had been resuscitated and referred to the Vascular unit for consideration of endoluminal repair of the ruptured aneurysm.

The patient was haemodynamically stable on presentation, with a haemoglobin level of 103 g/L (normal range, 140-175 g/L) and a creatinine level of 71 mmol/L (normal range, 53-106 mmol/L). Electrocardiography revealed pathological Q waves in the anterior leads and evidence of lateral ischaemia. Computed tomography (CT) scanning of the abdomen and pelvis showed a contained rupture of a left common iliac aneurysm measuring 5 cm in diameter, with a large

Key words:

Aneurysm, ruptured;
 Aortic aneurysm, abdominal;
 Iliac aneurysm;
 Stents

關鍵詞：

破裂的動脈瘤；
 腹主動脈瘤，腹部的；
 髂動脈瘤；
 支架

HKMJ 2002;8:145-8

Division of Vascular Surgery, Department of Surgery, The University of Hong Kong, Queen Mary Hospital, 102 Pokfulam Road, Hong Kong

ACW Ting, FRCS, FHKAM (Surgery)
 SWK Cheng, FRCS, FHKAM (Surgery)
 KF Kwok, MB, BS, FRCS

Correspondence to: Prof SWK Cheng

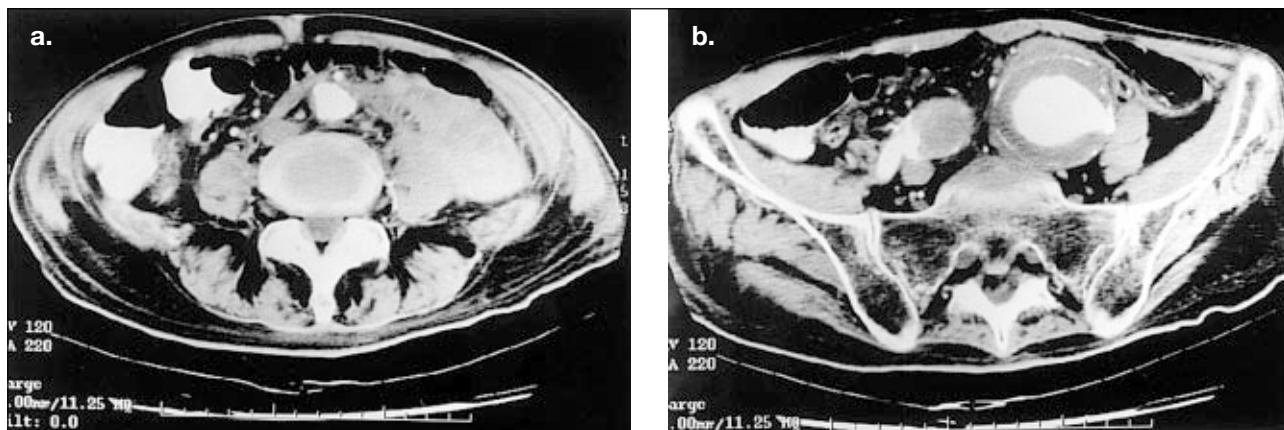


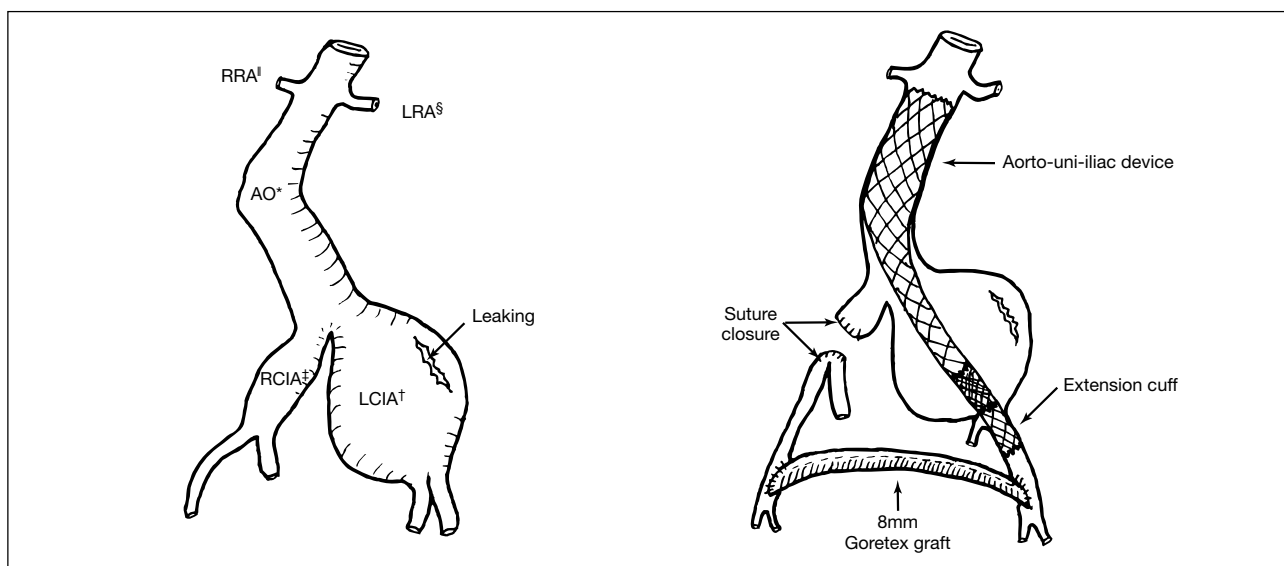
Fig 1. Computed tomography scan of the abdomen and pelvis

(a) A large retroperitoneal haematoma is seen on the left due to the leaking left common iliac artery aneurysm. Note the normal sized aorta; and (b) the 5 cm left common iliac artery aneurysm and leaking is seen. Note the aneurysmal right common iliac artery measuring 2.5 cm in diameter and the thrombus near the origin of the right internal iliac artery

retroperitoneal haematoma (Fig 1). The right common iliac artery was also aneurysmal, with a diameter of 2.5 cm, and there was a thrombus near the origin of the right internal iliac artery but the artery was still patent. Endoluminal stent grafting was judged appropriate using an aorto-uni-iliac device. Preoperative angiography was not undertaken. Surgery was performed in the operating theatre with the patient under general anaesthesia. Bilateral vertical groin incisions were made for access and the common femoral artery exposed. Systemic heparin (3000 units) was administered intravenously. An 'off-the-shelf' aorto-uni-iliac device (AneuRx, Medtronic AVE, Santa Rosa, California, US), with a diameter of 26 mm at the aortic end, a diameter of 15 mm at the iliac end, and a length of 165 mm, was deployed via vertical arteriotomy of the left common femoral artery. A 15 mm x 55 mm extension cuff was also inserted, to secure fixation to the external iliac artery and sealing of the internal iliac artery. The contralateral common iliac

artery was deemed too large for occlusion by insertion of a covered stent or intraluminal coils. A small, right lower quadrant oblique incision was thus made, with retroperitoneal approach to the right common iliac artery, which was divided and sutured to exclude the aneurysm sac. This was followed by a cross-femoral bypass with an 8 mm Goretex graft (WL Gore & Associates, Arizona, US) to maintain perfusion to the right lower limb and the right internal iliac artery (Fig 2).

The operation lasted 5 hours with a blood loss of 600 mL. Two units of blood were given intra-operatively. The patient was stable throughout the operation and was extubated and transferred postoperatively to the Intensive Care Unit, where he stayed for 2 days. The patient's recovery was uneventful, with repeated CT scanning of the abdomen and pelvis showing satisfactory exclusion of the aneurysm with no endoleak. The patient remained in hospital for 19 days and



* AO abdominal aorta
 † LCIA left common iliac artery
 ‡ RCIA right common iliac artery

§ LRA left renal artery
 ‖ RRA right renal artery

Fig 2. Schematic illustration of the endoluminal repair procedure undertaken

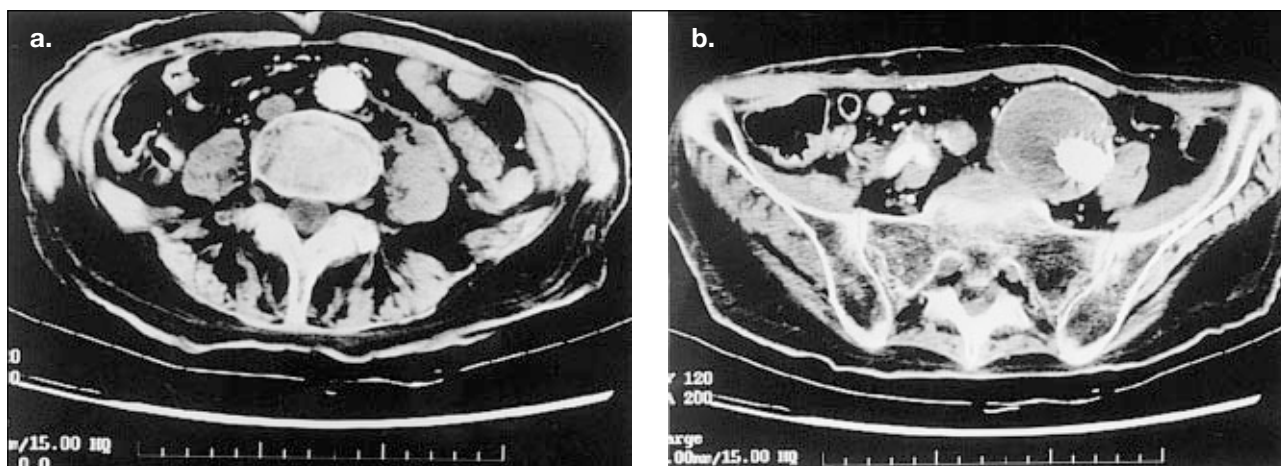


Fig 3. Computed tomography scan of the abdomen and pelvis 1 month postsurgery

(a) Resolution of the retroperitoneal haematoma is seen; and (b) exclusion of the aneurysm and the absence of endoleak is evident. Thrombosis of the aneurysm sac and retrograde perfusion of the right internal iliac artery via the cross femoral bypass graft can also be seen

was discharged to the nursing home in a stable condition. A subsequent CT scan of the abdomen and pelvis 1 month postsurgery confirmed exclusion of the aneurysm with no endoleak, and that the retroperitoneal haematoma had resolved (Fig 3). The patient remained well 3 months after the operation with no additional problems noted.

Discussion

Despite improvements in perioperative care, the standard surgical procedure for ruptured aortoiliac aneurysm still carries a high risk of mortality and morbidity.^{1,2} In a recent survey in the United Kingdom, 97% of vascular surgeons decided not to operate on selected patients with ruptured abdominal aortic aneurysms based on the presence of various risk factors.⁴ Among these, advanced age and severe neurological disease were the most influential factors affecting the decision. Studies have also examined the factors predicting poor outcomes in patients with ruptured abdominal aortic aneurysm. Hardman et al⁶ identified a set of five independent preoperative factors associated with mortality:

- (1) older than 76 years;
- (2) creatinine level greater than 190 mmol/L;
- (3) loss of consciousness after arrival;
- (4) haemoglobin level less than 90 g/L; and
- (5) electrocardiographic evidence of myocardial ischaemia.

A patient with three or more factors had a 100% risk of mortality associated with the procedure. The validity of these preoperative risk factors was also supported by Prance et al.⁷ In this case, with multiple risk factors including age and severe neurological disease, the patient was not considered a candidate for open aneurysm repair. Endoluminal repair, however, offered a suitable alternative treatment option.

The efficacy and feasibility of endoluminal repair for abdominal aortic aneurysms in an elective setting has been well reported.⁵ Its application in ruptured abdominal aortic

aneurysm is limited by the mandatory delay required in the assessment process and the selection of patients. Thorough preoperative assessment of the proximal aortic neck length and diameter, and the anatomy of the iliac landing zone with the help of spiral CT and angiography is required to select suitable patients for endoluminal repair. This delay limits its applicability in an emergency setting. However, the delay may be tolerable in a stable patient, as in this case. The time spent in such assessment may also obviate the major trauma of laparotomy, and allows operative treatment for many patients who would otherwise have been denied surgery. Strict anatomic requirements must be met for successful endoluminal repair. The adequacy of the proximal neck is important, and adverse iliac anatomy has been shown to preclude stent placement in as many as 50% of patients.⁸ The use of an aorto-uni-iliac device instead of a bifurcated device may extend the applicability of endoluminal repair. Patients with unfavourable iliac anatomy—for example, those with complex or extensive pelvic aneurysmal disease—may be considered for endoluminal repair using an aorto-uni-iliac device providing there is an adequate proximal neck, since only one iliac landing zone is required. The aorto-uni-iliac device is particularly suitable for patients with a common iliac aneurysm, as seen in the current patient. The adequacy of the proximal neck is not of concern and hence only minimal preoperative investigation, excluding angiography, is required.

The placement of an aorto-uni-iliac device is also technically easier because it does not require proper orientation and cannulation of the contralateral limb, and hence the exclusion of the aneurysm can be achieved within a very short time. This is important in an emergency situation of ruptured aneurysm. In the case of an unstable patient, a proximal aortic occlusion balloon can be used intra-operatively for temporary control of the aorta.⁹ Although there is concern regarding the durability of the cross-femoral bypass graft required in the placement of an aorto-uni-iliac device, as well as its potential for late complications such as graft infection, these concerns were not substantiated in

a recent study by Rehring et al,¹⁰ and would not be an important issue in emergency treatment of high-risk patients.

The current patient had an isolated iliac artery aneurysm. However, an aorto-uni-iliac device was required for stenting due to the involved proximal iliac neck. For an isolated iliac artery aneurysm with adequate proximal common iliac neck, stenting of the iliac aneurysm may be performed by the placement of a covered stent from the neck to the common femoral or external iliac artery, obviating the need for involving the contralateral iliac arteries. However, it may be necessary to embolise the ipsilateral internal iliac artery with the appropriately sized embolisation coils prior to stenting in order to prevent retrograde flow into the aneurysm sac after endovascular aneurysm exclusion. This procedure can be performed under local anaesthetic. The absence of laparotomy, aortic cross clamping, and extensive retroperitoneal dissection makes endoluminal repair an attractive alternative for patients with ruptured aortoiliac aneurysms. With the continued modification of stenting devices and increased experience, endoluminal stent grafting may be an option, especially in high-risk patients who would otherwise be denied treatment.

This case report illustrates the feasibility of endoluminal stent grafting in the management of patients with ruptured aortoiliac aneurysm. Endoluminal stent grafting may be a

viable option, especially in high-risk patients who are not regarded as suitable candidates for traditional open surgery.

References

1. Barry MC, Burke PE, Sheehan S, Leahy A, Broe PJ, Bouchier-Hayes DJ. An "all comers" policy for ruptured abdominal aortic aneurysms: how can results be improved? *Eur J Surg* 1998;164:263-70.
2. Halpern VJ, Kline RG, D'Angelo AJ, Cohen JR. Factors that affect the survival rate of patients with ruptured abdominal aortic aneurysms. *J Vasc Surg* 1997;26:939-48.
3. Desiron Q, Detry O, Sakalihan N, Defraigne JO, Limet R. Isolated atherosclerotic aneurysms of the iliac arteries. *Ann Vasc Surg* 1995;9 (Suppl):62S-6S.
4. Hewin DF, Campbell WB. Ruptured aortic aneurysm: the decision not to operate. *Ann R Coll Surg Engl* 1998;80:221-5.
5. Chuter TA, Reilly LM, Faruqi RM, et al. Endovascular aneurysm repair in high-risk patients. *J Vasc Surg* 2000;31:122-33.
6. Hardman DT, Fisher CM, Patel MI, et al. Ruptured abdominal aortic aneurysms: who should be offered surgery? *J Vasc Surg* 1996;23:123-9.
7. Prance SE, Wilson YG, Cosgrove CM, Walker AJ, Wilkins DC, Ashley S. Ruptured abdominal aortic aneurysms: selecting patients for surgery. *Eur J Vasc Endovasc Surg* 1999;17:129-32.
8. Treiman GS, Lawrence PF, Edwards WH Jr, Galt SW, Kraiss LW, Bhirangi K. An assessment of the current applicability of the EVT endovascular graft for treatment of patients with an infrarenal abdominal aortic aneurysm. *J Vasc Surg* 1999;30:68-75.
9. Greenberg RK, Srivastava SD, Ouriel K, et al. An endoluminal method of hemorrhage control and repair of ruptured abdominal aortic aneurysms. *J Endovasc Ther* 2000;7:1-7.
10. Rehring TF, Brewster DC, Cambria RP, et al. Utility and reliability of endovascular aortouniiliac with femorofemoral crossover graft for aortoiliac aneurysmal disease. *J Vasc Surg* 2000;31:1135-41.