



<b>Title</b>	<b>Obstructive sleep apnoea syndrome presented as failure to thrive in a Down's syndrome child</b>
<b>Author(s)</b>	<b>Hui, HNT; Ng, DKK; Hui, Y; Kwok, KL; Chau, KW</b>
<b>Citation</b>	<b>Hong Kong Practitioner, 2001, v. 23 n. 11, p. 490-494</b>
<b>Issued Date</b>	<b>2001</b>
<b>URL</b>	<b><a href="http://hdl.handle.net/10722/45408">http://hdl.handle.net/10722/45408</a></b>
<b>Rights</b>	<b>Creative Commons: Attribution 3.0 Hong Kong License</b>

# Obstructive sleep apnoea syndrome presented as failure to thrive in a Down's syndrome child

H N T Hui 許寧達, D K K Ng 吳國強, H Yau 許游, K L Kwok 郭嘉莉, K W Chau 周健偉

## Summary

Children suffering from Down's syndrome are prone to develop obstructive sleep apnoea syndrome (OSAS) due to craniofacial abnormalities, small upper airway, adenotonsillar hypertrophy and muscular hypotonia.<sup>1</sup> OSAS will lead to various complications including failure to thrive.<sup>2</sup> We report a Down's syndrome boy whose main presenting feature of OSAS was failure to thrive. He was successfully treated initially with nocturnal continuous positive airway pressure (CPAP) ventilation and subsequently with adenotonsillectomy.

## 摘要

患有唐氏綜合症的兒童，因顱面畸形、上呼吸道狹窄、扁桃腺肥大以及肌張力低下，易罹患阻塞性睡眠呼吸暫停綜合症（OSAS）。OSAS 可導致包括存活困難在內的各種合併症。本文報告了一例患唐氏綜合症的男童，其 OSAS 的主要表現為存活困難，最初使用的夜間連續氣道正壓（CPAP）通氣法和隨後採用的扁桃腺切除術，病童成功得以醫治。

HK Pract 2001;23:490-494

H N T Hui, MBChB, MRCP  
Medical Officer,

Department of Paediatrics, United Christian Hospital.

H Yau, MBBS, FRCS(Ed), FHKAM(ENT), FACS  
Consultant (ENT),

Department of Surgery, University of Hong Kong Medical Centre, Queen Mary Hospital.

D K K Ng, MBBS, MMedSc, FRCP, FHKAM(Paed)  
Consultant Paediatrician,

K L Kwok, MBChB, MRCP, FHKAM(Paed)  
Senior Medical Officer,

K W Chau, MBBS, MRCP, FHKAM(Paed)  
Specialist Medical Officer,

Department of Paediatrics, Kwong Wah Hospital.

Correspondence to : Dr D K K Ng, Department of Paediatrics, Kwong Wah Hospital, Kowloon, Hong Kong.

## Introduction

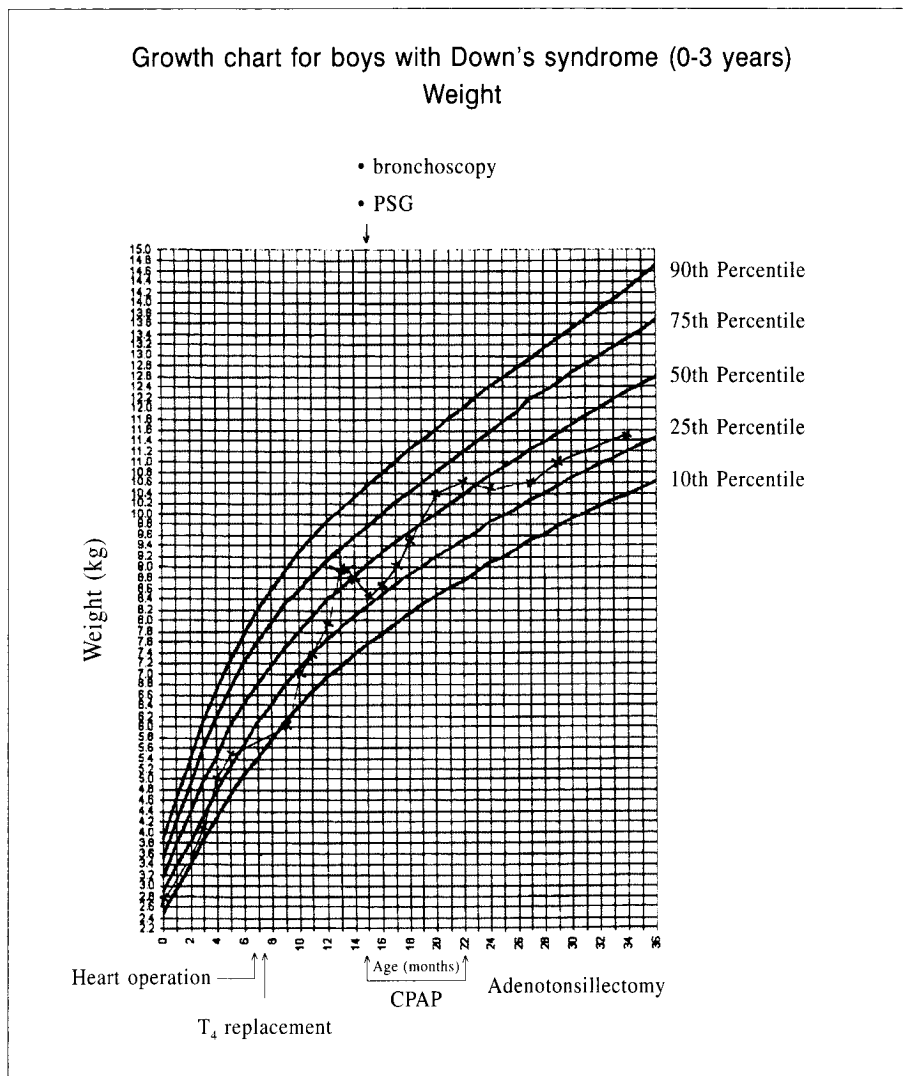
Children with Down's syndrome are prone to develop obstructive sleep apnoea syndrome (OSAS) due to craniofacial abnormalities, small upper airway, adenotonsillar hypertrophy and muscular hypotonia.<sup>1</sup> Paediatric patients with severe OSAS may not present with snoring. On the contrary, many of them will present with poor feeding and failure to thrive.

## Case report

HWH was born at full term with birth weight of 2.76 kg (10th-25th centile).<sup>3</sup> He had patent ductus arteriosus (PDA) and perimembranous ventricular septal defects (VSD) with congestive heart failure. He was treated medically with fluid restriction, concentrated caloric feeding and diuretics. His growth remained along 10-25th centile. Cardiac operation (PDA ligation and patch repair of VSD) was performed at 7 months of age. At the same time, he was diagnosed to have congenital hypothyroidism and was put on thyroxine replacement after the operation. Thereafter, his growth improved gradually to 8.9 kg (50-75th centile) at 13 months (Figure 1).

At 13 months, he suffered 2 episodes of upper respiratory tract infection and one episode of acute bronchiolitis. His feeding became poor and his body weight dropped to 8.5 kg (25th centile) at 15 months. He had poor appetite, difficulty in swallowing and vomiting. Milk scan did not reveal significant gastro-esophageal reflux. Thyroid function tests were normal. During a routine check-up, he was noted by the attending paediatrician to have respiratory distress during sleep with subcostal recession and tachycardia. Pulse oximetry showed readings of 91% and 99% during sleep and when awake, respectively. Restless sleep and frequent

Figure 1: Growth chart



awakening were noted. However, no definite snoring was noted by both parents. Supplementary O<sub>2</sub> at 1 L/min delivered via nasal cannula was able to abolish desaturation during sleep. He was also found to have tonsillar hypertrophy but there was no past history of tonsillitis noted. Sleep study was performed for suspected OSAS. Overnight polysomnography (PSG) demonstrated persistent tachycardia during sleep with prolonged episodes of hypoventilation. Obstructive apnoea/hypopnea index was found to be 8.8 episodes per hour. A diagnosis of OSAS was made based on PSG findings. His blood pressures were normal. Electrocardiogram and echocardiogram did not reveal any pulmonary hypertension. Flexible bronchoscopy revealed enlarged adenoids obstructing more than 80% of nasopharyngeal passage and inspiratory collapse at the tonsillar level due to enlarged tonsils.

He was treated with nocturnal continuous positive airway pressure (CPAP) ventilation via facemask. The required pressure at which apnoeic and hypnoeic episodes were abolished, was found to be 10 cm H<sub>2</sub>O. Supplementary oxygen was not required after initiation of CPAP. He tolerated CPAP well with improvement in quality of sleep. His feeding also improved, nausea and vomiting became less. His weight gain improved subsequently with body weight of 10.3 kg at 20 months (50-75th centile) (Figure 1).

Definitive surgical treatment of OSAS with adenotonsillectomy was carried out at 22 months when his body weight reached 10.5 kg. He tolerated the surgery well and made a smooth recovery. Post-op PSG showed no desaturation during sleep. Snoring and laboured breathing were not noticed. CPAP was therefore no

### Key messages

1. Obstructive sleep apnoea syndrome (OSAS) is common in Down's syndrome children (31-45%).
2. OSAS may not be associated with snoring.
3. Adenotonsillectomy is the definitive treatment in most childhood OSAS and will eliminate the need for continuous positive airway pressure.

longer necessary. He was discharged home within the same month. Subsequent follow up till the age of 34 months at outpatient clinic showed sustained growth along 25-50th centile.

### Discussion

Down's syndrome children are prone to develop OSAS for various reasons including midfacial and mandibular hypoplasia,<sup>1,4</sup> macroglossia, glossoptosis, hypoplastic trachea,<sup>5</sup> adenotonsillar enlargement,<sup>6,7</sup> increased secretion, lower respiratory tract abnormalities,<sup>6</sup> obesity and muscular hypotonia with resultant collapse of the airway during inspiration. The high prevalence of increased risk of OSAS amongst Down's syndrome children was supported by population studies. Marcus *et al* found OSAS in 24 out of 53 Down's syndrome children.<sup>8</sup> Stebbens VA *et al* found sleep related upper airway obstruction a common problem in children with Down's syndrome, occurring in 31% of their studied population.<sup>9</sup> In contrast OSAS only occurs in 2% of normal children.<sup>10</sup>

OSAS may have adverse effects on neurological and cardiac function as well as growth.<sup>2</sup> Growth impairment is one of the unique features of childhood OSAS. Early reports of children with severe OSAS were almost always associated with failure to thrive. Reports from the 1980s found failure to thrive in 27% to 56% of children with OSAS.<sup>11,12</sup> Poor caloric intake may result in inadequate growth. Brouillette *et al* reported significantly higher incidence of poor appetite, swallowing difficulty, nausea and vomiting in children with OSAS compared to control (26-30% vs 2-9%).<sup>13</sup> Poor growth described in some children with OSAS may be secondary to increased energy expenditure from increased work of breathing during sleep rather than decreased caloric intake.<sup>14</sup>

Although most patients with OSAS presented with snoring and difficulty in breathing during sleep,<sup>15</sup> it is important to be aware of other less common presenting symptoms such as failure to thrive, poor appetite, nausea and vomiting.<sup>14</sup> In fact, our patient presented with poor appetite and failure to thrive rather than snoring. Snoring is produced by vibration of the soft palate and faucal pillars. In patients suffering from severe OSAS, the absence of snoring may be related to the inadequate airflow through the obstructed upper airway that produces little vibration of the soft palate and faucal pillars. Medical doctors need to be aware of the less common presentations of OSAS especially in high risk patients such as children with Down's syndrome,<sup>16</sup> otherwise appropriate treatments will be delayed.

Adenotonsillectomy is the definitive treatment in children with OSAS with tonsillar and adenoid enlargement.<sup>15</sup> Adenotonsillectomy in children with OSAS was documented by some studies to have a positive impact on growth. Brouillette *et al* and Williams *et al* found significant catch-up growth after adenotonsillectomy in children with OSAS,<sup>12,17</sup> that may be related to the normalisation of IGF-1 axis.<sup>18</sup> Application of CPAP ventilation is also helpful to overcome the obstruction. Not surprisingly, our patient showed improved feeding, decrease gastrointestinal symptoms and improved growth after applications of nocturnal CPAP and adenotonsillectomy.

### Conclusion

Medical practitioners should be aware of the many different presentations of OSAS, especially in high-risk patients such as in Down's syndrome, so that the disease can be diagnosed at an early stage. Early and appropriate treatments can lead to a major impact on the outcome. Paediatric patients with severe OSAS may not present with snoring. Early diagnosis and appropriate treatment is possible only if medical practitioners keep the diagnosis in mind. ■

### References

1. Fink GB, Madaus WK, Walker GE. A quantitative study of the face in Down's syndrome. *Am J Orthod* 1975;67:540-553.
2. Arens R. Obstructive sleep apnoea in Childhood: Clinical Features. In: Loughlin GM, Carroll JL, Marcus CL, (eds). *Sleep Biology in Health and Disease*. New York: Marcel Dekker, Inc. 2000:575-600.

(Continued on page 494)

3. Growth charts for children with Down's syndrome. *J Pediatr* 1988;81.
4. Allanson JE, O'Hara P, Farkas LG, *et al*. Anthropometric craniofacial pattern profiles in Down's syndrome. *Am J Med Genet* 1993;47:748-752.
5. Aboussouan LS, O'Donovan PB, Moodie DS, *et al*. Hypoplastic trachea in Down's syndrome. *Am Rev Respir Dis* 1993;147:72-75.
6. Strome M. Obstructive sleep apnoea in Down's syndrome children: a surgical approach. *Laryngoscope* 1986;96:1340-1342.
7. Southall DP, Stebbens VA, Mirza R, *et al*. Upper airway obstruction with hypoxaemia and sleep disruption in Down's syndrome. *Dev Med Child Neurol* 1987;29:734-741.
8. Marcus CL, Keens TG, Bautista DB, *et al*. Obstructive sleep apnoea in children with Down's syndrome. *Pediatrics* 1991;88:132-139.
9. Stebbens VA, Dennis J, *et al*. Sleep related upper airway obstruction in a cohort with Down's syndrome. *Arch Dis Child* 1991;66:1333-1338.
10. Ali NJ, Pitson DJ, Stradling JR. The prevalence of snoring, sleep disturbance, and sleep related breathing disorders, and their relation to daytime sleepiness in 4-5 year old children. *Arch Dis Child* 1993;68:360-366.
11. Guilleminault C, Korobkin R, Winkel R. A review of 50 children with obstructive sleep apnoea syndrome. *Lung* 1981;159:275-287.
12. Brouillette RT, Fernbach SK, Hunt CE. Obstructive sleep apnoea in infants and children. *J Pediatr* 1982;100:31-40.
13. Brouillette R, Hanson D, David R, *et al*. A diagnostic approach to suspected obstructive sleep apnoea in children. *J Pediatr* 1984;105:10-14.
14. Marcus CL, Carroll JL, Koerner CB, *et al*. Determinants of growth in children with the obstructive sleep apnoea syndrome. *J Pediatr* 1994;125:556-662.
15. Ng DKK, Cheung JMY. Childhood snoring – what's the problem? *HK Pract* 2000;22:495-503.
16. American Academy of Pediatrics. Committee on Genetics. Health supervision for children with Down's syndrome. *Pediatrics* 2001;107(2):442-449.
17. Williams EF, Woo P, Miller R, *et al*. The effects of adenotonsillectomy on growth in young children. *Otolaryngol Head Neck Surg* 1991;104:509-516.
18. Bar, Tarasiuk, Segev, *et al*. The effect of adenotonsillectomy on serum insulin-like growth factor-1 and growth in children with obstructive sleep apnoea syndrome. *J Pediatr* 1999;135(1):76-80.