



Title	Inhaled foreign bodies: children with peanut in airway
Author(s)	Wong, SW; Ng, DKK; Ho, JCS; Tam, PKH; Chong, ASF; Chan, KL
Citation	Hong Kong Practitioner, 1999, v. 21 n. 11, p. 532-537
Issued Date	1999
URL	http://hdl.handle.net/10722/45399
Rights	Creative Commons: Attribution 3.0 Hong Kong License

Inhaled foreign bodies: children with peanut in airway

S W Wong 王錫偉, D K K Ng 吳國強, J C S Ho 何誌信, P Tam 譚廣亨, A S F Chong 莊瑞芬, K L Chan 陳廣亮

Summary

Foreign body aspiration is a common problem in young children. Many patients present after a significant delay despite having a witnessed choking event. Moreover, their presentations may mimic other common respiratory problems like pneumonia or asthma. It is extremely important to be attentive to history taking and clinical signs that may indicate early bronchoscopy to confirm the diagnosis.

摘要

兒童吸入異物很常見。雖然有時觀察到有噎塞的情況，還是經常出現診斷延誤。而且，有時臨床表現與哮喘和呼吸道感染（例如肺炎）相似。所以臨床病史及臨床症狀有可疑者要儘早做氣管內窺鏡檢查。

HK Pract 1999;21:532-537

Introduction

Foreign body aspiration is a common worldwide problem. Most cases occur in children. More than half of the children with foreign bodies are under 4 years of age and up to 94% are under 7 years of age.¹ With the

advent of bronchoscopy, there has been a fall in the mortality associated with foreign body aspiration to less than 1%.² Nevertheless, the incidence of foreign body aspiration has not changed significantly; it still causes more than 300 children deaths each year in United States.³

Tracheobronchial inhalation of foreign bodies may result in acute respiratory distress, chronic pulmonary infections or death. Diagnosis is obvious in those patients with a history of choking followed by respiratory symptoms. There may however be diagnostic problems in patients without a definite history of choking or foreign bodies aspiration. It was estimated that around 20% of patients had no positive history of foreign body aspiration.⁴ This group of patients can present with chronic cough, wheeze and fever which mimic other common respiratory conditions like pneumonia and asthma. As a result, appropriate treatment may be delayed. The consequence can be serious since irreversible parenchymal changes may occur.

We present here 2 cases with recurrent chest problems caused by aspiration of peanut and discuss various aspects concerning clinical presentation, diagnosis and treatment. We shall also discuss the radiological findings and the role of flexible bronchoscopy in diagnosis, and the surgical treatment for this condition.

Case 1

An 18-month-old boy was admitted to Kwong Wah Hospital because of cough and fever. There was no definite history of choking or foreign body aspiration. Birth history and past medical history were unremarkable. There was no family history of asthma, atopy nor any contact with pulmonary tuberculosis by the patient. He had no recent travel history. He received Bacille Calmette-Guerin (BCG) vaccination in Hong Kong. Initial frontal chest radiograph (**Figure 1**) showed increased retrocardiac density representing parenchymal

S W Wong, MBChB(HK), MRCP(UK), DCH(Ire)

Medical Officer,

D K K Ng, MBBS(HK), FRCP(Edin, Glas), FHKAM(Paed), FHKCPaed
Consultant,

J C S Ho, MBBS(HK), FRCP(Glas), FHKAM(Paed), FHKCPaed

Chief of Service,

Department of Paediatrics, Kwong Wah Hospital.

A S F Chong, MBBS(HK), FRCR(UK), FHKCR, FHKAM(Radiol)

Consultant,

Department of Radiology, Kwong Wah Hospital.

K L Chan, MBBS(HK), FRCS(Glas), FACS, FHKCS

Senior Medical Officer,

P Tam, MBBS(HK), MCh, FRCS(Edin), FHKCS

Chief of Service of Paediatric Surgery,

Department of Surgery, Queen Mary Hospital.

Correspondence to: Dr S W Wong, Department of Paediatrics, Kwong Wah Hospital, 25 Waterloo Road, Kowloon.

infiltration or atelectasis. There was generalised hyperinflation with flattening of the diaphragm bilaterally without mediastinal shift. He was diagnosed to suffer from bronchiolitis with pneumonia and was treated with a course of cefuroxime. Subsequent follow-up of patient revealed that he still had persistent mild cough. Mantoux test with five units of purified protein derivative was negative. Repeat frontal chest x-ray (CXR) (Figure 2) showed asymmetrical hypertranslucency of the left lung with diminished vascularity, depression of the ipsilateral diaphragm with mediastinal shift to the right. This sign of air trapping became more apparent on a left lateral decubitus film (Figure 3). In view of the persistent chest symptoms, foreign body aspiration was suspected. He was referred to us for further management.

Figure 1: Frontal chest x-ray of Case 1 at initial presentation

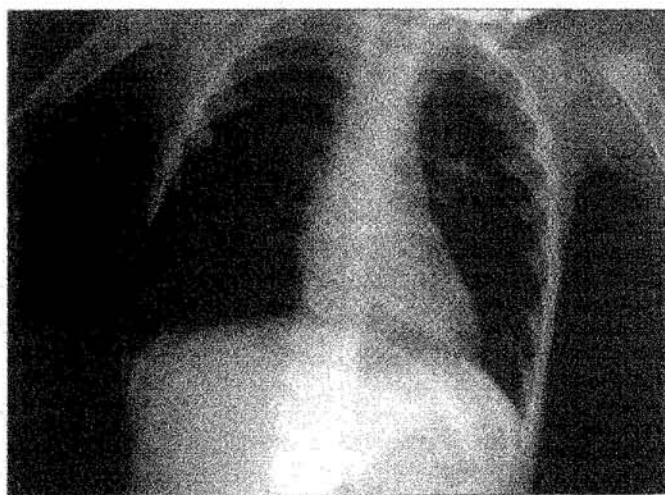


Figure 2: Follow-up frontal chest x-ray of Case 1 showing asymmetrical hypertranslucency of left lung and depressed left diaphragm

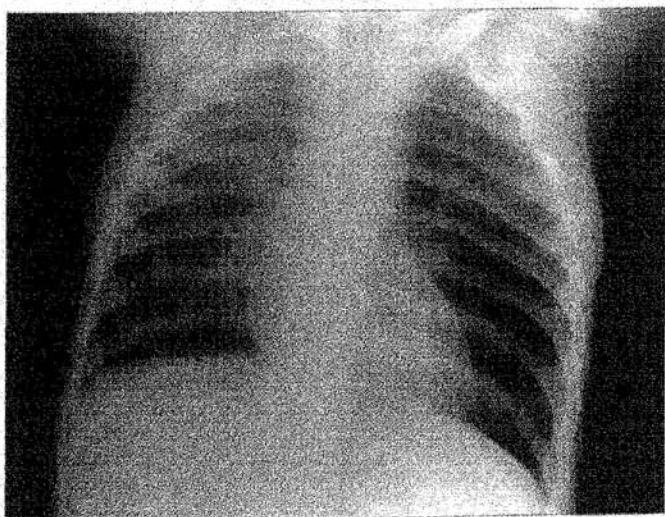
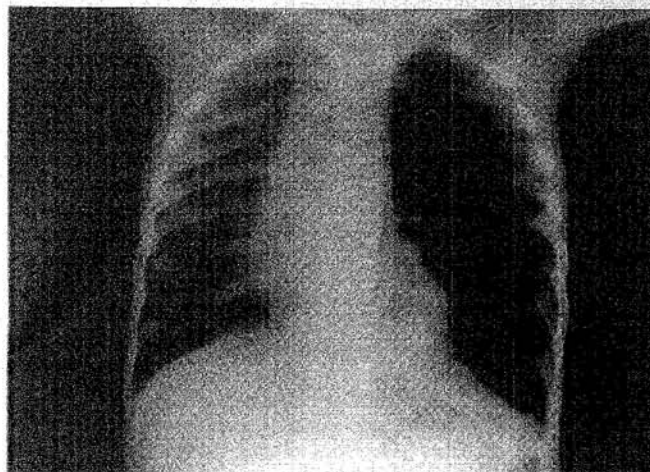


Figure 3: Left lateral decubitus chest x-ray of Case 1 showing the sign of air-trapping of left side more apparently



On admission, he was mildly tachypnoeic with respiratory rate of 40 per minute. Breath sound was diminished on left side and there was diffuse rhonchi on auscultation. Oxygen saturation was normal. CXR showed the full blown signs of obstructive emphysema of the left lung with left lower lobe infiltrate. No radio-opaque foreign body can be detected along the central airway.

Flexible bronchoscopy was performed. A yellow elliptical shaped foreign body was found in the left main bronchus. He was transferred immediately to the Paediatric Surgical Unit of Queen Mary Hospital for removal of foreign body. Emergency operation under general anaesthesia was performed on the same day of transfer. A fragment of peanut was found with the rigid bronchoscope and it was removed in piece-meal fashion till every bit was cleared. The surgeon did encounter some difficulties during the procedure in removing the peanut. Since it had remained in the bronchus for quite some time, the texture softened and it was like handling "bean curd".

Post-operatively, the child was stable and transferred back to Kwong Wah Hospital. He was treated with a course of intravenous cefuroxime and chest physiotherapy. He recovered well and subsequent CXR did not show any emphysematous change on the left side. Flexible bronchoscopy repeated 3 weeks after the procedure revealed no foreign body nor any sequelae. On follow up at 4 weeks after foreign body removal, all chest symptoms had subsided.

Case 2

A two-year-old girl was referred to our hospital by a family physician for suspected asthma. She was noted to have had shortness of breath with cough for one week. According to parents, she was given peanuts 1-2 weeks ago with "mild" choking. She had no previous history of wheezy attack and no family history of asthma nor atopy. Physical examination showed that she was tachypnoeic with bilateral wheezes. The air entry was equal on both sides. She was afebrile and CXR (Figure 4) did not reveal any abnormality. She was diagnosed to have acute bronchiolitis. Over the following five days, her chest symptoms and signs waxed and waned. She was treated with bronchodilators (nebulized salbutamol and ipratropium bromide) regularly with no significant clinical improvement. However, her cough and wheeze decreased about five days after admission. The patient was discharged with bronchodilator and was scheduled for follow-up in out-patient clinic.

She was referred to us again 10 days after discharge by another private practitioner for persistent cough. Her private doctor noted that she had a history of choking with peanuts three weeks ago and physical examination showed decreased air entry and coarse crepitations on the right side of her chest. He referred her to us to exclude foreign body aspiration in the right bronchus. After admission, her previous CXR and history were revealed. Foreign body (peanut) aspiration was strongly suspected and an urgent flexible bronchoscopy was arranged. A yellowish foreign body was found in the right main bronchus. A paediatric surgeon removed a 0.5 cm × 0.5 cm peanut from the right main bronchus with rigid bronchoscopy (Figure 5) under general anaesthesia.

Figure 4: Frontal chest x-ray of Case 2 on presentation

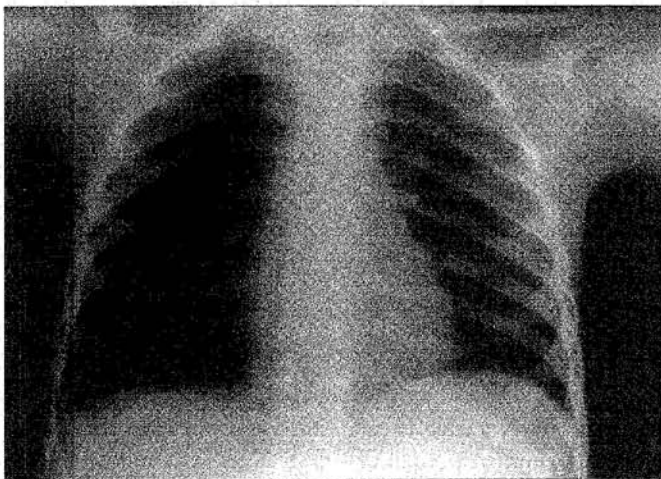
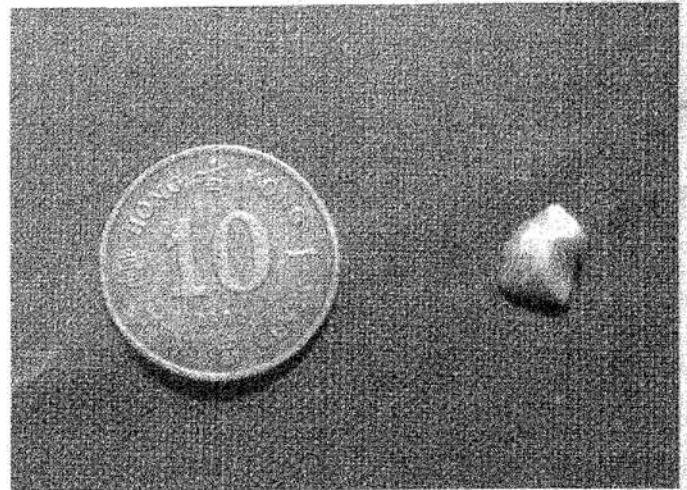


Figure 5: The peanut removed from Case 2



Discussion

In our first patient, although there was no definite history of choking, the parents admitted that the patient had taken peanuts shortly before the first presenting episode of cough and fever. The abnormal CXR findings led us to look for the possibility of foreign body inhalation. Complete removal of peanut fragments helped the patient in a dramatic way. In our second patient, even though the responsible doctor already knew there was history of ingestion and choking with peanut, he did not relate the symptoms with this piece of important information. Initial CXR showed abnormalities which was not picked up promptly and led to the delay in making the correct diagnosis. Fortunately, our colleague in the private sector made the correct diagnosis and referred her to us to exclude foreign body aspiration. Both these cases illustrated the point that foreign bodies should always be suspected in patients with persistent or recalcitrant respiratory symptoms. We should be more careful especially when children present with their first wheezy attack. A history of foreign body choking should always be taken seriously.

Vegetable substances particularly peanuts and grains are the commonest type of foreign body aspirated. Peanut account for one third of all cases. Cough, choking and wheezing are the commonest presenting symptoms and present in about 95% of all patients. Boys and girls are equally affected. Foreign body is distributed nearly evenly to the right and left main bronchi.³ Parents are advised not to give peanuts to children who have a high risk of aspiration because of incomplete eruption of their molar teeth for chewing.

(Continued on page 536)

Case Report

CXRs are positive in 80% of patients.⁴ The most common radiographic findings are unilateral or segmental consolidation or atelectasis. The exact features depend on size, location, duration and nature of the foreign body. A CXR taken on full inspiration may be entirely normal as dilatation of the bronchus can permit sufficient patency of the lumen at the site of the obstructing lesion with air entering the lung. To appreciate air-trapping as a result of "ball-valve" phenomenon, radiographs obtained during expiration are more appropriate. As infants and young children are unable to cooperate for satisfactory studies during the desired phases of respiration, the lateral decubitus film can be utilized as a useful and convenient alternative.⁵ When the child is placed on his side, the dependent hemithorax is splinted, resulting in restriction of movement and underaeration, with increased density and elevation of diaphragm on CXR under normal situation. If air-trapping is present, the dependent lung will remain hyperlucent rather than deflating as would normally. However, the sensitivity of inspiratory-expiratory radiographs is only about 80% and expiratory film can appear normal in 15-35% of all cases.⁵ Fluoroscopy, xeroradiography, xerotomography and radionuclide lung scanning have been proposed as diagnostic aids but are of limited use with attendant increased radiation exposure.

Computerized tomography scan (CT scan) is recommended in elusive cases as it can demonstrate non-opaque foreign bodies which are occult or difficult to localize and allows sensitive detection of subtle difference in parenchymal density for focal hyperaeration.⁶ Recently Magnetic Resonance Imaging (MRI) has been studied for detection of endobronchial foreign body, in particular peanut.⁷⁻⁹ In addition to being a non-invasive test without utilizing ionizing radiation, MRI can precisely locate fat-rich peanut as area of high T1 signal surrounded by the low signal air in the tracheobronchial airway. It also permits differentiation from other obstructing lesions such as granulation tissue, and observation of secondary effects such as atelectasis. The knowledge on size, location and number of the fragments before bronchoscopy can reduce the chance that small pieces of the peanut or fragments be missed thus improving the safety and efficiency of the procedure. Though the routine use of MRI as a first line investigation may be inappropriate, it is useful in patients with persistent symptoms after treatment when retained fragments are suspected.

Flexible bronchoscopy is useful in establishing diagnosis but is not recommended for therapeutic purpose

as satisfactory ventilation during the procedure may be difficult to achieve. Removal under rigid bronchoscopy is a safe, effective and often life saving procedure. Because of the smallness of the child's airway, there is no room for error in paediatric bronchoscopy. Therefore, it should only be performed in centres with a high level of experience in paediatric rigid bronchoscopy and in the presence of an anaesthetist competent in managing difficult airways in children. Successful outcome depends on the availability of endoscopic expertise, appropriate equipment (bronchoscopy with magnification, ventilation and satisfactory instrumentation) and safe paediatric anaesthesia. Complications of rigid bronchoscopy include cardiac arrhythmias, bronchospasm and cardiac arrest but they are rare. Pneumonia commonly develops in patients before and after bronchoscopy, and chest physiotherapy and antibiotics must therefore be instituted in all patients. Late complications of foreign body inhalation include bronchiectasis and persistent intractable pneumonia which may require lobectomy.

Conclusion

Foreign bodies should always be suspected in cases of repeated or difficult to treat pneumonia. Chronic, unexplained respiratory symptoms should warrant further investigation to exclude foreign body despite negative history and normal CXRs. Paediatricians should interpret the history cautiously, as parents may not report spontaneously what their children have eaten or swallowed especially for common food items like peanuts or beans which they consider irrelevant to their children's illness. Parents should be advised to avoid giving children peanuts before their molar teeth develop. Children can certainly aspirate bits of foreign bodies without a definite history of choking. Flexible bronchoscopy may facilitate diagnosis. Early diagnosis would avoid irreversible parenchymal changes which necessitate lung resection. Although various radiological and endoscopic methods can aid in diagnosis, we believe that a high index of clinical suspicion for a possible airway foreign body is needed to prevent morbidity associated with delay in diagnosis.

The removal of airway foreign bodies can be challenging even for the most experienced endoscopist. Current paediatric bronchoscopic equipments and techniques have improved the outcome for children with foreign body aspiration. ■

Key messages

1. Foreign body inhalation in children is an important clinical entity to be recognized not only by paediatricians but also family doctors or private practitioners.
2. Foreign body aspiration can mimic symptoms and signs of other common respiratory diseases e.g. pneumonia, asthma and acute bronchiolitis.
3. History of choking may be absent in patients and therefore further enquiry about recent type of food ingested may be useful.
4. Flexible bronchoscopy is an effective method in establishing the definitive diagnosis of foreign body aspiration.
5. Early diagnosis can prevent irreversible complications including bronchiectasis.

References

1. Catanco AJM, Reibschied SM, Ruiz RL, *et al*: Foreign body in the tracheobronchial tree. *Clin Pediatr*. 1997;36:701-706.
2. Meeker DP, Mehta AC. Bronchoscopy in foreign body removal. In: Wang KP, Mehta AC, editors. *Flexible Bronchoscopy*. Blackwell Science, Inc 1995.
3. Black RE, Johnson SG, Matlak ME: Bronchoscopic removal of aspirated foreign bodies in children. *J Pediatr Surg* 1994;29:682-684.
4. Wohach B, Raz A, Weinbery J, *et al*: Aspirated foreign bodies in the respiratory tract of children: Eleven years experience of 127 patients. *Int J Pediatr Otorhinolaryngol* 1994;30:1-10.
5. Capitanio MA, Kirkpatrick JA: The lateral decubitus film. An aid in determining air-trapping in children. *Radiology* 1972;103:460-462.
6. Berger PE, Kuhn JP, Kuhns LR: Computed tomography and the occult tracheobronchial foreign body. *Radiology* 1980;134:133-135.
7. Kitanaka S, Mikami I, Tokumaru A, *et al*: Diagnosis of peanut inhalation by MRI. *Pediatr Radiol* 1992;22:300-301.
8. Imaizumi H, Kaneko M, Nara S, *et al*: Definitive diagnosis and location of peanuts in the airways using magnetic resonance imaging techniques. *Ann Emerg Med* 1994;23:1379-1382.
9. O'Uchi T, Tokumaru A, Mikami I, *et al*: Value of magnetic resonance imaging in detecting a peanut causing bronchial obstruction. *Am J Radiol* 1992;159:481-482.
10. Kelly ST, Marsh BR: Airway foreign bodies. *Chest Surg Clin N Am* 1996; 6(2):253-276.
11. Brownlee KG, Crabbe DCG: Paediatric bronchoscopy. *Arch Dis Childhood* 1997;77:272-275.
12. Holinger LD. Foreign bodies of the airway and oesophagus. In: Holinger LD, Lusk RP, Green CG, editors. *Pediatric Laryngology and Bronchoesophagology*. Lippincott-Raven Publishers 1997.
13. Burton EM, Brick WG, Hall JD, *et al*: Tracheobronchial foreign body aspiration in children. *South Med J* 1996;89:195-198.