



Title	Stroke prevention by carotid endarterectomy
Author(s)	Lau, H; Cheng, SWK
Citation	Hong Kong Practitioner, 1998, v. 20 n. 9, p. 484-490
Issued Date	1998
URL	http://hdl.handle.net/10722/45393
Rights	Creative Commons: Attribution 3.0 Hong Kong License

Stroke Prevention By Carotid Endarterectomy

H Lau, FRCS(Edin), FCS(HK), MMed(Surg)(Singapore)

S W K Cheng,* FRCS(Edin), FACS, MS, FHKAM

Division of Vascular Surgery

Department of Surgery

Queen Mary Hospital

The University of Hong Kong

Summary

Cerebrovascular disease is the third leading cause of death in Hong Kong and stroke is a major cause of disability in the elderly. With increased life span, rehabilitation and care of patients with disabling stroke has become a substantial economic burden to the society and family. Prevention of stroke by carotid endarterectomy is definitely more cost-effective than treatment of stroke. Prospective randomized trials in North America and Europe have proven the benefit of carotid endarterectomy in symptomatic patients with severe carotid stenosis. The diagnosis of carotid stenosis can be easily confirmed by a duplex scan performed in experienced hands. With increased awareness of this condition, early identification of at risk patients with referral to a tertiary centre for consideration of carotid endarterectomy is able to reduce the risk of future stroke or death. (HK Pract 1998;20:484-490)

摘要

心血管疾病是本港第三大死因，而中風更是導致老年人殘疾的主要原因。隨著壽命延長，中風後殘疾護理和復康治療已成為社會及家庭的經濟沉重負擔。採用頸動脈內膜切除術預防中風遠較治療中風更為經濟。北美及歐洲前瞻性隨機試驗證實手術對有症狀的嚴重頸動脈狹窄患者有效。現在有經驗的檢查者使用多普勒擔當 duplex scan 檢查，很容易診斷出頸動脈狹窄。醫生應提高警覺，儘早診療和轉介有危險的病人，施行頸動脈內膜切除術，可以減少中風及死亡病例。

Introduction

Carotid endarterectomy was once the most common vascular procedure in the USA in the 1980s.^{1,2} However, concern for post-operative morbidity and mortality of this prophylactic procedure, particularly the risks of stroke and death, led to scepticism of its benefit. The quest

for evidence-based medicine then led to a number of controlled trials of carotid endarterectomy in North America and Europe. The North American Symptomatic Carotid Endarterectomy Trial (NASCET), comparing best medical treatment and carotid endarterectomy in symptomatic patients with critical (>70%) carotid stenosis, demon-

strated that 26% of medically treated patients (n=331) had a disabling stroke over 24 months, the stroke rate was 9% in the surgically treated group (n=328).³ An absolute risk reduction of 17% was observed. The trial was terminated early in patients with symptomatic high grade stenosis in 1991 because of the strong evidence of the benefit of carotid

* Address for correspondence : Dr Stephen Wing-keung Cheng, Associate Professor, Division of Vascular Surgery, Department of Surgery, The University of Hong Kong, Queen Mary Hospital, Hong Kong.

UPDATE ARTICLE

endarterectomy. The European Carotid Surgery Trial (ECST), which recruited 3,024 patients, reported similar results to NASCET for symptomatic patients with severe carotid stenosis. When symptomatic carotid stenosis was greater than 80%, the frequency of a major stroke or death at 3 years was 26.5% for the control group without surgery and 14.9% for the surgery group. The immediate risk of surgery is worth trading off against the long-term risk of stroke without surgery.⁴

Diagnosis

Presentation

Transient ischaemic attacks (TIAs) and stroke are the two commonest complaints encountered in patients with carotid stenosis.⁵ TIA is defined as a transient focal neurologic dysfunction of vascular origin with rapid onset and complete resolution within 24 hours. Neurologic deficits lasting longer than 24 hours but nevertheless resulting in complete resolution are termed reversible ischaemic neurologic deficits (RIND). TIAs encompass two major categories of symptoms based on the arterial territory, either carotid or vertebro-basilar. Carotid territory TIAs refer to those symptoms resulting from ischaemia to the cerebral hemisphere supplied by the terminal branches of internal carotid artery, anterior and middle cerebral arteries. Embolization to the ophthalmic branch of anterior cerebral artery gives rise to transient monocular blindness,

termed amaurosis fugax, in the ipsilateral eye. Transient hemispheric attacks (Table 1) may be associated with transient alterations in speech, motor or sensory disturbance. Vertebro-basilar TIAs are complex and often non-specific.

Clinical evaluation of patients with history of TIAs should include the identification of the affected arterial territory, the number and frequency of episodes, evidence of atherosclerosis and assessment of cardiac disease. Special attention should be paid to identify risk factors such as hypertension, diabetes mellitus, smoking, hyperlipidaemia and cardiac disease, especially atrial fibrillation.

Physical signs

Physical examination would be normal if there has been complete neurologic resolution. A carotid bruit may be the only positive physical sign in patients with significant carotid stenosis. Its

presence should alert the clinician to the possible existence of generalized atherosclerotic arterial occlusive disease. However, the presence of a carotid bruit is not diagnostic of a hemodynamically significant stenosis. The absence of a carotid bruit also does not exclude carotid artery disease as the turbulence created by the narrow stream of blood flow through a critical stenosis may not be strong enough to produce an audible bruit. The intensity of a carotid bruit does not necessarily relate to the degree of stenosis although a high-pitched carotid bruit may indicate a narrower lesion.⁶

Investigations

Patients who present with carotid territory TIAs or stroke should undergo prompt carotid duplex scan examination. Color Doppler Duplex scan has an accuracy of more than 90% in the detection of carotid stenosis but the reliability of the result depends on the skill and experience of the

Table 1: Symptoms of carotid territory transient ischaemic attacks

On the ipsilateral side of carotid stenosis

Amaurosis fugax – transient loss or blurring of vision

On the contralateral side of carotid stenosis

Motor – clumsiness, weakness, paralysis, hemiplegia
Sensory – numbness, anesthesia, hemi-paresthesia
Speech – dysarthria (non-dominant hemisphere),
motor or perceptive aphasia (dominant hemisphere)

(Continued on page 487)

UPDATE ARTICLE

operator (Figure 1).⁷ Duplex scan incorporates both B-mode ultrasound imaging and Doppler frequency analysis. It allows real-time spatial visualization of blood flow velocity in the carotid arteries and provides both anatomical and physiological evaluation. It permits morphological assessment of the stenotic plaque. Hypo-echogenic plaques represent cholesterol deposition or intraplaque haemorrhage, which may suggest instability of the plaque. Spectral analysis of Doppler frequency allows quantification of blood flow velocity and degree of stenosis. For the detection of a haemodynamic significant stenosis (>70%), a peak systolic velocity greater than 270 cm/sec and end diastolic velocity greater than 110 cm/sec has a sensitivity of 96% and positive predictive value of 93%.⁸ Carotid duplex scan is a useful non-invasive screening method of carotid stenosis.

An arch aortogram with bilateral carotid and vertebral arteriography allows full examination of the extra-cranial vessels from ascending aorta to their terminal intra-cranial branches (Figure 2). The status of carotid and vertebral arteries, adequacy of cerebral circulation and cross circulation, and the presence of unusual disease distribution or atypical anatomy can be delineated. Intra-cranial lesions, such as intra-cranial aneurysms and tumors, can also be detected. However, arteriography is not without risks and complications may occur at the puncture site, viz. bleeding, or distally. It carries a 1% risk of stroke and should be performed only if surgery is contemplated. Alternatives to conventional arteriography includes digital subtraction angio-

graphy, magnetic resonance imaging or angiography.⁹ Recently, some centres have advocated performing carotid endarterectomy on duplex data alone without an arteriogram.¹⁰⁻¹¹

Computed tomography of the brain should be performed to detect recent or old cerebral infarcts, or nonvascular intra-cranial lesions. Presentations of intracranial tumors,

Figure 1: Carotid duplex scan showing a high velocity stenosis in a patient presenting with repeated episodes of transient ischaemic attacks

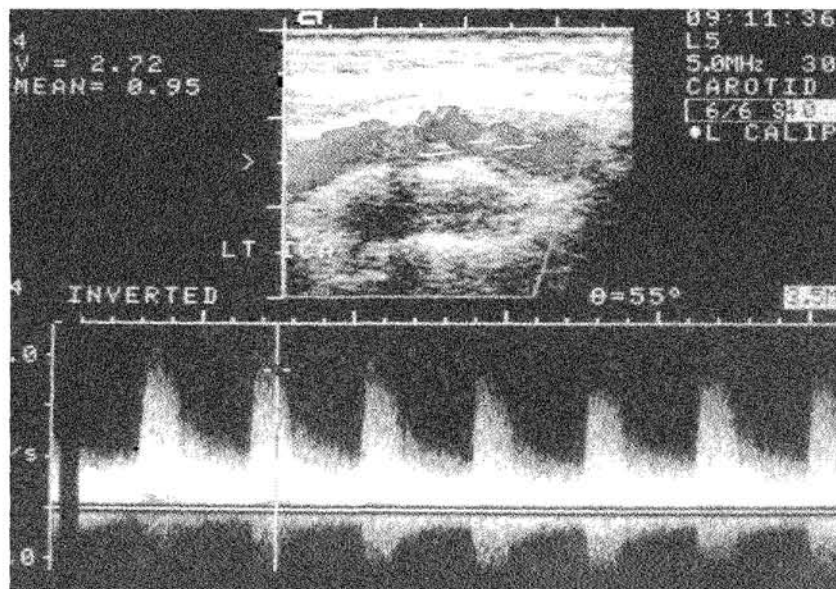
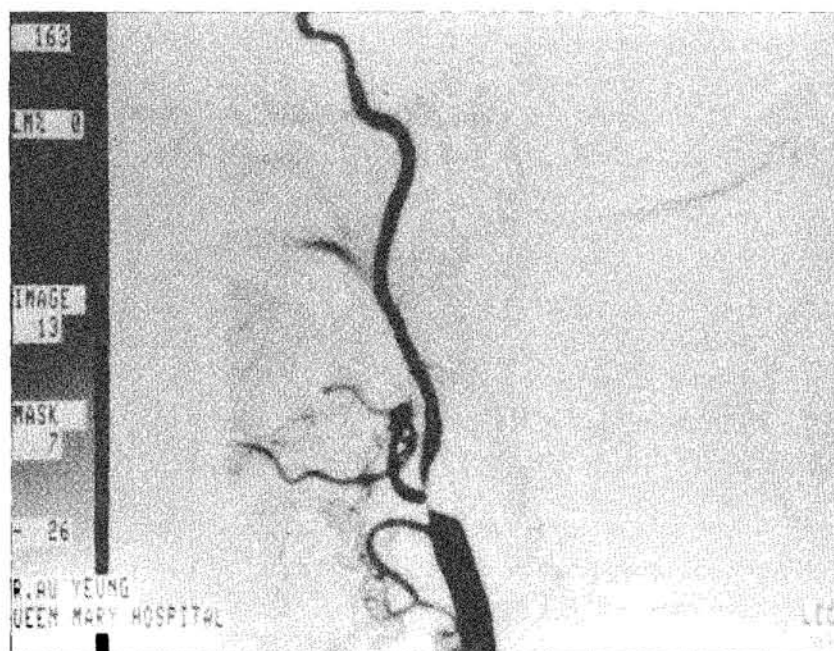


Figure 2: Carotid arteriography showing the significant stenotic lesion over the origin of the right internal carotid artery



UPDATE ARTICLE

subdural hematomas and vascular malformations can all simulate TIAs. **Table 2** shows the differential diagnoses of carotid territory TIAs.¹²

Cardiac evaluation, including transcutaneous or transoesophageal echocardiography, needs to be considered in these patients. Cardiogenic embolism is another major cause of TIAs. Thrombi may form within the heart in the presence

of atrial fibrillation, valvular disease and myocardial infarction. In addition, patients with carotid stenosis are often associated with coronary artery occlusive disease.

Management (Figure 3)


Control of risk factors and the use of anti-platelet agents are the mainstays of conservative treat-

ment.¹³⁻¹⁴ Optimal control of risk factors, viz. hypertension, diabetes mellitus, hypercholesterolaemia and cessation of smoking, should be achieved in all patients. The optimal dosage of aspirin is unclear but medium dose aspirin (75-325 mg/day) is the most widely tested antiplatelet regimen in the Antiplatelet Trialists' Collaboration overview of 145 randomized trials performed around the world.¹⁵ Ticlopidine is another effective antiplatelet agent but associated with more adverse effects.¹⁶ Antiplatelet therapy has been shown to confer a significant reduction in the risk of non-fatal stroke, myocardial infarction and vascular death in patients at high risk of occlusive vascular disease. The patient should be instructed about other possible symptoms of TIAs, with regular follow up. If the frequency of TIAs increases or the atherosclerotic occlusive lesion becomes haemodynamically significant on follow-up duplex scan examination, surgical intervention should be considered.

Table 2: Differential diagnoses of carotid territory transient ischaemic attacks

- | | |
|---|---------------------|
| • Carotid stenosis | • Hypoglycemia |
| • Cardiogenic embolism
e.g. atrial fibrillation, valvular lesions,
infective endocarditis,
myocardial infarction, etc. | • Cerebral tumor |
| • Hyperviscosity syndrome | • Epilepsy |
| • Small vessel disease | • Subdural hematoma |
| | • Drop attacks |
| | • Migraine |

Figure 3: Management algorithm for carotid stenosis



Symptomatic patients with carotid stenosis of 70-99% are now clearly indicated for surgical intervention.^{3-4,17} Carotid endarterectomy significantly reduces the mortality rate and increases stroke-free survival. Removal of the stenotic atherosclerotic plaque removes the source of embolization and prevents hypoperfusion. However, the operation carries a small risk of intra-operative stroke or death. The justification of this procedure therefore depends on the balance between the benefit and the risk of this operation. Surgical complication rates must be lower than the accepted

UPDATE ARTICLE

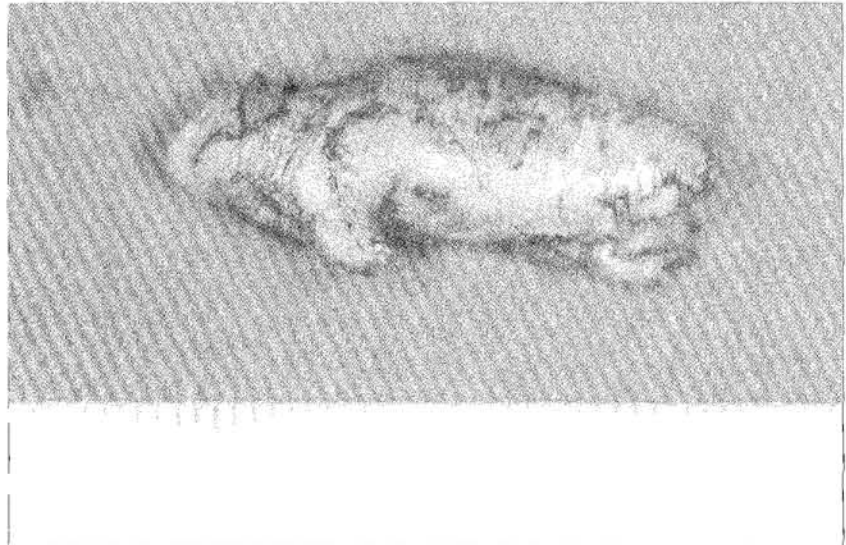limits, i.e. a perioperative stroke/mortality rate of less than 6% for symptomatic patients and 3% for asymptomatic patients.¹⁸⁻²⁰

Although the benefit margin seems narrow in asymptomatic patients with significant carotid stenosis, some patients do suffer from disabling stroke or even death without prior warning.²¹⁻²³ There is a clear correlation between the risk of stroke and the degree of stenosis.²⁴ The Asymptomatic Carotid Atherosclerosis Study (ACAS) results suggested that carotid endarterectomy combined with aspirin and risk factor reduction is superior to aspirin and risk factor reduction alone in preventing ipsilateral stroke in asymptomatic patients with diameter stenosis of the carotid artery of 60% or more.²⁵ The 5-year risk of stroke was 11% for the medical group (n = 834) and 5.1% for the surgical group (n = 825). A relative risk reduction of 53% was observed. Early surgical intervention should also be considered in patients with ulcerative plaque, multiple vessel disease and poor collateral reserve.

Operative technique

Under general anaesthesia, an incision is made along the anterior border of the sternomastoid muscle. After opening the carotid sheath, carotid arteries are gently mobilized and controlled. The vagus nerve and hypoglossal nerve should be identified and safeguarded. An arteriotomy is made over the site of occlusion and a shunt is inserted whenever feasible. Endarterectomy

Figure 4: Atherosclerotic carotid plaque removed after carotid endarterectomy



is performed, with great care in completing the endpoint in the internal carotid artery (**Figure 4**). The arteriotomy is closed with continuous 6/0 Prolene after removal of shunt. A suction drain is applied and the wound is closed in layers.

Close neuro-observation is necessary to look for neurologic complication after operation. Post-operative stroke or death is the major concern of this procedure. Other early complications include cervical hematoma, blood pressure abnormalities and nerve palsies. Patients should have bimonthly follow up after discharge. Surveillance carotid duplex scan is performed to monitor recurrence of stenosis half yearly.

Carotid angioplasty and stenting

Carotid angioplasty and stenting has recently been performed as an alternative treatment to carotid

endarterectomy. However, the safety and efficacy of carotid angioplasty and stenting have not been well proven. Published results were associated with significantly higher stroke and death rates than those of carotid endarterectomy.²⁶ Above all, the atherosclerotic plaque, a potential embolic source, is left behind even after successful stenting. Its current application should be limited to clinical trials only until the long term benefits can be resolved by large scale randomized controlled studies.²⁷

In summary

Carotid endarterectomy is a proven means of stroke prevention in symptomatic patients with 70-99% carotid stenosis. Identification of at-risk patients plays an important role in the primary health care. Patients with carotid stenosis should be referred for further assessment and follow up. ■

UPDATE ARTICLE

Key messages

1. Recognition of transient ischaemic attacks (TIAs) requires careful attention to patient's history.
2. Carotid territory TIAs have 4 main features: amaurosis fugax, motor, sensory and speech disturbance.
3. The absence of carotid bruit does not exclude the presence of significant carotid stenosis.
4. Duplex scan by an experienced staff is an accurate non-invasive method for diagnosing carotid arterial disease.
5. Carotid endarterectomy by a qualified surgeon with low peri-operative morbidity and mortality is of proven benefit in reducing the incidence of stroke in patients with severe carotid stenosis.

References

1. Thompson JE. History of carotid artery surgery. *Surg Clin North Am* 1986;66:225-231.
2. Williams N, Bell PR. Surgery for stroke: an update. *Br J Hosp Med* 1992;47:105-110.
3. Beneficial effect of carotid endarterectomy in symptomatic patients with high-grade carotid stenosis. North American Symptomatic Carotid Endarterectomy Trial Collaborators. *N Engl J Med* 1991;325:445-453.
4. Randomised trial of endarterectomy for recently symptomatic carotid stenosis: final results of the MRC European Carotid Surgery Trial (ECST). European Carotid Surgery Trialists' Collaborative Group. *Lancet* 1998;351:1379-1387.
5. Humphrey PR. Management of transient ischaemic attacks and stroke. *Postgrad Med J* 1995;71:577-584.
6. Kistler JP, Buonanno FS, Gress DR. Carotid endarterectomy—specific therapy based on pathophysiology. *N Engl J Med* 1991;325:505-507.
7. Taylor DC. Current noninvasive diagnosis of carotid artery stenosis: indications and limitations. *Can J Surg* 1994;37:114-123.
8. Neale ML, Chambers JL, Kelly AT, et al. Reappraisal of duplex criteria to assess significant carotid stenosis with special reference to reports from the North American Symptomatic Carotid Endarterectomy Trial and the European Carotid Surgery Trial. *J Vasc Surg* 1994;20:642-649.
9. Chakera TMH. Radiological investigations in stroke and transient ischaemic attacks. *Aust Fam Phy* 1991;20:1581-1584.
10. Ranger WR, Glover JL, Bendick PJ. Carotid endarterectomy based on preoperative duplex ultrasound. *Am Surg* 1995;61:548-554.
11. Gelabert HA, Moore WS. Carotid endarterectomy without angiography. *Surg Clin North Am* 1990;70:213-223.
12. Davis S. Management of transient ischaemic attacks. *Aust Fam Physician* 1991;20:1600-1603.
13. Endarterectomy for moderate symptomatic carotid stenosis: interim results from the MRC European Carotid Surgery Trial. *Lancet* 1996;347:1591-1593.
14. Moore WS, Barnett HJ, Beebe HG, et al. Guidelines for carotid endarterectomy. A multidisciplinary consensus statement from the Ad Hoc Committee, American Heart Association. *Circulation* 1995;91:566-579.
15. Collaborative overview of randomised trials of antiplatelet therapy – I: Prevention of death, myocardial infarction, and stroke by prolonged antiplatelet therapy in various categories of patients. Antiplatelet Trialists' Collaboration. *BMJ* 1994;308:81-106.
16. Gent M, Blakely JA, Easton JD, et al. The Canadian American Ticlopidine Study (CATS) in thromboembolic stroke. *Lancet* 1989;1:1215-1220.
17. Mayberg MR, Wilson SE, Yatsu F, et al. Carotid endarterectomy and prevention of cerebral ischaemia in symptomatic carotid stenosis. Veterans Affairs Cooperative Studies Program 309 Trialist Group. *JAMA* 1991;266:3289-3294.
18. Moore WS, Mohr JP, Najafi H, et al. Carotid endarterectomy: practice guidelines. Report of the Ad Hoc Committee to the Joint Council of the Society for Vascular Surgery and the North American Chapter of the International Society for Cardiovascular Surgery. *J Vasc Surg* 1992;15:469-479.
19. Rothwell PM, Slattery J, Warlow CP. A systematic comparison of the risks of stroke and death due to carotid endarterectomy for symptomatic and asymptomatic stenosis. *Stroke* 1996;27:266-269.
20. Rothwell PM, Slattery J, Warlow CP. A systematic review of the risks of stroke and death due to endarterectomy for symptomatic carotid stenosis. *Stroke* 1996;27:260-265.
21. Hobson RW2d, Weiss DG, Fields WS, et al. Efficacy of carotid endarterectomy for asymptomatic carotid stenosis. The Veterans Affairs Cooperative Study Group. *N Engl J Med* 1993;328:221-227.
22. Carotid surgery versus medical therapy in asymptomatic carotid stenosis. The CASANOVA Study Group. *Stroke* 1991;22:1229-1235.
23. Risk of stroke in the distribution of an asymptomatic carotid artery. The European Carotid Surgery Trialists Collaborative Group. *Lancet* 1995;345:209-212.
24. Eikelboom BC. Carotid endarterectomy: confidence restored. *Br J Surg* 1993;80:821-822.
25. Endarterectomy for asymptomatic carotid artery stenosis. Executive Committee for the Asymptomatic Carotid Atherosclerosis Study. *JAMA* 1995;273:1421-1428.
26. Yadav JS, Roubin GS, Iyer S, et al. Elective stenting of the extracranial carotid arteries. *Circulation* 1997;95:376-381.
27. Statement regarding carotid angioplasty and stenting. Society for Vascular Surgery, International Society for Cardiovascular Surgery, North American Chapter. *J Vasc Surg* 1996;24:900.