



Title	Myxofibrosarcoma of the sphenoid sinus
Author(s)	Lam, PKY; Trendell-Smith, N; Li, JHC; Fan, YW; Yuen, APW
Citation	Journal of Laryngology and Otology, 2002, v. 116 n. 6, p. 464-466
Issued Date	2002
URL	http://hdl.handle.net/10722/45375
Rights	Journal of Laryngology and Otology. Copyright © Cambridge University Press.

The Journal of Laryngology & Otolaryngology
June 2002, Vol. 116, pp. 464-466

Myxofibrosarcoma of the sphenoid sinus

PAUL K. Y. LAM, M.R.C.S., NIGEL TRENDSELL-SMITH, M.R.C.PATH., JIMMY H. C. LI, F.R.C.R., Y. W. FAN, F.R.C.S., ANTHONY P. W. YUEN, F.R.C.S.

Abstract

Myxofibrosarcoma was originally described as the myxoid variant of malignant fibrous histiocytoma (MFH). It is uncommon in the head and neck region. We hereby report a case of myxofibrosarcoma in the sphenoid sinuses. The diagnostic and management difficulties are discussed. Close collaboration between surgeon, radiologist, histopathologist and clinical oncologist in making accurate diagnosis and appropriate management of this rare tumour are emphasized.

Key words: Histiocytoma, Fibrous; Sphenoid Sinus

Introduction

Myxofibrosarcoma was originally described as the myxoid variant of malignant fibrous histiocytoma (MFH). It is one of the commonest sarcomas of the extremities and retroperitoneum in late adult life. The head and neck region, however, is an uncommon site with three to 10 per cent involvement.^{1,2} Primary tumour sites include the larynx, paranasal sinuses, oral cavity, salivary glands, face and scalp.^{3,4} Thirty per cent of cases were in the sinonasal tract, most commonly in the maxillary and ethmoid sinuses, whereas the sphenoid sinus is rarely involved. There are no specific clinical features of this particular tumour type, although its mass effect may occasionally be noted.⁶

Magnetic resonance imaging (MRI) and computerized tomographic (CT) scan may show malignant features such as local tissue invasion. Histopathological examination is, however, the gold standard in making a definitive diagnosis. Complete tumour resection with adequate resection margins remains the mainstay of treatment, but the roles of radiotherapy and chemotherapy are debatable.

Case report

A 55-year-old Chinese gentleman was referred to our division for management of a left nasal mass in March 2000. He complained of left-sided blood-stained rhinorrhoea for six months. On examination, a polypoidal mass was found filling the left nasal cavity. No neck nodes were palpable. CT scan and MRI of the paranasal sinus showed a soft tissue tumour in the sphenoid sinus extending through areas of cortical erosion to the nasopharynx and pituitary fossa. It occupied the nasal cavity anteriorly and the pre-pontine cistern posteriorly (Figures 1 and 2). Chest X-ray, hormone profile study, haematological and biochemical tests were all normal. The initial endoscopy-guided biopsy showed inflamed respiratory mucosa only. Further biopsies showed superficial fragments of a bland, hypocellular fibromyxoid stromal lesion. Although no firm pre-operative histological diagnosis was preferred, several differential diagnoses were considered. These included

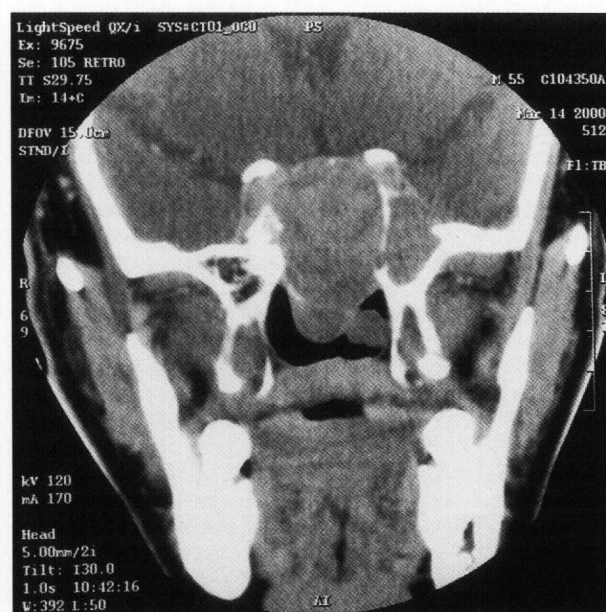


FIG. 1

Coronal CT image of the sphenoid bone showing an expansile soft tissue tumour in the sphenoid sinus with extension through areas of cortical erosion to involve the nasopharynx and the base of the left pterygoid process and pituitary fossa.

benign entities such as myxoma, superficial angiomyxoma and myxoid neurofibroma (excluded as S100 stain was negative) as well as low-grade malignancies such as myxofibrosarcoma and low grade fibromyxoid sarcoma amongst other myxoid lesions.

The lesion was excised via a mid-face degloving approach, in view of uncertain histology and radiologically aggressive features (Figure 3). The nasal septum was detached inferiorly to enhance exposure. The medial wall of the left maxillary sinus, left inferior turbinate and part of the

From the Division of Otorhinolaryngology Head and Neck Surgery, Department of Surgery and Pathology, The University of Hong Kong Medical Centre, Queen Mary Hospital, Hong Kong.

Accepted for publication: 4 December 2001.

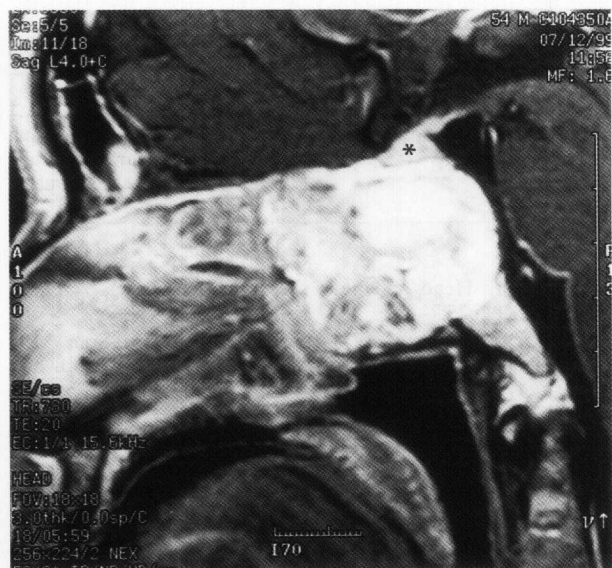


FIG. 2

Mid-sagittal enhanced T1-weighted spin-echo MR image (780/20) showing heterogeneous enhancement in the tumour which extends to the nasal cavity anteriorly and the pre-pontine cistern posteriorly. Note: pituitary gland (*).

posterior nasal septum were resected. The sphenoid sinus was opened up and complete tumour resection was achieved. The patient recovered uneventfully after the operation.

Histological examination of the resected specimen showed the typical appearances of an intermediate grade myxofibrosarcoma (myxoid malignant fibrous histiocytoma).⁶ The lesion was characterized by tumour nodules separated by fibrous septa with prominent myxoid stroma (Figures 4 and 5). Elongated, thin walled curvilinear vessels with perivascular tumour cell condensation were seen. The tumour cells stained positively for vimentin but were consistently negative for other immunohistochemical markers (including CD34, CD68, S100 and CAM5.2).

The patient was well and remained disease-free at eight months follow-up. Repeated computerized tomographic imaging and endoscopic examination showed no tumour recurrence.

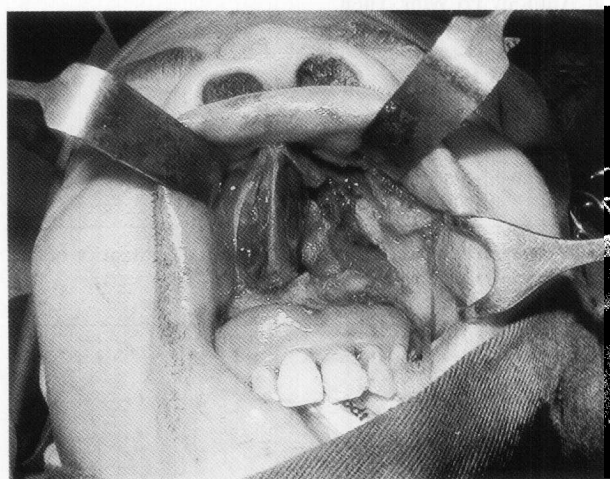


FIG. 3

Midface degloving approach for tumour resection.

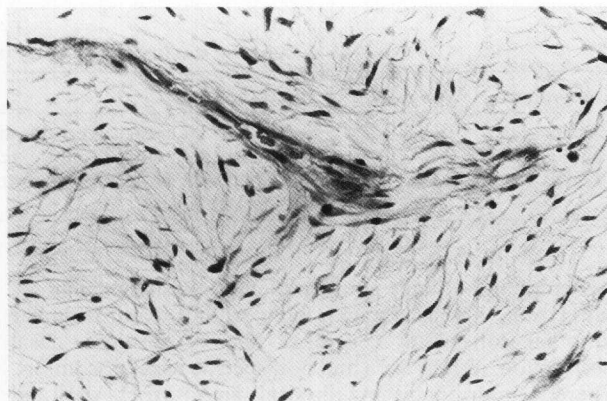


FIG. 4

Photomicrograph of intermediate grade myxofibrosarcoma showing characteristic curvilinear vessels in a myxoid paucicellular stroma. (H & E; ×100)

Discussion

MFH was first reported as a unique disease entity by O'Brien and Stout, 1964.⁷ Male preponderance was found with a ratio M:F = 3:1.⁸ The middle-aged to older adults were more commonly involved. Neck node enlargement was uncommon and mostly contributed by direct invasion rather than lymphatic dissemination. Twenty-five to 45 per cent of patients with MFH in the head and neck region developed distant metastasis, most often to the lung. It was an aggressive tumour with 20 to 42 per cent of cases developing local recurrence and 75 per cent of these happened within two years of treatment.^{2,4}

MFH consists of several histological subtypes: storiform-pleomorphic, myxoid, giant-cell, angiomatoid and inflammatory. Both angiomatoid and myxoid types carry better prognosis and the giant cell type has the worst.^{9,10} Myxofibrosarcoma was described as the myxoid variant of MFH and is one of the commonest sarcomas of the extremities and retroperitoneum in late adult life. The head and neck is uncommon for both myxofibrosarcoma and other variants of MFH.

The differential diagnosis of MFH consists of a variety of fibrous tumours and inflammatory conditions. Neuroilemmoma, fibromatosis, haemangiopericytoma and granuloma may be confused with MFH.¹¹ The clinical

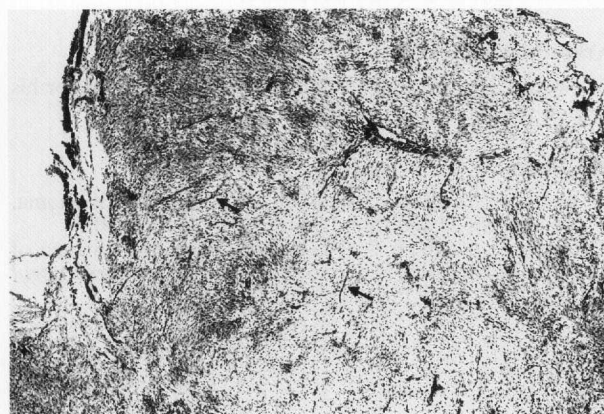


FIG. 5

Low power view of tumour showing vague nodular architecture and bland nature of tissue with prominent curvilinear vessels (arrows). (H & E; ×4)

TABLE I
CASES OF MALIGNANT FIBROUS HISTIOCYTOMA IN THE SPHENOID SINUS

Case report	Sex	Age	Tumour extent	Treatment	Results
Barnes <i>et al.</i> ²	F	67	Left sphenoid sinus-cavernous sinus	Surgery, adjuvant radiotherapy	Alive after 8 months
Blitzer <i>et al.</i> ⁴	M	66	Sphenoid sinus, intracranial extension	Radiotherapy	Died after 3 months
Present case	M	55	Left sphenoid sinus, nasopharynx and pituitary extension	Surgery	Alive after 8 months

presentation is usually not helpful in establishing diagnosis. MFH in the sinonasal tract usually exhibits features similar to other soft tissue neoplasm, namely epistaxis, nasal obstruction, rhinorrhoea and non-specific nasal discomfort. There is no distinguishing physical sign to MFH. MRI and CT scan show the extent of tumour involvement and malignant features such as adjacent tissues invasion, but are not in themselves diagnostic. Histological examination is the gold standard for diagnosis.

We report the third case of MFH and possibly the first myxofibrosarcoma in the sphenoid sinuses in the English medical literature (Table I).^{2,4} Considerable difficulty in making a definitive diagnosis prior to surgery was encountered, primarily attributed to its scarcity and non-specific clinical presentation. Complete tumour resection with adequate resection margin is essential.^{3,8,12} Local recurrence is frequent with positive resection margins. The midface degloving approach allows good exposure for surgery. The cosmetic result was good and the patient complained of transient infraorbital paresthesia only. Mild nasal crusting in the first few months could be cleaned with simple suction clearance.

Adjuvant radiotherapy is reserved for recurrent, unresectable or large lesions with a high chance of microscopic resection margin involvement; its efficacy is controversial.¹³ A post-operative watchful waiting policy was employed in this patient, because of the proximity to the optic nerves and the pituitary gland. Cyclophosphamide and vincristine have been used in metastatic myxofibrosarcoma, but the results are disappointing.¹⁴

In summary, myxofibrosarcoma is rare and aggressive in the head and neck region. It has a high propensity for local recurrence and distant metastasis. Close post-operative observation is essential. Because of its non-specific clinical presentation and bland histological appearances, definitive pre-operative diagnosis may be problematic. The current treatment is surgery for resectable lesions and radiotherapy for recurrent, unresectable lesions or tumours with positive resection margins. The value of chemotherapy in myxofibrosarcoma is still debatable.

Acknowledgement

We would like to acknowledge Dr John K. C. Chan for his help in the pathologic evaluation.

References

- Weiss SW, Enzinger FM. Malignant fibrous histiocytoma. An analysis of 200 cases. *Cancer* 1978;**41**:2250–60
- Barnes L, Kanbour A. Malignant fibrous histiocytoma of the head and neck. A report of 12 cases. *Arch Otolaryngol Head Neck Surg* 1988;**114**:1149–56
- Odell PF. Head and neck sarcomas: a review. *J Otolaryngol* 1996;**25**:7–13
- Blitzer A, Lawson W, Zak FG, Biller HF, Som ML. Clinical-pathological determinants in prognosis of fibrous histiocytomas of head and neck. *Laryngoscope* 1981;**91**:2053–69
- Russell WO, Cohen J, Enzinger F, Hajdu SI, Heise H, Martin RG, *et al.* A clinical and pathological staining system for soft tissue sarcomas. *Cancer* 1977;**40**:1562–70
- Mentzel T, Calonje E, Wadden C, Camplejohn RS, Beham A, Smith MA, *et al.* Myxofibrosarcoma. Clinicopathologic analysis of 75 cases with emphasis on the low-grade variant. *Am J Surg Pathol* 1996;**20**:391–405
- O'Brien JE, Stout AP. Malignant fibrous xanthoma. *Cancer* 1964;**17**:1445–55
- Blitzer A, Lawson W, Biller HF. Malignant fibrous histiocytoma of the head and neck. *Laryngoscope* 1977;**87**:1479–99
- Scott KM, Carter CS. Malignant fibrous histiocytoma of the larynx: case report and literature review. *J Otolaryngol* 1995;**24**:198–200
- Singh B, Santos V, Guffin TN Jr, Alexis R, Har-El G. Giant cell variant of malignant fibrous histiocytoma of the head and neck. *J Laryngol Otol* 1991;**105**:1079–81
- Sawyer R, Webb DL, Wittich DJ. Head and neck malignant fibrous histiocytomas. *Ear Nose Throat J* 1993;**72**:299–302
- Brookes GB, Rose PE. Malignant fibrous histiocytoma of the ethmoid sinus. *J Laryngol Otol* 1983;**97**:279–89
- Sasaki R, Sakai S, Itoh M, Murata M, Honda M, Aozasa K. Malignant fibrous histiocytoma in the maxillary sinus. Xanthoma-like change of the tumor after radiotherapy. *Laryngoscope* 1983;**93**:202–4
- Merk C, Angervall L, Kindblom LG, Oden A. Myxofibrosarcoma. A malignant soft tissue tumor of fibroblastic-histiocytic origin. A clinicopathologic and prognostic study of 110 cases using multivariate analysis. *Acta Pathol Microbiol Immunol Scand* **282**(suppl):1–40

Address for correspondence:
Dr Anthony Po Wing Yuen,
Department of Surgery,
The University of Hong Kong Medical Centre,
Queen Mary Hospital,
Hong Kong.

Fax: (852) 2855 3464
E-mail: pwyuen@hkucc.hku.hk

Dr A. P. W. Yuen takes responsibility for the integrity of the content of the paper.
Competing interests: None declared