



Title	Insertion of Provox®2 voice prosthesis using the anterograde technique immediately after the secondary tracheoesophageal puncture
Author(s)	Ng, RWM; Lam, P; Wong, BYH
Citation	Journal of Laryngology and Otology, 2005, v. 119 n. 12, p. 988-990
Issued Date	2005
URL	http://hdl.handle.net/10722/45369
Rights	Creative Commons: Attribution 3.0 Hong Kong License

Insertion of Provox[®]2 voice prosthesis using the anterograde technique immediately after the secondary tracheoesophageal puncture

RAYMOND W M NG, MD, FRCS(Ed), PAUL LAM, MD, FRCS(Ed), BIRGITTA Y H WONG, MD, MRCS(Ed)

Abstract

Insertion of a voice prosthesis through the tracheoesophageal puncture (TEP) is one way to restore the voice after total laryngectomy. The second generation Provox[®] voice prosthesis is presently one of the most popular devices. Although TEP can be done primarily, there are many centres that prefer it to be done at a second stage for various reasons. However, secondary TEP for retrograde replacement of prosthesis can be difficult and general anaesthesia is very often necessary. Moreover, the presence of neck stiffness and fibrosis from the surgery or previous radiotherapy could affect the neck extension for proper positioning of the trocar. Similarly, it is difficult to insert the prosthesis if there is stenosis at the pharyngoesophageal segment. We describe a technique in which creation of secondary TEP and insertion of Provox[®]2 is done with local anaesthesia under the same setting. The procedure is well tolerated and can be safely performed on an out-patient basis.

Key words: Speech, Alaryngeal; Rehabilitation; Laryngectomy; Endoscopy; Tracheoesophageal Fistula

Introduction

Insertion of a voice prosthesis through the tracheoesophageal puncture (TEP) is an important option in voice restoration following total laryngectomy.^{1,2} The second generation Provox[®] voice prosthesis (Provox[®]2, Atos Medical AB, Horby, Sweden), developed in the Netherlands Cancer Institute, is presently one of the most popular devices.^{3,4}

Although TEP for voice restoration can be done primarily during the laryngectomy, there are many centres that prefer it to be done at a second stage for various reasons.^{5–7} According to the manufacturer, secondary TEP for Provox[®]2 insertion is performed in a retrograde manner. The tracheoesophageal tract is created using a special trocar and cannula inserted transorally. The prosthesis, which is mounted on the Provox[®]2 guidewire, is pulled through the newly formed pharyngeal segment (neopharynx) until it exits at the expected TEP site.³ The technique is somewhat uncomfortable, and, most of time, general anaesthesia is required. In addition, it is difficult to pass the prosthesis through the neopharynx if stenosis is present along the pharyngoesophageal segment.

We describe a technique in which creation of secondary TEP and insertion of Provox[®]2 is done with local anaesthesia under the same setting. The procedure is well tolerated by patients and can be safely carried out on an out-patient basis.

Surgical Technique

The patient is placed comfortably in a sitting position at an angle of 30° to the horizontal plane. The nasal and

pharyngeal area is prepared for endoscopy by administration of a lidocaine spray. The proposed site for the tracheoesophageal puncture is injected with 2 ml of 1 per cent lidocaine plus 1:100000 units of adrenaline.

Transnasal oesophagoscopy (GIF-N230, Olympus, Keymed, Southend-on-Sea, UK) is performed when adequate anaesthesia is achieved, and the scope is advanced to the upper cervical oesophagus. If there is evidence of stenosis at the pharyngoesophageal segment, serial dilatation should be performed before creation of TEP. The oesophageal lumen is kept opened with insufflation of air through the endoscope. The site for tracheoesophageal puncture can be easily identified by shining the light from the endoscope within the oesophageal lumen. The puncture should be at least 5 mm postero-inferior to the mucocutaneous border of the tracheostome.

A 16 gauge intravenous cannula is inserted into the posterior tracheal wall and is directed backwards into the oesophageal lumen. Correct entrance of the cannula is confirmed by direct visualization using the endoscope. A guidewire is then inserted through the cannula into the oesophagus (Figure 1). After withdrawal of the cannula, the new tracheoesophageal fistula tract is dilated serially over the indwelling guidewire until an 8 mm external diameter is reached (Figure 2).

The length of the newly created tracheoesophageal tract is measured with the prosthesis sizer, which is inserted into the tract parallel with the guidewire. The sizing marker, seen outside the puncture site at the posterior tracheal wall, determines the appropriate size of voice prosthesis. To insert the new voice prosthesis, the dilator has to pass through the Provox[®]2 loading tube before being

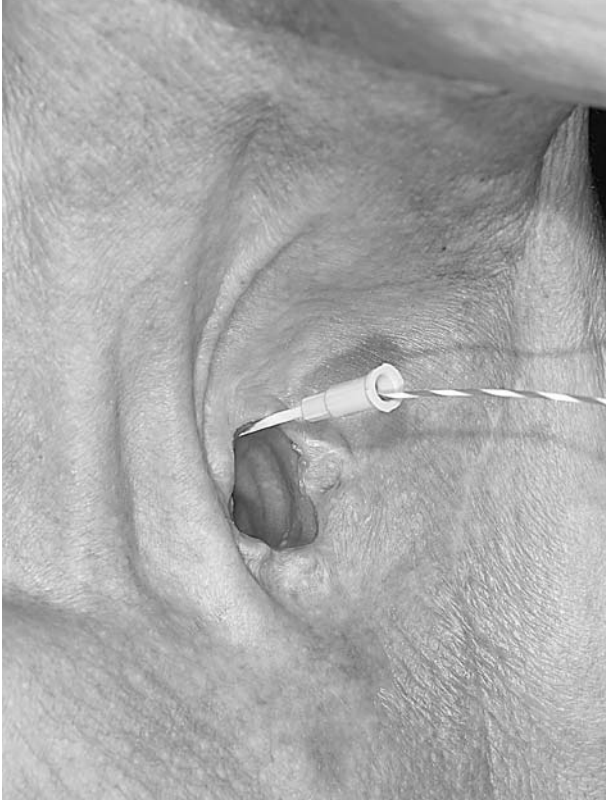


FIG. 1

The tracheoesophageal fistula is created by puncturing the posterior tracheal wall with a 16 gauge intravenous cannula into the oesophageal lumen under endoscopy examination. An indwelling guidewire is inserted to guide subsequent dilatation of the tract.

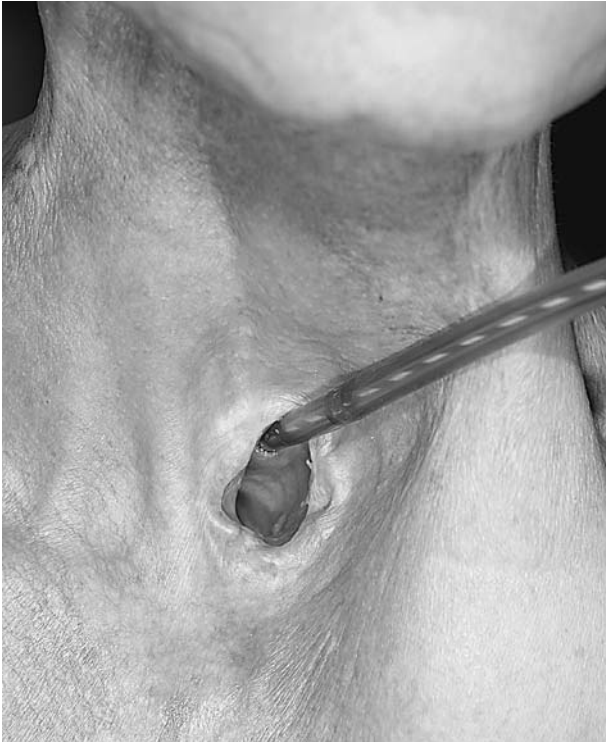

FIG. 2

The tracheoesophageal fistula tract is dilated serially using the Savary-Gilliard dilator over the indwelling guidewire until an 8 mm external diameter is reached.

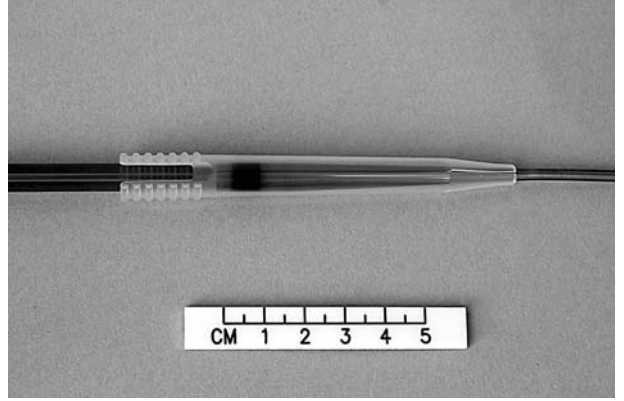


FIG. 3

The dilator is passed through the lumen of the Provox®2 loading tube.

reintroduced through the dilated tract over the guidewire (Figure 3). By doing so, the two tubes are introduced together into the oesophageal lumen (Figure 4). Keeping the loading tube fixed with one hand, the dilator and the guidewire are removed, leaving the tip of the loading tube inside the oesophageal lumen. The whole procedure is monitored with the videoendoscopy, ensuring the correct placement of the loading tube into the oesophageal lumen. The appropriate size Provox®2 prosthesis is mounted onto the introducer which is directed in an anterograde manner through the loading tube in the same way as for replacement of prosthesis.

Results

Six post-laryngectomy patients had the Provox®2 inserted using this technique in an anterograde manner. Two of them had a previously dislodged voice prosthesis leading to closure of the tract and were referred for secondary puncture. Four of the other patients had total laryngectomy performed at four to 12 month intervals.

The procedure took about 25 minutes. Size 8.0 mm Provox®2 were inserted in all cases. It was well tolerated and normal oral feedings resumed on the same day. All of the patients were referred to a speech therapist for voice rehabilitation. There have been no complications related to the creation of TEP or the insertion of the Provox®2. During the one month follow up, the voice prosthesis remained at its normal position and all patients were able to speak with the neoglottic speech.

Discussion

The second generation Provox® prosthesis (Provox®2) is a low-resistance, indwelling silicone voice prosthesis. It is one of the most popular devices for voice rehabilitation. Based on the original design, Provox®2 can be inserted in two directions. Anterogradely, the prosthesis can be replaced through an old tract from the neck with a specially designed introducer. On the other hand, a new device can be inserted in a retrograde manner through a newly created tracheoesophageal fistula tract using the trocar.³

Although primary voice restoration is possible, many centres prefer secondary TEP because of potential complications such as cervical cellulitis, mediastinitis, and leakage of saliva along the fistula tract causing aspiration pneumonia.⁶⁻⁸

However, secondary TEP for retrograde replacement of prosthesis can be difficult. In the presence of neck stiffness and fibrosis from the surgery or previous radiotherapy, it is

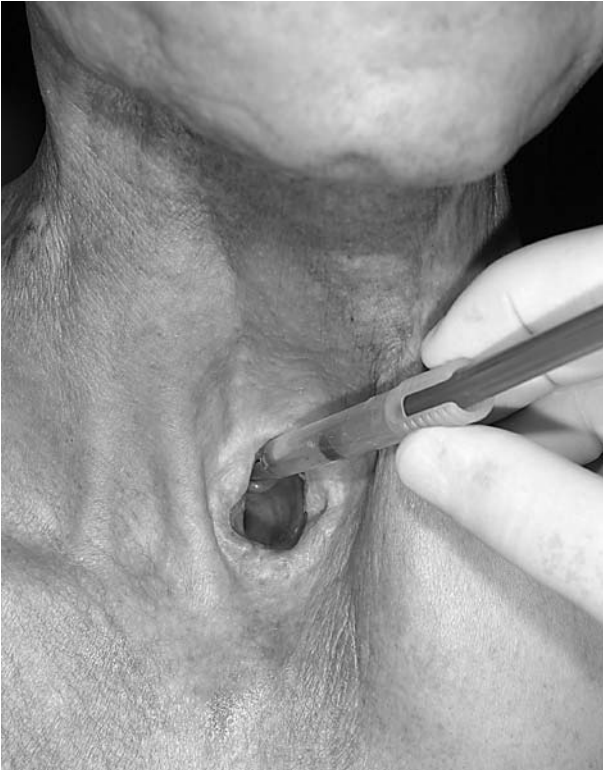

FIG. 4

The dilator and Provox®2 loading tube are inserted together into the newly created tracheoesophageal fistula tract. The loading tube serves to splint the tract when the dilator is removed. The whole procedure is under endoscopic guidance.

sometimes impossible to extend the neck for proper positioning of the trocar. Similarly, it is difficult to insert the prosthesis through the neopharynx if there is stenosis at the pharygoesophageal segment. Most of the time, the tract has to be dilated before the procedure. Furthermore, because the procedure is somewhat uncomfortable, general anaesthesia is very often necessary.

Another difficulty in creating the fistula tract is in correctly identifying the site for the puncture so as to prevent inevitable complications such as false lumen, neck abscess and haematoma. Through the use of the small calibre endoscope, the whole procedure can be monitored safely under direct vision, helping to accurately identify the correct site for puncture.⁹⁻¹¹

It is sometimes hard to keep the patency of the newly created fistula tract as it tends to close down quickly during the removal of dilator for an exchange of the prosthesis. Lau *et al.* suggested stenting the tract temporarily with a smaller catheter, which is subsequently replaced by a larger catheter and eventually the voice prosthesis.⁵ Using the technique as described, it is easy to direct the loading tube into the oesophageal lumen and to splint the newly created fistula for immediate placement of prosthesis.

Conclusion

A new technique to create a secondary tracheoesophageal puncture for immediate placement of Provox®2 voice prosthesis is described. It is simple and safe and the procedure can be performed on an out-patient basis under local anaesthesia with minimal patient discomfort.

References

- 1 Brown DH, Hilgers FJM, Irish JC, Balm AJ. Post-laryngectomy voice rehabilitation: State of the art at the millennium. *World J Surg* 2003;**27**:824-31
- 2 Stafford FW. Current indications and complications of tracheoesophageal puncture for voice restoration. *Curr Opin Otolaryngol Head Neck Surg* 2003;**11**:89-95
- 3 Hilgers FJM, Schouwenburg PF. A new low-resistance, self-retaining prosthesis (Provox®) for voice rehabilitation after total laryngectomy. *Laryngoscope* 1990;**100**:1202-5
- 4 Hilgers FJM, Ackerstaff AH, Balm AJM, Tan IB, Aaronson NK, Persson JO. Development and clinical evaluation of a second-generation voice prosthesis (Provox®2), designed for anterograde and retrograde insertion. *Acta Otolaryngol* 1997;**117**:889-95
- 5 Lau WF, Wei WI, Ho CM, Lam KH. Immediate tracheoesophageal puncture for voice restoration in laryngopharyngeal resection. *Am J Surg* 1988;**156**:269-72
- 6 Ruth H, Dans WE, Renner G. Deep neck abscess after tracheo-oesophageal puncture and insertion of a voice button prosthesis. *Otolaryngol Head Neck Surg* 1985;**93**:809-11
- 7 Andrews JC, Mickel RA, Hanson DG, Monahan GP, Ward PH. Major complications following tracheoesophageal puncture for voice rehabilitation. *Laryngoscope* 1987;**97**:562-7
- 8 Spiro JD, Spiro RH. Retropharyngeal abscess and carotid hemorrhage following tracheoesophageal puncture and voice prosthesis insertion: a case report. *Otolaryngol Head Neck Surg* 1990;**102**:762-3
- 9 Maniglia AJ. Vocal rehabilitation after total laryngectomy: a flexible fiberoptic endoscopic technique for tracheoesophageal fistula. *Laryngoscope* 1982;**92**:1437-9
- 10 Mazzara CA, Baredes S. Technique of tracheoesophageal puncture using flexible fiberoptic esophagoscopy. *Laryngoscope* 1993;**103**:928-9
- 11 Bach KK, Postma GN, Koufman JA. In-Office tracheoesophageal puncture using transnasal esophagoscopy. *Laryngoscope* 2003;**113**:173-6

Correspondence to:

Raymond W M Ng,
Division of Head & Neck Surgery,
Department of Surgery,
University of Hong Kong Medical Centre,
Queen Mary Hospital, 102 Pokfulam Road,
Hong Kong SAR, China

E-mail: ngwmm@hkucc.hku.hk

Dr R W M Ng takes responsibility for the integrity of the content of the paper.

Competing interests: None declared