



Title	Breast reconstruction with transverse rectus abdominis musculocutaneous (TRAM) flap in young women with breast cancer
Author(s)	Mak, ASY; Poon, AMS; Kwan, KH; Tung, MK
Citation	Hong Kong Practitioner, 1995, v. 17 n. 3, p. 112-119
Issued Date	1995
URL	http://hdl.handle.net/10722/45290
Rights	Creative Commons: Attribution 3.0 Hong Kong License

DISCUSSION PAPER

Breast Reconstruction With Transverse Rectus Abdominis Musculocutaneous (TRAM) Flap In Young Women With Breast Cancer

Mak Sze Yuen*, MBBS, FRCS,
FHKAM (Surgery)
Senior Medical Officer

Poon Ming See, MBBS, MPhil, PhD
Lecturer

Department of Physiology
The University of Hong Kong
Kwan Kin Hung, MBChB, FRCS

Medical Officer
Tung Man Kwong, MBBS, FRCS,
FHKAM (Surgery)
Consultant

Plastic & Reconstructive Surgery Team
Princess Margaret Hospital

Introduction

The most frequently used techniques of breast reconstruction after mastectomy are tissue expansion (followed by insertion of a silicone prosthesis) and autogenous flaps. The most commonly employed autogenous flaps are latissimus dorsi musculocutaneous flap and transverse rectus abdominis musculocutaneous (TRAM) flap¹. Breast reconstruction with autogenous tissue provides a more natural breast contour with characteristics resembling breast parenchyma. Latissimus dorsi musculocutaneous flap usually requires an underlying implant whereas TRAM flap offers the advantages of avoiding an implant and the associated concerns of implant infection, extrusion, leakage, capsular contracture and possible autoimmune disease. TRAM flap also provides the patient with an abdominoplasty at the donor site. Though the surgical time for the initial procedure is shorter in the tissue expander/implant group, the number of procedures, revision stages and dissatisfaction rates are significantly higher than the TRAM flap group². The failure rate after tissue expansion (21%) is significantly higher than those observed with the TRAM (3%) or latissimus dorsi (9%) flaps³. Since its original description in 1982⁴, the TRAM flap has become a particularly attractive reconstructive option among young women who are increasingly afflicted by breast carcinoma⁵.

Some women are poor or questionable candidates for TRAM flap breast reconstruction. Certain medical conditions like diabetes mellitus, cardiac and pulmonary diseases are not suitable for a safe TRAM flap procedure either because of the magnitude of the procedure or because the

Summary

Since its introduction in 1982, the transverse rectus abdominis musculocutaneous (TRAM) flap has become the standard for autogenous breast reconstruction. However, it has serious potential complications. In this article, the 10 TRAM flaps performed at Princess Margaret Hospital from December 1993 to September 1994 for young women with breast carcinoma were evaluated to assess the safety and complications of this technique. Majority of the patients were satisfied with the cosmetic outcome.

Keywords: Breast carcinoma, mastectomy, breast reconstruction, myocutaneous flap, autologous flap.

*Address for correspondence: Dr. Mak Sze Yuen, Senior Medical Officer, Plastic & Reconstructive Surgery Team, Princess Margaret Hospital, Hong Kong.

Breast Reconstruction with TRAM Flap in Young Women with Breast Cancer

microcirculation or oxygen delivery is compromised. Women with mental problems will be poor candidates because the TRAM flap requires a major investment of time and effort. They must be psychologically stable and have good social support. Overweight (weight 25% greater than ideal body weight) or elderly women and heavy smokers have a higher risk of developing complications⁶. Thin patients often result in a tight closure of the abdominal wound and a less attractive scar.

The TRAM flap has the disadvantage of being a complex and expensive procedure requiring longer hospitalization and recovery. Potential complications may be severe. Early complications include haematoma, seroma, infection, TRAM flap necrosis (i.e., partial or total flap necrosis) and abdominal complications (e.g. abdominal skin-edge necrosis, umbilical necrosis). Late complications are fat necrosis, abdominal-wall bulging and hernia. Fortunately, complications leading to prolonged disability have been rare and failure to achieve an acceptable result has been uncommon. These complications can usually be resolved successfully.

Since December 1993, TRAM flap has become our method of choice for young women (less than 45 years of age) with early (Stages I and II) breast cancer asking for reconstruction. The following is a review of the TRAM flaps performed by our team.

Materials and Methods

Patients

From December 1993 to September 1994, 10 TRAM flaps were performed for 10 patients (Table 1). All patients were non-smokers and the right breast to left breast ratio was 3 to 7. Four patients were nulliparous. Eight reconstructions were performed immediately after mastectomies. Two reconstructions were delayed, namely, 14 and 16 months after mastectomies. One patient had a lower midline scar for appendicectomy and one had a lower midline scar for ectopic pregnancy. One patient had a history of chronic schizophrenia which was only discovered after the operation, following a relapse.

Table 1: TRAM Flap Breast Reconstruction in 10 Patients with Carcinoma of the Breast

Patient	Age (years)	Weight (Kg)	Past Health	Right/Left Breast	Staging	Operative Time	Blood Loss(ml)
1. MHS	32	50.5	good	left	II	7 hr 5 min	1000
2. YKT*	35	56.0	appendicectomy, thyroidectomy	left	II	5 hr 40 min	1400
3. SFF	45	52.0	good	right	I	6 hr 5 min	1000
4. CYL	31	55.5	good	left	I	5 hr 40 min	2000
5. PCY*	43	44.4	good	left	I	3 hr 30 min	1200
6. MLC	45	72.3	schizophrenia	left	II	5 hr 25 min	2000
7. KCC	44	59.2	good	right	II	4 hr 30 min	1200
8. FLW*	39	75.0	ectopic pregnancy	left	I	4 hr 30 min	600
9. SCL*	37	77.0	good	right	I	4 hr 40 min	1500
10. SWW	36	58.5	good	left	I	3 hr 15 min	900

* nulliparous

Technique

The procedure for TRAM flap breast reconstruction is depicted in Figure 1. A single rectus muscle pedicle was used for unilateral reconstruction. Nine of the 10 TRAM flaps performed employed the contralateral rectus muscles while the ipsilateral rectus muscle was used in only one patient. The full width of the rectus abdominis muscle below the arcuate line was harvested with the TRAM flap. Zone IV of the flap was discarded because of its unreliable vascularity⁷. All the anterior rectus sheath defects could be repaired in one layer without the use of synthetic mesh. Suction drains were put in the tunnel, chest and abdominal wounds.

Figure 1: Diagrammatic Demonstration of Single-pedicle Contralateral TRAM Flap Reconstruction of the Breast

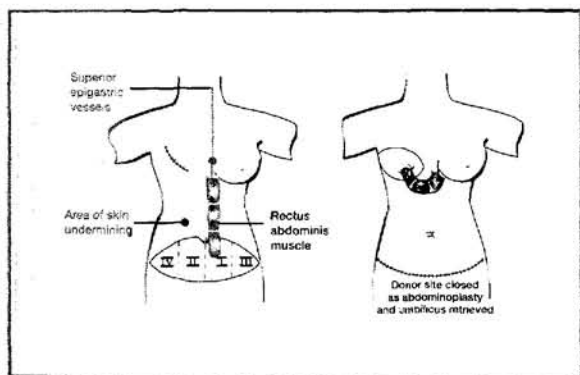


Figure 2: A Left Immediate TRAM Flap Breast Reconstruction in a 35 Years Old Woman

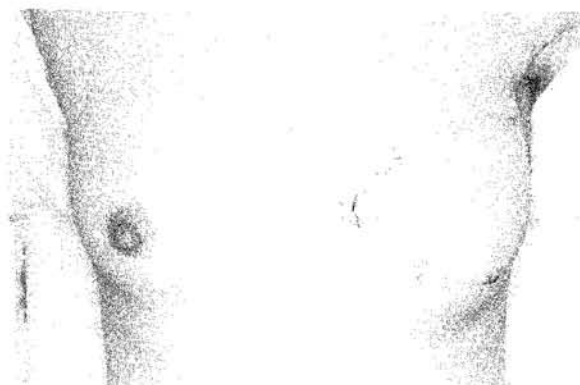
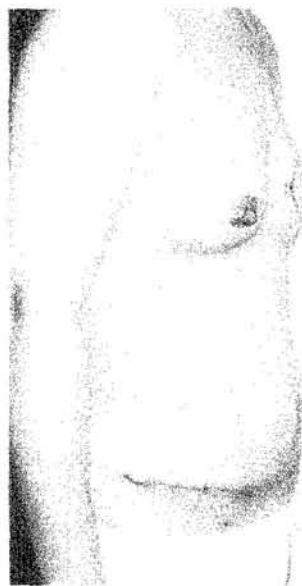

Figure 3: Lateral View of the same Patient as Figure 2



Results

The age of our patients ranged from 31 to 45 years (mean 38.7 years). The body weights ranged from 44.4 kg to 77.0 kg (mean 60.0 kg) (Table 1). The operative time ranged from 3 hr 30 min to 7 hr 5 min for immediate reconstruction (mean 5 hr 19 min). For the two delayed flaps, the mean duration was 3 hr 52 min. The mean blood loss was 1337.5 ml (ranged from 600 ml to 2000 ml) for immediate reconstruction and 1050 ml for delayed reconstruction (Table 1). All patients were discharged after the stitches were removed. The mean duration of hospital stay following the operation was 18.6 days.

All patients had infiltrating ductal carcinoma of the breast. Four were of pathologic stage I and six of stage II (Table 1).

No haematoma or seroma were encountered in these patients. Two patients complained of dysuria for a few days but their urine cultures were negative. This may be due to Foley catheterization during the operation. There was no abdominal skin-edge or umbilical necrosis.

The schizophrenic patient had partial necrosis (30%) of the TRAM flap at its zone II. TRAM flap skin-edge necrosis of less than 1 cm² was found in two patients and was self-limiting. No late complications such as hernia or fat necrosis were identified at follow-up. Up to now, only one patient requested nipple-areola reconstruction which was performed 10 months after the breast reconstruction.

Acceptability of the TRAM flap to the patients was assessed during follow-up by asking the patients to rate the results subjectively as good, satisfactory, fair or poor. Eight patients considered the results as good, one satisfactory and one fair.

Discussion

In the past two decades, the methods available for post-mastectomy breast reconstruction have changed significantly. Many patients nowadays are more aware of the different methods available. There is an increasing use of immediate breast reconstruction which involves lower risk of major or minor complications when compared to delayed reconstruction⁸. However, the patients must be well informed that additional procedures such as nipple reconstruction, revision of reconstruction and contralateral breast surgery may be necessary to produce a symmetrical, aesthetic breast appearance.

The single-pedicle TRAM flap is nourished by the superior epigastric artery within the rectus abdominis muscle, the blood circulation within the flap is not generous especially in zones II and IV which are contralateral to the rectus muscle (Figure 1). The reported incidence of partial TRAM loss was around 10%^{2,9,10}. In order to lower the flap complication rate, we only performed TRAM flap breast reconstruction on healthy, pre-menopausal and non-smoking patients whose micro-circulation was not

compromised. All of our patients enjoyed good health previously except the one with chronic schizophrenia. We had specifically asked for a history of mental illness before the operation, however the patient and her daughter denied any previous psychiatric illness and the patient appeared to be calm and stable. Unfortunately, it was this patient who presented with the only major flap complication. Thirty percent of her flap was necrosed. This corresponded exactly to zone II of the TRAM flap. The patient had a relapse of schizophrenia on the day following the operation. Revision of the flap with excision of the necrotic tissue and rotation of the rest of the TRAM flap for secondary closure was performed 5 weeks after the reconstruction. The final result was satisfactory to both the patient and the surgeon. This patient also had the longest hospital stay amongst our 10 patients. The other nine patients were discharged on the fifteenth post-operative day, following removal of stitches.

Although obesity is often considered to be a contraindication to the TRAM flap because of an increased complication rate¹¹, it does not represent an absolute contraindication if the obesity is not complicated by other risk factors¹². We encountered no particular problems with relatively obese women over 70 kg in weight. The TRAM flap breast reconstruction has also been shown to be a reliable procedure for very thin patients¹³. Four of our ten TRAM flaps were performed on nulliparous women. Although nulliparous women usually have tighter abdominal skin, we found no special problems when closing the abdominal donor site. Two of our patients had lower midline incision scars. The blood flow across the midline was definitely interrupted in the presence of a midline scar. This was confirmed during operation when a distinct delineation was noted at the midline incision after the flap was raised. This meant that zone II and zone IV should be discarded in these patients to avoid any flap necrosis afterwards.

Breast Reconstruction with TRAM in Young Women with Breast Cancer

We had two delayed reconstructions. Both had received post-mastectomy radiotherapy. Contralateral TRAM flaps were used in these two patients owing to the possible irradiation effects on the ipsilateral superior epigastric vessels.

Immediate breast reconstruction has become an increasingly appealing option⁸. This has obvious psychological advantages particularly for young women. There were concerns that immediate breast reconstruction might compromise the tumour ablative procedure, alter survival and impede either the detection or treatment of cancer recurrences. Recent studies have shown that cancer treatment, recurrence and patient survival are not adversely affected by the timing of breast reconstruction¹⁴⁻¹⁷. Also the presence of the musculocutaneous flap does not obstruct the administration of any therapy¹⁸. There is no evidence that there is an increased chance of local recurrence with immediate breast reconstruction¹⁹. Furthermore, immediate reconstruction is less costly, requires a shorter hospital stay and involves only one anaesthetic^{2,20}.

Our mean operative time of total mastectomy and axillary clearance followed by immediate breast reconstruction was 5 hr 19 min. The fastest time was 3 hr 30 min when a two-team approach was employed. One team performed the mastectomy while the other raised the abdominal flap. However, this approach was abandoned because of the fear of disseminating the tumour cells to the abdominal wound. Nevertheless, our operative time was comparable to other world series^{8,10}.

The TRAM flap sacrifices almost the whole rectus abdominis muscle, so there are concerns about abdominal-wall weakness as well as potential worsening of posture and back pain. Studies have shown that there is a measurable deficit in abdominal function following single-pedicle TRAM flap reconstruction, but this deficit is not incapacitating to the majority of patients with regard to daily activities, work and sports. Abdominal herniation is a rare occurrence⁵. The

use of synthetic mesh for closure of the anterior rectus sheath defect is controversial. Kroll and Marchi have demonstrated mesh reinforcement can lower the incidence of abdominal weakness, bulge or herniation²¹. We found no difficulty in closing the anterior rectus sheath defect because we did not remove the whole width of the anterior rectus sheath with the muscle. Up to now, we do not have any complaints about abdominal-wall weakness, bulge or herniation. TRAM flap will not prevent a normal pregnancy and delivery²². This is particularly important because many of our patients were at the child-bearing age.

Conclusion

The TRAM flap breast reconstruction is a useful technique that consistently achieves superior results in the breast. It is the most technically demanding of the commonly used techniques for breast reconstruction with the exception of microvascular free tissue transfers. With increasing experience, the complications related to the TRAM flap can be significantly reduced. At present, we only perform TRAM flap breast reconstruction for young and healthy women with breast carcinoma because they carry a much lower rate of complication. We find that this technique produces a breast similar in size, texture and shape to the contralateral breast. ■

References

1. Bostwick J III. *Plastic and Reconstructive Breast Surgery*. Vol I and II. Quality Medical Publishing Inc, 1990.
2. Crespo LD, Eberlein TJ, O'Connor N, Hergrueter CA, Pribaz JJ, Eriksson E. Postmastectomy complaints in breast reconstruction. *Ann Plast Surg* 1994; 32: 452-456.
3. Kroll SS, Baldwin B. A comparison of outcomes using three different methods of breast reconstruction. *Plast Reconstr Surg* 1992; 90: 455-462.
4. Harrampf CR Jr, Scheffan M, Black PW. Breast reconstruction following mastectomy with a transverse abdominal island flap: Anatomical and clinical observations. *Plast Reconstr Surg* 1982; 69: 216-224.
5. Mizgala CL, Harrampf CR Jr, Bennett GK. Assessment of the abdominal wall after pedicled TRAM flap surgery: 5- to 7- year follow-up of 150 consecutive patients. *Plast Reconstr Surg* 1994; 93: 988-1002.
6. Kroll SS. Necrosis of abdominoplasty and other secondary flaps after TRAM flap breast reconstruction. *Plast Reconstr Surg* 1994; 94: 637-643.

7. Hartrampf CR Jr. Hartrampf's Breast Reconstruction with Living Tissue. Raven Press, New York, 1991.
8. Trabulsi PP, Anthony JP, Mathes SJ. Changing trends in postmastectomy breast reconstruction: a 13-year experience. *Plast Reconstr Surg* 1994; 93: 1418-1427.
9. Schusterman MA, Kroll SS, Weldon ME. Immediate breast reconstruction: why the free TRAM over the conventional TRAM flap? *Plast Reconstr Surg* 1992; 90: 255-261.
10. Jacobsen WM, Meland NB, Woods JE. Autologous breast reconstruction with use of transverse rectus abdominis musculocutaneous flap: Mayo Clinic experience with 147 cases. *Mayo Clin Proc* 1994; 69: 635-640.
11. Kroll SS, Netscher DT. Complications of TRAM flap breast reconstruction in obese patients. *Plast Reconstr Surg* 1989; 84: 886-892.
12. Berrino P, Campora E, Leone S, Zappi L, Nicosia F, Santi P. The transverse rectus abdominis musculocutaneous flap for breast reconstruction in obese patients. *Ann Plast Surg* 1991; 27: 221-231.
13. Tzamas CD. Transverse rectus abdominis musculocutaneous flaps for lightweights: is a pinch enough? *Ann Plast Surg* 1993; 31: 262-264.
14. Georgiade GS, Georgiade N, McCarty KS, Seigler HF. Rationale for immediate reconstruction of breast following modified radical mastectomy. *Ann Plast Surg* 1982; 8: 20-28.
15. Noone RB, Murphy JB, Spear SL, Little JW III. A 6-year experience with immediate breast reconstruction after mastectomy for cancer. *Plast Reconstr Surg* 1985; 76: 258-269.
16. Johnson CH, van Heerden JA, Donohue JH, Martin JK Jr, Jackson IT. Oncological aspects of immediate breast reconstruction following mastectomy for malignancy. *Arch Surg* 1989; 124: 819-823.
17. Beasley ME. The pedicled TRAM as preference for immediate autogenous tissue breast reconstruction. *Clin Plast Surg* 1994; 21: 191-205.
18. Slavin SA, Love SM, Goldwyn RM. Recurrent breast cancer following immediate reconstruction with myocutaneous flaps. *Plast Reconstr Surg* 1994; 93: 1191-1204.
19. Elliott LF, Eskenazi L, Beegle PH Jr, Podres PE, Drazan L. Immediate TRAM flap breast reconstruction: 128 consecutive cases. *Plast Reconstr Surg* 1993; 92: 217-227.
20. Elkowitz A, Cole S, Slavin S, Seibert J, Weinstein M, Shaw W. Various methods of breast reconstruction after mastectomy: an economic comparison. *Plast Reconstr Surg* 1993; 92: 77-83.
21. Kroll SS, Marchi M. Comparison of strategies for preventing abdominal-wall weakness after TRAM flap breast reconstruction. *Plast Reconstr Surg* 1992; 89: 1045-1053.
22. Chen L, Hartrampf CR Jr, Bennett GK. Successful pregnancies following TRAM flap surgery. *Plast Reconstr Surg* 1993; 91: 69-71.

**** **** **** **** **** **** ****

CUMULATIVE HIV/AIDS STATISTICS IN HONG KONG

Updated 31 December, 1994

		TOTAL	(AIDS)
SEX	Male	478	(122)
	Female	42	(8)
ETHNICITY	Chinese	346	(90)
	Non-Chinese	174	(40)
TRANSMISSION ROUTES	Homo/Bisexual	190	(68)
	Heterosexual	212	(41)
	IVDU	11	(2)
	Blood/Blood Products Recipients	66	(12)
	Perinatal	1	(1)
	Undetermined	40	(6)
	TOTAL	520	(130)

Enquiries may be directed to the AIDS Counselling and Health Education Service (Telephone: 2780 8622)