



Title	Ear piercing: A review on the legislative regulations and potential health hazards; its relevance to family physicians
Author(s)	Poon, AMS; Mak, ASY
Citation	Hong Kong Practitioner, 2005, v. 27 n. 5, p. 192-196
Issued Date	2005
URL	http://hdl.handle.net/10722/45287
Rights	Creative Commons: Attribution 3.0 Hong Kong License

Ear piercing: A review on the legislative regulations and potential health hazards; its relevance to family physicians

Angela M S Poon 潘明施, Anthony S Y Mak 麥思源

Summary

Ear piercing is very popular. Legislation regulating the practice of ear piercing is lacking in Hong Kong. Complications arising from this normally low risk procedure do occur, especially with high ear piercing and improper techniques or instruments. This article reviews the existing legislations governing ear-piercing in different countries and the potential health hazards associated with ear-piercing. We hope to increase the awareness of the general public and primary care physicians to the potential serious medical problems that can result from such a minor procedure, which is performed for cosmetic reasons; and to prevent these complications from happening.

摘要

穿耳常被視為時裝或潮流的一部份，目前香港對此並無法律管制。由於穿耳的技術、設備以及穿洞的位置過高等問題，使這個低危險的操作也會出現併發症。本文回顧不同國家對穿耳的規管情況，穿耳的潛在危險和注意事項，希望提高家庭醫生和市民對穿耳的認識和警惕性，減少併發症。

HK Pract 2005;27:192-196

Angela M S Poon, MBBS, MPhil, PhD

Associate Professor.

Department of Physiology, Faculty of Medicine, The University of Hong Kong.

Anthony S Y Mak, MBBS, FRCS, FCSHK, FHKAM (Surgery)

Director.

Hong Kong Plastic and Cosmetic Surgery Centre.

Correspondence to : Dr Angela M S Poon, Department of Physiology, Faculty of Medicine, The University of Hong Kong, 21 Sassoon Road, Hong Kong.

Introduction

Ear piercing is now regarded as a part of fashion. High ear piercing and multiple piercing sites are becoming increasingly popular, both in the female and male. Ear piercing also takes place frequently in young children. Since there is no legislation regulating the practice of ear piercing in Hong Kong, complications like infections can occur with improper instruments and poor aseptic techniques. This article reviews the existing legislations governing ear-piercing in different countries and the potential health hazards associated with ear-piercing, especially those associated with high ear piercing and improper techniques or instruments. We hope to increase the awareness of the general public and primary care physicians to the potential serious medical problems that can result from such a minor procedure performed for cosmetic reasons so as to prevent these complications from happening.

History of ear piercing

The history of human beings wearing earrings is about 8,000 years old. The earliest earrings in the world were excavated in Inner Mongolia (內蒙古). These earrings were found in pairs and made from polished stones with diameters ranging from 2.5 to 6mm. Earrings made from bronze have also been excavated from Hubei (湖北) and dated back to Xia Dynasty (夏朝) about 4,000 years ago. The oldest mummified body in the world, which dated back over 5,000 years and found frozen in an Austrian glacier, had its ears pierced with holes enlarged to 7-11 mm diameters. Over the years in different parts of the world, ear piercing has been performed for cosmetic, magical or ritual purposes. Wearing precious jewels has always been a way to show wealth and standing. Archaeological evidence gathered

in China have shown that ear piercing was practiced in both man and women 8,000 years ago although it is now more common in females.

Legislations on ear piercing

Legislations on ear piercing and the stringency of control over this practice vary in different countries. In the UK, the local government has powers to control ear piercing, in whatever form, by licensing or by registration and bylaws for ear piercing businesses related to hygienic and safe practice.¹ In the US, most of the states require that the body piercing premises or businesses and the piercers are registered or certified by the local health authorities in order to ensure proper standards of practice. Individuals who pierce only the lobe of the ear (and the outer perimeter in Iowa) with a presterilized single-use stud-and-clasp ear piercing system are exempted from these regulations (or given a limited ear piercing registration in Northern Kentucky).²⁻⁴

In Australia, it is a licensable public health risk activity to operate, manage or control a business, charity, give demonstration or service that carries out a skin penetration procedure. However, closed ear piercing (a process by which the ear piercing that is carried out on the lower lobe of the ear by means of an apparatus that does not come into contact with the skin and can be operated only by the use of sealed and pre-sterilized disposable fittings) is excluded.⁵

In China, since May 2002, premises or personnel providing medical cosmetic services (including body piercing) are required to apply to 衛生行政部門 to register according to 醫療機構管理條例 and 醫療機構管理條例實施細則.⁶ In Japan, the regulation over ear piercing is very strict and ear piercing must be done by qualified medical personnel.

In Hong Kong, there is no regulation governing the practice of ear piercing. Attempts have been made to increase the general awareness of the potential risks of body piercing.^{7,8} The Health Department is drafting a document on “recommended guidelines on infection control for skin penetration practice” for reference by the trade and operators engaging in skin penetration practices. Views and comments are being consolidated now.^{7,8}

In the UK, while a person must be 18 years of age before they have a tattoo, there is no statutory age limit

for cosmetic body piercing including ear piercing. In the London Boroughs age restrictions vary because each Borough can independently use its licensing powers to impose conditions relating to age.⁹ In the US, the law also requires ear piercing in minors to be done either in the physical presence of a parent or legal guardian or with their written (or verbal in some states) permission.¹⁰ In Oregon, after the outbreak of infections in 2000, the state has banned the use of the type of gun used on those infected.¹¹

Technique of ear piercing

Ear piercing can be done by needles or ear piercing guns. In Hong Kong, piercing guns are widely used as they are generally considered to be “safe”, “easy to use” and “painless”. Most piercing guns consist of a spring-loaded action or are pressure driven. They are made of plastic or metal-encased plastic and thus cannot be sterilized in an autoclave. Very often these guns are wiped clean with alcohol or hydrogen peroxide which is not effective against viral infections like hepatitis or AIDS. Contact of the gun with the wound may introduce infective organisms and cause cross infections. In order to reduce the risk of introducing infections, ear piercing should also follow a strict aseptic technique. Sealed presterilized single-use stud-and-clasp earrings should be used and contact of the gun with the wound should be avoided. With the use of a piercing gun, the sharpened end of the ear stud is forced through the ear. Poorly designed guns or improper use of guns may result in a ragged tear with lacerations and cause tissue distortions providing a good hiding place for bacteria. This is especially true for those low quality earrings with thick posts which are poorly polished and may not even be sterile. The butterfly backing may also collect discharge and dirt favouring the growth of bacteria. Thus, careful choice of gun and jewelry is important in reducing trauma. Although strict aseptic technique of piercing can ensure against infection introduced at the time of piercing, proper aftercare of the wound on the part of the subject is equally important in preventing infections which may be acquired after the piercing procedure.

Complications of ear piercing

Ear piercing has been associated with many medical problems including local infection, sepsis, superficial cervical lymphadenopathy, oedema and haematoma.

localized discolouration, contact dermatitis, exuberant granulation tissue, scars, keloids and earlobe deformities together with embedded earrings, aspiration and ingestion of the jewels.^{12,13} The following is a review of the more serious complications reported.

(i) Infections

Infectious organisms may be introduced at the time of piercing with non-sterile techniques or by contaminated instruments/earrings and during healing when the wound is not kept clean. The presence of a foreign body by itself increases the risk of infection and prolongs the healing process. Serious complications are more common with high ear piercing. Skin commensals like *Staphylococcus Aureus* are the most common bacterial organisms isolated and serious complications like sepsis and toxic shock syndrome have been reported.¹⁴⁻¹⁶ Life threatening infections and complications due to Group A β -haemolytic streptococci have also been reported.^{17,18}

With the increasing popularity of high ear piercing, the incidence of auricular perichondritis is rising.¹⁹ **Figure 1** shows a case of auricular perichondritis as a result of high ear piercing. *Pseudomonas Aeruginosa* has been isolated from infected cartilage and contaminated disinfectant.²⁴ As the blood supply to the cartilage is poor, healing is more difficult. For serious infections, intravenous antibiotics, surgical drainage and resection of necrotic tissue may be needed.^{20,21} Ear deformities after high ear piercing requiring surgical reconstruction have been reported.²²⁻²⁴

Viral hepatitis has occurred after ear piercing.²⁵ Hepatitis B and C have been reported.²⁶⁻²⁸ Although no cases of AIDS have been found in the literature, HIV transmission is also a possibility.

(ii) Contact dermatitis

Contact dermatitis can result from metal allergy. Nickel allergy is the most common.²⁹ This usually presents as an eczematous rash. Sarcoidal-type allergic contact granuloma has also been described.³⁰ Wearing of earrings by itself may also induce nickel allergy which may result in lifelong morbidity.^{31,32}

Gold allergy and silver allergy are rare but have also been reported.^{33,34} The skin can become discolored from leeching of silver salts and may require surgical excision.

Figure 1: Auricular perichondritis developed after high ear piercing

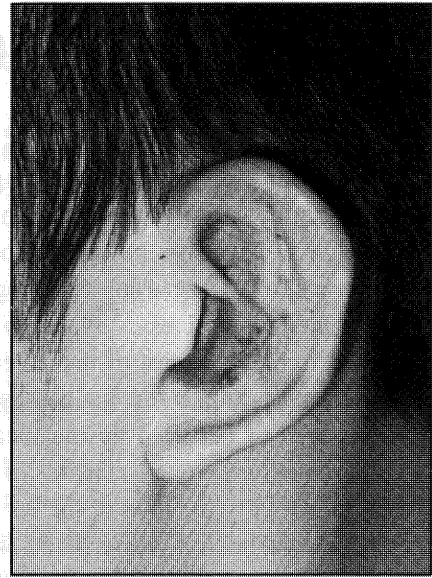


Figure 2: Keloids developed after piercing in the earlobe

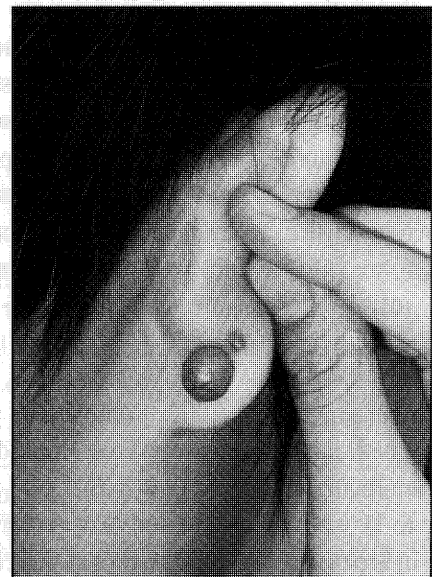
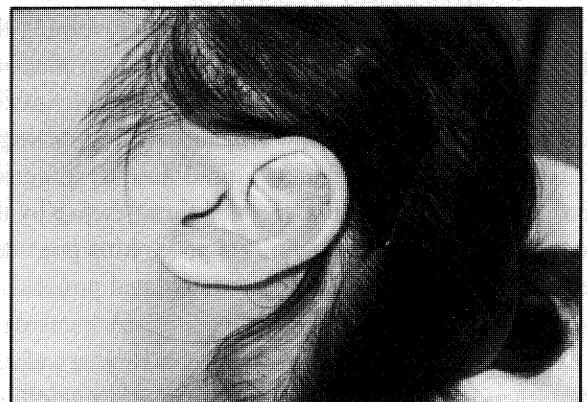


Figure 3: Keloid developed after high ear piercing



Key messages

1. There is no legislation governing ear piercing in Hong Kong.
2. The legislation relating to ear piercing differs in different countries. In some countries, exemptions are provided for piercing of the lower ear lobe with ear-piercing systems operated by the use of sealed and pre-sterilized disposable fittings.
3. Complications of ear piercing include infections, contact dermatitis, scars, keloids, together with aspiration and ingestion of the jewels. Serious complications are more common with high ear piercing and may require hospitalization and surgical treatment.
4. Aseptic technique of ear piercing prevents infections introduced at the time of ear piercing. Careful choice of gun and earrings helps to reduce trauma. Proper care of wounds prevents infections acquired afterwards. Nickel allergy can be minimized by the use of posts made of medical grade stainless steel or titanium.
5. Education of the general public on the potential health hazards and need for careful choice of ear piercing providers and piercing jewels as well as proper aftercare of the wounds should be carried out.
6. Family physicians should be aware of the potential serious complications and need for hospitalization and surgical treatment.

Following a recent assessment on the risk of sensitization of humans to nickel by piercing post assemblies, a nickel release rate of $0.2\mu\text{g}/\text{cm}^2/\text{week}$ is adopted as the new directive on the use of nickel for piercing assemblies exported to the EU market from September 2005.³⁵ Nickel sensitization and allergy can be minimized by the use of posts made of medical grade stainless steel or titanium.

(iii) Granuloma, scars and keloids

Scars and keloids have been associated with ear piercing.^{36,37} **Figure 2** shows keloids developed after piercing in the earlobe and **Figure 3** shows a keloid developed after high ear piercing. Keloids have a higher incidence in blacks and Asians. Treatment of keloids is still controversial and no single treatment modality is always successful. Medical therapies include

corticosteroids, interferon, 5-fluorouracil, and imiquimod; surgical treatment includes primary excision, skin graft or local flap and cryosurgery; physical modalities include pressure and radiation therapies.^{38,39} Auricular keloids pose distinctive cosmetic implications. Subjects should be informed of the risk and consent should be obtained before ear piercing.⁴⁰

Conclusions

In Hong Kong, there should be concern about the lack of regulations over those who perform ear piercing and the techniques and facilities they use. Educating the general public on the potential health hazards will help to increase their awareness in the need for a careful choice of ear piercing providers. Consumers should be aware of the risk of scars and keloids.

Proper training of ear piercing personnel should be enforced. Implementation of legislation or control over the standards of practice and the facilities will help to reduce the incidence of infections and their complications. A tight adherence to the nickel release directive on the part of the business can reduce the incidence of nickel sensitization and allergy. With the increasing popularity of high ear piercing and piercing in other parts of the body, primary care physicians in Hong Kong are likely to encounter more patients with complications.

Some of the more serious cases may require hospitalization and surgical treatment. Patients may feel embarrassed and reluctant to seek medical care, particularly with piercing in nontraditional sites. Physicians should be aware of the potential serious complications and be non-judgmental so as not to label or frighten the patient into delaying medical care.

References

1. http://www.publications.parliament.uk/pa/cm199899/cmhansrd/vo990427/text/90427w05.htm#90427w05.htm_sbhd3. Assessed 28/1/2005.
2. <http://www.nkyhealth.org/nkyhd/Documents/News/Piercing3-04.htm>. Assessed 1/28/2005.
3. <http://www.legislature.state.oh.us> Assessed 28/1/2005.
4. <http://www.legis.state.ia.us/GA/78GA/Legislation/HF/02000/HF02084/Current.html> Assessed 28/1/2005.
5. <http://www.legislation.act.gov.au/di/2001-184/current/pdf/2001-184.pdf>. Assessed 27/1/2005.
6. <http://www.clue.com.cn/mryf/xhwj102.html> Accessed 1/2/2005
7. Potential health hazards of body piercing. Consumer Council Choice Magazine #317 March 14, 2003.
8. To pierce or not to pierce. http://www.chau.gov.hk/text/eng/info/others_04.htm. Assessed 25/1/2005.

9. <http://www.hse.gov.uk/lau/lacs/76-2.htm> Accessed 25/1/2005.
10. <http://www.pmsofaz.org/legislation.htm> Accessed 28/1/2005.
11. <http://www.cnn.com/2004/HEALTH/02/25/piercing.dangers.ap/> Accessed 25/1/2005.
12. Hendricks WM. Complications of ear piercing: treatment and prevention. *Cutis* 1991;48:386.
13. Macgregor DM. The risks of ear piercing in children. *Scott Med J* 2001;49:9.
14. Lovejoy FH Jr, Smith DH. Life-threatening staphylococcal disease following ear piercing. *Paediatrics* 1970;46:301.
15. Shulman BH. Ear piercing and sepsis. *Clin Paediatr* 1973;12:27A.
16. McCarthy BP, Peoples WM. Toxic shock syndrome after ear piercing. *Paediatr Infect Dis J* 1988;7:741.
17. George J, White M. Infection as a consequence of ear piercing. *Practitioner* 1989; 233:404.
18. Ahmed-Jushuf IH, Selby PL, Brownjohn AM. Acute post-streptococcal glomerulonephritis following ear piercing. *Postgrad Med J* 1984;60:73.
19. Hanif J, Frosh A, Marnane C, et al. Lesson of the week: "High" ear piercing and the rising incidence of perichondritis of the pinna. *BMJ* 2001;322:906.
20. Widick MH, Coleman J. Perichondrial abscess resulting from a high ear-piercing. *Otolaryngol Head Neck Surg* 1992;107:803.
21. Cumberworth VL, Hogarth TB. Hazards of ear-piercing procedures which transverse the cartilage: a report of pseudomonas perichondritis and review of other complications. *Brit J Clin Pathol* 1991;44:512.
22. Campiglio G. Ear reconstruction after auricular chondritis secondary to ear piercing. *Plast Reconstr Surg* 2004;113:768.
23. Margulis A, Bauer BS, Alizadeh K. Ear reconstruction after auricular chondritis secondary to ear piercing. *Plast Reconstr Surg* 2003;111:891.
24. Iida N, Hosaka Y, Ogawa T. Correction of auricular deformity caused by high ear piercing: case report. *Ann Plast Surg* 2003;50:82.
25. Johnson CJ, Anderson H, Spearman J, et al. Ear piercing and hepatitis. Non sterile instruments for ear piercing and the subsequent onset of viral hepatitis. *JAMA* 1974;227:1165.
26. Hvolris JJ. Hepatitis B transmitted by ear-piercing. *Ugeskr Laeger* 1991; 153:119.
27. Grasset D, Borderes C, Escudie L, et al. Hepatitis C virus from ear-piercing. *Gastroenterol Clin Biol* 2004;28:507.
28. <http://www.rthk.org.hk/rthk/tv/doctorandyou> 2004/20040312.html Accessed 2/2/2005.
29. Garner LA. Contact dermatitis to metals. *Dermatol Ther* 2004;17:321.
30. Casper C, Groth W, Hunzelmann N. Sarcoid-like allergic contact granuloma: a rare complication of ear piercing. *Am J Dermatopathol* 2004; 26:59.
31. Mortz CG, Lauritsen JM, Bindslev-Jensen C, et al. Nickel sensitization in adolescents and association with ear piercing, use of dental braces and hand eczema. The Odense Adolescence Cohort Study on Atopic Diseases and Dermatitis. (TOACS). *Acta Derm Venereol* 2002;82:359.
32. Jensen CS, Bisby S, Baadsgaard O, et al. Decrease in nickel sensitization in a Danish schoolgirl population with ears pierced after implementation of a nickel-exposure regulation. *Br J Dermatol* 2002;146:636.
33. McDonagh AJ, Wright AL, Cork MJ, et al. Nickel sensitivity: the influence of ear piercing and atopy. *Br J Dermatol* 1992;126:16.
34. Osawa J, Kitamura K, Ikezawa Z, et al. Gold dermatitis due to ear piercing: correlations between gold and mercury hypersensitivities. *Contact Dermatitis* 1994;31:89.
35. <http://www.tdtrade.com/alert/eu0421c.htm> Accessed 25/1/2005.
36. Golladay ES. Outpatient adolescent surgical problems. *Adolesc Med Clin* 2004; 15:503.
37. Zuber TJ, DeWitt DE. Earlobe keloids. *Am Fam Physician* 1994;49:430.
38. Kelly AP. Medical and surgical therapies for keloids. *Dermatol Ther* 2004; 17:212.
39. Akoz T, Gideroglu K, Akan M. Combination of different techniques for the treatment of earlobe keloids. *Aesthetic Plastic Surg* 2002;26:184.
40. Gaughf CN, Pritzker AS, Davis L. Survey of informed consent for ear piercing: risk of keloids. *Pediatr Dermatol* 1996;13:430.