



Title	Phaeochromocytoma in children
Author(s)	Yeung, LPK; Kwan, EYW; Cheung, PT; Low, LCK
Citation	Hong Kong Medical Journal, 2002, v. 8 n. 6, p. 452-455
Issued Date	2002
URL	http://hdl.handle.net/10722/45234
Rights	Creative Commons: Attribution 3.0 Hong Kong License

LPK Yeung 楊寶琪
EYW Kwan 關彥華
PT Cheung 張璧濤
LCK Low 盧忠啟

Phaeochromocytoma in children

兒童患上嗜鉻細胞瘤的病例

Phaeochromocytoma is a rare disease in childhood with a subtle and wide range of clinical presentations. We report two confirmed cases and one potential case of phaeochromocytoma, each belonging to a different disease spectrum or syndromal disorder, namely sporadic phaeochromocytoma, von Hippel-Lindau disease, and multiple endocrine neoplasia type 2a. Knowledge of the molecular basis of the condition helps to make the diagnosis. Affected individuals and their family members should be screened for any associated syndromal disorders that can carry a substantial degree of morbidity and mortality.

嗜鉻細胞瘤是一種孩童時期罕見的疾病，其臨床徵狀細微多變。我們報告了兩宗確定的和一宗可能的嗜鉻細胞瘤病例，每個病例均屬於不同的病譜或呈現綜合性徵狀：有散發性嗜鉻細胞瘤，von Hippel-Lindau disease，和2a型多重內分泌瘤。了解此病的分子原理有助於診斷。此外，由於此病的發病率與死亡率甚高，所以要對患者及其家人進行檢查以識別是否有相關的綜合性徵狀。

Introduction

Phaeochromocytoma is a rare tumour among children and adolescents. It is an adrenomedullary catecholamine-secreting tumour that can occur at any age. Approximately 10% of patients with phaeochromocytoma are children^{1,2} and, for children with this disease, the incidence peak occurs at the age of 9 to 12 years. Boys are affected more often than girls, with a ratio of 2:1.

The frequency of multiple, bilateral, and extra-adrenal tumours is greater among children than adults, with the most common site of extra-adrenal involvement being the superior para-aortic region.¹

Between January 1986 and June 2001, there were two confirmed and one potential cases of phaeochromocytoma at the Department of Paediatrics, Queen Mary Hospital. Each patient had a different clinical syndromal disorder associated with phaeochromocytoma.

Case reports

Case 1

A 6-year-old boy presented with a history of sweatiness, weight loss, and lethargy. He was admitted to a hospital in Shanghai due to loss of consciousness 1 year after the initial presentation. He had a high blood pressure of 200/170 mm Hg. Abdominal ultrasonography revealed bilateral adrenal masses that were surgically removed. A small amount of adrenal tissue remained. The pathology of the resected mass was confirmed to be phaeochromocytoma. Postoperatively, his blood pressure level remained elevated at 140/100 mm Hg.

At the age of 11 years, he immigrated to Hong Kong and was admitted to hospital because of persistent sweating and weight loss. His blood pressure was elevated at 230/110 mm Hg. He was also found to have bilateral ptosis and a divergent squint. The visual acuity of his left eye was poor. Fundoscopic examination showed pigmentary change with capillary angioma of the retina invading the left optic disc. His right eye also had choroidoretinitis. Investigation showed an elevated 24-hour urine vanillylmandelic acid (VMA) level of 106 µmol/day

Key words:

Hippel-Lindau disease;
Multiple endocrine neoplasia type 2a;
Pheochromocytoma

關鍵詞：

Hippel-Lindau disease；
2a型多重內分泌瘤；
嗜鉻細胞瘤

Hong Kong Med J 2002;8:452-5

Department of Paediatrics, The University of Hong Kong, Queen Mary Hospital, 102 Pokfulam Road, Hong Kong

LPK Yeung, MRCP, FHKAM (Paediatrics)
EYW Kwan, MRCP, FHKAM (Paediatrics)
PT Cheung, FRCP, FHKAM (Paediatrics)
LCK Low, MD, FRCP

Correspondence to: Dr LPK Yeung

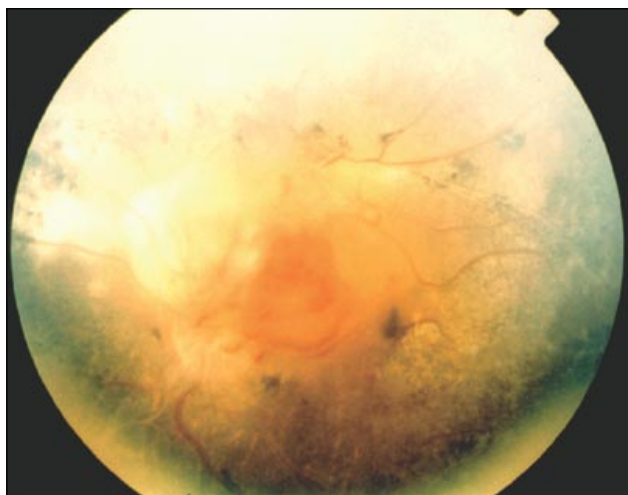


Fig 1. A retinal angiogram of patient 1 with von Hippel-Lindau disease showed the presence of an optic disc angioma

(normal range, 11-38 $\mu\text{mol/day}$). Ultrasonography of the abdomen and intravenous urogram were normal. ^{131}I -metaiodobenzylguanidine (^{131}I -MIBG) scan showed increased uptake in the left submandibular region, right adrenal bed, and bilateral lower pole of the kidneys. Aortogram showed vascular staining compatible with phaeochromocytoma in the liver, and the right adrenal and lower left para-aortic regions. Retinal angiogram confirmed bilateral optic disc angioma (Fig 1). Based on these features, the patient was diagnosed with von Hippel-Lindau (VHL) disease. Computed tomography (CT) scanning of the brain did not show any haemangioblastoma. Family screening of urine catecholamines, VMA, and homovanillic acid were normal. The patient was given phenoxybenzamine and propranolol for blood pressure control.

Surgical resection of the right adrenal tissues with lymph nodes in the lower left para-aortic region was performed. Histology confirmed phaeochromocytoma. The patient required postoperative maintenance antihypertensive therapy. Follow-up ^{131}I -MIBG scan the next year revealed an increased uptake over the submandibular region and right medial thorax at the level of T4. Subsequent imaging, including CT, ^{131}I -MIBG, and angiogram, showed persistent tumour in the neck region. Surgical resection was again performed with histology confirming metastatic phaeochromocytoma. His postoperative blood pressure was normal, although urine norepinephrine and normetanephrine levels remained elevated. This patient defaulted follow-up the year after the first dose of therapeutic ^{131}I -MIBG treatment.

Case 2

A 10-year-old boy presented to the emergency department with a 1-day history of diarrhoea. He was incidentally found to be hypertensive (blood pressure, 200/140 mm Hg). He also had a history of recurrent central abdominal pain and headache for 1 year with no sweating, tremor, palpitation, or chest discomfort. Physical examination was entirely normal except for the hypertension.

Investigations showed normal thyroid, liver, and renal functions. Serum aldosterone and cortisol levels were normal, excluding Conn's syndrome and Cushing's syndrome, respectively. Urine catecholamines and VMA levels were elevated (norepinephrine, 910 nmol/mmol creatinine [normal range, 0-60 nmol/mmol creatinine]; normetanephrine, 540 nmol/mmol creatinine [normal range, 0-40 nmol/mmol creatinine]; VMA, 12 $\mu\text{mol/mmol}$ creatinine [normal range, 0-5.4 $\mu\text{mol/mmol}$ creatinine]). Echocardiogram and ultrasonography of the abdomen were unremarkable although CT scanning of the thorax and abdomen showed a right thoracic paravertebral mass. Magnetic resonance imaging (MRI) showed a hyperintense T2-weighted lesion measuring 4.6 x 2.5 x 4.3 cm at the right paraspinal region at level T8 to T11 (Fig 2). ^{131}I -metaiodobenzylguanidine scan confirmed an avid lesion in the right lower thorax. Immunohistochemical studies of the resected tumour confirmed phaeochromocytoma. Family screening did not show the presence of hypertension.

Case 3

An asymptomatic 15-year-old boy was referred because of a family history of phaeochromocytoma. His father died at the age of 36 years because of medullary carcinoma of the thyroid. His 42-year-old paternal aunt had a 4-year history of hypertension and was subsequently diagnosed to have phaeochromocytoma.

Physical examination of the patient was unremarkable. Investigations, including urine catecholamines and VMA, serum liver and renal function tests, and biochemistry, were all within the normal ranges. Serum calcitonin was normal at 4.3 pmol/L. DNA analysis of the patient, his father, and his paternal aunt all showed germline mutations in codon 634 of exon 11 of the RET proto-oncogene, which was consistent with that of multiple endocrine neoplasia (MEN)

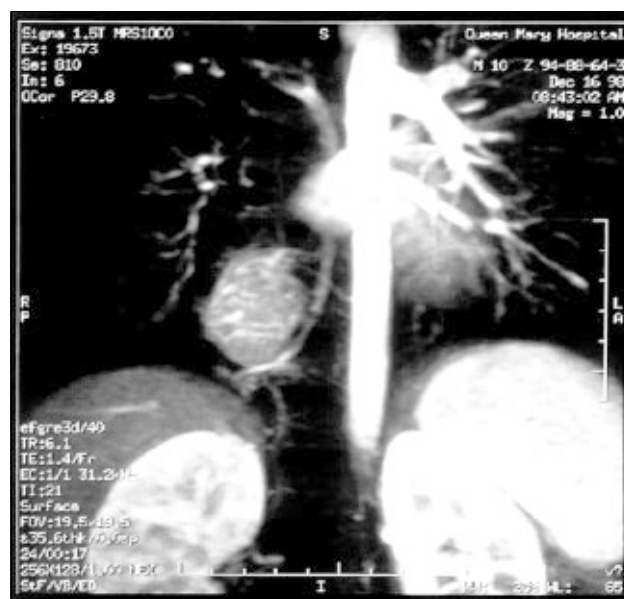


Fig 2. Magnetic resonance imaging of the thorax showed a hyperintense T2-weighted phaeochromocytoma measuring 4.6 x 2.5 x 4.3 cm at the right paraspinal region at level T8 to T11

type 2a and was highly predictive of the development of pheochromocytoma. The patient was referred for prophylactic removal of the thyroid gland. Total thyroidectomy was performed and histology confirmed medullary carcinoma of both lobes of the thyroid. Regional lymph node examination did not show metastasis. Biopsy of the parathyroid gland was taken with unremarkable findings. His adrenal condition has been closely monitored through regular measurement of urine catecholamines level. There is no evidence of a tumour evolving so far.

Discussion

The three patients reported here had different clinical syndromes associated with pheochromocytoma. Case 1 had VHL disease, case 2 had isolated sporadic pheochromocytoma, and case 3 had MEN type 2a with a high possibility of developing pheochromocytoma later in life. Syndromes known to be associated with pheochromocytoma in children include MEN type 2a, 2b (accounting for 50% of cases), VHL disease (15%), neurofibromatosis (1%), and tuberous sclerosis.^{1,2}

Unlike in adults, pheochromocytoma can sometimes have a vague and non-specific presentation in children. Hypertension is usually sustained rather than paroxysmal. Known symptoms such as headache, sweating, nausea, vomiting, weight loss, fatigue, abdominal pain, emotional lability, polyuria, polydipsia, constipation, visual disturbance, and cold extremities may or may not be present.

Patients with MEN type 2a are at risk of developing medullary carcinoma of the thyroid, pheochromocytoma, and parathyroid hyperplasia or tumour. Pheochromocytoma is usually bilateral or multifocal within the adrenal glands, and develops gradually in more than 50% of patients. The gene for MEN type 2 is mapped to chromosome 10 cen-10q11.2. It is a region containing c-RET-*proto-oncogene*, which encodes the tyrosine kinase receptor with cadherin-like and cysteine-rich extracellular domains, and tyrosine kinase intracellular domain.³ Ninety-five percent of cases of MEN type 2a are associated with mutation of cysteine-rich extracellular domain. Mutations in codon 634 account for 85% of MEN type 2a mutations whereas mutations in codon 918 account for 95% of MEN type 2b.

von Hippel-Lindau disease is an autosomal dominant inherited familial cancer syndrome predisposing to retinal and central nervous system haemangioblastoma, renal cell carcinoma, renal cysts, pheochromocytoma, pancreatic cysts, and tumours. The VHL gene, which functions as a tumour suppressor gene, is located at chromosome 3p25-26.⁴

Neurofibromatosis is an autosomal dominant condition predisposing to the development of tumour in central and peripheral nervous systems. One percent of patients with neurofibromatosis have pheochromocytoma. Gene loci

of neurofibromatosis type 1 and 2 are on chromosomes 17q11.2 and 22q12, respectively.

The genetic basis of familial pheochromocytoma is not yet well defined for many families. Recently, Astuti et al⁵ studied four members of the same family with familial pheochromocytoma, and found a frameshift mutation in the gene encoding succinate dehydrogenase complex subunit D (SDHD) in two generations of a family with four children with pheochromocytoma. The SDHD mutation is rarely found in sporadic pheochromocytoma. Neither the germline mutations in the VHL gene nor the c-RET *proto-oncogene* is commonly found in sporadic pheochromocytoma.⁶

For investigation of pheochromocytoma, urinary examination of catecholamines and metabolites is the first choice for screening as the test is non-invasive and has a high sensitivity of 100% and specificity of 98%.^{7,8}

Imaging techniques including ¹³¹I-MIBG scan, CT, and MRI are helpful for locating the tumour. Magnetic resonance imaging has the highest sensitivity (100%), followed by CT (98%) and ¹³¹I-MIBG (78%). Specificity is the highest in ¹³¹I-MIBG (100%), followed by CT (70%) and MRI (67%).⁹ A whole body evaluation by CT/MRI is suggested for localisation of the tumour if the adrenal glands are normal because of the high chance of extra-adrenal involvement. Positive findings should be followed by ¹³¹I-MIBG scan for confirmation because of its high specificity. Newer imaging techniques such as positron emission tomography have been used for locating pheochromocytoma with satisfactory results.¹⁰ Positron emission tomography is recommended for patients with suspected pheochromocytoma and positive biochemical tests but negative results with conventional imaging studies.

Case 3 has confirmed genetic MEN type 2a and close monitoring of the evolving pheochromocytoma is needed. Since almost all patients with MEN type 2a develop medullary carcinoma early in their lives, prophylactic excision of the thyroid gland is mandatory. In fact, the excised thyroid tissue of case 3 had already shown the presence of medullary carcinoma. Regular checking of serum calcium, calcitonin, and parathyroid hormone is needed because parathyroid hyperplasia is also a known association of the condition.

Surgery is still the mainstay of treatment for pheochromocytoma. Before undergoing an operation, however, the blood pressure must be pharmacologically normalised to avoid hypertensive crisis during surgery.^{11,12}

In most incidences, pheochromocytoma may be the only presenting problem for patients with MEN type 2a or VHL disease. Universal screening of patients with pheochromocytoma to exclude a familial or clinical syndrome is recommended, especially for young patients

who have positive family histories or multiple tumours. The investigations should aim at making the diagnosis and looking for complications of the syndromal disorder. Apart from performing the usual investigations, measurements of serum parathyroid hormone, serum calcium, calcitonin level, ophthalmoscopy, MRI of the brain, spine, and abdomen, and even genetic testing of VHL and c-RET genes are useful screening tests. In view of the high morbidity associated with the clinical syndromes, early detection of any associated problems can decrease the complications of this disease.

References

- Ross JH. Pheochromocytoma. Special considerations in children. *Urol Clin North Am* 2000;27:393-402.
- Gifford RW Jr, Manger WM, Bravo EL. Pheochromocytoma. *Endocrinol Metab Clin North Am* 1994;23:387-404.
- Thakker RV. Multiple endocrine neoplasia—syndromes of the twentieth century. *J Clin Endocrinol Metab* 1998;83:2617-20.
- Richards FM, Webster AR, McMahon R, Woodward ER, Rose S, Maher ER. Molecular genetic analysis of von Hippel-Lindau disease. *J Intern Med* 1998;243:527-33.
- Astuti D, Douglas F, Lennard TW, et al. Germline SDHD mutation in familial phaeochromocytoma. *Lancet* 2001;357:1181-2.
- Bar M, Friedman E, Jakobovitz O, et al. Sporadic phaeochromocytomas are rarely associated with germline mutations in the von Hippel-Lindau and RET genes. *Clin Endocrinol (Oxf)* 1997;47:707-12.
- Peaston RT, Lennard TW, Lai LC. Overnight excretion of urinary catecholamines and metabolites in the detection of pheochromocytoma. *J Clin Endocrinol Metab* 1996;81:1378-84.
- Bouloux PG, Fakeeh M. Investigation of phaeochromocytoma. *Clin Endocrinol (Oxf)* 1995;43:657-64.
- Bravo EL. Pheochromocytoma: new concepts and future trends. *Kidney Int* 1991;40:544-56.
- Shulkin BL, Wieland DM, Schwaiger M, et al. PET scanning with hydroxyephedrine: an approach to the localization of pheochromocytoma. *J Nucl Med* 1992;33:1125-31.
- Russell WJ, Metcalfe IR, Tonkin AL, Frewin DB. The preoperative management of phaeochromocytoma. *Anaesth Intensive Care* 1998;26:196-200.
- Hack HA. The perioperative management of children with phaeochromocytoma. *Paediatr Anaesth* 2000;10:463-76.



Clinical Laboratory and X-ray Services & CytoLab Pap Test Screening Centre

Enquiries: 2861 1308 Website: www.pathlabhk.com

Laboratories:

2nd-3rd Fl, Henan Building, 90-92 Jaffe Road, Wanchai, Hong Kong
香港灣仔謝菲道90-92號豫港大廈二至三樓
Tel: 2861 1308 Fax: 2529 6082

1005A Melbourne Plaza, 33 Queen's Road, Central, Hong Kong
香港中環皇后大道中33號萬邦行1005A室
Tel: 2526 6505 Fax: 2526 6560

1810 East Point Centre, 555 Hennessy Road, Causeway Bay, Hong Kong
香港銅鑼灣軒尼詩道555號東角中心1810室
Tel: 2891 3738 Fax: 2891 3803

1215 Argyle Centre Phase 1, 688 Nathan Road, Mongkok, Kowloon
香港九龍彌敦道688號旺角中心第一期1215室
Tel: 2393 6131 Fax: 2398 1695

Serving the medical community since 1975