



Title	Intra-operative spinal chord monitoring
Author(s)	Chiu, PKY; Wong, YW; Wong, ILC; Luk, KDK
Citation	Hong Kong Medical Journal, 1995, v. 1 n. 4, p. 335-340
Issued Date	1995
URL	http://hdl.handle.net/10722/45201
Rights	Creative Commons: Attribution 3.0 Hong Kong License

Intra-operative spinal chord monitoring

KY Chiu, YW Wong, ILC Wong, KDK Luk

Spinal surgery carries a small but definite risk of damaging the spinal chord. Early detection and correction of any reversible insult to the chord is important. An intra-operative “wake-up” test has been used to monitor the chord function for more than 20 years. However, it has its limitations and disadvantages. Advances in electronics have facilitated the development and clinical application of electrophysiological methods in assessing the integrity of the spinal chord during surgery. It is now possible to monitor the spinal chord during surgery using various evoked potentials techniques.

HKMJ 1995;1:335-340

Key words: Spinal cord compression; Spinal cord injuries; Intraoperative monitoring; Monitoring, physiologic

Introduction

Paraplegia resulting from spinal operation is the surgeon's and patient's most feared complication. With the recent development of powerful instrumentation in spinal surgery and the growing enthusiasm for using it in more patients, the risk of damaging the neural tissue is real.

Using scoliosis surgery as an example, a survey conducted in 1975 by the Morbidity and Mortality Committee of the Scoliosis Research Society showed a 0.72% acute neurological complication rate.¹ Most of these complications were attributable to distraction of the spine with Harrington instrumentation. Segmental spinal instrumentation such as Luque sublaminar wiring gained popularity rapidly in the 1980s because of the improved stabilisation provided. However, it also had a higher acute neurological complication rate of 17% compared with 1.5% when Harrington instrumentation alone was used.² Recently, the Cotrel-Dobousset instrumentation has been widely used (Fig 1). With the placement of multiple hooks and the provision of a strong corrective force, an increased risk of acute neurological complication is expected.

Spinal chord monitoring

If a reversible insult—such as overdistraction—affects the spinal chord and causes neurological deficit, the recovery is directly related to the speed of removal of the insult. MacEwen et al reported a high rate of complete recovery from paraplegia if the Harrington distraction rod was removed within three hours after the deficit was noted.¹

Before the era of intra-operative spinal chord monitoring, the neurological deficit could only be detected after a patient recovered from the anaesthesia. If patients could not move parts of the body after they regained consciousness, they had to be given general anaesthesia again in order to remove the insulting force. The latter was usually unprepared and significantly

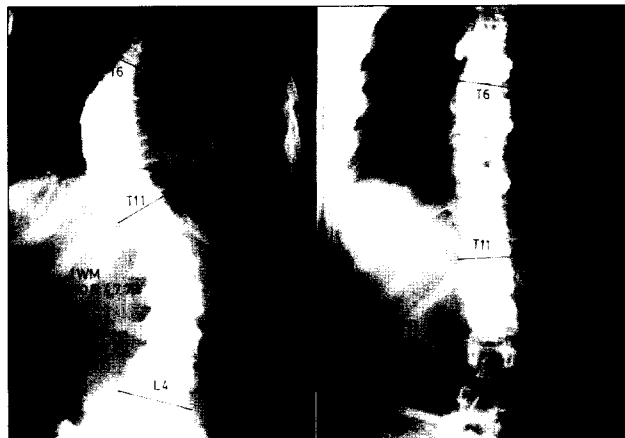

Fig 1. Idiopathic thoracic scoliosis treated with Cotrel-Dobousset instrumentation

Department of Orthopaedic Surgery, The University of Hong Kong, The Duchess of Kent Children's Hospital, Sandy Bay, Hong Kong

KY Chiu, MBBS, FRCSE

YW Wong, MBBS, FRCSE

ILC Wong, RN

KDK Luk, FRCSE, FRACS

Correspondence to: Dr KY Chiu

disturbed the activities of the operating theatre. In addition, there was already an undue delay between the insult occurring and its detection. The chance of complete recovery was thus jeopardised. This also imposed a severe psychological trauma on the patient.

The best time to detect and correct the problem is immediately after the crucial steps that may endanger the spinal chord during the operation. There are two ways by which the surgical team can evaluate the integrity of the neural pathway at the time of surgery. One method is to perform the "wake-up" test, which is still commonly practised. The other method is by evoked potentials monitoring.

The wake-up test

In 1973, a group of French spinal surgeons reported on the functional monitoring of the spinal chord during scoliosis surgery.³ By securing partial and temporary awakening during the course of anaesthesia, any loss of voluntary motor power was observed; they called it the wake-up test. They described two patients who could not move their toes voluntarily and thus had a positive wake-up test. With removal of the distraction forces, motor power returned after the operations.

Hall et al described in detail the technique for the wake-up test in 1978.⁴ Three patients had neurological deficits when awakened during surgery, and the deficits disappeared on release of the distraction force. They also found that 12 of 150 patients who had the wake-up test performed recalled the awakening, but none experienced any pain. Using this test, one is able to tell whether the spinal chord is still intact after any intra-operative manoeuvre, such as distraction. There is no need to wait and watch for paraplegia after the patient totally recovers from general anaesthesia. Prompt reversal of the damaging force can be effected, giving the best chance of regaining normal neural function.

One major disadvantage of the wake-up test is the need to interrupt the surgical procedure to allow for the awakening; this is time-consuming, and cannot be performed repeatedly during the operation. In addition, the wake-up test does not work if there is pre-existing paraparesis, if the patient is too young, mentally retarded, not able to obey orders and perform voluntary movements of the toes, or if there are any psychological problems. Apart from these limitations,

the wake-up test may also be complicated by accidental dislodgement of the endotracheal tube, intravenous lines, and even the hooks of the spinal instrumentation due to excessive movements of the partially awakened, agitated patient. Air embolism is also possible as a result of sudden, deep inhalation during arousal, sucking air into the open vessels in the wound.

What are evoked potentials?

Evoked potentials (EP) are the electrophysiological responses of the nervous system to external stimulation. Dawson stimulated the peripheral sensory nerve and studied the activities in the contralateral somatosensory cerebral cortex recorded by scalp electrodes.⁵ He called such activities somatosensory evoked potentials (SEP). Such electrical activities are often very weak and are buried in the strong, spontaneous background electroencephalographic activities.

Advances in electronics have facilitated the development of electrophysiological methods for monitoring the spinal chord during surgery. Using special amplifiers and filters, the extremely small signals can be enhanced and the artefacts eliminated. Using line-averaging techniques, the signal changes are recorded with repetitive stimulation over a period of time. The random background activities cancel themselves out and the time-locked evoked potentials are summated to give typical wave forms.

Several interesting animal experiments have been important in establishing the role of evoked potential monitoring in clinical use. Donaghy et al dropped a weight on a cat's spinal chord after a laminectomy.⁶ The early recovery of the evoked potentials correlated well with the recovery of motor function. The laterality of the motor function recovery was also closely correlated with the laterality of the evoked potentials. D'Angelo et al studied the pathways leading to the cortical evoked responses in cats.⁷ The impulses were found to be conducted in the ipsilateral posterior column and the feline equivalent of the spinothalamic tract in humans. They suggested that mechanical distortion of the nerve fibres led to the inhibition of conduction. Croft et al showed that the size of evoked potentials diminished with weight applied over the exposed chord of cats.⁸ If the weight was removed within two minutes, the evoked potentials returned. However, the evoked potentials disappeared if the weight was left there for 15 minutes. They postulated a vascular mechanism that mediated the changes.

Classification of evoked potentials monitoring

There are currently two major groups of evoked potentials monitoring. The classification depends on the sites of stimulation and signal recording, thus the direction of the "volleys" and the neural pathways involved.

The first group includes stimulation of the peripheral nerves and recording of the ascending volleys along the neural pathway, at a site rostral to the operated vertebrae. This method is SEP monitoring. If the recording electrodes are placed at the spinal chord level, the method is called spinal SEP monitoring. If the recording electrodes are placed over the scalp, the method is called cortical SEP monitoring.

The second group involves the monitoring of the descending volleys. The latter are recorded at a level caudal to the operated vertebrae with special electrodes placed very close to the chord, such as in the subarachnoid space. The stimulation is applied either directly on the spinal chord at a site rostral to the operated vertebrae or on the motor cortex by scalp electrodes. The former is called spinal chord evoked potentials (SCEP) monitoring and the latter, motor evoked potentials (MEP) monitoring.

Cortical SEP monitoring is most widely used by North American spinal surgeons. Spinal SEP monitoring is widely used, especially in England. Spinal chord evoked potentials and MEP monitoring are used mainly in Japan and in some centres in Europe.

Somatosensory evoked potentials monitoring

Somatosensory evoked potentials monitoring is probably still the most widely used modality. It is relatively simple and non-invasive. The stimulation can be made over the peripheral nerves (neural stimulation) or over a specific dermatome to give root-specific SEP monitoring (dermatomal stimulation). For neural stimulation, the posterior tibial nerve, the peroneal nerve, or both, can be stimulated for thoracic chord monitoring; the median or ulnar nerve can be stimulated for cervical chord monitoring. While unilateral stimulation may provide left-right discrimination, bilateral stimulation gives stronger signals that are less subject to noise and contamination.

For cortical SEP monitoring, the recordings are made by two scalp electrodes.^{2,9-11} This is relatively non-invasive, and the monitoring can be performed

outside the operating theatre—before and after the surgery. Unfortunately, cortical SEP is very sensitive to many anaesthetic agents, such as halothane, enflurane and others. The co-operation of the anaesthesiologist is essential. It is important to minimise any fluctuation in the anaesthetic level before, during, and after the crucial steps of surgery.

For spinal SEP monitoring, the recordings are made at the level rostral to the operated vertebrae.¹²⁻¹⁴ The recording electrodes may be placed in the spinous process, ligamentum flavum, or in the epidural space after making a laminotomy. Spinal SEP is less sensitive to anaesthetic agents than is cortical SEP. The signals are also larger, and the averaging process takes a shorter period of time. However, the technique is more invasive and is difficult to use out of the operating theatre. Recording reproducible potentials in the more rostral segments is difficult because of the decreasing amplitude caused by moving the electrodes in a cephalad direction.

According to a large multicentre survey recently published, the use of SEP monitoring was effective in reducing the neurological complication rate.¹⁵ More than 50 000 cases of intra-operative SEP monitoring for spinal surgery performed by 153 Scoliosis Research Society members were analysed. The years of experience with SEP monitoring was the primary predictor of post-operative neurological deficit. The neurological complication rate of the experienced teams was less than half that of the most inexperienced teams.

One theoretical drawback of SEP monitoring is the possibility of false negative results.^{16,17} The Cleveland Clinic reported their experience of 220 patients who had spinal SEP monitoring: seven patients had worsening of neurological function after surgery and four did not demonstrate significant signal change during monitoring.¹⁸ It has been argued whether one can call such events false negative, as SEP monitoring records only the ascending volleys and is insensitive to damage in the territory of the anterior spinal artery. It may be more appropriate to consider such events as a limitation of SEP monitoring rather than a false negative result.

Alternatively, some patients have recovered from the anaesthesia without any problems despite the intra-operative SEP monitoring strongly suggesting impairment of neural function. It is important to rule out technical errors, the effect of anaesthetic agents and other interference before one labels such events as false posi-

tives. It is possible that real defects have been reversed before they became clinically significant.

Spinal chord evoked potentials monitoring

Tamaki et al from Wakayama, Japan, pioneered the development of SCEP monitoring.¹⁹ Unlike SEP monitoring, the spinal chord itself is directly stimulated. The elicited evoked potentials are transferred via both the ascending and descending tracts. Stimulation is made using a specially designed, flexible electrode placed in the epidural space at a level cephalic to the operated vertebrae. It is introduced under direct vision during the operation by making a small laminotomy. The recording electrode is placed in the subarachnoid space close to the level of the conus medullaris. It is normally inserted percutaneously using a special lumbar puncture needle before the skin incision.

Spinal chord evoked potentials monitoring has been criticised as being too invasive and dangerous. However, complications are extremely rare and it is superior to SEP monitoring in several respects. Firstly, SCEP monitoring reflects the volleys along the motor pathway, and therefore theoretically eliminates the chance of a false negative as is possible in SEP monitoring. In addition, the recorded waveform is of larger amplitude and is more consistent as the chord is directly stimulated in SCEP monitoring. A much shorter time—usually seconds—is required for the averaging process. Cortical SEP monitoring requires several minutes for each recording. Hence, SCEP monitoring allows an instantaneous assessment of the chord integrity.

Motor evoked potentials monitoring

This is a relatively new method of intra-operative spinal chord monitoring and is not yet well established.²⁰ The stimulation is made directly over the cerebral motor cortex, either by transcranial magnetic or electrical stimulation; the descending volleys are recorded distal to the operated vertebrae. This method is theoretically attractive, as it monitors the motor pathway and thus eliminates the worry of false negatives encountered in SEP monitoring. It is particularly useful for cervical spine surgery—the signals of SEP monitoring diminish towards the rostral segments of the spine, and the placement of the flexible electrodes for SCEP monitoring is more difficult in this location. One potential hazard of MEP monitoring is neural tissue damage secondary to the transcranial stimulation of the brain. There have been no reports of such complications so far.

The Duchess of Kent Children's Hospital experience

The Duchess of Kent Children's Hospital is the only hospital in Hong Kong in which intra-operative spinal chord monitoring is routinely performed. From July 1992 through June 1994, we monitored 102 operations. The majority of these were for scoliosis surgery. We used the Viking II model (Nicolet Instrument Corp., Madison, Wi, US) [Fig 2] as the software allows monitoring of various types of evoked potentials.

Although we commonly use cortical SEP monitoring, we also have the facilities and knowledge to carry out SCEP monitoring. The latter was made possible after members of our team visited Professor Tamaki in Japan in 1992. We use SCEP monitoring for the more severe deformities as this technique is more sensitive and allows instantaneous assessment of the chord function. Motor evoked potentials monitoring has also been performed in a few patients; we use this method mainly for cervical spine surgery. The typical waveforms that one sees in cortical SEP, SCEP and MEP monitoring are shown in Fig 3.

In two patients with scoliosis, there were marked reductions or even disappearance of the wave forms after the corrective force was applied during surgery; the force was released immediately. In both cases, the evoked potentials recovered gradually after 15 minutes. A subsequent corrective force was re-applied cautiously and slowly with the potentials being carefully monitored. Neither patient woke up with a neurological deficit. A typical example is shown in Fig 4. We did not encounter any false negatives.



Fig 2. The machine used for intra-operative spinal chord monitoring at the Duchess of Kent Children's Hospital

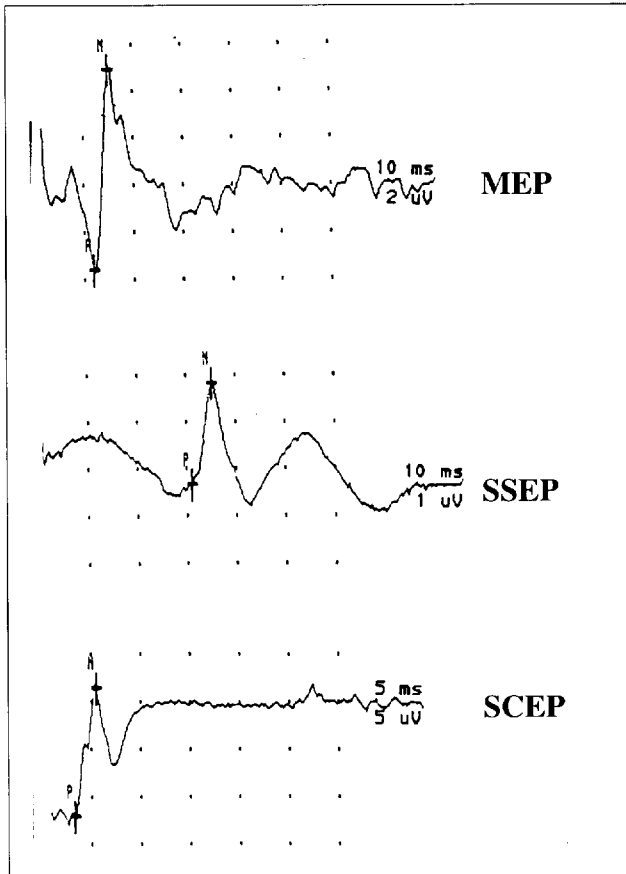


Fig 3. The typical waveforms of cortical somatosensory evoked potentials, spinal chord evoked potentials and motor evoked potentials monitoring

We also have performed spinal chord monitoring for selected cases of degenerative, neoplastic, and infective spinal disorders. Apart from early detection of reversible damage to the chord in scoliosis surgery, the indication can now be extended to situations where one would like to know whether or not the surgery has been adequate. We encountered a prominent increase in the potentials after decompressive laminectomy and reduction of spondylolisthesis in two patients with lumbar spine stenosis.

Conclusion

No spinal chord monitoring can prevent chord injury caused by a careless surgeon, such as inadvertent chord contusion or laceration, or the delivery of diathermy current to neural tissue through instrumentation. However, spinal chord monitoring can enable early detection of any reversible damage to the spinal chord which arises during the operation. This is now considered to be mandatory because the newer and more powerful instrumentation can provide a very strong corrective

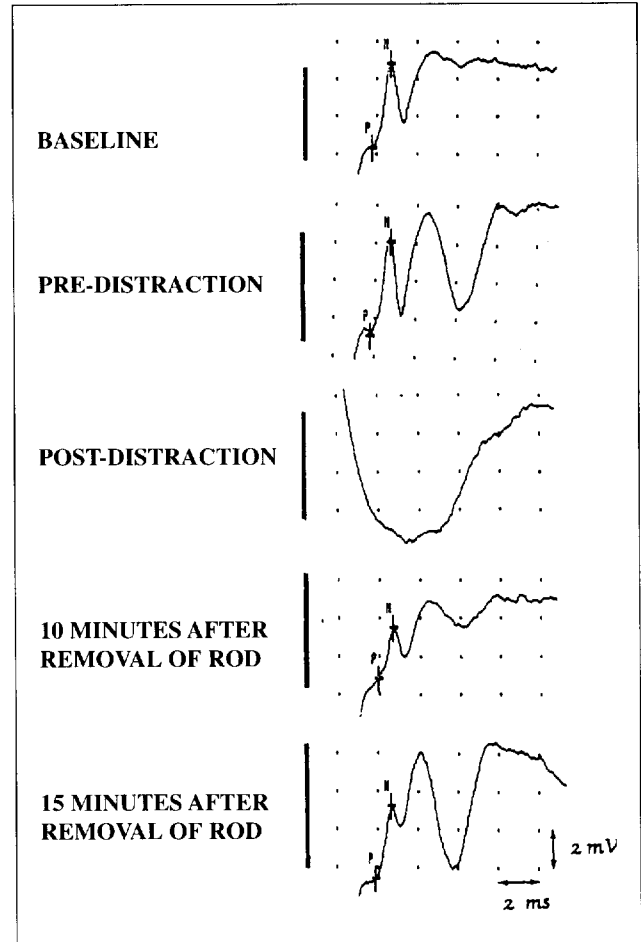


Fig 4. An example of "positive" monitoring in a patient with scoliosis who was treated with Harrington instrumentation

force to the deformed spine. The wake-up test has many limitations and disadvantages. Evoked potentials monitoring allows instantaneous and repetitive assessment of the chord function. It is most important that the personnel who perform the monitoring have a sound knowledge of the underlying electrophysiology.

References

1. MacEwen GD, Bunnell WP, Sriram K. Acute neurological complications in the treatment of scoliosis. *J Bone Joint Surg Ser A* 1975; 57:404-8.
2. Wilber RG, Thompson GH, Shaffer JW, Brown RH, Nash CL. Post-operative neurological deficits in segmental spinal instrumentation: a study using spinal cord monitoring. *J Bone Joint Surg Ser A* 1984;66:1173-87.
3. Vauzelle C, Stagnara P, Jouvinroux P. Functional monitoring of spinal cord activity during spinal surgery. *Clin Orthop Relat Res* 1973;93:173-8.
4. Hall JE, Levine CR, Sudhir KG. Intra-operative awakening to monitor spinal cord function during Harrington instrumentation and spine fusion. *J Bone Joint Surg Ser A* 1978;60:533-6.
5. Dawson GD. Cerebral responses to electrical stimulation of peripheral nerve in man. *J Neurol Neurosurg Psychiatry* 1947;10:137-40.

6. Donaghy RM, Numoto M. Prognostic significance of sensory evoked potential in spinal cord injury. Proceedings of the Seventeenth Spinal Cord Injury Conference; 1969 Veterans Administration Hospital; New York. New York: Sep 1969.
7. D'Angelo CM, Van Gilder JC, Taub A. Evoked cortical potentials in experimental spinal cord trauma. *J Neurosurg* 1973;38:332-6.
8. Croft TJ, Brodkey JS, Nulsen FE. Reversible spinal cord trauma: a model for electrical monitoring of spinal cord function. *J Neurosurg* 1972;36:402-6.
9. Nash CL, Lorig RA, Schatzinger MA, Beown RH. Spinal cord monitoring during operative treatment of the spine. *Clin Orthop Relat Res* 1977;126:100-5.
10. Engler GL, Spielholz NI, Bernhard WN, Danziger F, Merkin H, Wolff T. Somatosensory evoked potentials during Harrington instrumentation for scoliosis. *J Bone Joint Surg Ser A* 1978;60:528-32.
11. Bieber E, Tolo V, Uematsu S. Spinal cord monitoring during posterior spinal instrumentation and fusion. *Clin Orthop Relat Res* 1988;229:121-4.
12. Jones SJ, Edgar MA, Ransford AO, Thomas NP. A system for the electro-physiological monitoring of the spinal cord during operation for scoliosis. *J Bone Joint Surg Ser B* 1983;65:134-9.
13. Lamont RL, Wasson SL, Green MA. Spinal cord monitoring during spinal surgery using somatosensory spinal evoked potentials. *J Pediatr Orthop* 1983;3:31-6.
14. Forbes HJ, Allen PW, Waller CS, et al. Spinal cord monitoring in scoliosis surgery: experience with 1168 cases. *J Bone Joint Surg Ser B* 1991;73:487-91.
15. Nuwer MR, Dawson EG, Carlson LG, Kanim LE, Sherman JE. Somatosensory evoked potential spinal cord monitoring reduces neurologic deficits after scoliosis surgery: results of a large multicenter survey. *Electroencephalogr Clin Neurophysiol* 1995;96:6-11.
16. Ben-David B, Haller G, Taylor P. Anterior spinal fusion complicated by paraplegia: a case report of a false-negative somatosensory-evoked potential. *Spine* 1987;12:536-9.
17. Lesser RP, Raudzens P, Luders H, et al. Post-operative neurological deficits may occur despite unchanged intra-operative somatosensory evoked potentials. *Ann Neurol* 1986;19:22-5.
18. Dinner DS, Luders H, Lesser RP, Morris HH, Barnett G, Klem G. Intra-operative spinal somatosensory evoked potential monitoring. *J Neurosurg* 1986;65:807-14.
19. Tamaki T, Noguchi T, Takano H, et al. Spinal cord monitoring as a clinical utilization of the spinal evoked potential. *Clin Orthop Relat Res* 1984;184:58-64.
20. Owen JH. Update on evoked potentials during spinal surgery. *Orthopedics* 1993;4:12-20.