



Title	Endoscopic transnasal orbital decompression for thyrotoxic orbitopathy
Author(s)	Yuen, APW; Kwan, KYW; Chan, E; Kung, AWC; Lam, KSL
Citation	Hong Kong Medical Journal, 2002, v. 8 n. 6, p. 406-410
Issued Date	2002
URL	http://hdl.handle.net/10722/45127
Rights	Creative Commons: Attribution 3.0 Hong Kong License

APW Yuen 袁寶榮
 KYW Kwan 關焯榮
 E Chan 陳靄永
 AWC Kung 龔慧慈
 KSL Lam 林小玲

Endoscopic transnasal orbital decompression for thyrotoxic orbitopathy

治療甲狀腺毒眼肌病的內窺鏡鼻轉移眼窩減壓

Objective. To evaluate the efficacy of endoscopic transnasal orbital decompression alone for thyrotoxic orbitopathy.

Design. Retrospective review of consecutive procedures.

Setting. Tertiary referral otorhinolaryngology centre.

Patients. Twenty-three eyes of 14 patients.

Intervention. Endoscopic transnasal orbital decompression.

Main outcome measures. Proptosis reduction, intra-ocular pressure reduction, exposure keratitis reduction, visual acuity improvement, and complication rate.

Results. There were no surgical complications for the 23 orbital decompressions. Proptosis reduction was achieved in 22 (96%) eyes. The mean proptosis reduction was 4.6 mm (median, 5.0 mm; range, 1.0-8.0 mm). The postoperative intra-ocular pressure decreased after surgical decompression in 20 (87%) eyes with a mean reduction of 11 mm Hg (median, 6 mm Hg; range, 1-35 mm Hg). Of the 15 eyes with incomplete closure of the eyelid before the operation, 11 (73%) had complete eyelid closure after surgical decompression. Of the other four eyes that had incomplete closure, the gaps were reduced. The visual acuity was improved for 16 (70%) eyes with a median improvement of 3 Snellen lines (range, 1-8 lines).

Conclusion. Endoscopic transnasal medio-inferior orbital wall decompression is a safe and adequate treatment for thyrotoxic orbitopathy with proptosis, exposure keratitis, and visual loss.

目的：評估內窺鏡鼻轉移眼窩減壓對甲狀腺毒眼肌病的成效。

設計：回顧總覽一連串的手術。

安排：一所耳鼻喉科的三級轉介中心。

患者：14名患者的23只眼睛。

療法：內窺鏡鼻轉移眼窩減壓。

主要結果測量：眼球突出的減少，眼內壓的減少，暴露性角膜炎的減少，視敏度的改善程度及併發症的發生率。

結果：進行眼窩減壓手術後，23只眼睛均沒有出現併發症。其中22只眼球(96%)的突出平均減少了4.6 mm(中值，5.0 mm；範圍，1.0-8.0 mm)。20只眼球(87%)的眼內壓也平均減少了11 mm Hg(中值，6 mm Hg；範圍，1-35 mm Hg)。手術前有15只眼睛的眼皮不能完全閉合，進行減壓手術後，有11只(73%)眼睛的眼皮可完全閉合。而另外4只的眼皮閉合縫亦呈現減少。16只(70%)眼睛的視敏度有改善，改善的中值量為3排斯內倫視力線(範圍，1-8排)。

結論：內窺鏡鼻轉移中下眼窩壁減壓方法，對於患有眼球突出、暴露性角膜炎和視力損失的甲狀腺毒眼肌病是一種安全及適當的治療措施。

Key words:

Endoscopes;

Exophthalmos;

Keratitis;

Orbital diseases;

Thyrotoxicosis

關鍵詞：

內窺鏡；

眼球突出症；

角膜炎；

眼窩病；

甲狀腺毒症

Hong Kong Med J 2002;8:406-10

Queen Mary Hospital, 102 Pokfulam Road,
 Hong Kong:

Division of Otorhinolaryngology,

Department of Surgery

APW Yuen, FHKAM (Otorhinolaryngology)

Department of Ophthalmology

KYW Kwan, FHKAM (Ophthalmology)

E Chan, FHKAM (Ophthalmology)

Division of Endocrinology, Department of
 Medicine

AWC Kung, FHKAM (Medicine)

KSL Lam, FHKAM (Medicine)

Correspondence to: Dr APW Yuen

Introduction

Thyrotoxic orbitopathy in thyrotoxicosis is characterised by proptosis, diplopia, exposure keratitis, lid retraction, and visual loss.¹⁻⁵ The pathological changes within the orbit include inflammatory cell infiltration mainly of T-cells, swollen ocular muscles, and fibrosis.^{4,5} The exact mechanism of pathogenesis of these ocular changes in relation to the autoantibodies is still unknown. Although patients with thyrotoxicosis have some degree of orbitopathy, most patients have self-limiting disease. The minority of patients who have severe exposure keratitis and optic nerve compression require treatment with systemic steroid

and cyclosporine.⁶ Patients who fail to respond to conservative treatment require either surgical decompression or radiotherapy.

Early attempts at surgical orbital decompression were done via the lateral or superior walls of the orbit. These approaches have the problem of limited expansion of orbital content due to the presence of the temporalis muscle and the brain. Today, decompression via the maxillary and ethmoid sinuses is the standard procedure.

Endoscopic transnasal medial and inferior wall decompression of thyrotoxic orbitopathy was reported in 1990.⁷ Since then, there have been a few other reports on endoscopic orbital decompression.⁸⁻¹³ Most of these reports are of a combination of endoscopic transnasal decompression and lateral canthotomy. The number of patients undergoing endoscopic transnasal orbital decompression alone for orbitopathy is still small and the outcome of treatment is not well documented in the literature. This study aimed at evaluating endoscopic transnasal orbital decompression alone.

Subjects and methods

This was a retrospective study of endoscopic transnasal orbital decompression for thyrotoxicosis complicated by optic nerve compression or exposure keratitis. No patient was operated on for cosmetic reasons. All operations were performed at Queen Mary Hospital from July 1995 to November 2000 by a single surgeon. There were 23 consecutive orbital decompressions for 14 patients, including seven males and seven females. The median age was 52 years (range, 28-69 years). The median duration of thyrotoxicosis was 2.5 years (range, 4.0 months-23.0 years) before surgery.

The main reason for surgical decompression was exposure keratitis in 12 eyes, optic nerve compression in nine eyes, and both exposure keratitis and optic nerve compression in two eyes. All patients had been treated with systemic steroid (six had also been administered cyclosporin) before the operation, but did not respond. One patient had been treated with external radiotherapy for thyrotoxic exophthalmos before surgical intervention and failed to respond. All patients were operated because of poor response to medical therapy and/or radiotherapy. There were nine bilateral operations (seven performed in one stage and two performed in two stages, 1 and 2 weeks apart) and five unilateral orbital decompressions.

The eye assessment included intra-ocular pressure (IOP), visual acuity (VA), diplopia, lid retraction, proptosis, and fundi, and were performed by ophthalmologists the day before the operation, the day after the operation, and postoperatively every 3 to 4 months. The IOP was measured by the standard Goldmann applanation tonometer (Haag-Streit, Koniz, Switzerland) at primary gaze—looking straight

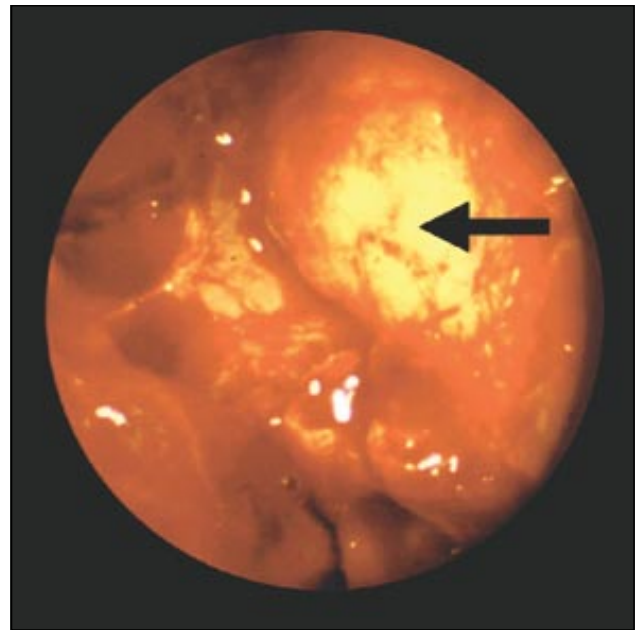


Fig 1. Endoscopic view of orbital fat (arrow) in the anterior ethmoid sinus cavity after orbital decompression of the left eye

ahead. Proptosis was measured by the Hertel exophthalmometer with the reference point at the lateral orbital rim—the distance (in mm) from the lateral orbital rim to the anterior corneal surface. Optic nerve compression is defined as clinical evidence of impaired optic nerve function together with radiological findings of orbital apex crowding. All patients had preoperative computed tomography (CT) assessment. Clinical tests for optic nerve function included Snellen VA, pupillary reaction, colour vision, and Humphrey static threshold perimetry.

All patients were operated on using general anaesthesia according to the technique described by Kennedy et al.⁷ The endoscopic transnasal approach was used with complete anterior and posterior ethmoidectomy and wide middle meatus antrostomy to expose the medial and inferior orbital wall. The medial wall over the anterior and posterior ethmoid sinuses was removed to the skull base superiorly and posteriorly to the optic nerve canal. As much of the medial floor of the orbit that could be removed with a curved bone curette from the middle meatus antrostomy was removed, and the periorbitum was removed to allow for maximum expansion of the orbital content. The middle turbinate and orbital fat were preserved for all patients. After orbital decompression, orbital fat was observed to be herniated into the nasal cavity, as shown in Fig 1. A postoperative CT scan of a patient showing removal of the medial wall and medial floor of the right and left orbits to allow for herniation of the orbital contents into the ethmoid and maxillary sinuses is seen in Fig 2.

Results

Of the 23 orbital decompressions, there were no intra-operative complications, including haemorrhage, infra-orbital or optic nerve damage, or lacrimal duct injury. The

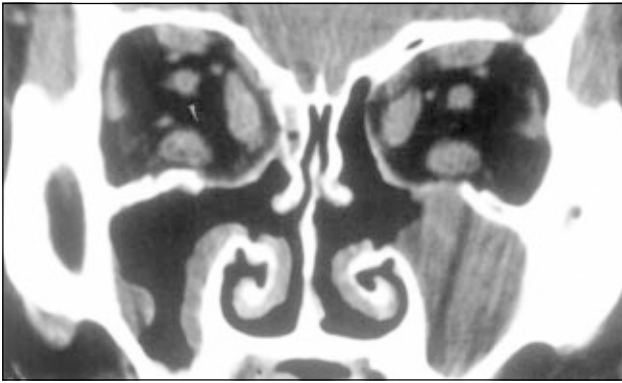


Fig 2. Postoperative coronal computed tomography scan of a patient

The medial wall and medial floor of the right and left orbits were removed to allow for herniation of orbital contents into the ethmoid and maxillary sinuses

only long-term complication was the development of diplopia for some patients. The mean preoperative proptosis was 24 mm (range, 19-27 mm). Proptosis reduction was achieved in 22 (96%) eyes. Of these 22 eyes, the mean proptosis reduction was 4.6 mm (median, 5.0 mm; range, 1.0-8.0 mm). No patient had developed further deterioration of proptosis at follow-up. The median follow-up was 32 months.

The mean preoperative IOP was 25 mm Hg (median, 22 mm Hg; range, 16-50 mm Hg) and 10 eyes had IOPs of more than 20 mm Hg. The postoperative IOPs were measured during each follow-up visit. The mean lowest postoperative IOP was 16 mm Hg (median, 16 mm Hg; range, 12-21 mm Hg). The postoperative IOPs decreased after surgical decompression in 20 (87%) eyes with a mean decrease of 11 mm Hg (median, 6 mm Hg; range, 1-35 mm Hg). Of the 10 eyes that had preoperative IOPs of more than 20 mm Hg (mean, 29 mm Hg; median, 24 mm Hg; range, 21-50 mm Hg), all had postoperative reductions of IOP to below 20 mm Hg (mean, 15 mm Hg; median, 15 mm Hg; range, 12-18 mm Hg). One patient with a preoperative IOP of 50 mm Hg in both eyes achieved lowest postoperative IOPs of 15 mm Hg and 16 mm Hg, which remained stable at 20 mm Hg or below at all follow-up visits. All except one patient had stable postoperative IOPs of less than 20 mm Hg without medication until the last follow-up visit. Both eyes of one patient relapsed 18 months after the operation, with IOPs increasing from 20 mm Hg and 19 mm Hg to 36 mm Hg in both eyes despite the proptosis reduction of 2 mm and 1 mm and VA improvement of 1 line for one eye. The patient refused further orbital decompression and was treated conservatively with oral steroid until the last follow-up visit, at which time the IOPs of both eyes had decreased to 20 mm Hg.

Incomplete eyelid closure was evident in 15 eyes with exposure keratitis before the operation, and the mean gap was 2.3 mm (median, 3.7 mm; range, 2.0-8.0 mm). After orbital decompression, 11 (73%) eyes had complete eyelid closure. Of the remaining four eyes with incomplete closure,

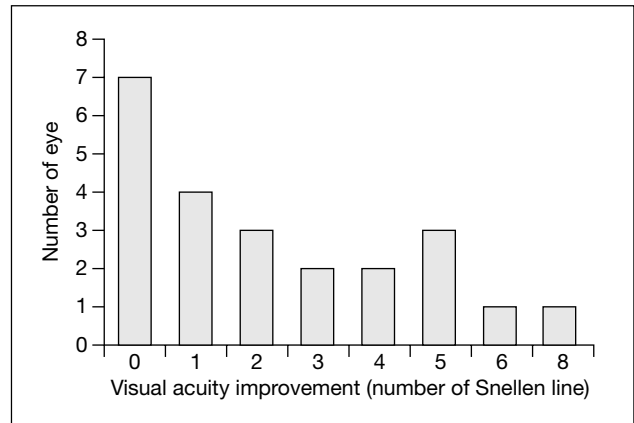


Fig 3. Visual acuity improvement

the gaps were reduced from 5 mm to 2 mm for two eyes, from 5 mm to 3 mm for one eye, and from 4 mm to 2 mm for one eye. One patient subsequently had levator recession and one had ectropion correction surgery.

The median preoperative VA was 6/15 (range from hand movement to 6/7.5). The median postoperative VA was 6/8.5 (range from 6/60 to 6/6). The VA improvement is shown in Fig 3. The VA improved in 16 (70%) eyes, for which the median improvement was 3 Snellen lines (range, 1-8 lines). The patient with the maximum improvement of 8 Snellen lines had VA changes from finger counting to 6/7.5. Patients with VA improvement had a mean IOP reduction of 10.3 mm Hg and mean reduction of proptosis of 4.3 mm compared with a mean IOP reduction of 3.5 mm Hg and a mean reduction of proptosis of 2.8 mm for those patients without VA improvement (*t* test; *P*=0.274 and 0.082, respectively).

Diplopia was present before the operation in nine patients (five diffuse, one at upward gaze, one at upward and lateral gazes, one at downward and lateral gazes, and one at upward, downward, and lateral gazes). One patient had reduced severity of diplopia after surgery and the other eight patients had no change in diplopia severity. Of the five patients who had no diplopia before the operation, three patients had diplopia after the operation (all at lateral gaze). Muscle realignment was performed for six patients between 6 and 20 months after the orbital decompression. All six patients had improvement of diplopia after muscle realignment.

All patients had a history of preoperative failed steroid treatment, either intermittent or continuous. The mean total duration of steroid treatment was 10 months (median, 6 months; range, 2 days-36 months). Postoperatively, all patients could stop the steroid treatment—three patients stopped the steroid therapy immediately after the operation and nine patients gradually stopped from 6 weeks to 18 months (median, 6 months) after surgery. The patient with IOPs increasing from 20 mm Hg and 19 mm Hg to 36 mm Hg in both eyes during follow-up had stopped taking oral steroid 5 months postoperatively but had to restart oral

steroid because of relapse of orbitopathy and increasing IOPs. This patient was the only patient to relapse after initial satisfactory improvement. The patient was still taking steroids at the last follow-up 30 months after operation. No patient was given cyclosporin after operation.

Discussion

Orbital decompression aims to remove the orbital wall to allow for expansion of the increased volume of the orbital contents. Of the four walls surrounding the orbital contents, one or more may be removed for orbital decompression. The superior wall may be approached by craniotomy. This is, however, not recommended because of the significant morbidity associated with brain pulsation to the orbital contents, cerebrospinal fluid leakage, and meningitis.¹⁴ The lateral wall may be decompressed simply by lateral orbitotomy, although there is limited space for the lateral expansion of the orbital contents by orbitotomy alone and a small scar is created on the face. More lateral space may be created by scraping out the zygoma. The amount of empty space created is, however, limited and there is a potential complication of pulsating proptosis associated with contraction of the temporalis muscle during mastication. The inferior wall is a good site for decompression because there is a large empty antral space to accommodate the orbital contents. The infra-orbital nerve is situated in the floor of the orbital wall, however, and is prone to damage resulting in numbness of the face and upper alveolus. The medio-inferior wall together with the medial wall and floor of the orbit medial to the infra-orbital nerve is a good site for decompression since there is adequate space for the orbital contents in the maxillary and ethmoid sinuses. There are no important structures within these spaces. If necessary, the removal of the wall of the orbit and optic canal over the sphenoid sinus

also allows for decompression. The initial choice of orbital decompression is, therefore, the removal of the medial wall and inferior wall medial to the infra-orbital nerve.

Removal of the medial wall and medial floor of the orbit can be done by the transantral, transconjunctival, or transnasal routes. The transantral route has disadvantages of causing infra-orbital nerve damage, postoperative facial swelling, and inadequate access to the posterior part of the medial wall.^{15,16} The transconjunctival approach has disadvantages of limited exposure and access to the posterior part of the ethmoid and sphenoid region.¹³ This route is used mainly as an adjunct to other decompression approaches in patients who require additional decompression of the lateral orbital floor and the lateral wall. The transnasal route is the preferred surgical approach.⁷ This route has the additional advantage of good access to the posterior medial wall for orbital and optic nerve decompression without the disadvantage of the other two routes.

With the advent of video-endoscopic sinus surgery techniques, the endoscopic transnasal approach has become a feasible alternative to the other approaches. Most surgeons would perform transnasal medio-inferior wall and lateral orbitotomy together. There are only limited reports on the use of transnasal orbital decompression alone. Table 1 shows a summary of the results of this study and reports from the literature of endoscopic decompression alone. The overall mean proptosis reduction is 4.6 mm. Large reductions of up to 8 mm are possible with this approach alone. Of those patients with exposure keratitis, 73% had complete closure of the eyelid after the operation. The results of endoscopic transnasal decompression alone for proptosis and exposure keratitis are satisfactory for most patients. Table 2 shows the literature review of results of combined transnasal

Table 1. Literature review of endoscopic transnasal orbital decompression

Study	No. of orbital decompressions	Proptosis reduction Mean (range) [mm]	Visual acuity improvement No. (%)
Kennedy et al, 1990 ⁷	5	4.7 (3.0-6.0)	4 (80.0)
Metson et al, 1995 ⁸	8	3.5 (2.2-4.8)	-
Neugebauer et al, 1996 ⁹	36	3 (0-6.5)	-
Koay et al, 1997 ¹⁰	30	3.9 (2.0-8.0)	2 (6.7)
Lund et al, 1997 ¹¹	24	4.4 (1.0-10.0)	-
Present study	23	4.6 (1.0-8.0)	16 (69.6)

Table 2. Literature review of other orbital wall decompression procedures

Study	Orbital decompression No. (type)	Proptosis reduction Mean (range) [mm]	Visual acuity improvement No. (%)
Kennedy et al, 1990 ⁷	6 (transnasal and lateral orbitotomy)	5.7 (4.0-7.0)	Preoperative abnormal: 1 improvement, 1 same; Preoperative normal: 3 no change, 1 worse
Metson et al, 1995 ⁸	33 (transnasal and lateral wall)	5.4 (2.0-9.0)	-
Ulualp et al, 1999 ¹²	28 (transnasal and lateral wall)	4 (3 orbits increased: 0.5, 1, and 1)	-
Sillers et al, 1997 ¹³	2 (transnasal and lateral wall)	4.5 (2-7)	-
Garrity et al, 1993 ¹⁵	727 (transantral inferior and medial wall)	4.7 (1 increased: 2; 2 increased: 1; maximum reduction: 12)	Preoperative normal: 15% worse; Preoperative abnormal: 65% better, 24% same, 11% worse
Warren et al, 1989 ¹⁶	305 (transantral inferior and medial wall)	4.0 (1.0-12.0)	5 worse to become blind (% improvement not mentioned)

orbital decompression with lateral orbitotomy or external lateral decompression and transantral decompression. There is additional decompression with the lateral inferior and lateral wall decompression procedure. Although the efficacy of various operations can only be resolved by well-conducted prospective randomised studies, the number of patients who need surgical decompression is small, so it would be difficult to conduct more powerful randomised trials to compare the various surgical options and treatments. Although the removal of more of the orbital wall can create more space and should be able to further decompress the orbit, the results of this study show that additional removal of the lateral orbital floor, lateral orbitotomy, or zygoma reduction is only indicated for a small percentage of patients for whom surgery is unsuccessful or who relapse after transnasal medio-inferior decompression.

The endoscopic transnasal approach has the additional advantage of decompression to the more posterior part of the orbit and optic canal in the posterior ethmoid and sphenoid sinuses. Visual acuity improvement is more difficult to compare among different approaches and among individual patients because the recovery of VA also depends on the degree of irreversible damage to the optic nerve. It is likely that patients with long-standing optic nerve compression and poor VA have a lower chance of complete recovery. Great improvement from finger counting to 6/7.5 was, however, possible for one patient with early surgical decompression.

Conclusion

Endoscopic transnasal medio-inferior orbital wall decompression alone is a safe and effective treatment for thyrotoxic exophthalmos causing proptosis, exposure keratitis, and visual loss. Additional orbital wall decompression is indicated only for a small number of patients for whom surgery is unsuccessful or who relapse after initial endoscopic transnasal orbital decompression.

References

1. Fells P. Thyroid-associated eye disease: clinical management. *Lancet* 1991;338:29-32.
2. Kung WC. Cytokines and hormonal regulations. *Curr Opin Endocrinol Diabetes* 1999;6:77-83.
3. Kung WC. Recent progress in the management of Graves' Disease. *Medical Progress* 2000;27:21-6.
4. Weetman AP. Thyroid-associated eye disease: pathophysiology. *Lancet* 1991;338:25-8.
5. Kazim M, Goldberg RA, Smith TJ. Insights into the pathogenesis of thyroid-associated orbitopathy: evolving rationale for therapy. *Arch Ophthalmol* 2002;120:380-6.
6. Prummel MF, Mourits MP, Berghout A, et al. Prednisone and cyclosporine in the treatment of severe Graves' ophthalmopathy. *N Engl J Med* 1989;321:1353-9.
7. Kennedy DW, Goodstein ML, Miller NR, Zinreich SJ. Endoscopic transnasal orbital decompression. *Arch Otolaryngol Head Neck Surg* 1990;116:275-82.
8. Metson R, Shore JW, Gliklich RE, Dallow RL. Endoscopic orbital decompression under local anesthesia. *Otolaryngol Head Neck Surg* 1995;113:661-7.
9. Neugebauer A, Nishino K, Neugebauer P, Konen W, Michel O. Effects of bilateral orbital decompression by an endoscopic endonasal approach in dysthyroid orbitopathy. *Br J Ophthalmol* 1996;80:58-62.
10. Koay B, Bates G, Elston J. Endoscopic orbital decompression for dysthyroid eye disease. *J Laryngol Otol* 1997;111:946-9.
11. Lund VJ, Larkin G, Fells P, Adams G. Orbital decompression for thyroid eye disease: a comparison of external and endoscopic techniques. *J Laryngol Otol* 1997;111:1051-5.
12. Ulualp SO, Massaro BM, Toohill RJ. Course of proptosis in patients with Graves' disease after endoscopic orbital decompression. *Laryngoscope* 1999;109:1217-22.
13. Sillers MJ, Cuijly-Siller C, Kuhn FA, Porubsky ES, Morpeth JF. Transconjunctival endoscopic orbital decompression. *Otolaryngol Head Neck Surg* 1997;117(Suppl):137S-41S.
14. Naffziger HC. Progressive exophthalmos following thyroidectomy: its pathology and treatment. *Ann Surg* 1931;94:582-6.
15. Garrity JA, Fatourechi V, Bergstralh EJ, et al. Results of transantral orbital decompression in 428 patients with severe Graves' ophthalmopathy. *Am J Ophthalmol* 1993;116:533-47.
16. Warren JD, Spector JG, Burde R. Long-term follow-up and recent observations on 305 cases of orbital decompression for dysthyroid orbitopathy. *Laryngoscope* 1989;99:35-40.